MEDICAL TERMINOLOGY FOR HEALTHCARE PROFESSIONS

Andrea Nelson and Katherine Greene
University of West Florida

LibreTexts™

Medical Terminology for Healthcare Professions (Nelson and Greene)

This text is disseminated via the Open Education Resource (OER) LibreTexts Project (https://LibreTexts.org) and like the thousands of other texts available within this powerful platform, it is freely available for reading, printing, and "consuming."

The LibreTexts mission is to bring together students, faculty, and scholars in a collaborative effort to provide an accessible, and comprehensive platform that empowers our community to develop, curate, adapt, and adopt openly licensed resources and technologies; through these efforts we can reduce the financial burden borne from traditional educational resource costs, ensuring education is more accessible for students and communities worldwide.

Most, but not all, pages in the library have licenses that may allow individuals to make changes, save, and print this book. Carefully consult the applicable license(s) before pursuing such effects. Instructors can adopt existing LibreTexts texts or Remix them to quickly build course-specific resources to meet the needs of their students. Unlike traditional textbooks, LibreTexts' web based origins allow powerful integration of advanced features and new technologies to support learning.

LibreTexts is the adaptable, user-friendly non-profit open education resource platform that educators trust for creating, customizing, and sharing accessible, interactive textbooks, adaptive homework, and ancillary materials. We collaborate with individuals and organizations to champion open education initiatives, support institutional publishing programs, drive curriculum development projects, and more.

The LibreTexts libraries are Powered by NICE CXone Expert and were supported by the Department of Education Open Textbook Pilot Project, the California Education Learning Lab, the UC Davis Office of the Provost, the UC Davis Library, the California State University Affordable Learning Solutions Program, and Merlot. This material is based upon work supported by the National Science Foundation under Grant No. 1246120, 1525057, and 1413739.

Any opinions, findings, and conclusions or recommendations expressed in this material are those of the author(s) and do not necessarily reflect the views of the National Science Foundation nor the US Department of Education.

Have questions or comments? For information about adoptions or adaptions contact info@LibreTexts.org or visit our main website at https://LibreTexts.org.

The LibreTexts name, logo, and book covers are trademarked by LibreTexts, Inc. (a 501(c)(3) not-for-profit organization) and protected against unauthorized use.

This text was compiled on 09/04/2026

TABLE OF CONTENTS

Introduction

Acknowledgements

Licensing

Chapters

1.1: Word Parts and Rules

1.2: Prefixes and Suffixes

1.3: Body Terminology

1.4: Sensory Systems

1.5: Integumentary System

1.6: Skeletal System

1.7: Muscular System

1.8: Nervous System

1.9: Cardiovascular System

1.10: Blood Vessels and Blood

1.11: Lymphatic and Immune Systems

1.12: Respiratory System

1.13: Digestive System

1.14: Endocrine System

1.15: Urinary System

1.16: Male Reproductive System

1.17: Female Reproductive System

1.18: Obstetrics

Index

Glossary

Detailed Licensing

This page titled Medical Terminology for Healthcare Professions (Nelson and Greene) is shared under a CC BY 4.0 license and was authored, remixed, and/or curated by Andrea Nelson and Katherine Greene via source content that was edited to the style and standards of the LibreTexts platform.

Introduction

Welcome to ***Medical Terminology for Healthcare Professions***. Medical terminology is a language that is used in healthcare settings. Medical terms are built from Greek and Latin word parts and include acronyms, eponyms, and modern-day language terms.

Learning a new language can be a daunting task. This book offers methods for breaking down medical words and making them more manageable. To be successful, you will need to be committed to memorizing the word parts, learning the rules, and identifying the rebels. Once you meet that commitment we will show you how to apply the rules to the word parts you have memorized. As you memorize the language components of medical terminology it is important to support that learning with the context of anatomy and physiology. Consider where in the body the medical term is referencing and then how it works within the body. This will build a medical terminology foundation that you can continue to grow in your future healthcare courses.

How Open Educational Resources (OER) work

This book is an adaptation of *Building a Medical Terminology Foundation,* published by Carter and Rutherford at eCampus Ontario with revisions in text and activities for clarification and flow. The anatomy and physiology content of this OER has been adapted from the OpenStax *Anatomy and Physiology* OER by Betts et al. Both books are licensed under a Creative Commons Attribution 4.0 International License and in the spirit of OPEN education we have licensed this OER with the same license.

Building a Medical Terminology Foundation Book Citation:

Carter, K., & Rutherford, M. (2020). *Building a Medical Terminology Foundation*. eCampus Ontario. https://ecampusontario.pressbooks.pub/medicalterminology/

Anatomy and Physiology Book Citation:

Betts, J.G., et al. (2013). *Anatomy and Physiology*. OpenStax. http://cnx.org/content/col11496/latest/

Students: This OER book is different from many traditional medical terminology textbooks. Interactive content is built into each chapter that is available only in the online format. If using a PDF copy or EPUB version of this book, you will be directed to a hyperlink to access the interactive content. Further, glossary terms will be bolded in green and their definitions can be found in the glossary at the end of the book. In this book you will work through each body system that includes word parts, whole medical terms, and common abbreviations associated with that particular body system. At the end of each body system chapter is a vocabulary list of associated terms related to that body system. The interactive reinforcement activities require you to click, drag and drop, listen and repeat, flip, and test yourself.

Faculty and teaching staff: While this OER book was curated and created for Healthcare Administration, Health Sciences, and Pre-Professional students, our hope is that you will take this OER and customize it for your program and share again.

Medical Terminology for Healthcare Professions Book Citation:

Nelson, A., & Greene, K. (2021). *Medical Terminology for Healthcare Professions*. University of West Florida Pressbooks. https://pressbooks.uwf.edu/medicalterminology/

***Other formats available upon request

This page titled Introduction is shared under a CC BY 4.0 license and was authored, remixed, and/or curated by Andrea Nelson and Katherine Greene via source content that was edited to the style and standards of the LibreTexts platform.

Acknowledgements

Ever since attending an Open Educational Resources (OER) workshop in 2019, I (Andrea) have always wanted to make an OER medical terminology book. I have been searching for years for the right OER book and, finally in Spring of 2021, my co-author (Katherine) found *Building a Medical Terminology Foundation* by Kimberlee Carter and Marie Rutherford. Their book was just what we had been searching for. We are so grateful for all of their hard work on creating such a wonderful book. By chance in the Fall of 2021 our university signed a contract with *Pressbooks* and the Health Sciences librarian, Cindy Gruwell, was experienced with the process. While the book provided us with an excellent foundation, Katherine and I worked very hard to create a text that would best serve future healthcare students. We are so happy that the creation of this book will save our students here, and elsewhere, on textbook costs while also allowing them to have continued access to this book after their course ends.

Andrea M. Nelson, PT, DPT, GCS, CLT, University of West Florida

Katherine Greene, MPH, University of West Florida

Thanks and Gratitude

We give the biggest thanks and appreciation to **Kimberlee Carter**, of Conestoga College ITAL, and **Marie Rutherford**, of Georgian College CAAT, for creating the OER book, *Building a Medical Terminology Foundation,* from which our book was based.

We wish to thank **Stephanie Clark**, Dean of Libraries at the University of West Florida, for encouraging faculty to create and use OER materials in their courses and for establishing a relationship with *Pressbooks*.

We extend our gratitude to **Cindy Gruwell**, Asst. Librarian/Coordinator of Scholarly Communication and Health Sciences Librarian at the University of West Florida, for all of her support, assistance, and guidance through the process of revising, updating, and publishing our OER book.

We appreciate the support of **Angela Hahn**, Chair of the Health Sciences and Administration Department at the University of West Florida, in taking on this project to lessen textbook costs for students across campus taking our Medical Terminology course.

We would also like to thank **Karen Valaitis**, Clinical Assistant Professor in the Health Sciences and Administration Department at the University of West Florida, for her continued advocacy and push in our department for adopting OER materials for our students.

We also extend thanks to **Kylie Pugh**, Instructional Designer at the University of West Florida's Center for Teaching Learning and Technology, for her design and editing help.

Lastly, we would like to acknowledge **Denise Seabert**, Dean of the College of Health and Human Services at Fresno State University. Without her encouragement, we would not have been brought together. We truly appreciate all that you have done for both of us.

This page titled Acknowledgements is shared under a CC BY 4.0 license and was authored, remixed, and/or curated by Andrea Nelson and Katherine Greene via source content that was edited to the style and standards of the LibreTexts platform.

Licensing

A detailed breakdown of this resource's licensing can be found in ***Back Matter/Detailed Licensing****.*

This page titled Licensing is shared under a CC BY 4.0 license and was authored, remixed, and/or curated by Andrea Nelson and Katherine Greene via source content that was edited to the style and standards of the LibreTexts platform.

CHAPTERS

1.1: Word Parts and Rules
1.2: Prefixes and Suffixes
1.3: Body Terminology
1.4: Sensory Systems
1.5: Integumentary System
1.6: Skeletal System
1.7: Muscular System
1.8: Nervous System
1.9: Cardiovascular System
1.10: Blood Vessels and Blood
1.11: Lymphatic and Immune Systems
1.12: Respiratory System
1.13: Digestive System
1.14: Endocrine System
1.15: Urinary System
1.16: Male Reproductive System
1.17: Female Reproductive System
1.18: Obstetrics

This page titled Chapters is shared under a CC BY 4.0 license and was authored, remixed, and/or curated by Andrea Nelson and Katherine Greene.

1.1: Word Parts and Rules

Learning Objectives

- Identify word parts in medical terms.
- Examine the rules for building medical terms.

Word Parts

Medical terms are built from word parts. Those word parts are prefix, word root, suffix, and combining form vowel. When a word root is combined with a combining form vowel the word part is referred to as a combining form.

Query 1.1.1

This interactive element is not available in this format. Visit the link or scan the QR code to access it online.

View this Interactive Content online

Identifying Word Parts in Medical Terms

By the end of this book, you will have identified hundreds of word parts within medical terms. Let's start with some common medical terms that many non-medically trained people may be familiar with.

Examples

Osteoarthritis
Oste/o/arthr/itis – Inflammation of bone and joint.
Oste/o is a combining form that means bone
arthr/o is a combining form that means joint
-itis is a suffix that means inflammation

Intravenous
Intra/ven/ous – Pertaining to within a vein.
Intra- is a prefix that means within
ven/o – is a combining form that means vein
-ous is a suffix that means pertaining to

Notice, when breaking down words that you place slashes between word parts and a slash on each side of a combining form vowel.

Language Review

Before we begin analyzing the rules let's complete a short language review that will assist with pronunciation and spelling.

Short Vowels

a, e, i, o, u, and sometimes y are indicated by lower case.

Long Vowels
A, E, I, O, U are indicated by upper case.

Consonants
Consonants are all of the other letters in the alphabet. b, c, d, f, g, h, j, k, l, m, n, p, q, r, s, t, v, w, x, and z.

Language Rules

Language rules are a good place to start when building a medical terminology foundation. Many medical terms are built from word parts and can be translated literally. At first, literal translations sound awkward. Once you build a medical vocabulary and become proficient at using it, the awkwardness will slip away. For example, suffixes will no longer be stated and will be assumed. The definition of *intravenous* then becomes *within the vein*.

Since you are at the beginning of building your medical terminology foundation, stay literal when applicable. It should be noted that as with all language rules there are always exceptions and we refer to those as rebels.

Language Rules for Building Medical Terms

1. When combining two combining forms, you keep the combining form vowel.
2. When combining a combining form with a suffix that begins with a consonant, you keep the combining form vowel.

   Examples

   Gastr/o/enter/o/logy – The study of the stomach and the intestines

   - Following **rule 1,** when we join combining form gastr/o (meaning stomach) with the combining form enter/o (meaning intestines) we keep the combining form vowel o.
   - Following **rule 2**, when we join the combining form enter/o (meaning intestines) with the suffix -logy (that starts with a suffix and means the study of) we keep the combining form vowel o.

3. When combining a combining form with a suffix that begins with a vowel, you drop the combining form vowel.
4. A prefix goes at the beginning of the word and no combining form vowel is used.

   Examples

   Intra/ven/ous – Pertaining to within the vein

   - Following **rule 3**, notice that when combining the combining form ven/o (meaning vein) with the suffix -ous (that starts with a vowel and means pertaining to) we drop the combining form vowel o.
   - Following **rule 4**, the prefix intra- (meaning within) is at the beginning of the medical term with no combining form vowel used.

5. When defining a medical word, start with the suffix first and then work left to right stating the word parts. You may need to add filler words. As long as the filler word does not change the meaning of the word you may use it for the purpose of building a medical vocabulary. Once you start to apply the word in the context of a sentence it will be easier to decide which filler word(s) to choose.

   Examples

   Intra/ven/ous – Pertaining to within the vein or Pertaining to within a vein.

   - Following **rule 5**, notice that I start with the suffix -ous (that means pertaining to) then we work left to right starting with the prefix Intra- (meaning within) and the combining form ven/o (meaning vein).

- Notice that we have used two different definitions that mean the same thing.
- In these examples we do not have the context of a full sentence. For the purpose of building a medical terminology foundation either definition is accepted.

This page titled 1.1: Word Parts and Rules is shared under a CC BY 4.0 license and was authored, remixed, and/or curated by Andrea Nelson and Katherine Greene via source content that was edited to the style and standards of the LibreTexts platform.

1.2: Prefixes and Suffixes

Learning Objectives

- Understand the difference between a prefix and a suffix.
- Differentiate prefixes that deal with body parts, color, and direction.
- Distinguish suffixes that deal with procedures.

Prefixes

Prefixes are located at the beginning of a medical term. The prefix alters the meaning of the medical term. It is important to spell and pronounce prefixes correctly.

Many prefixes that you find in medical terms are common to English language prefixes. A good technique to help with memorization is the following:

- Start by reviewing the most common prefixes.
- Consider common English language words that begin with the same prefixes.
- Compare them to the examples of use in medical terms.

Common Prefixes

PREFIX	MEANING	EXAMPLE OF USE IN MEDICAL TERMS
A-, An-	Without; Lacking	Anemia
Andr/o-	Male	Androgen
Anti-	Against	Anticholinergic drugs
Auto-	Self	Autocrine
Bio-	Life	Biology
Chem/o-	Chemistry	Chemotherapy
Contra-	Against	Contraception
Cyt/o-	Cell	Cytokine
Dis-	Separation; Taking apart	Dissection
Dys-	Difficult; Abnormal	Dyspnea
Eu-	Good; Well	Eupnea
Fibr/o-	Fiber	Fibrosis
Gluco-, Glyco-	Glucose; Sugar	Glycogen
Gyn/o-, Gynec-	Female	Gynecology
Hydr/o-	Water	Hydrocephalus
Idio-	Self; One's own	Idiopathic
Lyso-, Lys-	Break down; Destruction; Dissolving	Lysosome

PREFIX	MEANING	EXAMPLE OF USE IN MEDICAL TERMS
Mal-	Bad; Abnormal	Malignant
Myc/o-	Fungus	Mycetoma
Necr/o-	Death	Necrosis
Neo-	New	Neonate
Oxy-	Sharp; Acute; Oxygen	Oxytocin
Pan-, Pant/o-	All or everywhere	Pancytopenia
Pharmaco-	Drug; Medicine	Pharmacist
Re-	Again; Backward	Rejuvenation
Somat/o-, Somatico-	Body; Bodily	Somatic cell

Body Part Prefixes

PREFIX	MEANING	EXAMPLE OF USE IN MEDICAL TERMS
Acous/o-	Hearing	Acoustic meatus
Aden/o-	Gland	Adenoid
Adip/o-	Fat	Adipocyte
Adren/o-	Gland	Adrenal cortex
Angi/o-	Blood vessel	Angioplasty
Arteri/o-	Artery	Arteriole
Arthr/o-	Joint	Arthroplasty
Bucc/o-	Cheek	Buccal cavity
Bronch/i-	Bronchus	Bronchioles
Burs/o-	Bursa	Bursa
Carcin/o-	Cancer	Basal cell carcinoma
Cardi/o-	Heart	Cardiology
Cephal/o-	Head	Cephalic flexure
Chol-	Bile	Cholesterol
Chondri-	Cartilage	Chondrosarcoma
Coron-	Heart	Coronary arteries
Cost-	Rib	Costal cartilage
Crani/o-	Brain	Cranium
Cutane-	Skin	Cutaneous
Cyst/o-, Cysti-	Bladder or sac	Cystoscopy
Derm-, Dermat/o-	Skin	Dermatologist

Duoden/o-	Duodenum	Duodenitis
Gastr-	Stomach	Gastrectomy
Gloss-	Tongue	Glossectomy
Hem-, Hema-, Hemat-, Hemo-, Hemat/o-	Blood	Hematopoiesis
Hepat/o-, Hepatico-	Liver	Hepatic portal system
Hist/o-, Histio-	Tissue	Histology
Hyster/o-	Uterus	Hysterectomy
Ileo-	Ileum	Ileostomy
Ischi/o-	Ischium	Ischial tuberosity
Kerat/o-	Corena (eye or skin)	Keratin
Lacrim/o-	Tear (from your eyes)	Lacrimal fluid
Lact/o-, Lacti-	Milk	Lactose
Laryng/o-	Larynx	Laryngitis
Lingu/o-	Tongue	Lingual tonsil
Lip/o-	Fat	Lipolysis
Lymph/o-	Lymph	Lymphocyte
Mamm-, Mast/o-	Breast	Mammary glands
Mening/o-	Meninges	Meningitis
Muscul/o-	Muscle	Musculoskeletal
My/o-	Muscle	Myocardium
Myel/o-	Spinal cord or bone marrow	Myelin
Nephr/o-	Kidney	Nephron
Neur/i-, Neur/o-	Nerve	Neuron
Oculo-	Eye	Oculomotor nerve
Onco-	Tumor; Bulk; Volume	Oncogene
Onych/o-	Fingernail; Toenail	Onychodystrophy
Oo-	Egg; Ovary	Oocyte
Oophor/o-	Ovary	Oophorectomy
Op-, Opt-	Vision	Optic nerve
Ophthalm/o-	Eye	Ophthalmic artery
Orchid/o-, Orchio-	Testis	Orchidectomy

Orth/o-	Straight; Normal; Correct	Orthostatic
Osseo-	Bony	Osseous tissue
Ossi-	Bone	Ossicles
Ost-, Oste/o-	Bone	Osteoporosis
Ot/o-	Ear	Otolaryngologist
Ovar/i-, Ovario-, Ovi-, Ovo-	Ovary	Ovarian follicle
Phalang-	Phalanx	Phalanges
Pharyng/o-	Pharynx; Throat	Pharyngeal tonsil
Phleb/o-	Vein	Phlebotomist
Phren/i-, Phreno-, Phrenico-	Diaphragm	Phrenic nerve
Pleur-, Pleur/a-, Pleur/o-	Rib, pleura	Pleural cavity
Pneum/a- Pneumat/o-	Air; Lung	Pneumonia
Proct/o-	Anus; Rectum	Proctoscopy
Prostat-	Prostate	Prostatectomy
Pseudo-	False	Pseudostratified
Psych/o-, Psyche-	Mind	Psychiatrist
Radio-	Radiation; Radius	Radioisotopes
Ren/o-	Kidney	Renal cortex
Retin-	Retina (of the eye)	Retinitis pigmentosa
Rhin/o-	Nose	Rhinoscope
Salping/o-	Tube	Salpingo-oophorectomy
Sarco-	Muscular; Flesh-like	Sarcomere
Schiz/o-	Split; Cleft	Schizophrenia
Sclera-, Sclero-	Hardness	Sclerosis
Sigmoid/o-	Sigmoid colon	Sigmoidoscopy
Sperma-, Spermo-, Spermato-	Sperm	Spermatocyte
Splen/o-	Spleen	Splenomegaly
Sten/o-	Narrowed; Blocked	Stenosis
Stern-	Sternum	Sternoclavicular joint
Stom/a-, Stomat/o-	Mouth	Stomatitis
Thorac/o-, Thoracico-	Chest	Thoracic cavity
Thromb/o-	Blood clot	Thrombolytic

Thyr/o-	Thyroid gland	Thyroiditis
Trache/o-	Trachea	Trachealis
Tympan/o-	Eardrum	Tympanic membrane
Ur/o-	Urine	Urologist
Vagin-	Vagina	Vaginal
Varic/o-	Duct; Blood vessel	Varicose veins
Vasculo-	Blood vessel	Vasculitis
Ven/o-	Vein	Venae cavae
Vertbr-	Vertebra; Spine	Vertebral column

Color Prefixes

PREFIX	MEANING	EXAMPLE OF USE IN MEDICAL TERMS
Chlor/o-	Green	Chlorophyll
Chrom-, Chromato-	Color	Chromosome
Cyano-	Blue	Cyanosis
Erythr/o-	Red	Erythrocyte
Leuk/o-	White	Leukocyte
Melan/o-	Black	Melanin

Physical Property and Shape Prefixes

PREFIX	MEANING	EXAMPLE OF USE IN MEDICAL TERMS
Cry/o-	Cold	Cryotherapy
Elect-	Electrical activity	Electrocardiogram
Kin/o-, Kine-, Kinesi/o-	Movement	Kinetic energy
Kyphy/o-	Humped	Kyphosis
Rhabd/o-	Rod-shaped; Striated	Rhabdomyosarcoma
Phot/o-	Light	Photoreceptor
Reticul/o-	Net	Reticulocytes
Scoli/o-	Twisted	Scoliosis
Therm/o-	Heat	Thermotherapy

Direction and Position Prefixes

PREFIX	MEANING	EXAMPLE OF USE IN MEDICAL TERMS
Ab-, Abs-	Away from	Abductor
Ad-	Towards	Adductor
Ante-	Before; Forward	Antenatal
Circum-	Around	Circumcision
Cycl-	Circle; Cycle	Cyclic neutropenia
De-	Away from; Ending	Dehydration
Dia-	Across; Through	Diagnosis
Ect/o-, Exo-	Outer; Outside	Exocrine gland
End/o-, Ent-, Enter/o-	Within; Inner	Endocrine gland
Epi-	Upon; Outside of	Epidermis
Ex-, Extra-	Beyond	Expiration
Infra-	Beneath; Below	Infratemporal fossa
Inter-	Between	Interstitial fluid
Intra-	Within	Intracellular fluid
Meso-	Middle	Mesoderm
Meta-	Beyond; Change	Metabolism
Para-	Alongside; Abnormal	Parathyroid glands
Path/o-	Disease	Pathologist
Peri-	Around	Pericardium
Post-	Behind; After	Postpartum
Pre-	Before; In front	Precancerous
Retro-	Backward; Behind	Retroperitoneum
Sub-	Under	Subcutaneous layer
Super-	Above	Superior
Supra-	Above; Upon	Supraglottis
Sy-, Syl-, Sym-, Syn-, Sys-	Together	Syndrome
Trans-	Across; Through	Transdermal

Quantity Prefixes

PREFIX	MEANING	EXAMPLE OF USE IN MEDICAL TERMS
Bi-	Two	Biceps

Brady-	Slow	Bradycardia
Diplo-	Double	Diploid
Hemi-	Half	Hemihypertrophy
Hetero-	Other; Different	Heterogeneous
Homo-	Same	Homozygous genotype
Hyper-	Above; Beyond; Excessive	Hypertension
Hypo-	Under; Deficient	Hypotension
Iso-	Equal; Like	Isointense
Macro-	Large; Long; Big	Macrophage
Mic-, Micro-	Small	Microglia
Mon-, Mono-	One	Monocyte
Olig/o-	Few; Little	Oliguria
Poly-	Many; Excessive	Polyuria
Quadri-	Four	Quadriceps
Semi-	Half	Semilunar valves
Tachy-	Fast	Tachycardia
Tetra-	Four	Tetralogy of Fallot
Tri-	Three	Triceps
Uni-	One	Unicellular

Concept Check

- Do you know the difference between the prefixes **inter-**, **infra-**, and **intra-**?
- What color is an erythrocyte? A leukocyte?
- Which prefixes could you use to indicate something is:
  - around something else?
  - within something else?
  - below something else?

Suffixes

Suffixes are word parts that are located at the end of words. Suffixes can alter the meaning of medical terms. It is important to spell and pronounce suffixes correctly.

Suffixes in medical terms are common to English language suffixes. Suffixes are not always explicitly stated in the definition of a word. It is common that suffixes will not be explicitly stated when defining a medical term in the workplace. However, when transcribing or reading medical reports the suffix is always clearly written. In order to properly spell and pronounce medical terms, it is helpful to learn the suffixes.

Common Suffixes

SUFFIX	MEANING	EXAMPLE OF USE IN MEDICAL TERMS
-ac	Pertaining to	Cardiac
-blast, -blasto, -blastic	Bud; Germ	Myeloblast
-cyte, -cytic	Cell	Thrombocyte
-dynia	Pain; Swelling	Thoracodynia
-eal, -ial	Pertaining to	Esophageal
-ectasis	Expansion; Dilation	Atelectasis
-emia	Blood condition	Anemia
-ia	Condition	Hemophilia
-iasis	Condition; Formation of	Psoriasis
-ism	Condition	Hypothyroidism
-ites, -itis	Inflammation	Arthritis
-ity	Pertaining to	Immunity
-ium	Structure or tissue	Epithelium
-lysis, -lytic	Break down; Destruction; Dissolving	Osteolytic
-malacia	Softening	Osteomalacia
-megaly	Enlargement	Acromegaly
-oid	Resembling	Arachnoid trabeculae
-oma	Tumor	Angiosarcoma
-osis	Condition; Usually abnormal	Endometriosis
-ous	Pertaining to	Aqueous
-pathy	Disease	Lymphadenopathy
-penia	Deficiency; Lack of	Thrombocytopenia
-phagia, -phagy	Eating; Swallowing	Dysphagia
-phasia	Speech	Aphasia
-plasia, -plastic	Growth	Hyperplasia
-plegia	Paralysis	Hemiplegia
-pnea	Breathing	Sleep apnea
-poiesis	Production	Hemopoiesis
-ptosis	Falling; Drooping	Apoptosis

-rrhage, -rrhagic	Bleeding	Hemorrhage
-rrhea	Flow or discharge	Diarrhea
-sclerosis	Hardening	Arteriosclerosis
-sis	Condition	Agranulocytosis
-stasis	Level; Unchanging	Homeostasis
-trophy	Growth	Hypertrophy
-uria	In the urine	Anuria

Procedure Suffixes

SUFFIX	MEANING	EXAMPLE OF USE IN MEDICAL TERMS
-centesis	Surgical puncture to remove fluid	Thoracentesis
-desis	Surgical binding	Pleurodesis
-ectomy	Cut out; Removal	Mastectomy
-gram	Record; Picture	Electrocardiogram
-graph	Instrument used to create a record or picture	Electrocardiograph
-graphy	To record or take a picture	Echocardiography
-meter	Device used for measuring	Sphygmomanometer
-opsy	Visual examination	Biopsy
-ostomy	Opening	Colostomy
-otomy	Incision	Laparotomy
-pexy	Surgical fixation	Oophoropexy
-plasty	Surgical reconstruction	Vertebroplasty
-scope	For examining	Endoscope
-scopy	Examine	Endoscopy

Concept Check

- Do you know the difference between the suffixes **-gram**, **-graph**, and **-graphy?**
- Which suffixes denote a condition or disease?

Word parts and definitions from "Appendix A: Word Parts and What They Mean" by MedlinePlus and is under public domain.

Definitions of medical term examples from:

- *Anatomy and Physiology* (on OpenStax), by Betts et al. and is used under a CC BY 4.0 international license. Download and access this book for free at https://openstax.org/books/anatomy-and-physiology/pages/1-introduction
- *Concepts of Biology* (on OpenStax), by Fowler et al. and is used under a CC BY 4.0 international license. Download and access this book for free at https://openstax.org/books/concepts-biology/pages/1-introduction

- *NCI Dictionary of Cancer Terms* by the National Cancer Institute and is used under public domain.

This page titled 1.2: Prefixes and Suffixes is shared under a CC BY 4.0 license and was authored, remixed, and/or curated by Andrea Nelson and Katherine Greene via source content that was edited to the style and standards of the LibreTexts platform.

1.3: Body Terminology

Learning Objectives

- Assess medical language learning to the context of anatomy and physiology
- Investigate the basic architecture and levels of organization of the human body
- Evaluate the anatomical position, regional terms, directional terms, body planes, and body quadrants for anatomical positioning
- Recall body cavities and the functions of associated membranes

As you memorize the language components of medical terminology, it is important to support that learning within the context of anatomy and physiology. Proceeding through the body system chapters, you will learn word parts, whole medical terms, and common abbreviations. It is important to put into context where in the body the medical term is referencing, and then consider how it works within the body.

Anatomy focuses on structure and **physiology** focuses on function. Much of the study of physiology centers on the body's tendency toward homeostasis.

Consider the structures of the body in terms of fundamental levels of organization that increase in complexity: subatomic particles, atoms, molecules, organelles, cells, tissues, organs, organ systems, organisms, and biosphere (Figure 3.1).

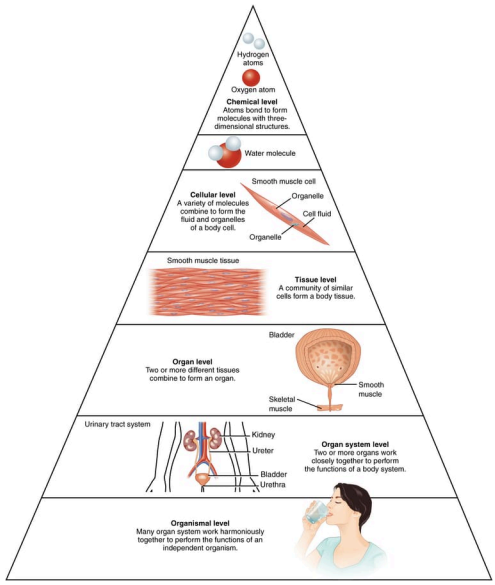

Figure 3.1 Levels of Structural Organization of the Human Body. The organization of the body often is discussed in terms of six distinct levels of increasing complexity, from the smallest chemical building blocks to a unique human organism. From Betts et al., 2013. Licensed under CC BY 4.0. [Image description.]

The Levels of Organization

All matter in the universe is composed of one or more unique pure substances called **elements**. Familiar examples are hydrogen, oxygen, carbon, nitrogen, calcium, and iron.

- The smallest unit of any of these pure substances (elements) is an **atom**.
  - Atoms are made up of subatomic particles such as the proton, electron, and neutron.
- Two or more atoms combine to form a **molecule**, such as the water molecules, proteins, and sugars found in living things.
  - **Molecules** are the chemical building blocks of all body structures.

- A **cell** is the smallest independently functioning unit of a living organism.
  - Even bacteria, which are extremely small, independently-living organisms, have a cellular structure. Each bacterium is a single cell. All living structures of human anatomy contain cells, and almost all functions of human physiology are performed in cells or are initiated by cells
  - A human cell typically consists of flexible membranes that enclose cytoplasm, a water-based cellular fluid, together with a variety of tiny functioning units called **organelles**. In humans, as in all organisms, cells perform all functions of life.
- A **tissue** is a group of many similar cells (though sometimes composed of a few related types) that work together to perform a specific function.
- An **organ** is an anatomically distinct structure of the body composed of two or more tissue types. Each organ performs one or more specific physiological functions.

An **organ system** is a group of organs that work together to perform major functions or meet the physiological needs of the body.

> **Did you know?**
>
> Organs are very collaborative and work with multiple body systems. For example, the heart (cardiovascular system) and lungs (respiratory system) work together to deliver oxygen throughout the body and remove carbon dioxide from the body.

Consider the breakdown into eleven distinct organ systems of the human body (Figure 3.2 and Figure 3.3). Assigning organs to organ systems can be imprecise since organs that "belong" to one system can also have functions integral to another system. In fact, most organs contribute to more than one system.

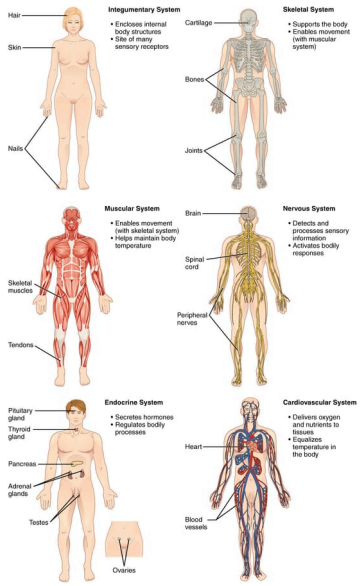

Figure 3.2. Organ Systems of the Human Body. Organs that work together are grouped into organ systems. From Betts et al., 2013. Licensed under CC BY 4.0 [Image description.]

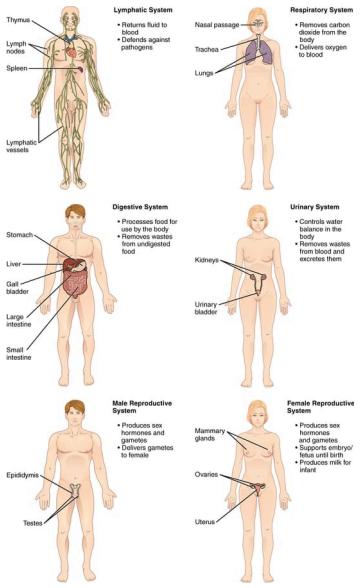

Figure 3.3. Organ Systems of the Human Body (continued). Organs that work together are grouped into organ systems. From Betts et al., 2013. Licensed under CC BY 4.0 [Image description.]

The **organism** level is the highest level of organization. An organism is a living being that has a cellular structure and that can independently perform all physiologic functions necessary for life. In multicellular organisms, including humans, all cells, tissues, organs, and organ systems of the body work together to maintain the life and health of the organism.

Watch this video:

YouTube Video

This interactive element is not available in this format. Visit the link or scan the QR code to access it online.

View this YouTube Video online

Media 3.1. Introduction to Anatomy & Physiology: Crash Course A&P #1 [Online video]. Copyright 2015 by CrashCourse.

Anatomical Position

Anatomists and healthcare providers use terminology for the purpose of precision and to reduce medical errors. For example, is a scar "above the wrist" located on the forearm two or three inches away from the hand? Or is it at the base of the hand? Is it on the palm-side or back-side? By using precise anatomical terminology, we eliminate ambiguity. Anatomical terms derive from ancient Greek and Latin words.

To further increase precision, anatomists standardize the way in which they view the body. Just as maps are normally oriented with north at the top, the standard body "map," also known as the anatomical position, is that of the body standing upright with the feet at shoulder width and parallel, toes forward. The upper limbs are held out to each side, and the palms of the hands face forward as illustrated in Figure 3.4.

Using this standard position reduces confusion. It does not matter how the body being described is oriented, the terms are used as if it is in anatomical position. For example, a scar in the "anterior (front) carpal (wrist) region" would be present on the palm side of the wrist. The term "anterior" would be used even if the hand were palm down on a table.

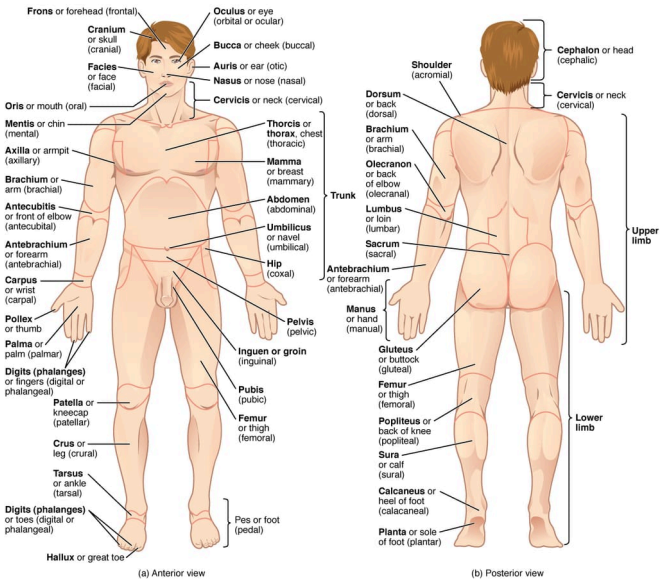

Figure 3.4. Regions of the Human Body. The human body is shown in anatomical position in an (a) anterior view and a (b) posterior view. The regions of the body are labeled in boldface. From Betts et al., 2013. Licensed under CC BY 4.0 [Image description.]

A body that is lying down is described as either prone or supine. These terms are sometimes used in describing the position of the body during specific physical examinations or surgical procedures.

> **Did you know?**
>
> Terminology is used for the purpose of precision and reduction of medical error.

Regional Terms

The human body's numerous regions have specific terms to help increase precision. Notice that the term "brachium" or "arm" is reserved for the "upper arm" and "antebrachium" or "forearm" is used rather than "lower arm." Similarly, "femur" or "thigh" is correct, and "leg" or "crus" is reserved for the portion of the lower limb between the knee and the ankle. You will be able to describe the body's regions using the terms from the anatomical position.

Directional Terms

Directional terms are essential for describing the relative locations of different body structures (Figure 3.5). For instance, an anatomist might describe one band of tissue as "inferior to" another or a physician might describe a tumor as "superficial to" a deeper body structure. Commit these terms to memory to avoid confusion when you are studying or describing the locations of particular body parts.

- **Anterior** (or **ventral**) describes the front or direction toward the front of the body. The toes are anterior to the foot.
- **Posterior** (or **dorsal**) describes the back or direction toward the back of the body. The popliteus is posterior to the patella.
- **Superior** (or **cranial**) describes a position above or higher than another part of the body proper. The orbits are superior to the oris.
- **Inferior** (or **caudal**) describes a position below or lower than another part of the body proper; near or toward the tail (in humans, the coccyx, or lowest part of the spinal column). The pelvis is inferior to the abdomen.
- **Lateral** describes the side or direction toward the side of the body. The thumb (pollex) is lateral to the digits.
- **Medial** describes the middle or direction toward the middle of the body. The hallux is the medial toe.
- **Proximal** describes a position in a limb that is nearer to the point of attachment or the trunk of the body. The brachium is proximal to the antebrachium.
- **Distal** describes a position in a limb that is farther from the point of attachment or the trunk of the body. The crus is distal to the femur.

- **Superficial** describes a position closer to the surface of the body. The skin is superficial to the bones.
- **Deep** describes a position farther from the surface of the body. The brain is deep to the skull.

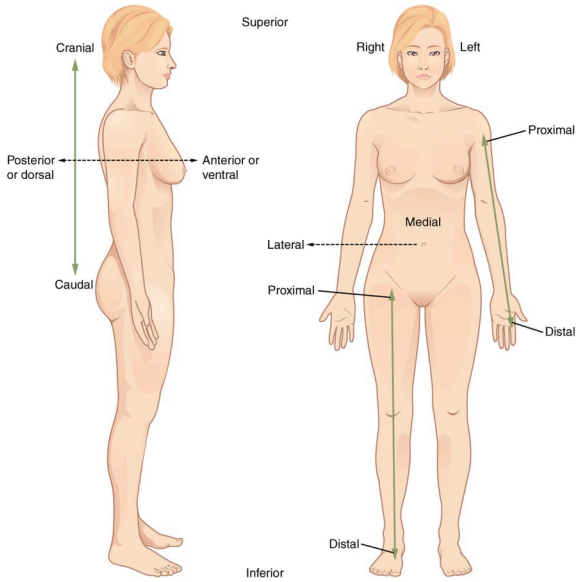

Figure 3.5. Directional Terms Applied to the Human Body. Paired directional terms are shown as applied to the human body. From Betts et al., 2013. Licensed under CC BY 4.0. [Image description.]

Practice the Directional Terms

Query 1.3.1

This interactive element is not available in this format. Visit the link or scan the QR code to access it online.

View this Interactive Content online

Concept Check

- Find a partner and take turns choosing two body parts on your or your partner's body.
- Using directional terms, describe the location of those body parts relative to one another.

Body Planes

A section is a two-dimensional surface of a three-dimensional structure that has been cut. Modern medical imaging devices enable clinicians to obtain "virtual sections" of living bodies. We call these scans. Body sections and scans can be correctly interpreted, however, only if the viewer understands the plane along which the section was made. A plane is an imaginary two-dimensional surface that passes through the body. There are three planes commonly referred to in anatomy and medicine:

- The **sagittal plane** is the plane that divides the body or an organ vertically into right and left sides. If this vertical plane runs directly down the middle of the body, it is called the midsagittal or median plane. If it divides the body into unequal right and left sides, it is called a parasagittal plane or, less commonly, a longitudinal section.
- The **frontal plane** is the plane that divides the body or an organ into an anterior (front) portion and a posterior (rear) portion. The frontal plane is often referred to as a coronal plane ("corona" is Latin for "crown").

- The **transverse plane** is the plane that divides the body or organ horizontally into upper and lower portions. Transverse planes produce images referred to as cross-sections.

Can You Locate the Planes?

Query 1.3.2

This interactive element is not available in this format. Visit the link or scan the QR code to access it online.

View this Interactive Content online

Body Cavities and Serous Membranes

The body maintains its internal organization by means of membranes, sheaths, and other structures that separate compartments. The **dorsal (posterior) cavity** and the **ventral (anterior) cavity** are the largest body compartments (Figure 3.6). These cavities contain and protect delicate internal organs, and the ventral cavity allows for significant changes in the size and shape of the organs as they perform their functions. The lungs, heart, stomach, and intestines, for example, can expand and contract without distorting other tissues or disrupting the activity of nearby organs.

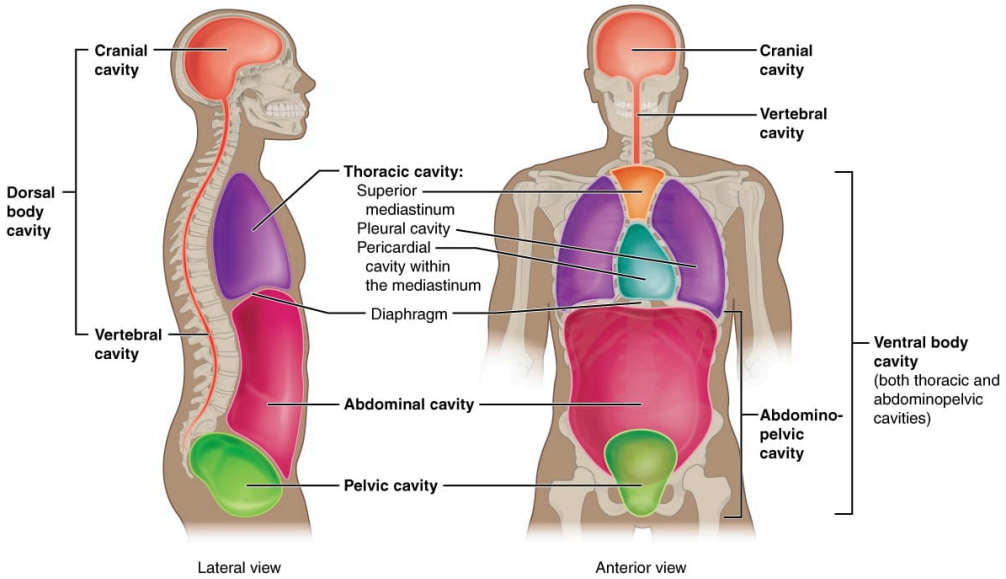

Figure 3.6. Dorsal and Ventral Body Cavities. The ventral cavity includes the thoracic and abdominopelvic cavities and their subdivisions. The dorsal cavity includes the cranial and spinal cavities. From Betts et al., 2013. Licensed under CC BY 4.0. [Image description.]

Subdivisions of the Posterior (Dorsal) and Anterior (Ventral) Cavities

The posterior (dorsal) and anterior (ventral) cavities are each subdivided into smaller cavities.

The posterior (dorsal) cavity has two main subdivisions:

- The **cranial cavity** houses the brain.
  - Protected by the bones of the skulls and cerebrospinal fluid.
- The **spinal cavity** (or vertebral cavity) encloses the spinal cord.
  - Protected by the vertebral column and cerebrospinal fluid.

The anterior (ventral) cavity has two main subdivisions:

- The **thoracic cavity** is the more superior subdivision of the anterior cavity, and it is enclosed by the rib cage.
  - The thoracic cavity contains the lungs and the heart, which are located in the mediastinum.
  - The diaphragm forms the floor of the thoracic cavity and separates it from the more inferior abdominopelvic cavity.
- The **abdominopelvic cavity** is the largest cavity in the body.
  - No membrane physically divides the abdominopelvic cavity.
  - The abdominal cavity houses the digestive organs, the pelvic cavity, and the reproductive organs.

Practice Locating Cavities

Query 1.3.3

This interactive element is not available in this format. Visit the link or scan the QR code to access it online.

View this Interactive Content online

Abdominal Regions and Quadrants

To promote clear communication, for instance about the location of a patient's abdominal pain or a suspicious mass, healthcare providers typically divide up the cavity into either nine regions or four quadrants.

Practice locating the quadrants

Query 1.3.4

This interactive element is not available in this format. Visit the link or scan the QR code to access it online.

View this Interactive Content online

Tissue Membranes

A **tissue membrane** is a thin layer or sheet of cells that covers the outside of the body (for example, skin), the organs (for example, pericardium), internal passageways that lead to the exterior of the body (for example, abdominal mesenteries), and the lining of the movable joint cavities. There are two basic types of tissue membranes: connective tissue and epithelial membranes (Figure 3.7).

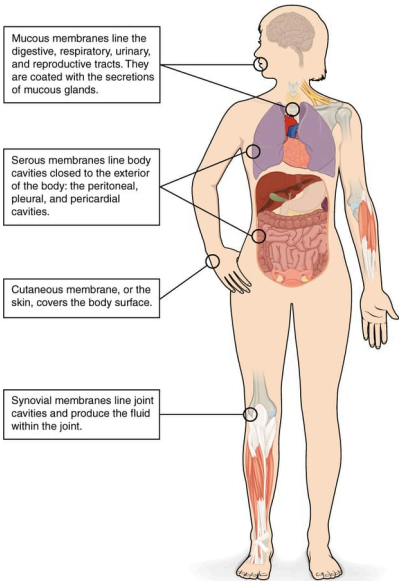

Figure 3.7. Tissue Membranes. The two broad categories of tissue membranes in the body are (1) connective tissue membranes, which include synovial membranes, and (2) epithelial membranes, which include mucous membranes, serous membranes, and the cutaneous membrane, in other words, the skin. From Betts et al., 2013. Licensed under CC BY 4.0. [Image description.]

Connective Tissue Membranes

The **connective tissue membrane** is formed solely from connective tissue.

- These membranes encapsulate organs, such as the kidneys, and line our movable joints.

A **synovial membrane** is a type of connective tissue membrane that lines the cavity of a freely movable joint.

- For example, synovial membranes surround the joints of the shoulder, elbow, and knee.

Did you know?

- Synovial membranes line cavities that hold synovial fluid.
- Synovial fluid lubricates the joints for movement.

Epithelial Membranes

The **epithelial membrane** is composed of epithelium attached to a layer of connective tissue.

- For example, your skin.

The **mucous membrane** is also a composite of connective and epithelial tissues.

- Sometimes called mucosae, these epithelial membranes line the body cavities and hollow passageways that open to the external environment and include the digestive, respiratory, excretory, and reproductive tracts.
- Mucus, produced by the epithelial exocrine glands, covers the epithelial layer.
- The underlying connective tissue, called the **lamina propria** (literally “own layer”), helps support the fragile epithelial layer.

The skin is an epithelial membrane also called the **cutaneous membrane**.

- It is a stratified squamous epithelial membrane resting on top of connective tissue. The apical surface of this membrane is exposed to the external environment and is covered with dead, keratinized cells that help protect the body from desiccation and pathogens.

Membranes of the Anterior (Ventral) Body Cavity

A **serous membrane** (also referred to as serosa) is an epithelial membrane composed of mesodermally derived epithelium called the mesothelium that is supported by connective tissue (Figure 3.8). These membranes line the coelomic cavities of the body and they cover the organs located within those cavities. They are essentially membranous bags, with mesothelial lining the inside and connective tissue on the outside.

- **Parietal layers:** line the walls of the body cavity.
- **Visceral layer:** covers the organs (the viscera).
- Between the parietal and visceral layers is a very thin, fluid-filled **serous space.**

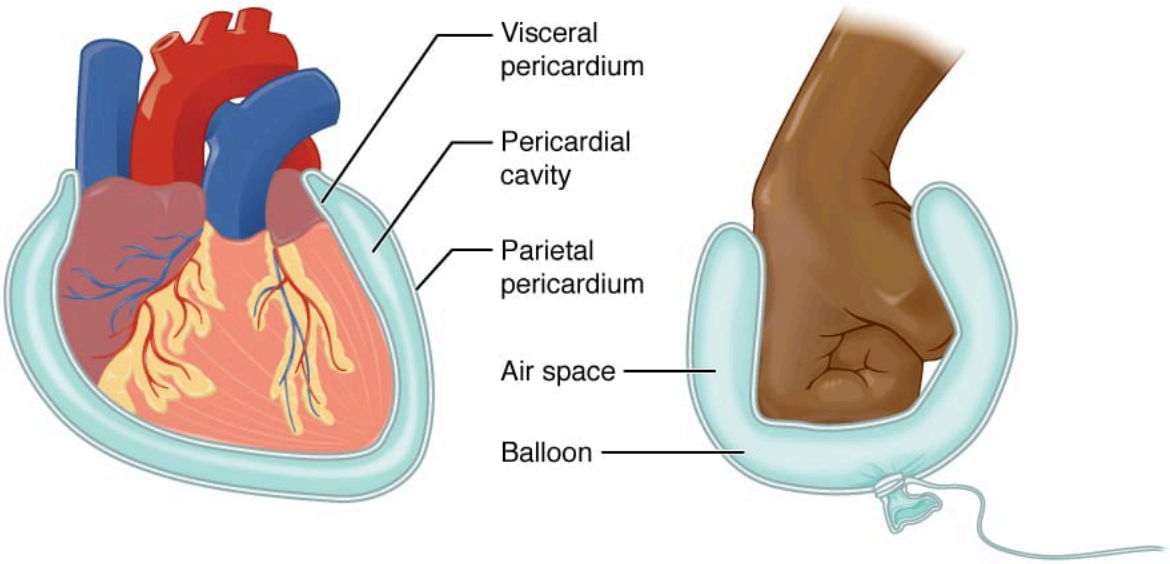

Figure 3.8. Serous Membrane. Serous membrane lines the pericardial cavity and reflects back to cover the heart—much the same way that an underinflated balloon would form two layers surrounding a fist. From Betts et al., 2013. Licensed under CC BY 4.0. [Image description.]

There are three serous cavities and their associated membranes. Serous membranes provide additional protection to the viscera they enclose by reducing friction that could lead to inflammation of the organs.

- **Pleura**: surrounds the lungs in the pleural cavity and reduces friction between the lungs and the body wall.
- **Pericardium:** surrounds the heart in the pericardial cavity and reduces friction between the heart and the wall of the pericardium.
- **Peritoneum:** surrounds several organs in the abdominopelvic cavity. The peritoneal cavity reduces friction between the abdominal and pelvic organs and the body wall.

Practice Body Terminology

Query 1.3.5

This interactive element is not available in this format. Visit the link or scan the QR code to access it online.

View this Interactive Content online

Body Terminology Vocabulary

Anatomical position: That of the body standing upright, with the feet at shoulder width and parallel, toes forward. The upper limbs are held out to each side, and the palms of the hands face forward.

Anterior (ventral): Describes the front or direction toward the front of the body.

Cerebrospinal fluid (CSF): A colorless fluid produced by the brain that cushions the brain and spinal cord within the posterior (dorsal) cavity.

Coelomic: Cavities that do not open to the outside.

Connective tissue: Type of tissue that serves to hold in place, connect, and integrate the body's organs and systems.

Cutaneous membrane: Epithelial tissue made up of stratified squamous epithelial cells that cover the outside of the body; skin.

Deep: Describes a position farther from the surface of the body.

Distal: A position in a limb that is farther from the point of attachment or the trunk of the body.

Epithelial membrane: Epithelium attached to a layer of connective tissue.

Frontal plane: Two-dimensional, vertical plane that divides the body or organ into anterior and posterior portions.

Homeostasis: The state of steady internal conditions maintained by living things.

Inferior (caudal): A position below or lower than another part of the body proper.

Lateral: Describes the side or direction toward the side of the body.

Medial: Describes the middle or direction toward the middle of the body.

Mucous membrane: Epithelial membranes that line the body cavities and hollow passageways that open to the external environment.

Parietal layer: Outermost layer of the pleura that connects to the thoracic wall, mediastinum, and diaphragm.

Pericardium: Membrane that separates the heart from other mediastinal structures; consists of two distinct, fused sublayers: the fibrous pericardium and the parietal pericardium.

Peritoneum: Serous membrane that lines the abdominopelvic cavity and covers the organs found there.

Pleura: The membrane that wraps around the outside of your lungs and lines the inside of your chest cavity.

Posterior (dorsal): Describes the back or direction toward the back of the body.

Prone: A face-down orientation.

Proximal: A position in a limb that is nearer to the point of attachment or the trunk of the body.

Sagittal plane: Two-dimensional, vertical plane that divides the body or organ into right and left sides.

Serous membrane: One of the thin membranes that cover the walls and organs in the thoracic and abdominopelvic cavities.

Serous space: The very thin, fluid-filled space between the parietal and visceral layers.

Superficial: Describes a position nearer to the surface of the body.

Superior (cranial): A position above or higher than another part of the body proper.

Supine: A face-up orientation.

Synovial membrane: Thin layer that lines the inner surface of the joint cavity at a synovial joint; produces the synovial fluid.

Tissue membrane: Thin layer or sheet of cells that covers the outside of the body, organs, and internal cavities.

Visceral layer: Innermost layer of the pleura that is superficial to the lungs and extends into the lung fissures.

Test Yourself

Query 1.3.6

This interactive element is not available in this format. Visit the link or scan the QR code to access it online.

View this Interactive Content online

References

CrashCourse. (2015, January 6). *Introduction to anatomy & physiology: Crash Course A&P #1* [Video]. YouTube. https://youtu.be/uBGI2BujkPQ

Image Descriptions

Figure 3.1 image description: This illustration shows biological organization as a pyramid. The chemical level is at the apex of the pyramid where atoms bond to form molecules with three-dimensional structures. An example is shown with two white hydrogen atoms bonding to a red oxygen atom to create water. The next level down on the pyramid is the cellular level, as illustrated with a long, tapered, smooth muscle cell. At this level, a variety of molecules combine to form the interior fluid and organelles of a body cell. The next level down is the tissue level. A community of similar cells forms body tissue. The example given here is a section of smooth muscle tissue, which contains many smooth muscle cells closely bound side by side. The next level down is the organ level, as illustrated with the bladder and urethra. The bladder contains smooth muscle while the urethra contains skeletal muscle. These are both examples of muscle tissues. The next level down is the organ system level, as illustrated by the entire urinary system containing the kidney, ureters, bladder, and urethra. At this level, two or more organs work closely together to perform the functions of a body system. At the base of the pyramid is the organismal level illustrated with a woman drinking water. At this level, many organ systems work harmoniously together to perform the functions of an independent organism. [Return to Figure 3.1].

Figure 3.2 image description: This illustration shows eight silhouettes of a human female, each showing the components of a different organ system. The integumentary system encloses internal body structures and is the site of many sensory receptors. The integumentary system includes the hair, skin, and nails. The skeletal system supports the body and, along with the muscular system, enables movement. The skeletal system includes cartilage, such as that at the tip of the nose, as well as the bones and joints. The muscular system enables movement, along with the skeletal system, but also helps to maintain body temperature. The muscular system includes skeletal muscles, as well as tendons that connect skeletal muscles to bones. The nervous system detects and processes sensory information and activates bodily responses. The nervous system includes the brain, spinal cord, and peripheral nerves, such as those located in the limbs. The endocrine system secretes hormones and regulates bodily processes. The endocrine system includes the pituitary gland in the brain, the thyroid gland in the throat, the pancreas in the abdomen, the adrenal glands on top of the kidneys, and the testes in the scrotum of males as well as the ovaries in the pelvic region of females. The cardiovascular system delivers oxygen and nutrients to the tissues as well as equalizes temperature in the body. The cardiovascular system includes the heart and blood vessels. [Return to Figure 3.2].

Figure 3.3 image description: The lymphatic system returns fluid to the blood and defends against pathogens. The lymphatic system includes the thymus in the chest, the spleen in the abdomen, the lymphatic vessels that spread throughout the body, and the lymph nodes distributed along the lymphatic vessels. The respiratory system removes carbon dioxide from the body and

delivers oxygen to the blood. The respiratory system includes the nasal passages, the trachea, and the lungs. The digestive system processes food for use by the body and removes wastes from undigested food. The digestive system includes the stomach, the liver, the gallbladder (connected to the liver), the large intestine, and the small intestine. The urinary system controls water balance in the body and removes and excretes waste from the blood. The urinary system includes the kidneys and the urinary bladder. The reproductive system of males and females produce sex hormones and gametes. The male reproductive system is specialized to deliver gametes to the female while the female reproductive system is specialized to support the embryo and fetus until birth and produce milk for the infant after birth. The male reproductive system includes the two testes within the scrotum as well as the epididymis which wraps around each testis. The female reproductive system includes the mammary glands within the breasts and the ovaries and uterus within the pelvic cavity. [Return to Figure 3.3]

Figure 3.4 image description: This illustration shows an anterior and posterior view of the human body. The cranial region encompasses the upper part of the head while the facial region encompasses the lower half of the head beginning below the ears. The eyes are referred to as the ocular region. The cheeks are referred to as the buccal region. The ears are referred to as the auricle or otic region. The nose is referred to as the nasal region. The chin is referred to as the mental region. The neck is referred to as the cervical region. The trunk of the body contains, from superior to inferior, the thoracic region encompassing the chest, the mammary region encompassing each breast, the abdominal region encompassing the stomach area, the coxal region encompassing the beltline, and the pubic region encompassing the area above the genitals. The umbilicus, or navel, is located at the center of the abdomen. The pelvis and legs contain, from superior to inferior, the inguinal or groin region between the legs and the genitals, the pubic region surrounding the genitals, the femoral region encompassing the thighs, the patellar region encompassing the knee, the crural region encompassing the lower leg, the tarsal region encompassing the ankle, the pedal region encompassing the foot and the digital/phalangeal region encompassing the toes. The great toe is referred to as the hallux. The regions of the upper limbs, from superior to inferior, are the axillary region encompassing the armpit, the brachial region encompassing the upper arm, the antecubital region encompassing the front of the elbow, the antebrachial region encompassing the forearm, the carpal region encompassing the wrist, the palmar region encompassing the palm, and the digital/phalangeal region encompassing the fingers. The thumb is referred to as the pollux. The posterior view contains, from superior to inferior, the cervical region encompassing the neck, the dorsal region encompassing the upper back, and the lumbar region encompassing the lower back. The regions of the back of the arms, from superior to inferior, include the cervical region encompassing the neck, acromial region encompassing the shoulder, the brachial region encompassing the upper arm, the olecranal region encompassing the back of the elbow, the antebrachial region encompasses the back of the arm, and the manual region encompassing the palm. The posterior regions of the legs, from superior to inferior, include the gluteal region encompassing the buttocks, the femoral region encompassing the thigh, the popliteal region encompassing the back of the knee, the sural region encompassing the back of the lower leg, and the plantar region encompassing the sole. Some regions are combined into larger regions. These include the trunk, which is a combination of the thoracic, mammary, abdominal, naval, and coxal regions. The cephalic region is a combination of all of the head regions. The upper limb region is a combination of all of the arm regions. The lower limb region is a combination of all of the leg regions. [Return to Figure 3.4].

Figure 3.5 image description: This illustration shows two diagrams: one of a side view of a female and the other of an anterior view of a female. Each diagram shows directional terms using double-sided arrows. The cranial-distal arrow runs vertically behind the torso and lower abdomen. The cranial arrow is pointing toward the head while the caudal arrow is pointing toward the tail bone. The posterior/anterior arrow is running horizontally through the back and chest. The posterior or dorsal arrow is pointing toward the back while the anterior, or ventral arrow, is pointing toward the abdomen. On the anterior view, the proximal/distal arrow is on the right arm. The proximal arrow is pointing up toward the shoulder while the distal arrow is pointing down toward the hand. The lateral-medial arrow is a horizontal arrow on the abdomen. The medial arrow is pointing toward the navel while the lateral arrow is pointing away from the body to the right. Right refers to the right side of the woman's body from her perspective while left refers to the left side of the woman's body from her perspective. [Return to Figure 3.5].

Figure 3.6 image description: This illustration shows a lateral and anterior view of the body and highlights the body cavities with different colors. The cranial cavity is a large, bean-shaped cavity filling most of the upper skull where the brain is located. The vertebral cavity is a very narrow, thread-like cavity running from the cranial cavity down the entire length of the spinal cord. Together the cranial cavity and vertebral cavity can be referred to as the dorsal body cavity. The thoracic cavity consists of three cavities that fill the interior area of the chest. The two pleural cavities are situated on both sides of the body, anterior to the spine and lateral to the breastbone. The superior mediastinum is a wedge-shaped cavity located between the superior regions of the two thoracic cavities. The pericardial cavity within the mediastinum is located at the center of the chest below the superior mediastinum. The pericardial cavity roughly outlines the shape of the heart. The diaphragm divides the thoracic and abdominal cavities. The abdominal cavity occupies the entire lower half of the trunk, anterior to the spine. Just under the abdominal cavity, anterior to the buttocks, is the pelvic cavity. The pelvic cavity is funnel-shaped and located inferior and anterior to the abdominal cavity. Together the abdominal and pelvic cavity can be referred to as the abdominopelvic cavity while the thoracic, abdominal, and pelvic cavities together can be referred to as the ventral body cavity. [Return to Figure 3.6].

Figure 3.7 image description: This illustration shows the silhouette of a human female from an anterior view. Several organs are showing in her neck, thorax, abdomen, left arm, and right leg. Text boxes point out and describe the mucous membranes in several different organs. The topmost box points to the mouth and trachea. It states that mucous membranes line the digestive, respiratory, urinary, and reproductive tracts. They are coated with the secretions of mucous glands. The second box points to the outside edge of the lungs as well as the large intestine and states that serous membranes line body cavities that are closed to the exterior of the body, including the peritoneal, pleural, and pericardial cavities. The third box points to the skin of the hand. It states that the cutaneous membrane, also known as the skin, covers the body surface. The fourth box points to the right knee. It states that synovial membranes line joint cavities and produce the fluid within the joint.[Return to Figure 3.7]

Figure 3.8 image description: This diagram shows the pericardium on the left next to an analogy of a hand punching a balloon on the right. The pericardium is a two-layered sac that surrounds the entire heart except where the blood vessels emerge on the heart's superior side. The pericardium has two layers because it folds over itself in the shape of the letter U. The inner layer that borders the heart is the visceral pericardium while the outer layer is the parietal pericardium. The space between the two layers is called the pericardial cavity. The heart sits in the cavity much like a fist punching into a balloon. The balloon surrounds the lower part of the fist with a two-layered sac, with the top of the balloon, where it contacts the fist, being analogous to the visceral pericardium. The bottom of the balloon, where it is tied off, is analogous to the parietal pericardium. The air within the balloon is analogous to the pericardial cavity. [Return to Figure 3.8].

Unless otherwise indicated, this chapter contains material adapted from *Anatomy and Physiology* (on OpenStax), by Betts et al. and is used under a CC BY 4.0 international license. Download and access this book for free at https://openstax.org/books/anatomy-and-physiology/pages/1-introduction.

This page titled 1.3: Body Terminology is shared under a CC BY 4.0 license and was authored, remixed, and/or curated by Andrea Nelson and Katherine Greene via source content that was edited to the style and standards of the LibreTexts platform.

1.4: Sensory Systems

Learning Objectives

- Examine the anatomy of the sensory systems
- Determine the main functions of the sensory systems
- Differentiate the medical terms of the sensory systems and common abbreviations
- Discover the medical specialties associated with the sensory systems
- Recognize common diseases, disorders, and procedures related to the sensory systems

Sensory Systems Word Parts

Click on prefixes, combining forms, and suffixes to reveal a list of word parts to memorize for the Sensory Systems.

Query 1.4.1

This interactive element is not available in this format. Visit the link or scan the QR code to access it online.

View this Interactive Content online

Introduction to the Sensory Systems

Ask anyone what the senses are, and they are likely to list the five major senses as **taste, smell, touch, hearing, and sight**. However, these are not all of the senses. The most obvious omission from this list is **balance**. Touch can be further subdivided into pressure, vibration, stretch, and hair-follicle position based on the type of mechanoreceptors that perceive these touch sensations. Other overlooked senses include temperature perception by thermoreceptors and pain perception by nociceptors.

Within the realm of physiology, senses can be classified as either general or special. A **general sense** is one that is distributed throughout the body and has receptor cells within the structures of other organs. Mechanoreceptors in the skin, muscles, or walls of blood vessels are examples of this type. General senses often contribute to the sense of touch, as described above, or to proprioception and kinesthesia, or to a visceral sense, which is most important to autonomic functions. A **special sense** is one that has a specific organ devoted to it, namely the eye, inner ear, tongue, or nose.

Gustation (Taste) and Olfaction (Smell)

Watch this video:

YouTube Video

This interactive element is not available in this format. Visit the link or scan the QR code to access it online.

View this YouTube Video online

Media 4.1 Taste & Smell: Crash Course A&P #16 [Online video]. Copyright 2015 from CrashCourse.

Practice Medical Terms Related to the Sensory Systems

Query 1.4.2

This interactive element is not available in this format. Visit the link or scan the QR code to access it online.

View this Interactive Content online

Gustation (Taste)

Gustation is the special sense associated with the tongue. The surface of the tongue, along with the rest of the oral cavity, is lined by a stratified squamous epithelium. Raised bumps called papillae contain the structures for gustatory transduction. There are **four types of papillae**, based on their appearance:

- circumvallate
- foliate
- filiform
- fungiform

Within the structure of the papillae are taste buds that contain specialized gustatory receptor cells for the transduction of taste stimuli. These receptor cells are sensitive to the chemicals contained within foods that are ingested, and they release neurotransmitters based on the amount of the chemical in the food. Neurotransmitters from the gustatory cells can activate sensory neurons in the facial, glossopharyngeal, and vagus cranial nerves.

Only a few recognized **submodalities** exist within the sense of taste, or gustation. Until recently, only four tastes were recognized: **sweet**, **salty**, **sour**, and **bitter**. Research at the turn of the 20th century led to the recognition of the fifth taste, umami, during the mid-1980s. Very recent research has suggested that there may also be a sixth taste for **fats**, or lipids.

Olfaction (Smell)

Like taste, olfaction is also responsive to chemical stimuli. The olfactory receptor neurons are located in a small region within the superior nasal cavity. The nasal epithelium, including the olfactory cells, can be harmed by airborne toxic chemicals. Scent receptor messages travel to the cerebrum, specifically to the primary olfactory cortex that is located in the inferior and medial areas of the temporal lobe and additionally to the hypothalamus, where smells become associated with long-term memory and emotional response.

Did you know?

The human body can detect over 10,000 odors.

Concept Check

- Which parts of the brain are active with recording and associating scents with memories and emotions?
- Recall and list the four types of papillae (taste buds) found on the tongue.

Audition (Hearing), Equilibrium (Balance), and Somatosensation (Touch)

Watch this video:

YouTube Video

This interactive element is not available in this format. Visit the link or scan the QR code to access it online.

View this YouTube Video online

Media 4.2 Hearing & Balance: Crash Course A&P #17 [Online video]. Copyright 2015 by CrashCourse.

Audition (Hearing)

Hearing, or **audition**, is the **transduction** of sound waves into a neural signal that is made possible by the structures of the ear (see Figure 4.1).

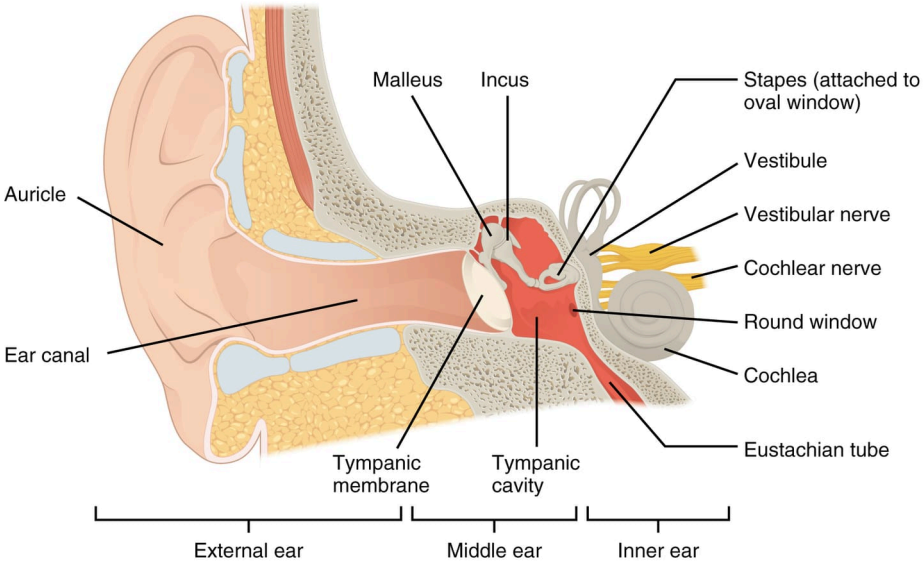

Figure 4.1 Structures of the Ear. The external ear contains the auricle, ear canal, and tympanic membrane. The middle ear contains the ossicles and is connected to the pharynx by the Eustachian tube. The inner ear contains the cochlea and vestibule, which are responsible for audition and equilibrium, respectively. From Betts et al., 2013. Licensed under CC BY 4.0. [Image description.]

- The **external ear** consists of the auricle, sometimes referred to as the pinna, ear canal, and tympanic membrane.
  - The C-shaped curves of the auricle direct sound waves toward the **auditory canal**. The canal enters the skull through the external auditory meatus of the **temporal bone**. At the end of the auditory canal is the **tympanic membrane**, which vibrates after it is struck by sound waves.
- The **middle ear** consists of the ossicles, oval window, and tympanic membrane.
  - The three **ossicles** are the malleus, incus, and stapes, which are Latin names that roughly translate to hammer, anvil, and stirrup. The malleus is attached to the tympanic membrane and articulates with the incus. The incus, in turn, articulates with the stapes. The stapes is then attached to the inner ear, where the sound waves will be transduced into a neural signal. Vibrations of the ossicles travel through the **oval window**, moving fluid in a wave-like motion. The frequency of the fluid waves matches the frequencies of the sound waves. The middle ear is connected to the pharynx through the Eustachian tube, which helps equilibrate air pressure across the **tympanic membrane**. The tube is normally closed but will pop open when the muscles of the pharynx contract during swallowing or yawning.

- The **inner ear** is often described as a **bony labyrinth**, as it is composed of a series of canals embedded within the temporal bone.
  - It consists of the **cochlea that is responsible for hearing** and the **vestibule that is responsible for balance.** The neural signals from these two regions are relayed to the brain stem through separate fiber bundles. However, these two distinct bundles travel together from the inner ear to the brain stem as the **vestibulocochlear** nerve. Sound is transduced into neural signals within the cochlear region of the inner ear, which contains the sensory neurons of the spiral ganglia. These ganglia are located within the spiral-shaped cochlea of the inner ear. The cochlea is attached to the stapes through the oval window.

The image below is a cross-sectional view of the cochlea that shows the scala vestibuli and scala tympani run along both sides of the cochlear duct (Figure 4.2). The cochlear duct contains several organs of Corti, which transduce the wave motion of the two scalas into neural signals. The organs of Corti lie on top of the basilar membrane, which is the side of the cochlear duct located between the organs of Corti and the scala tympani. As the fluid waves move through the scala vestibuli and scala tympani, the basilar membrane moves at a specific spot, depending on the frequency of the waves. Higher frequency waves move the region of the basilar membrane that is close to the base of the cochlea. Lower frequency waves move the region of the basilar membrane that is near the tip of the cochlea.

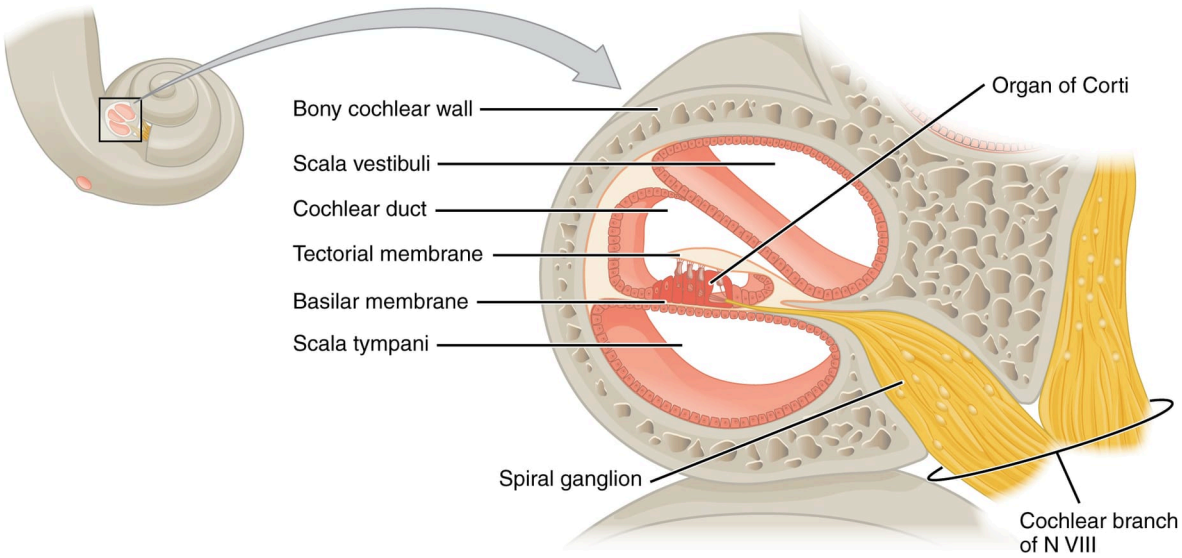

Figure 4.2 Cross Section of the Cochlea. The three major spaces within the cochlea are highlighted. The scala tympani and scala vestibuli lie on either side of the cochlear duct. The organ of Corti, containing the mechanoreceptor hair cells, is adjacent to the scala tympani, where it sits atop the basilar membrane. From Betts et al., 2013. Licensed under CC BY 4.0. [Image description.]

The cochlea encodes auditory stimuli for frequencies between 20 and 20,000 hertz (Hz), which is the range of sound that human ears can detect. The unit of Hz measures the frequency of sound waves in terms of cycles produced per second. Frequencies as low as 20 Hz are detected by hair cells at the apex, or tip, of the cochlea. Frequencies in the higher ranges of 20 kHz are encoded by hair cells at the base of the cochlea, close to the round and oval windows. Most auditory stimuli contain a mixture of sounds at a variety of frequencies and intensities (represented by the amplitude of the sound wave). The hair cells along the length of the cochlear duct, which are each sensitive to a particular frequency, allow the cochlea to separate auditory stimuli by frequency, just as a prism separates visible light into its component colors.

> **Did you know?**
>
> Sound travels at a speed of 1,130 feet per second.

Equilibrium (Balance)

Along with audition, the **inner ear** is responsible for **encoding** information about equilibrium. The cells that sense head position,

head movement, and body motion are located within the vestibule of the inner ear. Head position is sensed by otolith organs, whereas head movement is sensed by the semicircular canals (see Figure 4.3). The neural signals generated in the vestibular ganglion are transmitted through the vestibulocochlear nerve to the brainstem and cerebellum.

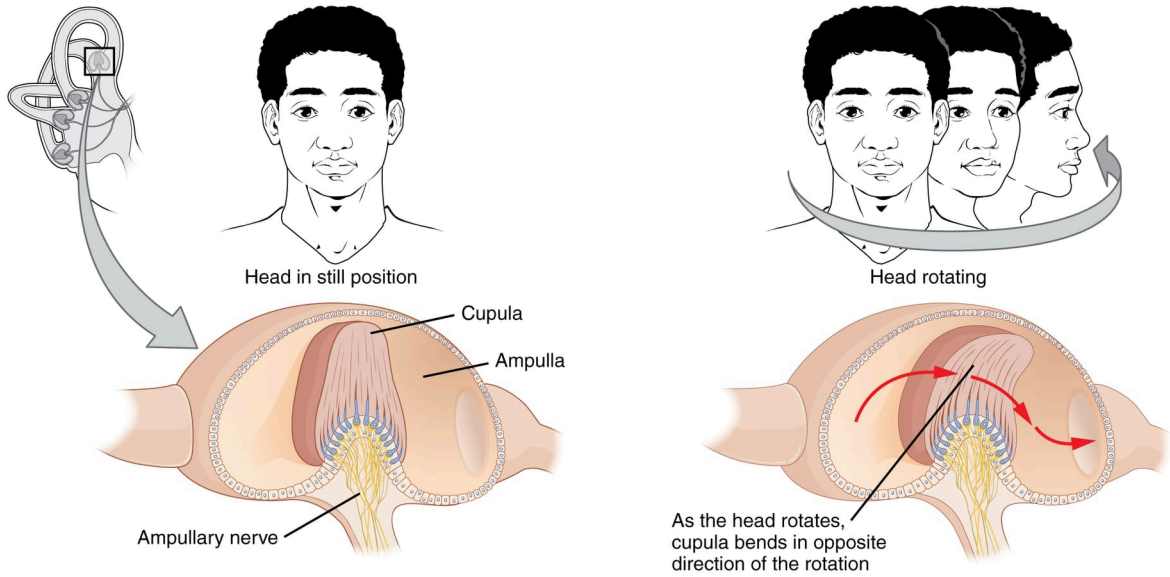

Figure 4.3 Rotational Coding by Semicircular Canals. Rotational movement of the head is encoded by the hair cells in the base of the semicircular canals. As one of the canals moves in an arc with the head, the internal fluid moves in the opposite direction, causing the cupula and stereocilia to bend. The movement of two canals within a plane results in information about the direction in which the head is moving, and activation of all six canals can give a very precise indication of head movement in three dimensions. From Betts et al., 2013. Licensed under CC BY 4.0. [Image description.]

Somatosensation (Touch)

Somatosensation is considered a general sense, as opposed to the special senses discussed in this section. Somatosensation is the group of **sensory modalities** that are associated with touch, **proprioception**, and **interoception**. These modalities include pressure, vibration, light touch, tickle, itch, temperature, pain, proprioception, and kinesthesia. This means that its receptors are not associated with a specialized organ, but are instead spread throughout the body in a variety of organs. Many of the somatosensory receptors are located in the skin, but receptors are also found in muscles, tendons, joint capsules, ligaments, and in the walls of visceral organs.

The two types of somatosensory signals that are transduced by free nerve endings are pain and temperature. Temperature receptors are stimulated when local temperatures differ from body temperature. Some thermoreceptors are sensitive to just cold and others to just heat. **Nociception** is the sensation of potentially damaging stimuli. Mechanical, chemical, or thermal stimuli beyond a set threshold will elicit painful sensations. Stressed or damaged tissues release chemicals that activate receptor proteins in the nociceptors.

For example, the sensation of heat associated with spicy foods involves capsaicin, the active molecule in hot peppers. Capsaicin molecules bind to a transmembrane ion channel in nociceptors that is sensitive to temperatures above 37°C (98.6°F). The dynamics of capsaicin binding with this transmembrane ion channel are unusual in that the molecule remains bound for a long time. Because of this, it will decrease the ability of other stimuli to elicit pain sensations through the activated nociceptor. For this reason, capsaicin can be used as a topical analgesic, such as in products such as Icy Hot™.

Did you know?

With the aging process, humans lose sensory receptors cells, including cells that detect pain and temperature changes.

Concept Check

- What structure exists within the ear to assist with maintaining **equilibrium**?
- What are the medical terms used to describe the sense of taste and touch?

Ear Anatomy Labeling Activity

Query 1.4.3

This interactive element is not available in this format. Visit the link or scan the QR code to access it online.

View this Interactive Content online

Vision (Sight)

Watch this video:

YouTube Video

This interactive element is not available in this format. Visit the link or scan the QR code to access it online.

View this YouTube Video online

Media 4.3 Vision: Crash Course A&P #18 [Online video]. Copyright 2015 by CrashCourse.

Vision is the special sense of sight that is based on the transduction of light stimuli received through the eyes. The eyes are located within either orbit in the skull. The bony orbits surround the eyeballs, protecting them and anchoring the soft tissues of the eye (see Figure 4.4). The eyelids, with lashes at their leading edges, help to protect the eye from abrasions by blocking particles that may land on the surface of the eye.

The inner surface of each lid is a thin membrane known as the palpebral conjunctiva. The conjunctiva extends over the sclera, connecting the eyelids to the eyeball. Tears are produced by the lacrimal gland, located beneath the lateral edges of the nose. Tears produced by this gland flow through the lacrimal duct to the medial corner of the eye where the tears flow over the conjunctiva, washing away foreign particles.

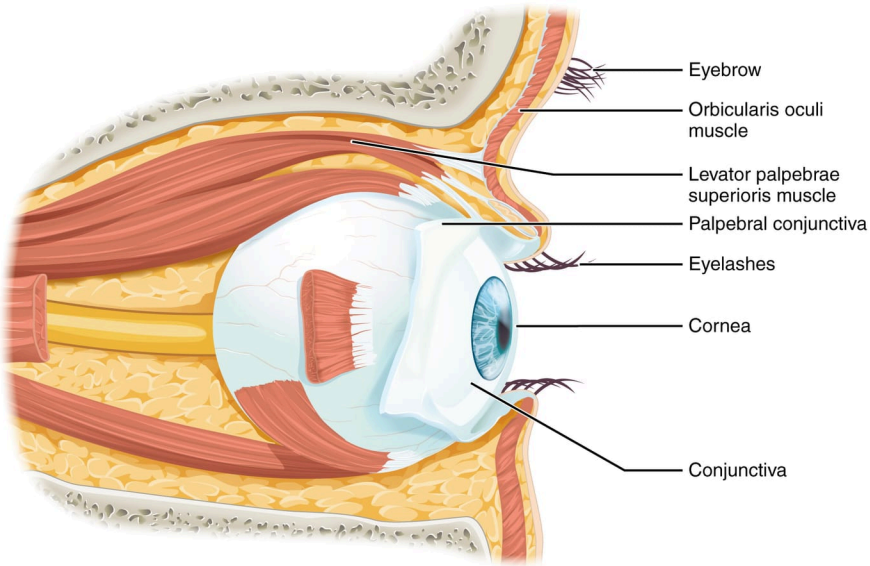

Figure 4.4 The Eye in the Orbit. The eye is located within the orbit and surrounded by soft tissues that protect and support its function. The orbit is surrounded by cranial bones of the skull. From Betts et al., 2013. Licensed under CC BY 4.0. [Image description.]

Movement of the eye within the orbit is accomplished by the contraction of six extraocular muscles that originate from the bones of the orbit and insert into the surface of the eyeball. Four of the muscles are arranged at the cardinal points around the eye and are named for those locations. They are the:

- superior rectus
- medial rectus
- inferior rectus
- lateral rectus.

When each of these muscles contracts, the eye moves toward the contracting muscle. For example, when the superior rectus contracts, the eye rotates to look up.

The eye itself is a hollow sphere composed of three layers of tissue:

- The **outermost layer** is the fibrous tunic, which includes the white sclera and clear cornea. The sclera accounts for five-sixths of the surface of the eye, most of which is not visible, though humans are unique compared with many other species in having so much of the "white of the eye" visible (see Figure 4.5). The transparent cornea covers the anterior tip of the eye and allows light to enter the eye.
- The **middle layer** of the eye is the vascular tunic, which is mostly composed of the choroid, ciliary body, and iris. The choroid is a layer of highly vascularized connective tissue that provides a blood supply to the eyeball. The choroid is posterior to the ciliary body, a muscular structure that is attached to the lens by zonule fibers. These two structures bend the lens, allowing it to focus light on the back of the eye. Overlaying the ciliary body, and visible in the anterior eye, is the iris—the colored part of the eye. The iris is a smooth muscle that opens or closes the pupil, which is the hole at the center of the eye that allows light to enter. The iris constricts the pupil in response to bright light and dilates the pupil in response to dim light.
- The **innermost layer** of the eye is the neural tunic, or retina, which contains the nervous tissue responsible for photoreception.

The eye is also divided into two cavities:

- The **anterior cavity**
  - The anterior cavity is the space between the cornea and lens, including the iris and ciliary body. It is filled with a watery fluid called the aqueous humor.
- The **posterior cavity**
  - The posterior cavity is the space behind the lens that extends to the posterior side of the interior eyeball, where the retina is located. The posterior cavity is filled with a more viscous fluid called the vitreous humor.

The **retina** is composed of several layers and contains specialized cells for the initial processing of visual stimuli. The

photoreceptors (rods and cones) change their membrane potential when stimulated by light energy. The change in membrane potential alters the number of neurotransmitters that the photoreceptor cells release onto bipolar cells in the outer synaptic layer. It is the bipolar cell in the retina that connects a photoreceptor to a retinal ganglion cell (RGC) in the inner synaptic layer. There, amacrine cells additionally contribute to retinal processing before an action potential is produced by the RGC. The axons of RGCs, which lie at the innermost layer of the retina, collect at the optic disc and leave the eye at the optic nerve (see Figure 4.5). Because these axons pass through the retina, there are no photoreceptors at the very back of the eye where the optic nerve begins. This creates a "blind spot" in the retina and a corresponding blind spot in our visual field.

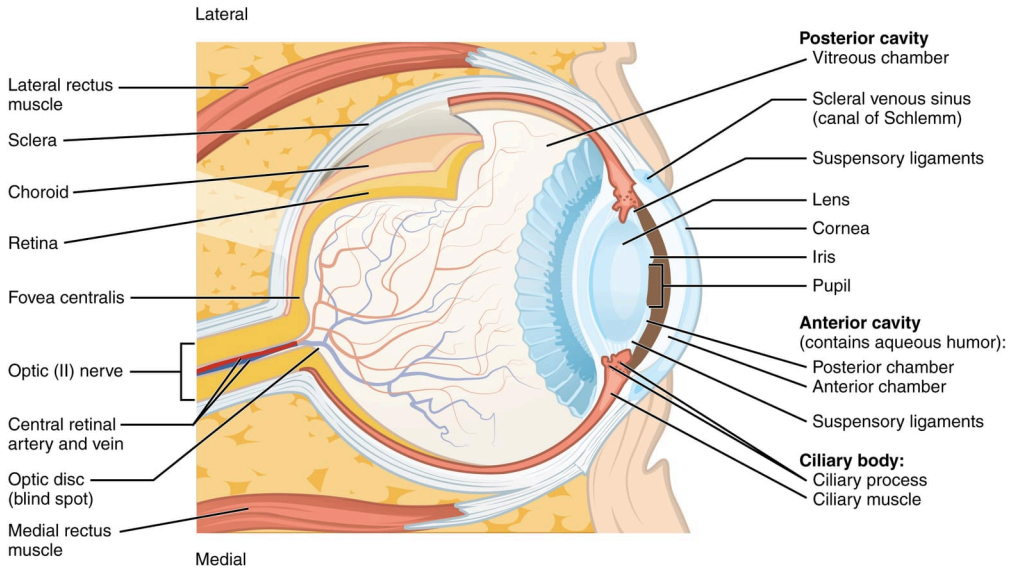

Figure 4.5. Structure of the Eye. The sphere of the eye can be divided into anterior and posterior chambers. The wall of the eye is composed of three layers: the fibrous tunic, vascular tunic, and neural tunic. Within the neural tunic is the retina, with three layers of cells and two synaptic layers in between. The center of the retina has a small indentation known as the fovea. From Betts et al., 2013. Licensed under CC BY 4.0. [Image description.]

Photoreceptors in the retina (rods and cones) are located behind the axons, RGCs, bipolar cells, and retinal blood vessels. A significant amount of light is absorbed by these structures before the light reaches the photoreceptor cells. At the exact center of the retina is a small area known as the fovea. At the fovea, the retina lacks the supporting cells and blood vessels, and only contains photoreceptors. Therefore, visual acuity is greatest at the fovea. This is because the fovea is where the least amount of incoming light is absorbed by other retinal structures (see Figure 4.5). As one moves in either direction from this central point of the retina, visual acuity drops significantly.

Example: Visual Acuity (VA) between the fovea and peripheral retina.

The difference in visual acuity between the fovea and peripheral retina is easily evidenced by looking directly at a word in the middle of this paragraph. The visual stimulus in the middle of the field of view falls on the fovea and is in the sharpest focus. **Without moving your eyes off that word, notice that words at the beginning or end of the paragraph are not in focus.** The images in your peripheral vision are focused by the peripheral retina and have vague, blurry edges and words that are not as clearly identified. As a result, a large part of the neural function of the eyes is concerned with moving the eyes and head so that important visual stimuli are centered on the fovea.

There are three types of **cone opsins** that are sensitive to different wavelengths of light and provide us with **color vision**. By comparing the activity of the three different cones, the brain can extract color information from visual stimuli (see Figure 4.6). For example, a bright blue light that has a wavelength of approximately 450 nm would activate the **"red"** cones minimally, the **"green"** cones marginally, and the **"blue"** cones predominantly. The relative activation of the three different cones is calculated by the brain, which perceives the color as blue. However, cones cannot react to low-intensity light, and rods do not sense the color of light. Therefore, our low-light vision is, in essence, in **grayscale**. In other words, in a dark room, everything appears as a shade

of gray. If you think that you can see colors in the dark, it is most likely because your brain knows what color something is and is relying on that memory.

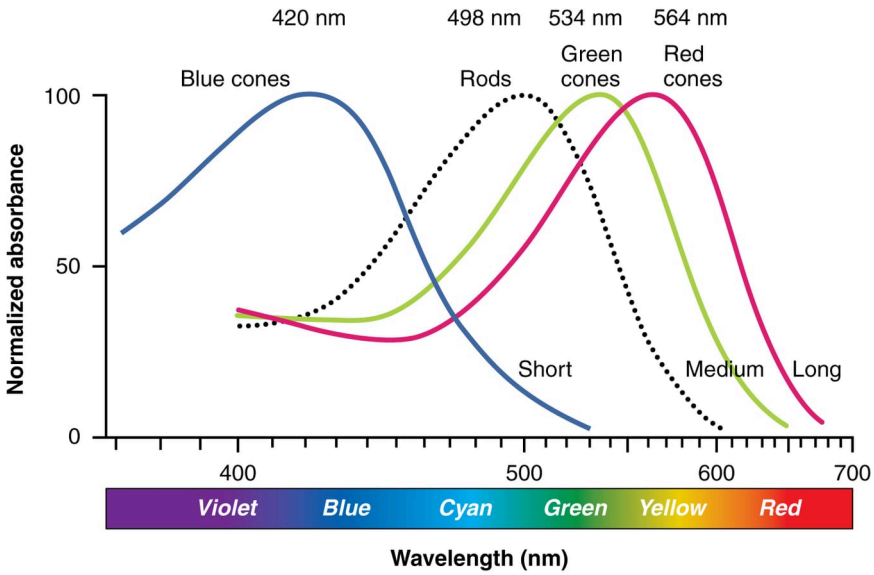

Figure 4.6 Comparison of Color Sensitivity of Photopigments. Comparing the peak sensitivity and absorbance spectra of the four photopigments suggests that they are most sensitive to particular wavelengths. From Betts et al., 2013. Licensed under CC BY 4.0. [Image description.]

Anatomy Labeling Activity

Query 1.4.4

This interactive element is not available in this format. Visit the link or scan the QR code to access it online.

View this Interactive Content online

Query 1.4.5

This interactive element is not available in this format. Visit the link or scan the QR code to access it online.

View this Interactive Content online

Practice Terms Related to the Sensory Systems

Query 1.4.6

This interactive element is not available in this format. Visit the link or scan the QR code to access it online.

View this Interactive Content online

Common Abbreviations for the Sensory Systems

Many terms and phrases related to the sensory systems are abbreviated. Learn these common abbreviations by expanding the list below.

Query 1.4.7

This interactive element is not available in this format. Visit the link or scan the QR code to access it online.

View this Interactive Content online

Diseases and Disorders of the Sensory Systems

Olfactory Diseases and Disorders

Anosmia

Blunt force trauma to the face, such as that common in many car accidents, can lead to the loss of the olfactory nerve, and subsequently, loss of the sense of smell. This condition is known as anosmia. When the frontal lobe of the brain moves relative to the ethmoid bone, the olfactory tract axons may be sheared apart. Professional fighters often experience anosmia because of repeated trauma to the face and head. In addition, certain pharmaceuticals, such as antibiotics, can cause anosmia by killing all the olfactory neurons at once. If no axons are in place within the olfactory nerve, then the axons from newly formed olfactory neurons have no guide to lead them to their connections within the olfactory bulb. There are temporary causes of anosmia, as well, such as those caused by inflammatory responses related to respiratory infections or allergies.

Loss of the sense of smell can result in food tasting bland. A person with an impaired sense of smell may require additional spice and seasoning levels for food to be tasted. Anosmia may also be related to some presentations of mild depression, because the loss of enjoyment of food may lead to a general sense of despair. The ability of olfactory neurons to replace themselves decreases with age, leading to age-related anosmia. This explains why some older adults salt their food more than younger people do. However, this increased sodium intake can increase blood volume and blood pressure, increasing the risk of cardiovascular diseases in older adults.

Ears, Nose, and Throat Diseases and Disorders

Otitis Media

Otitis Media is known as inflammation of the middle ear canal that involves the eardrum. It is commonly seen in younger children due to bacterial and viral infections. Signs and symptoms include fever, cough and cold symptoms, hearing loss, irritability, and otalgia. Treatment involves symptomatic control as well as antibiotic (amoxicillin) use if necessary (Centers for Disease Control and Prevention, n.d.-a; MedlinePlus, 2021).

Otitis Externa

Otitis Externa is inflammation of the external ear canal. It is known as swimmer's ear because it is associated with its exposure to water. Its clinical presentation and management are the same as otitis media (Centers for Disease Control and Prevention, n.d.-b).

Conductive Hearing Loss

Conductive hearing loss occurs when something disrupts sound through the mid and outer ear, such as physical damage to the eardrum (perforation). Hearing loss can be managed with pharmacotherapy, surgery, or a combination of the two (National Institute on Aging, n.d.).

Sensorineural Hearing Loss

Sensorineural hearing loss results from damage to the neural structures. This type of hearing loss is usually permanent (National Institute on Aging, n.d.).

Tinnitus

Tinnitus is a condition in which a person hears ringing, roaring, or buzzing in their ears. It may be a symptom of earwax blocking the ear canal, hearing loss, hormonal changes in women, or a brain tumor. Although there is no cure, several treatments are available (National Institute on Deafness and Other Communication Disorders, 2017).

Otosclerosis

Otosclerosis is the hardening of the ear due to new bone formation of the inner ear ossicles. Its etiology may be related to prior measles infection, stress fractures to the tissue surrounding the inner ear, or immune disorders. Mild otosclerosis can be surgically treated (National Institute on Deafness and Other Communication Disorders, 2018).

Rhinitis

Rhinitis is inflammation of the nasal cavity mucosal lining which can lead to congestion and rhinorrhea. Potential causes include allergy, bacterial or viral infection, and exposure to chemicals. Treatment regimens include symptom management, saline sprays, and oral antihistamines (Akhouri & House, 2021).

Dacryostenosis

Dacryostenosis, also known as nasolacrimal obstruction, is an obstruction of the nasolacrimal duct. It prevents tears from draining from the eyes into the ducts and, thus, individuals have excessive tearing. Its etiology is congenital and the result of the duct not forming properly. This condition is managed via observation, as it resolves over time (usually within 1 year) (Pezzoli & Patel, 2021).

Eye Diseases and Disorders

Blindness

The term “blindness” may cover a broad spectrum of visual disability, from limited visibility to total blindness. The parameters for legal blindness are visual field is 20 degrees or narrower and/or visual acuity is 20/200 or less in both eyes even after correction (Lee & Mesfin, 2021). Many of the conditions described below lead to visual disability, low vision, and legal blindness.

Cataract

A cataract is a clouding of the normally clear lens of your eye. For people who have cataracts, it is like seeing through cloudy lenses or windows. Age-related cataracts are the most common type, although cataracts can develop as a result of a congenital condition or due to trauma. Treatment usually involves surgery to remove the clouding of the lens (Nizami & Gulani, 2021).

Conjunctivitis

Conjunctivitis is a condition involving inflammation of the conjunctiva. Common causes include allergens and bacterial and viral pathogens. The cause of conjunctivitis determines if it is transmissible from one individual to another; conjunctivitis caused by the adenovirus, for example, is highly contagious, whereas conjunctivitis caused by pollen is not. Management involves treating the underlying cause of conjunctivitis (Ryder & Benson, 2021).

Diabetic Retinopathy

Diabetic retinopathy is a disease of the retina caused by diabetes mellitus. The retinal veins dilate, leading to swelling as fluid leaks from blood vessels into the retina. It is estimated that 77% of patients with type 1 diabetes and 25% of patients with type 2 diabetes have diabetic retinopathy. Management involves controlling the patient’s diabetes (Shukla & Tripathy, 2021).

Glaucoma

Glaucoma is a condition in which increased pressure in the eye leads to progressive vision loss. It is the second most common cause of permanent blindness in the United States. The most common form of glaucoma is primary open-angle glaucoma. This form is associated with elevated pressure caused by a backup of fluid in the eye. Management depends on the type of glaucoma and the severity of the case. Glaucoma-related vision loss cannot be reversed (Dietze et al., 2021).

Macular Degeneration/ Age-related Macular Degeneration (AMD)

Macular degeneration is the progressive damage of a portion of the retina known as the macula. Severe central vision is lost with peripheral vision retained. Macular degeneration is the leading cause of blindness in people over the age of 60 years (Ruia & Kaufman, 2021).

Nystagmus

Nystagmus is a condition whereby involuntary repetitive movements of one or both eyes make it impossible to fixate on a single object (Sekhon et al., 2020).

Retinal Detachment

Retinal detachment occurs when the retina gets pulled away or separated from its normal position. Signs and symptoms include flashing lights, floaters, and vision loss. Treatment generally involves surgery. If left untreated, a retinal detachment can lead to blindness (Blair & Czyz, 2021).

Strabismus

Strabismus is a condition where the affected eye rotates due to mismatched eye coordination. Each eye is focused differently as described below:

- **Esotropia:** the convergence of one or both eyes medially.
- **Exotropia:** the deviation of one eye laterally.
- **Hypertropia:** the deviation of one eye superiorly.
- **Hypotropia:** the deviation of one eye inferiorly.

If not managed, the brain may reject input from one eye, resulting in **amblyopia.** Also known as lazy eye, amblyopia is caused when there is an imbalance of stimuli from the brain to the eyes (one eye receives more than the other). It usually occurs in childhood and requires early intervention to rectify this condition (New York State Department of Health, 2012).

Medical Terms in Context

Query 1.4.8

This interactive element is not available in this format. Visit the link or scan the QR code to access it online.

View this Interactive Content online

Query 1.4.9

This interactive element is not available in this format. Visit the link or scan the QR code to access it online.

View this Interactive Content online

Medical Specialties and Procedures Related to the Sensory Systems

Several medical specialties support the sensory systems. An **optometrist** is an eye specialist that examines and evaluates for ocular pathology and prescribes corrective lenses. An **ophthalmologist** evaluates and manages eye pathology as well as performs surgery. An **otorhinolaryngologist** (ENT) is a physician that specializes in ears, nose, and throat treatment and conditions. An **audiologist** evaluates and manages individuals with hearing loss.

Sensory Systems Vocabulary

Acoustic neuroma: A benign tumor of the vestibular nerve in the internal auditory canal.

Anisocoria: Condition of unequal pupil size.

Anosmia: Loss of the sense of smell.

Aphakia: Condition of no lens.

Audiologist: Specialist who studies, diagnoses, and treats hearing-related issues.

Audiology: Medical specialty that studies hearing and hearing impairment.

Audiometry: The testing of the acuity of the sense of hearing.

Binocular: The use of both eyes to create one composite image.

Blepharitis: Inflammation of eyelids.

Blepharoplasty: Surgical repair of the eyelid.

Blepharoptosis: Drooping of the upper eyelid.

Cataract: A condition in which the lens of the eye becomes cloudy.

Conjunctivitis: Inflammation or infection of the conjunctiva; also called pinkeye.

Dacryocystitis: Inflammation of the tear (lacrimal) sac.

Dacryocystorhinostomy: Creation of an artificial opening between the lacrimal sac and the nose (to restore drainage).

Diplopia: Double vision.

Endophthalmitis: Inflammation within the eye.

Epistaxis: Nosebleed.

Hyperopia: Farsightedness.

Iridectomy: Excision of part of the iris.

Iritis: Inflammation of the iris.

Keratitis: Inflammation of the cornea.

Keratomalacia: Degeneration of the cornea.

Keratoplasty: Surgical replacement of the cornea.

Kinesthesia: Sense of body movement based on sensation in the skeletal muscles, tendons, joints, and the skin.

Labyrinthitis: Inflammation of the inner ear (labyrinth).

Mastoidectomy: Excision of the mastoid bone.

Mastoiditis: Inflammation of the mastoid bone.

Mechanoreceptor: A sensory neuron that responds to mechanical pressure.

Myopia: Nearsightedness.

Myringoplasty: Surgical repair of the tympanic membrane.

Nasopharyngeal: Pertaining to the nose and pharynx (throat).

Nociceptors : Sensory neurons that respond to pain.

Ophthalmia neonatorum: Conjunctivitis in newborns (severe).

Ophthalmologist: A doctor who has special training in diagnosing and treating eye problems.

Ophthalmology: A surgical specialty focused on the structure, function, and surgery of the eye.

Ophthalmopathy: Disease of the eye.

Ophthalmoplegia: Paralysis of one or more eye muscles.

Ophthalmoscope: Instrument used to view the inside of the eye.

Ophthalmoscopy: An exam of the fundus of the eye using a magnifying lens and light.

Optometrist: A specialist who diagnoses, treats, and manages diseases and disorders of the eye.

Optometry: The professional practice of eye and vision care that involves measuring vision.

Otalgia: Pain in the ear.

Otolaryngologist.: A doctor who has special training in diagnosing and treating diseases of the ear, nose, and throat.

Otomycosis: Fungal infection of the external ear.

Otosclerosis: Hardening of the ear.

Otoscope: Instrument used to view the ear.

Otoscopy: Process of viewing the ear canal and eardrum.

Pharyngitis: Inflammation of the pharynx.

Photophobia: A condition in which the eyes are more sensitive than normal to light.

Proprioception : Sense of position and movement of the body.

Retinoblastoma: Cancer that forms in the tissues of the retina.

Retinopathy: Disease of the retina.

Retinoscopy: Process of determining the refractive state of the eye.

Rhinitis: Inflammation of the mucous membranes of the nose.

Rhinorrhea: Excess nasal drainage; also called a “runny nose.”

Sinusitis: Inflammation of the sinuses.

Stapedectomy: Excision of the stapes.

Stye: Infection of an oil gland of the eyelid (hordeolum).

Thermoreceptors: Specialized neurons that respond to changes in temperature.

Tonometer: Instrument used to measure pressure (within the eye).

Tonometry: Process of measuring pressure (within the eye).

Tonsillitis: Inflammation of the tonsils.

Tympanic membrane: Ear drum.

Tympanoplasty: Surgical repair of the tympanic membrane.

Visceral (sense): Sense associated with the internal organs.

Visual acuity: Sharpness of vision.

Xerophthalmia: Condition of dry eye.

Test Yourself

Query 1.4.10

This interactive element is not available in this format. Visit the link or scan the QR code to access it online.

View this Interactive Content online

References

Akhouri, S., & House, S. A. (2021). Allergic rhinitis. In *StatPearls [Internet]*. https://www.ncbi.nlm.nih.gov/books/NBK538186/

Blair, K., & Czyz, C. N. (2021). Retinal detachment. In *StatPearls [Internet]*. https://www.ncbi.nlm.nih.gov/books/NBK551502/

Centers for Disease Control and Prevention. (n.d.-a). *Ear infection*. https://www.cdc.gov/antibiotic-use/ear-infection.html

Centers for Disease Control and Prevention. (n.d.-b). *Swimming and ear infections*. https://www.cdc.gov/healthywater/swimming/swimmers/rwi/ear-infections.html

CrashCourse. (2015, May 11). *Vision: Crash course A&P #18* [Video]. YouTube. https://www.youtube.com/watch?v=o0DYP-u1rNM

CrashCourse. (2015, April 27). *Taste & smell: Crash course A&P #16* [Video]. YouTube. https://www.youtube.com/watch?v=mFm3yA1nslE

CrashCourse. (2015, May 4). *Hearing & balance: Crash course A&P #17* [Video]. YouTube. https://www.youtube.com/watch?v=Ie2j7GpC4JU

Dietze, J., Blair, K., Havens, S. J. (2021). Glaucoma. In *StatPearls [Internet]*. https://www.ncbi.nlm.nih.gov/books/NBK538217/

Lee, S. Y., & Mesfin, F. B. (2021). Blindness. In *StatPearls [Internet]*. https://www.ncbi.nlm.nih.gov/books/NBK448182/

MedlinePlus. (2021). *Ear infections*. National Institutes of Health, U.S. Department of Health and Human Services. https://medlineplus.gov/earinfections.html

National Institute on Aging. (n.d.). *Hearing loss: A common problem for older adults*. National Institutes of Health, U.S. Department of Health and Human Services. https://www.nia.nih.gov/health/hearing-loss-common-problem-older-adults

National Institute on Deafness and Other Communication Disorders. (2017). *Tinnitus*. National Institutes of Health, U.S. Department of Health and Human Services. https://www.nidcd.nih.gov/health/tinnitus

National Institute on Deafness and Other Communication Disorders. (2018). *Otosclerosis*. National Institutes of Health, U.S. Department of Health and Human Services. https://www.nidcd.nih.gov/health/otosclerosis

New York State Department of Health. (2012). *Types of vision problems*. https://www.health.ny.gov/diseases/conditions/vision_and_eye_health/types_of_vision_problems.htm

Nizami, A. A., & Gulani, A. C. (2021). Cataract. In *StatPearls [Internet]*. https://www.ncbi.nlm.nih.gov/books/NBK539699/

Pezzoli, M., & Patel, B. C. (2021). Dacryostenosis. In *StatPearls [Internet]*. https://www.ncbi.nlm.nih.gov/books/NBK563132/

Ruia, S., & Kaufman, E. J. (2021). Macular degeneration. In *StatPearls [Internet]*. https://www.ncbi.nlm.nih.gov/books/NBK560778/

Ryder, E. C., & Benson, S. (2021). Conjunctivitis. In *StatPearls [Internet]*. https://www.ncbi.nlm.nih.gov/books/NBK541034/

Sekhon, R. K., Rocha Cabrero, F., & Deibel, J. P. (2020). Nystagmus types. In *StatPearls [Internet]*. https://www.ncbi.nlm.nih.gov/books/NBK539711/

Shukla, U. V., & Tripathy, K. (2021). Diabetic retinopathy. In *StatPearls [Internet]*. https://www.ncbi.nlm.nih.gov/books/NBK560805/

Image Descriptions

Figure 4.1 image description: This image shows the structure of the ear with the major parts labeled. The ear is divided up into 3 parts from left to right: external ear, middle ear, and inner ear. Labels for each part read: external ear (auricle, ear canal), middle ear (tympanic membrane, malleus, incus, tympanic cavity), inner ear (stapes, vestibule, vestibular nerve, cochlear nerve, cochlea, round window, eustachian tube). [Return to Figure 4.1].

Figure 4.2 image description: This diagram shows the structure of the cochlea in the inner ear. Labels read (from top, counterclockwise): bony cochlear wall, scala vestibuli, cochlear duct, tectorial membrane, basilar membrane, scala tympani, spiral ganglion, cochlear branch of N VIII, organ of Corti. [Return to Figure 4.2].

Figure 4.3 image description: The left panel of this image shows a person's head in a still position. Underneath this, the ampullary nerve is shown. Labels read: cupula, ampulla, ampullary nerve). The right panel shows a person rotating his head, and below that, the direction of movement of the cupula is shown. Label reads: as the head rotates, cupula bends in opposite direction of the rotation. [Return to Figure 4.3].

Figure 4.4 image description: This diagram shows the lateral view of the eye. The major parts are labeled. Labels read (from top): eyebrow, orbicularis oculi muscle, levator palpebrae superioris muscle, palpebral conjunctiva, eyelashes, cornea, conjunctiva. [Return to Figure 4.4].

Figure 4.5 image description: This diagram shows a lateral and medial view of the eyeball. The major parts are labeled. Labels read (from top, clockwise): posterior cavity (vitreous chamber, scleral venous sinus (canal of Schlemm), suspensory ligaments, lens, cornea, iris, pupil); anterior cavity (contains aqueous humor, posterior chamber, anterior chamber, suspensory ligaments); Ciliary body (ciliary process and muscle), medial rectus muscle, optic disc (blind spot), central retinal artery and vein, fovea centralis, retina, choroid, sclera, lateral rectus muscle. [Return to Figure 4.5].

Figure 4.6 image description: This graph shows the normalized absorbance versus wavelength for different cell types in the eye. The Y-axis is normalized absorbance, and the X-axis is the wavelength (nm) with the colors violet, blue, cyan, green, yellow, and red across the bottom. The lines in the graph indicate blue cones which peak at 420 nm, rods that peak at 498 nm, green cones which peak at 534 nm, and red cones which peak at 564 nm. Blue cones line is labeled as short, green cones as medium, and red cones as long. [Return to Figure 4.6].

Unless otherwise indicated, this chapter contains material adapted from *Anatomy and Physiology* (on OpenStax), by Betts et al. and is used under a CC BY 4.0 international license. Download and access this book for free at https://openstax.org/books/anatomy-and-physiology/pages/1-introduction.

This page titled 1.4: Sensory Systems is shared under a CC BY 4.0 license and was authored, remixed, and/or curated by Andrea Nelson and Katherine Greene via source content that was edited to the style and standards of the LibreTexts platform.

1.5: Integumentary System

Learning Objectives

- Examine the anatomy of the integumentary system
- Determine the main functions of the integumentary system
- Differentiate integumentary system medical terms and common abbreviations
- Discover medical specialties associated with the integumentary system
- Recognize common diseases, disorders, and procedures related to the integumentary system

Integumentary System Word Parts

Click on prefixes, combining forms, and suffixes to reveal a list of word parts to memorize for the Integumentary System.

Query 1.5.1

This interactive element is not available in this format. Visit the link or scan the QR code to access it online.

View this Interactive Content online

Introduction to the Integumentary System

The integumentary system refers to the skin and its accessory structures. In the adult human body, the skin makes up about 16% of body weight and covers an area of 1.5 to 2 m^2.

In fact, the skin and accessory structures are the largest organ system in the human body. The skin protects your inner organs, and it is in need of daily care and protection to maintain its health.

Did you know?

The skin and accessory structures are the largest organ system in the human body.

Watch this video:

YouTube Video

This interactive element is not available in this format. Visit the link or scan the QR code to access it online.

View this YouTube Video online

Media 5.1. The Integumentary System, Part 1 – Skin Deep: Crash Course A&P #6 [Video]. Copyright 2015 by CrashCourse.

Practice Medical Terms Related to the Integumentary System

Query 1.5.2

This interactive element is not available in this format. Visit the link or scan the QR code to access it online.

View this Interactive Content online

Anatomy (Structures) of the Integumentary System

The skin and its accessory structures make up the integumentary system, which provides the body with overall protection. The skin is made of multiple layers of cells and tissues, which are held to underlying structures by connective tissue (Figure 5.1). The deeper layer of skin is well vascularized. It also has numerous sensory autonomic, and sympathetic nerve fibers ensuring communication to and from the brain.

The skin is composed of two main layers:

1. The epidermis
2. The dermis
    1. Beneath the dermis lies the hypodermis, also known as the subcutaneous layer.

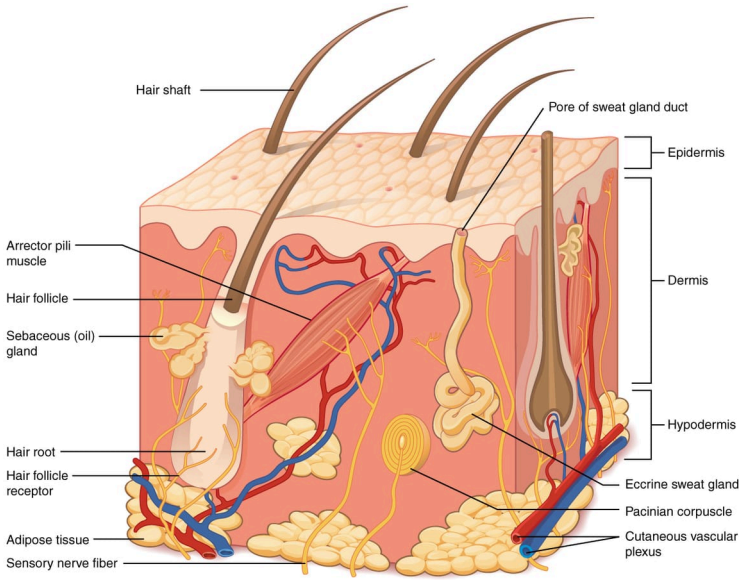

Figure 5.1 Layers of Skin. From Betts et al., 2013. Licensed under CC BY 4.0. [Image description.]

Concept Check

- On the diagram above find the two layers of the skin: **epidermis** and **dermis**.
- The literal breakdown for **hypodermis** is "below the dermis." On the diagram above, where can you locate it?
- Can you find a **hair follicle**, **hair root**, and **hair shaft**?
- Keep reading to find out what the **arrector pili muscle** does when you are frightened.

Epidermis

The epidermis is composed of keratinized, stratified squamous epithelium. It is made of four or five layers of epithelial cells, depending on its location in the body. It is avascular.

- **Thin skin** has four layers of cells. From deep to superficial, these layers are the stratum basale, stratum spinosum, stratum granulosum, and stratum corneum. Most of the skin can be classified as thin skin.
- **Thick skin** is found only on the palms of the hands and the soles of the feet. It has a fifth layer, called the stratum lucidum, located between the stratum corneum and the stratum granulosum (see Figure 5.2).

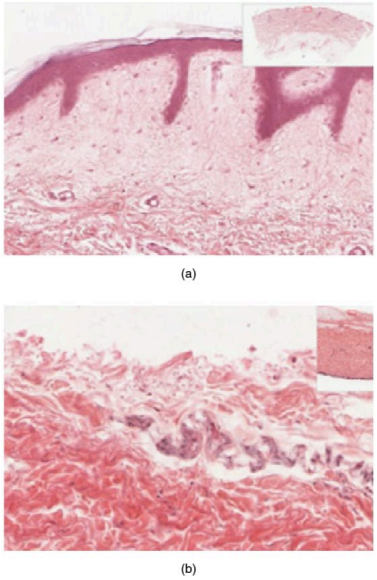

Figure 5.2 Thin Skin versus Thick Skin. These slides show cross-sections of the epidermis and dermis of (a) thin and (b) thick skin. Note the significant difference in the thickness of the epithelial layer of the thick skin. From the top, LM × 40, LM × 40. (Micrographs provided by the Regents of University of Michigan Medical School © 2012). From Betts et al., 2013. Licensed under CC BY 4.0. [Image description.]

The cells in all of the layers except the stratum basale are called keratinocytes. **Keratin** is an intracellular fibrous protein that gives hair, nails, and skin their hardness and water-resistant properties. The keratinocytes in the stratum corneum are dead and regularly slough away, being replaced by cells from the deeper layers (see Figure 5.3).

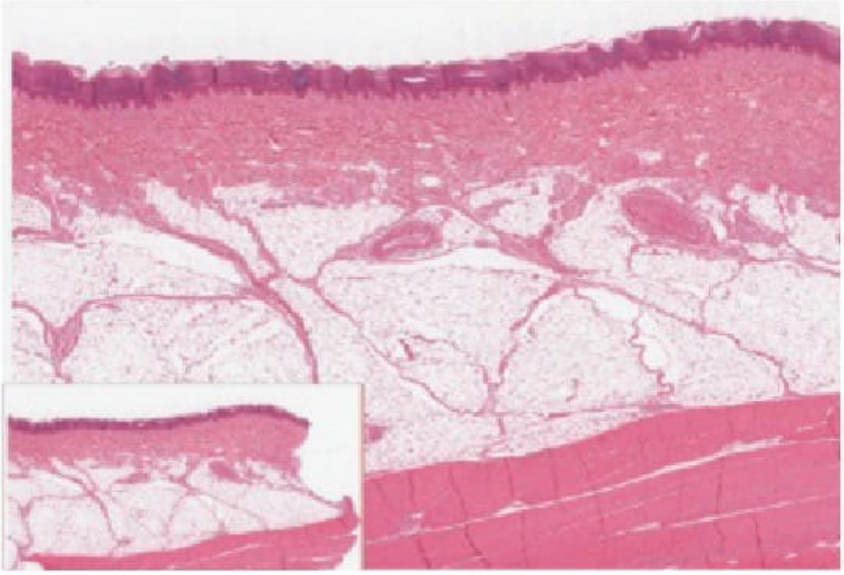

Figure 5.3 Epidermis. The epidermis is epithelium composed of multiple layers of cells. The basal layer consists of cuboidal cells, whereas the outer layers are squamous, keratinized cells, so the whole epithelium is often described as being keratinized stratified squamous epithelium. LM × 40. (Micrograph provided by the Regents of University of Michigan Medical School © 2012). From Betts et al., 2013. Licensed under CC BY 4.0. [Image description.]

Dermis

The dermis contains blood and lymph vessels, nerves, and other structures, such as hair follicles and sweat glands. The dermis is made of two layers (papillary layer and reticular layer) of connective tissue that compose an interconnected mesh of elastin and collagenous fibers, produced by fibroblasts (see Figure 5.4).

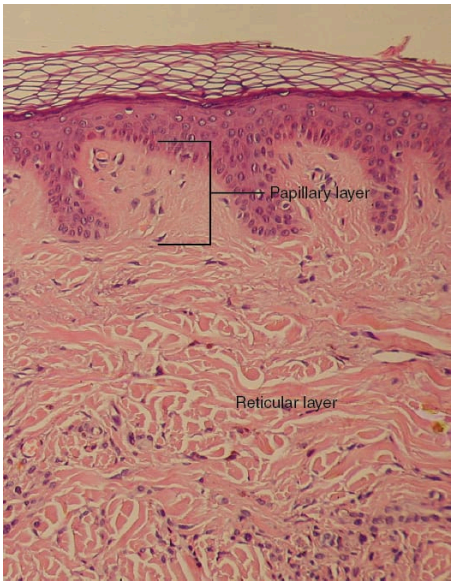

Figure 5.4 Layers of the Dermis. This stained slide shows the two components of the dermis—the papillary layer and the reticular layer. Both are made of connective tissue with fibers of collagen extending from one to the other, making the border between the two somewhat indistinct. The dermal papillae extending into the epidermis belong to the papillary layer, whereas the dense collagen fiber bundles below belong to the reticular layer. LM × 10. (credit: modification of work by "kilbad"/Wikimedia Commons). From Betts et al., 2013. Licensed under CC BY 4.0. [Image description.]

Papillary Layer

The papillary layer is made of loose, areolar connective tissue, which means the collagen and elastin fibers of this layer form a loose mesh. This superficial layer of the dermis projects into the stratum basale of the epidermis to form finger-like dermal papillae (see Figure 5.4). Within the papillary layer are fibroblasts, a small number of adipocytes, and an abundance of small blood vessels. In addition, the papillary layer contains phagocytes that help fight bacteria or other infections that have breached the skin. The layer also contains lymphatic capillaries, nerve fibers, and Meissner corpuscles.

Reticular Layer

Underlying the papillary layer is the much thicker reticular layer, composed of dense, irregular connective tissue. The layer is well vascularized and has a rich sensory and sympathetic nerve supply. The reticular layer appears reticulated due to a tight meshwork of fibers. Elastin fibers provide some elasticity to the skin, enabling movement. Collagen fibers provide structure and tensile strength, with strands of collagen extending into both the papillary layer and the hypodermis. In addition, collagen binds water to keep the skin hydrated. Collagen injections and Retin-A creams help restore skin turgor by either introducing collagen externally or stimulating blood flow and repair of the dermis, respectively.

Hypodermis (Subcutaneous Layer)

The hypodermis, also known as the subcutaneous layer, serves to connect the skin to the underlying fascia of the bones and muscles. It is not strictly a part of the skin, although the border between the hypodermis and dermis can be difficult to distinguish. The hypodermis consists of well-vascularized, loose, areolar connective tissue and adipose tissue, which functions as a mode of fat storage and provides insulation and cushioning for the integument.

Practice Labeling the Layers of the Skin

Query 1.5.3

This interactive element is not available in this format. Visit the link or scan the QR code to access it online.

View this Interactive Content online

Physiology (Function) of the Integumentary System

The skin and accessory structures perform a variety of essential functions, such as protecting the body from invasion by microorganisms, chemicals, and other environmental factors; preventing dehydration; acting as a sensory organ; modulating body temperature and electrolyte balance; and synthesizing vitamin D. The underlying hypodermis has important roles in storing fats, forming a “cushion” over underlying structures, and providing insulation from cold temperatures.

Protection

The skin protects the body from wind, water, and UV sunlight. It acts as a protective barrier against water loss and it also is the first line of defense against abrasive activity such as grit, microbes, or harmful chemicals. Sweat excreted from sweat glands deters microbes from over-colonizing the skin surface by generating dermcidin, which has antibiotic properties.

Sensory Function

The skin acts as a sense organ because the epidermis, dermis, and hypodermis contain specialized sensory nerve structures that detect touch, surface temperature, and pain. These receptors are more concentrated on the tips of the fingers, which are most sensitive to touch, especially the Meissner corpuscle, which responds to light touch, and the Pacinian corpuscle, which

responds to vibration. Merkel cells, seen scattered in the stratum basale, are also touch receptors. In addition to these specialized receptors, there are sensory nerves connected to each hair follicle, pain and temperature receptors scattered throughout the skin, and motor nerves innervate the arrector pili muscles and glands. This rich innervation helps us sense our environment and react accordingly,

Thermoregulation

The integumentary system helps regulate body temperature through its tight association with the sympathetic nervous system. The sympathetic nervous system is continuously monitoring body temperature and initiating appropriate motor responses.

- When the **body becomes warm** sweat glands, accessory structures to the skin, secrete water, salt, and other substances to cool the body.
  - Even when the body does not appear to be noticeably sweating, approximately 500 mL of sweat are secreted a day.
- If the **body becomes excessively warm** due to high temperatures, vigorous activity, or a combination of the two, sweat glands will be stimulated by the sympathetic nervous system to produce large amounts of sweat.
  - When the sweat evaporates from the skin surface, the body is cooled as body heat is dissipated.
  - In addition to sweating, arterioles in the dermis dilate so that excess heat carried by the blood can dissipate through the skin and into the surrounding environment (Figure 5.5).
  - This accounts for the skin redness that many people experience when exercising.
- When **body temperatures drop**, the arterioles constrict to minimize heat loss, particularly in the ends of the digits and tip of the nose.
  - This reduced circulation can result in the skin taking on a whitish hue.
  - Although the temperature of the skin drops as a result, passive heat loss is prevented, and internal organs and structures remain warm.
  - If the temperature of the skin drops too much (such as environmental temperatures below freezing), the conservation of body core heat can result in frostbite.

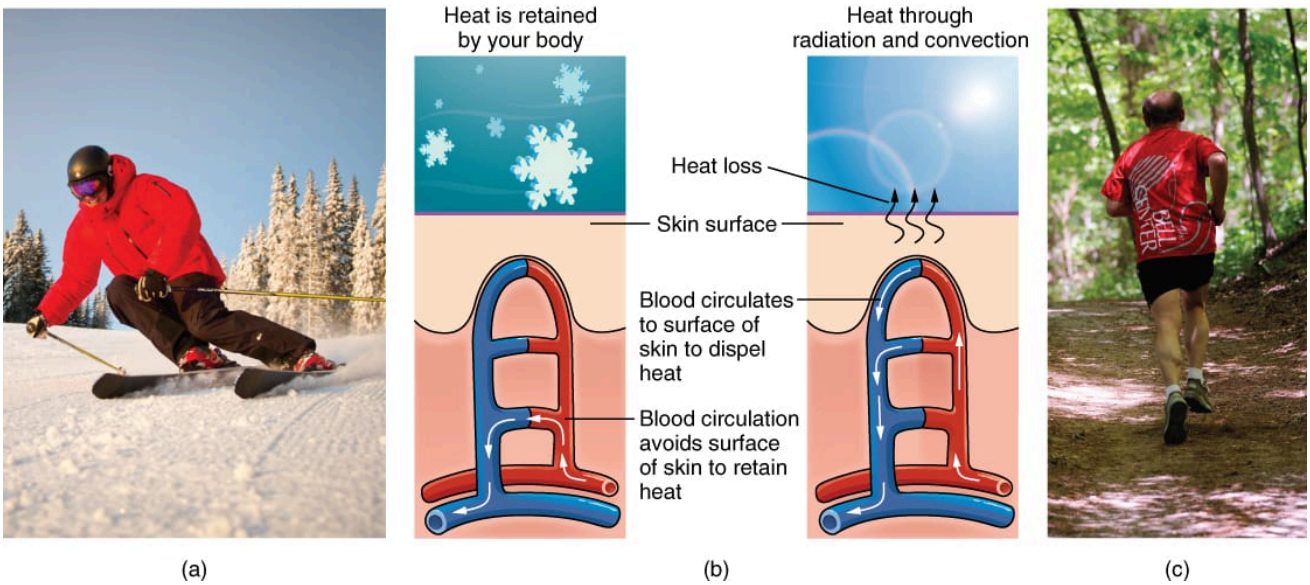

Figure 5.5 Thermoregulation. During strenuous physical activities, such as skiing (a) or running (c), the dermal blood vessels dilate and sweat secretion increases (b). These mechanisms prevent the body from overheating. In contrast, the dermal blood vessels constrict to minimize heat loss in response to low temperatures (b). (credit a: "Trysil"/Flickr; credit c: Ralph Daily). From Betts et al., 2013. Licensed under CC BY 4.0. [Image description.]

Concept Check

Can you describe the **thermoregulation** process between the integumentary system and the sympathetic system?

- What happens when the body temperature is too warm?

- What happens when the body temperature is too cold?

Vitamin D Synthesis

The epidermal layer of human skin synthesizes Vitamin D when exposed to UV radiation. In the presence of sunlight, a form of Vitamin D_3 called cholecalciferol is synthesized from a derivative of the steroid cholesterol in the skin. The liver converts cholecalciferol to calcidiol, which is then converted to calcitriol (the active chemical form of the vitamin) in the kidneys.

- Vitamin D is essential for the normal absorption of calcium and phosphorus, which are required for healthy bones.
- The absence of sun exposure can lead to a lack of vitamin D in the body. In children, this can cause rickets. Vitamin D deficiency in elderly individuals may lead to osteomalacia.
- In present-day society, Vitamin D is added as a supplement to many foods, including milk and orange juice, compensating for the need for sun exposure. In addition to its essential role in bone health, Vitamin D is essential for general immunity against bacterial, viral, and fungal infections.

Did you know?

Vitamin D is essential for general immunity against bacterial, viral, and fungal infections.

Watch this video:

YouTube Video

This interactive element is not available in this format. Visit the link or scan the QR code to access it online.

View this YouTube Video online

Media 5.2. The Integumentary System, Part 2 – Skin Deeper: Crash Course A&P #7 [Online video]. Copyright 2015 by CrashCourse.

Accessory Structures

Accessory structures of the skin include hair, nails, sweat glands, and sebaceous glands. These structures embryologically originate from the epidermis and can extend down through the dermis into the hypodermis.

Hair

Hair is a keratinous filament growing out of the epidermis. It is primarily made of dead, keratinized cells. Strands of hair originate in an epidermal penetration of the dermis called the hair follicle. The hair shaft is the part of the hair not anchored to the follicle, and much of this is exposed at the skin's surface. The rest of the hair, which is anchored in the follicle, lies below the surface of the skin and is referred to as the hair root. The hair root ends deep in the dermis at the hair bulb and includes a layer of mitotically active basal cells called the hair matrix. The hair bulb surrounds the hair papilla, which is made of connective tissue and contains blood capillaries and nerve endings from the dermis (see Figure 5.6).

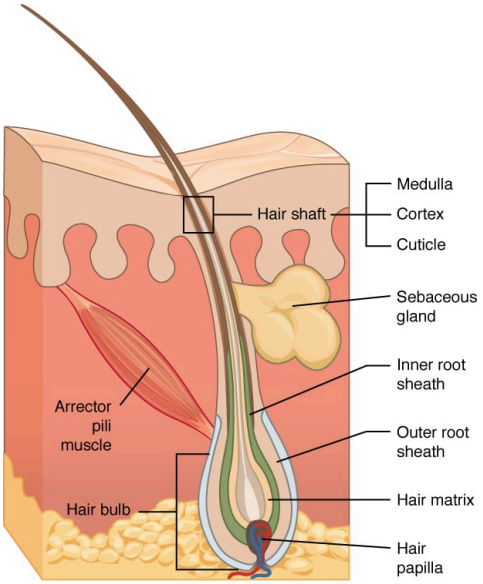

Figure 5.6 Hair. Hair follicles originate in the epidermis and have many different parts. From Betts et al., 2013. Licensed under CC BY 4.0. [Image description.]

Hair Function

Hair serves a variety of functions, including protection, sensory input, thermoregulation, and communication. For example:

- Hair on the head protects the skull from the sun.
- Hair in the nose and ears, and around the eyes (eyelashes) defends the body by trapping and excluding dust particles that may contain allergens and microbes.
- Hair of the eyebrows prevents sweat and other particles from dripping into and bothering the eyes.

Hair also has a sensory function due to sensory innervation by a hair root plexus surrounding the base of each hair follicle. Hair is extremely sensitive to air movement or other disturbances in the environment, much more so than the skin surface. This feature is also useful for the detection of the presence of insects or other potentially damaging substances on the skin surface.

Each hair root is connected to a smooth muscle called the arrector pili that contracts in response to nerve signals from the sympathetic nervous system, making the external hair shaft "stand up." The primary purpose for this is to trap a layer of air to add insulation. This is visible in humans as goosebumps. Of course, this is much more obvious in organisms with a heavier coat than most humans, such as when a frightened cat raises its fur.

> **Did you know?**
>
> When frightened, the arrector pili muscle is responsible for your hair standing on end. The same is true when a cat's fur is raised.

Hair Growth, Loss, and Color

Hair grows and is eventually shed and replaced by new hair. Hair typically grows at the rate of 0.3 mm per day. On average, 50 hairs are lost and replaced per day. Hair loss occurs if there is more hair shed than what is replaced and can happen due to hormonal or dietary changes. Hair loss can also result from the aging process, or the influence of hormones. Similar to the skin, hair gets its color from the pigment melanin, produced by melanocytes in the hair papilla. Different hair color results from differences in the type of melanin. As a person ages, the melanin production decreases, and hair tends to lose its color and becomes gray and/or white.

Nails

The **nail bed** is a specialized structure of the epidermis that is found at the tips of our fingers and toes. The nail body is formed on the nail bed and protects the tips of our fingers and toes as they are the farthest extremities and the parts of the body that experience the maximum mechanical stress (see Figure 5.7). The nail body forms a back-support for picking up small objects with the fingers. The nail body is composed of densely packed dead keratinocytes.

The epidermis in this part of the body has evolved a specialized structure upon which nails can form. The nail body forms at the nail root, which has a matrix of proliferating cells from the stratum basale that enables the nail to grow continuously. The lateral nail fold overlaps the nail on the sides, helping to anchor the nail body. The nail fold that meets the proximal end of the nail body forms the nail cuticle, also called the eponychium.

The nail bed is rich in blood vessels, making it appear pink, except at the base where a thick layer of epithelium over the nail matrix forms a crescent-shaped region called the **lunula** (the "little moon"). The area beneath the free edge of the nail, furthest from the cuticle, is called the hyponychium. It consists of a thickened layer of stratum corneum.

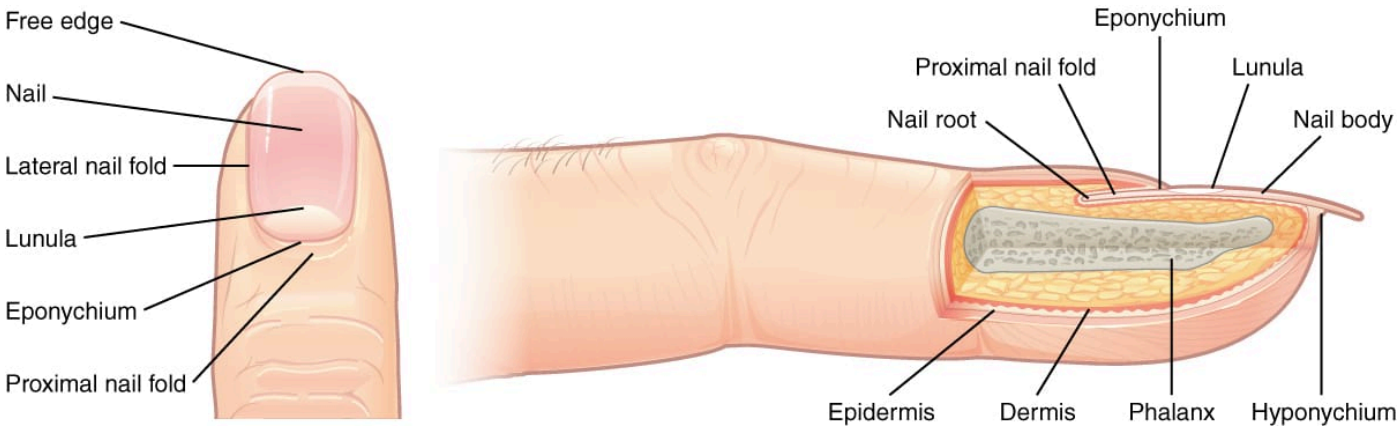

Figure 5.7 Nails. The nail is an accessory structure of the integumentary system. From Betts et al., 2013. Licensed under CC BY 4.0. [Image description.]

Sweat Glands

Sudoriferous Glands

When the body becomes warm, sudoriferous glands produce sweat to cool the body. Sweat glands develop from epidermal projections into the dermis and are classified as merocrine glands; that is, the secretions are secreted by exocytosis through a duct without affecting the cells of the gland. There are two types of sweat glands, each secreting slightly different products.

An **eccrine sweat gland** is a type of gland that produces hypotonic sweat for thermoregulation as described previously. These glands are found all over the skin's surface but are especially abundant on the palms of the hand, the soles of the feet, and the forehead (Figure 5.8). They are coiled glands lying deep in the dermis, with the duct rising up to a pore on the skin surface where the sweat is released. This type of sweat, released by exocytosis, is hypotonic and composed mostly of water, with some salt, antibodies, traces of metabolic waste, and dermcidin, an antimicrobial peptide. **Eccrine glands** are a primary component of thermoregulation in humans and thus help to maintain homeostasis.

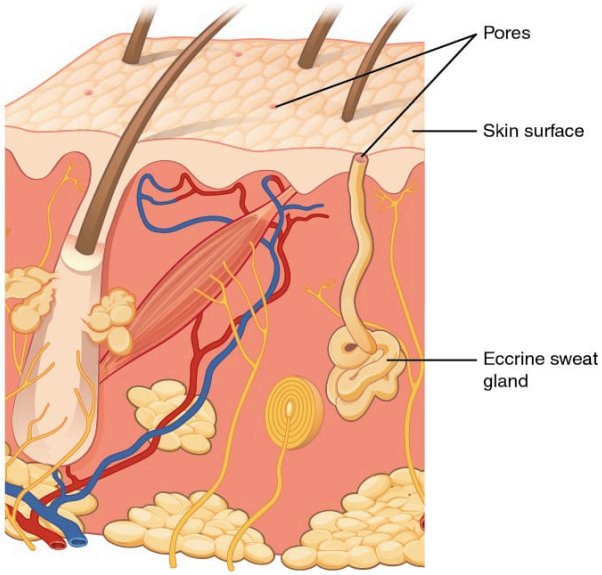

Figure 5.8 Eccrine Gland. Eccrine glands are coiled glands in the dermis that release sweat that is mostly water. From Betts et al., 2013. Licensed under CC BY 4.0. [Image description.]

An **apocrine sweat gland** is usually associated with hair follicles in densely hairy areas, such as armpits and genital regions. Apocrine sweat glands are larger than eccrine sweat glands and lie deeper in the dermis, sometimes even reaching the hypodermis, with the duct normally emptying into the hair follicle. In addition to water and salts, apocrine sweat includes organic compounds that make the sweat thicker and subject to bacterial decomposition and subsequent smell. The release of this sweat is under both nervous and hormonal control and plays a role in the poorly understood human pheromone response. Most commercial antiperspirants use an aluminum-based compound as their primary active ingredient to stop sweat. When the antiperspirant enters the sweat gland duct, the aluminum-based compounds precipitate due to a change in pH and form a physical block in the duct, which prevents sweat from coming out of the pore.

Sebaceous Glands

A **sebaceous gland** is a type of oil gland that is found all over the body and helps to lubricate and waterproof the skin and hair. Most sebaceous glands are associated with hair follicles. They generate and excrete sebum, a mixture of lipids, onto the skin surface, thereby naturally lubricating the dry and dead layer of keratinized cells of the stratum corneum, keeping it pliable. The fatty acids of sebum also have antibacterial properties and prevent water loss from the skin in low-humidity environments. The secretion of sebum is stimulated by hormones, many of which do not become active until puberty. Thus, sebaceous glands are relatively inactive during childhood.

Did you know?

Aluminum-based compounds due to a change in pH form a physical block in the sweat gland duct. This prevents sweating.

Practice Terms Related to the Integumentary System

Query 1.5.4

This interactive element is not available in this format. Visit the link or scan the QR code to access it online.

View this Interactive Content online

Common Abbreviations for the Integumentary System

Many terms and phrases related to the integumentary system are abbreviated. Learn these common abbreviations by expanding the list below.

Query 1.5.5

This interactive element is not available in this format. Visit the link or scan the QR code to access it online.

View this Interactive Content online

Changes Due to Aging

All systems in the body accumulate subtle and some not-so-subtle changes as a person ages. Among these changes are reductions in cell division, metabolic activity, blood circulation, hormonal levels, and muscle strength (see Figure 5.9). In the skin, these changes are reflected in decreased mitosis in the stratum basale, leading to a thinner epidermis. The dermis, which is responsible for the elasticity and resilience of the skin, exhibits a reduced ability to regenerate, which leads to slower wound healing. The hypodermis, with its fat stores, loses structure due to the reduction and redistribution of fat, which in turn contributes to the thinning and sagging of skin.

Figure 5.9 Aging. Generally, skin, especially on the face and hands, starts to display the first noticeable signs of aging, as it loses its elasticity over time. (credit: Janet Ramsden). From Betts et al., 2013. Licensed under CC BY 4.0. [Image description.]

The accessory structures also have lowered activity, generating thinner hair and nails, and reduced amounts of sebum and sweat. A reduced sweating ability can cause some elderly to be intolerant to extreme heat. Other cells in the skin, such as melanocytes and dendritic cells, also become less active, leading to a paler skin tone and lowered immunity. Wrinkling of the skin occurs due to the breakdown of its structure, which results from decreased collagen and elastin production in the dermis, weakening of muscles lying under the skin, and the inability of the skin to retain adequate moisture.

Did you know?

A reduced sweating ability can cause some older adults to be intolerant to extreme heat.

Diseases and Disorders of the Integumentary System

The integumentary system is susceptible to a variety of diseases, disorders, and injuries. These range from annoying but relatively benign bacterial or fungal infections that are categorized as disorders, to skin cancer and severe burns, which can be fatal. In this section, you will learn several of the most common skin conditions.

Most cancers are identified by the organ or tissue in which the cancer originates. In general, cancers result from an accumulation of DNA mutations. These mutations can result in cell populations that do not die when they should and uncontrolled cell proliferation that leads to tumors. Although many tumors are benign, some metastasize. Cancers are characterized by their ability to metastasize. One common form of cancer is skin cancer.

Sun Damage

Melanin synthesis peaks about 10 days after initial sun exposure, which is why pale-skinned individuals tend to suffer sunburns of the epidermis initially. Dark-skinned individuals can also get sunburns but are more protected than are pale-skinned individuals. Too much sun exposure can eventually lead to wrinkling due to the destruction of the cellular structure of the skin, and in severe cases, can cause sufficient DNA damage to result in skin cancer. When there is an irregular accumulation of melanocytes in the skin, freckles appear. Moles are larger masses of melanocytes, and although most are benign, they should be monitored for changes that might indicate the presence of cancer (see Figure 5.10).

Figure 5.10 Moles. Moles range from benign accumulations of melanocytes to melanomas. These structures populate the landscape of our skin. (credit: the National Cancer Institute). From Betts et al., 2013. Licensed under CC BY 4.0. [Image description.]

Basal Cell Carcinoma (BCC)

Basal cell carcinoma is a form of cancer that affects the mitotically active stem cells in the stratum basale of the epidermis. It is the most common of all cancers that occur in the United States and is frequently found on the head, neck, arms, and back, which are the most susceptible to long-term sun exposure. Although UV rays are the main culprit, exposure to other agents, such as radiation and arsenic, can also lead to this type of cancer. Wounds on the skin due to open sores, tattoos, burns, et cetera may be predisposing factors. Basal cell carcinomas start in the stratum basale and usually spread along this boundary. At some point, they begin to grow toward the surface and become an uneven patch, bump, growth, or scar on the skin surface (see Figure 5.11). Like most cancers, basal cell carcinomas respond best to treatment when caught early. Treatment options include surgery, freezing (cryosurgery), and topical ointments.

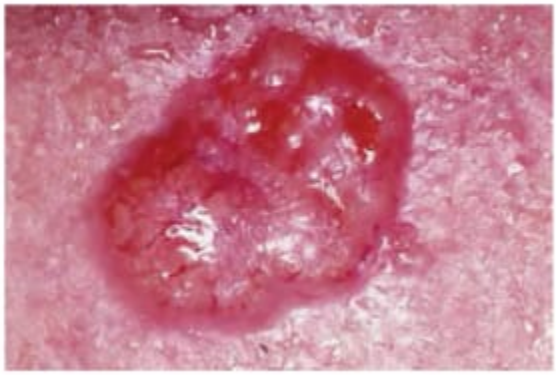

Figure 5.11 Basal Cell Carcinoma. Basal cell carcinoma can take several different forms. Similar to other forms of skin cancer, it is readily cured if caught early and treated. (credit: John Hendrix, MD). From Betts et al., 2013. Licensed under CC BY 4.0. [Image description.]

Squamous Cell Carcinoma (SCC)

Squamous cell carcinoma is cancer that affects the keratinocytes of the stratum spinosum and presents as lesions commonly found on the scalp, ears, and hands (see Figure 5.12). It is the second most common skin cancer. The American Cancer Society reports that two of 10 skin cancers are squamous cell carcinomas, and it is more aggressive than basal cell carcinoma. If not removed, these carcinomas can metastasize. Surgery and radiation are used to cure squamous cell carcinoma.

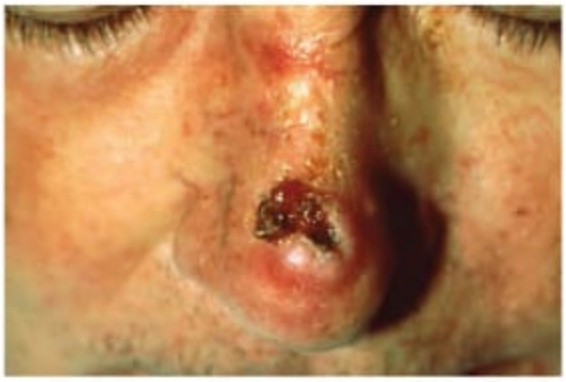

Figure 5.12 Squamous Cell Carcinoma Squamous cell carcinoma presents here as a lesion on a nose. (credit: the National Cancer Institute). From Betts et al., 2013. Licensed under CC BY 4.0. [Image description.]

Melanoma

Melanoma is cancer characterized by the uncontrolled growth of melanocytes, the pigment-producing cells in the epidermis. Typically, a melanoma develops from a mole. It is the most fatal of all skin cancers, as it is highly metastatic and can be difficult to detect before it has spread to other organs. Melanomas usually appear as asymmetrical brown and black patches with uneven borders and a raised surface (see Figure 5.13). Treatment typically involves surgical excision and immunotherapy.

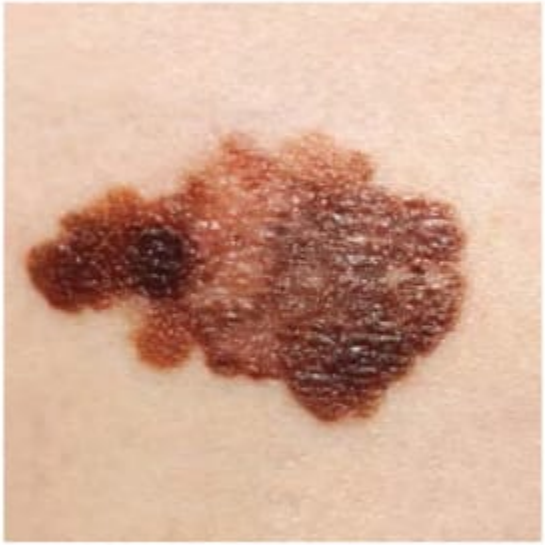

Figure 5.13 Melanoma. Melanomas typically present as large brown or black patches with uneven borders and a raised surface. (credit: the National Cancer Institute). From Betts et al., 2013. Licensed under CC BY 4.0. [Image description.]

ABCDE for Early Diagnosis

Doctors often give their patients the following ABCDE mnemonic to help with the diagnosis of early-stage melanoma. If you observe a mole on your body displaying these signs, consult a doctor:

- **A**symmetry: the two sides are not symmetrical
- **B**orders: the edges are irregular in shape
- **C**olor: the color is varied shades of brown or black
- **D**iameter: it is larger than 6 mm (0.24 in)
- **E**volving: its shape has changed

Some specialists cite the following additional signs for the most serious form, nodular melanoma:

- Elevated: it is raised on the skin surface
- Firm: it feels hard to the touch
- Growing: it is getting larger

Albinism

Albinism is a genetic disorder that affects (completely or partially) the coloring of skin, hair, and eyes. This is primarily due to the inability of melanocytes to produce melanin. Individuals with albinism tend to appear white or very pale due to the lack of melanin in their skin and hair. Recall that melanin helps protect the skin from the harmful effects of UV radiation. Individuals with albinism tend to need more protection from UV radiation, as they are more prone to sunburns and skin cancer. They also tend to be more sensitive to light and have vision problems due to the lack of pigmentation on the retinal wall.

Treatment of this disorder usually involves addressing the symptoms, such as limiting UV light exposure to the skin and eyes. In vitiligo, the melanocytes in certain areas lose their ability to produce melanin, possibly due to an autoimmune reaction. This leads to a loss of color in patches (see Figure 5.14). Neither albinism nor vitiligo directly affects the lifespan of an individual.

Figure 5.14 Vitiligo. Individuals with vitiligo experience depigmentation that results in lighter colored patches of skin. The condition is especially noticeable on darker skin. (credit: Klaus D. Peter). From Betts et al., 2013. Licensed under CC BY 4.0. [Image description.]

Changes in Skin Coloration

Other changes in the appearance of skin coloration can be indicative of diseases associated with other body systems.

- Liver disease or liver cancer can cause the accumulation of bile and the yellow pigment bilirubin, leading to the skin appearing **yellow** or jaundiced.
- Tumors of the pituitary gland can result in the secretion of large amounts of melanocyte-stimulating hormone (MSH), which results in a **darkening** of the skin.
- Addison's disease can stimulate the release of excess amounts of adrenocorticotropic hormone (ACTH), which can give the skin a **deep bronze** color
- A sudden drop in oxygenation can affect skin color, causing the skin to initially turn **ashen** (white).
- After a prolonged reduction in oxygen levels, dark red deoxyhemoglobin becomes dominant in the blood, making the skin appear **blue**, a condition referred to as cyanosis. This happens when the oxygen supply is restricted, as when someone is experiencing difficulty in breathing because of asthma or a heart attack. However, in these cases, the effect on skin color has nothing to do with the skin's pigmentation.

Skin Disorders

Two common skin disorders are eczema and acne. Eczema is an inflammatory condition and occurs in individuals of all ages. Acne involves the clogging of pores, which can lead to infection and inflammation and is often seen in adolescents. Other disorders include seborrheic dermatitis (on the scalp), psoriasis, fungal infections, cold sores, impetigo, scabies, hives, and warts.

Eczema

Eczema is an allergic reaction that manifests as dry, itchy patches of skin that resemble rashes (see Figure 5.15). It may be accompanied by swelling of the skin, flaking, and in severe cases, bleeding. Symptoms are usually managed with moisturizers, corticosteroid creams, and immunosuppressants.

Figure 5.15 Eczema. Eczema is a common skin disorder that presents as a red, flaky rash. (credit: "Jambula"/Wikimedia Commons). From Betts et al., 2013. Licensed under CC BY 4.0. [Image description.]

Acne

Acne is a skin disturbance that typically occurs on areas of the skin that are rich in sebaceous glands (face and back). It is most common along with the onset of puberty due to associated hormonal changes, but can also occur in infants and continue into adulthood. Hormones, such as androgens, stimulate the release of sebum. Overproduction and accumulation of sebum along with keratin can block hair follicles. This plug is initially white. The sebum, when oxidized by exposure to air, turns black. Acne results from infection by acne-causing bacteria (Propionibacterium and Staphylococcus), which can lead to redness and potential scarring due to the natural wound healing process (see Figure 5.16).

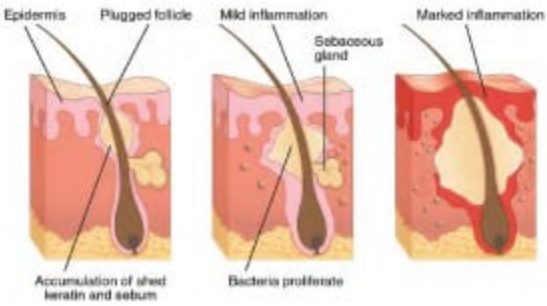

Figure 5.16. Acne. Acne is a result of over-productive sebaceous glands, which leads to the formation of blackheads and inflammation of the skin. From Betts et al., 2013. Licensed under CC BY 4.0. [Image description.]

Ringworm

Tinea or dermatophytosis is often referred to as ringworm. Ringworm presents as a circular rash that is itchy and red and can be found on various parts of the body. It is referred to by the location that it is found:

- Tinea pedis – feet (commonly referred to as athlete's feet)
- Tinea capitis – scalp
- Tinea barbae – beard
- Tinea manuum – hands
- Tinea unguium – toenails and fingernails (also called onychomycosis)
- Tinea corporis – body parts such as arms and legs (Center for Disease Control and Prevention, n.d.-a)

To learn more about ringworm, visit the Center for Disease Control and Prevention's web page on fungal infections.

Psoriasis

Psoriasis is a chronic autoimmune disorder that results in patches of thick red skin with the appearance of silvery scales. These patches can be found on elbows, knees, scalp, low back, face, feet, fingernails, toenails, and even the mouth. Psoriasis can be confused with other skin diseases, so a dermatologist is the best physician to diagnose psoriasis. Treatments may include creams, ointments, ultraviolet light therapy, and medication (Center for Disease Control and Prevention, n.d.-b). To learn more, visit the Center for Disease Control and Prevention's web page on psoriasis.

Injuries

Because the skin is the part of our bodies that meets the world most directly, it is especially vulnerable to injury. Injuries include **burns, wounds**, **scars,** and **calluses**. They can be caused by sharp objects, heat, or excessive pressure or friction to the skin.

Skin injuries set off a healing process that occurs in several overlapping stages.

- The first step to repairing damaged skin is the **formation of a blood clot** that helps stop the flow of blood and scabs over time. Many different types of cells are involved in wound repair, especially if the surface area that needs repair is extensive.
- Before the basal stem cells of the stratum basale can recreate the epidermis, fibroblasts mobilize and divide rapidly to **repair the damaged tissue** by collagen deposition, forming granulation tissue.
- Blood capillaries follow the fibroblasts and help **increase blood circulation and oxygen** supply to the area.
- Immune cells, such as macrophages, roam the area and **engulf any foreign matter** to reduce the chance of infection.

Burns

A burn results when the skin is damaged by intense heat, radiation, electricity, or chemicals. The damage results in the death of skin cells, which can lead to a massive loss of fluid. Dehydration, electrolyte imbalance, and renal and circulatory failure follow, which can be fatal. Burn patients are treated with intravenous fluids to offset dehydration, as well as intravenous nutrients that enable the body to repair tissues and replace lost proteins. Another serious threat to the lives of burn patients is infection. Burned skin is extremely susceptible to bacteria and other pathogens due to the loss of protection by intact layers of skin.

Burn Classification

Burns are sometimes measured in terms of the size of the total surface area affected. This is referred to as the *rule of nines*, which associates specific anatomical areas with a percentage that is a factor of nine (see Figure 5.17).

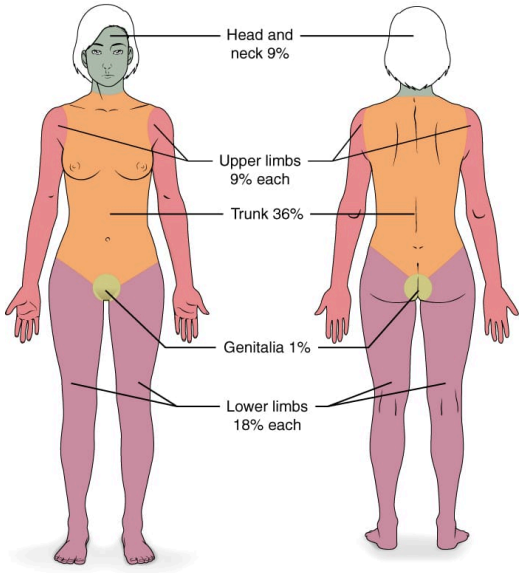

Figure 5.17 Calculating the Size of a Burn. The size of a burn will guide decisions made about the need for specialized treatment. Specific parts of the body are associated with a percentage of body area. From Betts et al., 2013. Licensed under CC BY 4.0. [Image description.]

Burns are also classified by the degree of their severity:

- A **first-degree** burn is a superficial burn that affects only the epidermis. Although the skin may be painful and swollen, these burns typically heal on their own within a few days. Mild sunburn fits into the category of a first-degree burn.
- A **second-degree** burn goes deeper and affects both the epidermis and a portion of the dermis. These burns result in swelling and a painful blistering of the skin. It is important to keep the burn site clean and sterile to prevent infection. If this is done, the burn will heal within several weeks.
- A **third-degree** burn fully extends into the epidermis and dermis, destroying the tissue and affecting the nerve endings and sensory function. These are serious burns that may appear white, red, or black; they require medical attention and will heal slowly without it.
- A **fourth-degree** burn is even more severe, affecting the underlying muscle and bone.

Oddly, third and fourth-degree burns are usually not as painful because the nerve endings themselves are damaged. Full-thickness burns cannot be repaired by the body, because the local tissues used for repair are damaged and require debridement, or amputation in severe cases, followed by grafting of the skin from an unaffected part of the body, or from skin grown in tissue culture for grafting purposes. Skin grafts are required when the damage from trauma or infection cannot be closed with sutures or staples.

Scars and Keloids

Most cuts or wounds, with the exception of ones that only scratch the epidermis, lead to scar formation. Scarring occurs in cases in which there is repair of skin damage, but the skin fails to regenerate the original skin structure. Fibroblasts generate scar tissue in the form of collagen, and the bulk of repair is due to the basket-weave pattern generated by collagen fibers and does not result in regeneration of the typical cellular structure of skin. Instead, the tissue is fibrous in nature and does not allow for the regeneration of accessory structures, such as hair follicles, sweat glands, or sebaceous glands.

Sometimes, there is an overproduction of scar tissue, because the process of collagen formation does not stop when the wound is healed; this results in a keloid. In contrast, scars that result from acne and chickenpox have a sunken appearance and are called atrophic scars.

Scarring of skin after wound healing is a natural process and does not need to be treated further. Application of mineral oil and lotions may reduce the formation of scar tissue. However, modern cosmetic procedures, such as dermabrasion, laser treatments, and filler injections have been invented as remedies for severe scarring. All of these procedures try to reorganize the structure of the epidermis and underlying collagen tissue to make it look more natural.

Bedsores and Stretch Marks

Skin and its underlying tissue can be affected by excessive pressure. One example of this is called a bedsore. Bedsores, also called **decubitus ulcers**, are caused by constant, long-term, unrelieved pressure on certain body parts that are bony, reducing blood flow to the area and leading to necrosis. Bedsores are most common in elderly patients who have debilitating conditions that cause them to be immobile. Most hospitals and long-term care facilities have the practice of turning the patients every few hours to prevent the incidence of bedsores. If left untreated, bedsores can be fatal if they become infected.

The skin can also be affected by pressure associated with rapid growth. A stretch mark results when the dermis is stretched beyond its limits of elasticity, as the skin stretches to accommodate the excess pressure. Stretch marks usually accompany rapid weight gain during puberty and pregnancy. They initially have a reddish hue but lighten over time. Other than for cosmetic reasons, treatment of stretch marks is not required. They occur most commonly over the hips and abdomen.

Calluses

When you wear shoes that do not fit well and are a constant source of abrasion on your toes, you tend to form a callus at the point of contact. This occurs because the basal stem cells in the stratum basale are triggered to divide more often to increase the thickness of the skin at the point of abrasion to protect the rest of the body from further damage. This is an example of a minor or local injury, and the skin manages to react and treat the problem independently of the rest of the body. Calluses can also form on your fingers if they are subject to constant mechanical stress, such as long periods of writing, playing string instruments, or video games. A corn is a specialized form of callus. Corns form from abrasions on the skin that result from an elliptical-type motion.

Medical Terms in Context

Query 1.5.6

This interactive element is not available in this format. Visit the link or scan the QR code to access it online.

View this Interactive Content online

Query 1.5.7

This interactive element is not available in this format. Visit the link or scan the QR code to access it online.

View this Interactive Content online

Medical Specialties and Procedures Related to the Integumentary System

A dermatologist is a medical doctor with specialized training in treating diseases, disorders, and injuries related to the integumentary system and its accessory structures. There are many dermatologic subspecialties, such as cosmetic dermatology, dermatopathology, and pediatric dermatology. To learn more, visit the American Academy of Dermatology Association's webpage on dermatology as a career.

Dermatologists can be specially trained to perform a procedure called Mohs surgery. Mohs surgery excises skin cancers in thin

layers until all cancer is removed from the tissue (Prickett & Ramsey, 2021).

Integumentary System Vocabulary

Abscess: An enclosed collection of pus in tissues, organs, or confined spaces in the body.

Adipocyte: Fat cell.

Adipose tissue: Fat tissue.

Autonomic: Involuntary or unconscious.

Avascular: Without blood vessels.

Bacteria: Single-cell microorganisms that reproduce by cell division and may cause infection by invading body tissue.

Benign: Non-cancerous.

Biopsy: The removal of cells or tissues for examination by a pathologist.

Cancer: Abnormal cells in the body that divide uncontrollably.

Cauterize: To destroy tissue using a hot or cold instrument, an electrical current, or a chemical that burns or dissolves the tissue to kill tumors or stop bleeding.

Cellulitis: An infection of the skin and subcutaneous tissue, characterized by tenderness, fever, and blisters.

Contusion: Injury resulting in a bruise.

Cyanosis: A condition in which the oxygen supply is restricted, causing the skin to look blue.

Cyst: Closed sac containing fluid or semisolid material.

Debridement : Excision of damaged tissues and cell debris from a wound or burn to prevent infection and promote healing.

Dehydration : A net loss of water that results in insufficient water in blood and other tissues.

Dermabrasion: A procedure to remove superficial scars using sandpaper or revolving wire brushes.

Dermatitis: Inflammation of the skin.

Dermatofibroma: Fibrous tumor of the skin.

Dermatologist: Medical doctor who specializes in diagnosing and treating skin disorders.

Dermatology: Study of disorders of the skin.

Dermis: The layer of skin that is made of dense, irregular connective tissue that houses blood vessels, hair follicles, sweat glands, and other structures.

Diaphoresis: Sweating.

Eczema: Non-infectious, inflammatory disease presenting as redness, blisters, scabs, and itching.

Edema: Swelling due to excessive liquid in the tissues.

Epidermis: The outer, protective layer of the skin.

Excisional skin surgery: A surgical procedure used to remove moles, cysts, skin cancer, and other skin growths using local anesthesia.

Exocytosis: A form of active transport in which a cell exports material using vesicular transport.

Fascia: Fibrous tissue.

Frostbite: A condition in which conservation of the body core heat results in the skin freezing.

Gangrene: Death of tissue due to blood supply loss.

Hidradenitis: Inflammation of a sweat gland.

Hypodermis: Also known as the subcutaneous layer; the layer of the skin below the dermis that is composed mainly of loose connective and fatty tissues.

Incision: A cut made in the body to perform surgery.

Infection: The invasion and growth of bacteria, viruses, yeast, fungi, or other microorganisms in the body.

Intradermal: Within the skin.

Intravenous: Into or within the vein.

Jaundiced: Yellow-colored.

Keloid: A raised or hypertrophic scar.

Keratinocytes: Cells that manufacture and store the protein keratin.

Keratosis: Any growth of horny tissue.

Laceration: Torn, ragged-edged wound.

Lesion: An area of abnormal tissue.

Meissner corpuscle: A specialized sensory nerve structure that responds to light touch.

Melanocyte: A cell that produces the pigment melanin.

Metastasis: The process in which cancer spreads from one part of the body to another.

Necrosis: Accidental cell death.

Nevus: A benign growth on the skin that is formed by a cluster of melanocytes.

Nodule: A growth or lump that may be malignant or benign.

Onychocryptosis: An ingrown nail.

Onychomycosis: A fungal infection of the nail.

Onychophagia: Nail-biting.

Osteomalacia: A softening of adult bones due to Vitamin D deficiency.

Pacinian corpuscle: A specialized sensory nerve structure that responds to vibration.

Pallor: Unnatural paleness of the skin.

Paronychia: Infection of the skin around the nail.

Pathogen: An organism that causes a disease.

Percutaneous: Passing through the skin, as an injection or a topical medicine.

Phagocytes: Cells that engulf and absorb bacteria and cell particles.

Pruritus: Itching.

Reticulated: Net like.

Rhytidoplasty: Excision of wrinkles of the skin.

Rickets: A painful condition in children where bones are misshapen due to a lack of calcium, causing bow-leggedness.

Scar: A collagen-rich skin formed after the process of wound healing that differs from normal skin.

Staphylococcus aureus: A bacteria that is commonly found in minor skin infections, as well as in the nose of some healthy people.

Stratum basale: The deepest layer of the epidermis.

Streptococcus: The bacteria that causes strep throat.

Subcutaneous: Beneath the skin.

Sympathetic nervous system: The division of the nervous system involved in our fight-or-flight responses. It continuously monitors body temperature and initiates appropriate motor responses.

Tinea: A group of fungal skin diseases of the hair, skin, and nail tissues.

Transdermal: Absorbed through the unbroken skin.

Vascularized: Tissue that has numerous blood vessels.

Virus: A simple microorganism that may cause infection by invading body tissue.

Test Yourself

Query 1.5.8

This interactive element is not available in this format. Visit the link or scan the QR code to access it online.

View this Interactive Content online

References

Centers for Disease Control and Prevention. (n.d.-a). Ringworm. Centers for Disease Control and Prevention: Fungal Diseases. https://www.cdc.gov/fungal/diseases/ringworm/definition.html

Centers for Disease Control and Prevention. (n.d.-b). Psoriasis. Centers for Disease Control and Prevention: Fungal Diseases. https://www.cdc.gov/psoriasis/

CrashCourse. (2015, January 6). The Integumentary system, part 1 – skin deep: Crash Course A&P #6 [Video]. YouTube. https://youtu.be/Orumw-PyNjw

CrashCourse. (2015, February 16). The Integumentary system, part 2 – skin deeper: Crash Course A&P #7 [Video]. YouTube.

https://youtu.be/EN-x-zXXVwQ

Prickett, K. A., & Ramsey, M. L. (2021). Mohs micrographic surgery. In StatPearls [Internet]. https://www.ncbi.nlm.nih.gov/books/NBK441833/

Image Descriptions

Figure 5.1 image description: This illustration shows a cross-section of skin tissue. The outermost layer is called the epidermis and occupies one-fifth of the cross-section. Several hairs are emerging from the surface. The epidermis dives around one of the hairs, forming a follicle. The middle layer is called the dermis, which occupies four-fifths of the cross-section. The dermis contains an arrector pili muscle connected to one of the follicles. The dermis also contains an eccrine sweat gland, composed of a bunch of tubules. One tubule travels up from the bunch, through the epidermis, opening onto the surface of a pore. There are two string-like nerves traveling vertically through the dermis. The right nerve is attached to a Pacinian corpuscle, which is a yellow structure consisting of concentric ovals similar to an onion. The lowest level of the skin, the hypodermis, contains fatty tissue, arteries, and veins. Blood vessels travel from the hypodermis and connect to hair follicles and arrector pili muscle in the dermis. [Return to Figure 5.1].

Figure 5.2 image description: Part A is a micrograph showing a cross-section of thin skin. The topmost layer is a thin, translucent layer with irregular texture and areas where cells are sloughing off. The deepest layer is dark purple and extends into the third layer with finger-like projections. The third light purple layer contains thin bands of fibers and small, dark cells. The fourth, and deepest layer, is darker than the third layer but is still light purple. It contains thick fiber bands that are loosely packed. Part B is a magnified view of the epidermis of thick skin. It shows the topmost layer is five times thicker than the topmost layer of thin skin. The topmost layer of thick skin is also denser and less translucent than the topmost layer of thin skin. [Return to Figure 5.2].

Figure 5.3 image description: The outer layer of cells in this micrograph is the thinnest layer and stained deep purple due to the full keratinization of dead cells. The next layer occupies one-quarter of the micrograph, is lightly stained, and is a dense collection of cells. The third layer from the top is mostly white, with lightly stained, loosely-packed strands radiating in random directions. The bottom-most layer is densely-packed, with thick bands of highly organized muscle tissue that are darkly stained. [Return to Figure 5.3].

Figure 5.4 image description: This micrograph shows layers of skin in a cross-section. The papillary layer of the dermis extends between the downward fingers of the darkly stained epidermis. The papillary layer appears finer than the reticular layer, consisting of smaller, densely-packed fibers. The reticular layer is three times thicker than the papillary layer and contains larger, thicker fibers. The fibers seem more loosely packed than those of the papillary layer, with some separated by empty spaces. Both layers of the dermis contain cells with darkly stained nuclei. [Return to Figure 5.4].

Figure 5.5 image description: Part A is a photo of a man skiing with several snow-covered trees in the background. Part B is a diagram with a right and left half. The left half is titled " Heat is retained by the body," while the right half is titled "Heat loss through radiation and convection." Both show blood flowing from an artery through three capillary beds within the skin. The beds are arranged vertically, with the topmost bed located along the boundary of the dermis and epidermis. The bottommost bed is located deep in the hypodermis. The middle bed is evenly spaced between the topmost and bottommost beds. In each bed, oxygenated blood (red) enters the bed on the left and deoxygenated blood (blue) leaves the bed on the right. The left diagram shows a picture of snowflakes above the capillary beds, indicating that the weather is cold. Blood is only flowing through the deepest of the three capillary beds, as the upper beds are closed off to reduce heat loss from the outer layers of the skin. The right diagram shows a picture of the sun above the capillary beds, indicating that the weather is hot. Blood is flowing through all three capillary beds, allowing heat to radiate out of the blood, increasing heat loss. Part C is a photo of a man running through a forested trail on a summer day. [Return to Figure 5.5].

Figure 5.6 image description: A cross-section of the skin containing a hair follicle. The follicle is teardrop-shaped. Its enlarged base, labeled the hair bulb, is embedded in the hypodermis. The outermost layer of the follicle is the epidermis, which invaginates from the skin surface to envelop the follicle. Within the epidermis is the outer root sheath, which is only present on the hair bulb. It does not extend up the shaft of the hair. Within the outer root sheath is the inner root sheath. The inner root sheath extends about half of the way up the hair shaft, ending midway through the dermis. The hair matrix is the innermost layer. The hair matrix surrounds the bottom of the hair shaft where it is embedded within the hair bulb. The hair shaft, in itself, contains three layers: the outermost cuticle, a middle layer called the cortex, and an innermost layer called the medulla. [Return to Figure 5.6].

Figure 5.7 image description: The anatomy of the fingernail region. The top image shows a dorsal view of a finger. The proximal

nail fold is the part underneath where the skin of the finger connects with the edge of the nail. The eponychium is a thin, pink layer between the white proximal edge of the nail (the lunula), and the edge of the finger skin. The lunula appears as a crescent-shaped white area at the proximal edge of the pink-shaded nail. The lateral nail folds are where the sides of the nail contact the finger skin. The distal edge of the nail is white and is called the free edge. An arrow indicates that the nail grows distally out from the proximal nail fold. The lower image shows a lateral view of the nail bed anatomy. In this view, one can see how the edge of the nail is located just proximal to the nail fold. This end of the nail, from which the nail grows, is called the nail root. [Return to Figure 5.7].

Figure 5.8 image description: An illustration of an eccrine sweat gland embedded in a cross-section of skin tissue. The eccrine sweat gland is a bundle of white tubes embedded in the dermis. A single white tube travels up from the bundle and opens onto the surface of the epidermis. The opening is called a pore. There are several pores on the small block of skin portrayed in this diagram. [Return to Figure 5.8].

Figure 5.9 image description: This figure consists of two photos. One photo shows a young woman on the phone. Her skin is smooth and unwrinkled. The other photo shows an elderly woman in the same posture while on the phone. The skin of her hands and forearms is wrinkled. [Return to Figure 5.9].

Figure 5.10 image description: Five photos of moles. The three upper photos show moles that are small, flat, and dark brown. The bottom left photo shows a dark black mole that is raised above the skin. The bottom right photo shows a large, raised, reddish mole with protruding hairs. [Return to Figure 5.10].

Figure 5.11 image description: This photo shows an enlarged view of a basal cell carcinoma, a large, pink, irregular bump on the skin. The carcinoma is marked with irregular, dark-red stripes that resemble tiny blood vessels. The surrounding skin is the same pink color as the carcinoma, but without the red striping or raised appearance. [Return to Figure 5.11].

Figure 5.12 image description: This photo shows a man's nose. The squamous cell carcinoma is located just above the tip of the nose and appears as a deep red, irregularly-shaped sore that spans almost the entire bridge of his nose. [Return to Figure 5.12].

Figure 5.13 image description: This photo shows a patch of fair skin containing a large melanoma. The melanoma is dark brown and splotchy in appearance. [Return to Figure 5.13].

Figure 5.14 image description: This photo shows the back of a man's neck. There is a large, discolored patch of skin at the base of his hairline. The discolored area extends over the ears onto the cheeks, toward the front of the face. The man's head and facial hair are mostly gray, but white patches of hair are seen above the discolored skin. [Return to Figure 5.14].

Figure 5.15 image description: This photo shows a person with eczema on the ventral skin of the forearms. The person is white, but their light skin is mottled with many red marks, giving it the appearance of a rash. In some areas, the skin is breaking and peeling. [Return to Figure 5.15].

Figure 5.16 image description: Three diagrams show the progression of acne in three steps from left to right. All three depict a cross-section of skin containing a hair follicle. In the left diagram, the follicle has a swollen area about halfway up the hair shaft, just above a sebaceous gland. The follicle is plugged with sebum, depicted as a yellowish substance. In the middle diagram, the follicle has become more swollen, as a label indicates that bacteria are reproducing within the blockage. The surrounding epidermis becomes inflamed as a result of the bacterial infection. In the rightmost image, the blockage has swollen to about five times its original size and has broken the surrounding epidermis, which is now red and inflamed. [Return to Figure 5.16].

Figure 5.17 image description: This diagram depicts the percentage of the total body area burned when a victim suffers complete burns to regions of the body. Complete burning of the face, head, and neck account for 19% of the total body area. Burning of the chest, abdomen, and entire back above the waist accounts for 36% of the total body area. Anterior and posterior surfaces of the arms and hands account for 18% of the total body area (9% for each arm). The anterior and posterior surface of both legs, along with the buttocks, accounts for 36% of the total body area (18% for each leg). Finally, the anterior and posterior surfaces of the genitalia account for 1% of the total body area. [Return to Figure 5.17].

Unless otherwise indicated, this chapter contains material adapted from *Anatomy and Physiology* (on OpenStax), by Betts et al. and is used under a CC BY 4.0 international license. Download and access this book for free at https://openstax.org/books/anatomy-and-physiology/pages/1-introduction.

This page titled 1.5: Integumentary System is shared under a CC BY 4.0 license and was authored, remixed, and/or curated by Andrea Nelson and Katherine Greene via source content that was edited to the style and standards of the LibreTexts platform.

1.6: Skeletal System

Learning Objectives

- Examine the anatomy of the skeletal system
- Determine the main functions of the skeletal system
- Differentiate the medical terms of the skeletal system
- Discover common diseases, disorders, and procedures related to the skeletal system
- Recognize common medical specialties associated with the skeletal system

Skeletal System Word Parts

Click on prefixes, combining forms, and suffixes to reveal a list of word parts to memorize for the Skeletal System.

Query 1.6.1

This interactive element is not available in this format. Visit the link or scan the QR code to access it online.

View this Interactive Content online

Introduction to the Skeletal System

The **skeletal system** forms the framework of the body. It is the body system composed of bones, cartilage, and ligaments. Each bone serves a particular function and varies in size, shape, and strength. Bones are weight-bearing structures in your body and can therefore change in thickness as you gain or lose weight. The skeletal system performs the following critical functions for the human body:

- supports the body
- facilitates movement
- protects internal organs
- produces blood cells
- stores and releases minerals and fat

Watch this video:

YouTube Video

This interactive element is not available in this format. Visit the link or scan the QR code to access it online.

View this YouTube Video online

Media 6.1. The Skeletal System: Crash Course A&P #19 [Online video]. Copyright 2015 by CrashCourse.

Practice Medical Terms Related to the Skeletal System

Query 1.6.2

This interactive element is not available in this format. Visit the link or scan the QR code to access it online.

View this Interactive Content online

Anatomy (Structures) of the Skeletal System

The skeletal system includes all of the bones, cartilages, and ligaments of the body that support and give shape to the body and body structures. The **skeleton** consists of the bones of the body. For adults, there are 206 bones in the skeleton. Younger individuals have higher numbers of bones because some bones fuse together during childhood and adolescence to form an adult bone. The primary functions of the skeleton are to provide a rigid, internal structure that can support the weight of the body against the force of gravity, and to provide a structure upon which muscles can act to produce movements of the body.

In addition to providing for support and movements of the body, the skeleton has protective and storage functions. It protects the internal organs, including the brain, spinal cord, heart, lungs, and pelvic organs. The bones of the skeleton serve as the primary storage site for important minerals such as calcium and phosphate. The bone marrow found within bones stores fat and houses the blood-cell-producing tissue of the body.

The skeleton is subdivided into two major divisions: the **axial** and **appendicular**.

The Axial Skeleton

The **axial skeleton** forms the vertical, central axis of the body and includes all bones of the head, neck, chest, and back (see Figure 6.1). It serves to protect the brain, spinal cord, heart, and lungs. It also serves as the attachment site for muscles that move the head, neck, and back, and for muscles that act across the shoulder and hip joints to move their corresponding limbs.

The axial skeleton of the adult consists of 80 bones, including the **skull**, the **vertebral column**, and the **thoracic cage**. The skull is formed by 22 bones. Also associated with the head are an additional seven bones, including the **hyoid bone** and the **ear ossicles** (three small bones found in each middle ear). The vertebral column consists of 24 bones, each called a **vertebra**, plus the **sacrum** and **coccyx**. The thoracic cage includes the 12 pairs of **ribs** and the **sternum**, the flattened bone of the anterior chest.

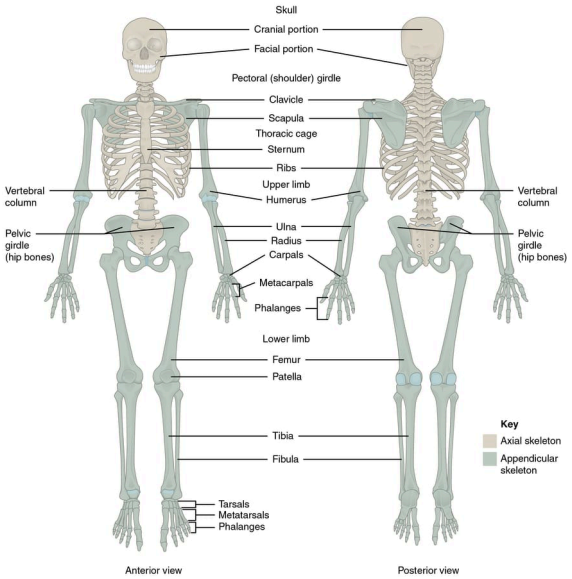

Figure 6.1 Axial and Appendicular Skeleton. The axial skeleton supports the head, neck, back, and chest and thus forms the vertical axis of the body. It consists of the skull, vertebral column (including the sacrum and coccyx), and the thoracic cage, formed by the ribs and sternum. The appendicular skeleton is made up of all bones of the upper and lower limbs. From Betts et al., 2013. Licensed under CC BY 4.0. [Image description.]

The **cranium** or skull supports the face and protects the brain. It is subdivided into the bones of the skull and the bones of the face.

Bones of the Skull

- **Frontal** – forms the forehead
- **Parietal** – the upper lateral sides of the cranium
- **Occipital** – the posterior skull and base of the cranial cavity
- **Temporal** – the lower lateral sides of the cranium
- **Sphenoid** -the 'keystone' bone that forms part of the base of the skull and eye sockets
- **Ethmoid** – forms part of the nose and orbit and base of the cranium
- **Auditory ossicles** – the small bones of the middle ear
- **External auditory meatus** – the external opening of the ear and temporal bone

Bones of the Face

- **Zygomatic** – the cheekbone
- **Maxillary** – the upper jaw and hard palate
- **Palatine** – the lateral walls of the nose
- **Lacrimal** – the walls of the orbit
- **Inferior conchae** – the lower lateral wall of the nasal cavity
- **Vomer –** the bone that separates the left and right nasal cavity
- **Mandible** – the lower jaw bone (the only movable bone of the skull)
- **Hyoid –** the bone located between the mandible and larynx, not connected to other bones

Did you know?

The axial skeleton has 80 bones and includes bones of the skull (and face), vertebral column, and thoracic cage.

Bones of the Vertebral Column

The vertebral column is also known as the spinal column or spine (see Figure 6.2). It consists of a sequence of vertebrae (singular = vertebra), each of which is separated and united by an **intervertebral disc**. Together, the vertebrae and intervertebral discs form the vertebral column. It is a flexible column that supports the head, neck, and body and allows for their movements. It also protects the spinal cord, which passes down the back through openings in the vertebrae.

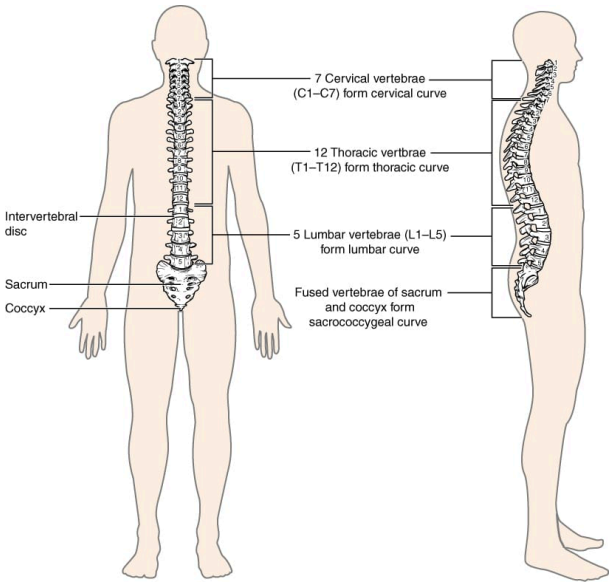

Figure 6.2 Vertebral Column. The adult vertebral column consists of 24 vertebrae, plus the sacrum and coccyx. The vertebrae are divided into three regions: cervical C1–C7 vertebrae, thoracic T1–T12 vertebrae, and lumbar L1–L5 vertebrae. The vertebral column is curved, with two primary curvatures (thoracic and sacrococcygeal curves) and two secondary curvatures (cervical and lumbar curves). From Betts et al., 2013. Licensed under CC BY 4.0. [Image description.]

Types of Vertebrae

- **Cervical** – C1 to C7, the first 7 vertebrae in the neck region
- **Thoracic** – T1 to T12, the next 12 vertebrae that form the outward curvature of the spine
- **Lumbar** – L1 to L5, the next 5 vertebrae that form the inner curvature of the spine
- **Sacrum** – the triangular-shaped bone at the base of the spine
- **Coccyx** – the tailbone

Bones of the Thoracic Cavity

The thoracic cage (rib cage) forms the thorax (chest) portion of the body. It consists of the 12 pairs of ribs with their costal cartilages and the sternum (see Figure 6.3). The ribs are anchored posteriorly to the 12 thoracic vertebrae (T1–T12). The thoracic cage protects the heart and lungs.

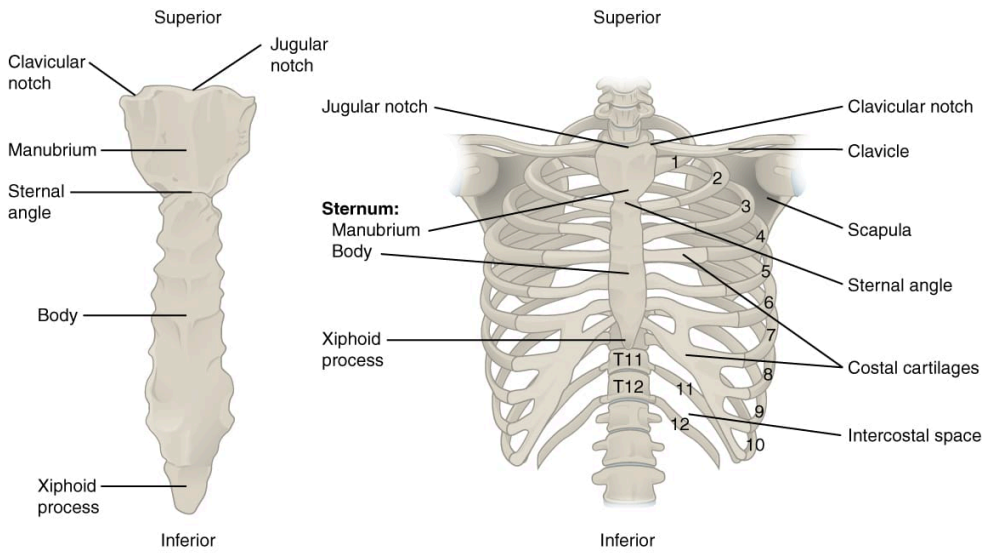

Figure 6.3 Thoracic Cage. The thoracic cage is formed by the (a) sternum and (b) 12 pairs of ribs with their costal cartilages. The ribs are anchored posteriorly to the 12 thoracic vertebrae. The sternum consists of the manubrium, body, and xiphoid process. The ribs are classified as true ribs (1–7) and false ribs (8–12). The last two pairs of false ribs are also known as floating ribs (11–12). From Betts et al., 2013. Licensed under CC BY 4.0. [Image description.]

Ribs

There are 12 sets of **ribs** and can be divided as such:

- 7 **true ribs** – they are attached to the front of the sternum
- 3 **false ribs** – they are attached to the cartilage that joins the sternum
- 2 **floating ribs** – they are not attached to the front of the sternum

Sternum

The **sternum**, also known as the breast bone, is divided into 3 parts:

- **manubrium** – the upper portion of the breast bone
- **body** – the middle portion of the breast bone
- **xiphoid process** – the lower portion of the breast bone and is made up of cartilage

Concept Check

- What is the medical term for the upper jaw bone and the lower jaw bone?
- What medical term is used for the bones of the inner ear?
- How many bones make up the cervical region of the vertebral column?

The Appendicular Skeleton

The **appendicular skeleton** includes all bones of the upper and lower limbs, plus the bones that attach each limb to the axial skeleton. There are 126 bones in the appendicular skeleton of an adult.

Bones of the Pectoral Girdle

- **Scapula** – the shoulder blades

- **Clavicle** – the collarbone, which connects the sternum to the scapula
- **Acromion** – the extension that forms the bony point of the shoulder

Bones of the Upper Limbs

The bones of the upper limbs include the bones of the arms, wrists, and hands.

Bones of the Arm

- **Humerus** – the bone in the upper arm
- **Radius** – the bone that runs thumb-side of the forearm
- **Ulna** – the bone that runs on the side of the little finger of the forearm (Figure 6.4)

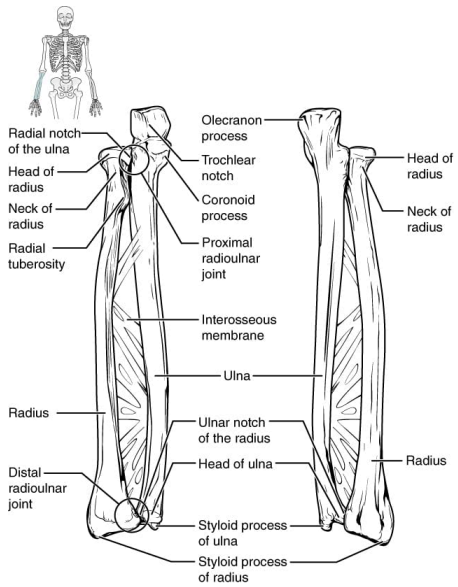

Figure 6.4 Ulna and Radius. The ulna is located on the medial side of the forearm, and the radius is on the lateral side. These bones are attached by an interosseous membrane. From Betts et al., 2013. Licensed under CC BY 4.0. [Image description.]

Bones of the Wrist and Hand

- **Carpals** – the wrist bones
- **Metacarpals** – the bones in the palm
- **Phalanges** – the finger and toe bones

Each phalanx has three bones: the distal, medial, and proximal. The exception is the thumb and big toe which has two bones: the distal and proximal (Figure 6.5). There are 30 bones in each upper limb. Can you count them on your limb?

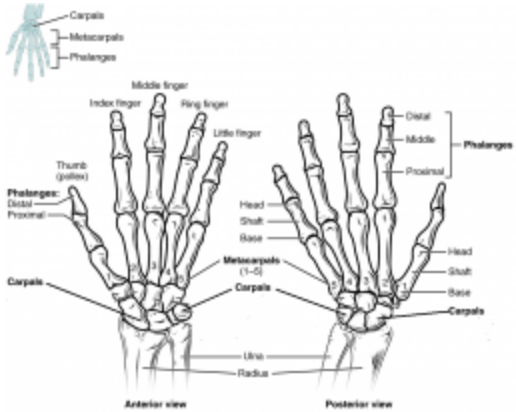

Figure 6.5 Bones of the Hands. The eight carpal bones form the base of the hand. These are arranged into proximal and distal rows of four bones each. The metacarpal bones form the palm. The thumb and fingers consist of the phalanx bones. From Betts et al., 2013. Licensed under CC BY 4.0. [Image description.]

Did you know?

The appendicular skeleton has 126 bones. It is divided into the bones of the upper limbs and lower limbs that attach each limb to the skeleton.

Bones of the Pelvic Region

The bones of the pelvic region protect the reproductive, urinary, and excretory organs.

- **Pelvic girdle** – the hip or coxal bone; it is formed by the fusion of three bones during adolescence
- **Illium** – the largest part of the hip bone
- **Ischium** – the lower portion of pelvic girdle
- **Pubis** – the anterior portion of pelvic girdle
- **Pelvis** – consists of four bones: the left and right hip bones as well as the sacrum and coccyx
- **Acetabulum** – the large socket in the pelvic bones that holds the head of the femur

The shape of the pelvic girdle is different for males than females. In the male, it is a funnel shape. In the female, it is shaped like a basin to accommodate the fetus during pregnancy.

Bones of the Lower Limbs

The bones of the lower limb include bones of the leg and the feet.

Bones of the Leg

- **Femur** – the thigh bone and is also referred to as the upper leg bone; it is the longest and strongest bone in the human body
- **Patella** – the kneecap
- **Tibia** – the shin bone; it is a medial bone and the main weight-bearing bone of the lower leg
- **Fibula** – the smaller of the lower leg bones (see Figure 6.6)

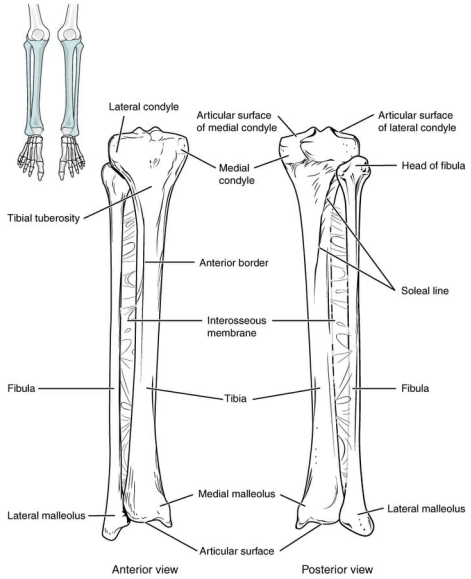

Figure 6.6 Tibia and Fibula. The tibia is the larger, weight-bearing bone located on the medial side of the leg. The fibula is the slender bone of the lateral side of the leg and does not bear weight. From Betts et al., 2013. Licensed under CC BY 4.0. [Image description.]

Bones of the Ankles and Feet

- **Tarsals** – the ankle bones (7 total)
- **Malleolus** – the bony protrusions of the ankle bones
- **Talus** – the superior ankle bones
- **Calcaneus** – the heel bones
- **Metatarsals** – the foot bones
- **Phalanges** – the bones of the toes (see Figure 6.7)

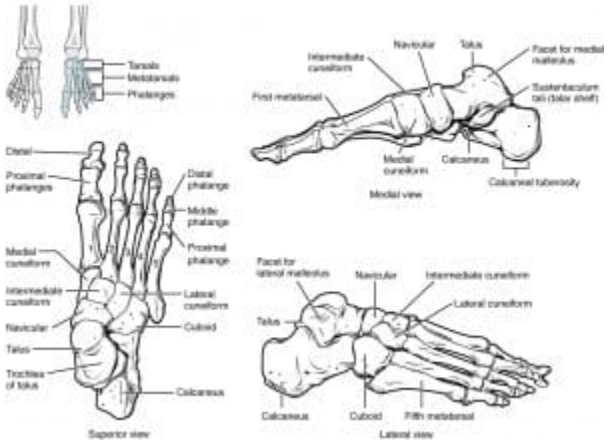

Figure 6.7 Bones of the Foot. The bones of the foot are divided into three groups. The posterior foot is formed by the seven tarsal bones. The mid-foot has five metatarsal bones. The toes contain the phalanges. From Betts et al., 2013. Licensed under CC BY 4.0. [Image description.]

Did you know?

The femur is the longest and strongest bone of the body and accounts for approximately one-quarter of a person's total height.

Concept Check

Answer the following questions:

- Is the humerus the same as the funny bone?
- What is the medical term for the kneecap?

Anatomy Labeling Activity

Query 1.6.3

This interactive element is not available in this format. Visit the link or scan the QR code to access it online.

View this Interactive Content online

Physiology (Function) of the Skeletal System

The bones of the skeletal system are comprised of an inner spongy tissue referred to as bone marrow. There are two types of bone marrow: red and yellow. The red bone marrow produces the red blood cells, and it does so by a process called hematopoiesis. The yellow bone marrow contains adipose tissues which can be a source of energy. The bones of the skeletal system also store minerals such as calcium and phosphate. These minerals are important for the physiological processes in the body and are released into the bloodstream when levels are low in the body.

Joints

Watch this video:

YouTube Video

This interactive element is not available in this format. Visit the link or scan the QR code to access it online.

View this YouTube Video online

Media 6.2. Joints: Crash Course A&P #20 [Online video]. Copyright 2015 by CrashCourse.

Most bones connect to at least one other bone in the body. The area where bones meet bones or where bones meet cartilage are called articulations. Joints can be classified based on their ability to move. At **movable** joints, the articulating surfaces of the adjacent bones can move smoothly against each other. However, other joints may be connected by connective tissue or cartilage. These joints are designed for stability and provide for little or no movement. Importantly, joint stability and movement are related to each other. This means that stable joints allow for little or no mobility between the adjacent bones. Conversely, joints that provide the most movement between bones are the least stable.

Based on the **function of joints**, there are 3 types of joints:

- **Synarthrosis** joints allow no movement.

- For example, joints of the skull
- **Amphiarthrosis** joints allow some movement.
  - For example, joints of the pubic symphysis
- **Diarthrosis** joints allow for free movement.
  - For example, joints of the knee

Structures associated with joints are:

- **Cartilage –** the elastic connective tissue that is found at the ends of bones, nose tip, et cetera
- **Synovial membrane –** the lining or covering of synovial joints
- **Synovial fluid –** the lubricating fluid found between synovial joints
- **Ligaments** – the tough, elastic connective tissue that connects bone to bone
- **Tendons** – the fibrous connective tissue that attaches muscle to bone
- **Bursa** – the closed, fluid-filled sacs that work as a cushion
- **Meniscus** – C-shaped cartilage that acts as shock absorbers between bones

> **Did you know?**
>
> The left and right hip bones are connected by an amphiarthrosis joint.

Body Movements

Synovial joints are movable joints and provide most of the body movements. Body movement occurs when the bones, joints, and muscles work together.

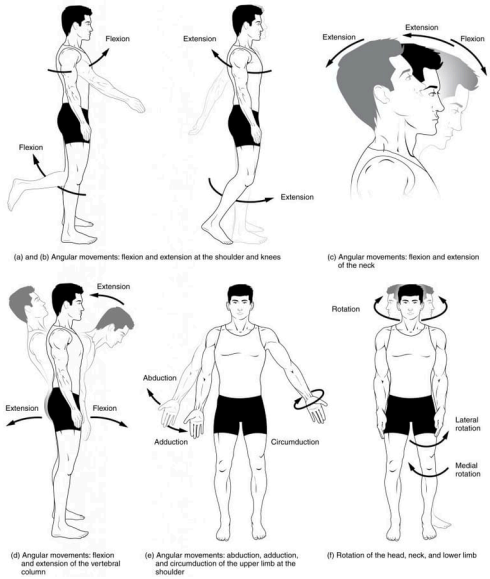

Figure 6.8 Movements of the Body, Part 1. Synovial joints give the body many ways in which to move. (a) and (b) Flexion and extension motions are in the sagittal (anterior and posterior) plane of motion. These movements take place at the shoulder, hip, elbow, knee, wrist, metacarpophalangeal, metatarsophalangeal, and interphalangeal joints. (c) and (d) Anterior bending of the head or vertebral column is flexion, while any posterior-going movement is extension. (e) Abduction and adduction are motions of the limbs, hand, fingers, or toes in the coronal (medial and lateral) plane of movement. Moving the limb or hand laterally away from the body, or spreading the fingers or toes, is abduction. Adduction brings the limb or hand toward or across the midline of the body or brings the fingers or toes together. Circumduction is the movement of the limb, hand, or fingers in a circular pattern, using the sequential combination of flexion, adduction, extension, and abduction motions. Adduction/abduction and circumduction take place at the shoulder, hip, wrist, metacarpophalangeal, and metatarsophalangeal joints. (f) Turning of the head side to side or twisting of the body is rotation. Medial and lateral rotation of the upper limb at the shoulder or lower limb at the hip involves turning the anterior surface of the limb toward the midline of the body (medial or internal rotation) or away from the midline (lateral or external rotation). From Betts et al., 2013. Licensed under CC BY 4.0. [Image description.]

Flexion and Extension

Flexion and **extension** are movements that take place within the sagittal plane and involve anterior or posterior movements of the body or limbs. For the vertebral column, **flexion** (anterior flexion) is an anterior (forward) bending of the neck or body, while **extension** involves a posterior-directed motion, such as straightening from a flexed position or bending backward. **Lateral flexion** is the bending of the neck or body toward the right or left side. These movements of the vertebral column involve both the joints as well as the associated intervertebral disc.

In the limbs, flexion decreases the angle between the bones (bending of the joint), while extension increases the angle and straightens the joint (see Figures 6.8(a-d)). You will discover in the muscular system chapter that the associated muscles to these movements are flexor and extensor.

Abduction and Adduction

Abduction and adduction motions occur within the coronal plane and involve medial-lateral motions of the limbs, fingers, toes, or thumb. For example, abduction is raising the arm at the shoulder joint, moving it laterally away from the body, while adduction brings the arm down to the side of the body (see Figure 6.8(e)). In the muscular system chapter, you will discover that the associated muscles to these movements are the abductor and adductor.

Circumduction

Circumduction is the movement of a body region in a circular manner, in which one end of the body region being moved stays relatively stationary while the other end describes a circle. It involves the sequential combination of flexion, adduction, extension, and abduction at a joint (see Figure 6.8(e)).

Rotation

Rotation can occur within the vertebral column, at a **pivot joint**, or at a **ball-and-socket joint**. Rotation of the neck or body is the twisting movement produced by the summation of the small rotational movements available between adjacent vertebrae. At a pivot joint, one bone rotates in relation to another bone.

Rotation can also occur at the **ball-and-socket joints** of the shoulder and hip. Here, the humerus and femur rotate around their long axis, which moves the anterior surface of the arm or thigh either toward or away from the midline of the body (see Figure 6.8(f)).

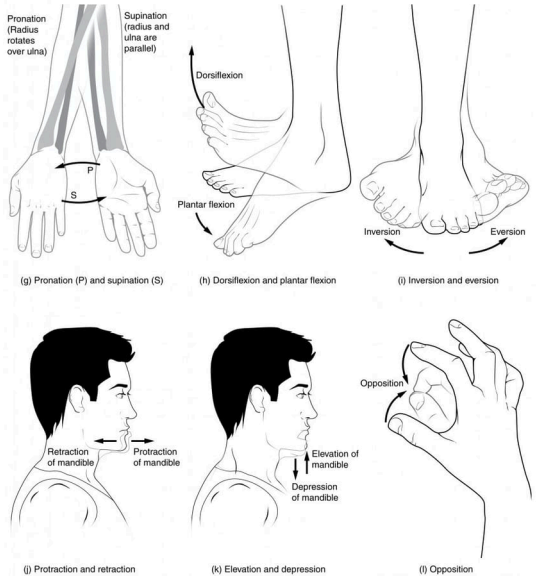

Figure 6.9 Movements of the Body, Part 2. (g) Supination of the forearm turns the hand to the palm forward position in which the radius and ulna are parallel, while forearm pronation turns the hand to the palm backward position in which the radius crosses over the ulna to form an "X." (h) Dorsiflexion of the foot at the ankle joint moves the top of the foot toward the leg, while plantar flexion lifts the heel and points the toes. (i) Eversion of the foot moves the bottom (sole) of the foot away from the midline of the body, while foot inversion faces the sole toward the midline. (j) Protraction of the mandible pushes the chin forward, and retraction pulls the chin back. (k) Depression of the mandible opens the mouth, while elevation closes it. (l) Opposition of the thumb brings the tip of the thumb into contact with the tip of the fingers of the same hand and reposition brings the thumb back next to the index finger. From Betts et al., 2013. Licensed under CC BY 4.0. [Image description.]

Supination and Pronation

Supination and pronation are movements of the forearm. In the anatomical position, the upper limb is held next to the body with the palm facing forward. This is the **supinated position** of the forearm. In this position, the radius and ulna are parallel to each other. When the palm faces backward, the forearm is in the **pronated position**, and the radius and ulna form an X-shape.

Pronation is the movement that allows the palm to face backward while in supination the palm faces forward. It helps to remember that supination is the motion you use when scooping up soup with a spoon (see Figure 6.9(g)).

Dorsiflexion and Plantar Flexion

Dorsiflexion and **plantar flexion** are movements at the ankle joint, which is a hinge joint. Lifting the front of the foot, so that the top of the foot moves (upward) toward the anterior leg is dorsiflexion, while lifting the heel of the foot from the ground or pointing the toes downward is plantar flexion. These are the only movements available at the ankle joint (see Figure 6.9(h)).

Inversion and Eversion

Inversion and eversion are complex movements that involve the multiple plane joints among the tarsal bones of the posterior foot (intertarsal joints) and thus are not motions that take place at the ankle joint. **Inversion** is the turning of the foot to angle the bottom of the foot toward the midline, while **eversion** turns the bottom of the foot away from the midline. The foot has a greater range of inversion than eversion motion. These are important motions that help to stabilize the foot when walking or running on an uneven surface and aid in the quick side-to-side changes in direction used during active sports such as basketball, racquetball, or soccer (see Figure 6.9(i)).

Protraction and Retraction

Protraction and **retraction** are anterior-posterior movements of the scapula or mandible. Protraction of the scapula occurs when the shoulder is moved forward, as when pushing against something or throwing a ball. Retraction is the opposite motion, with the scapula being pulled posteriorly and medially, toward the vertebral column. For the mandible, protraction occurs when the lower

jaw is pushed forward, to stick out the chin, while retraction pulls the lower jaw backward (see Figure 6.9(j)).

Depression and Elevation

Depression and **elevation** are downward and upward movements of the scapula or mandible. The upward movement of the scapula and shoulder is elevation, while a downward movement is depression. These movements are used to shrug your shoulders. Similarly, elevation of the mandible is the upward movement of the lower jaw used to close the mouth or bite on something, and depression is the downward movement that produces the opening of the mouth (see Figure 6.9(k)).

Concept Check

- Discuss the joints involved and movements required for you to cross your arms together in front of your chest.
- Differentiate between **pronation** and **supination**.

Practice Skeletal System Movement Terms

Query 1.6.4

This interactive element is not available in this format. Visit the link or scan the QR code to access it online.

View this Interactive Content online

Medical Terms in Context

Query 1.6.5

This interactive element is not available in this format. Visit the link or scan the QR code to access it online.

View this Interactive Content online

Query 1.6.6

This interactive element is not available in this format. Visit the link or scan the QR code to access it online.

View this Interactive Content online

Diseases and Disorders of the Skeletal System

Osteoporosis

The National Institute of Health's Osteoporosis and Related Bone Diseases National Resource Center describes osteoporosis as bone loss that causes bones to become weak and thin over time. This weakness can lead to fractures from simple movements and occur often in the wrist, shoulder, spine, and hip (National Institute of Arthritis and Musculoskeletal and Skin Diseases, n.d.-b). To learn more, please visit the National Institute of Health's web page on osteoporosis.

Arthritis

Arthritis often presents as edema, arthralgia, and ankylosis (National Institute of Arthritis and Musculoskeletal and Skin Diseases, n.d.-a). Common types of arthritis are osteoarthritis (OA), rheumatoid arthritis (RA), Gout and lupus. To learn more about arthritis visit this web page from the National Institute of Arthritis and Musculoskeletal and Skin Diseases.

Osteoarthritis

Osteoarthritis is the most common form of arthritis and according to the Centers for Disease Control and Prevention (CDC), affects over 32.5 million adults in the United States. The breakdown of cartilage and bone occurs over time when joints are exposed to heavy workloads either through occupation, obesity, and/or prior injury to a joint. Common signs and symptoms are pain, stiffness, and aching that worsens over time. While there is no cure, symptoms can be managed through exercise, medications, and in severe cases, joint replacements (Centers for Disease Control and Prevention, n.d.-a).

Rheumatoid Arthritis

The CDC describes rheumatoid arthritis (RA) as an autoimmune and inflammatory disease. Autoimmune diseases are disorders in which the immune system overreacts and begins to attack itself. In the case of RA, inflammation of the joint tissues of the hands, wrists, and knees is painful and debilitating. Treatments may include immunosuppressive drugs and anti-inflammatory drugs (Betts et al., 2013). RA can also affect other tissues throughout the body and cause problems in organs such as the lungs, heart, and eyes. RA can affect children; in this case, it is referred to as **juvenile rheumatoid arthritis** (Centers for Disease Control and Prevention, n.d.-b).

Gout

Gout is an inflammatory arthritis caused by the buildup of uric acid crystals in a joint. Gout has periods of flares and remission and is commonly treated through lifestyle changes and medication. While any joint can be affected, it is common in the lower extremities and most often in the big toe (Centers for Disease Control and Prevention, n.d.-c). To learn more about the causes and treatments please visit the Arthritis Foundation's web page about gout.

Myasthenia Gravis

The National Institute of Neurological Disorders and Strokes describes myasthenia gravis as a "chronic autoimmune neuromuscular disease that causes weakness in the skeletal muscles" (Office of Communications and Public Liaison, 2020). To learn more, read the National Institute of Neurological Disorders and Stroke's myasthenia gravis fact sheet.

Fibromyalgia

Fibromyalgia is a challenging disease to diagnose since symptoms manifest differently and are similar to other diseases. Signs and symptoms may include widespread pain, chronic fatigue, gastrointestinal problems, and headaches. It is not known what causes fibromyalgia. A doctor may need to order tests to rule out other conditions before making a diagnosis of fibromyalgia (National Institute of Arthritis and Musculoskeletal and Skin Diseases, n.d.-c). To learn more about the diagnosis and treatment for fibromyalgia, please read this handout from the National Institute of Arthritis and Musculoskeletal and Skin Diseases (pdf).

Osteomyelitis

Osteomyelitis is a bone infection caused when staphylococcus bacteria travel through the bloodstream from an infection in one part of the body to the bone. Staphylococcus bacteria are found on the skin, and they can transfer to the bone through a wound and/or surgical contamination. The risk increases as people age or if their immune system is compromised (Momodu & Savaliya, 2021). To learn more, visit the Mayo Clinic's web page on osteomyelitis.

Disorders of the Curvature of the Spine

Developmental anomalies, pathological changes, or obesity can enhance the normal vertebral column curves, resulting in the development of abnormal or excessive curvatures (see Figure 6.10). Disorders associated with the curvature of the spine include:

- **Kyphosis:** Also referred to as humpback, it is an excessive posterior curvature of the thoracic region. This can develop when osteoporosis causes weakening and erosion of the anterior portions of the upper thoracic vertebrae, resulting in their gradual collapse (see Figure 6.11).
- **Lordosis:** Also referred to as swayback, it is an excessive anterior curvature of the lumbar region and is most commonly associated with obesity or late pregnancy. The accumulation of body weight in the abdominal region results in an anterior shift in the line of gravity that carries the weight of the body. This causes an anterior tilt of the pelvis and a pronounced enhancement of the lumbar curve.
- **Scoliosis:** An abnormal, lateral curvature, accompanied by twisting of the vertebral column. Scoliosis is the most common vertebral abnormality among girls. The cause is usually unknown, but it may result from weakness of the back muscles, defects such as differential growth rates in the right and left sides of the vertebral column, or differences in the length of the lower limbs. When present, scoliosis tends to get worse during adolescent growth spurts. Although most individuals do not require treatment, a back brace may be recommended for growing children. In extreme cases, surgery may be required.

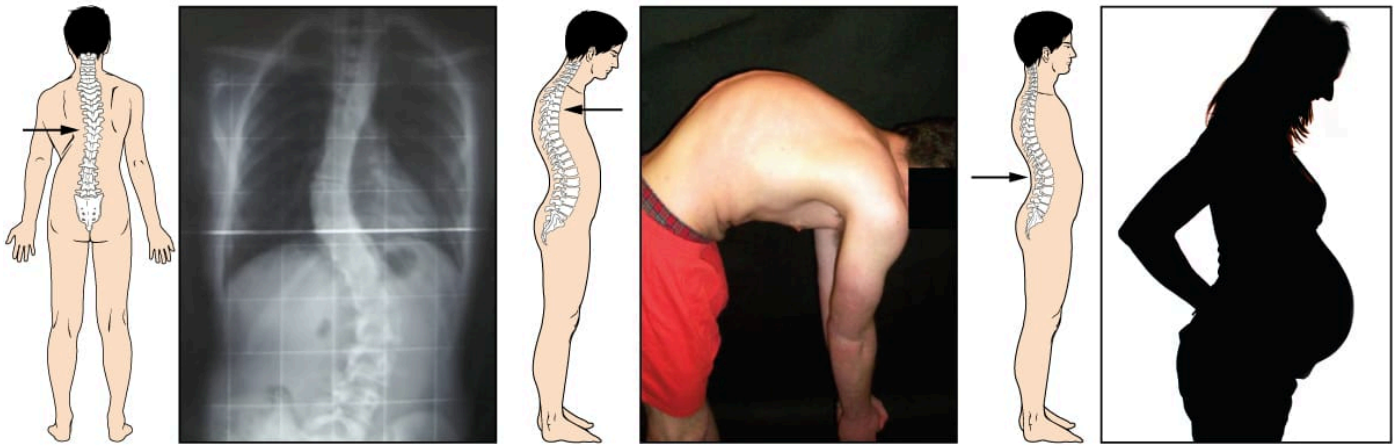

(a) Scoliosis (b) Kyphosis (c) Lordosis

Figure 6.10 Abnormal Curvatures of the Vertebral Column. (a) Scoliosis is an abnormal lateral bending of the vertebral column. (b) An excessive curvature of the upper thoracic vertebral column is called kyphosis. (c) Lordosis is an excessive curvature in the lumbar region of the vertebral column. From Betts et al., 2013. Licensed under CC BY 4.0. [Image description.]

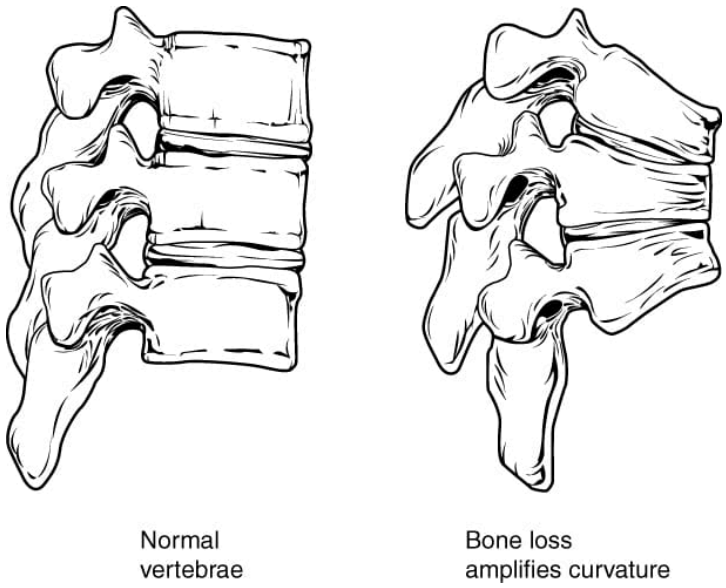

Figure 6.11. Osteoporosis. Osteoporosis is an age-related disorder that causes the gradual loss of bone density and strength. When the thoracic vertebrae are affected, there can be a gradual collapse of the vertebrae. This results in kyphosis, an excessive curvature of the thoracic region. From Betts et al., 2013. Licensed under CC BY 4.0. [Image description.]

Fractures

A **fracture** is a broken bone. It will heal whether or not a physician resets it in its anatomical position. If the bone is not reset correctly, the healing process will keep the bone in its deformed position. **Crepitation or crepitus** is the creaking or popping sound that is heard when fractured bones move against each other. Fractures are classified by their complexity, location, and other features (see Figure 6.12). Some fractures may be described using more than one term because they may have the features of more than one type (e.g., an open transverse fracture).

Types of fractures include:

- **Closed or simple** – bones are broken but do not protrude the skin
- **Open or compound** – bones are broken and pierce through the skin
- **Transverse** – bone is broken straight across
- **Spiral** – the bone has twisted apart
- **Comminuted –** bones are broken and crushed into pieces
- **Greenstick –** bones are partially broken; occurs mainly in children
- **Oblique** – bones are broken at an angle
- **Coles** – bones are broken at the wrist or distal radius
- **Stress** – a small crack in the bone

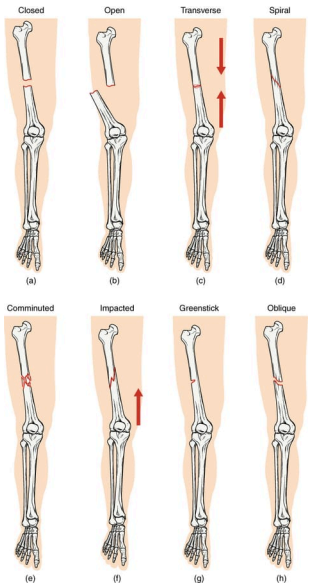

Figure 6.12. Types of Fractures. Compare healthy bone with different types of fractures: (a) closed fracture, (b) open fracture, (c) transverse fracture, (d) spiral fracture, (e) comminuted fracture, (f) impacted fracture, (g) greenstick fracture, and (h) oblique fracture. From Betts et al., 2013. Licensed under CC BY 4.0. [Image description.]

Bone Cancer

There are three types of primary bone cancers: osteosarcoma, Ewing Sarcomas, and chondrosarcoma. These are considered primary cancers because they originate in the bones. Osteosarcoma and Ewing Sarcomas primarily affect children, teenagers, and young adults. Chondrosarcoma primarily affects older adults (National Cancer Institute, n.d.-a). To learn more, visit the American Cancer Society's web page on bone cancer.

Medical Specialties and Procedures Related to the Skeletal System

Orthopedic Surgeon

Orthopedic surgeons are medical doctors who have specialized training in the prevention, diagnosis, treatment, and surgery of disorders and diseases related to the musculoskeletal systems (Bureau of Labor Statistics, 2021a). For more details, please visit the American College of Surgeons' page on Orthopedic Surgery.

Rheumatologist

Rheumatologists are medical doctors who specialize in the diagnosis and treatment of disorders of the joints, muscles, and bones. They diagnose and treat diseases such as arthritis, musculoskeletal disorders, osteoporosis, plus autoimmune diseases like ankylosing spondylitis, a chronic spinal inflammatory disease, and rheumatoid arthritis (Fowler et al., 2013). For more details, please follow the link to the American College of Rheumatology's page on rheumatology.

Doctor of Chiropractic (DC)/Chiropractor

Chiropractors are required to have a Doctor of Chiropractic (D.C.) degree, which is a 4-year postgraduate professional degree, and a state license. Chiropractors focus on spinal adjustments, nutrition, and preventing injury without the use of pharmaceuticals or surgical procedures (Bureau of Labor Statistics, 2021b). To learn more, visit the Bureau of Labor Statistics' website.

Physical Therapist

A physical therapist is a licensed professional who develops individualized treatment plans for their clients. These plans can include exercises, hands-on therapy, and equipment, such as canes or wheelchairs. Although current licensure laws require that those entering the field have a doctor of physical therapy degree, physical therapists who began working before those requirements went into effect may have a bachelor's or master's degree (Bureau of Labor Statistics, 2021c). To learn more, please visit the American Physical Therapy Association website.

Diagnostic Procedures

Common diagnostic procedures related specifically to the skeletal system include x-rays, bone mineral density testing, and arthroscopy.

- **X-rays** are common diagnostic tests used to confirm or rule out fractures and broken bones. The radiation dose is low so it is considered a safe diagnostic test (MedlinePlus, 2021).
- **Dual x-ray absorptiometry (BMD)**, also called a **bone mineral density** test, is a test to determine osteoporosis by measuring the amount of bone mineral in a particular amount of bone (National Cancer Institute, n.d.-b).
- **Arthroscopy** is a procedure that involves a small incision and the insertion into the joint of an arthroscope, a pencil-thin instrument that allows for visualization of the joint interior. Small surgical instruments are also inserted via additional incisions. These tools allow a surgeon to remove or repair a torn meniscus or to reconstruct a ruptured cruciate ligament.

Practice Terms Related to the Skeletal System

Query 1.6.7

This interactive element is not available in this format. Visit the link or scan the QR code to access it online.

View this Interactive Content online

Skeletal System Vocabulary

Abduction: Moving the limb or hand laterally away from the body, or spreading the fingers or toes.

Adduction: Movement that brings the limb or hand toward or across the midline of the body, or brings the fingers or toes together.

Amphiarthrosis: A slightly mobile joint.

Ankylosis: Fixation and immobility of a joint.

Appendicular skeleton: All bones of the upper and lower limbs, plus the girdle bones that attach each limb to the axial skeleton.

Arthralgia: Joint pain.

Arthritis: Chronic inflammation of the synovial joints.

Arthrocentesis: Surgical puncture to aspirate fluid from a joint.

Arthrodesis: Surgical fixation of a joint.

Arthrography: Process of recording a joint.

Arthroplasty: Joint replacement surgery.

Arthroscopy: Process of viewing a joint using an endoscope.

Articulations : Where two bone surfaces meet.

Autoimmune diseases/disorders: Disorders in which the immune system overreacts and begins to attack itself.

Axial skeleton: The central, vertical axis of the body, including the skull, vertebral column, and thoracic cage.

Bradykinesia: Condition of slow movement.

Bursitis: Inflammation of a bursa near a joint.

Chondromalacia: Degeneration of cartilage.

Chronic: A condition that lasts a long time with periods of remission and exacerbation.

Craniotomy: An operation in which a piece of the skull is removed.

Diarthrosis: Freely mobile joints.

Diskectomy: Excision of the intervertebral disk.

Discitis: Inflammation of the intervertebral disk.

Dyskinesia: Abnormal involuntary movements of the extremities, trunk, or jaw.

Edema: Swelling due to excessive liquid in the tissues.

Eversion: Foot movement in which the bottom of the foot is turned laterally, away from the midline.

Extension: Movement in the sagittal plane that increases the angle of a joint (straightens the joint).

Flexion: Movement in the sagittal plane that decreases the angle of a joint (bends the joint).

Hematopoiesis: The production of blood cells.

Hyperkinesia: Excessive movement of muscles of the body as a whole.

Hypertrophy: The enlargement of muscles.

Inversion: Foot movement in which the bottom of the foot is turned toward the midline.

Kyphosis: An excessive posterior curvature of the thoracic region; also called humpback.

Lordosis: Excessive anterior curvature of the lumbar vertebral column region; also called swayback.

Lumbar: Pertaining to the lumbar region of the spine (L1 to L5).

Lumbosacral: Pertaining to the region of the back that includes the lumbar vertebrae, sacrum, and nearby structures.

Muscular dystrophy: A general term for the group of inherited myopathies that are characterized by wasting and weakness of the skeletal muscle.

Osteitis: Inflammation of bone.

Osteoarthritis: The most common type of arthritis; associated with aging and “wear and tear” of the articular cartilage.

Osteoblast: The cell responsible for forming new bone.

Osteochondritis: Inflammation of bone and cartilage.

Osteocyte: Bone cell.

Osteomalacia: A softening of adult bones due to Vitamin D deficiency.

Osteomyelitis: Inflammation of bone and bone marrow.

Osteonecrosis: Abnormal condition of bone death (lack of blood supply).

Osteopenia: Abnormally low bone mass or bone mineral density.

Osteopetrosis: Abnormal condition of porous bones.

Osteoporosis: A disease characterized by a decrease in bone mass that occurs when the rate of bone resorption exceeds the rate of bone formation.

Osteosarcoma: Malignant tumor of bone.

Pelvic: Pertaining to the pelvis.

Pronation: Forearm motion that moves the palm of the hand from the palm forward to the palm backward position.

Rotation: Movement of a bone around a central axis or around its long axis.

Sarcopenia: Age-related muscle atrophy.

Scoliosis: Lateral curvature of the spine.

Spondyloarthritis: Inflammation of the joints of the spine.

Spondylosis: A degenerative spinal disease that can involve any part of the vertebra, intervertebral disk, and surrounding soft tissue.

Supination: Forearm motion that moves the palm of the hand from the palm backward to the palm forward position.

Synarthrosis: An immobile or nearly immobile joint.

Synovectomy: Excision of the synovial membrane.

Synovial sarcoma: Malignant tumor of the synovial membrane.

Tendinitis: Inflammation of the tendon.

Tenosynovitis: Inflammation of the synovial membrane of a tendon.

Vertebroplasty: A procedure used to repair a bone in the spine that has a break caused by cancer, osteoporosis, or trauma.

Test Yourself

Query 1.6.8

This interactive element is not available in this format. Visit the link or scan the QR code to access it online.

View this Interactive Content online

References

Bureau of Labor Statistics. (2021a). Physicians and surgeons. In *Occupational outlook handbook*. U.S. Department of Labor. https://www.bls.gov/ooh/healthcare/physicians-and-surgeons.htm

Bureau of Labor Statistics. (2021b). Chiropractors. In *Occupational outlook handbook*. U.S. Department of Labor. https://www.bls.gov/ooh/healthcare/chiropractors.htm

Bureau of Labor Statistics. (2021c). Physical therapists. In *Occupational outlook handbook*. U.S. Department of Labor. https://www.bls.gov/ooh/healthcare/physical-therapists.htm

Centers for Disease Control and Prevention. (n.d.-a). *Osteoarthritis*. https://www.cdc.gov/arthritis/basics/osteoarthritis.htm

Centers for Disease Control and Prevention. (n.d.-b). *Rheumatoid arthritis*. CDC Arthritis Program. https://www.cdc.gov/arthritis/basics/rheumatoid-arthritis.html

Centers for Disease Control and Prevention. (n.d.-c). *Gout*. https://www.cdc.gov/arthritis/basics/gout.html

Fowler, S., Roush, R., & Wise, J. (2013). *Concepts of biology*. OpenStax. Access for free at https://openstax.org/books/concepts-biology/pages/1-introduction

MedlinePlus. (2021). *X-rays*. U.S. National Library of Medicine. https://medlineplus.gov/xrays.html

Momodu, I. I., & Savaliya, V. (2021). Osteomyelitis. In *StatPearls [Internet]*. https://www.ncbi.nlm.nih.gov/books/NBK532250/

National Cancer Institute. (n.d.-a). *Primary bone cancer* [Fact sheet]. National Institutes of Health, U.S. Department of Health and Human Services. https://www.cancer.gov/types/bone/bone-fact-sheet

National Cancer Institute. (n.d.-b). *Dual x-ray absorptiometry*. National Institutes of Health, U.S. Department of Health and Human Services. https://www.cancer.gov/publications/dictionaries/cancer-terms/def/dual-x-ray-absorptiometry

National Institute of Arthritis and Musculoskeletal and Skin Diseases. (n.d.-a). *Arthritis*. National Institutes of Health, U.S. Department of Health and Human Services. https://www.niams.nih.gov/health-topics/arthritis

National Institute of Arthritis and Musculoskeletal and Skin Diseases. (n.d.-b). *Osteoporosis overview*. National Institutes of Health, U.S. Department of Health and Human Services. https://www.bones.nih.gov/health-info/bone/osteoporosis/overview

National Institutes of Arthritis and Musculoskeletal and Skin Diseases. (n.d-c). *Health topics: Fibromyalgia* [PDF]. National Institutes of Health, U.S. Department of Health and Human Services. https://www.niams.nih.gov/print/view/pdf/advanced_reading_pdf_/advanced?view_args%5B0%5D=1957

Office of Communications and Public Liaison. (2020). *Myasthenia gravis fact sheet*. National Institute of Neurological Disorders and Stroke, U.S. Department of Health and Human Services. https://www.ninds.nih.gov/Disorders/Patient-Caregiver-Education/Fact-Sheets/Myasthenia-Gravis-Fact-Sheet

Image Descriptions

Figure 6.1 image description: This diagram shows the human skeleton and identifies the major bones. The left panel shows the anterior view (from the front) and the right panel shows the posterior view (from the back). Labels read (from the top of the skull): skull (cranial portion, facial portion), pectoral shoulder girdle, clavicle, scapula, thoracic cage (sternum, ribs), upper limb (humerus, ulna, radius, carpals, metacarpals, phalanges), vertebral column, pelvic girdle (hip bones), lower limb (femur, patella, tibia, fibula, tarsals, metatarsals, phalanges). [Return to Figure 6.1].

Figure 6.2 image description: This image shows the structure of the vertebral column. The left panel shows the front view of the vertebral column. Labels and the right panel show the side view of the vertebral column. labels read (from top): 7 cervical vertebrae (C1-C7) form cervical curve, 12 thoracic vertebrae (T1-T12) form the thoracic curve, intervertebral disc, 5 lumbar vertebrae (L1-L5) form lumbar curve, Fused vertebrae of sacrum and coccyx form a sacrococcygeal curve, sacrum, coccyx. [Return to Figure 6.2].

Figure 6.3 image description: This figure shows the skeletal structure of the rib cage. The left panel shows the anterior view of the sternum. Labels read (from top): clavicular notch, jugular notch, manubrium, sternal angle, body, xiphoid process. The right panel shows the anterior panel of the sternum including the entire rib cage. Labels read (from top): jugular notch, clavicular notch, clavicle, sternum (manubrium, body, xiphoid process), scapula, sternal angle, costal cartilages, intercostal space. Ribs are numbered 1-12 from the top. [Return to Figure 6.3].

Figure 6.4 image description: This diagram labels the bones of the lower arm (excluding the hands). Labels read (from top): olecranon process, head of radius, radial notch of the ulna, trochlear notch, coronoid process, radial tuberosity, proximal radioulnar joint, neck of radius, radius, interosseous membrane, ulna, ulnar notch of the radius, head of the ulna, distal radioulnar joint, styloid process of ulna, styloid process of radius. [Return to Figure 6.4].

Figure 6.5 image description: This diagram shows an anterior and posterior view of the hands with corresponding labels. Anterior view labels read (from top): middle finger, ring finger, index finger, little finger, thumb, phalanges (distal, proximal), metacarpals, carpals, ulna, radius. Posterior view labels read (from top): Phalanges (distal, middle, proximal), head shaft and base of the proximal phalanx, head shaft and base of the metatarsal, metatarsals 1-5, carpals, ulna, radius. [Return to Figure 6.5].

Figure 6.6 image description: This image shows the structure of the tibia and the fibula. The left panel shows the anterior view. Labels read (from top): lateral condyle, medial condyle, tibial tuberosity, anterior border, interosseous membrane, fibula, tibia, medial malleolus, lateral malleolus, articular surface. The right panel shows the posterior view. Labels read (from top): the articular surface of medial and lateral condyles, medial condyle, head of the fibula, soleal line, interosseous membrane, tibia, fibula, medial malleolus, lateral malleolus, articular surface. [Return to Figure 6.6].

Figure 6.7 image description: This figure shows the bones of the foot. The left panel shows the superior view. Labels read (from toes): distal, proximal phalanges, distal phalange, middle phalange, proximal phalanx, medial cuneiform, intermediate and lateral cuneiforms, navicular, cuboid, talus, trochlea of talus, calcaneus. The top right panel shows the medial view. Labels read (from left to right starting at toe): first metatarsal, medial cuneiform, intermediate cuneiform, navicular, talus, calcaneus, facet for medial malleolus, sustentaculum tali (talar shelf), calcaneal tuberosity. The bottom right panel shows the lateral view. Labels read (from left at the heel, to right): calcaneus, talus, facet for lateral malleolus, cuboid, navicular, intermediate and lateral cuneiforms, fifth metatarsal. [Return to Figure 6.7].

Figure 6.8 image description: This multi-part image shows different types of movements that are possible by different joints in the body. Labels read (from the top, left): a and b angular movements: flexion and extension at the shoulders and knees, c) angular movements: flexion and extension of the neck (arrows pointing left and right to indicate movement). Labels (from the bottom, left) read d) angular movements: flexion and extension of the vertical column, e) angular movements abduction, adduction, and circumduction of the upper limb at the shoulder, f) rotation of the head, neck, and lower limb. [Return to Figure 6.8].

Figure 6.9 image description: This multi-part image shows different types of movements that are possible by different joints in the body. The top left image shows a hand and forearm in the pronation and supination positions. The top middle image shows a foot in the dorsiflexion and plantar flexion positions. The top right image shows a foot in the inversion and eversion positions. The bottom left image shows the retraction and protraction of a man's mandible. The bottom middle image shows the elevation and depression of a man's mandible. The bottom right image shows a hand in the opposition position. [Return to Figure 6.9].

Figure 6.10 image description: This image shows the changes to the abnormal curves of the vertebral columns in different diseases. The left panel shows the change in the curve of the vertebral column in scoliosis, the middle panel shows the change in the curve of the vertebral column in kyphosis, and the right panel shows the change in the curve of the vertebral column in lordosis. [Return to Figure 6.10].

Figure 6.11 image description: This figure shows the changes to the spine in osteoporosis. The left panel shows the structure of normal vertebrae and the right panel shows the curved vertebrae in osteoporosis. [Return to Figure 6.11].

Figure 6.12 image description: In this illustration, each type of fracture is shown on the right femur from an anterior view. In the closed fracture, the femur is broken in the middle of the shaft with the upper and lower halves of the bone completely separated. However, the two halves of the bones are still aligned in that the broken edges are still facing each other. In an open fracture, the femur is broken in the middle of the shaft with the upper and lower halves of the bone completely separated. Unlike the closed fracture, in the open fracture, the two bone halves are misaligned. The lower half is turned laterally and it has protruded through the skin of the thigh. The broken ends no longer line up with each other. In a transverse fracture, the bone has a crack entirely through its width, however, the broken ends are not separated. The crack is perpendicular to the long axis of the bone. Arrows indicate that this is usually caused by compression of the bone in a superior-inferior direction. A spiral fracture travels diagonally through the diameter of the bone. In a comminuted fracture, the bone has several connecting cracks at its middle. The bone could

splinter into several small pieces at the site of the comminuted fracture. In an impacted fracture, the crack zig zags throughout the width of the bone like a lightning bolt. An arrow indicates that these are usually caused by an impact that pushes the femur up into the body. A greenstick fracture is a small crack that does not extend through the entire width of the bone. The oblique fracture shown here is traveling diagonally through the shaft of the femur at about a thirty degree angle. [Return to Figure 6.12].

Unless otherwise indicated, this chapter contains material adapted from *Anatomy and Physiology* (on OpenStax), by Betts et al. and is used under a CC BY 4.0 international license. Download and access this book for free at https://openstax.org/books/anatomy-and-physiology/pages/1-introduction.

This page titled 1.6: Skeletal System is shared under a CC BY 4.0 license and was authored, remixed, and/or curated by Andrea Nelson and Katherine Greene via source content that was edited to the style and standards of the LibreTexts platform.

1.7: Muscular System

Learning Objectives

- Examine the anatomy of the muscular system
- Determine the main functions of the muscular system
- Differentiate the medical terms of the muscular system and common abbreviations
- Discover common diseases, disorders, and procedures related to the muscular system
- Recognize the medical specialties associated with the muscular system

Muscular System Word Parts

Click on prefixes, combining forms, and suffixes to reveal a list of word parts to memorize for the Muscular System.

Query 1.7.1

This interactive element is not available in this format. Visit the link or scan the QR code to access it online.

View this Interactive Content online

Introduction to the Muscular System

When most people think of muscles, they think of the muscles that are visible just under the skin, particularly of the limbs. These are skeletal muscles, so-named because most of them move the skeleton, but there are two additional types of muscles: the smooth muscle and the cardiac muscle. The body has over 600 muscles which contribute significantly to the body's weight.

Watch this video:

YouTube Video

This interactive element is not available in this format. Visit the link or scan the QR code to access it online.

View this YouTube Video online

Media 7.1 Muscles, Part 2 – Organismal Level: Crash Course A&P #22 [Online video]. Copyright 2015 by CrashCourse.

Medical Terms Related to the Muscular System

Query 1.7.2

This interactive element is not available in this format. Visit the link or scan the QR code to access it online.

View this Interactive Content online

Anatomy (Structures) of the Muscular System

Muscle is one of the four primary tissue types of the body, and it is made up of specialized cells called fibers. The body contains three types of muscle tissue: skeletal muscle, cardiac muscle, and smooth muscle (see Figure 7.1). All three muscle tissues have some properties in common; they all exhibit a quality called **excitability** as their plasma membranes can change their electrical states (from polarized to depolarized) and send an electrical wave called an action potential along the entire length of the membrane. **Fascia** is fibrous connective tissue that encloses muscles.

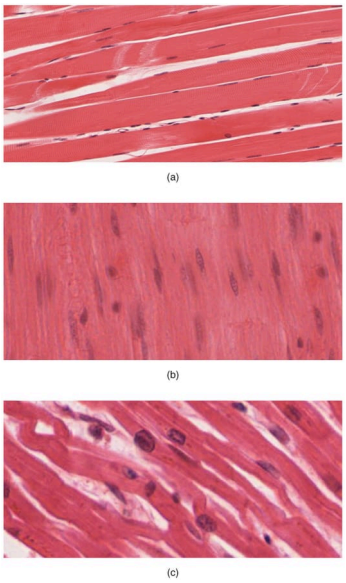

Figure 7.1 The Three Types of Muscle Tissue. The body contains three types of muscle tissue: (a) skeletal muscle, (b) smooth muscle, and (c) cardiac muscle. (Micrographs provided by the Regents of University of Michigan Medical School © 2012). From Betts et al., 2013. Licensed under CC BY 4.0. [Image description.]

Three Types of Muscle Tissues

- **Skeletal** – closely associated with the skeletal system. Also known as striated muscles, they are responsible for voluntary muscle movement, such as swallowing, et cetera.
- **Smooth** – mainly associated with the walls of the internal organs. Also known as visceral muscles, they are responsible for involuntary muscle movement, such as breathing, et cetera.
- **Cardiac** – heart muscle or myocardium. Its appearance is similar to a skeletal muscle and is responsible for the pumping of blood. It gives the heart beat.

Skeletal Muscle

Skeletal muscles act not only to produce movement but also to stop movement, such as resisting gravity to maintain posture. Small, constant adjustments of the skeletal muscles are needed to hold a body upright or balanced in any position. Muscles also prevent excess movement of the bones and joints, maintaining skeletal stability and preventing skeletal structure damage or deformation.

Skeletal muscles are located throughout the body at the openings of internal tracts to control the movement of various substances. These muscles allow functions, such as swallowing, urination, and defecation, to be under voluntary control. Skeletal muscles also protect internal organs (particularly abdominal and pelvic organs) by acting as an external barrier or shield to external trauma and by supporting the weight of the organs.

Skeletal muscles contribute to the maintenance of homeostasis in the body by generating heat. This heat is very noticeable during exercise, when sustained muscle movement causes body temperature to rise, and in cases of extreme cold when shivering produces random skeletal muscle contractions to generate heat.

Did you know?

The gluteus maximus is the largest muscle and the heart is the hardest working muscle.

Smooth Muscle

Smooth muscle, so named because the cells do not have striations, is present in the walls of hollow organs like the urinary bladder, uterus, stomach, intestines, and in the walls of passageways, such as the arteries and veins of the circulatory system, and the tracts of the respiratory, urinary, and reproductive systems. Smooth muscle is also present in the eyes, where it functions to change the size of the iris and alter the shape of the lens; and in the skin where it causes hair to stand erect in response to cold temperature or fear.

Cardiac Muscle

Cardiac muscle tissue is only found in the heart. Highly coordinated contractions of cardiac muscle pump blood into the vessels of the circulatory system. Similar to skeletal muscle, cardiac muscle is striated and organized into **sarcomeres**, possessing the same banding organization as skeletal muscle (see Figure 7.1). Cardiac muscle fibers cells also are extensively branched and are connected to one another at their ends by intercalated discs. An **intercalated disc** allows the cardiac muscle cells to contract in a wave-like pattern so that the heart can work as a pump.

Concept Check

- Compare and contrast the three types of muscle tissues.
- Where in the body do you find each of the muscle types?

Physiology (Function) of the Muscular System

The main function of the muscular system is to assist with **movement**. Muscles work as antagonistic pairs. As one muscle contracts, the other muscle relaxes. This contraction pulls on the bones and assists with movement. Contraction is the shortening of the muscle fibers while relaxation lengthens the fibers. This sequence of relaxation and contraction is influenced by the nervous system.

Muscles also work to keep the **posture** of the body. This is done through muscle contraction where the trunk is kept straight either when sitting or standing.

Did you know?

If all the muscles in the jaw worked together, it could close the teeth with a force as great as 200 pounds on the molars (Science Reference Section, 2019).

Naming of Muscles

There are many nomenclatures for naming muscles. Some of these include:

- **divisions** – biceps, triceps, quadriceps
- **size** – maximus (largest), minimus (smallest)
- **shape** – deltoid (triangular), trapezius (trapezoid)
- **action** – flexor (to flex), adductor (towards midline of the body)

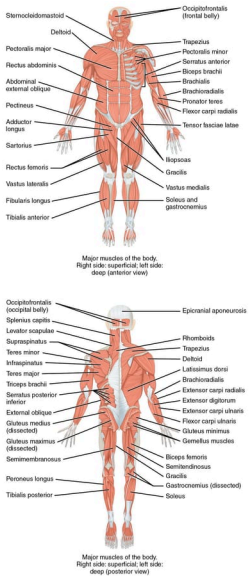

Figure 7.2. Overview of the Muscular System. On the anterior and posterior views of the muscular system above, superficial muscles (those at the surface) are shown on the right side of the body while deep muscles (those underneath the superficial muscles) are shown on the left half of the body. For the legs, superficial muscles are shown in the anterior view while the posterior view shows both superficial and deep muscles. From Betts et al., 2013. Licensed under CC BY 4.0. [Image description.]

Table 7.1. Understanding a Muscle Name from the Latin. Adapted from Betts et al., 2013. Licensed under CC BY 4.0.

EXAMPLE	WORD	LATIN ROOT 1	LATIN ROOT 2	MEANING	TRANSLATION
abductor digiti minimi	abductor	ab = away from	duct = to move	a muscle that moves away from	A muscle that moves the little finger or toe away
	digiti	digitus = digit	n/a	refers to a finger or toe	
	minimi	minimus = mini, tiny	n/a	little	
adductor digiti minimi	adductor	ad = to, toward	duct = to move	a muscle that moves towards	A muscle that moves the little finger or toe toward
	digiti	digitus = digit	n/a	refers to a finger or toe	

EXAMPLE	WORD	LATIN ROOT 1	LATIN ROOT 2	MEANING	TRANSLATION
	minimi	minimus = mini, tiny	n/a	little	

Common Abbreviations for the Muscular System

Many terms and phrases related to the muscle system are abbreviated. Learn these common abbreviations by expanding the list below.

Query 1.7.3

This interactive element is not available in this format. Visit the link or scan the QR code to access it online.

View this Interactive Content online

Diseases and Disorders of the Muscle System

Duchenne Muscular Dystrophy

Duchenne Muscular Dystrophy (DMD) is caused by the inability of the body to make dystrophin (a muscle protein). This causes the muscles to become weak as the person ages. This disease primarily affects boys. Signs and symptoms typically present before the age of six and may include a delay of motor milestones and progressive weakness in the lower extremities and pelvis. Since all muscles are affected, the person will eventually require a wheelchair and assistance with breathing (National Human Genome Research Institute, 2013). To learn more, please visit the Genetic and Rare Diseases Information Center's web page on Duchenne Muscular Dystrophy.

Cerebral Palsy

Cerebral palsy (CP) is caused by an interruption to the normal development of a person's brain leading to weakness with muscles. Depending on the area of the brain that is affected, signs and symptoms will vary in the type and severity between individuals. Balance and coordination are often challenging due to the inability to control muscles (Centers for Disease Control and Prevention, n.d.). To learn more, please visit the Centers for Disease Control and Prevention's web page on cerebral palsy.

Carpal Tunnel Syndrome

Carpal tunnel syndrome may present with pain, numbness, or weakness to the hand(s) caused by pressure on the median nerve. Some causes for this pressure are repetitive movements, trauma or injury to the wrist, or fluid retention related to pregnancy or menopause (National Institute of Neurological Disorders and Stroke, 2020). To learn more, visit the National Institute of Neurological Disorders and Stroke web page on carpal tunnel.

Paralysis

Paralysis is the loss of strength and control of the muscles in parts of the body. Paralysis can be localized where it affects specific areas such as the face, feet, vocal cords, et cetera, or it can be generalized where it affects a larger area of the body. There are various types of generalized paralysis, including:

- **Paresis** – a partial paralysis wherein there is a moderate degree of muscular weakness

- **Paraplegia** – paralysis that affects the lower extremities and lower portions of the trunk
- **Quadriplegia** – affects all four limbs
- **Hemiplegia** – affects one side of the body. For example, the arm and leg on the same side of the body (National Library of Medicine, 2021)

To learn more about paralysis, please visit the Cleveland Clinic's web page on paralysis.

Sprain and Strain

A **sprain** is an injury to a joint whereby a ligament is stretched or torn. Joints can be sprained as a result of falling, twisting, or being hit. Sprains most often occur in the ankle, although other joints can be affected. Signs and symptoms of a sprain include pain, swelling, bruising, and an inability to use the joint (National Institute of Arthritis and Musculoskeletal and Skin Diseases, n.d.).

A **strain** is an injury to a muscle or a tendon caused by stretching or tearing. Tendons or muscles can be strained as a result of an injury, lifting heavy objects incorrectly, or overstress, and they can develop suddenly or over time. Signs and symptoms of a strain include pain, muscle spasms, swelling, cramping, and difficulty moving the muscle (National Institute of Arthritis and Musculoskeletal and Skin Diseases, n.d.).

Medical Terminology in Context

Query 1.7.4

This interactive element is not available in this format. Visit the link or scan the QR code to access it online.

View this Interactive Content online

Medical Specialties and Procedures Related to Muscular System

Orthopedic Surgeon

Orthopedic surgeons are medical doctors who have specialized training in the prevention, diagnosis, treatment, and surgery of disorders and diseases related to the musculoskeletal systems (Bureau of Labor Statistics, 2021). For more details, please visit the American College of Surgeons' web page on orthopedic surgery.

Massage Therapist

Massage therapists manipulate muscles and other soft tissues through touch to relieve pain, aid the injury-healing process, and reduce stress. Massage therapists generally have a postsecondary degree, although requirements vary by state (Bureau of Labor Statistics, 2021b). To learn more about massage therapy, visit the American Massage Therapy Association's web page.

Diagnostic Procedures

Electromyography (EMG) is a procedure that assesses the electrical signals muscles send while at rest and when they are used. During the test, a needle electrode is placed into the muscle, and a machine records the muscle activity. EMG can be used to diagnose myasthenia gravis, muscular dystrophy, and other conditions affecting the muscles (MedlinePlus, 2021a). To learn more, please visit the Medline Plus web page on electromyography.

Magnetic Resonance Imaging (MRI) is a test that uses radio waves and a magnetic field to view internal organs and structures. MRI tests are used to diagnose a variety of conditions, such as torn ligaments or tumors. They are also used to view the brain and

spinal cord (Medline Plus, 2021b).

Range of Motion Testing is a diagnostic procedure used to determine the amount of movement around a specific joint.

Practice Terms Related to the Muscular System

Query 1.7.5

This interactive element is not available in this format. Visit the link or scan the QR code to access it online.

View this Interactive Content online

Muscular System Vocabulary

Antagonistic: In opposition to each other.

Bradykinesia: Condition of slow movement.

Cardiac muscle: Involuntary and found only in the heart. Highly coordinated contractions pump blood into the vessels of the circulatory system.

Dyskinesia: Abnormal involuntary movements of the extremities, trunk, or jaw.

Electromyogram: Record of the electricity of the muscle.

Electromyography (EMG): Recording of muscle electrical activity in response to a nerve's stimulation of the muscle.

Fibromyalgia: A common nonarticular rheumatic syndrome characterized by muscle pain.

Hemiplegia: Paralysis on one side of the body.

Hemostasis: The process by which the body seals a ruptured blood vessel to prevent further blood loss.

Hyperkinesia: Excessive movement of muscles of the body as a whole.

Hypertrophy: The enlargement of muscles.

Magnetic Resonance Imaging (MRI): A procedure in which radio waves and a powerful magnet linked to a computer are used to create detailed pictures of areas inside the body.

Muscular dystrophy: A general term for the group of inherited myopathies that are characterized by wasting and weakness of the skeletal muscle.

Myalgia: Pain in a muscle or group of muscles.

Myasthenia Gravis: A disease in which antibodies made by a person's immune system prevent certain nerve-muscle interactions, causing weakness in the arms and legs, vision problems, and drooping eyelids or head.

Myeloma: Cancer that arises in plasma cells.

Paraplegia: Paralysis that affects both legs and lower part of the body.

Paresis: Partial paralysis wherein there is still some control of the muscles.

Polymyositis: An inflammatory disease of the muscles closest to the center of the body.

Quadriplegia: Paralysis of all four limbs.

Rhabdomyolysis: Necrosis or disintegration of skeletal muscle.

Skeletal muscle: The muscles responsible for voluntary muscle movement; also called striated muscle.

Smooth muscle: The muscles responsible for involuntary muscle movement; also called visceral muscle.

Sprain: The stretching or tearing of the supporting ligaments.

Strain: An overstretching or overexertion of a muscle or tendon.

Tendinitis: Inflammation of the tendon.

Test Yourself

Query 1.7.6

This interactive element is not available in this format. Visit the link or scan the QR code to access it online.

View this Interactive Content online

References

Bureau of Labor Statistics. (2021a). Physicians and surgeons. In *Occupational outlook handbook*. U.S. Department of Labor. https://www.bls.gov/ooh/healthcare/physicians-and-surgeons.htm

Bureau of Labor Statistics. (2021b). Massage therapists. In *Occupational outlook handbook*. U.S. Department of Labor. https://www.bls.gov/ooh/healthcare/massage-therapists.htm

Centers for Disease Control and Prevention. (n.d.). *What is cerebral palsy?* https://www.cdc.gov/ncbddd/cp/facts.html

CrashCourse. (2015, July 15). *Muscles, part 2 – organismal level: Crash course A&P #22* [Video]. YouTube. https://youtu.be/I80Xx7pA9hQ

National Library of Medicine. (2021). *Medical Subject Headings database*. National Institutes of Health, U.S. Department of Health and Human Services. https://www.nlm.nih.gov/mesh/meshhome.html

MedlinePlus. (2021a). *Electromyography (EMG) and nerve conduction studies*. U.S. National Library of Medicine. https://medlineplus.gov/lab-tests/electromyography-emg-and-nerve-conduction-studies

MedlinePlus. (2021b). *MRI scans*. U.S. National Library of Medicine, U.S. Department of Health and Human Services. https://medlineplus.gov/mriscans.html

National Human Genome Research Institute (2013). *About Duchenne Muscular Dystrophy*. National Institutes of Health, U.S. Department of Health and Human Services. https://www.genome.gov/Genetic-Disorders/Duchenne-Muscular-Dystrophy

National Institute of Arthritis and Musculoskeletal and Skin Diseases. (n.d.). *Sprain vs. strain*. National Institutes of Health, U.S. Department of Health and Human Services. https://www.niams.nih.gov/health-topics/sprains-and-strains#tab-symptoms

National Institute of Neurological Disorders and Stroke. (2020). *Carpal tunnel syndrome fact sheet*. National Institutes of Health, U.S. Department of Health and Human Services. https://www.ninds.nih.gov/Disorders/Patient-Caregiver-Education/Fact-Sheets/

Carpal-Tunnel-Syndrome-Fact-Sheet

Science Reference Section. (2019). *What is the strongest muscle in the human body?* Library of Congress. https://www.loc.gov/everyday-mysteries/biology-and-human-anatomy/item/what-is-the-strongest-muscle-in-the-human-body/

Image Descriptions

Figure 7.1 image description: The top panel shows a micrographic view of skeletal muscle. The middle panel shows a micrographic view of smooth muscle. The bottom panel shows a micrographic view of cardiac muscle. [Return to Figure 7.1].

Figure 7.2 image description: The top panel shows the anterior view of the human body with the major muscles labeled. Labels read (from the top, head): occipitofrontalis (frontal belly), sternocleidomastoid, trapezius, deltoid, pectoralis minor, serratus anterior, pectoralis major, arm muscles: biceps brachii, brachialis, brachioradialis, pronator teres, flexor carpi radialis, abdominal: rectus abdominis, abdominal external oblique, lower body: tensor fasciae latae, iliopsoas, pectineus, adductor longus, sartorius, gracilis, rectus femoris, vastus lateralis, vastus medialis, fibularis longus, tibialis anterior. The bottom panel shows the posterior view of the human body with the major muscles labeled. Labels read (from the top, head, left side): epicranial aponeurosis, occipitofrontalis, splenius capitis, levator scapulae, rhombus, trapezius, supraspinatus, teres minor, infraspinatus, teres major, triceps brachii, serratus posterior inferior, external oblique, lower body: gluteus medius, gluteus maximus, semimembranosus, peroneus longus, tibialis posterior, (right side, from top) trapezius, deltoid, latissimus dorsi, arm: brachioradialis, extensor carpi radialis, extensor digitorum, extensor carpi ulnaris, flexor carpi ulnaris, lower body: gluteus minimus, gemellus muscles, biceps femoris, semitendinosus, gracilis, gastrocnemius, soleus. [Return to Figure 7.2].

Unless otherwise indicated, this chapter contains material adapted from *Anatomy and Physiology* (on OpenStax), by Betts et al. and is used under a CC BY 4.0 international license. Download and access this book for free at https://openstax.org/books/anatomy-and-physiology/pages/1-introduction.

This page titled 1.7: Muscular System is shared under a CC BY 4.0 license and was authored, remixed, and/or curated by Andrea Nelson and Katherine Greene via source content that was edited to the style and standards of the LibreTexts platform.

1.8: Nervous System

Learning Objectives

- Examine the anatomy of the nervous system
- Determine the main functions of the nervous system
- Differentiate the medical terms of the nervous system and common abbreviations
- Recognize the medical specialties associated with the nervous system
- Discover common diseases, disorders, and procedures related to the nervous system

Nervous System Word Parts

Click on prefixes, combining forms, and suffixes to reveal a list of word parts to memorize for the Nervous System.

Query 1.8.1

This interactive element is not available in this format. Visit the link or scan the QR code to access it online.

View this Interactive Content online

Introduction to the Nervous System

The picture you have in your mind of the nervous system probably includes the **brain**, the **nervous tissue** contained within the cranium, and the **spinal cord**, the extension of nervous tissue within the vertebral column. That suggests it is made of two organs—and you may not even think of the spinal cord as an organ—but the nervous system is a very complex structure. Within the brain, many different and separate regions are responsible for many different and separate functions. It is as if the nervous system is composed of many organs that all look similar and can only be differentiated using tools such as the microscope or electrophysiology.

Watch this video:

YouTube Video

This interactive element is not available in this format. Visit the link or scan the QR code to access it online.

View this YouTube Video online

Media 8.1 The Nervous System, Part 1: Crash Course A&P #8 [Online video]. Copyright 2015 by CrashCourse.

Practice Medical Terms Related to the Nervous System

Query 1.8.2

This interactive element is not available in this format. Visit the link or scan the QR code to access it online.

View this Interactive Content online

Anatomy (Structures) of the Nervous System

The Central and Peripheral Nervous Systems

The nervous system can be divided into two major regions: the central and peripheral nervous systems. The central nervous system (CNS) is the brain and spinal cord, and the peripheral nervous system (PNS) is everything else (see Figure 8.1). The brain is contained within the cranial cavity of the skull, and the spinal cord is contained within the vertebral cavity of the vertebral column. It is a bit of an oversimplification to say that the CNS is what is inside these two cavities and the peripheral nervous system is outside of them, but that is one way to start to think about it. In actuality, there are some elements of the peripheral nervous system that are within the cranial or vertebral cavities. The peripheral nervous system is so named because it is on the periphery—meaning beyond the brain and spinal cord. Depending on different aspects of the nervous system, the dividing line between central and peripheral is not necessarily universal.

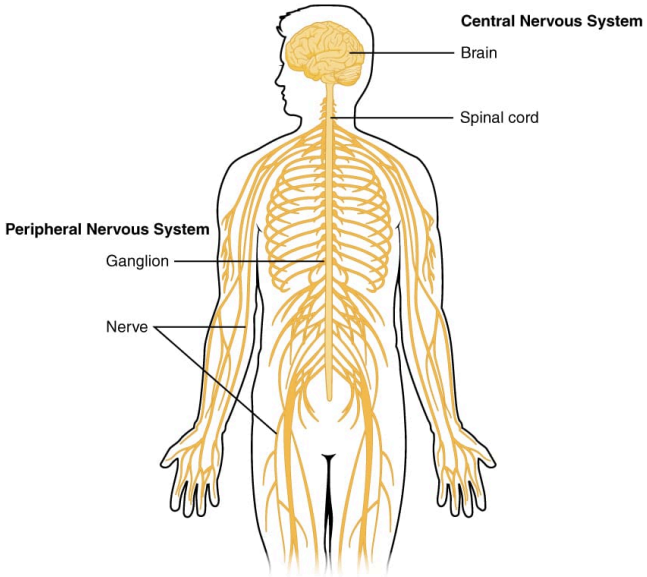

Figure 8.1 Central and Peripheral Nervous System. The structures of the PNS are referred to as ganglia and nerves, which can be seen as distinct structures. The equivalent structures in the CNS are not obvious from this overall perspective and are best examined in prepared tissue under the microscope. From Betts et al., 2013. Licensed under CC BY 4.0. [Image description.]

Nervous tissue, present in both the CNS and PNS, contains two basic types of cells: neurons and glial cells. **Neurons** are the primary type of cell that most anyone associates with the nervous system. They are responsible for the computation and communication that the nervous system provides. They are electrically active and release chemical signals to target cells. Glial cells, or **glia**, are known to play a supporting role for nervous tissue. Ongoing research pursues an expanded role that glial cells might play in signaling, but neurons are still considered the basis of this function. Neurons are important, but without glial support, they would not be able to perform their function. A glial cell is one of a variety of cells that provide a framework of tissue that supports the neurons and their activities. The neuron is the more functionally important of the two, in terms of the communicative

function of the nervous system. To describe the functional divisions of the nervous system, it is important to understand the structure of a neuron.

Neurons are cells and therefore have a **soma,** or cell body, but they also have extensions of the cell; each extension is generally referred to as a process. There is one important process that every neuron has called an **axon**, which is the fiber that connects a neuron with its target. Another type of process that branches off from the soma is the dendrite. **Dendrites** are responsible for receiving most of the input from other neurons.

Looking at nervous tissue, some regions predominantly contain cell bodies and regions that are largely composed of just axons. These two regions within nervous system structures are often referred to as **gray matter** (the regions with many cell bodies and dendrites) or **white matter** (the regions with many axons). Figure 8.2 demonstrates the appearance of these regions in the brain and spinal cord. The colors ascribed to these regions are what would be seen in "fresh," or unstained, nervous tissue. Gray matter is not necessarily gray. It can be pinkish because of blood content, or even slightly tan, depending on how long the tissue has been preserved. White matter is white because axons are insulated by a lipid-rich substance called myelin. Lipids can appear as white ("fatty") material, much like the fat on a raw piece of chicken or beef. Gray matter may have that color ascribed to it because next to the white matter, it is just darker—hence, gray.

The distinction between **gray matter** and **white matter** is most often applied to central nervous tissue, which has large regions that can be seen with the unaided eye. When looking at peripheral structures, often a microscope is used and the tissue is stained with artificial colors. That is not to say that central nervous tissue cannot be stained and viewed under a microscope, but unstained tissue is most likely from the CNS—for example, a frontal section of the brain or cross-section of the spinal cord.

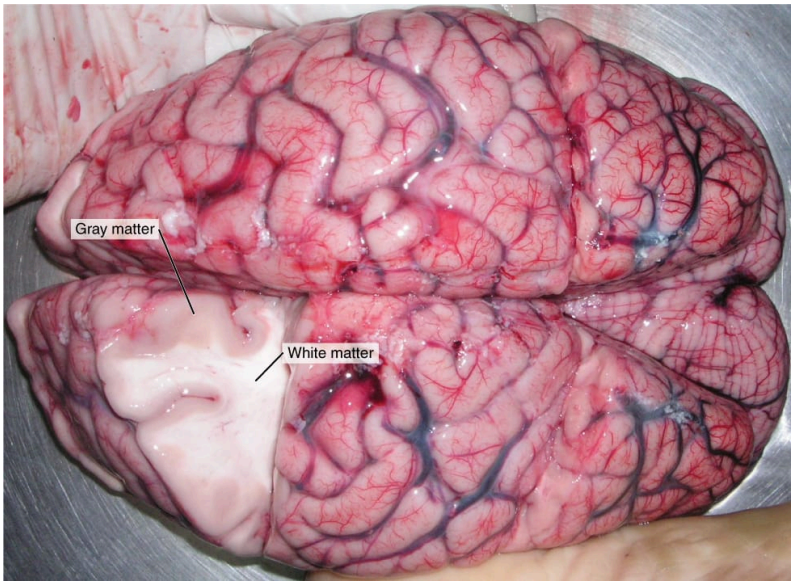

Figure 8.2 Gray Matter and White Matter. A brain removed during an autopsy, with a partial section removed, shows white matter surrounded by gray matter. Gray matter makes up the outer cortex of the brain. (credit: modification of work by "Suseno"/Wikimedia Commons). From Betts et al., 2013. Licensed under CC BY 4.0. [Image description.]

Did you know?

The brain has over 100 billion neurons.

The Adult Brain

The adult brain is separated into four major regions: the cerebrum, the diencephalon, the brain stem, and the cerebellum. The cerebrum is the largest portion and contains the cerebral cortex and subcortical nuclei. It is divided into two halves by the longitudinal fissure.

The Cerebrum

The iconic gray mantle of the human brain, which appears to make up most of the mass of the brain, is the cerebrum (see Figure 8.3). The wrinkled portion is the cerebral cortex, and the rest of the structure is beneath that outer covering. There is a large separation between the two sides of the cerebrum called the **longitudinal** fissure. It separates the cerebrum into two distinct halves, a right and left **cerebral hemisphere**. Deep within the cerebrum, the white matter of the corpus callosum provides the major pathway for communication between the two hemispheres of the cerebral cortex.

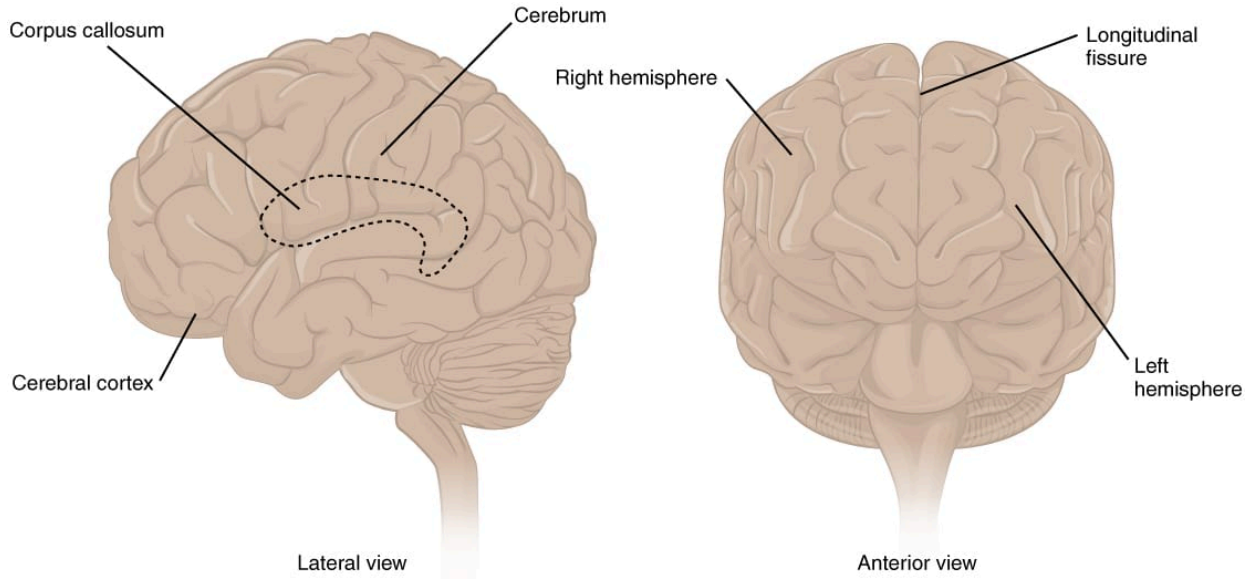

Figure 8.3 The Cerebrum. The cerebrum is a large component of the CNS in humans, and the most obvious aspect of it is the folded surface called the cerebral cortex. From Betts et al., 2013. Licensed under CC BY 4.0. [Image description.]

Many of the higher neurological functions, such as memory, emotion, and consciousness, are the result of cerebral function. The complexity of the cerebrum is different across vertebrate species. The cerebrum of the most primitive vertebrates is not much more than the connection for the sense of smell. In mammals, the cerebrum comprises the outer gray matter that is the cortex (from the Latin word meaning “bark of a tree”) and several deep nuclei that belong to three important functional groups. The basal nuclei are responsible for cognitive processing, the most important function being that associated with planning movements. The basal forebrain contains nuclei that are important in learning and memory. The limbic cortex is the region of the cerebral cortex that is part of the limbic system, a collection of structures involved in emotion, memory, and behavior.

Did you know?

The brain is about 75% water and is the fattest organ in the body.

Cerebral Cortex

The cerebrum is covered by a continuous layer of gray matter that wraps around either side of the forebrain—the **cerebral cortex**. This thin, extensive region of wrinkled gray matter is responsible for the higher functions of the nervous system. A gyrus (plural = gyri) is the ridge of one of those wrinkles, and a sulcus (plural = sulci) is the groove between two gyri. The pattern of these folds of tissue indicates specific regions of the cerebral cortex.

The head is limited by the size of the birth canal, and the brain must fit inside the cranial cavity of the skull. Extensive folding in the cerebral cortex enables more gray matter to fit into this limited space. If the gray matter of the cortex were peeled off of the cerebrum and laid out flat, its surface area would be roughly equal to one square meter.

The folding of the cortex maximizes the amount of gray matter in the cranial cavity. During embryonic development, as the

telencephalon expands within the skull, the brain goes through a regular course of growth that results in everyone's brain having a similar pattern of folds. The surface of the brain can be mapped based on the locations of large gyri and sulci. Using these landmarks, the cortex can be separated into four major regions, or lobes (see Figure 8.4). The lateral sulcus that separates the temporal lobe from the other regions is one such landmark. Superior to the lateral sulcus is the **parietal lobe** and **frontal lobe**, which are separated from each other by the **central sulcus**. The posterior region of the cortex is the **occipital lobe**, which has no obvious anatomical border between it and the parietal or temporal lobes on the lateral surface of the brain. From the medial surface, an obvious landmark separating the parietal and occipital lobes is called the parieto-occipital sulcus. The fact that there is no obvious anatomical border between these lobes is consistent with the functions of these regions being interrelated.

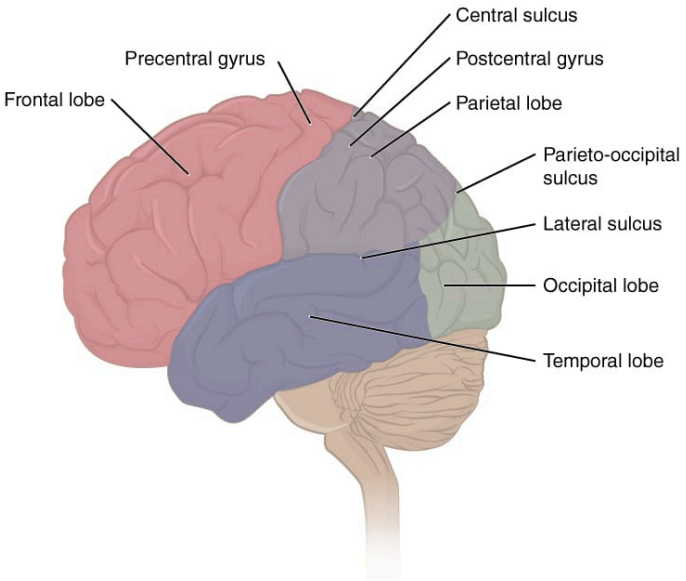

Figure 8.4 Lobes of the Cerebral Cortex. The cerebral cortex is divided into four lobes. Extensive folding increases the surface area available for cerebral functions. From Betts et al., 2013. Licensed under CC BY 4.0. [Image description.]

Concept Check

- Identify the two major divisions of the nervous system.
- Describe the **cerebral cortex.**
- What are the halves of the cerebrum known as?

The Diencephalon

The diencephalon is deep beneath the cerebrum and constitutes the walls of the third ventricle. The diencephalon can be described as any region of the brain with "thalamus" in its name. The two major regions of the diencephalon are the thalamus itself and the hypothalamus (see Figure 8.5). There are other structures, such as the epithalamus, which contains the pineal gland, or the subthalamus, which includes the subthalamic nucleus that is part of the basal nuclei.

Thalamus

The **thalamus** is a collection of nuclei that relay information between the cerebral cortex and the periphery, spinal cord, or brainstem. All sensory information, except for the sense of smell, passes through the thalamus before processing by the cortex. For example, the portion of the thalamus that receives visual information will influence what visual stimuli are important, or what receives attention.

The cerebrum also sends information down to the thalamus, which usually communicates motor commands. This involves interactions with the cerebellum and other nuclei in the brainstem. The cerebrum interacts with the basal nuclei, which involves connections with the thalamus. The primary output of the basal nuclei is to the thalamus, which relays that output to the cerebral

cortex. The cortex also sends information to the thalamus that will then influence the effects of the basal nuclei.

Hypothalamus

Inferior and slightly anterior to the thalamus is the hypothalamus, the other major region of the diencephalon. The hypothalamus is a collection of nuclei that are largely involved in regulating homeostasis. The hypothalamus is the executive region in charge of the **autonomic nervous system** and the endocrine system through its regulation of the anterior pituitary gland. Other parts of the hypothalamus are involved in memory and emotion as part of the limbic system.

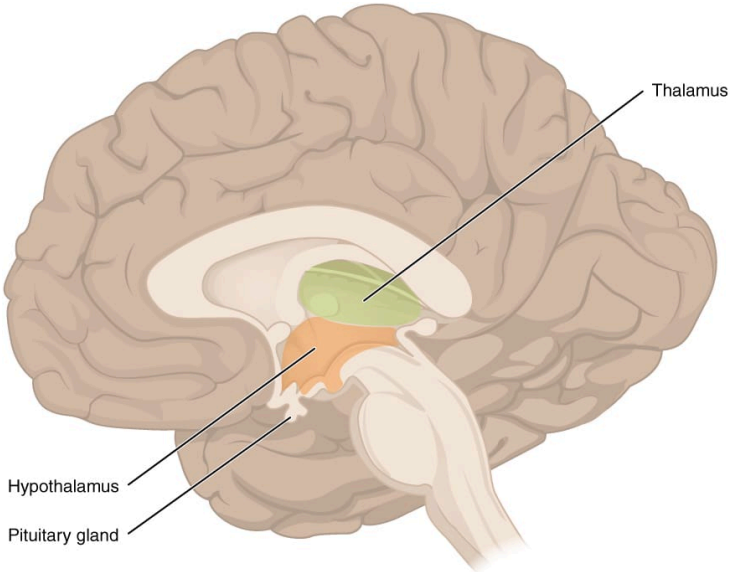

Figure 8.5 The Diencephalon. The diencephalon is composed primarily of the thalamus and hypothalamus, which together define the walls of the third ventricle. The thalami are two elongated, ovoid structures on either side of the midline that make contact in the middle. The hypothalamus is inferior and anterior to the thalamus, culminating in a sharp angle to which the pituitary gland is attached. From Betts et al., 2013. Licensed under CC BY 4.0. [Image description.]

Brain Stem

The midbrain and hindbrain (composed of the **pons** and the **medulla**) are collectively referred to as the brain stem (see Figure 8.6). The structure emerges from the ventral surface of the forebrain as a tapering cone that connects the brain to the spinal cord. Attached to the brain stem but considered a separate region of the adult brain is the cerebellum. The midbrain coordinates sensory representations of the visual, auditory, and somatosensory perceptual spaces. The pons is the main connection with the cerebellum. The pons and the medulla regulate several crucial functions, including the cardiovascular and respiratory systems and rates.

The cranial nerves connect through the brain stem and provide the brain with the sensory input and motor output associated with the head and neck, including most of the special senses. The major ascending and descending pathways between the spinal cord and brain, specifically the cerebrum, pass through the brain stem.

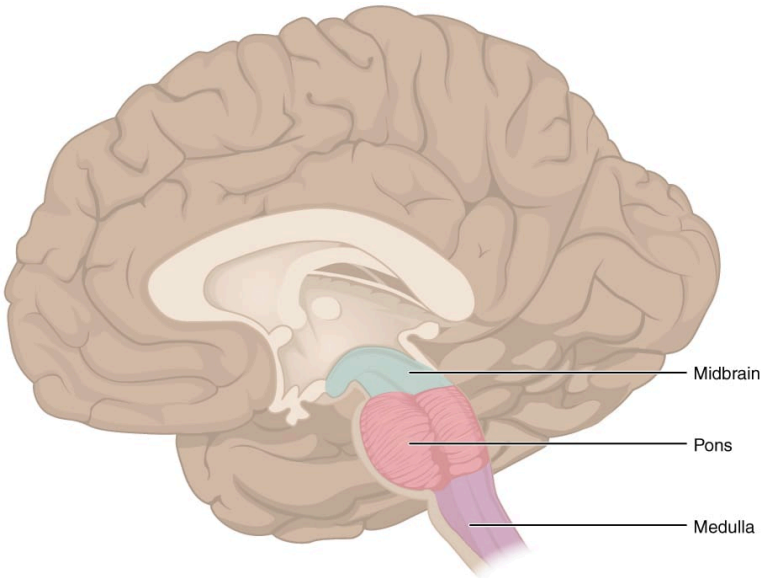

Figure 8.6 The Brain Stem. The brain stem comprises three regions: the midbrain, the pons, and the medulla. From Betts et al., 2013. Licensed under CC BY 4.0. [Image description.]

Midbrain

One of the original regions of the embryonic brain, the midbrain is a small region between the thalamus and pons. It is separated into the **tectum** and **tegmentum**, from the Latin words for roof and floor, respectively. The cerebral aqueduct passes through the center of the midbrain, such that these regions are the roof and floor of that canal.

Pons

The word **pons** comes from the Latin word for bridge. It is visible on the anterior surface of the brain stem as the thick bundle of white matter attached to the cerebellum. The pons is the main connection between the cerebellum and the brain stem. The bridge-like white matter is only the anterior surface of the pons; the gray matter beneath that is a continuation of the tegmentum from the midbrain. Gray matter in the tegmentum region of the pons contains neurons receiving descending input from the forebrain that is sent to the cerebellum.

Medulla

The medulla is the region known as the **myelencephalon** in the embryonic brain. The initial portion of the name, “myel,” refers to the significant white matter found in this region—especially on its exterior, which is continuous with the white matter of the spinal cord. The tegmentum of the midbrain and pons continues into the medulla because this gray matter is responsible for processing cranial nerve information. A diffuse region of gray matter throughout the brain stem, known as the reticular formation, is related to sleep and wakefulness, such as general brain activity and attention.

The Cerebellum

The cerebellum, as the name suggests, is the “little brain.” It is covered in **gyri** and sulci like the cerebrum and looks like a miniature version of that part of the brain (see Figure 8.7). The cerebellum is largely responsible for comparing information from the cerebrum with sensory feedback from the periphery through the spinal cord. It accounts for approximately 10% of the mass of the brain.

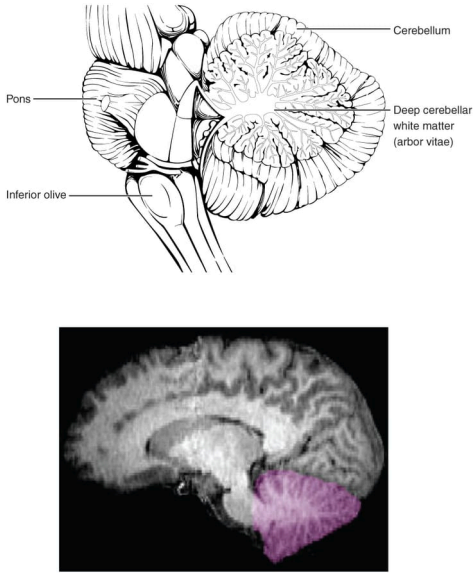

Figure 8.7 The Cerebellum. The cerebellum is situated on the posterior surface of the brain stem. Descending input from the cerebellum enters through the large white matter structure of the pons. Ascending input from the periphery and spinal cord enters through the fibers of the inferior olive. Output goes to the midbrain, which sends a descending signal to the spinal cord. From Betts et al., 2013. Licensed under CC BY 4.0. [Image description.]

Concept Check

- What is the primary processing purpose of the **medulla**?
- Identify the structure in the brain responsible for sensory feedback through the spinal cord. Suggest what may happen if this function fails.

The Spinal Cord

The description of the CNS is concentrated on the structures of the brain, but the spinal cord is another major organ of the system. Whereas the brain develops out of expansions of the neural tube into primary and then secondary vesicles, the spinal cord maintains the tube structure and is only specialized into certain regions. As the spinal cord continues to develop in the newborn, anatomical features mark its surface. The anterior midline is marked by the anterior median fissure, and the posterior midline is marked by the posterior median sulcus. Axons enter the posterior side through the dorsal (posterior) nerve root, which marks the posterolateral sulcus on either side. The axons emerging from the anterior side do so through the ventral (anterior) nerve root. Note that it is common to see the terms dorsal (dorsal = “back”) and ventral (ventral = “belly”) used interchangeably with posterior and anterior, particularly in reference to nerves and the structures of the spinal cord. You should learn to be comfortable with both.

On the whole, the posterior regions are responsible for sensory functions and the anterior regions are associated with motor functions. This comes from the initial development of the spinal cord, which is divided into the basal plate and the alar plate. The basal plate is closest to the ventral midline of the neural tube, which will become the anterior face of the spinal cord and gives rise to motor neurons. The alar plate is on the dorsal side of the neural tube and gives rise to neurons that will receive sensory input from the periphery.

The length of the spinal cord is divided into regions that correspond to the regions of the vertebral column. The name of a spinal cord region corresponds to the level at which spinal nerves pass through the intervertebral foramina. Immediately adjacent to the brain stem are the following divisions of the spinal cord:

- cervical region
- thoracic region
- lumbar region

- sacral region.

The spinal cord is not the full length of the vertebral column because the spinal cord does not grow significantly longer after the first or second year, but the skeleton continues to grow. The nerves that emerge from the spinal cord pass through the intervertebral **foramina** at the respective levels. As the vertebral column grows, these nerves grow with it and result in a long bundle of nerves that resembles a horse's tail and is named the **cauda equina**. The sacral spinal cord is at the level of the upper lumbar vertebral bones. The spinal nerves extend from their various levels to the proper level of the vertebral column.

> **Did you know?**
>
> The bundle of nerve fibers making up the spinal cord is no thicker than the human thumb.

Neurons

Neurons are the cells considered to be the basis of nervous tissue. They are responsible for the electrical signals that communicate information about sensations, and that produce movements in response to those stimuli, along with inducing thought processes within the brain. An important part of the function of neurons is in their structure or shape. The three-dimensional shape of these cells makes the immense number of connections within the nervous system possible.

Parts of a Neuron

As you learned in the first section, the main part of a neuron is the **cell body**, which is also known as the soma (soma = "body"). The cell body contains the nucleus and most of the major organelles. What makes neurons special is that they have many extensions of their cell membranes, which are generally referred to as processes. Neurons are usually described as having one, and only one, axon—a fiber that emerges from the cell body and projects to target cells. That single axon can branch repeatedly to communicate with many **target** cells. It is the axon that **propagates** the nerve impulse, which is communicated to one or more cells. The other processes of the neuron are dendrites, which receive information from other neurons at specialized areas of contact called synapses. The dendrites are usually highly branched processes, providing locations for other neurons to communicate with the cell body. Information flows through a neuron from the dendrites, across the cell body, and down the axon. This gives the neuron a polarity—meaning that information flows in this one direction. Figure 8.8 shows the relationship of these parts to one another.

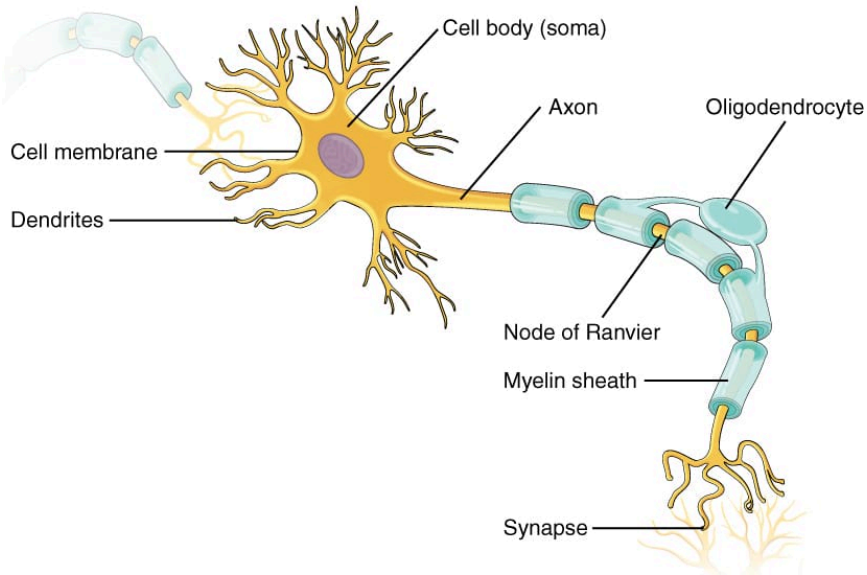

Figure 8.8 Parts of a Neuron. The major parts of the neuron are labeled on a multipolar neuron from the CNS. From Betts et al., 2013. Licensed under CC BY 4.0. [Image description.]

Where the axon emerges from the cell body, there is a special region referred to as the **axon hillock**. This is a tapering of the cell

body toward the axon fiber. Within the axon hillock, the cytoplasm changes to a solution of limited components called **axoplasm**. Because the axon hillock represents the beginning of the axon, it is also referred to as the initial segment.

Many axons are wrapped by an insulating substance called myelin, which is made from glial cells. Myelin acts as insulation much like the plastic or rubber that is used to insulate electrical wires. A key difference between **myelin** and the insulation on a wire is that there are gaps in the myelin covering of an axon. Each gap is called a node of Ranvier and is important to the way that electrical signals travel down the axon. The length of the axon between each gap, which is wrapped in myelin, is referred to as an axon segment. At the end of the axon is the axon terminal, where there are usually several branches extending toward the target cell, each of which ends in an enlargement called a synaptic end bulb. These bulbs are what make the connection with the target cell at the synapse.

Types of Neurons

There are many neurons in the nervous system—a number in the trillions. And there are many different types of neurons. They can be classified by many different criteria. The first way to classify them is by the number of processes attached to the cell body. Using the standard model of neurons, one of these processes is the axon, and the rest are dendrites. Because information flows through the neuron from dendrites or cell bodies toward the axon, these names are based on the neuron's polarity (see Figure 8.9).

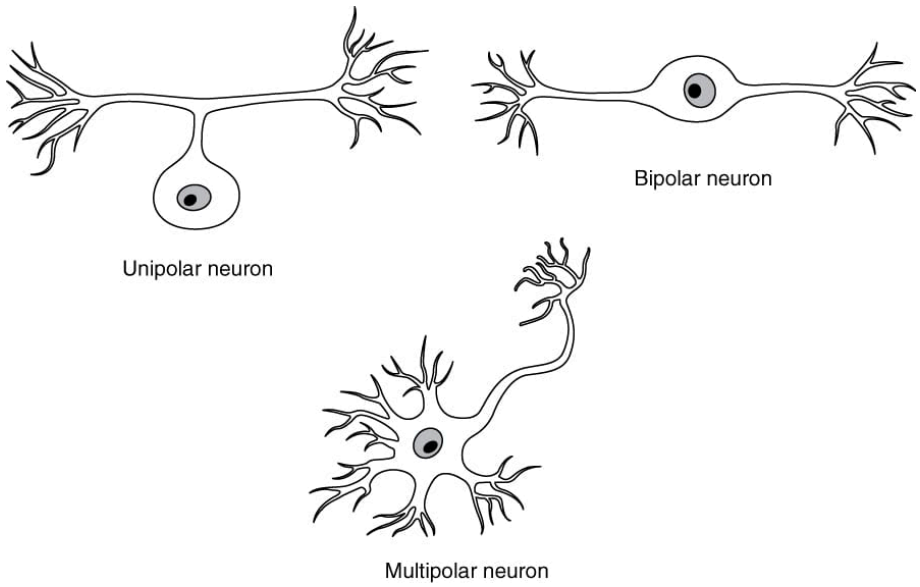

Figure 8.9 Neuron Classification by Shape. Unipolar cells have one process that includes both the axon and dendrite. Bipolar cells have two processes, the axon, and a dendrite. Multipolar cells have more than two processes, the axon, and two or more dendrites. From Betts et al., 2013. Licensed under CC BY 4.0. [Image description.]

Unipolar cells have only one process emerging from the cell. True unipolar cells are only found in invertebrate animals, so the unipolar cells in humans are more appropriately called "pseudo-unipolar" cells. Invertebrate unipolar cells do not have dendrites.

Bipolar cells have two processes, which extend from each end of the cell body, opposite to each other. One is the axon and one the dendrite. Bipolar cells are not very common. They are found mainly in the olfactory epithelium (where smell stimuli are sensed), and as part of the retina.

Multipolar neurons are all of the neurons that are not unipolar or bipolar. They have one axon and two or more dendrites (usually many more). With the exception of the unipolar sensory ganglion cells, and the two specific bipolar cells mentioned above, all other neurons are multipolar.

Neurons can also be classified on the basis of where they are found, who found them, what they do, or even what chemicals they use to communicate with each other. Some neurons referred to in this section on the nervous system are named on the basis of those sorts of classifications (see Figure 8.10). For example, a multipolar neuron that has a very important role to play in a part of the brain called the cerebellum is known as a Purkinje (commonly pronounced per-KIN-gee) cell. It is named after the anatomist who discovered it (Jan Evangilista Purkinje, 1787–1869).

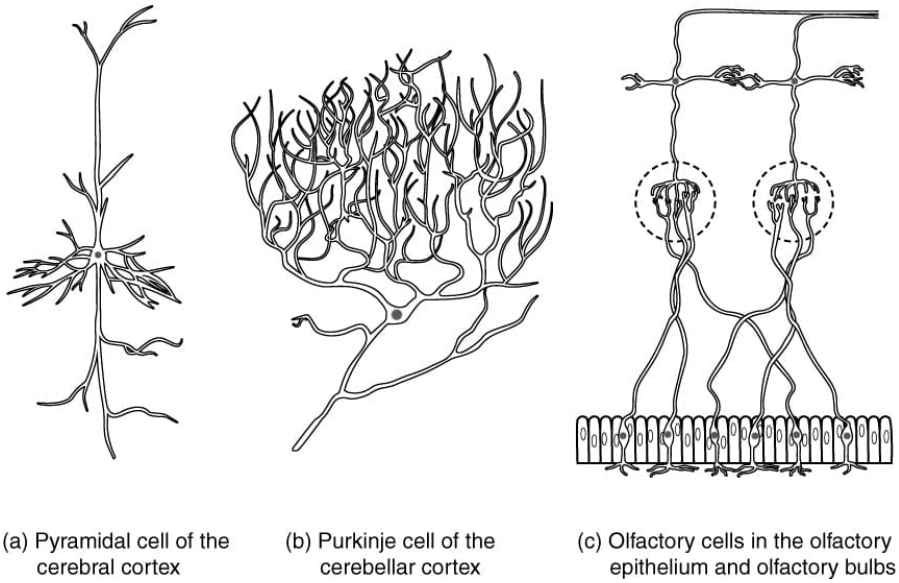

Figure 8.10 Other Neuron Classifications. Three examples of neurons that are classified on the basis of other criteria. (a) The pyramidal cell is a multipolar cell with a cell body that is shaped something like a pyramid. (b) The Purkinje cell in the cerebellum was named after the scientist who originally described it. (c) Olfactory neurons are named for the functional group to which they belong. From Betts et al., 2013. Licensed under CC BY 4.0. [Image description.]

Glial Cells

Glial cells, or neuroglia or simply glia, are the other type of cell found in nervous tissue. They are considered to be supporting cells, and many functions are directed at helping neurons complete their function for communication. The name glia comes from the Greek word that means "glue," and was coined by the German pathologist Rudolph Virchow, who wrote in 1856, "This connective substance, which is in the brain, the spinal cord, and the special sense nerves, is a kind of glue (neuroglia) in which the nervous elements are planted." Today, research into nervous tissue has shown that there are many deeper roles that these cells play, and research may find much more about them in the future.

There are six types of glial cells. Four of them are found in the CNS and two are found in the PNS. Table 8.1 outlines some common characteristics and functions.

Table 8.1: Glial Cell Types by Location and Basic Function. From Betts et al., 2013. Licensed under CC BY 4.0.

CNS GLIA	PNS GLIA	BASIC FUNCTION
Astrocyte	Satellite cell	Support
Oligodendrocyte	Schwann cell	Insulation, myelination
Microglia	–	Immune surveillance and phagocytosis
Ependymal cell	–	Creating CSF

Glial Cells of the CNS

One cell providing support to neurons of the CNS is the astrocyte, so named because it appears to be star-shaped under the microscope (astro- = "star"). **Astrocytes** have many processes extending from their main cell body (not axons or dendrites like neurons, just cell extensions). Those processes extend to interact with neurons, blood vessels, or the connective tissue covering the CNS that is called the pia mater (see Figure 8.11). Generally, they are supporting cells for the neurons in the central nervous system. Some ways in which they support neurons in the central nervous system are by maintaining the concentration of chemicals in the extracellular space, removing excess signaling molecules, reacting to tissue damage, and contributing to the **blood-brain barrier** (BBB). The blood-brain barrier is a physiological barrier that keeps many substances that circulate in the rest

of the body from getting into the central nervous system, restricting what can cross from circulating blood into the CNS. Nutrient molecules, such as glucose or amino acids, can pass through the BBB, but other molecules cannot. This actually causes problems with drug delivery to the CNS. Pharmaceutical companies are challenged to design drugs that can cross the BBB as well as have an effect on the nervous system.

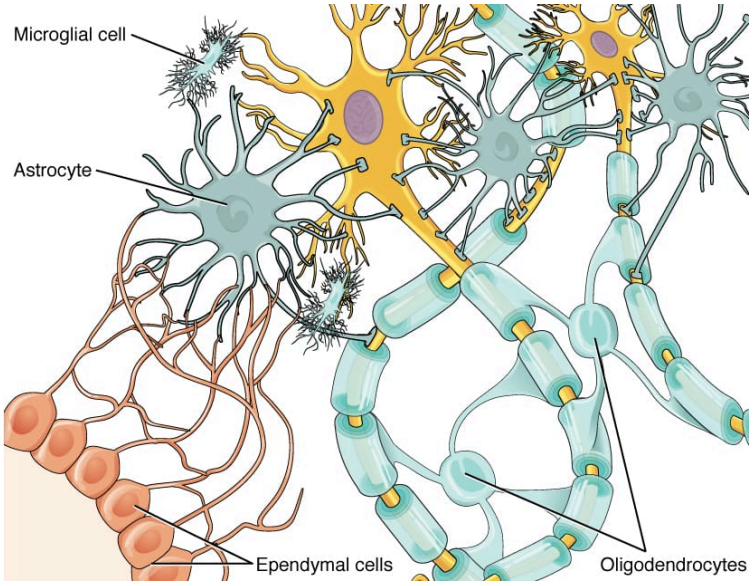

Figure 8.11 Glial Cells of the CNS. The CNS has astrocytes, oligodendrocytes, microglia, and ependymal cells that support the neurons of the CNS in several ways. From Betts et al., 2013. Licensed under CC BY 4.0. [Image description.]

Like a few other parts of the body, the brain has a privileged blood supply. Very little can pass through by diffusion. Most substances that cross the wall of a blood vessel into the CNS must do so through an active transport process. Because of this, only specific types of molecules can enter the CNS. Glucose—the primary energy source—is allowed, as are amino acids. Water and some other small particles, like gases and ions, can enter, but most everything else cannot, including white blood cells, which are one of the body's main lines of defense. While this barrier protects the CNS from exposure to toxic or pathogenic substances, it also keeps out the cells that could protect the brain and spinal cord from disease and damage. The BBB also makes it harder for pharmaceuticals to be developed that can affect the nervous system. Aside from finding efficacious substances, the means of delivery is also crucial.

Oligodendrocyte, sometimes called just "oligo," is the glial cell type that insulates axons in the CNS. The name means "cell of a few branches" (oligo- = "few"; dendro- = "branches"; -cyte = "cell"). There are a few processes that extend from the cell body. Each one reaches out and surrounds an axon to insulate it in myelin.

Microglia are, as the name implies, smaller than most of the other glial cells. Ongoing research into these cells, although not entirely conclusive, suggests that they may originate as white blood cells, called macrophages, that become part of the CNS during early development. While their origin is not conclusively determined, their function is related to what macrophages do in the rest of the body. When macrophages encounter diseased or damaged cells in the rest of the body, they ingest and digest those cells or the pathogens that cause disease. Microglia are the cells in the CNS that can do this in normal, healthy tissue, and they are therefore also referred to as CNS-resident macrophages.

The **ependymal** cell is a glial cell that filters blood to make cerebrospinal fluid (CSF), the fluid that circulates through the CNS. Because of the privileged blood supply inherent in the BBB, the extracellular space in nervous tissue does not easily exchange components with the blood. Ependymal cells line each ventricle, one of four central cavities that are remnants of the hollow center of the neural tube formed during the embryonic development of the brain. They also have cilia on their apical surface to help move the CSF through the ventricular space. The relationship of these glial cells to the structure of the CNS is seen in Figure 8.11.

Glial Cells of the PNS

One of the two types of glial cells found in the PNS is the **satellite** cell. Satellite cells are found in sensory and autonomic ganglia, where they surround the cell bodies of neurons. This accounts for the name, based on their appearance under the microscope. They provide support, performing similar functions in the periphery as astrocytes do in the CNS—except, of course,

for establishing the BBB.

The second type of glial cell is the **Schwann** cell, which insulates axons with myelin in the periphery. Schwann cells are different from oligodendrocytes in that a Schwann cell wraps around a portion of only one axon segment and no others. Oligodendrocytes have processes that reach out to multiple axon segments, whereas the entire Schwann cell surrounds just one axon segment. The nucleus and cytoplasm of the Schwann cell are on the edge of the myelin sheath. The relationship of these two types of glial cells to ganglia and nerves in the PNS is seen in Figure 8.12.

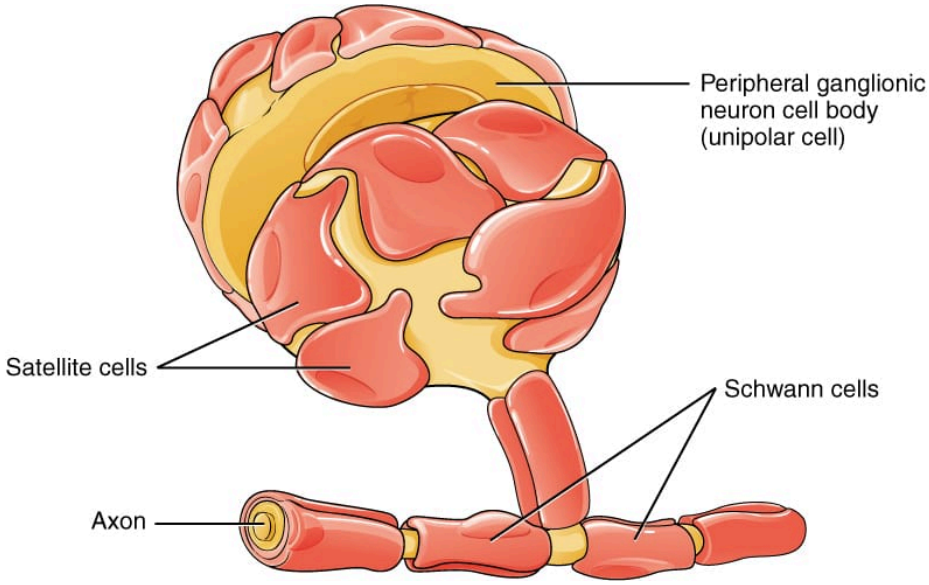

Figure 8.12 Glial Cells of the PNS. The PNS has satellite cells and Schwann cells. From Betts et al., 2013. Licensed under CC BY 4.0. [Image description.]

Myelin

The appearance of the myelin sheath can be thought of as similar to the pastry wrapped around a hot dog for "pigs in a blanket" or similar food. The glial cell is wrapped around the axon several times with little to no cytoplasm between the glial cell layers. For **oligodendrocytes**, the rest of the cell is separate from the myelin sheath as a cell process extends back toward the cell body. A few other processes provide the same insulation for other axon segments in the area. For Schwann cells, the outermost layer of the cell membrane contains cytoplasm and the nucleus of the cell as a bulge on one side of the myelin sheath. During development, the glial cell is loosely or incompletely wrapped around the axon. The edges of this loose enclosure extend toward each other, and one end tucks under the other. The inner edge wraps around the axon, creating several layers, and the other edge closes around the outside so that the axon is completely enclosed.

Anatomy Labeling Activity

Query 1.8.3

This interactive element is not available in this format. Visit the link or scan the QR code to access it online.

View this Interactive Content online

Physiology (Function) of the Nervous System

The nervous system is involved in receiving information about the environment around us (sensation) and generating responses to that information (motor responses). The nervous system can be divided into regions that are responsible for sensation (sensory functions) and the response (motor functions), but there is a third function that needs to be included. Sensory input needs to be integrated with other sensations, as well as with memories, emotional state, or learning (cognition). Some regions of the nervous system are termed integration or association areas. The process of integration combines sensory perceptions and higher cognitive functions such as memories, learning, and emotion to produce a response.

Sensation

The first major function of the nervous system is sensation—receiving information about the environment to gain input about what is happening outside the body (or, sometimes, within the body). The sensory functions of the nervous system register the presence of a change from homeostasis or a particular event in the environment, known as a stimulus. The senses we think of most are the "big five": taste, smell, touch, sight, and hearing. The stimuli for taste and smell are both chemical substances (molecules, compounds, ions, etc.), touch is physical or mechanical stimuli that interact with the skin, sight is light stimuli, and hearing is the perception of sound, which is a physical stimulus similar to some aspects of touch. There are more senses than just those, but that list represents the major senses. Those five are all senses that receive stimuli from the outside world, and of which there is conscious perception. Additional sensory stimuli might be from the internal environment (inside the body), such as the stretch of an organ wall or the concentration of certain ions in the blood.

Response

The nervous system produces a response on the basis of the stimuli perceived by sensory structures. An obvious response would be the movement of muscles, such as withdrawing a hand from a hot stove, but there are broader uses of the term. The nervous system can cause the contraction of all three types of muscle tissue. For example, skeletal muscle contracts to move the skeleton, cardiac muscle is influenced as heart rate increases during exercise, and smooth muscle contracts as the digestive system moves food along the digestive tract. Responses also include the neural control of glands in the body as well, such as the production and secretion of sweat by the eccrine and merocrine sweat glands found in the skin to lower body temperature.

Responses can be divided into those that are voluntary or conscious (contraction of skeletal muscle) and those that are involuntary (contraction of smooth muscles, regulation of cardiac muscle, activation of glands). Voluntary responses are governed by the somatic nervous system and involuntary responses are governed by the autonomic nervous system, which are discussed in the next section.

Integration

Stimuli that are received by sensory structures are communicated to the nervous system where that information is processed. This is called integration. Stimuli are compared with, or integrated with, other stimuli, memories of previous stimuli, or the state of a person at a particular time. This leads to the specific response that will be generated. Seeing a baseball pitched to a batter will not automatically cause the batter to swing. The trajectory of the ball and its speed will need to be considered. Maybe the count is three balls and one strike, and the batter wants to let this pitch go by in the hope of getting a walk to first base. Or maybe the batter's team is so far ahead, it would be fun to just swing away.

Controlling the Body

The nervous system can be divided into two parts mostly on the basis of a functional difference in responses. The somatic nervous system (SNS) is responsible for conscious perception and voluntary motor responses. Voluntary motor response means the contraction of skeletal muscle, but those contractions are not always voluntary in the sense that you have to want to perform them. Some somatic motor responses are reflexes and often happen without a conscious decision to perform them. If your friend jumps out from behind a corner and yells "Boo!" you will be startled and you might scream or leap back. You didn't decide to do that, and you may not have wanted to give your friend a reason to laugh at your expense, but it is a reflex involving skeletal muscle contractions. Other motor responses become automatic (in other words, unconscious) as a person learns motor skills (referred to as "habit learning" or "procedural memory").

The autonomic nervous system (ANS) is responsible for involuntary control of the body, usually for the sake of homeostasis

(regulation of the internal environment). Sensory input for autonomic functions can be from sensory structures tuned to external or internal environmental stimuli. The motor output extends to smooth and cardiac muscle as well as glandular tissue. The role of the autonomic system is to regulate the organ systems of the body, which usually means to control homeostasis. Sweat glands, for example, are controlled by the autonomic system. When you are hot, sweating helps cool your body down. That is a homeostatic mechanism. When you are nervous, you might start sweating also. That is not homeostatic, it is the physiological response to an emotional state.

There is another division of the nervous system that describes functional responses. The enteric nervous system (ENS) is responsible for controlling the smooth muscle and glandular tissue in your digestive system. It is a large part of the PNS, and is not dependent on the CNS. It is sometimes valid, however, to consider the enteric system to be a part of the autonomic system because the neural structures that make up the enteric system are a component of the autonomic output that regulates digestion. There are some differences between the two, but for our purposes here there will be a good bit of overlap. See Figure 8.13 for examples of where these divisions of the nervous system can be found.

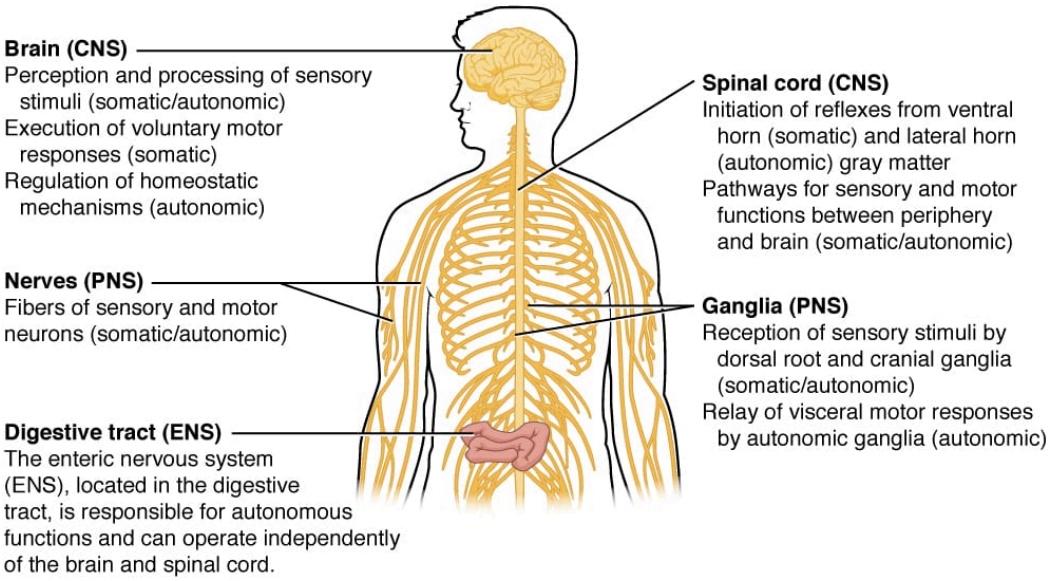

Figure 8.13 Somatic, Autonomic, and Enteric Structures of the Nervous System. Somatic structures include the spinal nerves, both motor and sensory fibers, as well as the sensory ganglia (posterior root ganglia and cranial nerve ganglia). Autonomic structures are found in the nerves also but include the sympathetic and parasympathetic ganglia. The enteric nervous system includes the nervous tissue within the organs of the digestive tract. From Betts et al., 2013. Licensed under CC BY 4.0. [Image description.]

Functions of the Cerebral Cortex

The cerebrum is the seat of many of the higher mental functions, such as memory and learning, language, and conscious perception, which are the subjects of subtests of the mental status exam. The cerebral cortex is the thin layer of gray matter on the outside of the cerebrum. It is approximately a millimeter thick in most regions and highly folded to fit within the limited space of the cranial vault. These higher functions are distributed across various regions of the cortex, and specific locations can be said to be responsible for particular functions. There is a limited set of regions, for example, that are involved in language function, and they can be subdivided on the basis of the particular part of language function that each governs.

Cognitive Abilities

Assessment of cerebral functions is directed at cognitive abilities. The abilities assessed through the mental status exam can be separated into four groups: orientation and memory, language and speech, sensorium, and judgment and abstract reasoning.

Orientation and Memory

Orientation is the patient's awareness of his or her immediate circumstances. It is awareness of time, not in terms of the clock but of the date and what is occurring around the patient. It is awareness of place, such that a patient should know where he or she is and why. It is also awareness of who the patient is—recognizing personal identity and being able to relate that to the examiner.

The initial tests of orientation are based on the questions, “Do you know what the date is?” or “Do you know where you are?” or “What is your name?” Further understanding of a patient’s awareness of orientation can come from questions that address remote memory, such as “Who is the President of the United States?”, or asking what happened on a specific date.

Memory is largely a function of the temporal lobe, along with structures beneath the cerebral cortex such as the hippocampus and the amygdala. The storage of memory requires these structures of the medial temporal lobe. A famous case of a man who had both medial temporal lobes removed to treat intractable epilepsy provided insight into the relationship between the structures of the brain and the function of memory.

The prefrontal cortex can also be tested for the ability to organize information. In one subtest of the mental status exam called set generation, the patient is asked to generate a list of words that all start with the same letter, but not to include proper nouns or names. The expectation is that a person can generate such a list of at least 10 words within 1 minute. Many people can likely do this much more quickly, but the standard separates the accepted normal from those with compromised prefrontal cortices.

Language and Speech

Language is, arguably, a very human aspect of neurological function. There are certainly strides being made in understanding communication in other species, but much of what makes the human experience seemingly unique is its basis in language. Any understanding of our species is necessarily reflective, as suggested by the question “What am I?” And the fundamental answer to this question is suggested by the famous quote by René Descartes, “Cogito Ergo Sum” (translated from Latin as “I think, therefore I am”). Formulating an understanding of yourself is largely describing who you are to yourself. It is a confusing topic to delve into, but language is certainly at the core of what it means to be self-aware.

The neurological exam has two specific subtests that address language. One measures the ability of the patient to understand language by asking them to follow a set of instructions to perform an action, such as “touch your right finger to your left elbow and then to your right knee.” Another subtest assesses the fluency and coherency of language by having the patient generate descriptions of objects or scenes depicted in drawings, and by reciting sentences or explaining a written passage.

An important example of multimodal integrative areas is associated with language function (see Figure 8.14). Adjacent to the auditory association cortex, at the end of the lateral sulcus just anterior to the visual cortex, is Wernicke’s area. In the lateral aspect of the frontal lobe, just anterior to the region of the motor cortex associated with the head and neck is Broca’s area. Both regions were originally described on the basis of losses of speech and language, which is called aphasia. The aphasia associated with Broca’s area is known as expressive aphasia, which means that speech production is compromised. This type of aphasia is often described as non-fluency because the ability to say some words leads to broken or halting speech. Grammar can also appear to be lost. The aphasia associated with Wernicke’s area is known as receptive aphasia, which is not a loss of speech production but a loss of understanding of content. Patients, after recovering from acute forms of this aphasia, report not being able to understand what is said to them or what they are saying themselves, but they often cannot keep from talking.

The two regions are connected by white matter tracts that run between the posterior temporal lobe and the lateral aspect of the frontal lobe. Conduction aphasia associated with damage to this connection refers to the problem of connecting the understanding of language to the production of speech. This is a very rare condition but is likely to present as an inability to faithfully repeat spoken language.

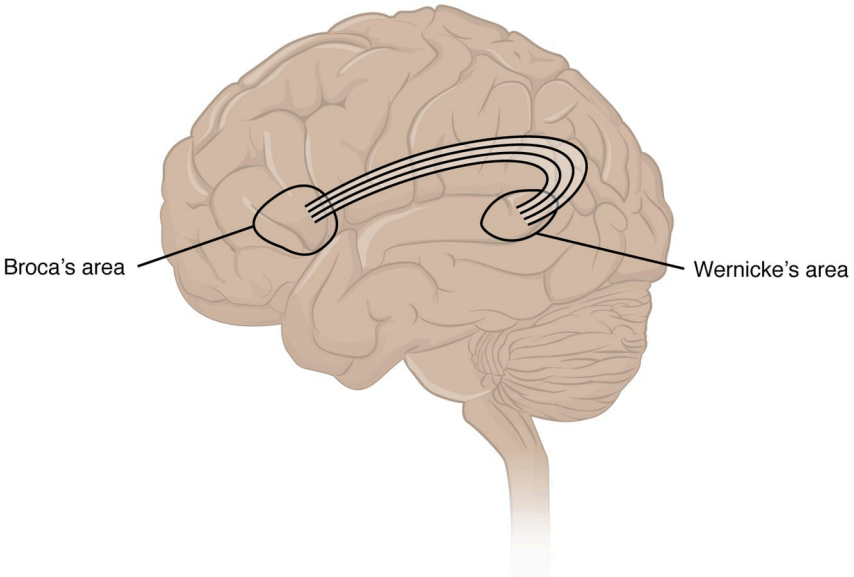

Figure 8.14 Broca's and Wernicke's Areas. Two important integration areas of the cerebral cortex associated with language function are Broca's and Wernicke's areas. The two areas are connected through the deep white matter running from the posterior temporal lobe to the frontal lobe. From Betts et al., 2013. Licensed under CC BY 4.0. [Image description.]

Sensorium

Those parts of the brain involved in the reception and interpretation of sensory stimuli are referred to collectively as the sensorium. The cerebral cortex has several regions that are necessary for sensory perception. Several of the subtests can reveal activity associated with these sensory modalities, such as being able to hear a question or see a picture. Two subtests assess specific functions of these cortical areas.

The first is praxis, a practical exercise in which the patient performs a task completely on the basis of verbal description without any demonstration from the examiner. The second subtest for sensory perception is gnosis, which involves two tasks. The first task, known as stereognosis, involves the naming of objects strictly on the basis of the somatosensory information that comes from manipulating them. The patient keeps their eyes closed and is given a common object, such as a coin, that they have to identify. The patient should be able to indicate the particular type of coin, such as a dime versus a penny, or a nickel versus a quarter, on the basis of the sensory cues involved. For example, the size, thickness, or weight of the coin may be an indication, or to differentiate the pairs of coins suggested here, the smooth or corrugated edge of the coin will correspond to the particular denomination. The second task, graphesthesia, is to recognize numbers or letters written on the palm with a dull pointer, such as a pen cap.

Judgment and Abstract Reasoning

Planning and producing responses requires an ability to make sense of the world around us. Making judgments and reasoning in the abstract are necessary to produce movements as part of larger responses. For example, when your alarm goes off, do you hit the snooze button or jump out of bed? Are 10 extra minutes in bed worth the extra rush to get ready for your day? Will hitting the snooze button multiple times lead to feeling more rested or result in a panic as you run late? How you mentally process these questions can affect your whole day.

The prefrontal cortex is responsible for the functions responsible for planning and making decisions. In the mental status exam, the subtest that assesses judgment and reasoning is directed at three aspects of frontal lobe function. First, the examiner asks questions about problem-solving, such as "If you see a house on fire, what would you do?" The patient is also asked to interpret common proverbs, such as "Don't look a gift horse in the mouth." Additionally, pairs of words are compared for similarities, such as apple and orange, or lamp and cabinet.

Everyday Connections

Left Brain, Right Brain

Popular media often refer to right-brained and left-brained people, as if the brain were two independent halves that work differently for different people. This is a popular misinterpretation of an important neurological phenomenon. As an extreme measure to deal with a debilitating condition, the corpus callosum may be sectioned to overcome intractable epilepsy. When the connections between the two cerebral hemispheres are cut, interesting effects can be observed.

The reason for this is that the language functions of the cerebral cortex are localized to the left hemisphere in 95% of the population. Additionally, the left hemisphere is connected to the right side of the body through the corticospinal tract and the ascending tracts of the spinal cord. Motor commands from the precentral gyrus control the opposite side of the body, whereas sensory information processed by the postcentral gyrus is received from the opposite side of the body. For a verbal command to initiate movement of the right arm and hand, the left side of the brain needs to be connected by the corpus callosum. Language is processed in the left side of the brain and directly influences the left brain and right arm motor functions but is sent to influence the right brain and left arm motor functions through the corpus callosum. Likewise, the left-handed sensory perception of what is in the left pocket travels across the corpus callosum from the right brain, so no verbal report on those contents would be possible if the hand happened to be in the pocket.

People who have had their corpus callosum cut can perform two independent tasks at the same time because the lines of communication between the right and left sides of their brains have been removed. Whereas a person with an intact corpus callosum cannot overcome the dominance of one hemisphere over the other, this patient can. If the left cerebral hemisphere is dominant in the majority of people, why would right-handedness be most common?

Common Abbreviations for the Nervous System

Query 1.8.4

This interactive element is not available in this format. Visit the link or scan the QR code to access it online.

View this Interactive Content online

Disease and Disorders

Neurodegenerative Diseases – Alzheimer's disease, Parkinson's disease, Amyotrophic Lateral Sclerosis (ALS), Multiple sclerosis (MS)

A class of disorders that affect the nervous system are the neurodegenerative diseases: Alzheimer's disease, Parkinson's disease, Huntington's disease, amyotrophic lateral sclerosis (ALS), Creutzfeldt–Jakob disease, multiple sclerosis (MS), and other disorders that are the result of nervous tissue degeneration. In diseases like Alzheimer's, Parkinson's, or ALS, neurons die; in diseases like MS, myelin is affected. Some of these disorders affect motor function, and others present with dementia. Some are the result of genetics, such as Huntington's disease, or the result of autoimmunity, such as MS; others are not entirely understood, such as Alzheimer's and Parkinson's diseases.

Several diseases can result from the demyelination of axons. The causes of these diseases are not the same; some have genetic causes, some are caused by pathogens, and others are the result of autoimmune disorders. Though the causes are varied, the results are largely similar. The myelin insulation of axons is compromised, making electrical signaling slower.

Multiple sclerosis (MS) is one such disease. It is an example of an autoimmune disease. The antibodies produced by lymphocytes (a type of white blood cell) mark myelin as something that should not be in the body. This causes inflammation

and the destruction of the myelin in the central nervous system. As the insulation around the axons is destroyed by the disease, scarring becomes obvious.

Guillain-Barre (pronounced gee-YAN bah-RAY) syndrome is an example of a demyelinating disease of the peripheral nervous system. It is also the result of an autoimmune reaction, but the inflammation is in peripheral nerves. Sensory symptoms or motor deficits are common, and autonomic failures can lead to changes in the heart rhythm or a drop in blood pressure, especially when standing, which causes dizziness.

Other Nerve Disorders

Infection, trauma, and congenital disorders can all lead to significant signs, as identified through the neurological exam. It is important to differentiate between an acute event, such as stroke, and a chronic or global condition such as blunt force trauma. Responses seen in the neurological exam can help. A loss of language function observed in all its aspects is more likely a global event as opposed to a discrete loss of one function, such as not being able to say certain types of words. A concern, however, is that a specific function—such as controlling the muscles of speech—may mask other language functions. The various subtests within the mental status exam can address these finer points and help clarify the underlying cause of the neurological loss.

Stroke

Damage to the nervous system can be limited to individual structures or can be distributed across broad areas of the brain and spinal cord. Localized, limited injury to the nervous system is most often the result of circulatory problems. The loss of blood flow to part of the brain is known as a **stroke**, or a **cerebrovascular accident (CVA)**. There are two main types of stroke, depending on how the blood supply is compromised: ischemic and hemorrhagic. An **ischemic stroke** is the loss of blood flow to an area because vessels are blocked or narrowed. This is often caused by an embolus, which may be a blood clot or fat deposit. Ischemia may also be the result of thickening of the blood vessel wall, or a drop in blood volume in the brain known as **hypovolemia**. A **hemorrhagic stroke** is bleeding into the brain because of a damaged blood vessel. Accumulated blood fills a region of the cranial vault and presses against the tissue in the brain (see Figure 8.15).

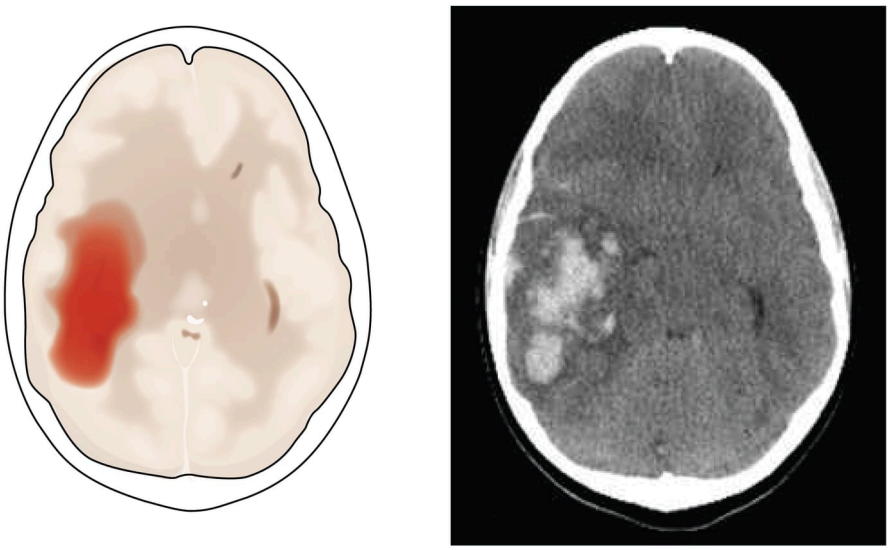

(a) (b)

Figure 8.15 Hemorrhagic Stroke. (a) A hemorrhage into the tissue of the cerebrum results in a large accumulation of blood with additional edema in the adjacent tissue. The hemorrhagic area causes the entire brain to be disfigured as suggested here by the lateral ventricles being squeezed into the opposite hemisphere. (b) A CT scan shows an intraparenchymal hemorrhage within the parietal lobe. (credit b: James Heilman). From Betts et al., 2013. Licensed under CC BY 4.0. [Image description.]

Cerebral Palsy

Cerebral palsy (CP) is caused by an interruption to the normal development of a person's brain, leading to weakness with muscles. Depending on the area of the brain that is affected, signs and symptoms will vary in the type and severity between individuals. Balance and coordination are often challenging due to the inability to control muscles (Centers for Disease Control

and Prevention, n.d.-a). To learn more about cerebral palsy, please visit the Centers for Disease Control and Prevention.

Traumatic Brain Injury (TBI)

According to the Centers for Disease Control and Prevention, about 166 people in the United States died each day from a traumatic brain injury in 2019. Brain injuries range from mild to severe and include concussions. TBI can be caused by falls, automobile accidents, assaults, and firearm-related suicide (Centers for Disease Control and Prevention, n.d.-b). To learn more about TBI, please visit the Centers for Disease Control and Prevention.

Practice Medical Terms in Context

Query 1.8.5

This interactive element is not available in this format. Visit the link or scan the QR code to access it online.

View this Interactive Content online

Query 1.8.6

This interactive element is not available in this format. Visit the link or scan the QR code to access it online.

View this Interactive Content online

Query 1.8.7

This interactive element is not available in this format. Visit the link or scan the QR code to access it online.

View this Interactive Content online

Medical Specialties

Neurologist

Neurologists are medical doctors who complete specialized training in the prevention, diagnosis, and treatment of disorders and conditions related to the brain and nervous system (Bureau of Labor Statistics, 2021). For more details visit the American Academy of Neurology.

Procedures Related to the Nervous System

Lumbar Puncture

A lumbar puncture is a procedure in which cerebrospinal fluid (CSF) is withdrawn from the lumbar region of the spinal column. This procedure can be used to diagnose and monitor certain infections, such as meningitis, administer drugs, or reduce spinal fluid pressure (Betts et al., 2013; ClinicalInfo, n.d.).

Electromyography (EMG)

Electromyography (EMG) is a procedure that assesses the electrical signals muscles send while at rest and when they are used. During the test, a needle electrode is placed into the muscle, and a machine records the muscle activity. EMG can be used to diagnose myasthenia gravis, muscular dystrophy, and other conditions affecting the muscles (MedlinePlus, 2021a). To learn more, please visit the Medline Plus web page on electromyography.

Electroencephalogram (EEG)

With electrodes applied to your scalp, an electroencephalogram (EEG) measures electrical activity in the brain. It's used to help diagnose conditions of the brain, including seizures, altered mental status, and hemorrhage. (Rayi & Murr, 2021). For more information, please visit the Mayo Clinic's web page on electroencephalograms.

Practice Terms Related to the Nervous System

Query 1.8.8

This interactive element is not available in this format. Visit the link or scan the QR code to access it online.

View this Interactive Content online

Nervous System Vocabulary

Afferent nerves: Nerves that carry sensory signals (nerve impulses) toward the central nervous from the periphery.

Aphasia: Loss of language function.

Arachnoid mater: Middle layer of the meninges named for the spider-web–like trabeculae that extend between it and the pia mater.

Astrocyte: Glial cell type of the central nervous system that provides support for neurons and maintains the blood-brain barrier.

Autonomic nervous system (ANS): Functional division of the nervous system that is responsible for homeostatic reflexes that coordinate control of cardiac and smooth muscle, as well as glandular tissue.

Axon: Single process of the neuron that carries an electrical signal (action potential) away from the cell body toward a target cell.

Axon hillock: Tapering of the neuron cell body that gives rise to the axon.

Axon segment: Single stretch of the axon insulated by myelin and bounded by nodes of Ranvier at either end (except for the first, which is after the initial segment, and the last, which is followed by the axon terminal).

Axon terminal: End of the axon, where there are usually several branches extending toward the target cell.

Axoplasm: Cytoplasm of an axon, which is different in composition than the cytoplasm of the neuronal cell body.

Babinski sign: Dorsiflexion of the foot with extension and splaying of the toes in response to the plantar reflex, normally suppressed by corticospinal input.

Bipolar: Shape of a neuron with two processes extending from the neuron cell body—the axon and one dendrite.

Blood-brain barrier (BBB): Physiological barrier between the circulatory system and the central nervous system that establishes a privileged blood supply, restricting the flow of substances into the central nervous system.

Brain: The large organ of the central nervous system composed of white and gray matter, contained within the cranium and continuous with the spinal cord.

Brain stem: Region of the adult brain that includes the midbrain, pons, and medulla oblongata and develops from the mesencephalon, metencephalon, and myelencephalon of the embryonic brain.

Broca's area: Region of the frontal lobe associated with the motor commands necessary for speech production.

Brodmann's areas: Mapping of regions of the cerebral cortex based on microscopic anatomy that relates specific areas to functional differences, as described by Brodmann in the early 1900s.

Cauda equina: Bundle of spinal nerve roots that descend from the lower spinal cord below the first lumbar vertebra and lie within the vertebral cavity; has the appearance of a horse's tail.

Caudate: Nucleus deep in the cerebrum that is part of the basal nuclei; along with the putamen, it is part of the striatum.

Central nervous system (CNS): Anatomical division of the nervous system located within the cranial and vertebral cavities, namely the brain and spinal cord.

Central sulcus: Surface landmark of the cerebral cortex that marks the boundary between the frontal and parietal lobes.

Cephalgia: Pain in the head.

Cerebellum: Region of the adult brain connected primarily to the pons that developed from the metencephalon (along with the pons) and is largely responsible for comparing information from the cerebrum with sensory feedback from the periphery through the spinal cord.

Cerebral angiography: Process of recording the blood vessels of the cerebrum.

Cerebral cortex: Outer gray matter covering the forebrain, marked by wrinkles and folds known as gyri and sulci.

Cerebrum: Region of the adult brain that develops from the telencephalon and is responsible for higher neurological functions such as memory, emotion, and consciousness.

Cerebral hemisphere: One half of the bilaterally symmetrical cerebrum.

Cerebrospinal fluid (CSF): A colorless fluid produced by the brain that cushions the brain and spinal cord within the posterior (dorsal) cavity.

Cerebral thrombosis: Formation of a blood clot in a blood vessel within the skull.

Choroid plexus: Specialized structure containing ependymal cells that line blood capillaries and filter blood to produce cerebrospinal fluid in the four ventricles of the brain.

Corpus callosum: Large white matter structure that connects the right and left cerebral hemispheres.

Dendrite: One of many branchlike processes that extends from the neuron cell body and functions as a contact for incoming signals (synapses) from other neurons or sensory cells.

Descending tract: Central nervous system fibers carrying motor commands from the brain to the spinal cord or periphery.

Diencephalon: Region of the adult brain that retains its name from embryonic development and includes the thalamus and hypothalamus.

Direct pathway: Connections within the basal nuclei from the striatum to the globus pallidus internal segment and substantia nigra pars reticulata that disinhibit the thalamus to increase cortical control of movement.

Dorsal (posterior) nerve root: Axons entering the posterior horn of the spinal cord.

Dura mater: Tough, fibrous, outer layer of the meninges that is attached to the inner surface of the cranium and vertebral column and surrounds the entire central nervous system.

Efferent nerves: Nerve tissue that carries impulses away from the CNS towards the peripheral that result in motor response (movement).

Electroencephalogram: The record of electrical activity of the brain.

Electroencephalography: Process of recording the electrical activity of the brain.

Embolus: An obstruction such as a blood clot or plaque that blocks the flow of blood in an artery or vein.

Encephalitis: Inflammation of the tissues of the brain.

Encephalomalacia: Softening of the tissues of the brain.

Enteric nervous system (ENS): Neural tissue associated with the digestive system that is responsible for nervous control through autonomic connections.

Ependymal cell: Glial cell type in the central nervous system responsible for producing cerebrospinal fluid.

Epithalamus: Region of the diencephalon containing the pineal gland.

Foramen magnum: Large opening in the occipital bone of the skull through which the spinal cord emerges and the vertebral arteries enter the cranium.

Frontal lobe: Region of the cerebral cortex directly beneath the frontal bone of the cranium.

Ganglion: Localized collection of neuron cell bodies in the peripheral nervous system.

Ganglionectomy: Excision of a ganglion.

Glial cell: One of the various types of neural tissue cells responsible for maintenance of the tissue, and largely responsible for supporting neurons.

Glioblastoma: A central nervous system tumor composed of developing glial tissue.

Glioma: A tumor that begins in the glial tissue.

Gray matter: Regions of the nervous system containing cell bodies of neurons with few or no myelinated axons; actually may be more pink or tan in color, but called gray in contrast to white matter.

Gyrus: Ridge formed by convolutions on the surface of the cerebrum or cerebellum.

Hemiplegia: Paralysis on one side of the body.

Hemorrhagic stroke: Disruption of blood flow to the brain caused by bleeding within the cranial vault.

Hydrocephalus: The abnormal buildup of cerebrospinal fluid in the ventricles of the brain.

Hyperesthesia: Increased sensitivity to stimuli.

Hypothalamus: A region of the forebrain below the thalamus; has function in both the autonomic and endocrine systems and

regulates homeostasis.

Ischemic stroke: Disruption of blood flow to the brain because blood cannot flow through blood vessels as a result of a blockage or narrowing of the vessel.

Integration: Nervous system function that combines sensory perceptions and higher cognitive functions (memories, learning, emotion, etc.) to produce a response.

Initial segment: First part of the axon as it emerges from the axon hillock, where the electrical signals known as action potentials are generated.

Longitudinal fissure: A large separation along the midline between the two cerebral hemispheres.

Lumbar puncture: Procedure used to withdraw cerebrospinal fluid from the lower lumbar region of the vertebral column.

Medulla oblongata: A part of the brain stem responsible for control of heart rate and breathing.

Meninges: The membranes that surround the central nervous system.

Meningioma: A tumor of the meninges.

Meningitis: Inflammation of the meninges, the tough membranes that surround the central nervous system.

Meningocele: Protrusion of the meninges.

Meningomyelocele: Protrusion of the meninges and spinal cord.

Microglia: Smaller than most of the other glial cells; they ingest and digest cells or pathogens that cause disease.

Midbrain: A portion of the brainstem, positioned above the pons, also called mesencephalon, that assists in motor reflexes associated with visual, auditory, and somatosensory stimuli.

Mononeuropathy: Disease affecting a single peripheral nerve.

Motor nerves: Peripheral, efferent, myelinated nerve tissue that stimulates muscle contraction.

Multipolar: Shape of a neuron that has multiple processes—the axon and two or more dendrites.

Myelin sheath: Lipid-rich layer of insulation that surrounds an axon, formed by oligodendrocytes in the central nervous system and Schwann cells in the peripheral nervous system; facilitates the transmission of electrical signals.

Nerves: Bundle of fibers that receives and sends messages between the body and the brain.

Neuralgia: Pain of the peripheral or cranial nerves.

Neuritis: Inflammation of a peripheral or cranial nerve.

Neuroglia: Supportive tissue of the nervous system, including the network of branched cells in the central nervous system (astrocytes, microglia, and oligodendrocytes) and the supporting cells of the peripheral nervous system (Schwann cells and satellite cells), also called glia.

Neurologist: A doctor who has special training in diagnosing and treating disorders of the nervous system.

Neurology: A medical specialty concerned with the study of the structures, functions, and diseases of the nervous system.

Neuroma: Tumor made up of nerve cells.

Neuron: Cells that propagate information via electrochemical impulses.

Neuropathy: A nerve problem that causes pain, numbness, tingling, swelling, or muscle weakness in different parts of the body.

Neurotransmitters: Chemicals that are made by nerve cells and used to communicate with other cells, including other nerve cells and muscle cells.

Node of Ranvier: Gap between two myelinated regions of an axon, allowing for strengthening of the electrical signal as it propagates down the axon.

Nucleus: The cell's central organelle, which contains the cell's DNA.

Occipital lobe: Region of the cerebral cortex directly beneath the occipital bone of the cranium.

Olfaction: The sense of smell.

Oligodendrocyte: Glial cell type in the central nervous system that provides the myelin insulation for axons in tracts.

Paresis: Partial paralysis wherein there is still some control of the muscles.

Paresthesia: Abnormal sensation in the extremities.

Parietal lobe: Region of the cerebral cortex directly beneath the parietal bone of the cranium.

Peripheral nervous system (PNS): All nervous tissue that is outside of the brain and spinal cord.

Pia mater: Thin, innermost membrane of the meninges that directly covers the surface of the central nervous system.

Poliomyelitis: Acute infection by the poliovirus, especially of the motor neurons in the spinal cord and brainstem.

Polyneuritis: Inflammation of several peripheral nerves at the same time.

Polyneuropathy: Disease of multiple peripheral nerves at the same time.

Pons: The main connection between the cerebellum and the brain stem. It is responsible for regulating several crucial functions, including the cardiovascular and respiratory systems.

Process: In cells, an extension of a cell body; in the case of neurons, this includes the axon and dendrites.

Psychiatrist: A medical doctor who specializes in neuroscience and diagnoses and treats mental disorders.

Psychiatry: The medical science that deals with the origin, diagnosis, prevention, and treatment of mental disorders.

Psychologist: A specialist who can talk with patients and their families about emotional and personal matters.

Psychology: The study of how the mind works and how thoughts and feelings affect behavior.

Psychosis: A severe mental disorder in which a person loses the ability to recognize reality or relate to others.

Quadriplegia: Paralysis of all four limbs.

Radiculopathy: Disease of the nerve roots.

Response: Nervous system function that causes a target tissue (muscle or gland) to produce an event as a consequence to stimuli.

Rhizotomy: Incision into a nerve root.

Satellite cell: Glial cell type in the peripheral nervous system that provides support for neurons in the ganglia.

Schwann cell: Glial cell type in the peripheral nervous system that provides the myelin insulation for axons in nerves.

Sensation: Nervous system function that receives information from the environment and translates it into the electrical signals of nervous tissue.

Soma: In neurons, that portion of the cell that contains the nucleus; the cell body, as opposed to the cell processes (axons and dendrites).

Somatic nervous system (SNS): Functional division of the nervous system that is concerned with conscious perception, voluntary movement, and skeletal muscle reflexes.

Spinal cord: Organ of the central nervous system found within the vertebral cavity and connected with the periphery through spinal nerves; mediates reflex behaviors.

Stimulus: An event in the external or internal environment that registers as activity in a sensory neuron.

Stroke: Loss of neurological function caused by an interruption of blood flow to a region of the central nervous system, also called cerebrovascular accident (CVA).

Subarachnoid space: Space between the arachnoid mater and pia mater that contains CSF and the fibrous connections of the arachnoid trabeculae.

Subdural hematoma: Accumulation of blood in the subdural space.

Sulcus: Groove formed by convolutions in the surface of the cerebral cortex.

Synapse: Narrow junction across which a chemical signal passes from neuron to the next, initiating a new electrical signal in the target cell.

Synaptic end bulb: Swelling at the end of an axon where neurotransmitter molecules are released onto a target cell across a synapse.

Sympathetic nervous system (SNS): The division of the nervous system involved in our fight-or-flight responses. It continuously monitors body temperature and initiates appropriate motor responses.

Temporal lobe: Region of the cerebral cortex directly beneath the temporal bone of the cranium.

Thalamus: Major region of the diencephalon that is responsible for relaying information between the cerebrum and the hindbrain, spinal cord, and periphery.

Tract: Bundle of axons in the central nervous system having the same function and point of origin.

Transient ischemic attack (TIA): Temporary disruption of blood flow to the brain in which symptoms occur rapidly but last only a short time.

Unipolar: Shape of a neuron which has only one process that includes both the axon and dendrite.

Ventricle: Central cavity within the brain where cerebrospinal fluid is produced and circulates.

Wernicke's area: Region at the posterior end of the lateral sulcus in which speech comprehension is localized.

White matter: Regions of the nervous system containing mostly myelinated axons, making the tissue appear white because of the high lipid content of myelin.

Test Yourself

Query 1.8.9

This interactive element is not available in this format. Visit the link or scan the QR code to access it online.

View this Interactive Content online

References

Bureau of Labor Statistics. (2021). Physicians and surgeons. In *Occupational outlook handbook*. U.S. Department of Labor. https://www.bls.gov/ooh/healthcare/physicians-and-surgeons.htm

Centers for Disease Control and Prevention. (n.d.-a). *What is cerebral palsy?* https://www.cdc.gov/ncbddd/cp/facts.html

Centers for Disease Control and Prevention. (n.d.-b). *Get the facts about TBI*. https://www.cdc.gov/traumaticbraininjury/get_the_facts.html

ClinicalInfo. (n.d.). *Spinal tap*. National Institute of Health Office of AIDS Research, U.S. Department of Health and Human Services. https://clinicalinfo.hiv.gov/en/glossary/spinal-tap

CrashCourse. (2015, February 23). *The nervous system, part 1: Crash course A&P #8* [Video]. YouTube. https://www.youtube.com/watch?v=qPix_X-9t7E

MedlinePlus. (2021a). *Electromyography (EMG) and nerve conduction studies*. U.S. Library of Medicine, U.S. Department of Health and Human Services. https://medlineplus.gov/lab-tests/electromyography-emg-and-nerve-conduction-studies

Rayi, A., & Murr, N. (2021). Electroencephalogram. In *StatPearls [Internet]*. https://www.ncbi.nlm.nih.gov/books/NBK563295/

Image Descriptions

Figure 8.1 image description: This diagram shows a silhouette of a human highlighting the nervous system. The central nervous system is composed of the brain and spinal cord. The brain is a large mass of ridged and striated tissue within the head. The spinal cord extends down from the brain and travels through the torso, ending in the pelvis. Pairs of enlarged nervous tissue, labeled ganglia, flank the spinal cord as it travels through the rib area. The ganglia are part of the peripheral nervous system, along with the many thread-like nerves that radiate from the spinal cord and ganglia through the arms, abdomen, and legs. [Return to Figure 8.1].

Figure 8.2 image description: This photo shows an enlarged view of the dorsal side of a human brain. The right side of the occipital lobe has been shaved to reveal the white and gray matter beneath the surface blood vessels. The white matter branches through the shaved section like the limbs of a tree. The gray matter branches and curves on the outside of the white matter, creating a buffer between the outer edges of the occipital lobe and the internal white matter. [Return to Figure 8.2].

Figure 8.3 image description: This figure shows the lateral view on the left panel and the anterior view on the right panel of the brain. The major parts including the cerebrum are labeled. Lateral view labels (clockwise from top) read: cerebrum, cerebral cortex, corpus callosum (located on the interior of the brain). Anterior view labels indicate the right and left hemispheres and the longitudinal fissure between them. [Return to Figure 8.3].

Figure 8.4 image description: This figure shows the lateral view of the brain and the major lobes are labeled. From the front of the brain (left) labels read: frontal lobe, precentral gyrus, central sulcus, postcentral gyrus, parietal lobe, lateral sulcus, occipital lobe, temporal lobe. [Return to Figure 8.4].

Figure 8.5 image description: This figure shows the location of the thalamus, hypothalamus, and pituitary gland in the brain.

Each part is labeled respectively. The thalamus is located in the midsection of the brain. The hypothalamus is located below the thalamus and the pituitary gland below that. [Return to Figure 8.5].

Figure 8.6 image description: This figure shows the location of the midbrain, pons, and the medulla in the brain that make up the brainstem. The midbrain is located at the top, the pons is located beneath that, and the medulla is the lowest most point of the brain stem. [Return to Figure 8.6].

Figure 8.7 image description: This figure shows the location of the cerebellum in the brain which is located on the posterior surface of the brain stem. Labels read (top, left): pons, inferior olive, (top, right) cerebellum, deep cerebellar white matter (arbor vitae). In the top panel, a lateral view labels the location of the cerebellum and the deep cerebellar white matter. In the bottom panel, a photograph of a brain, with the cerebellum in pink is shown. [Return to Figure 8.7].

Figure 8.8 image description: This illustration shows the anatomy of a neuron. The neuron has a very irregular cell body (soma) containing a purple nucleus. There are six projections protruding from the top, bottom, and left sides of the cell body. Each of the projections branches many times, forming small, tree-shaped structures protruding from the cell body. The right side of the cell body tapers into a long cord called the axon. The axon is insulated by segments of myelin sheath, which resemble a semitransparent toilet paper roll wound around the axon. The myelin sheath is not continuous but is separated into equally spaced segments. The bare axon segments between the sheath segments are called nodes of Ranvier. An oligodendrocyte is reaching its two arm-like projections onto two myelin sheath segments. The axon branches many times at its end, where it connects to the dendrites of another neuron. Each connection between an axon branch and a dendrite is called a synapse. The cell membrane completely surrounds the cell body, dendrites, and axon. The axon of another nerve is seen in the upper left of the diagram connecting with the dendrites of the central neuron. [Return to Figure 8.8].

Figure 8.9 image description: Three illustrations show some of the possible shapes that neurons can take. In the unipolar neuron, the dendrite enters from the left and merges with the axon into a common pathway, which is connected to the cell body. The axon leaves the cell body through the common pathway, the branches off to the right, in the opposite direction as the dendrite. Therefore, this neuron is T-shaped. In the bipolar neuron, the dendrite enters into the left side of the cell body while the axon emerges from the opposite (right) side. In a multipolar neuron, multiple dendrites enter the cell body. The only part of the cell body that does not have dendrites is the part that elongates into the axon. [Return to Figure 8.9].

Figure 8.10 image description: This diagram contains three black and white drawings of more specialized nerve cells. Part A shows a pyramidal cell of the cerebral cortex, which has two, long, nerve tracts attached to the top and bottom of the cell body. However, the cell body also has many short dendrites projecting out a short distance from the cell body. Part B shows a Purkinje cell of the cerebellar cortex. This cell has a single, long, nerve tract entering the bottom of the cell body. Two large nerve tracts leave the top of the cell body but immediately branch many times to form a large web of nerve fibers. Therefore, the Purkinje cell somewhat resembles a shrub or coral in shape. Part C shows the olfactory cells in the olfactory epithelium and olfactory bulbs. It contains several cell groups linked together. At the bottom, there is a row of olfactory epithelial cells that are tightly packed, side-by-side, somewhat resembling the slats on a fence. There are six neurons embedded in this epithelium. Each neuron connects to the epithelium through branching nerve fibers projecting from the bottom of their cell bodies. A single nerve fiber projects from the top of each neuron and synapses with nerve fibers from the neurons above. These upper neurons are cross-shaped, with one nerve fiber projecting from the bottom, top, right and left sides. The upper cells synapse with the epithelial nerve cells using the nerve tract projecting from the bottom of their cell body. The nerve tract projecting from the top continues the pathway, making a ninety-degree turn to the right and continuing to the right border of the image. [Return to Figure 8.10].

Figure 8.11 image description: This diagram shows several types of nervous system cells associated with two multipolar neurons. Astrocytes are star shaped-cells with many dendrite-like projections but no axon. They are connected with the multipolar neurons and other cells in the diagram through their dendrite-like projections. Ependymal cells have a teardrop-shaped cell body and a long tail that branches several times before connecting with astrocytes and the multipolar neuron. Microglial cells are small cells with rectangular bodies and many dendrite-like projections stemming from their shorter sides. The projections are so extensive that they give the microglial cell a fuzzy appearance. The oligodendrocytes have circular cell bodies with four dendrite-like projections. Each projection is connected to a segment of myelin sheath on the axons of the multipolar neurons. The oligodendrocytes are the same color as the myelin sheath segment and are adding layers to the sheath using their projections. [Return to Figure 8.11].

Figure 8.12 image description: This diagram shows a collection of PNS glial cells. The largest cell is a unipolar peripheral ganglionic neuron which has a common nerve tract projecting from the bottom of its cell body. The common nerve tract then splits into the axon, going off to the left, and the dendrite, going off to the right. The cell body of the neuron is covered with several satellite cells that are irregular, flattened, and take on the appearance of fried eggs. Schwann cells wrap around each myelin sheath segment on the axon, with their nucleus creating a small bump on each segment. [Return to Figure 8.12].

Figure 8.13 image description: A silhouette of a human with only the brain, spinal cord, PNS ganglia, nerves, and a section of the digestive tract visible. The brain, which is part of the CNS, is the area of perception and processing of sensory stimuli (somatic/autonomic), the execution of voluntary motor responses (somatic), and the regulation of homeostatic mechanisms (autonomic). The spinal cord, which is part of the CNS, is the area where reflexes are initiated. The gray matter of the ventral horn initiates somatic reflexes while the gray matter of the lateral horn initiates autonomic reflexes. The spinal cord is also the somatic and autonomic pathway for sensory and motor functions between the PNS and the brain. The nerves, which are part of the PNS, are the fibers of sensory and motor neurons, which can be either somatic or autonomic. The ganglia, which are part of the PNS, are the areas for the reception of somatic and autonomic sensory stimuli. These are received by the dorsal root ganglia and cranial ganglia. The autonomic ganglia are also the relay for visceral motor responses. The digestive tract is part of the enteric nervous system, the ENS, which is located in the digestive tract and is responsible for the autonomous function. The ENS can operate independently of the brain and spinal cord. [Return to Figure 8.13].

Figure 8.14 image description: An illustration of the brain with Broca's area and Wernicke's area identified. Broca's area is located in the lateral aspect of the frontal lobe. Wernicke's area is found at the end of the lateral sulcus just anterior to the visual cortex. The two are connected by white matter tracts between the posterior temporal love and lateral aspect of the frontal lobe. Both areas are associated with the loss of speech and language. Expressive aphasia is associated with Broca's area. Receptive aphasia is associated with Wernicke's area. [Return to Figure 8.14].

Figure 8.15 image description: The left panel of this figure shows an image of the brain with a region in red. This red region indicates a hemorrhage associated with a stroke. The right panel shows a hemorrhage as it might appear on a CT scan. [Return to Figure 8.15].

Unless otherwise indicated, this chapter contains material adapted from *Anatomy and Physiology* (on OpenStax), by Betts et al. and is used under a CC BY 4.0 international license. Download and access this book for free at https://openstax.org/books/anatomy-and-physiology/pages/1-introduction.

This page titled 1.8: Nervous System is shared under a CC BY 4.0 license and was authored, remixed, and/or curated by Andrea Nelson and Katherine Greene via source content that was edited to the style and standards of the LibreTexts platform.

1.9: Cardiovascular System

Learning Objectives

- Examine the anatomy of the heart
- Determine the main functions of the cardiovascular system
- Differentiate cardiovascular system medical terms and common abbreviations
- Recognize the medical specialties associated with the cardiovascular system
- Discover common diseases, disorders, and procedures related to the cardiovascular system

Cardiovascular System Word Parts

Click on prefixes, combining forms, and suffixes to reveal a list of word parts to memorize for the cardiovascular system.

Query 1.9.1

This interactive element is not available in this format. Visit the link or scan the QR code to access it online.

View this Interactive Content online

Introduction to the Cardiovascular System

The cardiovascular system is made of three components: the heart, vessels, and blood. The heart is a fist-sized vital organ that has *one* job: to pump blood. If one assumes an average heart rate of 75 beats per minute, a human heart would beat approximately 108,000 times in one day, more than 39 million times in one year, and nearly 3 billion times during a 75-year lifespan. At rest, each of the major pumping chambers of the heart ejects approximately 70 mL of blood per contraction in an adult. This would be equal to 5.25 liters of blood per minute and approximately 14,000 liters per day. Over one year, that would equal 10,000,000 liters of blood sent through roughly 100,000 km of blood vessels. In order to understand how that happens, it is necessary to understand the anatomy and physiology of the heart.

Watch this video:

YouTube Video

This interactive element is not available in this format. Visit the link or scan the QR code to access it online.

View this YouTube Video online

Media 9.1. The Heart, Part 1 – Under Pressure: Crash Course A&P #25 [Online video]. Copyright 2015 by CrashCourse.

Practice Medical Terms Related to the Cardiovascular System

Query 1.9.2

This interactive element is not available in this format. Visit the link or scan the QR code to access it online.

View this Interactive Content online

Anatomy of the Heart

Location

The human heart is located within the thoracic cavity, between the lungs in the space known as the **mediastinum**. Figure 9.1 shows the position of the heart within the thoracic cavity. Within the mediastinum, the heart is separated from the other mediastinal structures by a tough membrane known as the pericardium, or pericardial sac, and sits in its own space called the **pericardial cavity**. The great vessels, which carry blood to and from the heart, are attached to the superior surface of the heart, which is called the base. The base of the heart is located at the level of the third costal cartilage. The inferior tip of the heart, the apex, lies just to the left of the sternum between the junction of the fourth and fifth ribs.

Concept Check

- On the diagram below (Figure 1), locate the **mediastinum**, the **pericardial cavity**, the **base** of the heart and the **apex** of the heart.
- Locate the largest vein in the body, the **superior vena cava**.

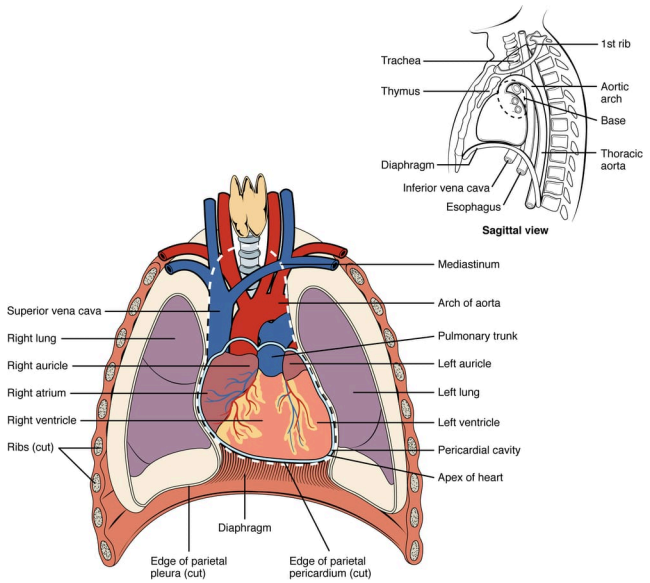

Figure 9.1. Position of the Heart in the Thorax. The heart is located within the thoracic cavity, medially between the lungs in the mediastinum. It is about the size of a fist, is broad at the top, and tapers toward the base. From Betts et al., 2013. Licensed under CC BY 4.0. [Image description.]

Membranes and Layers of the Heart Walls

The heart and the roots of the great vessels are surrounded by a membrane known as the **pericardium** or **pericardial sac**. The pericardium consists of two distinct sub layers:

- The sturdy outer fibrous pericardium is made of tough, dense connective tissue that protects the heart and holds it in position.
- Separated by the **pericardial cavity** and containing pericardial fluid the inner serous pericardium consists of two layers:
  - the outer **parietal pericardium**, which is fused to the fibrous pericardium.
  - the inner **visceral pericardium**, or **epicardium**, which is fused to the heart and forms the outer layer of the heart wall.

The walls of the heart consist of three layers:

- The outer **epicardium**, which is another name for the visceral pericardium mentioned above.
- The thick, middle **myocardium**, which is made of muscle tissue and gives the heart its ability to contract.
- The inner **endocardium**, which lines the heart chambers and is the main component of the heart valves.

Concept Check

- Look at Figure 9.2 below, and name the layers of the heart wall and surrounding membranes, starting with the innermost layer.
- As shown on the diagram, suggest why the **myocardium** layer is thicker than the **endocardium** layer.

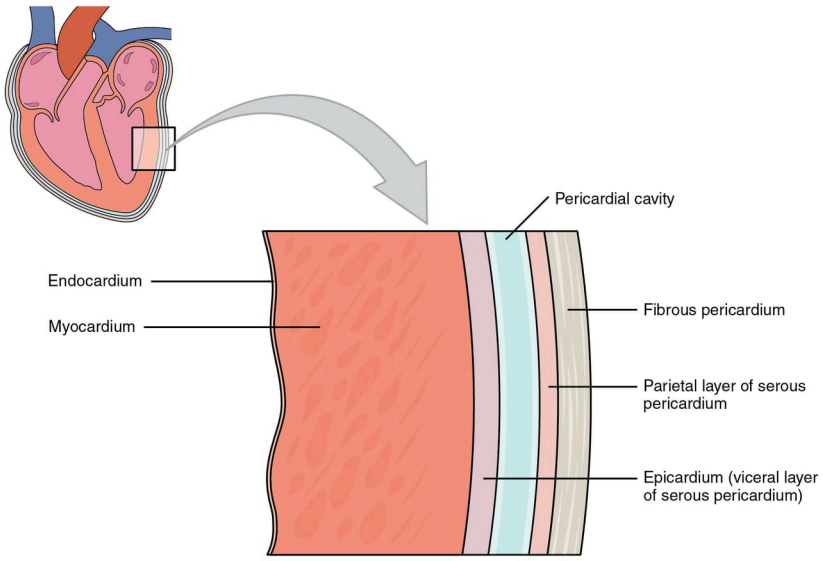

Figure 9.2. Pericardial Membranes and Layers of the Heart Wall. The pericardial membrane that surrounds the heart consists of three layers and the pericardial cavity. The heart wall also consists of three layers. The pericardial membrane and the heart wall share the epicardium From Betts et al., 2013. Licensed under CC BY 4.0. [Image description.]

Internal Structures of the Heart

The heart consists of four chambers:

- The upper chambers are the right and left **atria** (singular: atrium).
- The lower chambers are the right and left **ventricles.**

The **interventricular septum** is a muscular wall that separates the right and left ventricles. The interatrial septum separates the right and left atria.

The atrium and ventricle on each side of the heart are separated by an atrioventricular (AV) valve:

- The right AV valve, or **tricuspid valve,** separates the right atrium and right ventricle.
- The left AV valve, or **bicuspid valve,** separates the left ventricle and the left atrium. This valve is also called the **mitral valve.**

There are also two semilunar valves:

- The **pulmonary valve** separates the right ventricle from the pulmonary trunk.
- The **aortic valve** separates the left ventricle from the aorta.

Anatomy Labeling Activity

Query 1.9.3

This interactive element is not available in this format. Visit the link or scan the QR code to access it online.

View this Interactive Content online

Physiology of the Heart

In order for the heart to do its job of pumping blood to the lungs and the body, nutrients and oxygen must be supplied to the cells of the heart. The heart also needs to coordinate its contractions so that all parts are working together to pump blood effectively. To understand how all of this works together to give the heart its ability to pump blood, we will examine three interdependent aspects of heart function.

1. Circulation through the heart: Blood is pumped by the heart in order to provide oxygen and nutrients to every cell in the body.
2. The heart as an organ (coronary blood supply): The heart is an organ, made of cells and tissues which require their own blood supply.
3. The heart's electrical conduction system: The heart is able to independently generate and transmit instructions to the myocardium in order to make it contract and pump the blood.

1. Circulation Through the Heart: The Heart as a Pump

The heart pumps blood to two distinct but linked circulatory systems called the pulmonary and systemic circuits. The **pulmonary circuit** transports blood to and from the lungs, where it picks up oxygen and drops off carbon dioxide. The **systemic circuit** transports freshly oxygenated blood to virtually all of the tissues of the body and returns relatively deoxygenated blood and carbon dioxide to the heart to be sent back to the pulmonary circulation.

1. Blood that is carrying carbon dioxide and waste products from the body tissues is returned to the **right atrium** via the superior vena cava and the inferior vena cava.
2. From the right atrium, the deoxygenated blood moves through the **tricuspid valve** into the right ventricle.
3. The **right ventricle** pumps deoxygenated blood through the **pulmonary valve** into the **pulmonary trunk**, which splits into the **right and left pulmonary arteries**, leading toward the lungs. These arteries branch many times before reaching the **pulmonary capillaries**, where gas exchange occurs: carbon dioxide exits the blood, and oxygen enters. The pulmonary arteries are the only arteries in the postnatal body that carries deoxygenated blood. Did you notice that they are often colored blue on diagrams of the heart?
4. Freshly oxygenated blood returns from the lungs to the **left atrium** via the **pulmonary veins**. These veins are the only postnatal veins in the body that carry highly oxygenated blood and are often colored red on heart images.
5. From the left atrium, the blood moves through the **mitral valve** into the **left ventricle.**
6. The left ventricle pumps blood through the **aortic valve**, into the **aorta**, delivering blood to all parts of the body.

Did you know?

The heart sounds heard through a stethoscope are the sounds of the four heart valves opening and closing at specific times during one cardiac cycle.

Concept Check

- On Figure 9.3 below, use your finger to trace the pathway of blood flowing through the right side of the heart, naming each of the following structures as you encounter them: Superior and inferior venae cavae, right atrium, tricuspid valve, right ventricle, pulmonary valve, right and left pulmonary arteries.
- Suggest what would happen if the **aorta** experienced a blockage or constriction.

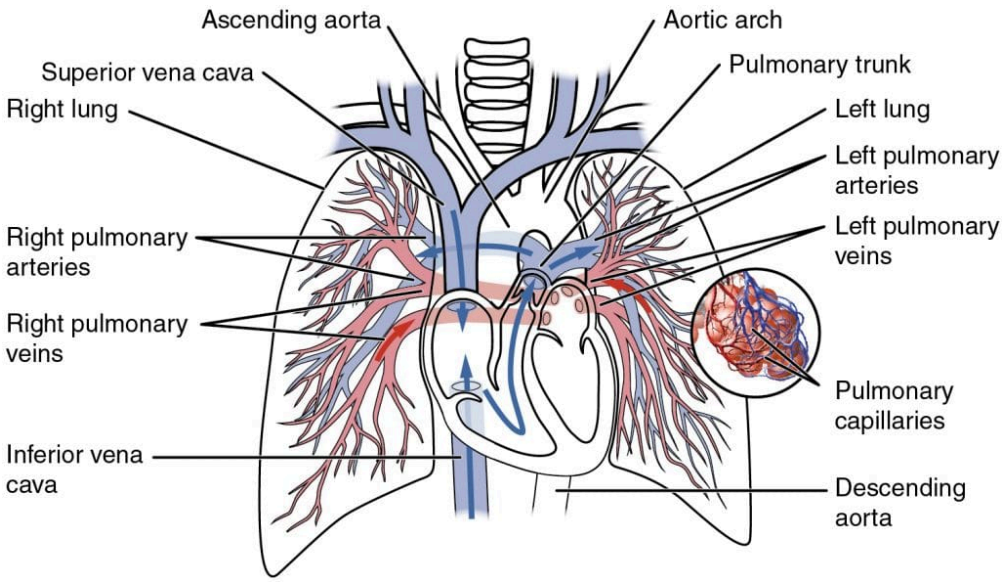

Figure 9.3. Pulmonary Circuit Blood exiting from the right ventricle flows into the pulmonary trunk, which bifurcates into the two pulmonary arteries. These vessels branch to supply blood to the pulmonary capillaries, where gas exchange occurs within the lung alveoli. Blood returns via the pulmonary veins to the left atrium. From Betts et al., 2013. Licensed under CC BY 4.0. [Image description.]

Pulmonary Circuit

Blood exiting from the right ventricle flows into the pulmonary trunk, which bifurcates into the two pulmonary arteries. These vessels branch to supply blood to the pulmonary capillaries, where gas exchange occurs within the lung alveoli. Blood returns via the pulmonary veins to the left atrium.

Concept Check

On Figure 9.4 below, use your finger to trace the pathway of blood flowing through the left side of the heart, naming each of the following structures as you encounter them: right and left pulmonary veins, left atrium, mitral valve, left ventricle, aortic valve, aorta.

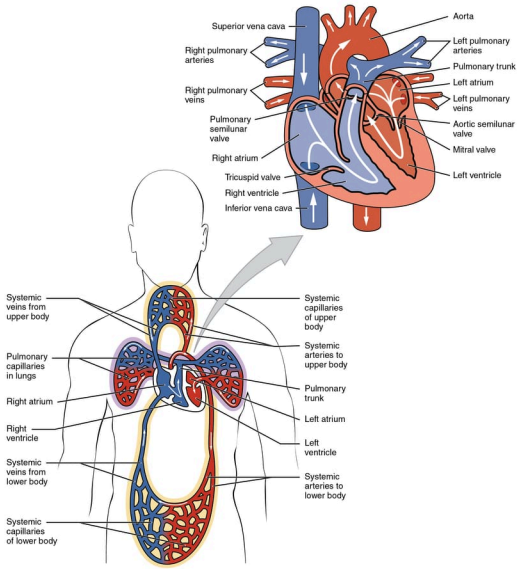

Figure 9.4. Dual System of the Human Blood Circulation. Blood flows from the right atrium to the right ventricle, where it is pumped into the pulmonary circuit. The blood in the pulmonary artery branches is low in oxygen but relatively high in carbon dioxide. Gas exchange occurs in the pulmonary capillaries (oxygen into the blood, carbon dioxide out), and blood high in oxygen and low in carbon dioxide is returned to the left atrium. From here, blood enters the left ventricle, which pumps it into the systemic circuit. Following the exchange in the systemic capillaries (oxygen and nutrients out of the capillaries and carbon dioxide and wastes in), blood returns to the right atrium and the cycle is repeated. From Betts et al., 2013. Licensed under CC BY 4.0. [Image description.]

Cardiac Cycle

The process of pumping and circulating blood is active, coordinated, and rhythmic. Each heartbeat represents one cycle of the heart receiving blood and ejecting blood.

- **Diastole** is the portion of the cycle in which the heart is relaxed and the atria and ventricles are filling with blood. The AV valves are open so that blood can move from the atria to the ventricles.
- **Systole** is the portion of the cycle in which the heart contracts, AV valves slam shut, and the ventricles eject blood to the lungs and the body through the open semilunar valves. Once this phase ends, the semilunar valves close, in preparation for another filling phase.

2. The Heart as an Organ: The Coronary Blood Supply

Myocardial cells require their own blood supply to carry out their function of contracting and relaxing the heart in order to pump blood. Their own blood supply provides nutrients and oxygen and carries away carbon dioxide and waste. These functions are provided by the coronary arteries and coronary veins.

Concept Check

On the image below, locate the three main coronary arteries:

- **Anterior interventricular artery** (more commonly known as the **left anterior descending artery, or LAD**)
- **Circumflex artery (Cx)**
- **Right coronary artery (RCA)**

Follow the path of each of these three arteries to try to determine which parts of the myocardium each artery (along with its many smaller branches) supplies with blood.

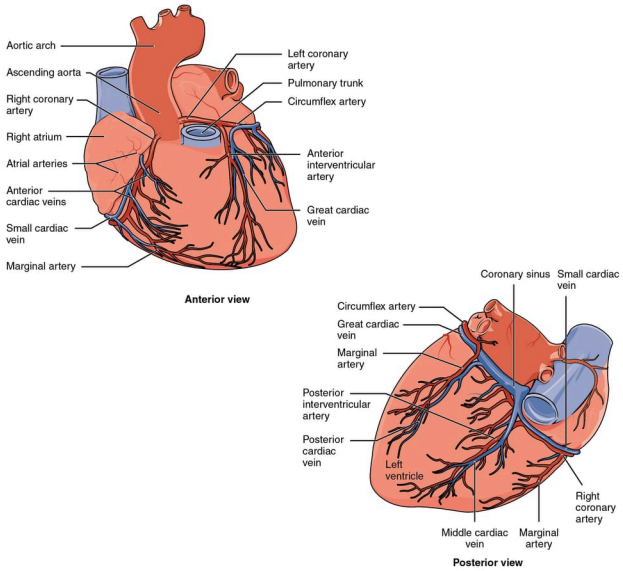

Figure 9.5 Coronary Circulation. The anterior view of the heart shows the prominent coronary surface vessels. The posterior view of the heart shows the prominent coronary surface vessels. From Betts et al., 2013. Licensed under CC BY 4.0. [Image description.]

3. The Heart's Electrical Conduction System

In order for all parts of the heart to work together to beat regularly and effectively, the heart has its own electrical system, which initiates and conducts each heartbeat through the entire myocardium. Specialized groups of heart cells perform this function all on their own, without requiring messages from the central nervous system.

Watch this video:

YouTube Video

This interactive element is not available in this format. Visit the link or scan the QR code to access it online.

View this YouTube Video online

Media 9.2. The Heart, Part 2 – Heart Throbs: Crash Course A&P #26 [Online video]. Copyright 2015 by CrashCourse.

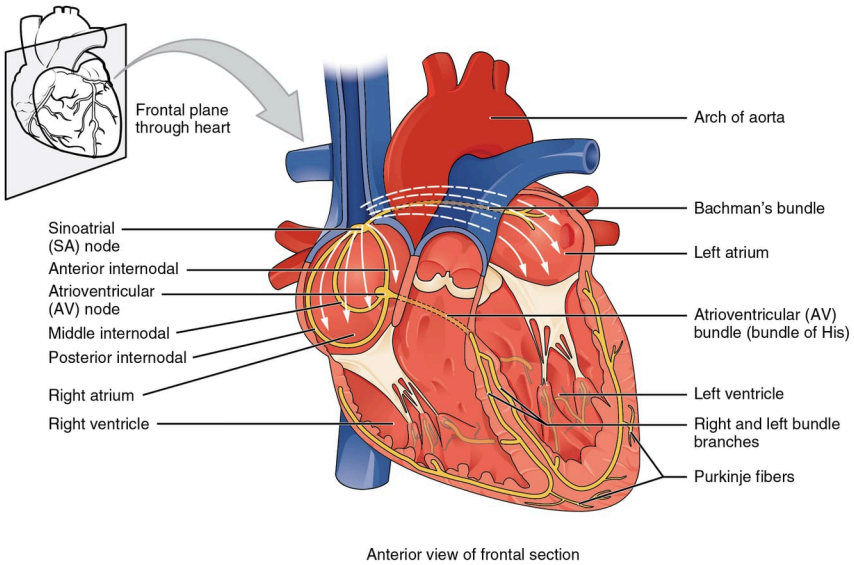

Figure 9.6. Conduction System of the Heart. Specialized conducting components of the heart include the sinoatrial node, the internodal pathways, the atrioventricular node, the atrioventricular bundle, the right and left bundle branches, and the Purkinje fibers. From Betts et al., 2013. Licensed under CC BY 4.0. [Image description.]

Concept Check

On the image above, trace the electrical impulse generated by the heart's pacemaker (the **sinoatrial node**, or **SA node**) through the rest of the conduction system, including the **atrioventricular (AV) node**, the **atrioventricular bundle (bundle of His)**, the **right and left bundle branches**, and the **Purkinje fibers**.

We can detect and record the electrical activity of the heart's conduction system using an electrocardiogram (ECG or EKG). Figure 9.7 shows the electrical impulse originating in the SA node (step 2) and traveling through the heart's conduction system, allowing the heart to complete one cardiac cycle. Each waveform on the ECG tracing represents electricity moving through and affecting a different part of the heart. Did you notice that the AV valves close when the electrical impulse reaches the ventricles, just before systole occurs?

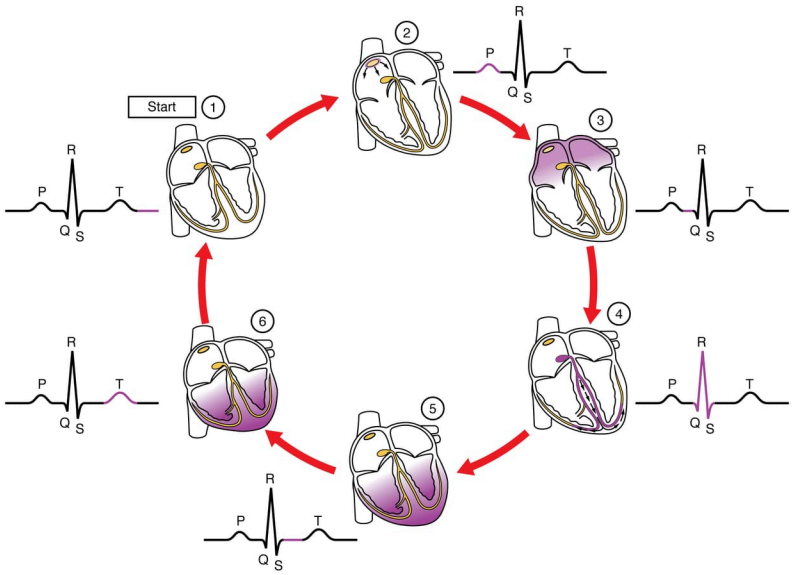

Figure 9.7. ECG Tracing Correlated to the Cardiac Cycle. This diagram correlates an ECG tracing with the electrical and mechanical events of a heart contraction. Each segment of an ECG tracing corresponds to one event in the cardiac cycle. From Betts et al., 2013. Licensed under CC BY 4.0. [Image description.]

Practice Terms Related to the Cardiovascular System

Query 1.9.4

This interactive element is not available in this format. Visit the link or scan the QR code to access it online.

View this Interactive Content online

Common Abbreviations for the Cardiovascular System

Many terms and phrases related to the cardiovascular system are abbreviated. Learn these common abbreviations by expanding the list below.

Query 1.9.5

This interactive element is not available in this format. Visit the link or scan the QR code to access it online.

View this Interactive Content online

Diseases and Disorders of the Heart

Cardiomyopathy

The heart of a well-trained athlete can be considerably larger than the average person's heart. This is because exercise results in an increase in muscle cells called hypertrophy. Hearts of athletes can pump blood more effectively at lower rates than those of non-athletes. However, when an enlarged heart is not the result of exercise, it may be due to **hypertrophic cardiomyopathy**. The cause of an abnormally enlarged heart muscle is unknown, but the condition is often undiagnosed and can cause sudden death in apparently otherwise healthy young people.

Other types of cardiomyopathy include:

- **Dilated cardiomyopathy**, which also has an unknown cause and is seen in people of any age. In this disorder, one of the ventricles of the heart is larger than normal.
- **Arrhythmogenic cardiomyopathy**, an inherited condition that results in irregular heart rhythms.
- **Restrictive cardiomyopathy**, which is a complication of other conditions which cause the myocardium to scar or stiffen (Centers for Disease Control and Prevention, 2019).

Cardiomyopathy may also be caused by myocardial infarctions, myocardial infections, pregnancy, alcohol or cocaine abuse, autoimmune and endocrine diseases. Because the myocardium is responsible for contracting and pumping blood, patients with cardiomyopathy experience impaired heart function which may lead to heart failure (Centers for Disease Control and Prevention, n.d.-a). To learn more, visit the Centers for Disease Control and Prevention's web page on cardiomyopathy.

Heart Failure

Heart failure is defined as the inability of the heart to pump enough blood to meet the needs of the body. It is also called **congestive heart failure (CHF).** This condition causes swelling in the lower extremities and shortness of breath, due to a buildup

of fluid in the lungs. It may be caused by cardiomyopathy, and it may lead to hypertension and heart valve disorders (Heart & Stroke, n.d.). To learn more, visit the American Heart Association's web page on heart failure.

Valvular Heart Disease

The four heart valves open and close at specific times during the cardiac cycle, in order to ensure that blood flows in only one direction through the heart. This requires that these valves open and close completely. Infections such as rheumatic disease or bacterial endocarditis can affect the heart valves and result in scar tissue formation which interferes with valve function. Other causes of heart valve disease include congenitally malformed valves, autoimmune diseases, and other cardiovascular diseases such as aortic aneurysms and atherosclerosis (Centers for Disease Control and Prevention, n.d.-b).

Heart valve disease may be asymptomatic or cause dyspnea, arrhythmias, fatigue and other symptoms. It is often detected when a heart murmur is heard through a stethoscope (Centers for Disease Control and Prevention, n.d.-b).

- **Mitral Valve Prolapse**
  - The mitral (bicuspid) valve is diseased or malformed and is not able to close completely, allowing the regurgitation of blood back into the left atrium during systole. Because some of the blood goes back into the atrium, insufficient blood is pumped out of the ventricle into the systemic circulation. This inability to close properly and the resulting regurgitation may also be found in other heart valves (Centers for Disease Control and Prevention, n.d.-b).
- **Aortic Stenosis**
  - The aortic valve is narrowed and hardened, preventing it from opening fully and allowing sufficient blood to travel to the systemic circulation. Any heart valve can be stenosed, but this disorder most often affects the aortic valve (Centers for Disease Control and Prevention, n.d.-b).

Visit the Center for Disease Control and Prevention's web page on valvular heart disease to learn more.

Aneurysms

An aneurysm is a defect in the wall of an artery in which the wall becomes thin and weak and starts to balloon out as blood pulses against the vessel wall. This can happen to any artery and even to the myocardial walls. Aneurysms sometimes occur in the portion of the aorta that is in the thorax (see Figure 9.8). If these aneurysms start to leak between layers of the vessel wall, the condition is known as aortic dissection. If an aortic or cardiac aneurysm bursts, there is sudden, massive internal bleeding (Centers for Disease Control and Prevention, n.d.-c).

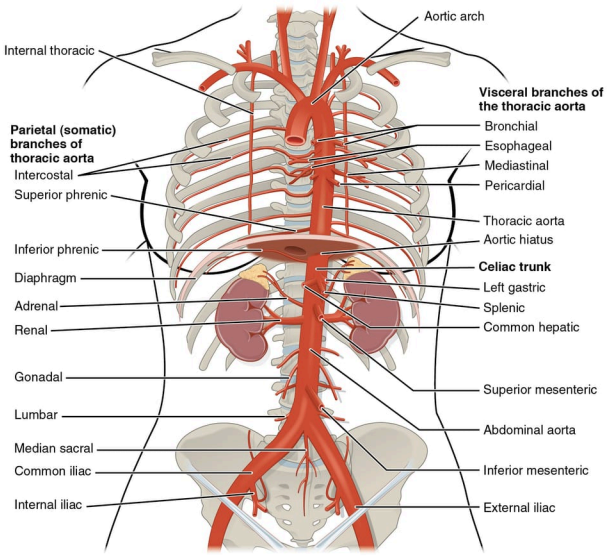

Figure 9.8. Arteries of the Thoracic and Abdominal Regions The thoracic aorta gives rise to the arteries of the visceral and parietal branches. From Betts et al., 2013. Licensed under CC BY 4.0. [Image description.]

People who smoke or have hypertension, hypercholesterolemia, and/or atherosclerosis have an increased risk of developing

aneurysms. Having a family history of aneurysms or certain genetic diseases may also increase a person's risk of developing an aneurysm.

Aneurysms can be asymptomatic and may be detected during diagnostic tests that are done for other reasons. They are sometimes repaired surgically and sometimes treated with medications such as antihypertensives (Centers for Disease Control and Prevention, n.d.-c; National Heart, Lung, and Blood Institute, n.d.). Visit the National Heart, Lung, and Blood Institute's web page on aortic aneurysms to learn more.

Heart Defects

Fetal circulation is different from postnatal circulation. There are two extra openings in the fetal heart, the foramen ovale and the ductus arteriosus, which allow blood circulation that bypasses the immature fetal lungs. The fetal blood is reoxygenated by the mother's lungs and transported between mother and fetus via the placenta. These two openings usually close around the time of birth.

Septal defects are commonly first detected through auscultation. Unusual heart sounds may be detected because blood is not flowing and valves are not closing correctly. Medical imaging is ordered to confirm or rule out a diagnosis. In many cases, treatment may not be needed.

- **Patent ductus arteriosus** is a congenital condition in which the ductus arteriosus fails to close. If untreated, the condition can result in congestive heart failure.
- **Patent foramen ovale** is one type of atrial septal defect (ASD), due to a failure of the hole in the interatrial septum to close at birth.
  - As much as 20 to 25% of the general population may have a patent foramen ovale. Most have the benign, asymptomatic version but in extreme cases, a surgical repair is required to close the opening permanently.
- **Tetralogy of Fallot** is a congenital condition that may also occur from exposure to unknown environmental factors; it occurs when there is an opening in the interventricular septum caused by blockage of the pulmonary trunk, normally at the pulmonary semilunar valve. This allows blood that is relatively low in oxygen from the right ventricle to flow into the left ventricle and mix with the blood that is relatively high in oxygen.
  - Signs and symptoms include a distinct heart murmur, low blood oxygen percent saturation, dyspnea, polycythemia, clubbing of the fingers and toes, and in children, difficulty in feeding or failure to grow and develop.
  - It is the most common cause of cyanosis following birth. Other heart defects may also accompany this condition, which is typically confirmed by echocardiography imaging.
- In the case of severe septal defects, including both tetralogy of fallot and patent foramen ovale, failure of the heart to develop properly can lead to a condition commonly known as a **blue baby.** Regardless of normal skin pigmentation, individuals with this condition have an insufficient supply of oxygenated blood, which leads to cyanosis, especially when active.

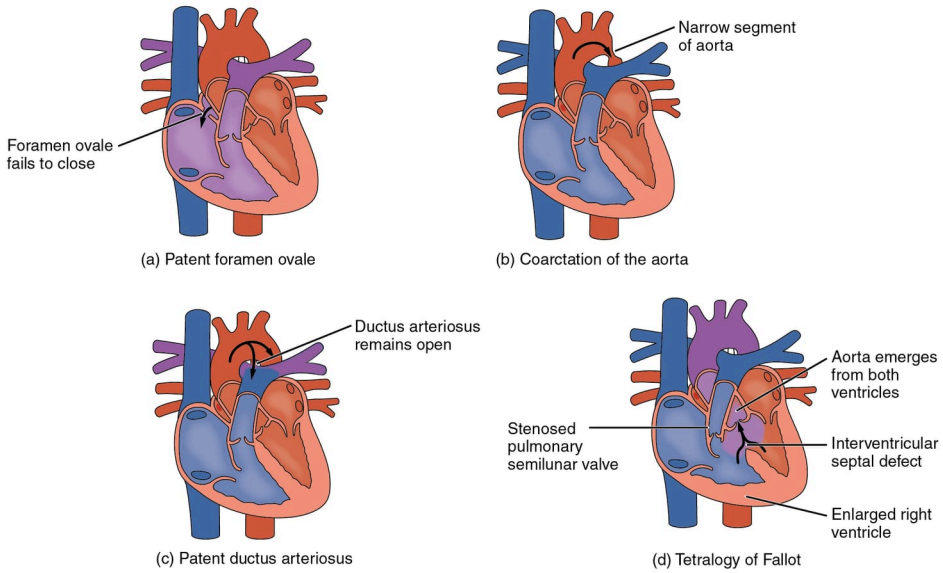

Figure 9.9. Congenital Heart Defects. (a) A patent foramen ovale defect is an abnormal opening in the interatrial septum, or more commonly, a failure of the foramen ovale to close. (b) Coarctation of the aorta is an abnormal narrowing of the aorta. (c) A patent ductus arteriosus is the failure of the ductus arteriosus to close. (d) Tetralogy of Fallot includes an abnormal opening in the interventricular septum. From Betts et al., 2013. Licensed under CC BY 4.0. [Image description.]

Diseases Related to Coronary Circulation

Coronary Artery Disease (CAD)

Coronary artery disease occurs when the buildup of plaque in the coronary arteries obstructs the flow of blood and decreases compliance of the vessels. This condition is called atherosclerosis. As the disease progresses and coronary blood vessels become more and more narrow, cells of the myocardium become ischemic which causes symptoms of angina pectoris, in some patients. If untreated, coronary artery disease can lead to myocardial infarction (MI).

The image below shows the blockage of coronary arteries on an angiogram.

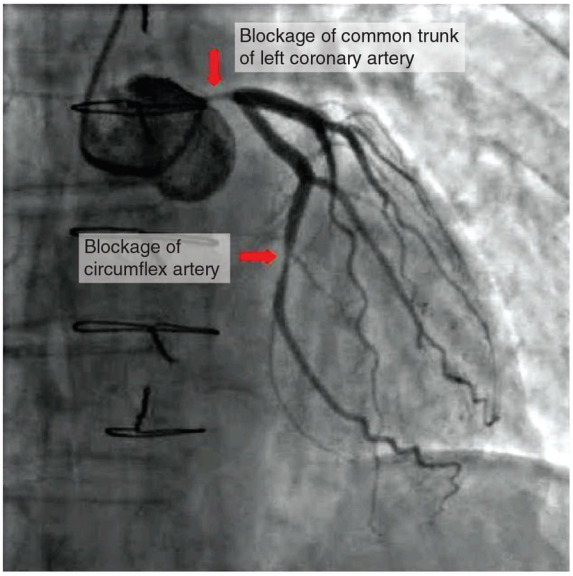

Figure 9.10. Angiogram of Atherosclerotic Coronary Arteries. In this coronary angiogram (X-ray), the dye makes visible two occluded coronary arteries. Such blockages can lead to decreased blood flow (ischemia) and insufficient oxygen (hypoxia) delivered to the cardiac tissues. If uncorrected, this can lead to cardiac muscle death (myocardial infarction). From Betts et al., 2013. Licensed under CC BY 4.0. [Image description.]

CAD is progressive and chronic. Risk factors include smoking, family history, hypertension, obesity, diabetes, high alcohol consumption, lack of exercise, stress, and hyperlipidemia. Treatments may include medication, changes to diet and exercise, angioplasty with a balloon catheter, insertion of a stent, or coronary artery bypass graft (CABG).

- **Angioplasty** is a procedure in which the occlusion is mechanically widened with a balloon. A specialized catheter with an expandable tip is inserted into a blood vessel in the arm or leg, and then directed to the site of the occlusion. At this point, the balloon is inflated to compress the plaque material and to open the vessel to increase blood flow. Once the balloon is deflated and retracted, a stent consisting of a specialized mesh is typically inserted at the site of occlusion to reinforce the weakened and damaged walls and prevent re-occlusion.
- **Coronary bypass surgery (Coronary artery bypass graft CABG)** is a surgical procedure which grafts a replacement vessel obtained from another part of the body to bypass the occluded area.

Myocardial Infarction

Myocardial infarction (MI) is the medical term for a heart attack.

A MI normally results from a lack of blood flow to a region of the heart, resulting in death of the cardiac muscle cells. A MI often occurs when a coronary artery is blocked by the buildup of atherosclerotic plaque. It can also occur when a piece of an atherosclerotic plaque breaks off and travels through the coronary arterial system until it lodges in one of the smaller vessels. MIs may be triggered by excessive exercise, in which the partially occluded artery is no longer able to pump sufficient quantities of blood, or severe stress, which may induce spasm of the smooth muscle in the walls of the vessel.

In the case of **acute MI (AMI)**, there is often sudden pain beneath the sternum (retrosternal pain) called angina pectoris, often radiating down the left arm in males but not in female patients. Other common signs and symptoms include dyspnea, palpitations, nausea and vomiting, diaphoresis, anxiety, and syncope. Many of the symptoms are shared with other medical conditions, including anxiety attacks and simple indigestion, so differential diagnosis is critical.

An MI can be confirmed by examining the patient's ECG.

Other diagnostic tests include:

- echocardiography.
- CT.

- MRI.
- Common blood tests indicating an MI include elevated levels of creatine kinase MB and cardiac troponin, both of which are released by damaged cardiac muscle cells.

MIs may induce dangerous heart rhythms and even cardiac arrest. Important risk factors for MI include coronary artery disease, age, smoking, high blood levels of LDL, low levels of HDL, hypertension, diabetes mellitus, obesity, lack of physical exercise, chronic kidney disease, excessive alcohol consumption, and use of illegal drugs.

> **Did you know?**
>
> It is estimated that between 22 and 64% of myocardial infarctions present without any symptoms.

Diseases of the (Electrical) Conduction System

Arrhythmia

The heart's natural pacemaker, the sinoatrial (SA) node initiates an electrical impulse 60 to 90 times per minute in a resting adult. This impulse travels through the heart's conduction system in order to ensure a smooth, coordinated pumping action. This electrical activity can be detected and recorded through the skin using an electrocardiograph. Arrhythmias may occur when the SA node fails to initiate an impulse, or when the conduction system fails to transmit that impulse through the heart.

In the event that the electrical activity of the heart is severely disrupted, cessation of electrical activity or fibrillation may occur. In fibrillation, the heart beats in a wild, uncontrolled manner, which prevents it from being able to pump effectively.

- **Atrial fibrillation** is a serious condition, but as long as the ventricles continue to pump blood, the patient's life may not be in immediate danger.
- **Ventricular fibrillation** is a medical emergency that requires life support, because the ventricles are not effectively pumping blood, left untreated ventricular fibrillation may lead to brain death.

The most common treatment is **defibrillation** which uses special paddles to apply a charge to the heart from an external electrical source in an attempt to establish a normal sinus rhythm. A defibrillator effectively stops the heart so that the SA node can trigger a normal conduction cycle. **External automated defibrillators (EADs**) are being placed in areas frequented by large numbers of people, such as schools, restaurants, and airports. These devices contain simple and direct verbal instructions that can be followed by non-medical personnel in an attempt to save a life.

> **Did you know?**
>
> Arrhythmia does *not* mean an absence of a heartbeat. That would be asystole, or flat line. Arrhythmia is defined as the absence of a *regular* rhythm, meaning that the heart rate is either too fast, too slow or just irregular.

Abnormal Heart Rates

Bradycardia is the condition in which resting adult heart rate drops below 60 beats per minute (bpm). A client exhibiting signs and symptoms such as weakness, fatigue, dizziness, syncope, chest discomfort, palpitations, or respiratory distress may indicate that the heart is not providing sufficient oxygenated blood to the tissues. If the patient is not exhibiting symptoms then bradycardia is not considered clinically significant. The term **relative bradycardia** may be used with a patient who has a heart rate in the normal range but is still suffering from these symptoms. Most patients remain asymptomatic as long as the heart rate remains above 50 bpm.

Tachycardia is the condition in which the resting rate is above 100 bpm. Tachycardia is not normal in a resting patient and may be detected in pregnant women or individuals experiencing extreme stress. Some individuals may remain asymptomatic, but when present, signs and symptoms may include dizziness, shortness of breath, rapid pulse, heart palpitations, chest pain,

or syncope. Treatment depends upon the underlying cause but may include medications, ablation, implantable cardioverter defibrillators, or surgery.

Heart Block

A **heart block** refers to an interruption in the normal conduction pathway. Heart blocks are generally named after the part of the conduction system that is causing the problem. For example, bundle branch blocks occur within either the left or right atrioventricular bundle branches.

AV blocks are often described by degrees. A **first-degree or partial block** indicates a delay in conduction between the SA and AV nodes. A **second-degree or incomplete block** occurs when some impulses from the SA node reach the AV node and continue, while others do not. In the **third-degree or complete block**, there is no correlation between atrial activity and ventricular activity. This means that none of the impulses generated by the SA node get transmitted to the rest of the heart and the AV node must take over as the primary pacemaker, initiating contractions at 40 to 60 bpm, which is adequate to maintain consciousness.

In order to speed up the heart rate and restore full sinus rhythm, a cardiologist can implant an **artificial pacemaker**, which delivers electrical impulses to the heart muscle to ensure that the heart continues to contract and pump blood effectively. These artificial pacemakers are programmable by the cardiologists and can either provide stimulation temporarily upon demand or on a continuous basis. Some devices also contain built-in defibrillators.

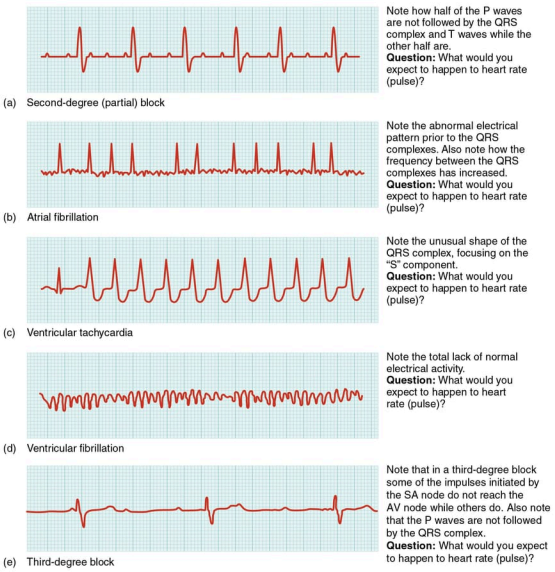

Figure 9.11. Common ECG Abnormalities. (a) In a second-degree or partial block, one-half of the P waves are not followed by the QRS complex and T waves while the other half are. (b) In atrial fibrillation, the electrical pattern is abnormal prior to the QRS complex, and the frequency between the QRS complexes has increased. (c) In ventricular tachycardia, the shape of the QRS complex is abnormal. (d) In ventricular fibrillation, there is no normal electrical activity. (e) In a third-degree block, there is no correlation between atrial activity (the P wave) and ventricular activity (the QRS complex). From Betts et al., 2013. Licensed under CC BY 4.0. [Image description.]

Medical Terms in Context

Query 1.9.6

This interactive element is not available in this format. Visit the link or scan the QR code to access it online.

View this Interactive Content online

Medical Specialties Related to the Cardiovascular System

Cardiologists and Thoracic Surgeons

Cardiologists are medical doctors that specialize in diagnosing and treating heart diseases. After completing medical school, cardiologists must complete at least six more years of training (Betts et al., 2013). Thoracic surgeons provide surgical treatments on the heart and other thoracic organs (National Cancer Institute, n.d.). For more information, visit the American College of Cardiology Foundation's web page on cardiologists.

Cardiology Technologists

Cardiology technologists complete a college training program and perform diagnostic tests such as electrocardiography and stress testing, as well as pacemaker monitoring (Bureau of Labor Statistics, 2021). Please visit the Bureau of Labor Statistics' web page on cardiology technologists for more information.

Cardiovascular Perfusionists

Cardiovascular perfusionists complete a college training program and are responsible for operation of the heart-lung bypass machine during open heart surgery. They also monitor the patient's vitals and administer medications (New York State Education Department, 2020). For more information, please read this job description from the American Board of Cardiovascular Perfusion (PDF).

Cardiovascular System Vocabulary

Ablation: The removal or destruction of a body part or tissue or its function. Ablation may be performed by surgery, hormones, drugs, radiofrequency, heat, or other methods.

Aneurysm: Weakening of the wall of a blood vessel, causing it to thin and balloon out, and possibly eventually burst, resulting in internal bleeding.

Angina pectoris: Chest pain. It may be a symptom of coronary artery disease and myocardial infarction.

Angiogram: An x-ray or computer image (CT scan or MRI) of the blood vessels and blood flow in the body. A dye may be injected through a catheter (small tube) into an artery or vein to make the blood vessels easier to see.

Antihypertensives: A class of medications used to treat high blood pressure.

Arrhythmia: A deviation from the normal pattern of impulse conduction and contraction of the heart.

Asymptomatic: Having no signs or symptoms of disease.

Atherosclerosis: A hardening of the arteries that involves the accumulation of plaque.

Auscultation: Listening to the heart using a stethoscope.

Atrioventricular (AV): The area of the heart where the atria and ventricles meet.

Atrioventricular (AV) valves: Mitral (bicuspid) valve that allows blood to flow from left atrium to left ventricle and tricuspid valve that allows blood to flow from right atrium to right ventricle.

Bradycardia: A condition in which the heart beats slower than 50 beats per minute.

Cardiac: Having to do with the heart.

Cardiac troponin: The regulatory protein for muscle contraction.

Cardiogenic: Originating from the heart.

Cardiologist: A physician who studies and treats diseases of the heart.

Cardiology: The study of the heart.

Cardiomegaly: Enlarged heart.

Cardiomyopathy: Disease of the heart muscle.

Compliance: The ability of the blood vessels to dilate and constrict as needed.

Computerized tomography (CT): A noninvasive imaging technique that uses computers to analyze several cross-sectional X-rays in order to reveal minute details about structures in the body.

Congenital: Present at birth.

Creatine kinase MB: An enzyme that catalyzes the conversion of creatine to phosphocreatine, consuming ATP.

Cyanosis: A condition in which the oxygen supply is restricted, causing the skin to look blue.

Diabetes mellitus: A disease in which the body does not control the amount of glucose (a type of sugar) in the blood and the kidneys make a large amount of urine. This disease occurs when the body does not make enough insulin or does not use it the way it should.

Diaphoresis: Sweating.

Diastole: Period of time when the heart muscle is relaxed and the chambers fill with blood.

Ductus arteriosus: A temporary connection between pulmonary trunk and aorta in the fetal heart.

Dyspnea: Difficulty breathing.

Echocardiogram: A computer picture of the heart created by bouncing high-energy sound waves (ultrasound) off internal tissues or organs of the chest.

Echocardiography: A procedure that uses high-energy sound waves (ultrasound) to look at tissues and organs inside the chest.

Electrocardiogram (ECG/EKG): The record of the heart's function produced by the electrocardiograph.

Electrocardiograph: The instrument that generates an electrocardiogram (ECG); 10 electrodes are placed in standard locations on the patient's skin to record heart function.

Electrocardiography: The science of recording the electrical activity of the heart.

Endocarditis: A condition in which the tissues lining the inside of the heart and the heart valves become inflamed.

Foramen ovale: An opening between right and left atria, which is normal in the fetal heart.

Great vessels: Include the superior vena cava, inferior vena cava, aorta and pulmonary trunk.

Heart murmur: An abnormal heart sound.

Heart rate: The number of times the heart beats within a certain time period, usually a minute.

High-density lipoprotein (HDL): Often referred to as "good" cholesterol.

Hypercholesterolemia: Higher than normal levels of cholesterol in the blood.

Hyperlipidemia: Excessive fat in the blood.

Hypertension: Abnormally high blood pressure.

Implantable cardioverter defibrillators (ICD): A small device placed by surgery in the chest or abdomen that is used to correct a heartbeat that is abnormal. Wires are passed through a vein to connect the device to the heart. When it detects abnormal heartbeats, it sends an electrical shock to the heart to restore the heartbeat to normal.

Inferior vena cava: One of the two largest veins in the body. It carries deoxygenated blood from the torso and legs back to the heart.

Interatrial septum: The wall separating the right and left atria.

Interventricular septum: The wall of myocardium that separates the right and left ventricles.

Ischemia: Lack of blood flow to body tissues.

Low-density lipoprotein (LDL): Often referred to as 'bad' cholesterol.

Magnetic Resonance Imaging (MRI): A procedure in which radio waves and a powerful magnet linked to a computer are used to create detailed pictures of areas inside the body.

Mitral valve: Located at the opening between the left atrium and left ventricle; also known as the bicuspid valve.

Myocardial infarction (MI): Heart attack, caused by lack of blood flow and oxygen to the heart.

Myocarditis: A rare condition in which the heart muscle becomes thick and inflamed and may also become weak.

Occlusion: A blockage.

Pacemaker: An electronic device that is implanted in the body to monitor heart rate and rhythm. It gives the heart electrical stimulation when it does not beat normally.

Palpitations: A rapid or irregular heartbeat that a person can feel.

Pericardial fluid: Watery fluid produced in the serous and visceral pericardium surrounding the surface of the heart.

Pericarditis: Inflammation of the (sac) surrounding the heart.

Pericardiocentesis: Surgical puncture to aspirate fluid from the (sac) surrounding the heart.

Plaque: A fatty material including cholesterol, connective tissue, white blood cells, and some smooth muscle cells.

Polycythemia: A rare disorder in which the bone marrow produces an abnormally large amount of blood cells.

Pulmonary trunk: The very large artery referred to as a trunk, a term indicating that the vessel gives rise to several smaller arteries.

Roots of the great vessels: The part of each great vessel (aorta, pulmonary trunk, inferior vena cava, superior vena cava) that connects to the base of the heart.

Serous membrane: One of the thin membranes that cover the walls and organs in the thoracic and abdominopelvic cavities.

Sinus rhythm: The normal electrical pattern followed by contraction of the heart.

Sphygmomanometer: A blood pressure cuff attached to a measuring device.

Stethoscope: An instrument used to hear sounds produced by the heart, lungs, or other parts of the body.

Superior vena cava: One of two large veins in the body, which carries deoxygenated blood from the head and upper extremities back to the heart.

Syncope: Fainting.

Systole: Period of time when the heart muscle is contracting.

Tachycardia: A condition in which the resting rate is above 100 bpm.

Valvuloplasty: The widening of a stenosed heart valve using a balloon catheter.

Test Yourself

Query 1.9.7

This interactive element is not available in this format. Visit the link or scan the QR code to access it online.

View this Interactive Content online

References

Bureau of Labor Statistics. (2021). Medical sonographers and cardiovascular technologists and technicians. In *Occupational outlook handbook*. U.S. Department of Labor. https://www.bls.gov/ooh/healthcare/diagnostic-medical-sonographers.htm

Centers for Disease Control and Prevention. (n.d.-a). *Cardiomyopathy*. CDC. https://www.cdc.gov/heartdisease/cardiomyopathy.htm

Centers for Disease Control and Prevention. (n.d.-b). *Valvular heart disease*. CDC. https://www.cdc.gov/heartdisease/valvular_disease.htm

Centers for Disease Control and Prevention. (n.d.-c). *Aortic aneurysm*. CDC. https://www.cdc.gov/heartdisease/aortic_aneurysm.htm

CrashCourse. (2015, July 6). *The heart, part 1 – under pressure: Crash course A&P #25* [Video]. YouTube. https://youtu.be/X9ZZ6tcxArI

CrashCourse. (2015, July 13). *The heart, part 2 – heart throbs: Crash course A&P #26* [Video]. YouTube. https://youtu.be/FLBMwcvOaEo

National Heart, Lung, and Blood Institute. (n.d.). *Aortic aneurysm*. National Institutes of Health, U.S. Department of Health and Human Services. https://www.nhlbi.nih.gov/health-topics/aneurysm

National Cancer Institute. (n.d.). *Definition of thoracic surgeon*. National Institutes of Health, U.S. Department of Health and Human Services.. https://www.cancer.gov/publications/dictionaries/cancer-terms/def/thoracic-surgeon

New York State Education Department. (2020). *Perfusionist*. Retrieved November 1, 2021, from http://www.op.nysed.gov/careers/perfprofile.htm

Image Descriptions

Figure 9.1 image description: This diagram shows the location of the heart in the thorax (sagittal and anterior views). The sagittal view labels read (from top, clockwise): first rib, aortic arch, thoracic arch, esophagus, inferior vena cava, diaphragm, thymus, trachea. The anterior view labels read (from top, clockwise): mediastinum, arch of aorta, pulmonary trunk, left auricle, left lung, left ventricle, pericardial cavity, apex of heart, edge of parietal pericardium, diaphragm, edge of parietal pleura, ribs, right ventricle, right atrium, right auricle, right lung, superior vena cava. [Return to Figure 9.1].

Figure 9.2 image description: This image shows a magnified view of the structure of the heart wall. Labels read (from top,

clockwise): pericardial cavity, fibrous pericardium, parietal layer of serous pericardium, epicardium (visceral layer of serous pericardium), myocardium, endocardium. [Return to Figure 9.2].

Figure 9.3 image description: This diagram shows the network of blood vessels in the lungs. Labels read (from top, clockwise (left-side of the body): aortic arch, pulmonary trunk, left lung, left pulmonary arteries, left pulmonary vein, pulmonary capillaries, descending aorta, (right side of body) inferior vena cava, right pulmonary veins, right pulmonary arteries, right lung, superior vena cava, ascending aorta. [Return to Figure 9.3].

Figure 9.4 image description: The top panel shows the human heart with the arteries and veins labeled (from top, clockwise): aorta, left pulmonary arteries, pulmonary trunk, left atrium, left pulmonary veins, aortic semilunar valve, mitral valve, left ventricle, inferior vena cava, right ventricle, tricuspid valve, right atrium, pulmonary semilunar valve, right pulmonary veins, right pulmonary arteries, superior vena cava. The bottom panel shows a rough map of the human circulatory system. Labels read (from top, clockwise): systemic capillaries of upper body, systemic arteries to upper body, pulmonary trunk, left atrium, left ventricle, systemic arteries to lower body, systemic capillaries of lower body, systemic veins from lower body, right ventricle, right atrium, pulmonary capillaries in lungs, systemic veins from upper body. [Return to Figure 9.4].

Figure 9.5 image description: The top panel of this figure shows the anterior view of the heart while the bottom panel shows the posterior view of the heart. The different blood vessels are labeled. Anterior view labels (from top of diagram, clockwise): left coronary artery, pulmonary trunk, circumflex artery, anterior interventricular artery, great cardiac vein, small cardiac vein, anterior cardiac veins, atrial arteries, right atrium, right coronary artery, ascending aorta, aortic arch. Posterior view labels (from top of diagram, clockwise): coronary sinus, small cardiac vein, right coronary artery, marginal artery, middle cardiac vein, posterior cardiac vein, posterior interventricular artery, marginal artery, great cardiac vein, circumflex artery. [Return to Figure 9.5].

Figure 9.6 image description: This image shows the anterior view of the frontal section of the heart with the major parts labeled. Labels read (from top of diagram, clockwise) arch of aorta, Bachman's bundle, atrioventricular bundle (bundle of His), left ventricle, right and left bundle branches, Purkinje fibers, right ventricle, right atrium, posterior intermodal, middle intermodal, atrioventricular node, anterior intermodal, Sinoatrial node. [Return to Figure 9.6].

Figure 9.7 image description: This diagram shows the six different stages of heart contraction and relaxation along with the stages in the QT cycle. [Return to Figure 9.7].

Figure 9.8 image description: This diagram shows the arteries in the thoracic and abdominal cavity. Visceral branches of the thoracic aorta labels (from top): bronchial, esophageal, mediastinal, pericardial, thoracic aorta, aortic hiatus, celiac trunk, left gastric, splenic, common hepatic, superior mesenteric, abdominal aorta, inferior mesenteric, external iliac. Parietal (somatic) branches of thoracic aorta labels (from top): intercostal, superior phrenic, inferior phrenic, diaphragm, adrenal, renal, gonadal, lumbar, medial sacral, common iliac, internal iliac. [Return to Figure 9.8].

Figure 9.9 image description: This diagram shows the structure of the heart with different congenital defects. The top left panel shows patent foramen ovale (label reads foramen ovale fails to close), the top right panel shows coarctation of the aorta (label reads narrow segment of aorta), the bottom left panel shows patent ductus arteriosus (label reads Ductus arteriosus remains open) and the bottom right shows tetralogy of fallot (labels read aorta emerges from both ventricles, interventricular septal defect, enlarged right ventricle, stenosed pulmonary semilunar valve). [Return to Figure 9.9].

Figure 9.10 image description: An angiogram of atherosclerotic coronary arteries. The image shows blockages in the common trunk of the left coronary artery and circumflex artery. Blockages can cause ischemia, hypoxia, and myocardial infarction. [Return to Figure 9.10].

Figure 9.11 image description: In this image the QT cycle for different heart conditions are shown. From top to bottom, the arrhythmias shown are second-degree partial blocks (text reads: Note how half of the P waves are not followed by the QRS complex and T waves while the other half are. Question: what would you expect to happen to heart rate?), atrial fibrillation (text reads: Note the abnormal electric pattern prior to the QRS complexes. Also note how the frequency between the QRS complexes has increased. Question: What would you expect to happen to heart rate?), ventricular tachycardia (text reads: Note the unusual shape of the QRS complex, focusing on the S component. Question: What would you expect to happen to heart rate?), ventricular fibrillation (text reads: Note the total lack of normal electrical activity. Question: What would you expect to happen to heart rate?), and third degree block (text reads: Note that in a third-degree block some of the impulses initiated by the SA node do not reach the AV node while others do. Also note that the P waves are not followed by the QRS complex. Question: What would you expect to happen to heart rate?). [Return to Figure 9.11].

Unless otherwise indicated, this chapter contains material adapted from *Anatomy and Physiology* (on OpenStax), by Betts et

al. and is used under a CC BY 4.0 international license. Download and access this book for free at https://openstax.org/books/anatomy-and-physiology/pages/1-introduction.

This page titled 1.9: Cardiovascular System is shared under a CC BY 4.0 license and was authored, remixed, and/or curated by Andrea Nelson and Katherine Greene via source content that was edited to the style and standards of the LibreTexts platform.

1.10: Blood Vessels and Blood

Learning Objectives

- Examine the anatomy of the blood vessels and the composition of blood
- Determine the main functions of the blood vessels and of the components of blood
- Differentiate medical terms of the blood vessels and blood and common abbreviations
- Recognize the medical specialties associated with the blood vessels and blood
- Discover common diseases, disorders, and procedures related to the blood vessels and blood

Blood Vessels and Blood Word Parts

Click on prefixes, combining forms, and suffixes to reveal a list of word parts to memorize for blood vessels and blood.

Query 1.10.1

This interactive element is not available in this format. Visit the link or scan the QR code to access it online.

View this Interactive Content online

Introduction to the Blood Vessels and Blood

Our large, complex bodies need blood to deliver nutrients to and remove wastes from our trillions of cells. The heart, as discussed in the previous chapter, pumps blood throughout the body in a network of blood vessels. Together, these three components—blood, heart, and vessels—make up the cardiovascular system.

Virtually every cell, tissue, organ, and system in the body is impacted by the circulatory system. This includes the generalized and more specialized functions of transport of materials, capillary exchange, maintaining health by transporting white blood cells and various immunoglobulins (antibodies), hemostasis, regulation of body temperature, and helping to maintain **acid-base** balance. Table 10.1 summarizes the important relationships between the circulatory system and the other body systems.

Table 10.1 Interaction of the Circulatory System with Other Body Systems. A table depicting the various body systems and the role of the circulatory system in each. Adapted from Betts et al., 2013. Licensed under CC BY 4.0.

SYSTEM	ROLE OF CIRCULATORY SYSTEM
Digestive	Absorbs nutrients and water; delivers nutrients (except most lipids) to the liver for processing by hepatic portal vein; provides nutrients essential for hematopoiesis and building hemoglobin.

SYSTEM	ROLE OF CIRCULATORY SYSTEM
Endocrine 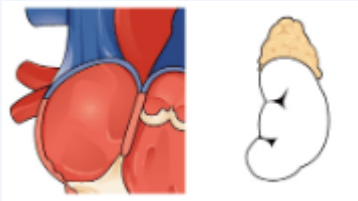	Delivers hormones; atrial natriuretic hormone (peptide) secreted by the heart atrial cells to help regulate blood volumes and pressures; epinephrine, ANH, angiotensin II, ADH, and thyroxine to help regulate blood pressure; estrogen to promote vascular health in women and men.
Integumentary	Carries clotting factors, platelets, and white blood cells for hemostasis, fighting infection, and repairing damage; regulates temperature by controlling blood flow to the surface, where heat can be dissipated; provides some coloration of integument; acts as a blood reservoir.
Lymphatic	Transports various white blood cells, including those produced by lymphatic tissue, and immunoglobulins (antibodies) throughout the body to maintain health; carries excess tissue fluid not able to be reabsorbed by the vascular capillaries back to the lymphatic system for processing.
Muscular	Provides nutrients and oxygen for contraction; removes lactic acid and distributes heat generated by contraction; muscular pumps aid in venous return; exercise contributes to cardiovascular health and helps to prevent atherosclerosis.
Nervous	Produces cerebrospinal fluid (CSF) within choroid plexuses; contributes to blood-brain barrier; cardiac and vasomotor centers regulate cardiac output and blood flow through vessels via the autonomic system.

SYSTEM	ROLE OF CIRCULATORY SYSTEM
Reproductive 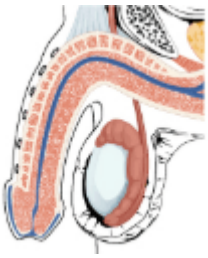	Aids in the erection of genitalia in both sexes during sexual arousal; transports gonadotropic hormones that regulate reproductive functions.
Respiratory	Provides blood for a critical exchange of gases to carry oxygen needed for metabolic reactions and carbon dioxide generated as byproducts of these processes.
Skeletal	Provides calcium, phosphate, and other minerals critical for bone matrix; transports hormones regulating buildup and absorption of matrix including growth hormone (somatotropin), thyroid hormone, calcitonin, and parathyroid hormones; erythropoietin stimulates myeloid cell hematopoiesis; some level of protection for select vessels by bony structures.
Urinary	Delivers 20% of resting circulation to kidneys for filtering, reabsorption of useful products, and secretion of excesses; regulates blood volume and pressure by regulating fluid loss in the form of urine and by releasing the enzyme renin that is essential in the renin-angiotensin-aldosterone mechanism.

Watch this video:

YouTube Video

This interactive element is not available in this format. Visit the link or scan the QR code to access it online.

View this YouTube Video online

Media 10.1 Blood Vessels, Part 1 – Form and Function: Crash Course A&P #27 [Online video]. Copyright 2015 by CrashCourse.

Practice Medical Terms Related to the Blood Vessels and Blood

Query 1.10.2

This interactive element is not available in this format. Visit the link or scan the QR code to access it online.

View this Interactive Content online

Anatomy of the Blood Vessels

Blood pumped by the heart flows through a series of vessels known as arteries, arterioles, capillaries, venules, and veins before returning to the heart.

- **Arteries** transport blood away from the heart and branch into smaller vessels, forming arterioles.
- **Arterioles** distribute blood to capillary beds, the sites of exchange with the body tissues.
- A **capillary** is a microscopic channel that supplies blood to the tissues themselves, a process called **perfusion.**
  - Exchange of gases and other substances occurs in the capillaries between the blood and the surrounding cells and their tissue fluid (interstitial fluid).
  - For capillaries to function, their walls must be leaky, allowing substances to pass through.
  - Capillaries lead back to small vessels known as venules**.**
- **Venules** are small veins that converge into larger veins.
- A **vein** is a blood vessel that conducts blood toward the heart
  - Compared to arteries, veins are thin-walled vessels with large and irregular lumens
  - Larger veins are commonly equipped with valves that promote the unidirectional flow of blood toward the heart and prevent backflow toward the capillaries caused by the inherent low blood pressure in veins as well as the pull of gravity
  - Other ways in which the body assists the transport of venous blood back to the heart involve contractions of skeletal muscles in the extremities (see figure below), as well as pressure variations caused by breathing motion in the chest.

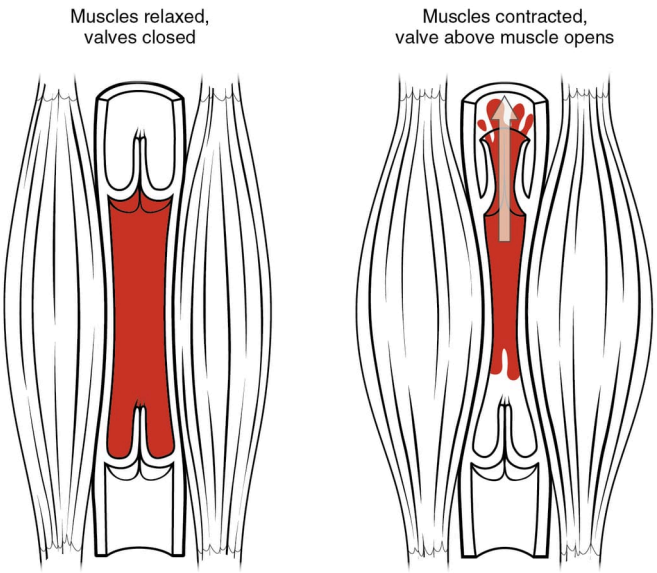

Figure 10.1 Skeletal Muscle Pump. The contraction of skeletal muscles surrounding a vein compresses the blood and increases the pressure in that area. This action forces blood closer to the heart where venous pressure is lower. Note the importance of the one-way valves to assure that blood flows only in the proper direction. From Betts et al., 2013. Licensed under CC BY 4.0. [Image description.]

Concept Check

- Select the correct bolded word: Arteries always carry blood **away from/towards** the heart
- Select the correct bolded word: Veins always carry blood **away from/towards** the heart.

Both arteries and veins have the same three distinct tissue layers, called **tunics**, for the garments first worn by ancient Romans. From the most interior layer to the outer, these tunics are the **tunica intima,** the **tunica media**, and the **tunica externa** (see Figure 10.3). The smooth muscle in the middle layer, the tunica media, provides the vessel with the ability to vasoconstrict and vasodilate as needed to ensure sufficient blood flow.

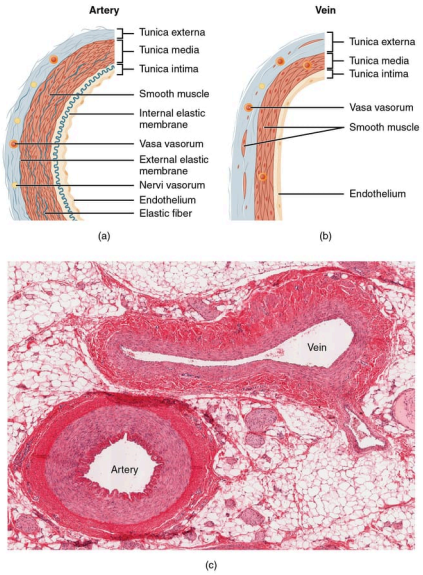

Figure 10.2 Structure of Blood Vessels. (a) Arteries and (b) veins share the same general features, but the walls of arteries are much thicker because of the higher pressure of the blood that flows through them. (c) A micrograph shows the relative differences in thickness. LM × 160. (Micrograph provided by the Regents of the University of Michigan Medical School © 2012). From Betts et al., 2013. Licensed under CC BY 4.0. [Image description.]

The table below compares the features of arteries and veins.

Table 10.2. Comparison of Arteries and Veins. From Betts et al., 2013. Licensed under CC BY 4.0.

CHARACTERISTIC	ARTERIES	VEINS
Direction of blood flow	Conducts blood away from the heart	Conducts blood toward the heart
General appearance	Rounded	Irregular, often collapsed
Pressure	High	Low
Wall thickness	Thick	Thin
Relative oxygen concentration	Higher in systemic arteries	Higher in pulmonary veins
	Lower in pulmonary arteries	Lower in systemic veins
Valves	Not present	Present most commonly in limbs and in veins inferior to the heart

The Major Arteries and Veins in the Human Body

Many arteries and veins share the same names, parallel one another throughout the body, and are very similar on the right and left sides of the body. For example, you will find a pair of femoral arteries and a pair of femoral veins, with one vessel on each side of the body. In contrast, some vessels closer to the midline of the body, such as the aorta, are unique and not paired. Names of vessels may change with location. Like a street that changes name as it passes through an intersection, an artery or vein can change names as it passes an anatomical landmark. For example, the left subclavian artery becomes the axillary artery as it passes into the axillary region, and then becomes the brachial artery as it enters the upper arm. The next two diagrams illustrate the major arteries and veins in the human body.

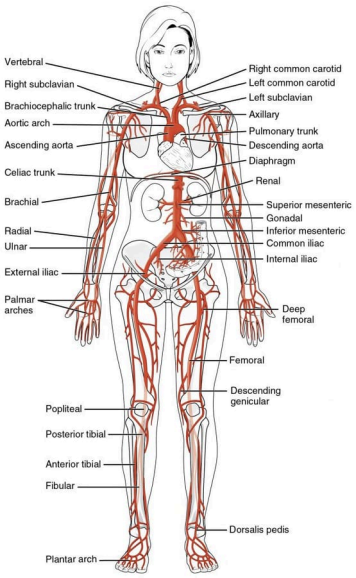

Figure 10.3 Systemic Arteries. The major systemic arteries shown here deliver oxygenated blood throughout the body. From Betts et al., 2013. Licensed under CC BY 4.0. [Image description.]

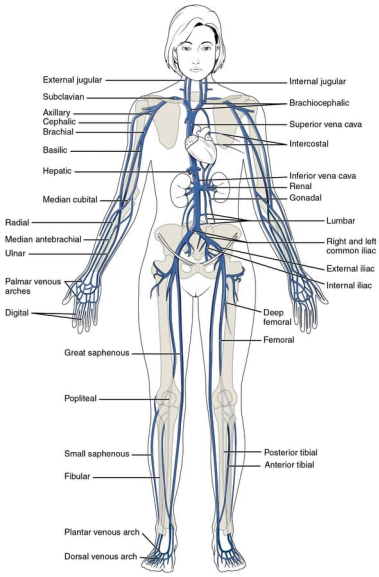

Figure 10.4 Major Systemic Veins of the Body. The major systemic veins of the body are shown here in an anterior view. From Betts et al., 2013. Licensed under CC BY 4.0. [Image description.]

Concept Check

- Without looking back at the images of the main arteries and veins of the body, can you **name** and **locate** 3 arteries and 3 veins in your body?

Physiology of the Blood Vessels

Arteries and veins transport blood in two distinct circuits: the systemic circuit and the pulmonary circuit. Systemic arteries provide blood rich in oxygen to the body's tissues. The blood returned to the heart through systemic veins has less oxygen, since much of the oxygen carried by the arteries has been delivered to the cells. In contrast, in the pulmonary circuit, arteries carry blood low in oxygen exclusively to the lungs for gas exchange. Pulmonary veins then return freshly oxygenated blood from the lungs to the heart to be pumped back out into systemic circulation.

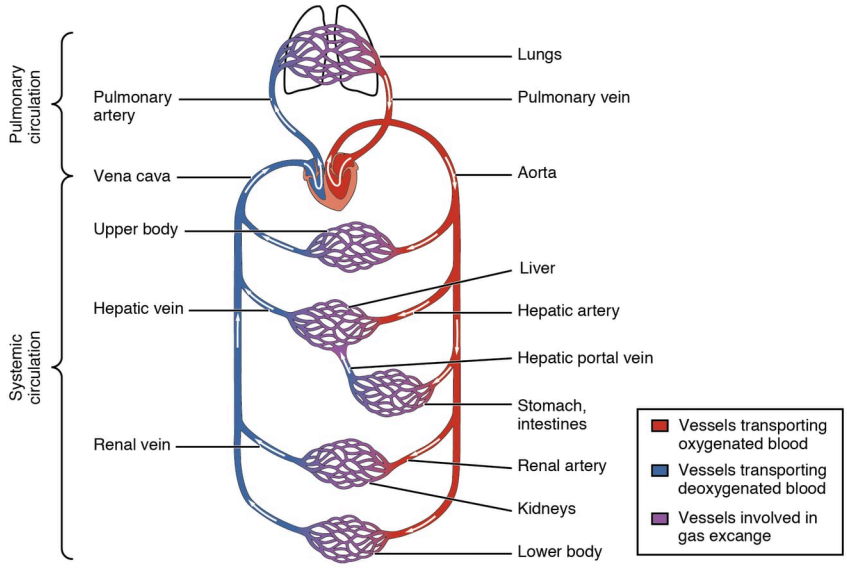

Figure 10.5 Cardiovascular Circulation. The pulmonary circuit moves blood from the right side of the heart to the lungs and back to the heart. The systemic circuit moves blood from the left side of the heart to the head and body and returns it to the right side of the heart to repeat the cycle. The arrows indicate the direction of blood flow, and the colors show the relative levels of oxygen concentration. From Betts et al., 2013. Licensed under CC BY 4.0. [Image description.]

Blood Pressure

Blood pressure is the force exerted by blood upon the walls of the blood vessels or the chambers of the heart. Blood pressure may be measured in capillaries and veins, as well as the vessels of the pulmonary circulation; however, the general term “blood pressure” refers to the pressure of blood flowing in the arteries of the systemic circulation. Blood pressure is one of the critical parameters measured on virtually every patient in every healthcare setting. The technique used today was developed more than 100 years ago by a pioneering Russian physician, Dr. Nikolai Korotkoff. Turbulent blood flow through the vessels can be heard as a soft ticking while measuring blood pressure; these sounds are known as Korotkoff sounds.Blood pressure is measured in mm Hg and is usually obtained from the brachial artery using a sphygmomanometer and a stethoscope. Blood pressure is recorded as systolic pressure over diastolic pressure.

Five variables influence blood flow and blood pressure:

- Cardiac output
- Vessel compliance
- Volume of the blood
- Viscosity of the blood
- Blood vessel length and diameter

Did you know?

120/80 mm Hg is a normal, healthy blood pressure. **60 to 100** beats per minute is a normal, resting, adult pulse.

Pulse

Each time the heart ejects blood forcefully into the circulation, the arteries must expand and then **recoil** to accommodate the surge of blood moving through them. This expansion and recoiling of the arterial wall is called the **pulse** and allows us to measure heart rate. Pulse can be palpated manually by placing the tips of the fingers across an artery that runs close to the body surface, such as the radial artery or the common carotid artery. These sites and other pulse sites are shown in the figure below.

Both the rate and the strength of the pulse are important clinically. A high or irregular pulse rate can be caused by physical activity or other temporary factors, but it may also indicate a heart condition. The pulse strength indicates the strength of ventricular contraction and cardiac output. If the pulse is strong, then systolic pressure is high. If it is weak, systolic pressure has fallen, and medical intervention may be warranted.

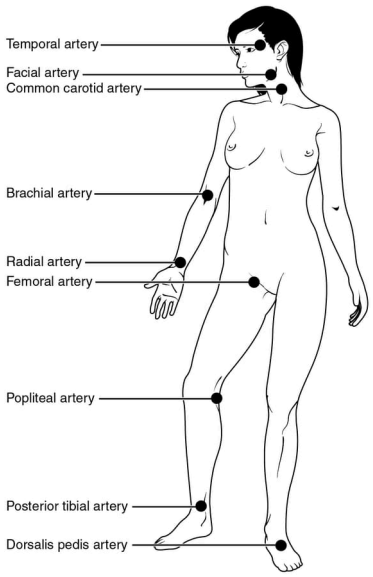

Figure 10.6 Pulse Sites. The pulse is most readily measured at the radial artery, but can be measured at any of the pulse points shown. From Betts et al., 2013. Licensed under CC BY 4.0. [Image description.]

The Composition (Anatomy) of Blood and the Functions of the Components

Blood is a connective tissue made up of cellular elements and an extracellular matrix. The cellular elements are referred to as the **formed elements** and include **red blood cells (RBCs)**, **white blood cells (WBCs)**, and **platelets**. The extracellular matrix, called **plasma**, makes blood unique among connective tissues because it is fluid. This fluid, which is mostly water, perpetually suspends the formed elements and enables them to circulate throughout the body within the cardiovascular system. In the laboratory, blood samples are often centrifuged in order to separate the components of blood from one another (see the figure below). Erythrocytes are the heaviest elements in blood and settle at the very bottom of the tube. Above the erythrocyte layer we see the **buffy coat**, a pale, thin layer of leukocytes and thrombocytes, which together make up less than 1% of the sample of whole blood. Above the buffy coat is the blood plasma, normally a pale, straw-colored fluid, which constitutes the remainder of the sample.

In normal blood, about 45% of a sample is erythrocytes, which is referred to as the hematocrit. The hematocrit of any one sample can vary significantly, however, about 36 to 50%, according to gender and other factors. Not counting the buffy coat, which makes up less than 1% of the blood, we can estimate the mean plasma percentage to be the percent of blood that is not erythrocytes: approximately 55%.

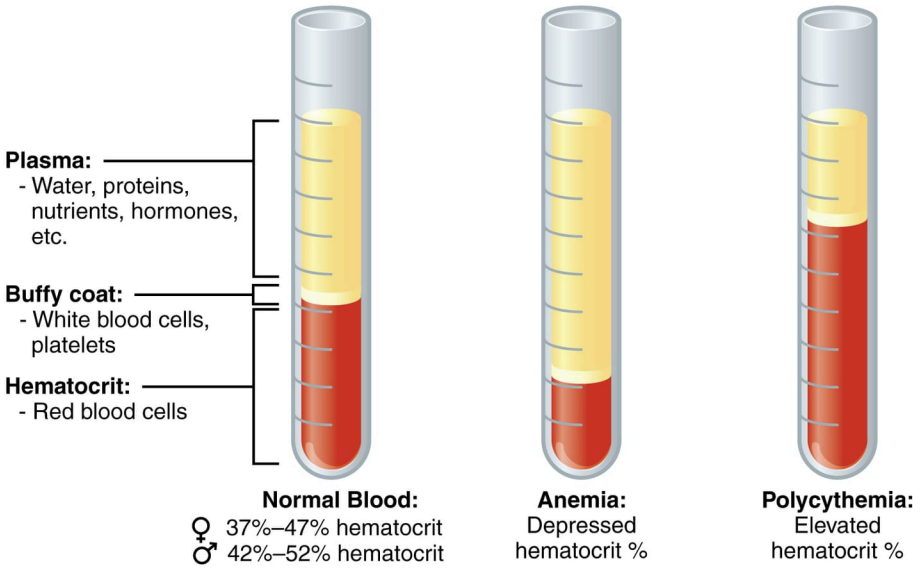

Figure 10.7 Composition of Blood. The cellular elements of blood include a vast number of erythrocytes and comparatively fewer leukocytes and platelets. Plasma is the fluid in which the formed elements are suspended. A sample of blood spun in a centrifuge reveals that plasma is the lightest component. It floats at the top of the tube separated from the heaviest elements, the erythrocytes, by a buffy coat of leukocytes and platelets. Hematocrit is the percentage of the total sample that is composed of erythrocytes. Depressed and elevated hematocrit levels are shown for comparison. From Betts et al., 2013. Licensed under CC BY 4.0. [Image description.]

The table below provides a useful summary of the components of blood and their functions.

Table 10.3 Major Blood Components. This table displays the components of blood and their associated functions. Adapted from Betts et al., 2013. Licensed under CC BY 4.0.

COMPONENT AND % OF BLOOD	SUBCOMPONENT AND % OF COMPONENT	TYPE AND % (WHERE APPROPRIATE)	SITE OF PRODUCTION	MAJOR FUNCTION(S)
Plasma 46 – 63 percent	Water 92 percent	Fluid	Absorbed by intestinal tract or produced by metabolism	Transport medium
	Plasma proteins	Albumin 54 – 60 percent	Liver	Maintain osmotic concentration, transport lipid molecules
		Globulins 35 – 38 percent	Alpha globulins – liver	Transport, maintain osmotic concentration
			Beta globulins – liver	Transport, maintain osmotic concentration
			Gamma globulins (immunoglobulins) – plasma cells	Immune responses
		Fibrinogen 4 – 7 percent	Liver	Blood clotting in hemostasis

COMPONENT AND % OF BLOOD	SUBCOMPONENT AND % OF COMPONENT	TYPE AND % (WHERE APPROPRIATE)	SITE OF PRODUCTION	MAJOR FUNCTION(S)
	Regulatory proteins < 1 percent	*Hormones and enzymes*	*Various sources*	*Regulate various body functions*
	Other solutes 1 percent	*Nutrients, gases, and wastes*	*Absorbed by intestinal tract, exchanged in respiratory system, or produced by cells*	*Numerous and varied*
Formed elements 37 – 54 percent	*Erythrocytes 99 percent*	*Erythrocytes*	*Red bone marrow*	*Transport gases, primarily oxygen and some carbon dioxide*
	Leukocytes < 1 percent Platelets < 1 percent	*Granular Leukocytes: neutrophils eosinophils basophils*	*Red bone marrow*	*Nonspecific immunity*
		Agranular leukocytes: lymphocytes monocytes	*Lymphocytes: bone marrow and lymphatic tissue*	*Lymphocytes: specific immunity*
			Monocytes: redbone marrow	*Monocytes: nonspecific immunity*
	Platelets < 1 percent	*n/a*	*Megakaryocytes: Red Bone Marrow*	*Hemostasis*

Did you know?

Blood constitutes approximately 8% of adult body weight.

Concept Check

Use the table above to answer these questions:

- What substance makes up *most* of the plasma?
- What are some general functions of plasma and its components?
- What is the function of **erythrocytes**?
- What is the overall function of **leukocytes**? (Hint: which word appears in all 3 chart cells that list leukocyte functions?)
- What is the function of **platelets**?

Blood Plasma

Like other fluids in the body, plasma is composed primarily of water. In fact, it is about 92% water. Dissolved or suspended

within this water is a mixture of substances, most of which are proteins. The major components of plasma and their functions are summarized in the table above.

Formed Elements (Erythrocytes, Leukocytes, Thrombocytes)

The table below summarizes the main facts about the formed elements in blood.

Table 10.4 Summary of Formed Elements in Blood. Adapted from Betts et al., 2013. Licensed under CC BY 4.0.

FORMED ELEMENT	MAJOR SUBTYPES	NUMBER PRESENT PER MICROLITER (µL) AND MEAN (RANGE)	APPEARANCE IN A STANDARD BLOOD SMEAR	SUMMARY OF FUNCTIONS	COMMENTS
Erythrocytes (red blood cells) Red Blood Cell	n/a	5.2 million (4.4-5.0 million)	Flattened biconcave disk; no nucleus; pale red color	Transport oxygen and some carbon dioxide between tissues and lungs	Lifespan of approximately 120 days
Leukocytes (white blood cells)	n/a	7000 (5000 – 10,000)	Obvious dark-staining nucleus	All function in body defenses	Exit capillaries and move into tissues; lifespan of usually a few hours or days
Leukocytes (white blood cells) Types	**Granulocytes including neutrophils, eosinophils, and basophils**	**4360 (1800-9950)**	**Abundant granules in cytoplasm; nucleus normal lobed**	**Nonspecific (innate) resistance to disease**	**Classified according to membrane-bound granules in cytoplasm**
	Neutrophils 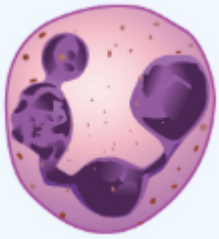 Neutrophil Cell	4150 (1800-7300)	Nuclear lobes increase with age; pale lilac granules	Phagocytic; particularly effective against bacteria. Release cytotoxic chemicals from granules	Most common leukocyte; lifespan of minutes to days

FORMED ELEMENT	MAJOR SUBTYPES	NUMBER PRESENT PER MICROLITER (μL) AND MEAN (RANGE)	APPEARANCE IN A STANDARD BLOOD SMEAR	SUMMARY OF FUNCTIONS	COMMENTS
	Eosinophils 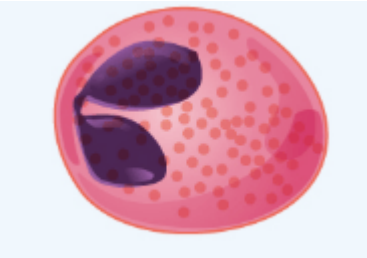 Eosinophils Cell	165 (0-700)	Nucleus generally two-lobed; bright red-orange granules	Phagocytic cells; particularly effective with antigen-antibody complexes. Release antihistamines. Increase in allergies and parasitic infections	Lifespan of minutes to days
	Basophils 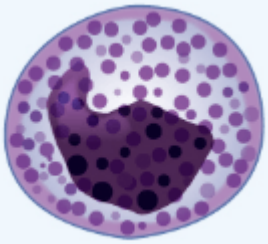 Basophil Cell	44 (0-150)	Nucleus generally two-lobed but difficult to see due to presence of heavy, dense, dark purple granules	Promotes inflammation	Least common leukocyte; lifespan unknown
	Agranulocytes including lymphocytes and monocytes	2640 (1700-4950)	Lack abundant granules in cytoplasm; have a simple-shaped nucleus that may be indented	Body defenses	Group consists of two major cell types from different lineages

FORMED ELEMENT	MAJOR SUBTYPES	NUMBER PRESENT PER MICROLITER (µL) AND MEAN (RANGE)	APPEARANCE IN A STANDARD BLOOD SMEAR	SUMMARY OF FUNCTIONS	COMMENTS
	Lymphocytes Lymphocytes Cell	2185 (1500-4000)	Spherical cells with a single often large nucleus occupying much of the cell's volume; stains purple; see in large (natural killer cells) and small (B and T cells) variants	Primarily specific (adaptive) immunity; T cells directly attack other cells (cellular immunity). B cells release antibodies (humoral immunity); natural killer cells are similar to T cells but nonspecific	Initial cells originate in bone marrow, but secondary production occurs in lymphatic tissue; several distinct subtypes; memory cells form after exposure to a pathogen and rapidly increase responses to subsequent exposure; lifespan of many years
	Monocytes Monocytes Cell	455 (200-950)	Largest leukocyte with an indented or horseshoe-shaped nucleus	Very effective phagocytic cells engulfing pathogens or worn-out cells; also serve as antigen-presenting cells (APCs) for other components of the immune system	Produced in red bone marrow; referred to as macrophages after leaving circulation
Platelets Platelet Cells	n/a	350,000 (150,000 – 500,000)	Cellular fragments surrounded by a plasma membrane and containing granules; purple stain	Hemostasis plus release growth factors for repair and healing of tissue	Formed from megakaryocytes that remain in the red bone marrow and shed platelets into circulation

Hemopoiesis/Hematopoiesis

The lifespan of the formed elements is very brief. Although one type of leukocyte (memory cells) can survive for years, most erythrocytes, leukocytes, and platelets normally live only a few hours to a few weeks. Thus, the body must form new blood cells and platelets quickly and continuously, a process known as hemopoiesis.

In children, hemopoiesis can occur in the medullary cavity of long bones; in adults, the process is largely restricted to the cranial and pelvic bones, the vertebrae, the sternum, and the proximal epiphyses of the femur and humerus. Throughout adulthood, the liver and spleen maintain their ability to generate the formed elements. This process is referred to as extramedullary hematopoiesis. When a disease such as bone cancer destroys the bone marrow, causing hemopoiesis to fail, extramedullary hematopoiesis may be initiated .

All formed elements arise from stem cells of the red bone marrow, called hematopoietic stem cells, or hemocytoblast. Hemopoiesis begins when the hematopoietic stem cell is exposed to appropriate chemical stimuli collectively called hemopoietic growth factors, which prompt it to divide and differentiate. One daughter cell remains a hematopoietic stem cell, allowing hemopoiesis to continue. The other daughter cell becomes either of two types of more specialized stem cells. Follow the chart below from top to bottom to learn how stem cells become mature formed elements of blood.

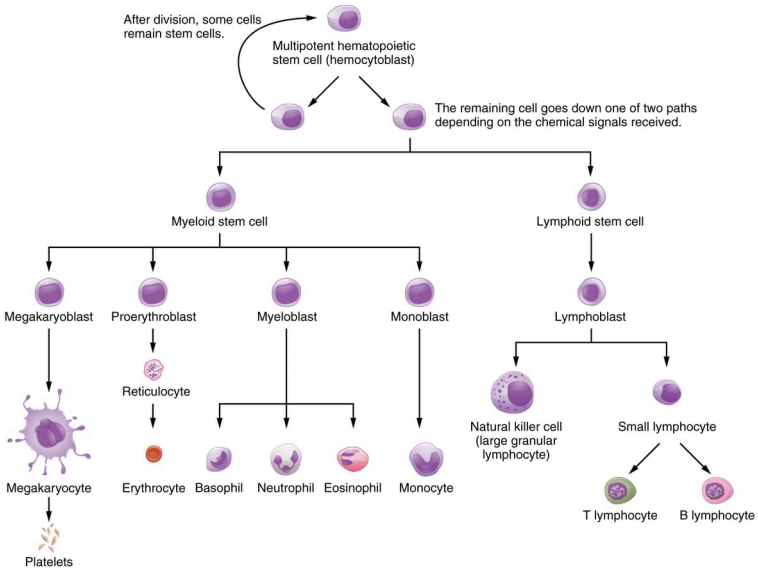

Figure 10.8 Hematopoietic System of Bone Marrow. Hemopoiesis is the proliferation and differentiation of the formed elements of blood. From Betts et al., 2013. Licensed under CC BY 4.0. [Image description.]

Erythrocytes

The most abundant formed elements in blood, erythrocytes are basically sacs packed with an oxygen-carrying compound called hemoglobin. Production of erythrocytes in the red bone marrow occurs at the staggering rate of more than 2 million cells per second. For this production to occur, raw materials including iron, copper, zinc B-vitamins, glucose, lipids, and amino acids must be present in adequate amounts. Erythrocytes live only 120 days on average, and thus must be continually replaced. Worn-out erythrocytes are phagocytized by macrophages and their hemoglobin is broken down. The breakdown products are recycled or removed as wastes.

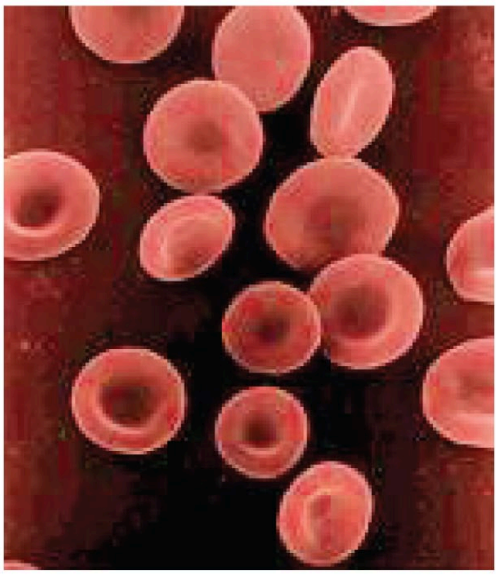

Figure 10.9 Shape of Red Blood Cells. Erythrocytes are biconcave discs with very shallow centers. This shape optimizes the ratio of surface area to volume, facilitating gas exchange. It also enables them to fold up as they move through narrow blood vessels. From Betts et al., 2013. Licensed under CC BY 4.0. [Image description.]

Leukocytes

Leukocytes protect the body against invading microorganisms and body cells with mutated DNA, and they clean up debris; thus, they are a major component of the body's defenses against disease. Figure 10.10 shows the different types of leukocytes.

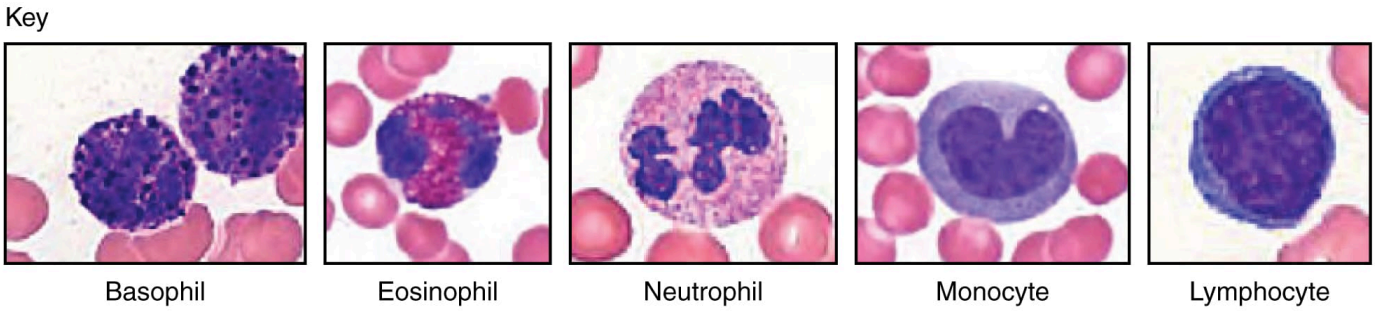

Figure 10.10 Leukocytes. (Micrographs provided by the Regents of University of Michigan Medical School © 2012). From Betts et al., 2013. Licensed under CC BY 4.0. [Image description.]

Concept Check

- What is **hemoglobin**?
- Can you name the 5 types of **leukocytes**?

Leukocytes routinely leave the bloodstream to perform their **defensive** functions in the body's tissues, where they are often given distinct names, such as **macrophage** or **microglia**, depending on their function. As shown in Figure 10.11 below, they leave the capillaries—the smallest blood vessels—or other small vessels through a process known as **emigration** or **diapedesis** in which they squeeze through adjacent cells in a blood vessel wall.

Once they have exited the capillaries, some leukocytes will take up fixed positions in lymphatic tissue, bone marrow, the spleen, the thymus, or other organs. Others will move about through the tissue spaces, sometimes wandering freely, and sometimes moving toward the direction in which they are drawn by chemical signals, a mechanism known as **positive chemotaxis.**

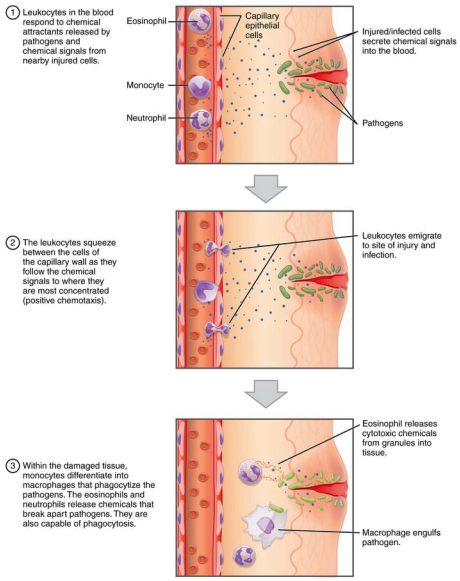

Figure 10.11 Emigration. Leukocytes exit the blood vessel and then move through the connective tissue of the dermis toward the site of a wound. Some leukocytes, such as the eosinophil and neutrophil, are characterized as granular leukocytes. They release chemicals from their granules that destroy pathogens; they are also capable of phagocytosis. The monocyte differentiates into a [pb_glossary id="411"]macrophage[/pb_glossary] that then [pb_glossary id="413"]phagocytizes[/pb_glossary] the pathogens. From Betts et al., 2013. Licensed under CC BY 4.0. [Image description.]

Lymphocytes

Lymphocytes are a type of leukocyte. The three major groups of lymphocytes include natural killer cells, B cells, and T cells.

- **Natural killer (NK) cells** are capable of recognizing cells that do not express “self” proteins on their plasma membrane or that contain foreign or abnormal markers. These “nonself” cells include cancer cells, cells infected with a virus, and other cells with atypical surface proteins.
- **B lymphocytes (B cells)** and **T lymphocytes (T cells)**, play prominent roles in defending the body against specific pathogens (disease-causing microorganisms) and are involved in specific immunity. B cells undergo a maturation process in the bone marrow, whereas T cells undergo maturation in the thymus. This site of the maturation process gives rise to the name B and T cells.
  - **Plasma cells**, a type of B cell, produce the antibodies or immunoglobulins that bind to specific foreign or abnormal components of plasma membranes.
  - **T cells** provide immunity by physically attacking foreign or diseased cells.
  - **Memory cells** are a variety of both B and T cells that form after exposure to a pathogen and mount rapid responses upon subsequent exposures. Unlike other leukocytes, memory cells live for many years.

Platelets

After entering the circulation, approximately one-third of the newly-formed platelets migrate to the spleen for storage for later release in response to any rupture in a blood vessel. They then become activated to perform their primary function, which is to limit blood loss. Platelets remain only about 10 days, then are phagocytized by macrophages.

Platelets are key players in **hemostasis**, the process by which the body seals a ruptured blood vessel and prevents further loss of blood. Although rupture of larger vessels usually requires medical intervention, hemostasis is quite effective in dealing with small, simple wounds. There are three steps to the process: vascular spasm, the formation of a platelet plug, and coagulation (blood clotting). Failure of any of these steps will result in **hemorrhage.** The figure below summarizes the steps of hemostasis.

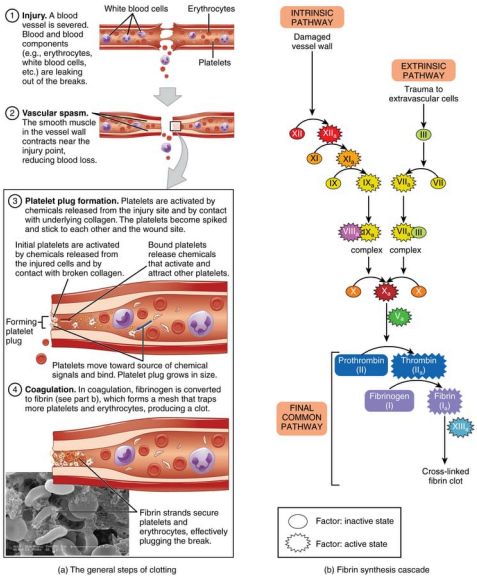

Figure 10.12 Hemostasis. (a) An injury to a blood vessel initiates the process of hemostasis. Blood clotting involves three steps. First, vascular spasm constricts the flow of blood. Next, a platelet plug forms to temporarily seal small openings in the vessel. Coagulation then enables the repair of the vessel wall once the leakage of blood has stopped. (b) The synthesis of fibrin in blood clots involves either an intrinsic pathway or an extrinsic pathway, both of which lead to a common pathway. (credit: Kevin MacKenzie). From Betts et al., 2013. Licensed under CC BY 4.0. [Image description.]

Fibrinolysis is the process in which a clot is degraded in a healing vessel. An **anticoagulant** is any substance that opposes coagulation. Several circulating plasma anticoagulants play a role in limiting the coagulation process to the region of injury and restoring a normal, clot-free condition of blood.

Concept Check

- Can you explain what happens in each step of **hemostasis**?
- Describe an **anticoagulant**.

Physiology of Blood

Although carrying oxygen and nutrients to cells and removing wastes from cells is the main function of blood, it is important to realize that blood also serves in defense, distribution of heat, and maintenance of homeostasis.

Transportation

Nutrients from the foods you eat are absorbed in the digestive tract. Most of these travel in the bloodstream directly to the liver, where they are processed and released back into the bloodstream for delivery to body cells.

Oxygen from the air you breathe diffuses into the blood, which moves from the lungs to the heart, which then pumps it out to the rest of the body.

Endocrine glands scattered throughout the body release their products, called **hormones**, into the bloodstream, which carries them to distant target cells.

Blood also picks up **cellular wastes** and byproducts, and transports them to various organs for removal. For instance, blood moves carbon dioxide to the lungs for **exhalation** from the body, and various waste products are transported to the kidneys and liver for excretion from the body in the form of urine or bile.

Defense

Leukocytes protect the organism from disease-causing bacteria, cells with **mutated** DNA that could multiply to become cancerous, or body cells infected with viruses.

When damage to the vessels results in bleeding, blood platelets and certain proteins dissolved in the plasma, interact to block the ruptured areas of the blood vessels involved. This protects the body from further blood loss.

Homeostasis

If you were exercising on a warm day, your rising core body temperature would trigger several homeostatic mechanisms, including increased transport of blood from your core to your body periphery, which is typically cooler. As blood passes through the vessels of the skin, heat would be dissipated to the environment, and the blood returning to your body core would be cooler. In contrast, on a cold day, blood is diverted away from the skin to maintain a warmer body core. In extreme cases, this may result in frostbite.

Blood helps to regulate the water content of body cells. Blood also helps to maintain the chemical balance of the body. Proteins and other compounds in blood act as buffers, which thereby help to regulate the pH of body tissues. The pH of blood ranges from 7.35 to 7.45.

Concept Check

These three terms all sound similar. Can you explain them by breaking down the word parts?

- Hemostasis
- Homeostasis
- Hematopoiesis

Blood Types

In order to understand blood types, it is important to understand several terms that relate to the body's **immune** functions (discussed in detail in the next chapter).

- Antigens are substances that the body does not recognize as belonging to itself ("self") and that therefore trigger a **defensive response** from the leukocytes of the immune system. Many people have antigens on the surfaces of their red blood cells. More than 50 antigens have been identified on erythrocyte membranes, but the most significant in terms of their potential harm to patients are classified in two groups: the ABO blood group and the Rh blood group.
- Antibodies are proteins which are produced by plasma cells in response to a "non-self" antigen being present in the body. Antibodies attach to the antigens on the plasma membranes of the erythrocytes in a blood transfusion and cause them to adhere to one another.
- **Agglutination** refers to the resulting clumps of red blood cells that are formed in such an antigen-antibody reaction. These clumps can block small blood vessels, thereby cutting off the supply of oxygen and nutrients to the tissues.
- Hemolysis, or the breakdown of the erythrocyte's cell membrane, takes place as the clumps of red cells start to degrade. The resulting release of the cell's contents, mainly hemoglobin, into the bloodstream can cause kidney failure.

ABO Blood Group

ABO blood types are **genetically** determined. Each type is determined by the presence or absence of certain antigens on the individual's red blood cell membrane, as well as the presence or absence of certain antibodies. Normally the body must be exposed to a **foreign antigen** before an antibody can be produced. This is not the case for the ABO blood group, in which some blood types come preloaded with their own set of antibodies against another type. The table below shows the ABO blood group as well as the universal donor and recipient in relation to blood transfusions.

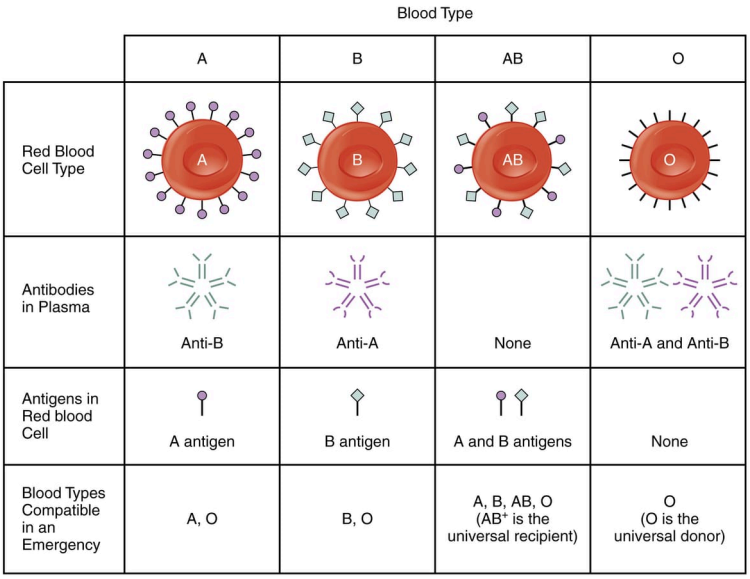

Figure 10.13 ABO Blood Groups. From Betts et al., 2013. Licensed under CC BY 4.0. [Image description.]

- Blood Type A
  - People whose erythrocytes have **A antigens** on their erythrocyte membrane surface.
  - People who have type A blood, without any prior exposure to incompatible blood, have preformed **anti-B antibodies** circulating in their blood. These antibodies will cause a serious immune reaction if they encounter blood that has B antigens.
- Blood Type B
  - People whose erythrocytes have **B antigens.**
  - People with type B blood have preformed **anti-A antibodies.**
- Blood Type AB
  - People can also have **both A and B antigens** on their erythrocytes, in which case they are blood type AB.
  - Individuals with type AB blood, **do not have preformed antibodies** to either A or B antigens.
- Blood Type O
  - People with **neither A nor B antigens** are designated blood type O.
  - People with type O blood have **both anti-A and anti-B antibodies** circulating in their blood plasma.

Rh Blood Group

The **Rh blood group** is classified according to the presence or absence of a second erythrocyte **antigen** identified as Rh. Those who have the Rh D antigen present on their erythrocytes are described as Rh positive (Rh^+) and those who lack it are Rh negative (Rh^-). Note that the Rh group is distinct from the ABO group, so any individual, no matter their ABO blood type, may have or lack this Rh antigen. When identifying a patient's blood type, the Rh group is designated by adding the word positive or negative to the ABO type. For example, A positive (A^+) means ABO group A blood with the Rh antigen present, and AB negative (AB^-) means ABO group AB blood without the Rh antigen.

Hemolytic Disease of the Newborn (HDN)

Antibodies to the Rh antigen are produced only in Rh^- individuals after exposure to the antigen. This process, called sensitization, occurs following a transfusion with Rh-incompatible blood or, more commonly, with the birth of an Rh^+ baby to an Rh^- mother.

- In a **first pregnancy** problems are rare**,** since the baby's Rh^+ cells rarely cross the placenta. However, during or immediately after birth, the Rh^- mother can be exposed to the baby's Rh^+ cells (Figure 10.14). Research has shown that this occurs in about 13 to 14% of such pregnancies. After exposure, the mother's immune system begins to generate anti-Rh antibodies.
- In a **second pregnancy** if a mother should conceive a Rh^+ baby, the Rh antibodies she has produced can cross the placenta into the fetal bloodstream and destroy the fetal RBCs. This condition, known as **hemolytic disease of the newborn (HDN)**

or erythroblastosis fetalis. This may cause anemia in mild cases, but the agglutination and hemolysis can be so severe that without treatment the fetus may die in the womb or shortly after birth.

- A drug known as RhoGAM, short for Rh immune globulin, can temporarily prevent the development of Rh antibodies in the Rh^- mother, thereby averting this potentially serious disease for the fetus. RhoGAM antibodies destroy any fetal Rh^+ erythrocytes that may cross the placental barrier. RhoGAM is normally administered to Rh^- mothers during weeks 26 to 28 of pregnancy and within 72 hours following birth.

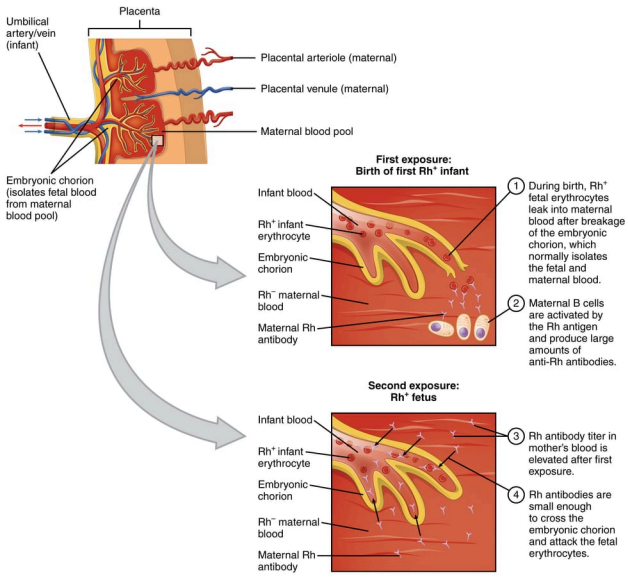

Figure 10.14 Erythroblastosis Fetalis. The first exposure of an Rh– mother to Rh+ erythrocytes during pregnancy induces sensitization. Anti-Rh antibodies begin to circulate in the mother's bloodstream. A second exposure occurs with a subsequent pregnancy with an Rh+ fetus in the uterus. Maternal anti-Rh antibodies may cross the placenta and enter the fetal bloodstream, causing agglutination and hemolysis of fetal erythrocytes. From Betts et al., 2013. Licensed under CC BY 4.0. [Image description.]

Blood Transfusions

Figure 10.15 is an example of a commercially produced "bedside" card which enables quick typing of both a recipient's and donor's blood before transfusion. The card contains three reaction sites or wells. One is coated with an anti-A antibody, one with an anti-B antibody, and one with an anti-D antibody (tests for the presence of Rh factor D). Mixing a drop of blood and saline into each well enables the blood to interact with a preparation of type-specific antibodies, also called anti-seras. Agglutination of RBCs in a given site indicates a positive identification of the blood antigens, in this case A and Rh antigens for blood type A+. To avoid serious and potentially fatal immune reactions, the donor's and recipient's blood types must match.

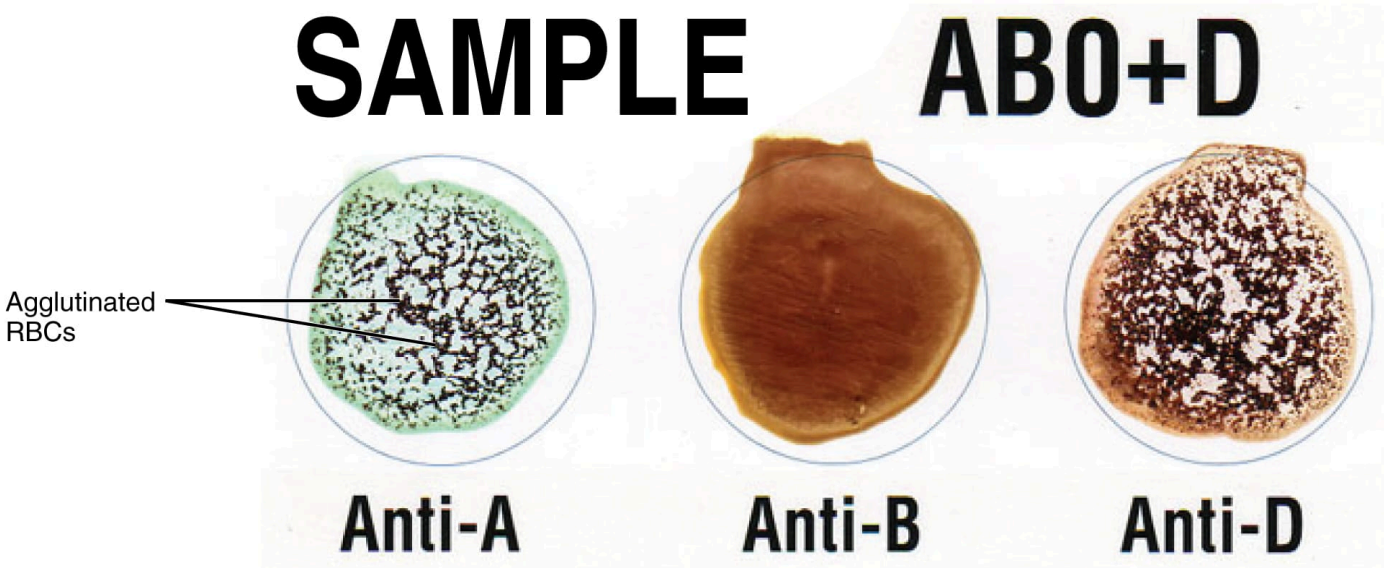

Figure 10.15. Cross Matching Blood Types. From Betts et al., 2013. Licensed under CC BY 4.0. [Image description.]

To avoid transfusion reactions, it is best to transfuse only matching blood types; that is, a type B^+ recipient should ideally receive blood only from a type B^+ donor and so on. That said, in emergency situations, when acute hemorrhage threatens the patient's life, there may not be time for cross-matching to identify blood type. In these cases, blood from a universal donor may be transfused.

Practice Terms Related to the Blood Vessels and Blood

Query 1.10.3

This interactive element is not available in this format. Visit the link or scan the QR code to access it online.

View this Interactive Content online

Diseases and Disorders of Blood Vessels and Blood

Arteriosclerosis

Arteriosclerosis is normally defined as the more generalized loss of compliance, or "hardening of the arteries." Atherosclerosis is a more specific term for the build-up of plaque in the walls of the vessel and is a specific type of arteriosclerosis.

When arteriosclerosis causes vessel compliance to be reduced, pressure and resistance within the vessel increase. This is a leading cause of hypertension and coronary heart disease, as it causes the heart to work harder to overcome this resistance. Any artery in the body can be affected by these pathological conditions, and individuals who have pathologies like coronary artery disease, may also be at risk for other vascular injuries, like strokes or peripheral arterial disease.

Atherosclerosis is a type of arteriosclerosis in which plaques form when circulating triglycerides, cholesterol and other substances seep between the damaged endothelial lining cells and become trapped within the artery wall, resulting in narrowed arteries and impaired blood flow (see Figure 10.16).

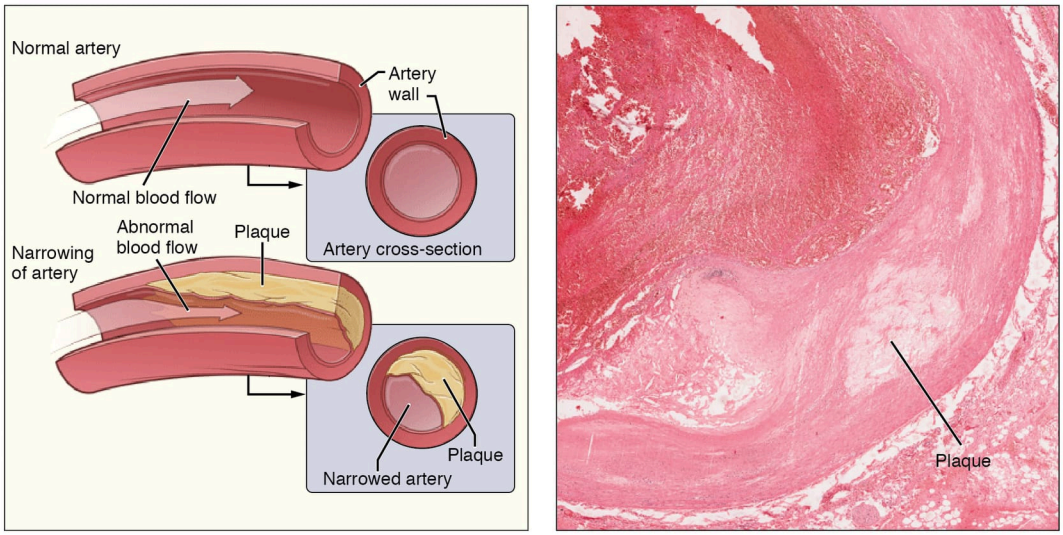

(a) (b)

Figure 10.16 Atherosclerosis. (a) Atherosclerosis can result from plaques formed by the buildup of fatty, calcified deposits in an artery. (b) Plaques can also take other forms, as shown in this micrograph of a coronary artery that has a buildup of connective tissue within the artery wall. LM × 40. (Micrograph provided by the Regents of University of Michigan Medical School © 2012). From Betts et al., 2013. Licensed under CC BY 4.0. [Image description.]

Sometimes a plaque can rupture, causing microscopic tears in the artery wall that allow blood to leak into the tissue on the other side. When this happens, platelets rush to the site to clot the blood. This clot can further obstruct the artery and—if it occurs in a coronary or cerebral artery—cause a sudden heart attack or stroke. Alternatively, plaque can break off and travel through the bloodstream as an embolus until it blocks a more distant, smaller artery.

Peripheral arterial disease (PAD; also called peripheral vascular disease [PVD]), occurs when atherosclerosis affects arteries in the legs. A major risk factor for both arteriosclerosis and atherosclerosis is advanced age, as the conditions tend to progress over time. There is also a distinct genetic component, and pre-existing hypertension and/or diabetes also greatly increase the risk. However, obesity, poor nutrition, lack of physical activity, and tobacco use all are major risk factors.

Treatment of atherosclerosis includes lifestyle changes, such as weight loss, smoking cessation, regular exercise, and adoption of a diet low in sodium and saturated fats. Medications to reduce cholesterol and blood pressure may be prescribed. For blocked coronary arteries, angioplasty or coronary artery bypass graft (CABG) surgery may be warranted. In a carotid endarterectomy, plaque is surgically removed from the walls of the carotid artery, which is the main source of oxygenated blood for the brain.

Edema and Varicose Veins

Despite the presence of valves and the contributions of other anatomical and physiological adaptations that assist in moving blood through veins, over the course of a day, some blood will inevitably pool, especially in the lower limbs, due to the pull of gravity. Any blood that accumulates in a vein will increase the pressure within it, which can then be reflected back into the smaller veins, venules, and eventually even the capillaries. This increased pressure in the capillaries will push fluids out of the capillaries and into the interstitial fluid, causing a condition called edema.

Most people experience a daily accumulation of tissue fluid, especially if they spend much of their work-life on their feet (like most health professionals). However, clinical edema goes beyond normal swelling and requires medical treatment. Edema has many potential causes, including hypertension and heart failure, severe protein deficiency, renal failure, and many others. In order to treat edema, which is a sign rather than a discrete disorder, the underlying cause must be diagnosed and alleviated.

Figure 10.17 Varicose Veins. Varicose veins are commonly found in the lower limbs. (credit: Thomas Kriese). From Betts et al., 2013. Licensed under CC BY 4.0. [Image description.]

Edema may be accompanied by varicose veins, especially in the superficial veins of the legs (see Figure 10.17). This disorder arises when defective valves allow blood to accumulate within the veins, causing them to distend, twist, and become visible on the surface of the skin. Varicose veins may occur in both sexes, but are more common in women and are often related to pregnancy. More than simple cosmetic blemishes, varicose veins are often painful and sometimes itchy or throbbing. Without treatment, they tend to grow worse over time. The use of a support hose, as well as elevating the feet and legs whenever possible, may be helpful in alleviating this condition.

Hypertension

Hypertension is defined as chronic and persistent blood pressure measurements of 140/90 mm Hg or above. Pressures between 120/80 and 140/90 mm Hg are defined as prehypertension. Hypertension is typically a silent disorder and patients may fail to recognize the seriousness of their condition and fail to follow their treatment plan, putting them at risk for a heart attack or stroke. Hypertension may also lead to an aneurysm, peripheral arterial disease, chronic kidney disease, or heart failure.

Hemorrhage

Minor blood loss is managed by hemostasis and repair. Hemorrhage is a loss of blood that cannot be controlled by hemostatic mechanisms. Initially, the body responds to hemorrhage by initiating mechanisms aimed at increasing blood pressure and maintaining blood flow. Ultimately, however, blood volume will need to be restored, either through physiological processes or through medical intervention. If blood loss is less than 20% of total blood volume, fast-acting homeostatic mechanisms causing increased cardiac output and vasoconstriction, would usually return blood pressure to normal and redirect the remaining blood to the tissues. Blood volume will then need to be restored via slower-acting homeostatic mechanisms, to increase body fluids and erythrocyte production.

Circulatory Shock

The loss of too much blood may lead to **circulatory shock**, a life-threatening condition in which the circulatory system is unable to maintain blood flow to adequately supply sufficient oxygen and other nutrients to the tissues to maintain cellular metabolism. It should not be confused with emotional or psychological shock. Typically, the patient in circulatory shock will demonstrate an increased heart rate but decreased blood pressure. Urine output will fall dramatically, and the patient may appear confused or lose consciousness. Unfortunately, shock is an example of a positive-feedback loop that, if uncorrected, may lead to the death of the patient.

There are several recognized forms of shock:

- **Hypovolemic shock** in adults is typically caused by hemorrhage, although in children it may be caused by fluid losses related to severe vomiting or diarrhea.
- **Cardiogenic shock** results from the inability of the heart to maintain cardiac output. Most often, it results from a myocardial infarction (heart attack), but it may also be caused by arrhythmias, valve disorders, cardiomyopathies, cardiac failure, or simply insufficient flow of blood through the cardiac vessels.
- **Vascular shock** occurs when arterioles lose their normal muscular tone and dilate dramatically. It may arise from a variety of causes, and treatments almost always involve fluid replacement and medications, called inotropic or pressor agents, which restore tone to the muscles of the vessels.
- **Anaphylactic shock** is a severe allergic response that causes the widespread release of histamines, triggering vasodilation throughout the body.
- **Obstructive shock**, as the name would suggest, occurs when a significant portion of the vascular system is blocked. It is not always recognized as a distinct condition and may be grouped with cardiogenic shock, including pulmonary embolism and cardiac tamponade. Treatments depend upon the underlying cause and, in addition to administering fluids intravenously, often include the administration of anticoagulants, removal of fluid from the pericardial cavity, or air from the thoracic cavity, and surgery as required. The most common cause is a pulmonary embolism. Other causes include stenosis of the aortic valve, cardiac tamponade, and a pneumothorax.

Erythrocyte Disorders

Changes in the levels of RBCs can have significant effects on the body's ability to effectively deliver oxygen to the tissues.

Anemia

The size, shape, and number of erythrocytes, and the number of hemoglobin molecules can have a major impact on a person's health. When the number of RBCs or hemoglobin is deficient, the general condition is called **anemia**. There are more than 400 types of anemia.

Anemia can be broken down into three major groups: those caused by blood loss, those caused by faulty or decreased RBC production, and those caused by excessive destruction of RBCs. In addition to these causes, various disease processes also can lead to anemias. These include chronic kidney diseases often associated with a decreased production of EPO, hypothyroidism, some forms of cancer, lupus, and rheumatoid arthritis.

Blood Loss Anemias:

Causes:

- Bleeding from wounds or other lesions, including ulcers, hemorrhoids, inflammation of the stomach (gastritis), and some cancers of the gastrointestinal tract
  - The excessive use of aspirin or other nonsteroidal anti-inflammatory drugs such as ibuprofen can trigger ulceration and gastritis
- Excessive menstruation and loss of blood during childbirth.

Anemias Caused by Faulty or Decreased RBC Production:

- **Sickle cell anemia**
  - A genetic disorder involving the production of an abnormal type of hemoglobin that delivers less oxygen to tissues and causes erythrocytes to assume a sickle (or crescent) shape (Figure 10.18).
- **Iron deficiency anemia**
  - The most common type of anemia and results when the amount of available iron is insufficient to allow the production of sufficient heme.
- **Vitamin deficiency anemia** (Generally insufficient vitamin B12 and folate).
- **Megaloblastic anemia** involves a deficiency of vitamin B12 and/or folate, often due to inadequate dietary intake.
- **Pernicious anemia** is caused by poor absorption of vitamin B12 and is often seen in patients with Crohn's disease, surgical removal of the intestines or stomach (common in some weight loss surgeries), intestinal parasites, and AIDS.

- **Aplastic anemia** is the condition in which myeloid stem cells are defective or replaced by cancer cells, resulting in insufficient quantities of RBCs being produced. This condition may be inherited, or it may be triggered by radiation, medication, chemotherapy, or infection.
- **Thalassemia** is an inherited condition typically occurring in individuals from the Middle East, the Mediterranean, African, and Southeast Asia, in which maturation of the RBCs does not proceed normally. The most severe form is called Cooley's anemia.

Figure 10.18 Sickle Cells. (credit: Janice Haney Carr). From Betts et al., 2013. Licensed under CC BY 4.0. [Image description.]

Did you know?

'O2 sat' or 'percent sat' is the percent saturation; that is, the percentage of hemoglobin sites occupied by oxygen in a patient's blood.

Polycythemia

Polycythemia is an elevated RBC count and is detected in a patient's elevated hematocrit. It can occur transiently in a person who is dehydrated; when water intake is inadequate or when water losses are excessive, the plasma volume falls. As a result, the hematocrit rises. A mild form of polycythemia is chronic, but normal, in people living at high altitudes. Some elite athletes train at high elevations specifically to induce this phenomenon. Finally, a type of bone marrow disease called polycythemia vera causes an excessive production of immature erythrocytes. Polycythemia vera can dangerously elevate the viscosity of blood, raising blood pressure and making it more difficult for the heart to pump blood throughout the body. It is a relatively rare disease that occurs more often in men than women, and is more likely to be present in patients over 60 years of age.

Platelet Disorders/Clotting Disorders

Thrombocytosis

Thrombocytosis is a condition in which there are too many platelets. This may trigger thrombosis, a potentially fatal disorder. A **thrombus** (plural = thrombi) is an aggregation of platelets, erythrocytes, and even WBCs typically trapped within a mass of fibrin strands. While the formation of a clot is a normal step in hemostasis, thrombi can form within an intact or only slightly damaged blood vessel, adhering to the vessel wall and decreasing or obstructing the flow of blood.

Thrombophilia

Thrombophilia, also called hypercoagulation, is a condition in which there is a tendency to form thrombosis. This may be an

inherited disorder or may be caused by other conditions including lupus, immune reactions to heparin, polycythemia vera, thrombocytosis, sickle cell disease, pregnancy, and even obesity.

When a portion of a thrombus breaks free from the vessel wall and enters the circulation, it is referred to as an **embolus**. An embolus that is carried through the bloodstream can be large enough to block a vessel critical to a major organ. When it becomes trapped, an embolus is called an **embolism**. In the heart, brain, or lungs, an embolism may accordingly cause a heart attack, a stroke, or a pulmonary embolism.

Thrombocytopenia

Thrombocytopenia is a condition in which there is an insufficient number of platelets, possibly leading to ineffective blood clotting and excessive bleeding.

Hemophilia

Hemophilia is a group of related genetic disorders in which certain plasma clotting factors are lacking or inadequate or nonfunctional. Patients with hemophilia bleed from even minor internal and external wounds, and leak blood into joint spaces after exercise and into urine and stool. Regular infusions of clotting factors isolated from healthy donors can help prevent bleeding in hemophilia patients. At some point, genetic therapy will become a viable option.

Leukocyte Disorders

Leukopenia

Leukopenia is a condition in which too few leukocytes are produced. If this condition is pronounced, the individual may be unable to ward off disease.

Leukocytosis

Leukocytosis is excessive leukocyte proliferation. Although leukocyte counts are high, the cells themselves are often nonfunctional, leaving the individual at increased risk for disease.

Leukemia

Leukemia is cancer involving an abundance of leukocytes. It may involve only one specific type of leukocyte from either the myeloid line (myelocytic leukemia) or the lymphoid line (lymphocytic leukemia). In chronic leukemia, mature leukocytes accumulate and fail to die. In acute leukemia, there is an overproduction of young, immature leukocytes. In both conditions the cells do not function properly.

Lymphoma

Lymphoma is a form of cancer in which masses of malignant T and/or B lymphocytes collect in lymph nodes, the spleen, the liver, and other tissues. As in leukemia, the malignant leukocytes do not function properly, and the patient is vulnerable to infection. Some forms of lymphoma tend to progress slowly and respond well to treatment. Others tend to progress quickly and require aggressive treatment, without which they are rapidly fatal.

Other Conditions Related to Abnormal Leukocyte Counts

Table 10.5. Conditions Related to Abnormal White Blood Cell Counts. From Betts et al., 2013. Licensed under CC BY 4.0.

CELL TYPE	CONDITIONS RELATED TO HIGH COUNTS	CONDITIONS RELATED TO LOW COUNTS
Neutrophil	Infection, inflammation, burns, unusual stress	Drug toxicity, other disorders
Eosinophil	Allergies, parasitic worm infestations, some autoimmune diseases	Drug toxicity, stress
Basophil	Allergies, parasitic infections, hypothyroidism	Pregnancy, stress, hyperthyroidism
Lymphocyte	Viral infections, some cancers	Chronic illness, immunosuppression (due to HIV or steroid therapy)
Monocyte	Viral or fungal infections, tuberculosis, some forms of leukemia, other chronic diseases	Bone marrow suppression

Common Blood Vessels and Blood Abbreviations

Many terms and phrases related to the blood vessels and blood are abbreviated. Learn these common abbreviations by expanding the list below.

Query 1.10.4

This interactive element is not available in this format. Visit the link or scan the QR code to access it online.

View this Interactive Content online

Medical Terms in Context

Query 1.10.5

This interactive element is not available in this format. Visit the link or scan the QR code to access it online.

View this Interactive Content online

Medical Specialties and Procedures Related to the Blood Vessels and Blood

Vascular Surgeons

Vascular surgery is a specialty in which the physician treats diseases of the blood and lymphatic vessels. This includes repair and replacement of diseased or damaged vessels, removal of plaque from vessels, minimally invasive procedures including the

insertion of venous catheters, and traditional surgery. For more information, please visit the Society for Vascular Surgery web page.

Hematologists

Hematologists are specialist physicians that diagnose and treat blood disorders (National Cancer Institute, n.d.). To learn more about hematologists, visit the American Society of Hematology.

Diagnostic Vascular Technologists

Diagnostic vascular technologists are specialists that image the vascular system. Most diagnostic vascular technologists have professional certification (Bureau of Labor Statistics, 2021a.). To learn more, visit the Society for Vascular Ultrasound's web page.

Phlebotomist

Phlebotomists are professionals trained to draw blood. When more than a few drops of blood are required, phlebotomists perform a venipuncture, typically of a surface vein in the arm. They perform a capillary stick on a finger, an earlobe, or the heel of an infant when only a small quantity of blood is required. An arterial stick is collected from an artery and used to analyze blood gases. After collection, the blood may be analyzed by medical laboratories or perhaps used for transfusions, donations, or research.

Medical Laboratory Technologists/Technicians

Medical or clinical laboratories employ a variety of individuals in technical positions. Two specialized positions are medical laboratory technologists and technicians. Technologists and technicians operate laboratory equipment, analyze body fluids, and discuss their findings with physicians. Technologists generally perform more complex procedures than technicians. Some states require certification (Bureau of Labor Statistics, 2021b).

Bone Marrow Biopsy/Bone Marrow Transplant

Sometimes, a healthcare provider will order a **bone marrow biopsy**, a diagnostic test of a sample of red bone marrow, or a **bone marrow transplant**, a treatment in which a donor's healthy bone marrow—and its stem cells—replaces the faulty bone marrow of a patient. These tests and procedures are often used to assist in the diagnosis and treatment of various severe forms of anemia, such as thalassemia major and sickle cell anemia, as well as some types of cancer, specifically leukemia.

In the past, bone marrow sampling or transplant was very painful, as the procedure involved inserting a large-bore needle into the region near the iliac crest of the pelvic bones. Now, direct sampling of bone marrow can often be avoided as stem cells can be isolated in just a few hours from a sample of a patient's blood. The isolated stem cells are then grown in culture using the appropriate hemopoietic growth factors and analyzed or sometimes frozen for later use.

For an individual requiring a transplant, a matching donor is essential to prevent the immune system from destroying the donor cells—a phenomenon known as tissue rejection. To treat patients with bone marrow transplants, it is first necessary to destroy the patient's own diseased marrow through radiation and/or chemotherapy. Donor bone marrow stem cells are then infused into the recipient's bloodstream so that they can establish themselves in the recipient's bone marrow.

Blood Vessels and Blood Vocabulary

Acquired immunodeficiency syndrome (AIDS): A disease caused by the human immunodeficiency virus (HIV). People with acquired immunodeficiency syndrome are at an increased risk for developing certain cancers and for infections that usually occur only in individuals with a weak immune system (National Cancer Institute, n.d.)

Anaphylaxis: An acute hypersensitivity reaction due to exposure to a previously encountered antigen.

Anemia: A condition in which the number of red blood cells or hemoglobin is deficient.

Aneurysm: Weakening of the wall of a blood vessel, causing it to thin and balloon out, and possibly eventually burst, resulting in

internal bleeding.

Angiography: A procedure to x-ray blood vessels.

Angioplasty: A procedure in which an occlusion is mechanically widened with a balloon.

Angioscope: Instrument used for visual examination of blood vessels.

Angioscopy: Endoscopic examination of blood vessels.

Anti-B antibodies: Proteins that will mount an immune response against B antigens.

Antibodies: Proteins made by plasma cells (a type of white blood cell) in response to an antigen (a substance that causes the body to make a specific immune response). Each antibody can bind to only one specific antigen. The purpose of this binding is to help destroy the antigen.

Antigens: Substances that provokes an immune response. This happens because the immune system sees the antigen as foreign, or 'non-self" (does not belong in that body).

Aortic stenosis: A condition in which the aortic valve becomes rigid and may calcify over time.

Artery: A blood vessel that transports blood away from the heart.

Arteriole: A very small artery that leads to a capillary.

Arteriogram: An x-ray of arteries.

Arteriosclerosis: The generalized loss of compliance; "hardening of the arteries".

Atherectomy: Excision of fatty plaque.

Atherosclerosis: A hardening of the arteries that involves the accumulation of fatty plaque.

Brachial artery : The large artery in the upper arm near the biceps muscle.

Capillaries: The smallest type of blood vessel. A capillary connects an arteriole (small artery) to a venule (small vein) to form a network of blood vessels in almost all parts of the body.

Cardiac output: The measurement of blood flow from the heart through the ventricles and is usually measured in liters per minute. Any factor that causes cardiac output to increase, by elevating heart rate or stroke volume or both, will elevate blood pressure and promote blood flow.

Cardiac tamponade: A potentially fatal condition in which excess fluid builds within the pericardial space, preventing the heart from beating effectively.

Cardiogenic: Originating from the heart.

Carotid artery: Located in the neck, it is one of the three major branches of the aortic arch.

Centrifugation: Process of using a rotating machine to generate centrifugal force to separate substances of different densities, remove moisture, or simulate gravitational effects.

Chemoreceptors: Cells that sense changes in chemical levels.

Chemotaxis: Movement in response to chemicals; a phenomenon in which injured or infected cells and nearby leukocytes emit the equivalent of a chemical "911" call, attracting more leukocytes to the site.

Compliance: The ability of the blood vessels to dilate and constrict as needed.

Coronary artery bypass graft (CABG): Surgery in which a healthy blood vessel taken from another part of the body is used to make a new path for blood around a blocked artery leading to the heart. This restores the flow of oxygen and nutrients to the

heart.

Coronary heart disease: A disease in which there is a narrowing or blockage of the coronary arteries.

Crohn's disease: A condition in which the gastrointestinal tract is inflamed over a long period of time.

Diapedesis: The migration of blood cells through the intact walls of blood vessels into the surrounding tissue.

Diastolic pressure: The arterial pressure of blood during ventricular relaxation, or diastole.

Edema: Swelling due to excessive liquid in the tissues.

Embolus: An obstruction such as a blood clot or plaque that blocks the flow of blood in an artery or vein.

Endarterectomy: Excision of plaque from within the artery.

Endothelium: Epithelium that lines vessels in the lymphatic and cardiovascular systems.

Epiphyses: The wider section at the end of long bones.

Erythrocyte: A red blood cell.

Erythropoietin (EPO): A hormone produced by the kidneys that triggers the production of red blood cells.

Extramedullary hematopoiesis: Hematopoiesis outside the medullary cavity of adult bones.

Heart rate: The number of times the heart beats within a certain time period, usually a minute.

Hematocrit: A lab test which measures the percentage red blood cells in a sample of whole blood.

Hematologist: A doctor who has special training in diagnosing and treating blood disorders.

Hematology: The study of blood and blood-forming issues.

Hematoma: A pool of mostly clotted blood that forms in an organ, tissue, or body space.

Hemolysis: The breakdown of red blood cells.

Hemopoiesis: The process by which the body produces blood.

Hemopoietic growth factors: Chemical messengers which promote the proliferation and differentiation of formed elements and include erythropoietin, thrombopoietin, colony-stimulating factors, and interleukins.

Hemorrhage: Excessive bleeding.

Hemostasis: The process by which the body seals a ruptured blood vessel to prevent further blood loss.

Homeostasis: The state of steady internal conditions maintained by living things.

Hypertension: Abnormally high blood pressure.

Hypothermia: Abnormally low body temperature.

Hypothyroidism: The disease state caused by insufficient production of thyroid hormone by the thyroid gland.

Hypovolemic: An abnormally low volume of blood circulating through the body.

Hypoxemia: Below-normal level of oxygen saturation of blood (typically <95 percent).

Hypoxia: Lack of oxygen supply to the tissues.

Immunodeficiency: The decreased ability of the body to fight infections and other diseases.

Intravenous: Into or within the vein.

Ischemia: Lack of blood flow to body tissues.

Leukocyte: White blood cell(s).

Leukocytopenia: An abnormal decrease in the number of leukocytes.

Lupus: A chronic, inflammatory, connective tissue disease that can affect the joints and many organs.

Lymphadenitis: Inflammation of lymph nodes.

Lymphadenopathy: Disease or swelling of the lymph nodes.

Lymphoma: A form of cancer in which masses of malignant T and/or B lymphocytes collect in lymph nodes, the spleen, the liver, and other tissues. These leukocytes do not function properly, and the patient is vulnerable to infection.

Macrophage: A large cell derived from a monocyte; they participate in innate immune responses.

Medulla oblongata: A part of the brain stem responsible for control of heart rate and breathing.

Myeloma: Cancer that arises in plasma cells.

Myelopoiesis: Formation of bone marrow.

Pancytopenia: A condition in which there is a lower-than-normal number of red and white blood cells and platelets in the blood.

Perfusion: Penetration of blood.

Peripheral arterial disease: Obstruction of vessels in peripheral regions of the body.

pH: A measure of how acidic or alkaline a substance is, as determined by the number of free hydrogen ions in the substance.

Phagocytized: The process by which certain cells are able to “eat” other cells or substances by engulfing them.

Phlebitis: Inflammation of a vein.

Phlebotomist: A medical professional trained to draw blood, typically by performing a venipuncture of a surface vein of the arm.

Phlebotomy: A procedure in which a needle is used to take blood from a vein, usually for laboratory testing.

Placenta: The organ that supplies oxygen and nutrients to the fetus, excretes waste products, and produces and secretes estrogens and progesterone.

Plaque: A fatty material including cholesterol, connective tissue, white blood cells, and some smooth muscle cells.

Plasma cells: A type of B lymphocyte that produces antibodies which bind to specific foreign or abnormal antigens, in order to destroy them.

Plasmapheresis: A procedure in which a machine is used to separate the plasma from the blood cells.

Pneumothorax: An abnormal collection of air in the space between the thin layer of tissue that covers the lungs and the chest cavity that can cause all or part of the lung to collapse.

Polycythemia vera: A type of bone marrow disease that causes an excessive production of immature erythrocytes.

Pulmonary embolism: A blood clot within the lung.

Rheumatoid arthritis: An autoimmune disorder in which the body mounts an immune response against its own joint tissues,

causing inflammation and damage to the joints.

Sepsis: Organismal-level inflammatory response to a massive infection.

Sickle cell disease: An inherited disease in which the red blood cells have an abnormal crescent shape, block small blood vessels, and do not last as long as normal red blood cells; also called sickle cell anemia.

Splenectomy: Excision of the spleen.

Splenomegaly: Enlarged spleen.

Sphygmomanometer: A blood pressure cuff attached to a measuring device, or gauge.

Systolic pressure: The arterial pressure resulting from the ejection of blood during ventricular contraction, or systole.

Thalassemia: A genetic disorder characterized by abnormal synthesis of globin proteins and excessive destruction of erythrocytes.

Thrombocyte: Platelets.

Thrombocytopenia: A condition in which there is an insufficient number of platelets.

Thrombocytosis: A condition in which there are too many platelets.

Thrombophlebitis: Inflammation of a vein that occurs when a blood clot forms.

Thrombosis: The formation of unwanted blood clots.

Thrombus: Aggregation of fibrin, platelets, and erythrocytes in an intact artery or vein.

Thrombolysis: The process of breaking up a thrombus that is blocking blood flow.

Thymectomy: Excision of the thymus gland.

Thymoma: Tumor of the thymus gland.

Tissue rejection: The recipient's immune system recognizes the transplanted tissue as non-self and mounts an immune response against it, ultimately destroying it.

Vasoconstriction: The physiological narrowing of blood vessels by contraction of the vascular smooth muscle.

Vasodilation: The physiological widening of blood vessels by relaxing the vascular smooth muscle.

Veins: Blood vessels that carry blood back to the heart.

Venules: Small blood vessels that carry blood to a vein.

Viscosity: A measure of a fluid's thickness or resistance to flow.

Test Yourself

Query 1.10.6

This interactive element is not available in this format. Visit the link or scan the QR code to access it online.

View this Interactive Content online

References

Bureau of Labor Statistics. (2021a). Medical sonographers and cardiovascular technologists. In *Occupational outlook handbook*. U.S. Department of Labor. https://www.bls.gov/ooh/healthcare/diagnostic-medical-sonographers.htm

Bureau of Labor Statistics. (2021b). Clinical laboratory technologists and technicians. In *Occupational outlook handbook*. U.S. Department of Labor. https://www.bls.gov/ooh/healthcare/clinical-laboratory-technologists-and-technicians.htm

CrashCourse. (2015, July 20). *Blood vessels, part 1 – form and function: Crash course A&P #27* [Video]. YouTube. https://youtu.be/v43ej5lCeBo

National Cancer Institute. (n.d.). *Definition of hematologist*. National Institute of Health, U.S. Department of Health and Human Services. https://www.cancer.gov/publications/dictionaries/cancer-terms/def/hematologist

Image Descriptions

Figure 10.1 image description: The left panel shows the structure of a skeletal muscle vein pump when the muscle is relaxed, and the right panel shows the structure of a skeletal muscle vein pump when the muscle is contracted.[Return to Figure 10.1].

Figure 10.2 image description: The top left panel of this figure shows the ultrastructure of an artery (labels read from top: tunica externa, tunica media, tunica intima, smooth muscle, internal elastic membrane, vasa vasorum, external elastic membrane, nervi vasorum, endothelium, elastic fiber), and the top right panel shows the ultrastructure of a vein (labels read from top: tunica externa, tunica media, tunica intima, vasa vasorum, smooth muscle, endothelium). The bottom panel shows a micrograph with the cross-sections of an artery and a vein. [Return to Figure 10.2].

Figure 10.3 image description: The major arteries in the human body. Labels read (from the top, clockwise) right common carotid, left common carotid, axillary, pulmonary trunk, descending aorta, diaphragm, renal, superior mesenteric, gonadal, inferior mesenteric, common iliac, internal iliac, deep femoral, femoral, descending genicular, dorsalis pedis, plantar arch, fibular, anterior tibial, posterior tibial, popliteal, palmar arches, external iliac, ulnar, radial, brachial, celiac trunk, ascending aorta, aortic arch, brachiocephalic trunk, right subclavian, vertebral. [Return to Figure 10.3].

Figure 10.4 image description: The major veins in the human body. Labels read (from the top, clockwise) internal jugular, brachiocephalic, superior vena cava, intercostal, inferior vena cava, gonadal, lumbar, right and left common iliac, external iliac, internal iliac, deep femoral, femoral, posterior tibial, anterior tibial, dorsal venous arch, plantar venous arch, fibular, small saphenous, popliteal, great saphenous, digital, palmar venous arches, ulnar, median antebrachial, medial cubital, hepatic, basilic, brachial, cephalic, axillary, subclavian, external jugular. [Return to Figure 10.4].

Figure 10.5 image description: This diagram shows how oxygenated and deoxygenated blood flows through the major organs in the body. Pulmonary circulation involves the lungs, pulmonary artery and vein, vena cava, and aorta. Systemic circulation involves the upper body, hepatic vein, renal vein, aorta, liver, hepatic artery, hepatic portal vein, stomach, intestines, renal artery, kidneys, and lower body. [Return to Figure 10.5].

Figure 10.6 image description: The pulse points as shown on a woman's body. Labels read (from top) temporal artery, facial artery, common carotid artery, brachial artery, radial artery, femoral artery, popliteal artery, posterior tibial artery, dorsalis pedis

artery. [Return to Figure 10.6].

Figure 10.7 image description: This figure shows three test tubes with a red and yellow liquid in them. The left panel shows normal blood, the center panel shows anemic blood and the right panel shows polycythemia. Labels indicate plasma (water, proteins, nutrients, hormones et cetera), buffy coat (white blood cells, platelets), and hematocrit (red blood cells). [Return to Figure 10.7].

Figure 10.8 image description: This flowchart shows the pathways in which a multipotent hematopoietic stem cell differentiates into the different cell types found in blood. From the top (multipotent hematopoietic stem cells can divide and some cells remain stem cells, while the remaining cell goes down one of two paths depending on the chemical signals received: myeloid stem cell or lymphoid stem cell. A myeloid stem cell then can become either a megakaryoblast (which then turns into a megakaryocyte, then becomes platelets), or it can become a proerythroblast (which then becomes a reticulocyte, then becoming an erythrocyte), or it can become a myeloblast (which then becomes either a basophil, neutrophil, eosinophil), or it can become a monoblast (which then it becomes a monocyte). If the cell becomes a lymphoid stem cell, it then becomes a lymphoblast, which then becomes either a natural killer cell or a small lymphocyte (either T or B lymphocyte). [Return to Figure 10.8].

Figure 10.9 image description: This image shows a microscopic view of erythrocytes (red blood cells). Erythrocytes have the appearance of a disc with a shallow center, which aids their function. [Return to Figure 10.9].

Figure 10.10 image description: This image shows a micrographic view of different leukocytes. From left to right: basophil, eosinophil, neutrophil, monocyte, lymphocyte. [Return to Figure 10.10].

Figure 10.11 image description: This figure shows how leukocytes respond to chemical signals from injured cells. The top panel shows chemical signals sent out by the injured cells (text labels read: 1) Leukocytes in the blood respond to chemical attractants released by pathogens and chemical signals from nearby injured cells). The middle panel shows leukocytes migrating to the injured cells (text labels read: 2)the leukocytes squeeze between the capillary wall as they follow the chemical signals to where they are most concentrated (positive chemotaxis)). The bottom panel shows macrophages phagocytosing the pathogens (text label reads: 3) Within the damaged tissue, monocytes differentiate into macrophages that phagocytize the pathogens. The eosinophils and neutrophils release chemicals that break apart pathogens. They are also capable of phagocytosis.). [Return to Figure 10.11].

Figure 10.12 image description: This figure details the steps in the clotting of blood. Each step is shown along with a detailed text box describing the steps on the left. On the right, a signaling pathway shows the different chemical signals involved in the clotting process. The steps described: 1. Injury: a blood vessel is severed. Blood and blood components (e.g. erythrocytes, white blood cells, et cetera) are leaking out of the breaks. 2. Vascular spasm: the smooth muscle in the vessel wall contracts near the injury point reducing blood loss. 3. Platelet plug formation: platelets are activated by chemicals released from the injury site and by contact with underlying collagen. The platelets become spiked and stick to each other and the wound site. Initial platelets are activated by chemicals released from the injured cells and by contact with broken collagen. Bound platelets release chemicals that activate and attract other platelets. platelets move toward the source of chemical signals and bind. Platelet plug grows in size. 4. Coagulation. In coagulation, fibrinogen is converted to fibrin (see part b), which forms a mesh that traps more platelets and erythrocytes, producing a clot. Part B Fibryn synthesis cascade: Intrinsic pathway (damaged vessel wall), Extrinsic pathway (trauma to extravascular cells), final common pathway (cross-linked fibrin clot). [Return to Figure 10.12].

Figure 10.13 image description: This chart shows the ABO blood group types. From left to right, the columns are blood types A, B, AB, and O. In descending order, the rows are: red blood cell type; antibodies in plasma; antigens in red blood cell; and blood types compatible in an emergency. Blood type A has anti-B antibodies and A antigens and is compatible with blood types A and O. Blood type B has anti-A antibodies and B antigens and is compatible with blood types B and O. Blood type AB has no antibodies, has A and B antigens, and is compatible with all blood types (AB^+ is the universal recipient). Blood type O has anti-A and anti-B antibodies, has no antigens, and is compatible with blood type O (O is the universal donor). [Return to Figure 10.13].

Figure 10.15 image description: This figure shows three different red blood cells with different blood types. [Return to Figure 10.15].

Figure 10.14 image description: This figure shows an umbilical artery and vein passing through the placenta on the top left. The top right panel shows the first exposure to Rh+ antibodies in the mother. The bottom right panel shows the response when the second exposure in the form of another fetus takes place. Textboxes detail the steps in each process: First exposure birth of first Rh+ infant: 1. During birth, Rh+ fetal erythrocytes leak into maternal blood after breakage of the embryonic chorion, which normally isolates the fetal and maternal blood. 2) Maternal B cells are activated by the Rh antigen and produce large amounts of anti-Rh antibodies. Second exposure: Rh+ fetus: 3) Rh antibody titer in mother's blood is elevated after first exposure. 4) Rh

antibodies are small enough to cross the embryonic chorion and attach to the fetal erythrocytes. [Return to Figure 10.14].

Figure 10.16 image description: The left panel (a) shows the cross-section of a normal and a narrowed artery. A normal artery has no plaque along the artery walls which means there is normal blood flow. In a narrow artery, plague forms on the arterial walls causing abnormal blood flow. The right panel (b) shows a micrograph of an artery with plaque in it. [Return to Figure 10.16].

Figure 10.17 image description: This photograph shows varicose veins in the lower leg. Varicose veins are distended, twisted veins that may present in patients with edema. [Return to Figure 10.17].

Figure 10.18 image description: This photograph shows the red blood cells of a person suffering from sickle cell anemia. Instead of being discoid shaped like healthy blood cells, sickle red blood cells are shaped like a sickle. [Return to Figure 10.18].

Unless otherwise indicated, this chapter contains material adapted from *Anatomy and Physiology* (on OpenStax), by Betts et al. and is used under a CC BY 4.0 international license. Download and access this book for free at https://openstax.org/books/anatomy-and-physiology/pages/1-introduction.

This page titled 1.10: Blood Vessels and Blood is shared under a CC BY 4.0 license and was authored, remixed, and/or curated by Andrea Nelson and Katherine Greene via source content that was edited to the style and standards of the LibreTexts platform.

1.11: Lymphatic and Immune Systems

Learning Objectives

- Examine the anatomy of the lymphatic and immune systems
- Determine the main functions of lymphatic and immune systems
- Differentiate lymphatic and immune systems medical terms and common abbreviations
- Recognize the medical specialties associated with lymphatic and immune systems
- Discover common diseases, disorders, and procedures related to lymphatic and immune systems

Word Parts for the Lymphatic and Immune Systems

Click on prefixes, combining forms, and suffixes to reveal a list of word parts to memorize for the Lymphatic and Immune Systems.

Query 1.11.1

This interactive element is not available in this format. Visit the link or scan the QR code to access it online.

View this Interactive Content online

Introduction to the Lymphatic and Immune Systems

The **lymphatic system** is a series of vessels, ducts, and trunks that remove interstitial fluid from the tissues and return it to the blood. The lymphatic vessels are also used to transport dietary lipids and cells of the **immune system**. Cells of the immune system, lymphocytes, all come from the hematopoietic system of the bone marrow. Primary lymphoid organs, the bone marrow and thymus gland, are the locations where lymphocytes proliferate and mature. Secondary lymphoid organs are the site in which mature lymphocytes congregate to mount immune responses. Many immune system cells use the lymphatic and circulatory systems for transport throughout the body to search for and then protect against pathogens.

This chapter begins by describing the anatomy and physiology of the lymphatic system, whose immune functions lead us into a discussion of the body's multifaceted defenses, which together make up the immune system. Since the lymphatic system shares organs with a number of other body systems, the pathology discussed near the end of this chapter mainly focuses on disorders of the immune system.

Watch this video:

YouTube Video

This interactive element is not available in this format. Visit the link or scan the QR code to access it online.

View this YouTube Video online

Media 11.1 Lymphatic System: Crash Course A&P #44 [Online video]. Copyright 2015 by CrashCourse.

Practice Medical Terms Related to the Lymphatic and Immune Systems

Query 1.11.2

This interactive element is not available in this format. Visit the link or scan the QR code to access it online.

View this Interactive Content online

Anatomy and Physiology of the Lymphatic and Immune Systems

The lymphatic vessels begin as open-ended capillaries, which feed into larger and larger lymphatic vessels, and eventually empty into the bloodstream. Along the way, the lymph travels through the lymph nodes, which are commonly found near the groin, armpits, neck, chest, and abdomen. Humans have about 500 to 600 lymph nodes throughout the body (see Figure 11.1). Several organs and tissues that participate in immunity are also part of the lymphatic system.

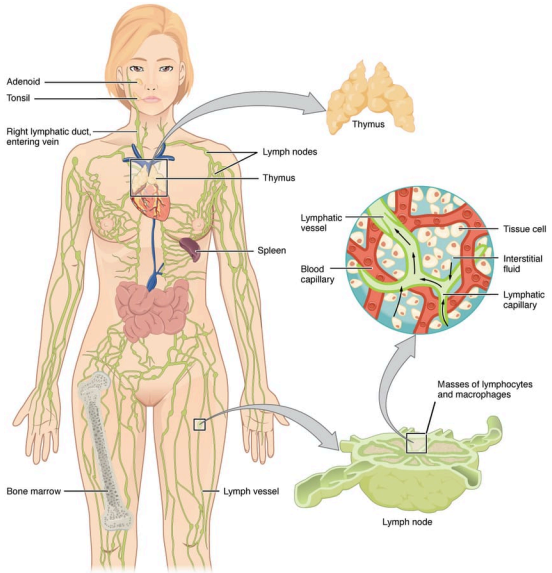

Figure 11.1 Anatomy of the Lymphatic System. Lymphatic vessels in the arms and legs convey lymph to the larger lymphatic vessels in the torso. From Betts et al., 2013. Licensed under CC BY 4.0. [Image description.]

Lymphatic Capillaries

An important function of the lymphatic system is to return the fluid (lymph) to the blood. Lymph may be thought of as recycled blood plasma. Blood pressure causes leakage of fluid from the blood capillaries, resulting in the accumulation of fluid in the interstitial space. In humans, 20 liters of plasma is released into the interstitial space of the tissues each day due to capillary leakage. The blood vessels reabsorb 17 liters of this interstitial fluid, leaving three liters in the tissues for the lymphatic system to transport back to the circulation. If the lymphatic system is damaged in some way, such as by being blocked by cancer cells or destroyed by injury, interstitial fluid accumulates in the tissue spaces, causing a condition called **lymphedema**.

Lymphatic capillaries, also called the terminal lymphatics, are vessels where interstitial fluid enters the lymphatic system to become lymph. Located in almost every tissue in the body, these vessels are interlaced among the arterioles and venules of the circulatory system in the soft connective tissues of the body (see Figure 11.2). Exceptions are the central nervous system, bone marrow, bones, teeth, and the cornea of the eye, which do not contain lymph vessels.

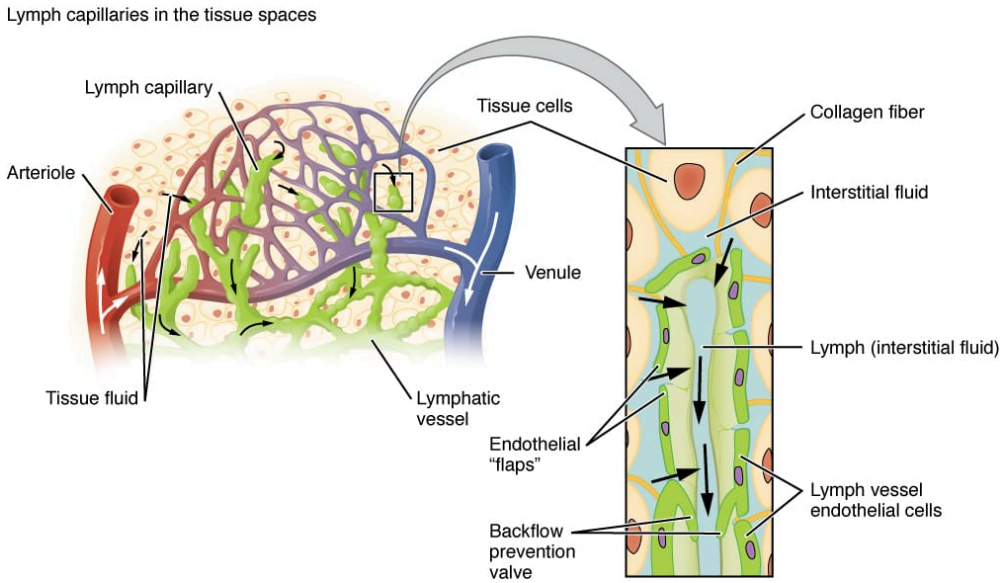

Figure 11.2 Lymphatic Capillaries. Lymphatic capillaries are interlaced with the arterioles and venules of the cardiovascular system. Collagen fibers anchor a lymphatic capillary in the tissue (inset). Interstitial fluid slips through spaces between the overlapping endothelial cells that compose the lymphatic capillary.From Betts et al., 2013. Licensed under CC BY 4.0. [Image description.]

Did you know?

Lymphatic vessels and blood vessels are similar in structure and function. Lymph is not actively pumped by the heart but is forced through the vessels by the movements of the body muscles.

Larger Lymphatic Vessels, Trunks, and Ducts

The lymphatic capillaries empty into larger lymphatic vessels, which are similar to veins in terms of their three-tunic structure and the presence of valves. These one-way valves are located fairly close to one another, and each one causes a bulge in the lymphatic vessel, giving the vessels a beaded appearance (see Figure 11.2).

In general, superficial lymphatics follow the same routes as veins, whereas deep lymphatic vessels of the viscera generally follow the paths of arteries. The superficial and deep lymphatics eventually merge to form larger lymphatic structures known as the **lymphatic trunks**. On the right side of the body, the right sides of the head, thorax, and right upper limb trunks drain lymph fluid into the right subclavian vein via the **right lymphatic duct** (see Figure 11.3). On the left side of the body, the trunks from the remaining portions of the body drain into the larger **thoracic duct**, which drains into the left subclavian vein. The thoracic duct itself begins just beneath the diaphragm in the **cisterna chyli.**

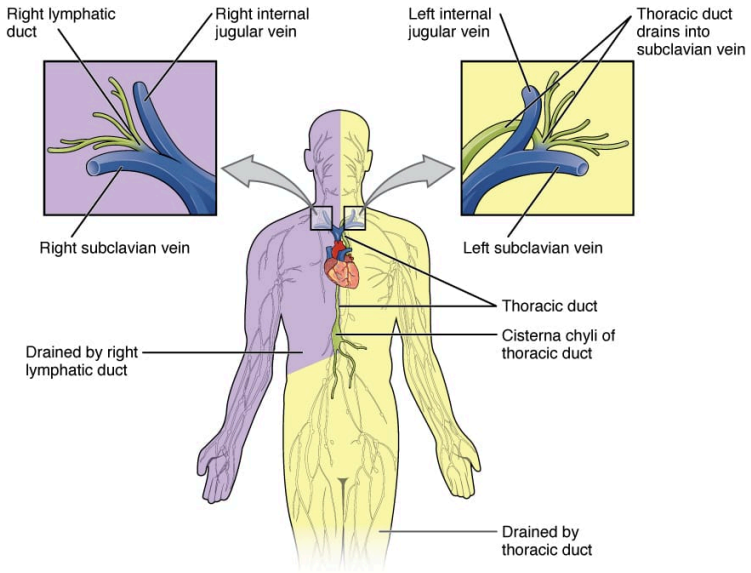

Figure 11.3 Major Trunks and Ducts of the Lymphatic System. The thoracic duct drains a much larger portion of the body than does the right lymphatic duct. From Betts et al., 2013. Licensed under CC BY 4.0. [Image description.]

Primary Lymphoid Organs

The **primary lymphoid organs** are the bone marrow and thymus gland. The lymphoid organs are where lymphocytes mature, proliferate, and are selected, which enables them to attack pathogens without harming the cells of the body.

- Bone Marrow
  - Recall that all blood cells, including lymphocytes, are formed in the red bone marrow. The B cell undergoes nearly all of its development in the red bone marrow, whereas the immature T cell, called a **thymocyte**, leaves the bone marrow and matures largely in the thymus gland.

- Thymus
  - The **thymus** gland, where T cells mature, is a bilobed organ found in the space between the sternum and the aorta of the heart (see Figure 11.4). Connective tissue holds the lobes closely together but also separates them and forms a capsule.
  - The loss of immune function with age is called **immunosenescence**. One major cause of age-related immune deficiencies is thymic involution.
    - The shrinking of the thymus gland begins at birth at a rate of about 3% tissue loss per year. This shrinking continues until 35 to 45 years of age when the rate declines to about 1% loss per year for the rest of one's life. At that pace, the total loss of thymic epithelial tissue and thymocytes would occur at about 120 years of age. So, in theory, 120 years could be the maximum life span.

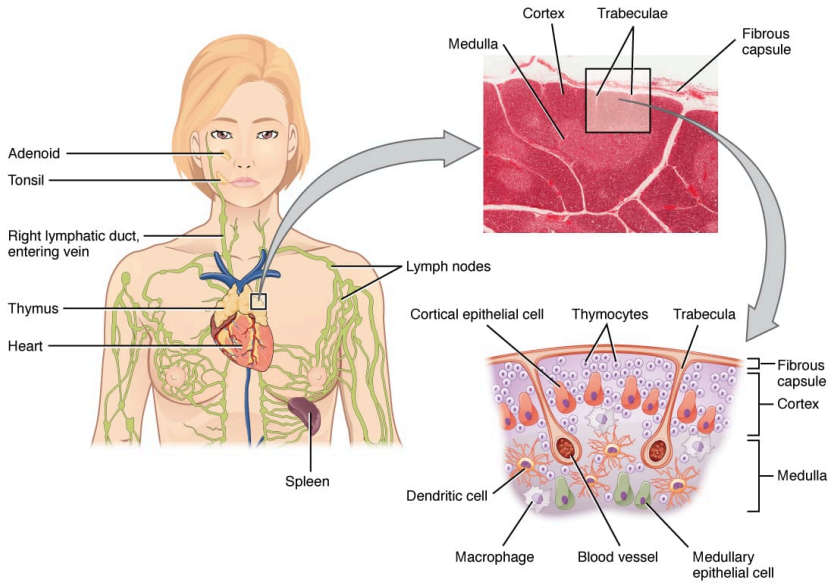

Figure 11.4 Location, Structure, and Histology of the Thymus. The thymus lies above the heart. The trabeculae and lobules, including the darkly staining cortex and the lighter staining medulla of each lobule, are clearly visible in the light micrograph of the thymus of a newborn. LM × 100. (Micrograph provided by the Regents of the University of Michigan Medical School © 2012). From Betts et al., 2013. Licensed under CC BY 4.0. [Image description.]

Concept Check

- Do you remember what the suffix "-oid" means?
- Can you explain the term **lymphoid**?

Secondary Lymphoid Organs

Lymphocytes develop and mature in the primary lymphoid organs, but they mount immune responses from the **secondary lymphoid organs,** which include the lymph nodes, spleen, and lymphoid nodules. A **naïve lymphocyte** is one that has left the primary organ, where it learned to function immunologically, and entered a secondary lymphoid organ where it waits to encounter an antigen against which it will mount a response (see Figure 11.5).

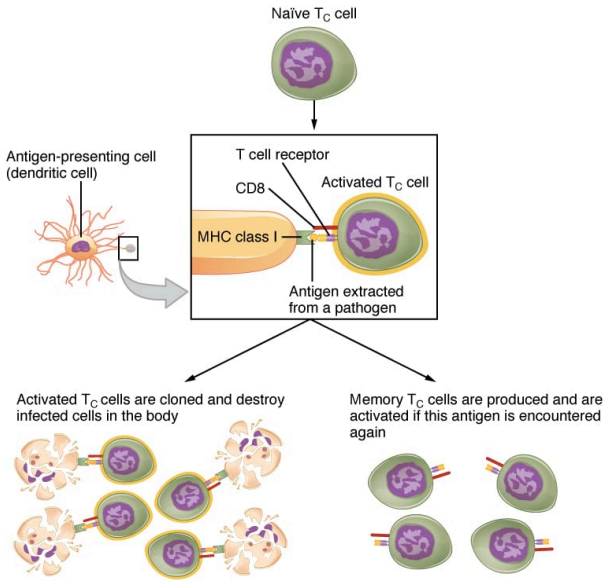

Figure 11.5 Clonal Selection and Expansion of T Lymphocytes. Stem cells differentiate into T cells with specific receptors, called clones. The clones with receptors specific for antigens on the pathogen are selected for and expanded. From Betts et al., 2013. Licensed under CC BY 4.0. [Image description.]

Did you know?

The thymus gland produces a hormone called thymosin and is therefore also considered to be part of the endocrine system.

Lymph Nodes

Lymph nodes function to remove debris and pathogens from the lymph and are thus sometimes referred to as the “filters of the lymph” (see Figure 11.6). Any bacteria that infect the interstitial fluid are taken up by the lymphatic capillaries and transported to a regional lymph node. Dendritic cells and macrophages within this organ internalize and kill many of the pathogens that pass through, thereby removing them from the body. The lymph node is also the site of adaptive immune responses mediated by T cells, B cells, and accessory cells of the adaptive immune system.

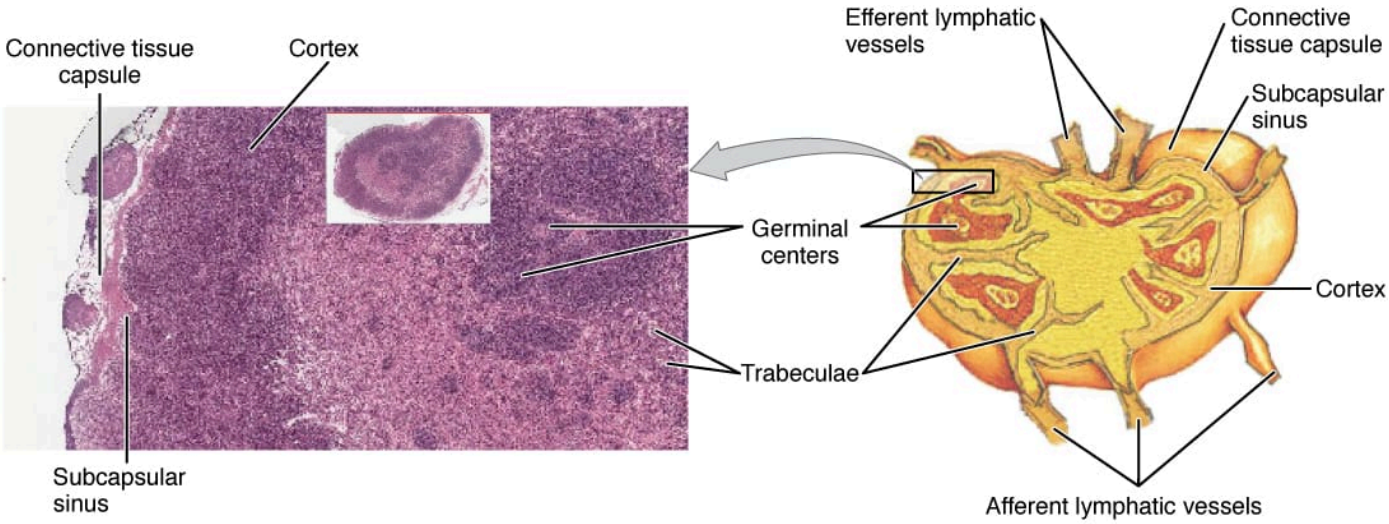

Figure 11.6 Structure and Histology of a Lymph Node. Lymph nodes are masses of lymphatic tissue located along the larger lymph vessels. The micrograph of the lymph nodes shows a germinal center, which consists of rapidly dividing B cells surrounded by a layer of T cells and other accessory cells. LM × 128. (Micrograph provided by the Regents of the University of Michigan Medical School © 2012). From Betts et al., 2013. Licensed under CC BY 4.0. [Image description.]

Spleen

The **spleen** is a vascular organ that is somewhat fragile due to the absence of a capsule. It is about 12 cm long and is attached to the lateral border of the stomach. The spleen is sometimes called the “filter of the blood” because of its extensive vascularization and the presence of macrophages and dendritic cells that remove microbes and other materials from the blood, including dying red blood cells. The spleen also functions as the location of immune responses to blood-borne pathogens.

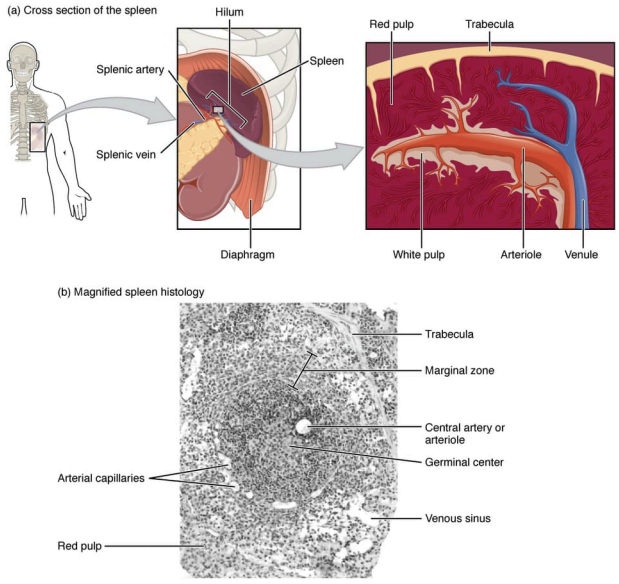

Figure 11.7 Spleen. (a) The spleen is attached to the stomach. (b) A micrograph of spleen tissue shows the germinal center. The marginal zone is the region between the red pulp and white pulp, which sequesters particulate antigens from the circulation and presents these antigens to lymphocytes in the white pulp. EM × 660. (Micrograph provided by the Regents of the University of Michigan Medical School © 2012). From Betts et al., 2013. Licensed under CC BY 4.0. [Image description.]

Did you know?

You can live without your spleen. Do you remember the term for “surgical removal of the spleen”?

Lymphoid Nodules

The other lymphoid tissues, the **lymphoid nodules**, consist of a dense cluster of lymphocytes without a surrounding fibrous capsule. These nodules are located in the respiratory and digestive tracts, areas routinely exposed to environmental pathogens.

Tonsils are lymphoid nodules located along the inner surface of the pharynx and are important in developing immunity to oral pathogens (see Figure 11.8). The tonsil located at the back of the throat, the pharyngeal tonsil, is sometimes referred to as the **adenoid** when swollen. Such swelling is an indication of an active immune response to infection. Tonsils have deep grooves called crypts, which accumulate all sorts of materials taken into the body through eating and breathing and actually “encourage” pathogens to penetrate deep into the tonsillar tissues where they are eliminated. A major function of tonsils is to help children’s bodies recognize, destroy, and develop immunity to common environmental pathogens so that they will be protected in their later lives. Tonsils are often removed in children who have recurring throat infections since swollen palatine tonsils can interfere with breathing and/or swallowing.

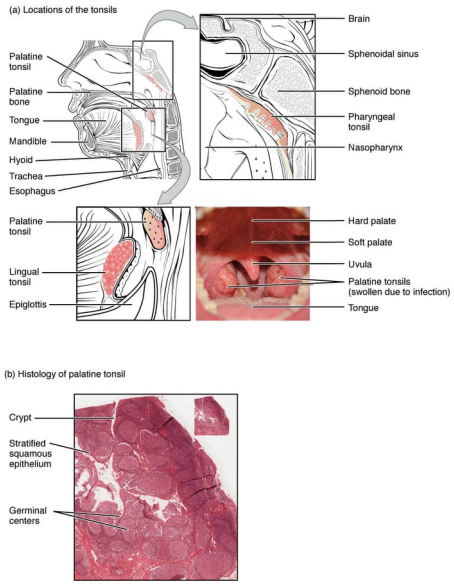

Figure 11.8. Locations and Histology of the Tonsils. (a) The pharyngeal tonsil is located on the roof of the posterior superior wall of the nasopharynx. The palatine tonsils lay on each side of the pharynx. (b) A micrograph shows the palatine tonsil tissue. LM × 40. (Micrograph provided by the Regents of the University of Michigan Medical School © 2012). From Betts et al., 2013. Licensed under CC BY 4.0. [Image description.]

Concept Check

Tonsils are named after their locations.

- Look at the figure above and determine which anatomical structure is closely associated with each set of tonsils and was therefore used to name the tonsils, for example, the lingual tonsils are named after the tongue (lingula).
- Can you tell which structures were used to name the palatine tonsils and the pharyngeal tonsils?

Bronchus-associated lymphoid tissue (BALT) consists of lymphoid follicular structures with an overlying epithelial layer found along the bifurcations of the bronchi, and between bronchi and arteries. These tissues, in addition to the tonsils, are effective against inhaled pathogens.

Mucosa-associated lymphoid tissue (MALT) consists of an aggregate of lymphoid follicles directly associated with mucous membrane. MALT makes up dome-shaped structures found underlying the mucosa of the gastrointestinal tract, breast tissue, lungs, and eyes. Peyer's patches, a type of MALT in the small intestine, are especially important for immune responses against ingested substances (see Figure 11.9). Peyer's patches contain specialized cells that sample material from the intestinal lumen and transport it to nearby follicles so that adaptive immune responses to potential pathogens can be mounted.

Figure 11.9 Mucosa-associated Lymphoid Tissue (MALT) Nodule. LM × 40. (Micrograph provided by the Regents of the University of Michigan Medical School © 2012). From Betts et al., 2013. Licensed under CC BY 4.0. [Image description.]

The Organization of the Immune System

The immune system is a collection of barriers, cells, and soluble proteins that interact and communicate with each other in extraordinarily complex ways. The modern model of immune function is organized into a three-phase immune response (based on the timing of their effects). Ideally, this response will rid the body of a pathogen entirely (see Figure 11.10).

Think of a primary infection as a race between the pathogen and the immune system:

1. The pathogen bypasses **barrier defenses** and starts to multiply in the host's body.
2. During the first 4 to 5 days, the **innate immune response** will partially control, but not stop the pathogen growth.
3. The slower but more specific and effective **adaptive immune response** gears up and becomes progressively stronger, it will begin to clear the pathogen from the body. This clearance is referred to as seroconversion. It should be noted that seroconversion does not necessarily mean a patient is getting well.

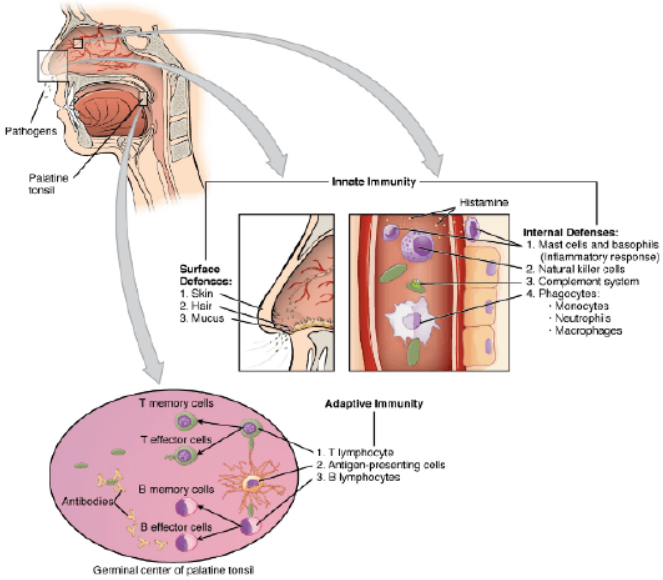

Figure 11.10 Cooperation between Innate and Adaptive Immune Responses. The innate immune system enhances adaptive immune responses so they can be more effective. From Betts et al., 2013. Licensed under CC BY 4.0. [Image description.]

Phase 1: Barrier Defenses

Barrier defenses are part of the body's most basic innate defense mechanisms. They are not a *response* to infections, but rather are continuously working to protect against pathogens by preventing them from entering the body, destroying them after they enter, or flushing them out before they can establish themselves.

Barrier defenses examples:

- **Skin**:
  - Keratinized cells of the surface are too dry for bacteria to grow and are continuously sloughed off, along with pathogens that are on their surfaces.
- **Skin (sweat glands, sebaceous glands)**:
  - Lower pH than pathogens prefer, may contain substances that are toxic to pathogens, washing action.
- **Oral Cavity (salivary glands):**
  - Lysozyme is an enzyme that destroys bacteria.
- **Stomach:**
  - Low pH which is fatal to many pathogens.
- **Mucosal:**
  - Traps both microbes and debris, and facilitates their removal.
- **Normal flora (nonpathogenic bacteria):**
  - Prevents pathogens from growing on mucosal surfaces.

Phase 2: Innate Immune Response

Innate immune responses are critical to the early control of infections. Whereas barrier defenses are the body's first line of physical defense against pathogens, innate immune responses are the first line of physiological defense. Innate responses occur rapidly, but with less specificity and effectiveness than the adaptive immune response. Within the first few days of an infection, a series of antibacterial proteins are induced, each with activities against certain bacteria. Additionally, interferons are induced that protect cells from viruses in their vicinity. Finally, the innate immune response does not stop when the adaptive immune response is developed. In fact, both can cooperate and one can influence the other in their responses against pathogens.

Innate immune responses (and early induced responses) are in many cases ineffective at completely controlling pathogen growth but they slow pathogen growth and allow time for the adaptive immune response to strengthen and either control or eliminate the pathogen. The innate immune system also sends signals to the cells of the adaptive immune system, guiding them in how to attack the pathogen.

Watch this video:

YouTube Video

This interactive element is not available in this format. Visit the link or scan the QR code to access it online.

View this YouTube Video online

Media 11.2 Immune System, Part 1: Crash Course A&P #45 [Online video]. Copyright 2015 by CrashCourse.

Cells of the Innate Immune Response

Phagocytes: Macrophages and Neutrophils

A phagocyte is a cell that is able to surround and engulf a particle or cell, a process called **phagocytosis**. The phagocytes of the immune system engulf other particles or cells, either to clean an area of debris, old cells, or to kill pathogenic organisms such as

bacteria. Macrophages, neutrophils, and dendritic cells are the major phagocytes of the immune system and are the body's fast acting, front line immunological defense against organisms that have breached barrier defenses and have entered the body.

Macrophages not only participate in innate immune responses but have also evolved to cooperate with lymphocytes as part of the adaptive immune response. Macrophages exist in many tissues of the body, either freely roaming through connective tissues or fixed to reticular fibers within specific tissues such as lymph nodes. When pathogens breach the body's barrier defenses, macrophages are the first line of defense.

A **neutrophil** is a phagocytic cell that is attracted via chemotaxis from the bloodstream to infected tissues. contains cytoplasmic granules, which in turn contain a variety of vasoactive mediators such as histamine. Whereas macrophages act like sentries, always on guard against infection, neutrophils can be thought of as military reinforcements that are called into a battle to hasten the destruction of the enemy.

A **monocyte** is a circulating precursor cell that differentiates into either a macrophage or **dendritic cell**, which can be rapidly attracted to areas of infection by signal molecules of inflammation.

Natural Killer (NK) Cells

Natural killer cells are a type of lymphocyte that have the ability to induce apoptosis in cells infected with pathogens such as intracellular bacteria and viruses. If apoptosis is induced before the virus has the ability to synthesize and assemble all its components, no infectious virus will be released from the cell, thus preventing further infection.

Soluble Mediators of the Innate Immune Response

The previous discussions have alluded to chemical signals that can induce cells to change various physiological characteristics, such as the expression of a particular receptor. These soluble factors are secreted during innate or early induced responses, and later during adaptive immune responses.

Concept Check

Do you know the difference between these terms?

- Intercellular
- Intracellular
- Interstitial

Cytokines and Chemokines

A **cytokine** is a signaling molecule that allows cells to communicate with each other over short distances. Cytokines are secreted into the intercellular space, and the action of the cytokine induces the receiving cell to change its physiology. A **chemokine** is a soluble chemical mediator similar to cytokines except that its function is to attract cells (chemotaxis) from longer distances.

Early Induced Proteins

Early induced proteins are those that are not constitutively present in the body but are made as they are needed early during the innate immune response. **Interferons** are an example of early induced proteins. Cells infected with viruses secrete interferons that travel to adjacent cells and induce them to make antiviral proteins. Thus, even though the initial cell is sacrificed, the surrounding cells are protected.

Inflammatory Response

The hallmark of the innate immune response is **inflammation**. Stub a toe, cut a finger, or do any activity that causes tissue damage and inflammation will result with its four characteristics: **heat, redness, pain,** and **swelling** ("loss of function" is sometimes mentioned as a fifth characteristic). It is important to note that inflammation does not have to be initiated by an

infection, but can also be caused by tissue injuries. The release of damaged cellular contents into the site of injury is enough to stimulate the response, even in the absence of breaks in physical barriers that would allow pathogens to enter (by hitting your thumb with a hammer, for example). The inflammatory reaction brings in phagocytic cells to the damaged area to clear cellular debris and encourages the entry of clotting factors to set the stage for wound repair. Inflammation also facilitates the transport of antigen to lymph nodes by dendritic cells for the development of the adaptive immune response.

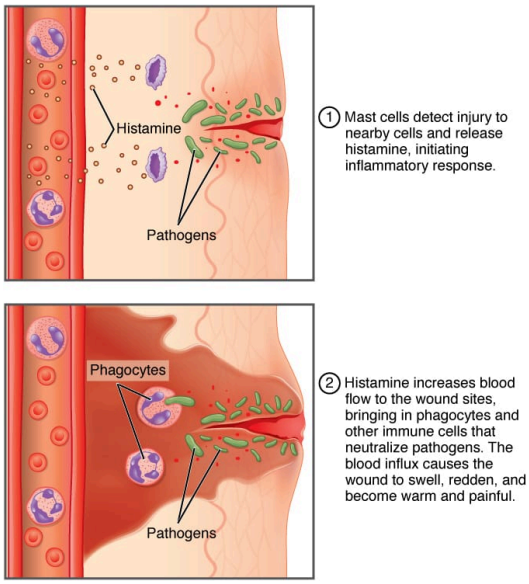

Figure 11.11 Inflammatory Response. From Betts et al., 2013. Licensed under CC BY 4.0. [Image description.]

The above image summarizes the following events in the inflammatory response:

- The released contents of injured cells stimulate the release of substances from **mast cells** including histamine, leukotrienes, and prostaglandins.
- **Histamine** increases blood flow to the area by vasodilation, resulting in **heat** and **redness**. Histamine also increases the permeability of local capillaries, causing plasma to leak out and form interstitial fluid, resulting in **swelling.**
- **Leukotrienes** attract neutrophils from the blood by chemotaxis.
  When local infections are severe, neutrophils are attracted to the sites of infections in large numbers, and as they phagocytose the pathogens and subsequently die, their accumulated cellular remains are visible as pus at the infection site.
- **Prostaglandins** cause vasodilation by relaxing vascular smooth muscle and are a major cause of the **pain** associated with inflammation. Nonsteroidal anti-inflammatory drugs such as aspirin and ibuprofen relieve pain by inhibiting prostaglandin production.

Concept Check

- Do you remember the suffix used to describe ‘inflammation’?
- Describe what causes the pain associated with inflammation.

Acute inflammation is a short-term innate immune response to an insult to the body. If the cause of the inflammation is not resolved, however, it can lead to **chronic inflammation**, which is associated with major tissue destruction and fibrosis.

Phase 3: Adaptive Immune Response

Watch this video:

YouTube Video

This interactive element is not available in this format. Visit the link or scan the QR code to access it online.

View this YouTube Video online

Media 11.3 Immune System, Part 2: Crash Course A&P #46 [Online video]. Copyright 2015 by CrashCourse.

Benefits of the Adaptive Immune Response

- **Specificity**
  - The ability to specifically recognize and mount a response against almost any pathogen.
  - Antigens are recognized by receptors on the surface of B and T lymphocytes.

- **Immunological Memory**
  - The first exposure to a pathogen is called a **primary adaptive response.**
  - Symptoms of a first infection, called primary disease, are always relatively severe because it takes time for an initial adaptive immune response to a pathogen to become effective.
  - Upon re-exposure to the same pathogen, a **secondary adaptive immune response** is generated, which is stronger and faster than the primary response, often eliminating the pathogen before it can cause damage or even symptoms.
  - This secondary response is the basis of **immunological memory**, which gives us immunity.

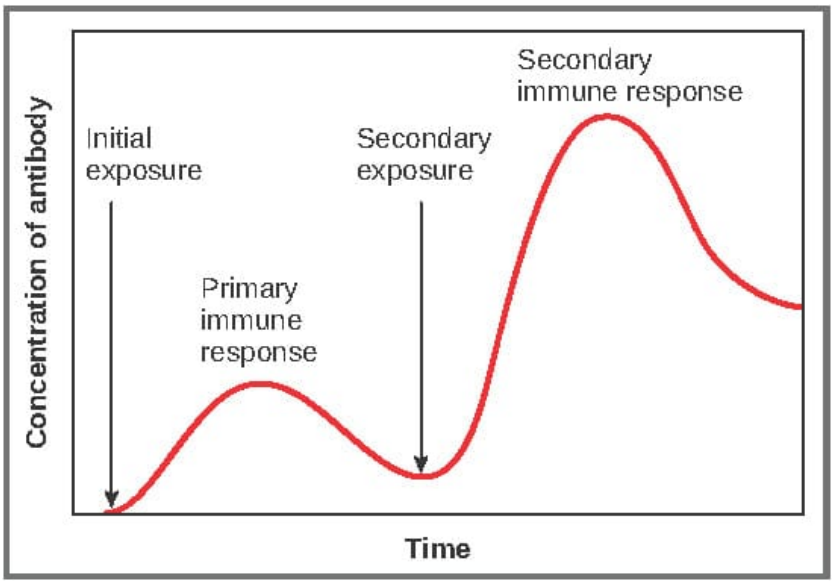

Figure 11.12 Primary and Secondary Antibody Responses. Antigen A is given once to generate a primary response and later to generate a secondary response. When a different antigen is given for the first time, a new primary response is made. From Betts et al., 2013. Licensed under CC BY 4.0. [Image description.]

- **Self Recognition**
  - The ability to distinguish between self-antigens, those that are normally present in the body, and foreign antigens, those that might be on a potential pathogen.
  - As T and B cells mature, there are mechanisms in place that prevent them from recognizing self-antigen, preventing a damaging immune response against the body. When these mechanisms fail, their breakdown leads to autoimmune diseases.

Lymphocytes: B Cells, T Cells, Plasma Cells

As stated above, lymphocytes are the primary cells of adaptive immune responses. These cells were introduced in the previous chapter and are summarized in the following table:

Table 11.1 Cells of the Adaptive Immune Response. From Betts et al., 2013. Licensed under CC BY 4.0.

CELL TYPE	DESCRIPTION AND DETAILS
Plasma Cell	B cell (lymphocyte) that has been activated through exposure to an antigen and produces antibodies against that antigen (see the figure below). There are 5 classes of antibodies (IgM, IgG, IgE, IgA, IgD), each functioning in different ways: **IgM** promotes chemotaxis, opsonization, and cell lysis, making it a very effective antibody against bacteria at early stages of a primary antibody response **IgG** is the one that crosses the placenta to protect the developing fetus from disease and exits the blood to the interstitial fluid to fight extracellular pathogens **IgA** is the only antibody to leave the interior of the body to protect body surfaces. IgA is also of importance to newborns, because this antibody is present in mother's breast milk (colostrum), which serves to protect the infant **IgE** is associated with allergies and anaphylaxis
T Cell	Different T cell types have the ability to either secrete soluble factors that communicate with other cells of the adaptive immune response or destroy cells infected with intracellular pathogen. ◦ Cytotoxic T Cell (Tc) kill target cells by inducing apoptosis using the same mechanism as NK cells: killing a virally infected cell before the virus can complete its replication cycle results in the production of no infectious particles ◦ Helper T Cell (Th) release cytokines, which help to develop and regulate other immune system cells ◦ Suppressor T Cell (also called regulatory T cell) control T Cell response, in order to prevent too many T cells from being formed during an immune response
Memory Cell	B cells and T cells formed during primary exposure to a pathogen (see the figure below). Remain in the body for a long time after infection and are able to mount a fast and effective immune response to a pathogen if it is encountered a second time, preventing the pathogen from causing disease.

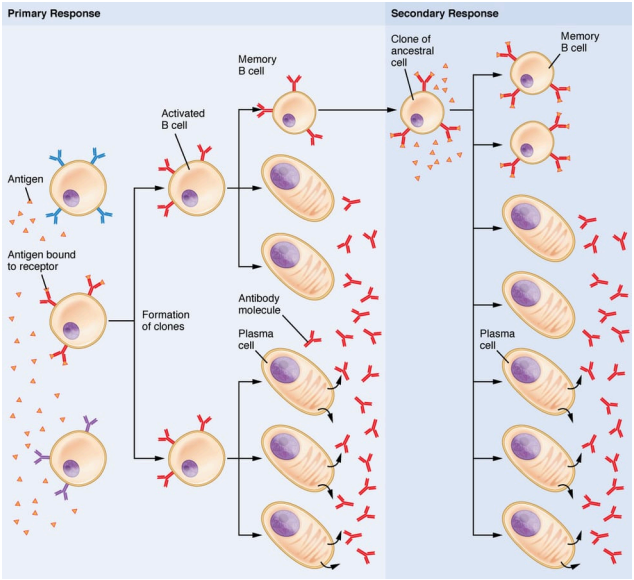

Figure 11.13 Clonal Selection of B Cells. During a primary B cell immune response, both antibody-secreting plasma cells and memory B cells are produced. These memory cells lead to the differentiation of more plasma cells and memory B cells during secondary responses. From Betts et al., 2013. Licensed under CC BY 4.0. [Image description.]

Active Versus Passive Immunity

Immunity to pathogens, and the ability to control pathogen growth so that damage to the tissues of the body is limited, can be acquired by:

1. The active development of an immune response in the infected individual; **or**
2. The passive transfer of immune components from an immune individual to a non-immune one.

The downside to this passive immunity is the lack of the development of immunological memory. Once the antibodies are transferred, they are effective for only a limited time before they degrade.

Table 11.2 Active Versus Passive Immunity. From Betts et al., 2013. Licensed under CC BY 4.0.

IMMUNITY	NATURAL	ARTIFICIAL
Active: resistance to pathogens acquired during an adaptive immune response	Result of memory cells formed during the adaptive immune response to a pathogen	Vaccine response. Through vaccination, one avoids the disease that results from the first exposure to the pathogen, yet reaps the benefits of protection from immunological memory. Vaccination was one of the major medical advances of the twentieth century and led to the eradication of smallpox and the control of many infectious diseases, including polio, measles, and whooping cough
Passive: transfer of antibodies from an immune person to a nonimmune person	Trans-placental antibodies from mother to fetus and maternal antibodies in breast milk protect newborn from infections	Immunoglobulin injections taken from animals previously exposed to a specific pathogen; a fast-acting method of temporarily protecting an individual who was possibly exposed to a pathogen

Evasion of the Immune System by Pathogens

The immune system and pathogens are in a slow, evolutionary race to see who stays on top. Early childhood is a time when the body develops much of its immunological memory that protects it from diseases in adulthood. Pathogens have shown the ability, however, to evade the body's immune responses, as described below.

- **Protective adaptations**: It is important to keep in mind that although the immune system has evolved to be able to control many pathogens, pathogens themselves have evolved ways to evade the immune response. An example is in *Mycobacterium tuberculosis*, which has evolved a complex cell wall that is resistant to the digestive enzymes of the macrophages that ingest them, and thus persists in the host, causing the chronic disease tuberculosis.
- **Multiple strains**: Bacteria sometimes evade immune responses because they exist in multiple strains, each having different surface antigens and requiring individual adaptive immune responses. One example is a small group of strains of *S. aureus*, called methicillin-resistant *Staphylococcus aureus (MRSA)*, which has become resistant to multiple antibiotics.
- **Antigen mutation:** Because viruses' surface molecules mutate continuously, viruses like influenza change enough each year that the flu vaccine for one year may not protect against the flu common to the next. New vaccine formulations must be derived for each flu season.
- **Genetic recombination:** An example is the influenza virus, which contains gene segments that can recombine when two different viruses infect the same cell. Recombination between human and pig influenza viruses led to the 2010 H1N1 swine flu outbreak.
- **Immunosuppression**: Pathogens, especially viruses, can produce immunosuppressive molecules that impair immune function.

Tissue Transplantation

With the use of tissue typing and anti-rejection drugs, transplantation of organs and the control of the anti-transplant immune response have made huge strides in the past 50 years. Immunosuppressive drugs such as cyclosporine A have made transplants more successful, but tissue matching is still key. Family members, since they share a similar genetic background, are much more likely to share major histocompatibility complex (MHC) molecules than unrelated individuals do.

One disease of transplantation occurs with bone marrow transplants, which are used to treat various diseases, including severe combined immunodeficiency disease (SCID) and leukemia. Because the bone marrow cells being transplanted contain lymphocytes capable of mounting an immune response, and because the recipient's immune response has been destroyed before receiving the transplant, the donor cells may attack the recipient tissues, causing graft-versus-host disease. Signs and symptoms of this disease, which usually include a rash and damage to the liver and mucosa, are variable. Attempts have been made to moderate the disease by first removing mature T cells from the donor bone marrow before transplanting it.

Immune Responses Against Cancer

It is clear that with some cancers, like Kaposi's sarcoma (see Figure 11.14), for example, that a healthy immune system does a good job at controlling them. This disease, which is caused by the human herpes virus, is almost never observed in individuals with strong immune systems. Other examples of cancers caused by viruses include liver cancer, caused by the hepatitis B virus, and cervical cancer, caused by the human papillomavirus. As these last two viruses have vaccines available for them, getting vaccinated can help prevent these two types of cancer by stimulating the immune response.

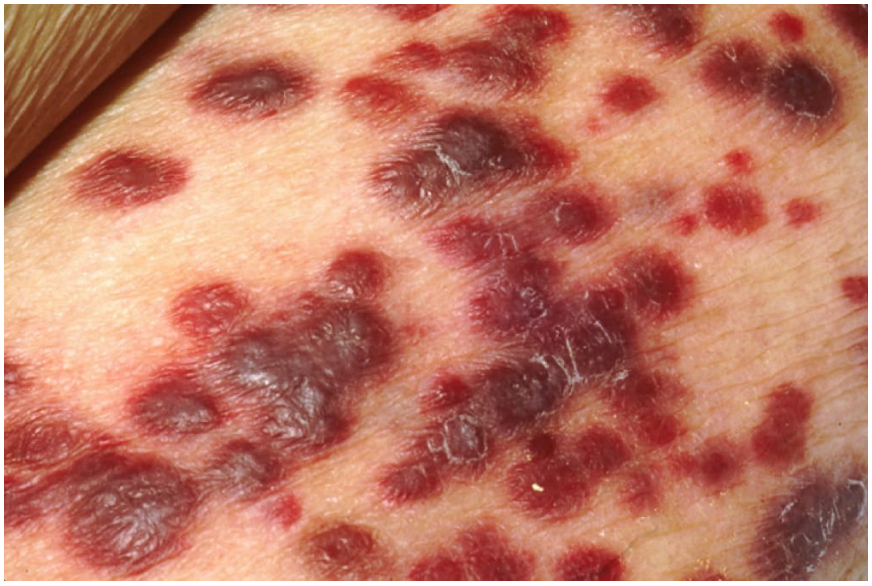

Figure 11.14 Kaposi's Sarcoma Lesions. (credit: National Cancer Institute). From Betts et al., 2013. Licensed under CC BY 4.0. [Image description.]

On the other hand, as cancer cells are often able to divide and mutate rapidly, they may escape the immune response, just as certain pathogens such as the human immunodeficiency virus (HIV) do.

There are three stages in the immune response to many cancers:

1. **Elimination** occurs when the immune response first develops toward tumor-specific antigens specific to the cancer and actively kills most cancer cells.
2. **Equilibrium** is the period that follows, during which the remaining cancer cells are held in check.
3. **Escape** of the immune response, and resulting disease, occurs because many cancers mutate and no longer express any specific antigens for the immune system to respond to.

This fact has led to extensive research in trying to develop ways to enhance the early immune response to completely eliminate the early cancer and thus prevent a later escape. One method that has shown some success is the use of cancer vaccines. These differ from other vaccines in that they are directed against the cells of one's own body. Treated cancer cells are injected into cancer patients to enhance their anti-cancer immune response and thereby prolong survival. The immune system has the capability to detect these cancer cells and proliferate faster than the cancer cells do, thus overwhelming the cancer in a similar way as they do for viruses. Cancer vaccines are being developed for malignant melanoma and renal (kidney) cell carcinoma.

Immune Responses and Stress

In order to protect the entire body from infection, the immune system is required to interact with other organ systems, sometimes in complex ways. For example, hormones such as cortisol (naturally produced by the adrenal cortex) and prednisone (synthetic) are well known for their abilities to suppress T cell immune mechanisms; hence, their prominent use in medicine as long-term, anti-inflammatory drugs.

One well-established interaction of the immune, nervous, and endocrine systems is the effect of stress on immune health. In the human vertebrate evolutionary past, stress was associated with the fight-or-flight response, largely mediated by the central nervous system and the adrenal medulla. This stress was necessary for survival since fighting or fleeing usually resolved the problem in one way or another. It has been found that short-term stress diverts the body's resources towards enhancing innate immune responses. This has the ability to act fast and would seem to help the body prepare better for possible infections associated with the trauma that may result from a fight-or-flight exchange.

On the other hand, there are no physical actions to resolve most modern day stresses, including short-term stressors like taking examinations and long-term stressors such as being unemployed or losing a spouse. The effect of stress can be felt by nearly every organ system, and the immune system is no exception (see Table 11.3). Chronic stress, unlike short-term stress, may inhibit immune responses even in otherwise healthy adults. The suppression of both innate and adaptive immune responses is clearly

associated with increases in some diseases.

Table 11.3 Effects of Stress on Body Systems. From Betts et al., 2013. Licensed under CC BY 4.0.

SYSTEM	STRESS-RELATED ILLNESS
Integumentary system	Acne, skin rashes, irritation
Nervous system	Headaches, depression, anxiety, irritability, loss of appetite, lack of motivation, reduced mental performance
Muscular and skeletal systems	Muscle and joint pain, neck and shoulder pain
Circulatory system	Increased heart rate, hypertension, increased probability of heart attacks
Digestive system	Indigestion, heartburn, stomach pain, nausea, diarrhea, constipation, weight gain or loss
Immune system	Depressed ability to fight infections
Male reproductive system	Lowered sperm production, impotence, reduced sexual desire
Female reproductive system	Irregular menstrual cycle, reduced sexual desire

Anatomy Labeling Activity

Query 1.11.3

This interactive element is not available in this format. Visit the link or scan the QR code to access it online.

View this Interactive Content online

Practice Terms Related to the Lymphatic and Immune Systems

Query 1.11.4

This interactive element is not available in this format. Visit the link or scan the QR code to access it online.

View this Interactive Content online

Common Abbreviations for the Lymphatic and Immune Systems

Many terms and phrases related to the lymphatic and immune systems are abbreviated. Learn these common abbreviations by expanding the list below.

Query 1.11.5

This interactive element is not available in this format. Visit the link or scan the QR code to access it online.

View this Interactive Content online

Diseases and Disorders of the Lymphatic and Immune Systems

The immune response can be under-reactive or over-reactive, leading to a state of disease. The factors that maintain immunological homeostasis are complex and incompletely understood.

Lymphedema

Lymphedema is a condition in which lymphatic fluid builds up in the body's soft tissues. Lymphedema often occurs in the arms and legs, although other body parts may be affected. There are two types of lymphedema: primary and secondary. Primary lymphedema may be congenital and is caused by abnormalities in the lymph system. Secondary lymphedema occurs when the lymph system is damaged or blocked due to injury, cancer, or cancer treatment. Signs and symptoms include swelling of the limbs and digits, difficulty moving the joints in the arms and legs, and the sensation that the skin is too tight. Lymphedema is rarely cured. Instead, treatment such as the use of pressure garments, light exercise, massage therapy, and surgery can reduce symptoms and lower the risk of complications. Patients with severe cases of lymphedema are at an increased risk of developing lymphangiosarcoma, an aggressive cancer of the lymph vessels (National Cancer Institute, 2021; Sleigh & Manna, 2021). For more information, visit the Mayo Clinic's web page on lymphedema.

Underactive Immune System: Immunodeficiencies

Suppressed immunity can result from inherited genetic defects or by acquiring viruses.

Inherited Immunodeficiencies/SCID

While many inherited immunodeficiencies exist, the most serious is severe combined immunodeficiency disease (SCID). This complex disease is caused by many different genetic defects which result in impaired B cell and T cell arms of the adaptive immune response. Children with this disease usually die of opportunistic infections within their first year of life unless they receive a bone marrow transplant. Such a procedure had not yet been perfected for David Vetter, the "boy in the bubble," who was treated for SCID by having to live in a sterile plastic cocoon for the 12 years before his death from infection in 1984. One of the features that make bone marrow transplants work as well as they do is the proliferative capability of hematopoietic stem cells of the bone marrow. Only a small amount of bone marrow from a healthy donor is given intravenously to the recipient. It finds its own way to the bone where it populates it, eventually reconstituting the patient's immune system, which is usually destroyed beforehand by treatment with radiation or chemotherapeutic drugs.

New treatments for SCID using gene therapy, inserting non-defective genes into cells taken from the patient and giving them back, have the advantage of not needing the tissue match required for standard transplants. Although not a standard treatment, this approach holds promise, especially for those in whom standard bone marrow transplantation has failed.

Acquired Immunodeficiency/HIV and AIDS

Although many viruses cause suppression of the immune system, only HIV wipes it out completely. HIV is transmitted through semen, vaginal fluids, and blood, and can be caught by risky sexual behaviors and the sharing of needles by intravenous drug users. There are sometimes, but not always, flu-like symptoms in the first 1 to 2 weeks after infection. The presence of anti-HIV antibodies indicates a positive HIV test. Because seroconversion takes different lengths of time in different individuals, multiple HIV tests are given months apart to confirm or eliminate the possibility of infection.

After seroconversion, the amount of virus circulating in the blood drops and stays at a low level for several years. During this time, the levels of CD4 T cells decline steadily, until at some point, the immune response is so weak that opportunistic disease and eventually death result.

Treatment for the disease consists of drugs that target virally encoded proteins that are necessary for viral replication but are absent from normal human cells. By targeting the virus itself and sparing the cells, this approach has been successful in significantly prolonging the lives of HIV-positive individuals.

Overactive Immune System: Hypersensitivities and Autoimmune Diseases

Hypersensitivities

Over-reactive immune responses include the hypersensitivities: allergies and inflammatory responses to nonpathogenic environmental substances. The table below compares different hypersensitivities.

Table 11.4 Table Summarizing Types of Hypersensitivities. From Betts et al., 2013. Licensed under CC BY 4.0.

TYPE OF HYPERSENSITIVITY	DETAILS AND EXPLANATION
Type I	◦ Allergies and allergic asthma ◦ Major symptoms of inhaled allergens are the nasal edema and runny nose caused by the increased vascular permeability and increased blood flow of nasal blood vessels ◦ 'Immediate Hypersensitivity': usually rapid and occur within just a few minutes ◦ Mild allergies are usually treated with antihistamines ◦ Severe allergies that may cause anaphylactic shock, which can be fatal within 20 to 30 minutes if untreated; epinephrine raises blood pressure and relaxes bronchial smooth muscle and is routinely used to counteract the effects of anaphylactic shock
Type II	◦ Occurs during mismatched blood transfusions and blood compatibility diseases such as erythroblastosis fetalis
Type III	◦ Occurs with diseases such as systemic lupus erythematosus

TYPE OF HYPERSENSITIVITY	DETAILS AND EXPLANATION
Type IV	◦ "Delayed hypersensitivity"-takes 24 to 72 hours to develop ◦ A standard cellular immune response in which the first exposure to an antigen is called **sensitization**, such that on re-exposure, an immune response results ◦ The classical test for delayed hypersensitivity is the tuberculin test for tuberculosis, where bacterial proteins from *M. tuberculosis* are injected into the skin. A couple of days later, a positive test, as indicated by an induration, means that the patient has been exposed to the bacteria and exhibits a cellular immune response to it ◦ Another type of delayed hypersensitivity is contact sensitivity, where substances such as the metal nickel cause a red and swollen area upon contact with the skin in an individual who was previously sensitized to the metal.

Autoimmune Responses

The worst cases of the immune system overreacting are autoimmune diseases in which the immune systems begin to attack cells of the patient's own body, causing chronic inflammation and significant damage. The trigger for these diseases is often unknown, although environmental and genetic factors are likely involved. Treatments are usually based on resolving the symptoms using immunosuppressive and anti-inflammatory drugs. Figure 11.15 below provides two examples of autoimmune diseases: rheumatoid arthritis (RA) and systemic lupus erythematosus (SLE).

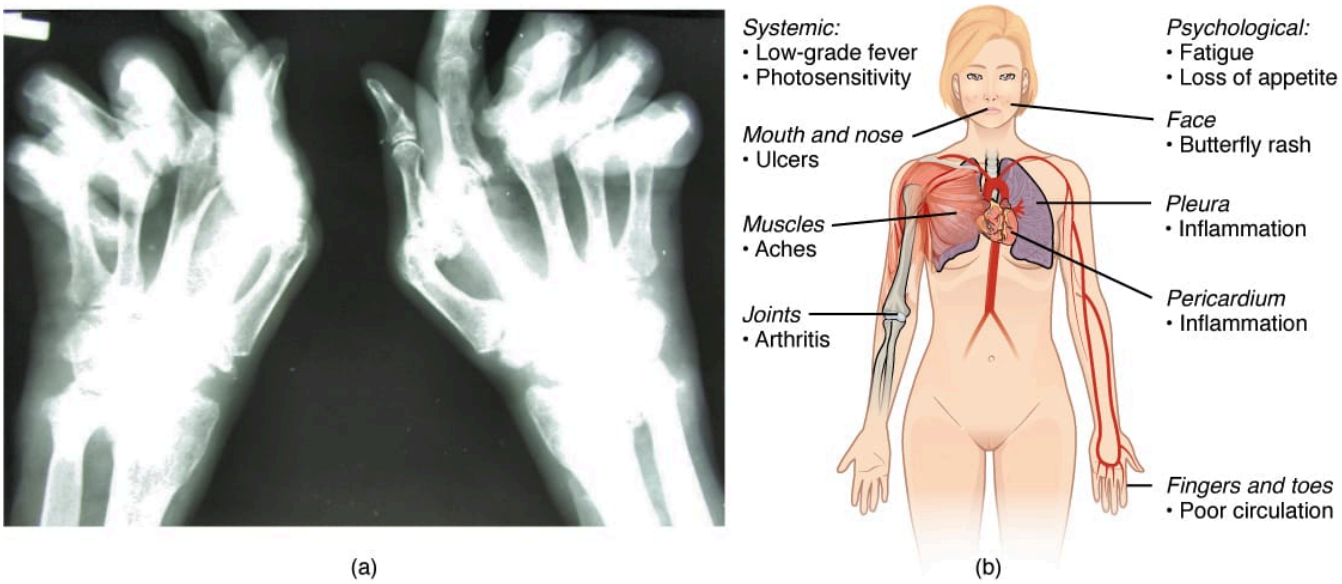

Figure 11.15 Autoimmune Disorders: Rheumatoid Arthritis and Lupus. (a) Extensive damage to the right hand of a rheumatoid arthritis sufferer is shown in the x-ray. (b) The diagram shows a variety of possible symptoms of systemic lupus erythematosus. From Betts et al., 2013. Licensed under CC BY 4.0. [Image description.]

Overall, there are more than 80 different autoimmune diseases, which are a significant health problem in the elderly. Table 11.5 below lists several of the most common autoimmune diseases, the antigens that are targeted (autoantigen or "self" antigen), and

the resulting tissue damage.

Table 11.5 Autoimmune Diseases. From Betts et al., 2013. Licensed under CC BY 4.0.

DISEASE	AUTOANTIGEN	SYMPTOMS
Celiac disease	Tissue transglutaminase	Damage to small intestine
Diabetes mellitus type I	Beta cells of pancreas	Low insulin production; inability to regulate serum glucose
Graves' disease	Thyroid-stimulating hormone receptor (antibody blocks receptor)	Hyperthyroidism
Hashimoto's thyroiditis	Thyroid-stimulating hormone receptor (antibody mimics hormone and stimulates receptor)	Hypothyroidism
Lupus erythematosus	Nuclear DNA and proteins	Damage of many body systems
Myasthenia gravis	Acetylcholine receptor in neuromuscular junctions	Debilitating muscle weakness
Rheumatoid arthritis	Joint capsule antigens	Chronic inflammation of joints

Lymphoma

Lymphoma is a form of cancer in which masses of malignant T and/or B lymphocytes collect in lymph nodes, the spleen, the liver, and other tissues. As in leukemia, the malignant leukocytes do not function properly, and the patient is vulnerable to infection. Some forms of lymphoma tend to progress slowly and respond well to treatment. Others tend to progress quickly and require aggressive treatment, without which they are rapidly fatal.

Medical Terms in Context

Query 1.11.6

This interactive element is not available in this format. Visit the link or scan the QR code to access it online.

View this Interactive Content online

Query 1.11.7

This interactive element is not available in this format. Visit the link or scan the QR code to access it online.

View this Interactive Content online

Query 1.11.8

This interactive element is not available in this format. Visit the link or scan the QR code to access it online.

View this Interactive Content online

Medical Specialties and Procedures Related to the Lymphatic and Immune Systems

Clinical immunologists and allergists diagnose and treat diseases of the immune system (National Center for O*Net Development, 2021). For more information, please visit the American Academy of Allergy, Asthma, and Immunology's web page on careers in immunology.

Skin Testing

Skin testing (for allergies) is done by a clinical immunologist/allergist to identify allergens in Type I hypersensitivity. In skin testing, allergen extracts are injected into the epidermis, and a positive result of the wheal and flare response usually occurs within 30 minutes. The soft center is due to fluid leaking from the blood vessels and the redness is caused by the increased blood flow to the area that results from the dilation of local blood vessels at the site.

Lymphatic and Immune Systems Vocabulary

Active immunity: Immunity developed from an individual's own immune system.

Acute inflammation: Inflammation occurring for a limited time period; rapidly developing.

Adaptive immune response: A relatively slow but very specific and effective immune response controlled by lymphocytes.

Afferent lymphatic vessels: Vessels that lead into a lymph node.

Allergens: Antigens that evoke type 1 hypersensitivity (allergy) responses.

Allergist: Specialist who specializes in treating individuals with a hypersensitivity to allergens.

Allergy: Inflammatory response due to a hypersensitivity to a substance that normally is harmless or would not cause an immune response in most people.

Anaphylactic shock: A severe and sometimes life-threatening immune system reaction to an antigen that a person has been previously exposed to. The reaction may include itchy skin, edema, collapsed blood vessels, fainting, difficulty in breathing, and death.

Antibody: A protein made by plasma cells (a type of white blood cell) in response to an antigen (a substance that causes the body to make a specific immune response). Each antibody can bind to only one specific antigen. The purpose of this binding is to help destroy the antigen.

Antigens: Substances that provokes an immune response. This happens because the immune system sees the antigen as foreign, or 'non-self" (does not belong in that body).

Apoptosis: Programmed cell death.

Autoimmune diseases/disorders: Disorders in which the immune system overreacts and begins to attack itself.

B cells: Lymphocytes that act by differentiating into an antibody-secreting plasma cell.

Barrier defenses: Antipathogen defenses deriving from a barrier that physically prevents pathogens from entering the body to establish an infection.

Bone marrow: Tissue found inside bones; the site of all blood cell differentiation and maturation of B lymphocytes.

Bronchus-associated lymphoid tissue (BALT): Lymphoid nodule associated with the respiratory tract.

CD4 T Cells: CD4 is the receptor that HIV uses to get inside T cells and reproduce. CD4+ helper T cells play an important role in T cell immune responses and antibody responses.

Chemokine: Soluble, long-range, cell-to-cell communication molecule.

Chemotaxis: Movement in response to chemicals; a phenomenon in which injured or infected cells and nearby leukocytes emit the equivalent of a chemical "911" call, attracting more leukocytes to the site.

Chronic inflammation: Ongoing inflammation that can be caused by foreign bodies, persistent pathogens, and autoimmune diseases such as rheumatoid arthritis.

Chyle: Lipid-rich lymph inside the lymphatic capillaries of the small intestine.

Cisterna chyli: A sac-like chamber that receives lymph from the lower abdomen, pelvis, and lower limbs by way of the left and right lumbar trunks and the intestinal trunk.

Complement: Enzymatic cascade of constitutive blood proteins that have antipathogen effects, including the direct killing of bacteria.

Cytokine: A signaling molecule that allows cells to communicate with each other over short distances.

Deep lymphatic vessels: Lymphatic vessels of the organs.

Efferent lymphatic vessels: Vessels that lead out of a lymph node.

Erythroblastosis fetalis: An immune reaction between maternal and fetal blood due to the Rh antigen; also known as hemolytic disease of the newborn (HDN).

Genetic recombination: The combining of gene segments from two different pathogens.

Graft-versus-host disease (GVHD): A condition that can occur in bone marrow transplant recipients; occurs when the transplanted cells mount an immune response against the recipient's tissue.

Histamine: A vasodilator involved in the inflammatory response.

Human immunodeficiency virus (HIV): An infectious disease transmitted through semen, vaginal fluids, and blood that suppresses the immune system. HIV infection may be managed with antiviral drugs or may progress to acquired immune deficiency syndrome (AIDS).

Hypersensitivities: Reacting to something that would not normally evoke a reaction.

Immune system: Series of barriers, cells, and soluble mediators that combine to response to infections of the body with pathogenic organisms.

Immunity: Resistant to the effects of pathogens.

Immunodeficiency: The decreased ability of the body to fight infections and other diseases.

Immunological memory: Ability of the adaptive immune response to mount a stronger and faster immune response upon re-exposure to a pathogen.

Immunology: The study of the body's immune system.

Induration: A firm, raised reddened patch of skin.

Inflammation: Basic innate immune response characterized by heat, redness, pain, and swelling.

Innate immune response: Fast-acting non-specific immune mechanisms that are present from birth.

Intercellular: Between cells.

Interferons: Early induced proteins made in virally infected cells that cause nearby cells to make antiviral proteins.

Interstitial fluid: Extracellular fluid not contained within blood vessels.

Interstitial space: Spaces between individual cells in the tissues.

Intracellular: Inside the cell membrane or within the cell.

Leukemia: A cancer involving an abundance of leukocytes.

Lymph: The term used to describe interstitial fluid once it has entered the lymphatic system.

Lymph node: One of the bean-shaped organs found associated with the lymphatic vessels.

Lymphatic capillaries: Smallest of the lymphatic vessels and the origin of lymph flow.

Lymphatic system: Network of lymphatic vessels, lymph nodes, and ducts that carries lymph from the tissues and back to the bloodstream.

Lymphatic trunks: Large lymphatics that collect lymph from smaller lymphatic vessels and empties into the blood via lymphatic ducts.

Lymphocytes: The second most common type of leukocyte and are essential for the immune response.

Lymphoid nodules: Unencapsulated patches of lymphoid tissue found throughout the body.

Lymphoma: A form of cancer in which masses of malignant T and/or B lymphocytes collect in lymph nodes, the spleen, the liver, and other tissues. These leukocytes do not function properly, and the patient is vulnerable to infection.

Macrophage: A large cell derived from a monocyte; they participate in innate immune responses.

Major histocompatibility complex (MHC): Protein structures found on the outside of cells that help the immune system recognize non-self antigens.

Mast cell: Cell found in the skin and the lining of body cells that contains cytoplasmic granules with vasoactive mediators such as histamine.

Memory T cells: Long-lived immune cells reserved for future exposure to a pathogen.

Monocyte: A type of immune cell that is made in the bone marrow.

Mucosa-associated lymphoid tissue (MALT): Lymphoid nodule associated with the mucosa.

Mucous membranes: Epithelial membranes that line the body cavities and hollow passageways that open to the external environment.

Naïve lymphocyte: Mature B or T cell that has not yet encountered antigen for the first time.

Natural killer cell (NK): Cytotoxic lymphocyte of innate immune response.

Neutrophil: Phagocytic white blood cell recruited from the bloodstream to the site of infection via the bloodstream.

Opsonization: A process by which an antibody or an antimicrobial protein binds to a pathogen, thereby marking it as a target for

phagocytes.

Passive immunity: Transfer of immunity to a pathogen to an individual that lacks immunity to this pathogen usually by the injection of antibodies.

Pathogen: An organism that causes a disease.

Phagocytosis: Movement of material from the outside to the inside of the cells via vesicles made from invaginations of the plasma membrane; process where some white blood cells engulf invading microorganisms.

Plasma cells: A type of B lymphocyte that produces antibodies, which bind to specific foreign or abnormal antigens in order to destroy them.

Primary adaptive response: Immune system's response to the first exposure to a pathogen.

Primary lymphoid organs: Site where lymphocytes mature and proliferate; for example, red bone marrow and the thymus gland.

Right lymphatic duct: Drains lymph fluid from the upper right side of the body into the right subclavian vein.

Staphylococcus aureus: A bacteria that is commonly found in minor skin infections, as well as in the nose of some healthy people.

Secondary adaptive response: Immune response observed upon re-exposure to a pathogen, which is stronger and faster than a primary response.

Secondary lymphoid organs: Sites where lymphocytes mount adaptive immune responses, examples include lymph nodes and spleen.

Seroconversion: The reciprocal relationship between virus levels in the blood and antibody levels.

Severe combined immunodeficiency disease (SCID): A rare, inherited disease that is marked by a lack of B and T lymphocytes.

Spleen: Secondary lymphoid organ that filters pathogens from the blood (white pulp) and removes degenerating or damaged blood cells (red pulp).

Superficial lymphatics: Lymphatic vessels of the subcutaneous tissues of the skin.

Systemic lupus erythematosus (SLE): A chronic, inflammatory, connective tissue disease that can affect the joints and many organs; also called lupus.

T cell: Lymphocyte that acts by secreting molecules that regulate the immune system or by causing the destruction of foreign cells, viruses, and cancer cells.

Thoracic duct: Large duct that drains lymph from the lower limbs, left thorax, left upper limb, and the left side of the head.

Thymocytes: A type of white blood cell that is part of the immune system and develops from stem cells in the bone marrow; also called T cells and T lymphocytes.

Thymus: Primary lymphoid organ, where t lymphocytes proliferate and mature.

Tissue typing: The determination of major histocompatibility complex (MHC) molecules in the tissue to be transplanted to better match the donor to the recipient.

Tonsils: Lymphoid nodules associated with the nasopharynx.

Vaccine: A killed or weakened pathogen or its components that, when administered to a healthy individual, leads to the development of immunological memory (a weakened primary immune response) without causing much in the way of symptoms.

Vasodilation: The physiological widening of blood vessels by relaxing the vascular smooth muscle.

Wheal and flare response: A soft, pale swelling at the site surrounded by a red zone.

Test Yourself

Query 1.11.9

This interactive element is not available in this format. Visit the link or scan the QR code to access it online.

View this Interactive Content online

References

CrashCourse. (2015, November 30). *Lymphatic system: Crash course A&P #44* [Video]. YouTube. https://youtu.be/I7orwMgTQ5I

CrashCourse. (2015, December 8). *Immune system, part 1: Crash course A&P #45* [Video]. YouTube. https://youtu.be/GIJK3dwCWCw

CrashCourse. (2015, December 14). *Immune system, part 2: Crash course A&P #46* [Video]. YouTube. https://youtu.be/2DFN4IBZ3rI

National Center for O*NET Development. (2021) 29-1229.01 – Allergists and Immunologists. *O*NET OnLine*. Retrieved November 2, 2021, from https://www.onetonline.org/link/summary/29-1229.01

National Cancer Institute. (2021). *Lymphedema (PDQ®)–Patient version*. National Institutes of Health. https://www.cancer.gov/about-cancer/treatment/side-effects/lymphedema/lymphedema-pdq

Sleigh, B. C., & Manna, Bi. (2021). Lymphedema. In *StatPearls [Internet]*. https://www.ncbi.nlm.nih.gov/books/NBK537239/

Image Descriptions

Figure 11.1 image description: The left panel shows a female human body, and the entire lymphatic system is shown Labels read (clockwise from top): thymus, lymph nodes, thymus, spleen, lymph vessel, bone marrow, right lymphatic duct, entering vein, tonsil, adenoid. The right panel shows magnified images of the thymus and the lymph node. Labels read (clockwise from top): tissue cell, interstitial fluid, lymphatic capillary, blood capillary, lymphatic vessel. Label of lymph node reads masses of lymphocytes and macrophages. [Return to Figure 11.1].

Figure 11.2 image description: This image shows the lymph capillaries in the tissue spaces. Labels read (clockwise, from top): lymph capillary, tissue cells, venule, lymphatic vessel, tissue fluid, arteriole). It also shows a magnified image showing the interstitial fluid and the lymph vessels. Labels read (clockwise, from top): collagen fiber, interstitial fluid, lymph, lymph vessel endothelial cells, backflow prevention valve, endothelial flaps. [Return to Figure 11.2].

Figure 11.3 image description: This figure shows the lymphatic trunks and the duct system in the human body. Labels read (clockwise from top) thoracic duct, cisterna chyli of thoracic duct, drained by thoracic duct, drained by right lymphatic duct. Callouts to the left and right show the magnified views of the left and right jugular vein respectively. Labels read (right lymphatic duct): right internal jugular vein, right subclavian vein, right lymphatic duct; (left jugular vein): left internal jugular vein, thoracic duct drains into subclavian vein, left subclavian vein.[Return to Figure 11.3].

Figure 11.4 image description: The left panel of this figure shows the head and chest of a woman and the location of the thymus is marked. Labels read (clockwise, from top) lymph nodes, spleen, heart, thymus, right lymphatic duct entering vein, tonsil, adenoid. The top right panel shows a micrograph of the thymus. Labels read (from left to right): medulla, cortex, trabeculae, fibrous capsule. The bottom right panel shows a magnified view of the structure of the thymus. Labels read (clockwise, from top): thymocytes, trabecula, fibrous capsule, cortex, medulla (layers), medullary epithelial cell, blood vessel, macrophage, dendritic cell, cortical epithelial cell.[Return to Figure 11.4].

Figure 11.5 image description: This flowchart shows the process in which a naïve T cell becomes activated T cells in the left part of the pathway and memory cells in the right part of the pathway. A naive T cell becomes an activated T cell when an antigen-presenting cell is introduced. The antigen is extracted from a pathogen and then either activated T cells are cloned and destroy the infected cells in the body, and/or memory T cells are produced and are activated if this antigen is encountered again. [Return to Figure 11.5].

Figure 11.6 image description: The left panel of this figure shows a micrograph of the cross section of a lymph node. Labels indicate the connective tissue capsule, cortex, and subcapsular sinus. The right panel shows the structure of a lymph node. Labels indicate (from top, clockwise) the efferent lymphatic vessels, connective tissue capsule, subcapsular sinus, cortex, afferent lymphatic vessels, trabecula, and germinal centers. [Return to Figure 11.6].

Figure 11.7 image description: The top left panel shows the location of the spleen in the human body. The top center panel shows a close up view of the location of the spleen. Labels read (clockwise, from top): hilum, spleen, diaphragm, splenic vein, splenic artery. The top right panel shows the blood vessels and spleen tissue. Labels read (from left to right, top then bottom) red pulp, trabecula (bottom) white pulp, arteriole, venule. The bottom panel shows a histological micrograph Labels read (clockwise, from top): trabecula, marginal zone, central artery or arteriole, germinal center, venous sinus, red pulp, arterial capillaries. [Return to Figure 11.7].

Figure 11.8 image description: The top panel of this image shows the locations of the tonsils. Labels read (clockwise from top):palatine tonsil, palatine bone, tongue, mandible, hyoid, trachea, esophagus. Callout shows the location of the pharyngeal tonsil. Labels read (from top): brain, sphenoidal sinus, sphenoid bone, pharyngeal tonsil, nasopharynx. Another callout details the location of the palatine tonsil. Labels read (from top): palatine tonsil, lingual tonsil, epiglottis. Another callout shows a photograph of the back of the throat where the tonsils are located. Labels read (from top) hard palate, soft palate, uvula, palatine tonsils (swollen due to infection) and tongue. The bottom panel shows the histological micrograph of the tonsils. Labels read (from top): crypt, stratified squamous epithelium, germinal centers. [Return to Figure 11.8].

Figure 11.9 image description: This figure shows a micrograph of a mucosa associated lymphoid tissue (MAST) nodule. Labels indicate the mucosa and Peyer's patches (which appear to be dark purple). [Return to Figure 11.9].

Figure 11.10 image description: This figure shows a lateral view of a human face in the top left. A magnified callout shows the germinal center of the palatine tonsil. Another magnified view shows how the innate immune system works. This process is described in greater detail in the text below the figure. [Return to Figure 11.10].

Figure 11.11 image description: The top panel of this figure shows the mast cells detecting an injury and initiating an inflammatory response. The bottom panel shows the increase in blood flow in response to histamine. [Return to Figure 11.11].

Figure 11.12 image description: This graph shows the antibody concentration as a function of time in primary and secondary response. Initial exposure indicates a low concentration of antibody, which then elevates over time during the primary immune response. It decreases a little during secondary exposure, but then spikes during the secondary immune response. [Return to Figure 11.12].

Figure 11.13 image description: This flowchart shows how the clonal selection of B cells takes place. The left panel shows the primary response and the right panel shows the secondary response. During a primary B cell immune response, both antibody-secreting plasma cells and memory B cells are produced. These memory cells lead to the differentiation of more plasma cells and memory B cells during secondary responses. [Return to Figure 11.13].

Figure 11.14 image description: This image shows Kaposi's Sarcoma lesions on the surface of the skin. [Return to Figure 11.14].

Figure 11.15 image description: The left panel of this figure shows an x-ray image of a person's hand with rheumatoid arthritis, and the right panel of this figure shows a woman's body with labels showing the different responses in the body when the patient suffers from lupus. Labels (from top, clockwise) read: psychological: fatigue, loss of appetite, face butterfly rash, pleura inflammation, pericardium inflammation, fingers and toes poor circulation, joints arthritis, muscles aches, mouth and nose ulcers, systemic: low-grade fever photosensitivity.[Return to Figure 11.15].

Unless otherwise indicated, this chapter contains material adapted from *Anatomy and Physiology* (on OpenStax), by Betts et al. and is used under a CC BY 4.0 international license. Download and access this book for free at https://openstax.org/books/anatomy-and-physiology/pages/1-introduction

This page titled 1.11: Lymphatic and Immune Systems is shared under a CC BY 4.0 license and was authored, remixed, and/or curated by Andrea Nelson and Katherine Greene via source content that was edited to the style and standards of the LibreTexts platform.

1.12: Respiratory System

Learning Objectives

- Examine the anatomy of the respiratory system
- Determine the main functions of the respiratory system
- Differentiate respiratory system medical terms and common abbreviations
- Recognize the medical specialties associated with the respiratory system
- Discover common diseases, disorders, and procedures related to the respiratory system

Respiratory System Word Parts

Click on prefixes, combining forms, and suffixes to reveal a list of word parts to memorize for the Respiratory System.

Query 1.12.1

This interactive element is not available in this format. Visit the link or scan the QR code to access it online.

View this Interactive Content online

Introduction to the Respiratory System

How long you can hold your breath as you continue reading... How long can you do it? Chances are you are feeling uncomfortable already. A typical human cannot survive without breathing for more than three minutes, and even if you wanted to hold your breath longer, your autonomic nervous system would take control. Although oxygen is critical for cells, it is the accumulation of carbon dioxide that primarily drives your need to breathe.

The major structures of the respiratory system function primarily to provide oxygen to body tissues for cellular respiration, remove the waste product carbon dioxide, and help to maintain acid-base balance. Portions of the respiratory system are also used for non-vital functions, such as sensing odors, speech production, and for straining, such as coughing.

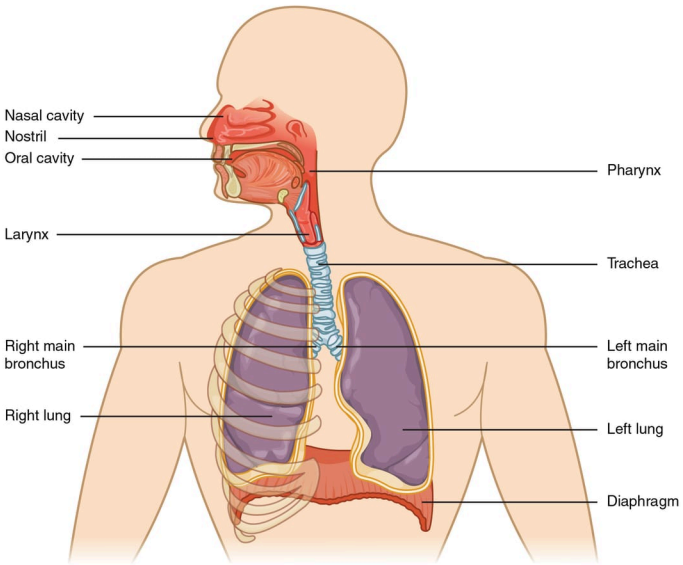

Figure 12.1 Major Respiratory Structures. The major respiratory structures span the nasal cavity to the diaphragm. From Betts et al., 2013. Licensed under CC BY 4.0. [Image description.]

Did you know?

If you hold your breath for longer than 3 minutes, your autonomic nervous system will take control.

Watch this video:

YouTube Video

This interactive element is not available in this format. Visit the link or scan the QR code to access it online.

View this YouTube Video online

Media 12.1. Respiratory System, Part 1: Crash Course A&P #31 [Online video]. Copyright 2015 by CrashCourse.

Practice Medical Terms Related to the Respiratory System

Query 1.12.2

This interactive element is not available in this format. Visit the link or scan the QR code to access it online.

View this Interactive Content online

Anatomy (Structures) of the Respiratory System

The Nose and its Adjacent Structures

The major entrance and exit for the respiratory system is through the **nose**. When discussing the nose, it is helpful to divide it into two major sections:

- external nose
- internal nose

The **nares** open into the nasal cavity, which is separated into left and right sections by the nasal septum (Figure 12.2). The **nasal septum** is formed anteriorly by a portion of the septal cartilage and posteriorly by the perpendicular plate of the ethmoid bone and the thin vomer bones.

Each lateral wall of the nasal cavity has three bony projections: the inferior conchae are separate bones, and the superior and middle conchae are portions of the ethmoid bone. **Conchae** increase the surface area of the nasal cavity, disrupting the flow of air as it enters the nose and causing air to bounce along the epithelium, where it is cleaned and warmed. The conchae and meatuses trap water during exhalation preventing dehydration.

The floor of the nasal cavity is composed of the hard palate and the soft palate. Air exits the nasal cavities via the internal nares and moves into the pharynx.

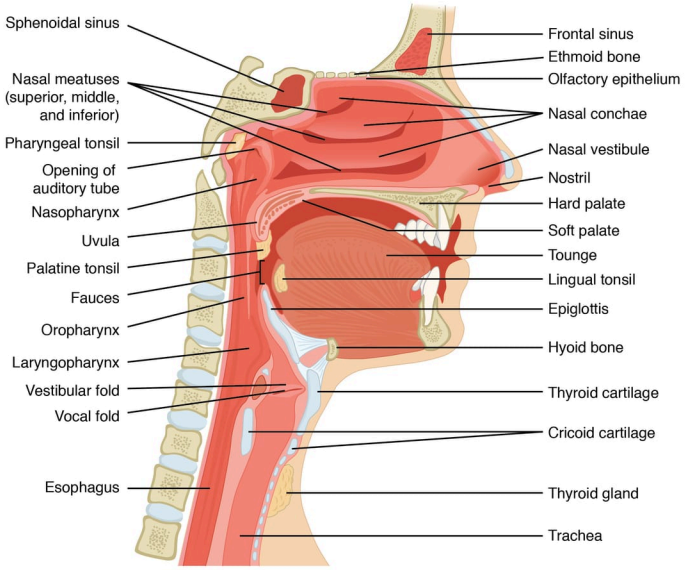

Figure 12.2 Upper Airway. From Betts et al., 2013. Licensed under CC BY 4.0. [Image description.]

Paranasal sinuses serve to warm and humidify incoming air and are lined with a mucosa which produces mucus. Paranasal sinuses are named for their associated bone:

- frontal sinus
- maxillary sinus
- sphenoidal sinus
- ethmoidal sinus

The nares and anterior portion of the nasal cavities are lined with mucous membranes, containing sebaceous glands and hair follicles that serve to prevent the passage of large debris, such as dirt, through the nasal cavity. An olfactory epithelium used to detect odors is found deeper in the nasal cavity.

The conchae, meatuses, and paranasal sinuses are lined by respiratory epithelium composed of pseudostratified ciliated columnar epithelium (Figure 12.3). The epithelium contains specialized epithelial cells that produce mucus to trap debris. The

cilia of the respiratory epithelium help to remove mucus and debris with a constant beating motion, sweeping materials towards the throat to be swallowed.

This moist epithelium functions to warm and humidify incoming air. Capillaries located just beneath the nasal epithelium warm the air by convection. Serous and mucus-producing cells also secrete **defensins**, or immune cells that patrol the connective tissue providing additional protection.

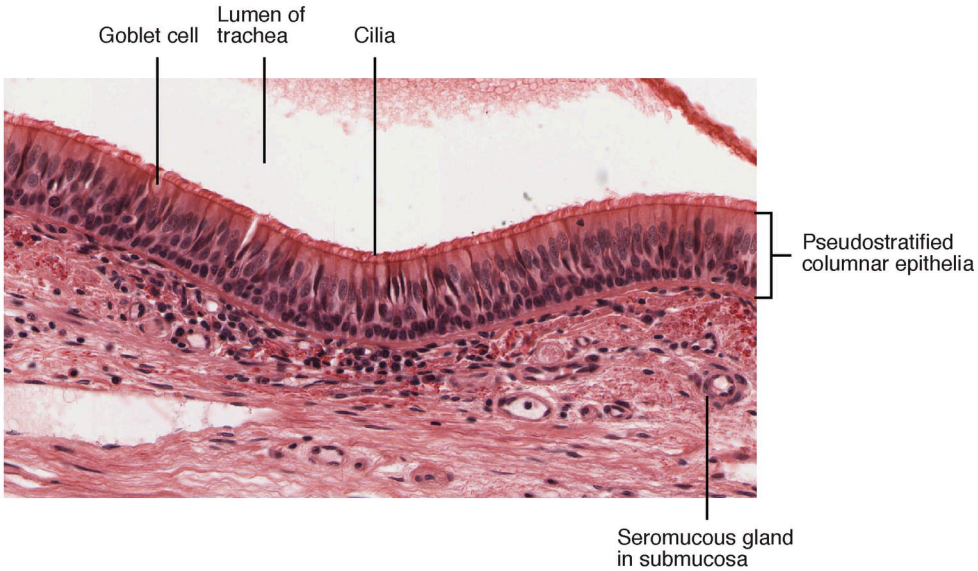

Figure 12.3 Pseudostratified Ciliated Columnar Epithelium. Respiratory epithelium is pseudostratified ciliated columnar epithelium. Seromucous glands provide lubricating mucus. LM × 680. (Micrograph provided by the Regents of University of Michigan Medical School © 2012). From Betts et al., 2013. Licensed under CC BY 4.0. [Image description.]

Did you know?

Cold air slows the movement of cilia that may result in the accumulation of mucus, leading to rhinorrhea during cold weather.

Pharynx

The pharynx is divided into three major regions: the **nasopharynx**, the **oropharynx**, and the **laryngopharynx** (see Figure 12.4).

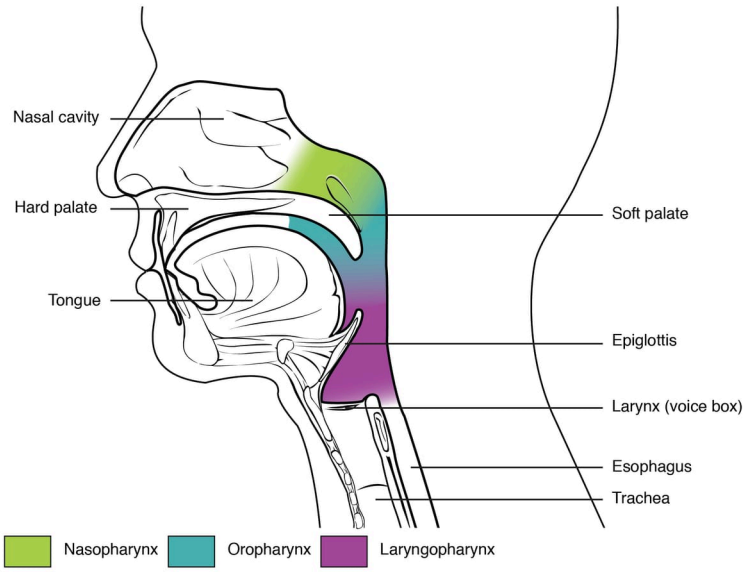

Figure 12.4 Divisions of the Pharynx. The pharynx is divided into three regions: the nasopharynx, the oropharynx, and the laryngopharynx. From Betts et al., 2013. Licensed under CC BY 4.0. [Image description.]

At the top of the **nasopharynx** are the pharyngeal tonsils. The function of the pharyngeal tonsil is not well understood, but it contains a rich supply of lymphocytes and is covered with ciliated epithelium that traps and destroys invading pathogens that enter during inhalation. The pharyngeal tonsils are large in children but tend to regress with age and may even disappear. The uvula and soft palate move like a pendulum during swallowing, swinging upward to close off the nasopharynx to prevent ingested materials from entering the nasal cavity. Auditory (Eustachian) tubes that connect to each middle ear cavity open into the nasopharynx. This connection is why colds often lead to ear infections.

The **oropharynx** is bordered superiorly by the nasopharynx and anteriorly by the oral cavity. The oropharynx contains two distinct sets of tonsils:

- The palatine tonsils.
  - A palatine tonsil is one of a pair of structures located laterally in the oropharynx in the area of the fauces.
- The lingual tonsils.
  - The lingual tonsil is located at the base of the tongue.

Similar to the pharyngeal tonsil, the palatine and lingual tonsils are composed of lymphoid tissue, and trap and destroy pathogens entering the body through the oral or nasal cavities.

The **laryngopharynx** is inferior to the oropharynx and posterior to the larynx. It continues the route for ingested material and air until its inferior end, where the digestive and respiratory systems diverge. The stratified squamous epithelium of the oropharynx is continuous with the laryngopharynx. Anteriorly, the laryngopharynx opens into the larynx, whereas posteriorly, it enters the esophagus.

Larynx

The structure of the larynx is formed by several pieces of cartilage. Three large cartilage pieces form the major structure of the larynx.

- Thyroid cartilage (anterior):
  - The thyroid cartilage is the largest piece of cartilage that makes up the larynx. The thyroid cartilage consists of the laryngeal prominence, or “Adam’s apple,” which tends to be more prominent in males.
- Epiglottis (superior):
  - Three smaller, paired cartilages—the arytenoids, corniculates, and cuneiforms—attach to the epiglottis and the vocal cords and muscle that help move the vocal cords to produce speech.
- Cricoid cartilage (inferior):

- The thick cricoid cartilage forms a ring, with a wide posterior region and a thinner anterior region.

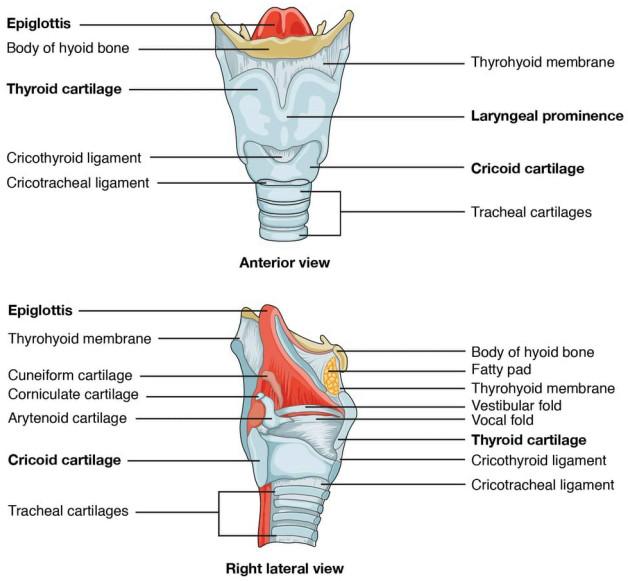

Figure 12.5 Larynx. The larynx extends from the laryngopharynx and the hyoid bone to the trachea. From Betts et al., 2013. Licensed under CC BY 4.0. [Image description.]

When the epiglottis is in the “closed” position, the unattached end of the epiglottis rests on the glottis. A vestibular fold, or false vocal cord, is one of a pair of folded sections of mucous membrane. A true vocal cord is one of the white, membranous folds attached by muscle to the thyroid and arytenoid cartilages of the larynx on their outer edges. The inner edges of the true vocal cords are free, allowing oscillation to produce sound.

The act of swallowing causes the pharynx and larynx to lift upward, allowing the pharynx to expand and the epiglottis of the larynx to swing downward, closing the opening to the trachea. These movements produce a larger area for food to pass through, while preventing food and beverages from entering the trachea.

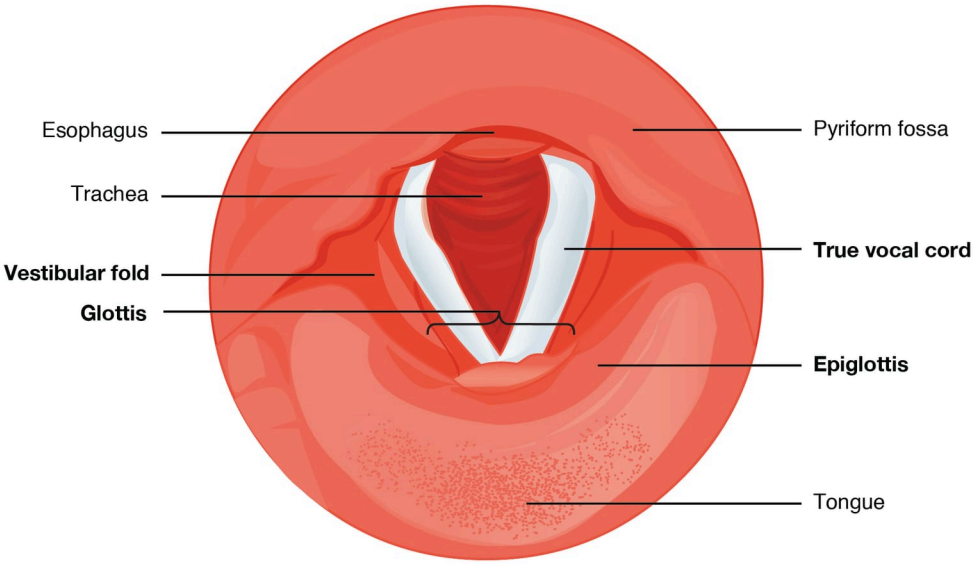

Figure 12.6 Vocal Cords. The true vocal cords and vestibular folds of the larynx are viewed inferiorly from the laryngopharynx. From Betts et al., 2013. Licensed under CC BY 4.0. [Image description.]

Similar to the nasal cavity and nasopharynx, this specialized epithelium produces mucus to trap debris and pathogens as they

enter the trachea. The cilia beat the mucus upward towards the laryngopharynx, where it can be swallowed down the esophagus.

Did you know?

Folds of the true vocal cords differ between individuals resulting in voices with different pitches.

Trachea

The trachea is formed by 16 to 20 stacked, C-shaped pieces of hyaline cartilage that are connected by dense connective tissue. The trachealis muscle and elastic connective tissue together form the fibroelastic membrane. The fibroelastic membrane allows the trachea to stretch and expand slightly during inhalation and exhalation, whereas the rings of cartilage provide structural support and prevent the trachea from collapsing. The trachealis muscle can be contracted to force air through the trachea during exhalation. The trachea is lined with pseudostratified ciliated columnar epithelium, which is continuous with the larynx. The esophagus borders the trachea posteriorly.

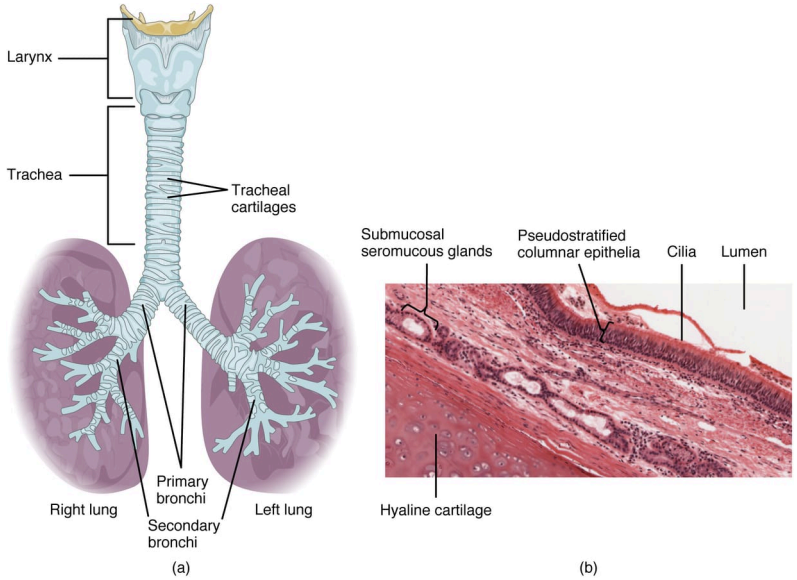

Figure 12.7 Trachea. (a) The tracheal tube is formed by stacked, C-shaped pieces of hyaline cartilage. (b) The layer visible in this cross-section of tracheal wall tissue between the hyaline cartilage and the lumen of the trachea is the mucosa, which is composed of pseudostratified ciliated columnar epithelium that contains goblet cells. LM × 1220. (Micrograph provided by the Regents of University of Michigan Medical School © 2012). From Betts et al., 2013. Licensed under CC BY 4.0. [Image description.]

Bronchial Tree

The trachea branches into the right and left primary bronchi at the carina. These bronchi are also lined by pseudostratified ciliated columnar epithelium containing mucus-producing goblet cells (Figure 12.7b). The carina is a raised structure that contains specialized nervous tissue that induces violent coughing if a foreign body, such as food, is present. Rings of cartilage, similar to those of the trachea, support the structure of the bronchi and prevent their collapse. The primary bronchi enter the lungs at the hilum. The bronchi continue to branch into a bronchial tree. A bronchial tree (or respiratory tree) is the collective term used for these multiple-branched bronchi. The main function of the bronchi, like other conducting zone structures, is to provide a passageway for air to move into and out of each lung. The mucous membrane traps debris and pathogens.

A bronchiole branches from the tertiary bronchi. Bronchioles, which are about 1 mm in diameter, further branch until they become the tiny terminal bronchioles, which lead to the structures of gas exchange. There are more than 1,000 terminal bronchioles in each lung. The muscular walls of the bronchioles do not contain cartilage like those of the bronchi. This muscular wall can change the size of the tubing to increase or decrease airflow through the tube.

Respiratory Zone

In contrast to the conducting zone, the respiratory zone includes structures that are directly involved in gas exchange. The respiratory zone begins where the terminal bronchioles join a respiratory bronchiole, the smallest type of bronchiole (see Figure 12.8), which then leads to an alveolar duct, opening into a cluster of alveoli.

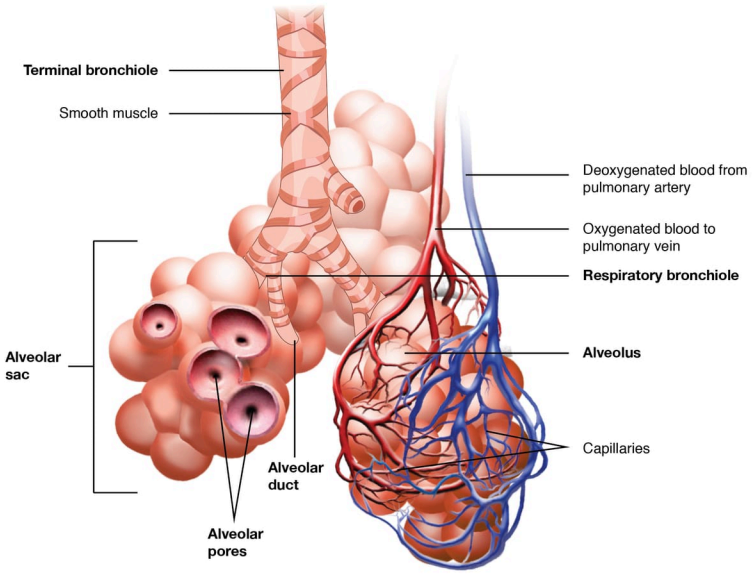

Figure 12.8 Respiratory Zone. Bronchioles lead to alveolar sacs in the respiratory zone, where gas exchange occurs. From Betts et al., 2013. Licensed under CC BY 4.0. [Image description.]

Alveoli

An alveolar duct opens into a cluster of alveoli. An alveolus is one of the many small, grape-like sacs that are attached to the alveolar ducts. An alveolar sac is a cluster of many individual alveoli that are responsible for gas exchange. An alveolus is approximately 200 μm in diameter with elastic walls that allow the alveolus to stretch during air intake, which greatly increases the surface area available for gas exchange. Alveoli are connected to their neighbors by alveolar pores, which help maintain equal air pressure throughout the alveoli and lung (see Figure 12.9).

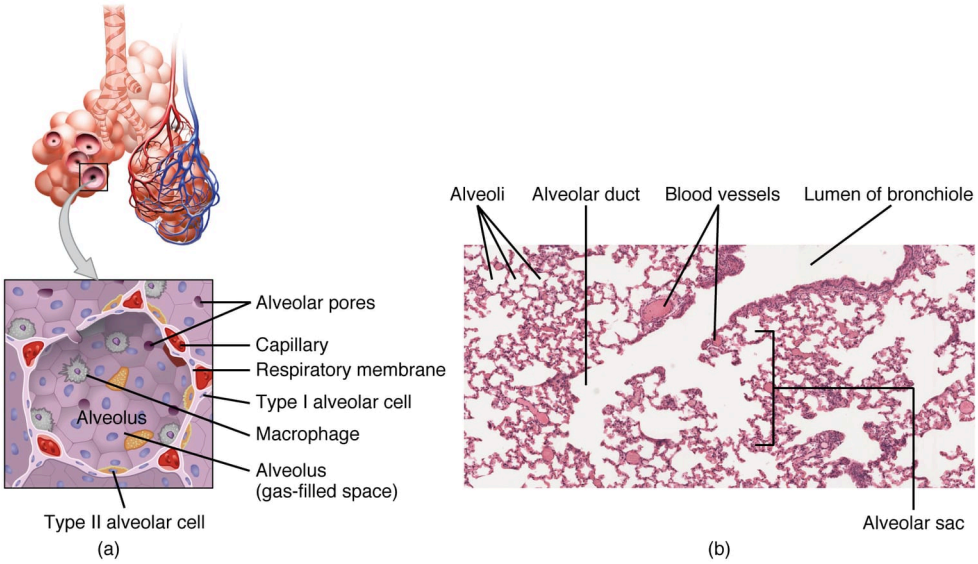

Figure 12.9 Structures of the Respiratory Zone. (a) The alveolus is responsible for gas exchange. (b) A micrograph shows the alveolar structures within lung tissue. LM × 178. (Micrograph provided by the Regents of University of Michigan Medical School © 2012). From Betts et al., 2013. Licensed under CC BY 4.0. [Image description.]

Concept Check

- What are the components of the bronchial tree?
- What is the purpose of cilia?
- Where does gas exchange take place?

Gross Anatomy of the Lungs

The lungs are pyramid-shaped, paired organs that are connected to the trachea by the right and left bronchi; on the inferior surface, the lungs are bordered by the diaphragm. The lungs are enclosed by the pleurae, which are attached to the mediastinum. The right lung is shorter and wider than the left lung, and the left lung occupies a smaller volume than the right. The cardiac notch allows space for the heart (see Figure 12.10). The apex of the lung is the superior region, whereas the base is the opposite region near the diaphragm. The costal surface of the lung borders the ribs. The mediastinal surface faces the midline.

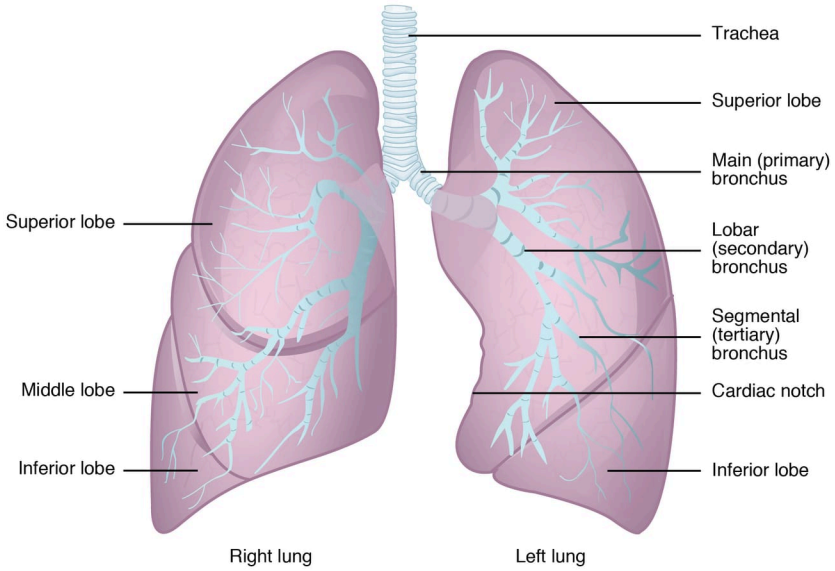

Figure 12.10 Gross Anatomy of the Lungs. From Betts et al., 2013. Licensed under CC BY 4.0. [Image description.]

Each lung is composed of smaller units called lobes. Fissures separate these lobes from each other. The right lung consists of three lobes: the superior, middle, and inferior lobes. The left lung consists of two lobes: the superior and inferior lobes. A pulmonary lobule is a subdivision formed as the bronchi branch into bronchioles. Each lobule receives its own large bronchiole that has multiple branches. An interlobular septum is a wall, composed of connective tissue, which separates lobules from one another.

Can you correctly label the respiratory system structures?

Query 1.12.3

This interactive element is not available in this format. Visit the link or scan the QR code to access it online.

View this Interactive Content online

Physiology (Function) of the Respiratory System

Blood Supply

The major function of the lungs is to perform gas exchange, which requires blood from the pulmonary circulation.

- This blood supply contains deoxygenated blood and travels to the lungs where erythrocytes pick up oxygen to be transported to tissues throughout the body.
- The pulmonary artery carries deoxygenated, arterial blood to the alveoli.
- The pulmonary artery branches multiple times as it follows the bronchi, and each branch becomes progressively smaller in diameter.
- One arteriole and an accompanying venule supply and drain one pulmonary lobule. As they near the alveoli, the pulmonary arteries become the pulmonary capillary network.
- The pulmonary capillary network consists of tiny vessels with very thin walls that lack smooth muscle fibers.
- The capillaries branch and follow the bronchioles and structure of the alveoli. It is at this point that the capillary wall meets the alveolar wall, creating the respiratory membrane.

- Once the blood is oxygenated, it drains from the alveoli by way of multiple pulmonary veins, which exit the lungs through the hilum.

Nervous Innervation

The blood supply of the lungs plays an important role in gas exchange and serves as a transport system for gases throughout the body. Innervation by both the parasympathetic and sympathetic nervous systems provides an important level of control through dilation and constriction of the airway.

- The parasympathetic system causes bronchoconstriction.
- The sympathetic nervous system stimulates bronchodilation.

Reflexes such as coughing, and the ability of the lungs to regulate oxygen and carbon dioxide levels, also result from autonomic nervous system control. Sensory nerve fibers arise from the vagus nerve, and from the second to fifth thoracic ganglia. The pulmonary plexus is a region on the lung root formed by the entrance of the nerves at the hilum. The nerves then follow the bronchi in the lungs and branch to innervate muscle fibers, glands, and blood vessels.

Pleura of the Lungs

Each lung is enclosed within a cavity that is surrounded by the pleura. The pleura (plural = pleurae) is a serous membrane that surrounds the lung. The right and left pleurae, which enclose the right and left lungs, respectively, are separated by the mediastinum.

The pleurae consist of two layers:

1. The **visceral pleura** is the layer that is superficial to the lungs and extends into and lines the lung fissures (see Figure 12.11).
2. The **parietal pleura** is the outer layer that connects to the thoracic wall, the mediastinum, and the diaphragm.

The visceral and parietal pleurae connect to each other at the hilum. The pleural cavity is the space between the visceral and parietal layers.

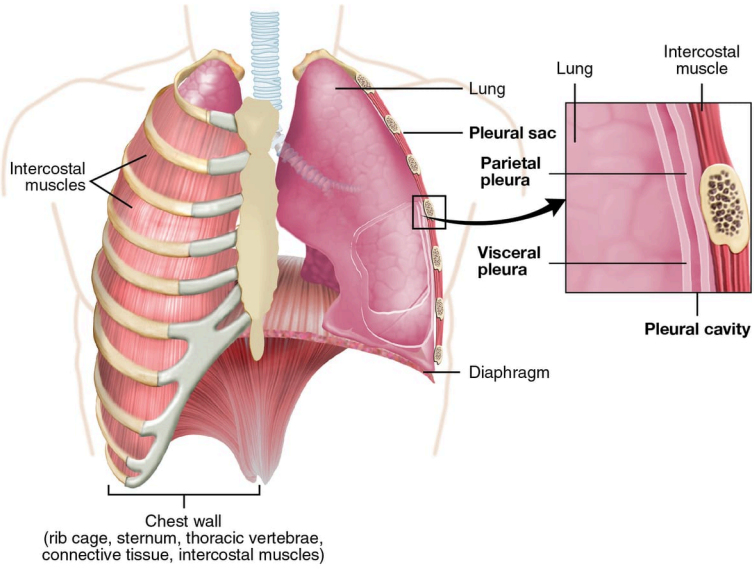

Figure 12.11 Parietal and Visceral Pleurae of the Lungs. From Betts et al., 2013. Licensed under CC BY 4.0. [Image description.]

The pleurae perform two major functions:

1. **Produce pleural fluid** that lubricates surfaces, reduces friction to prevent trauma during breathing, and creates surface tension that helps maintain the position of the lungs against the thoracic wall. This adhesive characteristic of the pleural fluid causes the lungs to enlarge when the thoracic wall expands during ventilation, allowing the lungs to fill with air.

2. The pleurae also **create a division** between major organs that prevents interference due to the movement of the organs, while preventing the spread of infection.

Pulmonary Ventilation

The difference in pressures drives pulmonary ventilation because air flows down a pressure gradient, that is, air flows from an area of higher pressure to an area of lower pressure.

- Air flows into the lungs largely due to a difference in pressure; atmospheric pressure is greater than intra-alveolar pressure, and intra-alveolar pressure is greater than intrapleural pressure.
- Air flows out of the lungs during expiration based on the same principle; pressure within the lungs becomes greater than the atmospheric pressure.

Pulmonary ventilation comprises two major steps: inspiration and expiration. Inspiration is the process of having air enter the lungs and expiration is the process of expelling air from the lungs (Figure 12.12). A respiratory cycle is one sequence of inspiration and expiration.

Two muscle groups are used during **normal inspiration**: the diaphragm and the external intercostal muscles. Additional muscles can be used if a bigger breath is required.

- The diaphragm contracts, it moves inferiorly toward the abdominal cavity, creating a larger thoracic cavity and more space for the lungs.
- The external intercostal muscles contract and move the ribs upward and outward, causing the rib cage to expand, which increases the volume of the thoracic cavity.

Due to the adhesive force of the pleural fluid, the expansion of the thoracic cavity forces the lungs to stretch and expand as well. This increase in volume leads to a decrease in intra-alveolar pressure, creating a pressure lower than atmospheric pressure. As a result, a pressure gradient is created that drives air into the lungs.

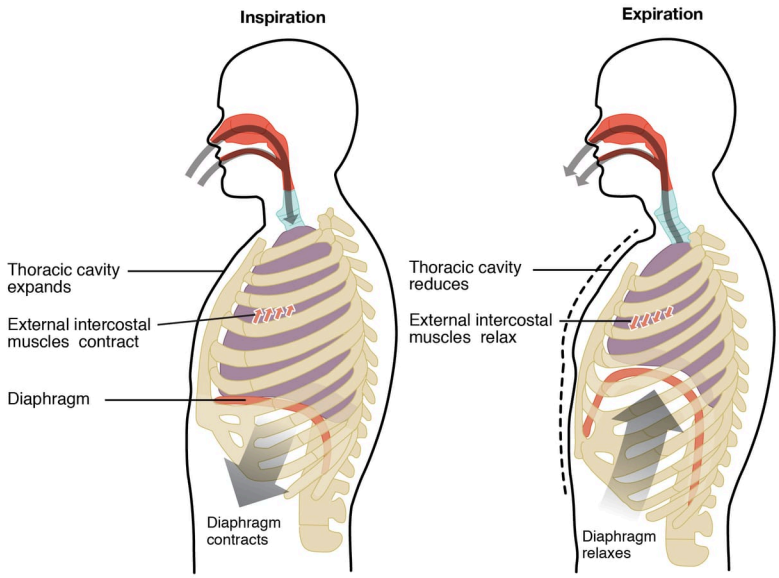

Figure 12.12 Inspiration and Expiration. Inspiration and expiration occur due to the expansion and contraction of the thoracic cavity, respectively. From Betts et al., 2013. Licensed under CC BY 4.0. [Image description.]

The process of **normal expiration** is passive, meaning that energy is not required to push air out of the lungs.

- The elasticity of the lung tissue causes the lung to recoil, as the diaphragm and intercostal muscles relax following inspiration.
- The thoracic cavity and lungs decrease in volume, causing an increase in intrapulmonary pressure. The intrapulmonary pressure rises above atmospheric pressure, creating a pressure gradient that causes air to leave the lungs.

There are different types, or modes, of breathing that require a slightly different process to allow inspiration and expiration:

- **Quiet breathing**, also known as eupnea, is a mode of breathing that occurs at rest and does not require the cognitive thought of the individual. During quiet breathing, the diaphragm and external intercostals must contract.
- **Diaphragmatic breathing**, also known as deep breathing, requires the diaphragm to contract. As the diaphragm relaxes, air passively leaves the lungs.
- **Costal breathing**, also known as a shallow breath, requires contraction of the intercostal muscles. As the intercostal muscles relax, air passively leaves the lungs.
- **Forced breathing**, also known as hyperpnea, is a mode of breathing that can occur during exercise or actions that require the active manipulation of breathing, such as singing.
  - During forced breathing, inspiration and expiration both occur due to muscle contractions. In addition to the contraction of the diaphragm and intercostal muscles, other accessory muscles must also contract.
    - During **forced inspiration**, muscles of the neck contract and lift the thoracic wall, increasing lung volume.
    - During **forced expiration**, accessory muscles of the abdomen contract, forcing abdominal organs upward against the diaphragm. This helps to push the diaphragm further into the thorax, pushing more air out. In addition, accessory muscles help to compress the rib cage, which also reduces the volume of the thoracic cavity.

Concept Check

- Breathing normally, place your hand on your stomach and take in one full respiratory cycle.
  - What type of breathing are you doing?
- Keeping your hand on your stomach, take in one large breath and exhale.
  - What type of breathing are you doing?
- Complete 10 jumping jacks. Once completed, place your hand on your stomach and take in one full respiratory cycle.
  - What type of breathing are you doing?

Respiratory Rate and Control of Ventilation

Breathing usually occurs without thought, although at times you can consciously control it, such as when you swim under water, sing a song, or blow bubbles. The respiratory rate is the total number of breaths that occur each minute. Respiratory rate can be an important indicator of disease, as the rate may increase or decrease during an illness or in a disease condition. The respiratory rate is controlled by the respiratory center located within the medulla oblongata in the brain, which responds primarily to changes in carbon dioxide, oxygen, and pH levels in the blood.

The normal respiratory rate of a child decreases from birth to adolescence:

- A child under 1 year of age has a normal respiratory rate between 30 and 60 breaths per minute.
- By the time a child is about 10 years old, the normal rate is closer to 18 to 30.
- By adolescence, the normal respiratory rate is similar to that of adults, 12 to 18 breaths per minute.

Did you know?

Respiratory rate is the total number of breaths that occur each minute

Watch this video:

YouTube Video

This interactive element is not available in this format. Visit the link or scan the QR code to access it online.

View this YouTube Video online

Media 12.1. Respiratory System, Part 2: Crash Course A&P #32 [Online video]. Copyright 2015 by CrashCourse.

Practice Terms Related to the Respiratory System

Query 1.12.4

This interactive element is not available in this format. Visit the link or scan the QR code to access it online.

View this Interactive Content online

Common Abbreviations for the Respiratory System

Many terms and phrases related to the respiratory system are abbreviated. Learn these common abbreviations by expanding the list below.

Query 1.12.5

This interactive element is not available in this format. Visit the link or scan the QR code to access it online.

View this Interactive Content online

Diseases and Disorders of the Respiratory System

A variety of diseases can affect the respiratory system, such as asthma, emphysema, chronic obstructive pulmonary disorder (COPD), and lung cancer. All of these conditions affect the gas exchange process and result in labored breathing and other difficulties.

The Effects of Second-Hand Tobacco Smoke

The burning of a tobacco cigarette creates multiple chemical compounds that are released through mainstream smoke, which is inhaled by the smoker, and through sidestream smoke, which is the smoke that is given off by the burning cigarette. **Second-hand smoke**, which is a combination of sidestream smoke and the mainstream smoke that is exhaled by the smoker, has been demonstrated by numerous scientific studies to cause disease. At least 40 chemicals in sidestream smoke have been identified that negatively impact human health, leading to the development of cancer or other conditions, such as immune system dysfunction, liver toxicity, cardiac arrhythmias, pulmonary edema, and neurological dysfunction. Tobacco and second-hand smoke

are considered to be carcinogenic. Exposure to second-hand smoke can cause lung cancer in individuals who are not tobacco users themselves.

- It is estimated that the risk of developing lung cancer is increased by up to 30% in nonsmokers who live with an individual who smokes in the house, as compared to nonsmokers who are not regularly exposed to second-hand smoke.
- Children who live with an individual who smokes inside the home have a larger number of lower respiratory infections, which are associated with hospitalizations, and higher risk of sudden infant death syndrome (SIDS). Second-hand smoke in the home has also been linked to a greater number of ear infections in children, as well as worsening symptoms of asthma.

Chronic Obstructive Pulmonary Disease (COPD)

COPD is a term used to represent a number of respiratory diseases, including chronic bronchitis and emphysema. COPD is a chronic condition with most symptoms appearing in middle-aged or older adults. Signs and symptoms include shortness of breath, cough, and sputum production. There is no cure for COPD. Shortness of breath may be controlled with bronchodilators. The best plan is to avoid triggers and getting sick. Clients with COPD are advised to avoid people who are sick, get vaccinated against influenza and pneumococcal pneumonia, and reduce their exposure to pollution and cigarette smoke. While there are several risk factors, as many as 75% of cases are associated with cigarette smoking (National Heart, Lung, and Blood Institute, n.d.). To learn more about COPD, visit the National Heart, Lung, and Blood Institute's web page.

Asthma

Asthma is a chronic disease characterized by inflammation, edema of the airway, and bronchospasms which can inhibit air from entering the lungs. Bronchospasms can lead to an "asthma attack." An attack may be triggered by environmental factors such as dust, pollen, pet hair, or dander, changes in the weather, mold, tobacco smoke, and respiratory infections, or by exercise and stress.

Signs and symptoms of an asthma attack involve coughing, shortness of breath, wheezing, and tightness of the chest. Symptoms of a severe asthma attack require immediate medical attention and may include dyspnea that results in cyanotic lips or face, confusion, drowsiness, a rapid pulse, sweating, and severe anxiety. The severity of the condition, frequency of attacks, and identified triggers influence the type of medication that an individual may require. Longer-term treatments are used for those with more severe asthma. Short-term, fast-acting drugs that are used to treat an asthma attack are typically administered via an inhaler. For young children or individuals who have difficulty using an inhaler, asthma medications can be administered via a nebulizer.

Lung Cancer

Lung cancer is a leading cause of cancer death among men and women. Smoking is the most significant risk factor for lung cancer, with 90% of cases in men and 80% of cases in women attributed to tobacco smoking. Signs and symptoms may include shortness of breath, wheezing, blood in the mucus, hoarseness, and trouble swallowing (MedlinePlus, n.d.).

There are two types of lung cancer, **small cell lung cancer (SCLC)** and non-small cell lung cancer (NSCLC). Both cancers occur when malignant cells form in the tissues of the lung. If metastasis occurs, lung cancer cells spread to other parts of the body. Treatment will depend on the type of lung cancer and the stage at diagnosis. Treatments may include surgery, chemotherapy, targeted therapy, immunotherapy, and radiation therapy (National Cancer Institute, 2021a, 2021b).

Sleep Apnea

Sleep apnea is a chronic disorder that occurs in children and adults. It is characterized by the cessation of breathing during sleep. These episodes may last for several seconds or several minutes, and may differ in the frequency with which they are experienced. Sleep apnea leads to poor sleep. Signs and symptoms include fatigue, evening napping, irritability, memory problems, morning headaches, and excessive snoring. A diagnosis of sleep apnea is usually done during a sleep study, where the patient is monitored in a sleep laboratory for several nights. Treatment of sleep apnea commonly includes the use of a device called a continuous positive airway pressure (CPAP) machine during sleep. The CPAP machine has a mask that covers the nose, or the nose and mouth, and forces air into the airway at regular intervals. This pressurized air can help to gently force the airway to remain open, allowing more normal ventilation to occur.

Medical Terms in Context

Query 1.12.6

This interactive element is not available in this format. Visit the link or scan the QR code to access it online.

View this Interactive Content online

Query 1.12.7

This interactive element is not available in this format. Visit the link or scan the QR code to access it online.

View this Interactive Content online

Query 1.12.8

This interactive element is not available in this format. Visit the link or scan the QR code to access it online.

View this Interactive Content online

Medical Specialties and Procedures Related to the Respiratory System

Respiratory Therapists (RTs)

Respiratory therapists (RTs) are healthcare professionals that monitor, assess, and treat people who are having problems breathing. RTs must have at least a two-year degree. RTs measure lung capacity, test oxygen and carbon dioxide levels, perform chest physiotherapy to remove mucus from patients' lungs, and operate ventilator equipment (Bureau of Labor Statistics, 2021). For more information, visit the American Association for Respiratory Care web page.

Thoracic Surgeon

A thoracic surgeon refers to a surgeon who has specialized in either thoracic (chest) surgery or cardiothoracic (heart and chest) surgery (National Cancer Institute, n.d.). To learn about the career path, read this PDF from The Society of Thoracic Surgeons.

Spirometry Testing

Spirometry testing is used to find out how well lungs are working by measuring air volume.

- **Respiratory volume** describes the amount of air in a given space within the lungs, or which can be moved by the lung, and is dependent on a variety of factors.
- **Tidal volume** refers to the amount of air that enters the lungs during quiet breathing, whereas inspiratory reserve volume is the amount of air that enters the lungs when a person inhales past the tidal volume.

- **Expiratory reserve volume** is the extra amount of air that can leave with forceful expiration, following tidal expiration.
- **Residual volume** is the amount of air that is left in the lungs after expelling the expiratory reserve volume.
- **Respiratory capacity** is the combination of two or more volumes.
- **Anatomical dead space** refers to the air within the respiratory structures that never participates in gas exchange, because it does not reach functional alveoli.
- **Respiratory rate** is the number of breaths taken per minute, which may change during certain diseases or conditions.

Both respiratory rate and depth are controlled by the respiratory centers of the brain, which are stimulated by factors such as chemical and pH changes in the blood. These changes are sensed by central chemoreceptors, which are located in the brain, and peripheral chemoreceptors, which are located in the aortic arch and carotid arteries. A rise in carbon dioxide or a decline in oxygen levels in the blood stimulates an increase in respiratory rate and depth.

Watch this video:

YouTube Video

This interactive element is not available in this format. Visit the link or scan the QR code to access it online.

View this YouTube Video online

Media 12.3. Peak Flow and Spirometry – Lung Function Tests [Online video]. Copyright 2012 by Oxford Medical Education.

Respiratory System Vocabulary

Adenoidectomy: Excision of the adenoids.

Alveolar duct: Small tube that leads from the terminal bronchiole to the respiratory bronchiole and is the point of attachment for alveoli.

Alveolitis: Inflammation of the alveoli.

Aphonia: Condition of the absence of one's voice.

Apnea: A temporary absence of respiration.

Asphyxia: Condition caused by a lack of oxygen that leads to impending or actual death.

Aspirate: To withdraw fluid, tissue, or other substances from a body cavity, cyst, or tumor.

Atelectasis: Failure of the lung to expand (inflate) completely.

Autonomic: Involuntary or unconscious.

Benign: Non-cancerous.

Bronchiectasis: Dilation of the bronchi.

Bronchitis: Inflammation of the bronchus.

Bronchodilators: A type of drug that causes small airways in the lungs to open up.

Bronchogenic carcinoma: Cancer that begins in the tissue that lines or covers the airways of the lungs, including small cell and non-small cell lung cancer.

Bronchopneumonia: Inflammation of the lung, particularly the bronchioles and alveoli, that is associated with bronchitis.

Bronchoscope: A thin, tube-like instrument used to examine the inside of the trachea, bronchi, and lungs.

Bronchoscopy: A procedure involving a bronchoscope to examine the inside of the trachea, bronchi, and lungs.

Bronchospasm: Spasmodic contraction of the smooth muscle of the bronchi.

Carcinogen: Any substance that causes cancer.

Cardiac notch: An indentation on the surface of the left lung.

Carina: A ridge at the base of the trachea (windpipe) that separates the openings of the right and left main bronchi (the large air passages that lead from the trachea to the lungs).

Chronic: A condition that lasts a long time with periods of remission and exacerbation.

Computerized tomography (CT): A noninvasive imaging technique that uses computers to analyze several cross-sectional X-rays in order to reveal minute details about structures in the body.

Conducting zone: The major functions of the conducting zone are to provide a route for incoming and outgoing air, remove debris and pathogens from the incoming air, and warm and humidify the incoming air.

Cyanotic: Pertaining to abnormal color of blue (bluish color, lips and nail beds) caused by deoxygenation.

Defensins: The lysozyme enzyme and proteins which have antibacterial properties.

Diaphragm: A sheet of skeletal muscle separating the thoracic and abdominal cavities that has to contract and relax for you to breathe.

Dysphonia: Condition of difficult speaking, including hoarseness and change in pitch or quality of the voice.

Dyspnea: Difficulty breathing.

Epiglottitis: Inflammation of the epiglottis.

Endoscope: A thin, tube-like instrument used to look at tissues inside the body.

Endoscopy: A procedure that uses an endoscope to examine the inside of the body.

Epiglottis: Leaf-shaped piece of elastic cartilage that is a portion of the larynx that swings to close the trachea during swallowing.

Epistaxis: Nosebleed.

Erythrocytes: Red blood cells.

Eupnea: A mode of breathing that occurs at rest and does not require the cognitive thought of the individual; also known as quiet breathing.

Expiration: Exhalation, or the process of causing air to leave the lungs.

External nose: The surface and skeletal structures that result in the outward appearance of the nose and contribute to its numerous functions.

Fauces: The opening of the oral cavity into the pharynx.

Fibroelastic membrane: A flexible membrane that closes the posterior surface of the trachea, connecting the C-shaped cartilages.

Glottis: Composed of the vestibular folds, the true vocal cords, and the space between these folds.

Hard palate: Located at the anterior region of the nasal cavity and is composed of bone.

Hemothorax: Hemorrhage within the pleural cavity.

Hematologist: A doctor who has special training in diagnosing and treating blood disorders.

Hematology: The study of blood and blood-forming issues.

Hilum of the lung: A concave region where blood vessels, lymphatic vessels, and nerves also enter the lungs.

Hypercapnia: Abnormally elevated blood levels of CO2 (carbon dioxide).

Hyperpnea: Forced breathing or breathing that is excessive.

Hypocapnia: Abnormally low blood levels of CO2 (carbon dioxide).

Hypoxemia: Below-normal level of oxygen saturation of blood (typically <95 percent).

Hypoxia: Lack of oxygen supply to the tissues.

Inferior: A position below or lower than another part of the body proper.

Influenza (flu): An acute viral infection involving the respiratory tract.

Inspiration: Inhalation, or process of breathing air into the lungs.

Laryngeal: Pertaining to the larynx.

Laryngitis: Inflammation of the larynx.

Laryngopharynx: One of the three regions of the pharynx; inferior to the oropharynx and posterior to the larynx.

Laryngoplasty: Surgical repair of the larynx.

Laryngoscope: A thin, tube-like instrument used to examine the larynx.

Laryngoscopy: Examination of the larynx with a mirror or laryngoscope.

Larynx: A cartilaginous structure inferior to the laryngopharynx that connects the pharynx to the trachea and helps regulate the volume of air that enters and leaves the lungs; also known as the voice box.

Lobectomy: Excision of the lobe(s) of an organ.

Lymphocytes: The second most common type of leukocyte and are essential for the immune response.

Malignant: Cancerous.

Mucus: A thick, slippery fluid made by the membranes that line certain organs of the body.

Nasopharyngitis: Inflammation of the nose and pharynx.

Nasopharynx: The upper part of the throat behind the nose. An opening on each side of the nasopharynx leads into the ear.

Nebulizer: A device used to turn liquid into a fine spray.

Nosocomial infection: Infection acquired in hospital.

Oropharynx: A passageway for both air and food; borders the nasopharynx and the oral cavity.

Oximeter: Instrument used to measure the oxygenation of tissues.

Pharyngeal tonsil: The tonsil located at the back of the throat; also known as the adenoid when swollen.

Pharyngitis: Inflammation of the pharynx.

Pharynx: A tube formed by skeletal muscle and lined by mucous membrane that is continuous with that of the nasal cavities; also known as the throat.

Pleural effusion: An abnormal collection of fluid between the thin layers of tissue (pleura) lining the lung and the wall of the chest cavity.

Pleurisy: Inflammation of the pleura.

Pneumoconiosis: A condition caused by the inhalation of dust.

Pneumonectomy: Excision of the lung.

Pneumonia: A severe inflammation of the lungs in which the alveoli (tiny air sacs) are filled with fluid.

Pneumothorax: An abnormal collection of air in the space between the thin layer of tissue that covers the lungs and the chest cavity that can cause all or part of the lung to collapse.

Polysomnography (PSG): Simultaneous and continuous monitoring of several parameters during sleep to study normal and abnormal sleep.

Posterior: Describes the back or direction toward the back of the body.

Pulmonary artery: Artery that arises from the pulmonary trunk.

Pulmonary edema: Fluid accumulation in alveoli and bronchioles (related to heart failure).

Pulmonary embolism: A blood clot within the lung.

Radiologist: A doctor who has special training in creating and interpreting pictures of areas inside the body.

Radiography: A procedure that uses x-rays to take pictures of areas inside the body.

Radiology: The use of radiation or other imaging technologies to diagnose or treat disease.

Respiratory zone: The respiratory zone includes structures that are directly involved in gas exchange.

Rhinitis: Inflammation of the mucous membranes of the nose.

Rhinoplasty: A plastic surgical operation on the nose, either reconstructive, restorative, or cosmetic.

Rhinorrhea: Excess nasal drainage; also called a “runny nose.”

Septal cartilage: The flexible hyaline cartilage connected to the nasal bone.

Sinusitis: Inflammation of the sinuses.

Soft palate: Located at the posterior portion of the nasal cavity and consists of muscle tissue.

Sonogram: A computer picture of areas inside the body created by high-energy sound waves.

Spirometry: The measurement of volume of air inhaled or exhaled by the lung.

Sputum: Mucus and other matter brought up from the lungs by coughing.

Stethoscope: An instrument is used to hear sounds produced by the heart, lungs, or other parts of the body.

Sympathetic nervous system (SNS): The division of the nervous system involved in our fight-or-flight responses. It continuously

monitors body temperature and initiates appropriate motor responses.

Tachypnea: Rapid breathing.

Thoracalgia: Pain in the chest.

Thoracentesis: Removal of fluid from the pleural cavity through a needle inserted between the ribs.

Thoracic: Pertaining to the chest.

Thoracoscope: A thin tube-like instrument used to examine the inside of the chest.

Thoracoscopy: Examination of the inside of the chest, using a thoracoscope.

Thoracotomy: An operation to open the chest.

Tonsillectomy: Excision of the tonsils.

Tonsillitis: Inflammation of the tonsils.

Tracheitis: Inflammation of the trachea.

Tracheostomy: Surgery to create an opening into the trachea.

Tracheotomy: Surgical incision of the trachea.

Trachea: The windpipe.

Upper respiratory infection: Infection of the nasal cavity, pharynx and larynx cause by a virus.

Uvula: A small bulbous, teardrop-shaped structure located at the apex of the soft palate.

Ventilator: A machine used to help a patient breathe.

Test Yourself

Query 1.12.9

This interactive element is not available in this format. Visit the link or scan the QR code to access it online.

View this Interactive Content online

References

Bureau of Labor Statistics. (2021). Respiratory therapists. In *Occupational outlook handbook*. U.S. Department of Labor. https://www.bls.gov/ooh/healthcare/respiratory-therapists.htm

CrashCourse. (2015, August 24). *Respiratory system, part 1: crash course A&P #31* [Video]. YouTube. https://youtu.be/bHZsvBdUC2I

CrashCourse. (2015, August 31). *Respiratory system, part 2: crash course A&P #32* [Video]. YouTube. https://youtu.be/Cqt4LjHnMEA

National Cancer Institute. (n.d.). *Thoracic surgeon definition*. National Institutes of Health, U.S. Department of Health.

https://www.cancer.gov/publications/dictionaries/cancer-terms/def/thoracic-surgeon

National Cancer Institute. (2021a). *Non-small cell lung cancer treatment (PDQ®)-Patient version*. National Institutes of Health, U.S. Department of Health. https://www.cancer.gov/types/lung/patient/non-small-cell-lung-treatment-pdq

National Cancer Institute. (2021b). *Small cell cancer treatment (PDQ®)-Patient version*. National Institutes of Health, U.S. Department of Health. https://www.cancer.gov/types/lung/patient/small-cell-lung-treatment-pdq

National Heart, Lung, and Blood Institute. (n.d.). *COPD*. National Institutes of Health, U.S. Department of Health. https://www.nhlbi.nih.gov/health-topics/copd

Oxford Medical Education. (2012, May 13). *Peak flow and spirometry – Lung function tests* [Video]. YouTube. https://www.youtube.com/watch?v=M4C8EInOMOI

Image Descriptions

Figure 12.1 image description: This figure shows the upper half of the human body. The major organs in the respiratory system are labeled. [Return to Figure 12.1].

Figure 12.2 image description: This figure shows a cross section view of the nose and throat. The major parts are labeled. [Return to Figure 12.2].

Figure 12.3 image description: This figure shows a micrograph of pseudostratified epithelium. [Return to Figure 12.3].

Figure 12.4 image description: This figure shows the side view of the face. The different parts of the pharynx are color-coded and labeled (from the top): nasal cavity, hard palate, soft palate, tongue, epiglottis, larynx, esophagus, trachea. [Return to Figure 12.4].

Figure 12.5 image description: The top panel of this figure shows the anterior view of the larynx, and the bottom panel shows the right lateral view of the larynx. [Return to Figure 12.5].

Figure 12.6 image description: This diagram shows the cross-section of the larynx. The different types of cartilages are labeled (clockwise from top): pyriform fossa, true vocal cord, epiglottis, tongue, glottis, vestibular fold, trachea, esophagus. [Return to Figure 12.6].

Figure 12.7 image description: The top panel of this figure shows the trachea and its organs. The major parts including the larynx, trachea, bronchi, and lungs are labeled. [Return to Figure 12.7].

Figure 12.8 image description: This image shows the bronchioles and alveolar sacs in the lungs and depicts the exchange of oxygenated and deoxygenated blood in the pulmonary blood vessels. [Return to Figure 12.8].

Figure 12.9 image description: This figure shows the detailed structure of the alveolus. The top panel shows the alveolar sacs and the bronchioles. The middle panel shows a magnified view of the alveolus, and the bottom panel shows a micrograph of the cross section of a bronchiole. [Return to Figure 12.9].

Figure 12.10 image description: Diagram of the lungs with the major parts labelled (from top, clockwise): trachea, superior lobe, main bronchus, lobar bronchus, segmental bronchus, inferior lobe, inferior lobe, middle lobe, superior lobe of the left lung. [Return to Figure 12.10].

Figure 12.11 image description: This figure shows the lungs and the chest wall, which protects the lungs, in the left panel. In the right panel, a magnified image shows the pleural cavity and a pleural sac. [Return to Figure 12.11].

Figure 12.12 image description: The left panel of this image shows a person inhaling air and the location of the chest muscles. The right panel shows the person exhaling air and the contraction of the thoracic cavity. [Return to Figure 12.12].

Unless otherwise indicated, this chapter contains material adapted from *Anatomy and Physiology* (on OpenStax), by Betts et al. and is used under a CC BY 4.0 international license. Download and access this book for free at https://openstax.org/books/anatomy-and-physiology/pages/1-introduction.

This page titled 1.12: Respiratory System is shared under a CC BY 4.0 license and was authored, remixed, and/or curated by Andrea Nelson and Katherine Greene via source content that was edited to the style and standards of the LibreTexts platform.

1.13: Digestive System

Learning Objectives

- Examine the anatomy of the digestive system
- Determine the main functions of the digestive system
- Differentiate the medical terms of the digestive system and common abbreviations
- Recognize the medical specialties associated with the digestive system
- Discover common diseases, disorders, and procedures related to the digestive system

Digestive System Word Parts

Click on prefixes, combining forms, and suffixes to reveal a list of word parts to memorize for the Digestive System.

Query 1.13.1

This interactive element is not available in this format. Visit the link or scan the QR code to access it online.

View this Interactive Content online

Introduction to the Digestive System

The digestive system is continually at work, yet people seldom appreciate the complex tasks it performs in a choreographed biologic symphony. Consider what happens when you eat an apple. Of course, you enjoy the apple's taste as you chew it, but in the hours that follow, unless something goes amiss and you get a stomachache, you don't notice that your digestive system is working. You may be taking a walk or studying or sleeping, having forgotten all about the apple, but your stomach and intestines are busy digesting it and absorbing its vitamins and other nutrients. By the time any waste material is excreted, the body has appropriated all it can use from the apple. In short, whether you pay attention or not, the organs of the digestive system perform their specific functions, allowing you to use the food you eat to keep you going.

This chapter examines the structure and functions of these organs and explores the mechanics and chemistry of the digestive processes. The function of the digestive system is to break down the foods you eat, release their nutrients, and absorb those nutrients into the body. Although the small intestine is the workhorse of the system, where the majority of digestion occurs, and where most of the released nutrients are absorbed into the blood or lymph, each of the digestive system organs makes a vital contribution to this process (see Figure 13.1).

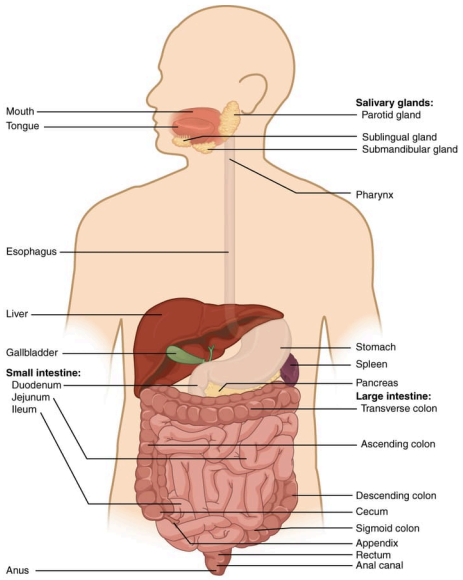

Figure 13.1 Components of the Digestive System. All digestive organs play integral roles in the life-sustaining process of digestion. From Betts et al., 2013. Licensed under CC BY 4.0. [Image description.]

Watch this video:

YouTube Video

This interactive element is not available in this format. Visit the link or scan the QR code to access it online.

View this YouTube Video online

Media 13.1 Digestive System, Part 1: Crash Course A&P #33. Copyright 2015 by CrashCourse.

Practice Medical Terms Related to the Digestive System

Query 1.13.2

This interactive element is not available in this format. Visit the link or scan the QR code to access it online.

View this Interactive Content online

Practice with This Activity:

Query 1.13.3

This interactive element is not available in this format. Visit the link or scan the QR code to access it online.

View this Interactive Content online

Anatomy (Structures) of the Digestive System

The Mouth

The cheeks, tongue, and palate frame the mouth, which is also called the **oral cavity** (or buccal cavity). The structures of the mouth are illustrated in Figure 13.2.

At the entrance to the mouth are the lips, or labia (singular = labium). Their outer covering is skin, which transitions to a mucous membrane in the mouth proper. Lips are very vascular with a thin layer of keratin; hence, the reason they are red.

The pocket-like part of the mouth that is framed on the inside by the gums and teeth, and on the outside by the cheeks and lips is called the **oral vestibule**. Moving farther into the mouth, the opening between the oral cavity and throat (oropharynx) is called the **fauces** (like the kitchen "faucet"). The main open area of the mouth, or oral cavity proper, runs from the gums and teeth to the fauces.

When you are chewing, you do not find it difficult to breathe simultaneously. The next time you have food in your mouth, notice how the arched shape of the roof of your mouth allows you to handle both digestion and respiration at the same time. This arch is called the palate. The anterior region of the palate serves as a wall (or septum) between the oral and nasal cavities as well as a rigid shelf against which the tongue can push food. It is created by the maxillary and palatine bones of the skull and, given its bony structure, is known as the hard palate. If you run your tongue along the roof of your mouth, you'll notice that the hard palate ends in the posterior oral cavity, and the tissue becomes fleshier. This part of the palate, known as the **soft palate**, is composed mainly of skeletal muscle. You can therefore manipulate, subconsciously, the soft palate—for instance, to yawn, swallow, or sing (see Figure 13.2).

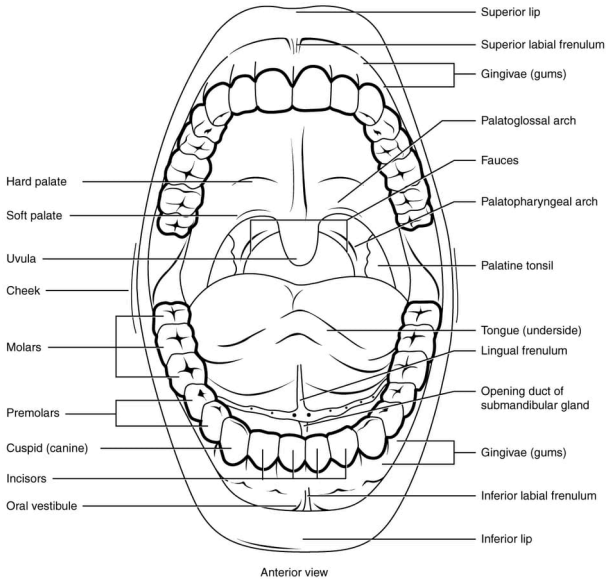

Figure 13.2 Mouth. The mouth includes the lips, tongue, palate, gums, and teeth. From Betts et al., 2013. Licensed under CC BY 4.0. [Image description.]

A fleshy bead of tissue called the **uvula** drops down from the center of the posterior edge of the soft palate. Although some have suggested that the uvula is a vestigial organ, it serves an important purpose. When you swallow, the soft palate and uvula move upward, helping to keep foods and liquid from entering the nasal cavity. Unfortunately, it can also contribute to the sound produced by snoring. Two muscular folds extend downward from the soft palate, on either side of the uvula. Toward the front, the **palatoglossal arch** lies next to the base of the tongue; behind it, the **palatopharyngeal arch** forms the superior and lateral margins of the fauces. Between these two arches are the palatine tonsils, clusters of lymphoid tissue that protect the pharynx. The lingual tonsils are located at the base of the tongue.

Did you know?

You can eat upside down. Food doesn't need gravity to reach your stomach. Peristalsis, a wave-like muscle movement, pushes food along.

Tongue

Perhaps you have heard it said that the **tongue** is the strongest muscle in the body. Those who stake this claim cite its strength proportional to its size. Although it is difficult to quantify the relative strength of different muscles, it remains indisputable that the tongue is a workhorse, facilitating **ingestion**, **mechanical digestion**, **chemical digestion** (lingual lipase), **sensation** (of taste, texture, and temperature of food), **swallowing**, and **vocalization**.

The tongue is attached to the mandible, the styloid processes of the temporal bones, and the hyoid bone. The hyoid is unique in that it only distantly/indirectly articulates with other bones. The tongue is positioned over the floor of the oral cavity. A medial septum extends the entire length of the tongue, dividing it into symmetrical halves.

The top and sides of the tongue are studded with papillae, extensions of lamina propria of the mucosa, which are covered in stratified squamous epithelium (see Figure 13.3).

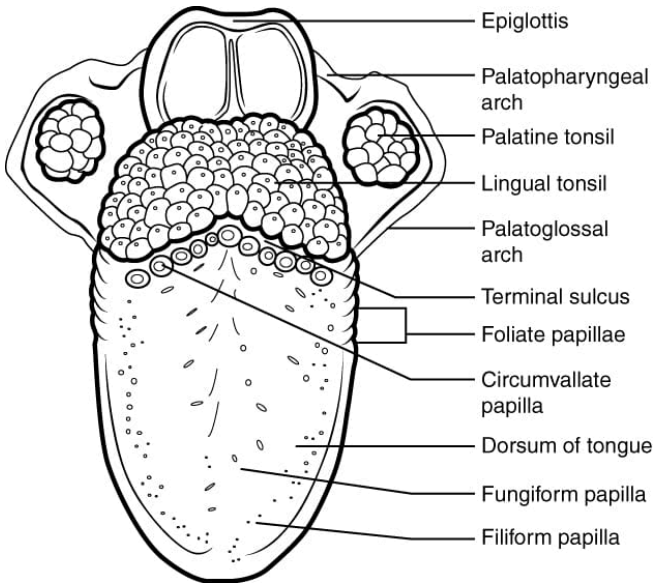

Figure 13.3 Tongue. This superior view of the tongue shows the locations and types of lingual papillae. From Betts et al., 2013. Licensed under CC BY 4.0. [Image description.]

Salivary Glands

Many small **salivary glands** are housed within the mucous membranes of the mouth and tongue. These minor exocrine glands are constantly secreting **saliva**, either directly into the oral cavity or indirectly through ducts, even while you sleep. In fact, an average of 1 to 1.5 liters of saliva is secreted each day. Usually, just enough saliva is present to moisten the mouth and teeth. Secretion increases when you eat because saliva is essential to moisten food and initiate the chemical breakdown of carbohydrates. Small amounts of saliva are also secreted by the **labial glands** in the lips. In addition, the **buccal glands** in the cheeks, palatal glands in the palate, and lingual glands in the tongue help ensure that all areas of the mouth are supplied with adequate saliva.

Concept Check

- Describe how the **anatomy** of the **mouth** permits breathing and chewing at the same time.
- Explain the role **saliva** performs in the digestive system.

Pharynx

The pharynx (throat) is involved in both digestion and respiration. It receives food and air from the mouth, and air from the nasal cavities. When food enters the pharynx, involuntary muscle contractions close off the air passageways. A short tube of skeletal muscle lined with a **mucous membrane**, the pharynx runs from the posterior oral and nasal cavities to the opening of the esophagus and larynx. It has three subdivisions. The most superior, the nasopharynx, is involved only in breathing and speech. The other two subdivisions, the **oropharynx** and the **laryngopharynx**, are used for both breathing and digestion. The oropharynx begins inferior to the nasopharynx and is continuous below with the laryngopharynx. The inferior border of the laryngopharynx connects to the esophagus, whereas the anterior portion connects to the larynx, allowing air to flow into the bronchial tree.

Esophagus

The esophagus is a muscular tube that connects the pharynx to the stomach. It is approximately 25.4 cm (10 in) in length, located posterior to the trachea, and remains in a collapsed form when not engaged in swallowing. As you can see in Figure 13.4, the esophagus runs a mainly straight route through the mediastinum of the thorax. To enter the abdomen, the esophagus penetrates the diaphragm through an opening called the esophageal hiatus.

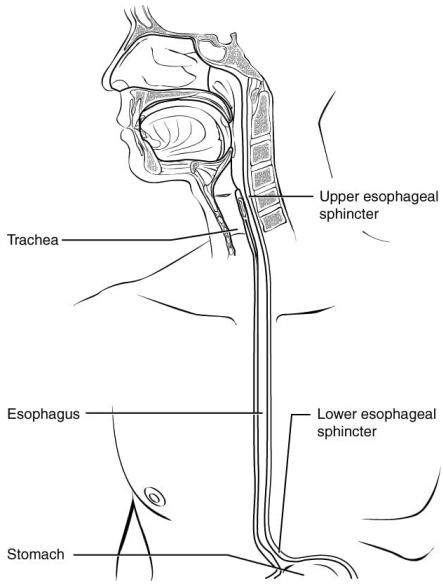

Figure 13.4 Esophagus. The upper esophageal sphincter controls the movement of food from the pharynx to the esophagus. The lower esophageal sphincter controls the movement of food from the esophagus to the stomach. From Betts et al., 2013. Licensed under CC BY 4.0. [Image description.]

Passage of Food Through the Esophagus

The upper **esophageal sphincter**, which is continuous with the inferior pharyngeal **constrictor,** controls the movement of food from the pharynx into the esophagus. The upper two-thirds of the esophagus consists of both smooth and skeletal muscle fibers, with the latter fading out in the bottom third of the esophagus. Rhythmic waves of **peristalsis**, which begin in the upper esophagus, propel the bolus of food toward the stomach. Meanwhile, secretions from the esophageal mucosa lubricate the esophagus and food. Food passes from the esophagus into the stomach at the lower esophageal sphincter (also called the gastroesophageal or cardiac sphincter). Recall that sphincters are muscles that surround tubes and serve as valves, closing the tube when the sphincters contract and opening it when they relax.

Stomach

There are four main regions in the **stomach**: the cardia, fundus, body, and pylorus (see Figure 13.5). The **cardia** (or cardiac region) is the point where the esophagus connects to the stomach and through which food passes into the stomach. Located inferior to the diaphragm, above and to the left of the cardia, is the dome-shaped **fundus**. Below the fundus is the **body**, the main part of the stomach. The funnel-shaped **pylorus** connects the stomach to the duodenum. The wider end of the funnel, the **pyloric antrum**, connects to the body of the stomach. The narrower end is called the **pyloric canal**, which connects to the duodenum. The smooth muscle **pyloric sphincter** is located at this latter point of connection and controls stomach emptying. In the absence of food, the stomach deflates inward, and its mucosa and submucosa fall into a large fold called a **ruga.**

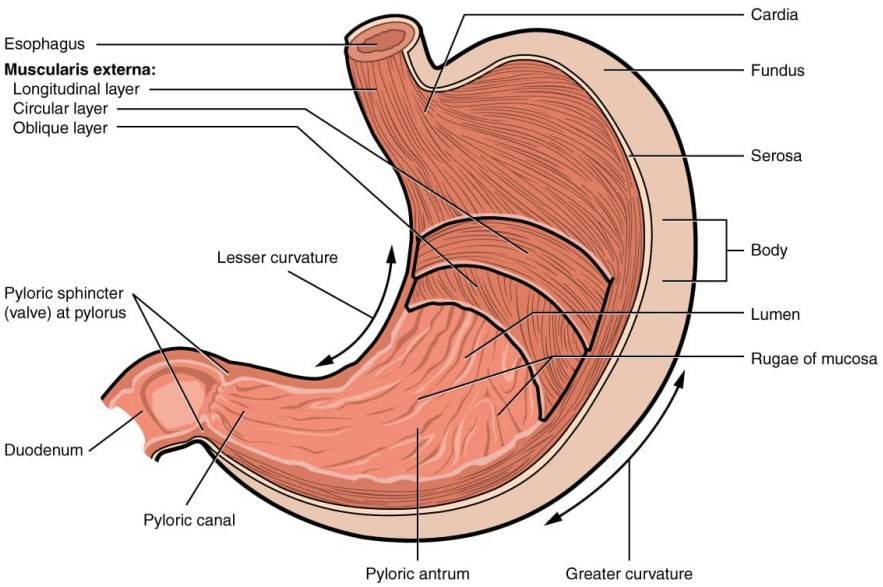

Figure 13.5 Stomach. The stomach has four major regions: the cardia, fundus, body, and pylorus. The addition of an inner oblique smooth muscle layer gives the muscularis the ability to vigorously churn and mix food. From Betts et al., 2013. Licensed under CC BY 4.0. [Image description.]

The convex lateral surface of the stomach is called the greater curvature; the **concave** medial border is the lesser curvature. The stomach is held in place by the lesser omentum, which extends from the liver to the lesser curvature, and the greater omentum, which runs from the greater curvature to the posterior abdominal wall.

Small Intestines

Chyme released from the stomach enters the **small intestine**, which is the primary digestive organ in the body. Not only is this where most digestion occurs, but it is also where practically all absorption occurs. The longest part of the **alimentary canal**, the small intestine, is about 3.05 meters (10 feet) long in a living person (but about twice as long in a cadaver due to the loss of muscle tone). Since this makes it about five times longer than the large intestine, you might wonder why it is called "small." In fact, its name derives from its relatively smaller diameter of only about 2.54 cm (1 in), compared with 7.62 cm (3 in) for the large intestine. As you will see shortly, in addition to its length, the folds and projections of the lining of the small intestine work to give it an enormous surface area, which is approximately 200 m^2, more than 100 times the surface area of your skin. This large surface area is necessary for complex processes of digestion and absorption that occur within it.

The coiled tube of the small intestine is subdivided into three regions. From proximal to distal, these are the duodenum, jejunum, and ileum (see Figure 13.6).

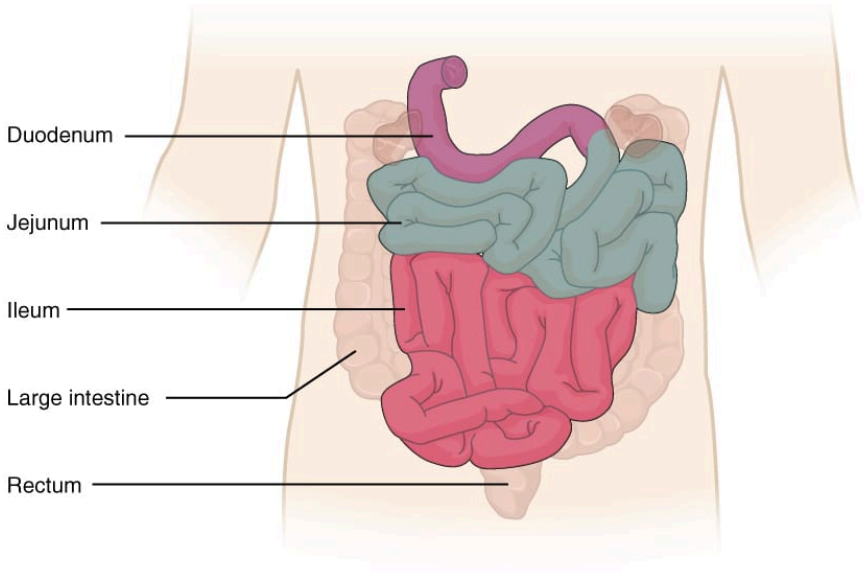

Figure 13.6 Small Intestine. The three regions of the small intestine are the duodenum, jejunum, and ileum. From Betts et al., 2013. Licensed under CC BY 4.0. [Image description.]

Did you know?

Your body absorbs 90% of your nutrients through the **small intestine** into your blood.

Large Intestines

The **large intestine** is the terminal part of the alimentary canal. The primary function of this organ is to finish absorption of nutrients and water, synthesize certain vitamins, form feces, and eliminate feces from the body. The large intestine runs from the appendix to the anus. It frames the small intestine on three sides. Despite its being about one-half as long as the small intestine, it is called large because it is more than twice the diameter of the small intestine, about 3 inches. The large intestine is subdivided into four main regions: the cecum, the colon, the rectum, and the anus. The ileocecal valve, located at the opening between the ileum and the large intestine, controls the flow of **chyme** from the small intestine to the large intestine.

Cecum

The first part of the large intestine is the **cecum**, a sac-like structure that is suspended inferior to the ileocecal valve. It is about 6 cm (2.4 in) long, receives the contents of the ileum, and continues the absorption of water and salts. The **appendix** (or vermiform appendix) is a winding tube that attaches to the cecum. Although the 7.6-cm (3-in) long appendix contains lymphoid tissue, suggesting an immunologic function, this organ is generally considered vestigial. However, at least one recent report assumes a survival advantage conferred by the appendix: in diarrheal illness, the appendix may serve as a bacterial reservoir to repopulate the enteric bacteria for those surviving the initial phases of the illness. Moreover, its twisted anatomy provides a haven for the accumulation and multiplication of enteric bacteria. The **mesoappendix**, the mesentery of the appendix, tethers it to the mesentery of the ileum.

Colon

The cecum blends seamlessly with the **colon**. Upon entering the colon, the food residue first travels up the **ascending colon** on the right side of the abdomen. At the inferior surface of the liver, the colon bends to form the **right colic flexure** (hepatic flexure) and becomes the **transverse colon**. The region defined as the hindgut begins with the last third of the transverse colon and continues. Food residue passing through the transverse colon travels across to the left side of the abdomen, where the colon angles sharply immediately inferior to the spleen, at the **left colic flexure** (splenic flexure). From there, food residue passes

through the **descending colon**, which runs down the left side of the posterior abdominal wall. After entering the pelvis inferiorly, it becomes the s-shaped **sigmoid colon**, which extends medially to the midline (see Figure 13.7). The ascending and descending colon, and the rectum (discussed next) are located in the retroperitoneum. The transverse and sigmoid colon are tethered to the posterior abdominal wall by the mesocolon.

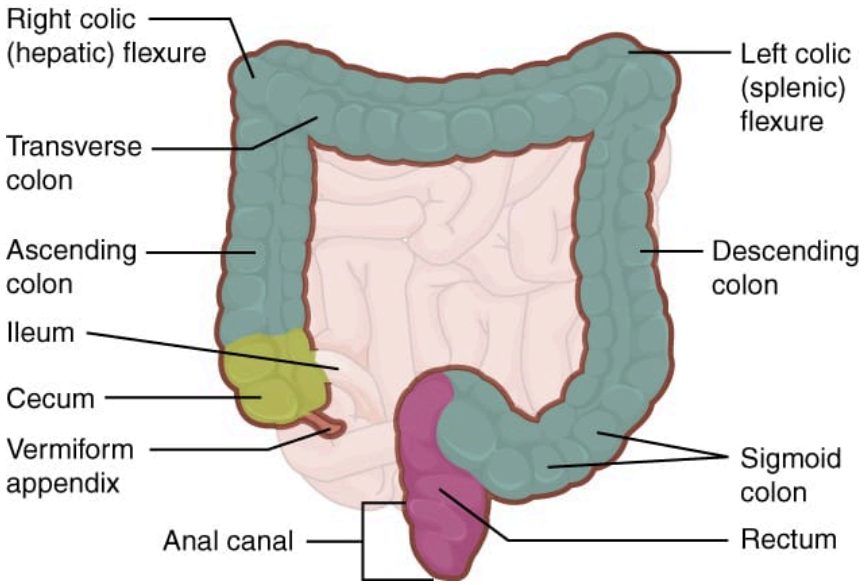

Figure 13.7 Large Intestine. The large intestine includes the cecum, colon, and rectum. From Betts et al., 2013. Licensed under CC BY 4.0. [Image description.]

Accessory Organs of Digestion

Chemical digestion in the small intestine relies on the activities of three accessory digestive organs: the liver, pancreas, and gallbladder (see Figure 13.8). The digestive role of the liver is to produce bile and export it to the duodenum. The gallbladder primarily stores, concentrates, and releases bile. The pancreas produces pancreatic juice, which contains digestive enzymes and bicarbonate ions, and delivers it to the duodenum.

Concept Check

On the Figure 13.8 diagram, locate the following **anatomical organs** and consider how these organs **support** the digestive process

- Liver
- Pancreas
- Gallbladder

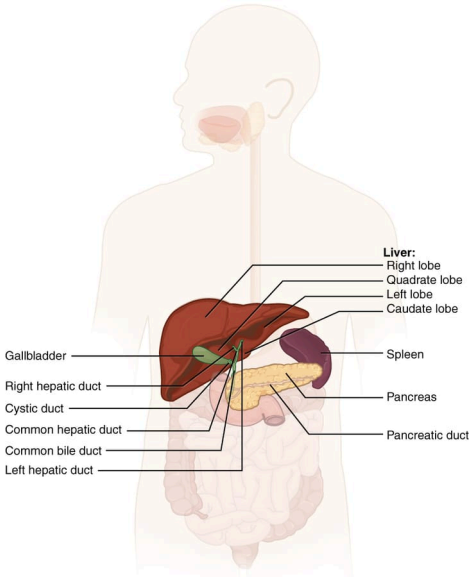

Figure 13.8 Accessory Organs. The liver, pancreas, and gallbladder are considered accessory digestive organs, but their roles in the digestive system are vital. From Betts et al., 2013. Licensed under CC BY 4.0. [Image description.]

Liver

The **liver** is the largest gland in the body, weighing about three pounds in an adult. It is also one of the most important organs. In addition to being an accessory digestive organ, it plays a number of roles in metabolism and regulation. The liver lies inferior to the diaphragm in the right upper quadrant of the abdominal cavity and receives protection from the surrounding ribs.

The liver is divided into two primary lobes: a large right lobe and a much smaller left lobe. In the right lobe, some anatomists also identify an inferior quadrate lobe and a posterior caudate lobe, which are defined by internal features. The liver is connected to the abdominal wall and diaphragm by five peritoneal folds referred to as ligaments.

The **porta hepatis** ("gate to the liver") is where the **hepatic artery** and **hepatic portal vein** enter the liver. These two vessels, along with the common hepatic duct, run behind the lateral border of the lesser omentum on the way to their destinations. The hepatic portal vein delivers partially deoxygenated blood containing nutrients absorbed from the small intestine and actually supplies more oxygen to the liver than do the much smaller hepatic arteries. In addition to nutrients, drugs and toxins are also absorbed. After processing the bloodborne nutrients and toxins, the liver releases nutrients needed by other cells back into the blood, which drains into the central vein and then through the hepatic vein to the inferior vena cava. With this **hepatic** portal circulation, all blood from the alimentary canal passes through the liver. This largely explains why the liver is the most common site for the metastasis of cancers that originate in the alimentary canal.

Bile produced by the liver is a mixture secreted by the liver to accomplish the emulsification of lipids in the small intestine.

Bilirubin, the main bile pigment, is a waste product produced when the spleen removes old or damaged red blood cells from the circulation. These breakdown products, including proteins, iron, and toxic bilirubin, are transported to the liver via the splenic vein of the hepatic portal system. In the liver, proteins and iron are recycled, whereas bilirubin is excreted in the bile. It accounts for the green color of bile. Bilirubin is eventually transformed by intestinal bacteria into stercobilin, a brown pigment that gives your stool its characteristic color. In some disease states, bile does not enter the intestine, resulting in white ('acholic') stool with a high fat content, since virtually no fats are broken down or absorbed.

Between meals, bile is produced but conserved. The valve-like hepatopancreatic ampulla closes, allowing bile to divert to the gallbladder, where it is concentrated and stored until the next meal.

Pancreas

The soft, oblong, glandular **pancreas** lies transversely in the retroperitoneum behind the stomach. Its head is nestled into the

“c-shaped” curvature of the duodenum with the body extending to the left about 15.2 cm (6 in) and ending as a tapering tail in the hilum of the spleen. It is a curious mix of exocrine (secreting digestive enzymes) and endocrine (releasing hormones into the blood) functions (Figure 13.9).

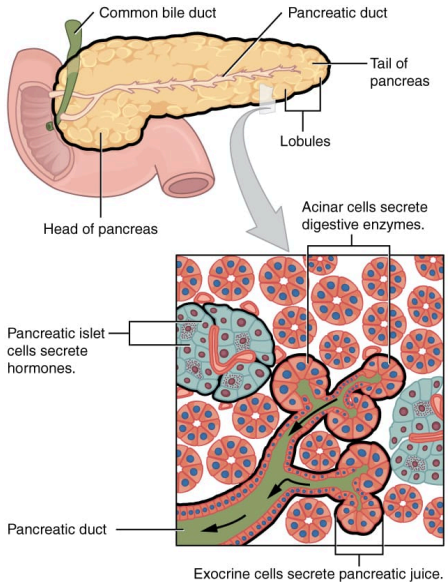

Figure 13.9 Exocrine and Endocrine Pancreas. The pancreas has a head, a body, and a tail. It delivers pancreatic juice to the duodenum through the pancreatic duct. From Betts et al., 2013. Licensed under CC BY 4.0. [Image description.]

The exocrine part of the pancreas arises as little grape-like cell clusters, each called an **acinus** (plural = acini), located at the terminal ends of pancreatic ducts. These acinar cells secrete enzyme-rich **pancreatic juice** into tiny merging ducts that form two dominant ducts. The larger duct fuses with the common bile duct (carrying bile from the liver and gallbladder) just before entering the duodenum via a common opening (the hepatopancreatic ampulla). The smooth muscle sphincter of the hepatopancreatic ampulla controls the release of pancreatic juice and bile into the small intestine. The second and smaller pancreatic duct, the **accessory duct** (duct of Santorini), runs from the pancreas directly into the duodenum, approximately 1 inch above the hepatopancreatic ampulla. When present, it is a persistent remnant of pancreatic development.

Scattered through the sea of exocrine acini are small islands of endocrine cells, the islets of Langerhans. These vital cells produce the hormones pancreatic polypeptide, insulin, glucagon, and somatostatin.

Gallbladder

The **gallbladder** is 8 to 10 cm (~3 to 4 in) long and is nested in a shallow area on the posterior aspect of the right lobe of the liver. This muscular sac stores, concentrates, and, when stimulated, propels the bile into the duodenum via the common bile duct. It is divided into three regions. The fundus is the widest portion and tapers medially into the body, which in turn narrows to become the neck. The neck angles slightly superiorly as it approaches the hepatic duct. The cystic duct is 1 to 2 cm (less than 1 in) long and turns inferiorly as it bridges the neck and hepatic duct.

The simple columnar epithelium of the gallbladder mucosa is organized in rugae, similar to those of the stomach. There is no submucosa in the gallbladder wall. The wall’s middle, muscular coat is made of smooth muscle fibers. When these fibers contract, the gallbladder’s contents are ejected through the **cystic duct** and into the bile duct (Figure 13.10). The visceral peritoneum reflected from the liver capsule holds the gallbladder against the liver and forms the outer coat of the gallbladder. The gallbladder’s mucosa absorbs water and ions from bile, concentrating it by up to 10-fold.

Concept Check

- Locate the **cystic duct** on the diagram shown below (Figure 13.10).

- Consider what **complications** could arise if this duct was blocked or obstructed.

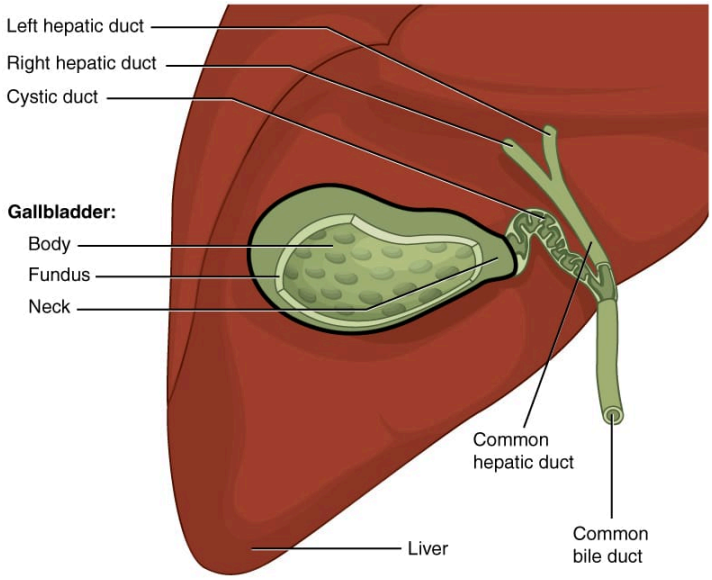

Figure 13.10 Gallbladder. The gallbladder stores and concentrates bile, and releases it into the two-way cystic duct when it is needed by the small intestine. From Betts et al., 2013. Licensed under CC BY 4.0. [Image description.]

Watch this video:

YouTube Video

This interactive element is not available in this format. Visit the link or scan the QR code to access it online.

View this YouTube Video online

Media 13.2 What does the liver do? – Emma Bryce. Copyright 2014 by TED-Ed.

Concept Check

At rest, about 1500 mL of blood per minute flows through the liver. What percentage of this blood flow comes from the hepatic portal system?

Anatomy Labeling Activity

Query 1.13.4

This interactive element is not available in this format. Visit the link or scan the QR code to access it online.

View this Interactive Content online

Physiology (Function) of the Digestive System

The main functions of the digestive system are:

- Ingesting food
- Digesting food
- Absorbing nutrients
- Elimination of waste products

Digestive Processes

The processes of digestion include six activities: ingestion, **propulsion**, mechanical or physical digestion, chemical digestion, absorption, and **defecation**.

The first of these processes, **ingestion**, refers to the entry of food into the alimentary canal through the mouth. There, the food is chewed and mixed with saliva, which contains enzymes that begin breaking down the carbohydrates in the food plus some lipid digestion via lingual lipase. Chewing increases the surface area of the food and allows an appropriately sized bolus to be produced.

Food leaves the mouth when the tongue and pharyngeal muscles propel it into the esophagus. This act of swallowing, the last voluntary act until defecation, is an example of **propulsion**, which refers to the movement of food through the digestive tract. It includes both the voluntary process of swallowing and the involuntary process of peristalsis. **Peristalsis** consists of sequential, alternating waves of contraction and relaxation of alimentary wall smooth muscles, which act to propel food along (see Figure 13.11). These waves also play a role in mixing food with digestive juices. Peristalsis is so powerful that foods and liquids you swallow enter your stomach even if you are standing on your head.

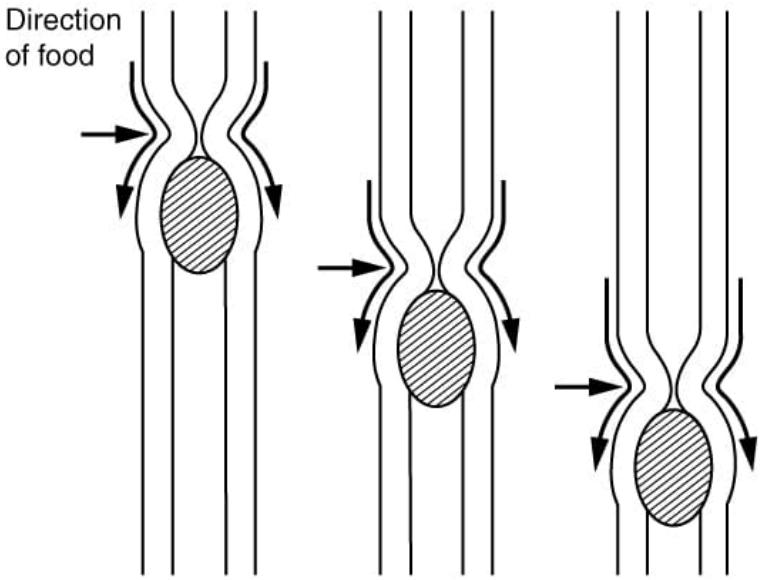

Figure 13.11. Peristalsis. Peristalsis moves food through the digestive tract with alternating waves of muscle contraction and relaxation. From Betts et al., 2013. Licensed under CC BY 4.0. [Image description.]

Digestion includes both mechanical and chemical processes. **Mechanical digestion** is a purely physical process that does not change the chemical nature of the food. Instead, it makes the food smaller to increase both surface area and mobility. It includes **mastication**, or chewing, as well as tongue movements that help break food into smaller bits and mix food with saliva. Although there may be a tendency to think that mechanical digestion is limited to the first steps of the digestive process, it occurs after the food leaves the mouth, as well. The mechanical churning of food in the stomach serves to further break it apart and expose more of its surface area to digestive juices, creating an acidic "soup" called **chyme**.

Segmentation, which occurs mainly in the small intestine, consists of localized contractions of circular muscle of the muscularis layer of the alimentary canal. These contractions isolate small sections of the intestine, moving their contents back and forth while continuously subdividing, breaking up, and mixing the contents. By moving food back and forth in the intestinal lumen, segmentation mixes food with digestive juices and facilitates absorption.

In **chemical digestion**, starting in the mouth, digestive secretions break down complex food molecules into their chemical building blocks (for example, proteins into separate amino acids). These secretions vary in composition but typically contain water, various enzymes, acids, and salts. The process is completed in the small intestine.

Food that has been broken down is of no value to the body unless it enters the bloodstream and its nutrients are put to work. This occurs through the process of **absorption**, which takes place primarily within the small intestine. There, most nutrients are absorbed from the lumen of the alimentary canal into the bloodstream through the epithelial cells that make up the mucosa. Lipids are absorbed into lacteals and are transported via the lymphatic vessels to the bloodstream.

In **defecation**, the final step in digestion, undigested materials are removed from the body as feces.

Digestive System: From Appetite Suppression to Constipation

Age-related changes in the digestive system begin in the mouth and can affect virtually every aspect of the digestive system. Taste buds become less sensitive, so food isn't as appetizing as it once was. A slice of pizza is a challenge, not a treat, when you have lost teeth, your gums are diseased, and your salivary glands aren't producing enough saliva. Swallowing can be difficult, and ingested food moves slowly through the alimentary canal because of reduced strength and tone of muscular tissue. Neurosensory feedback is also dampened, slowing the transmission of messages that stimulate the release of enzymes and hormones.

Pathologies that affect the digestive organs—such as hiatal hernia, gastritis, and peptic ulcer disease—can occur at greater frequencies as you age. Problems in the small intestine may include duodenal ulcers, maldigestion, and malabsorption. Problems in the large intestine include hemorrhoids, diverticular disease, and constipation. Conditions that affect the function of accessory organs—and their abilities to deliver pancreatic enzymes and bile to the small intestine—include jaundice, acute pancreatitis,

cirrhosis, and gallstones.

In some cases, a single organ is in charge of a digestive process. For example, ingestion occurs only in the mouth and defecation only in the anus. However, most digestive processes involve the interaction of several organs and occur gradually as food moves through the alimentary canal (see Figure 13.12). Some chemical digestion occurs in the mouth. Some absorption can occur in the mouth and stomach; for example, alcohol and aspirin.

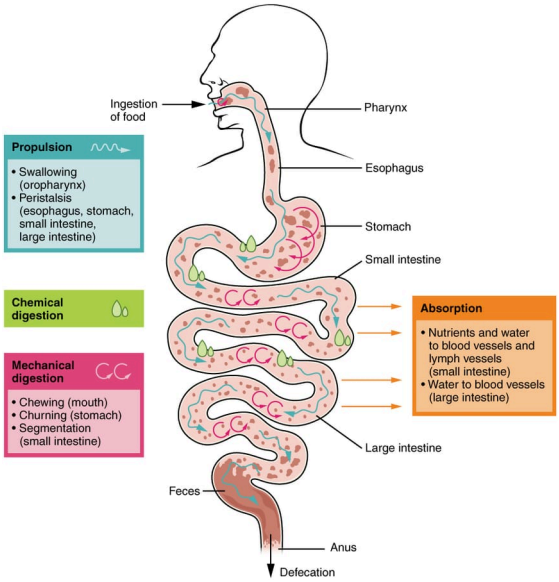

Figure 13.12. Digestive Processes. The digestive processes are ingestion, propulsion, mechanical digestion, chemical digestion, absorption, and defecation. From Betts et al., 2013. Licensed under CC BY 4.0. [Image description.]

Regulatory Mechanisms

Neural and endocrine regulatory mechanisms work to maintain the optimal conditions in the lumen needed for digestion and absorption. These regulatory mechanisms, which stimulate digestive activity through mechanical and chemical activity, are controlled both extrinsically and intrinsically.

Watch this video:

YouTube Video

This interactive element is not available in this format. Visit the link or scan the QR code to access it online.

View this YouTube Video online

Media 13.3 Digestive System, Part 3: Crash Course A&P #35. Copyright 2015 by CrashCourse.

Practice Terms Related to the Digestive System

Query 1.13.5

This interactive element is not available in this format. Visit the link or scan the QR code to access it online.

View this Interactive Content online

Common Abbreviations for the Digestive System

Many terms and phrases related to the digestive system are abbreviated. Learn these common abbreviations by expanding the list below.

Query 1.13.6

This interactive element is not available in this format. Visit the link or scan the QR code to access it online.

View this Interactive Content online

Diseases and Disorders of the Digestive System

Gastroesophageal Reflux Disease

Gastroesophageal reflux disease (GERD) is caused by stomach acid flowing upwards into the esophagus. Those suffering from the condition will often feel a burning sensation in the chest or throat (MedlinePlus, 2021a). To learn more about GERD, visit the National Institute of Diabetes and Digestive and Kidney Diseases' web page.

Cholecystitis

Cholecystitis is known as inflammation of the gallbladder. Gall stone development can block the gallbladder's release of bile, leading to an inflammatory response. Cholecystitis can be characterized as acute (the sudden onset of irritation of the gallbladder) or chronic (prolonged irritation of the gallbladder usually caused by repeated bouts of acute cholecystitis). Treatment may require a cholecystectomy (Jones, Genova, et al., 2021; Jones, Gnanapandithan, et al., 2021). To learn more, visit the Mayo Clinic's web page on cholecystitis.

Cirrhosis

Cirrhosis is a condition whereby the liver scars. Potentially fatal complications can arise, including liver failure. It generally cannot be reversed, although many of the underlying causes of cirrhosis can be treated and may help lower the likelihood of cirrhosis-related complications. Cirrhosis is caused by different forms of liver disease and chronic alcoholism (National Institute of Diabetes and Digestive and Kidney Diseases, n.d.-a).

Cirrhosis often has no signs or symptoms until liver damage is extensive and may include:

- Fatigue

- Easily bleeding or bruising
- Loss of appetite
- Nausea
- Edema
- Weight loss
- Itchy skin
- Jaundice
- Ascites (National Institute of Diabetes and Digestive and Kidney Diseases, n.d.-a)

To learn more, visit the National Institute of Diabetes and Digestive and Kidney Diseases' web page on cirrhosis.

Esophageal Cancer

Esophageal cancer begins in the innermost layer of the esophagus and spreads to the other layers. Risk factors include tobacco use, heavy alcohol use, and older age (National Cancer Institute, 2021a). To learn more, visit the Mayo Clinic's web page on esophageal cancer.

Hepatitis

Inflammation of the liver is referred to as hepatitis. It can be caused by heavy alcohol use, toxins, drugs, or as a result of an autoimmune response, but it is most often caused by a virus. Viral hepatitis is caused by one of several viruses: hepatitis A, B, C, D, or E. In the United States, 90% of hepatitis cases are caused by the A, B, and C viruses. Many cases are asymptomatic (Mehta & Reddivari, 2021).

- **Hepatitis A** is transmitted via the fecal-oral route. Infection may last for a few weeks or several months, although most individuals recover without long-term liver damage. Hepatitis A can be prevented with a vaccine.
- **Hepatitis B** is transmitted via bodily fluid, sexual transmission, contact with shared objects (such as utensils), the sharing of equipment (such as needles or medical equipment), nosocomial transmission, or childbirth. Infection may be mild or can develop into a chronic condition. Hepatitis B can be prevented with a vaccine.
- **Hepatitis C** is transmitted via bodily fluid, sexual transmission, nosocomial infection, childbirth, or blood transfusion. Although infection may be mild, most people develop a chronic condition. There is no vaccine for hepatitis C (Centers for Disease Control and Prevention, n.d.-a).
- **Hepatitis D** only occurs in people with hepatitis B. It is transmitted via bodily fluid, sexual transmission, childbirth, needle-sharing, needle stick injuries, and shared items such as toothbrushes or razors. Infection may last for a short time or may develop into a chronic condition. There is no vaccine for hepatitis D, although the hepatitis B vaccine can protect individuals from hepatitis D infection (Centers for Disease Control and Prevention, n.d.-b).
- **Hepatitis E** is transmitted most often via the fecal-oral route. In some countries, it may also be transmitted via contaminated water and undercooked or uncooked meat. In the United States, most cases are related to travel to countries where hepatitis E is prevalent. Most people with hepatitis E recover without treatment, although it can be fatal. There is no vaccine for hepatitis E approved for use in the United States (Centers for Disease Control and Prevention, n.d.-c).

For more information, visit the National Institute of Diabetes and Digestive and Kidney Diseases' web page on viral hepatitis.

Celiac Sprue (Celiac Disease)

Individuals who possess celiac disease have an immune sensitivity reaction occurring in the small intestines when they consume gluten. Typically people with this condition are genetically predisposed to the condition. Damage to the small intestine will occur if continued consumption of gluten occurs. Following a gluten-free diet generally resolves most symptoms and complications of celiac disease (National Institute of Diabetes and Digestive and Kidney Diseases, n.d.-b). For more information, visit the Mayo Clinic's web page on celiac disease.

Crohn's Disease and Ulcerative Colitis

Crohn's disease and ulcerative colitis are chronic inflammatory bowel diseases (IBD) whereby a section or segments of the digestive tract experience inflammation. Crohn's disease can occur anywhere along the digestive tract from the mouth to the anus, although it is most often found in the small intestines. This often leads to the malabsorption of nutrients from food.

Ulcerative colitis is localized inflammation and ulcers in the colon (National Institute of Diabetes and Digestive and Kidney Diseases, n.d.-c, n.d.-d). To learn more, visit the Mayo Clinic's web pages on Crohn's disease and ulcerative colitis.

Colon Cancer

Colon cancer is cancer formation in the colon portion of the digestive tract. Familial or personal history of rectal or colon cancer, heavy use of tobacco or alcohol, and older age are risk factors for colon cancer. It is often diagnosed through a colonoscopy (National Cancer Institute, 2021b). To learn more, visit the National Cancer Institute's web page on colon cancer.

Hernia

A hernia occurs when part of an organ or tissue squeezes through a weak spot in a surrounding muscle. A hernia can happen in the groin (inguinal hernia), around the belly button (umbilical hernia), through a scar (incisional hernia), through the diaphragm (hiatal hernia), or as a result of a birth defect (congenital diaphragmatic hernia) (MedlinePlus, 2021b). For more information, visit the Cleveland Clinic's web page on hernias.

Irritable Bowel Syndrome

Irritable bowel syndrome (IBS) is a common disorder affecting the large intestines. It often involves abdominal pain, bloating, and changes in bowel movements, although individuals with IBS may experience remission and flare-ups. Diet and lifestyle modifications often help in the management of the condition. (National Institute of Diabetes and Digestive and Kidney Diseases, n.d.-e). To learn more, visit the National Institute of Diabetes and Digestive and Kidney Diseases' web page on IBS.

Polyps

A polyp is a small growth of tissue protruding from the intestinal wall. Most are harmless but can transition over time into a cancerous growth. Typically, they are found in men and adults. over the age of 45 (National Institute of Diabetes and Digestive and Kidney Diseases, n.d.-f). To learn more, review the National Institute of Diabetes and Digestive and Kidney Diseases' web page on polyps.

Medical Terms in Context

Query 1.13.7

This interactive element is not available in this format. Visit the link or scan the QR code to access it online.

View this Interactive Content online

Query 1.13.8

This interactive element is not available in this format. Visit the link or scan the QR code to access it online.

View this Interactive Content online

Medical Specialties and Procedures Related to the Digestive System

Gastroenterology

Gastroenterology is a branch of internal medicine that focuses on the diagnosis and treatment of conditions afflicting the digestive system. A physician who specializes in this area is known as a gastroenterologist. (Bureau of Labor Statistics, 2021; National Cancer Institute, n.d.). To learn more about gastroenterology, visit the American College of Gastroenterology's web page.

Procedures

Upper and Lower Gastrointestinal Series

Upper and lower gastrointestinal series are procedures that involve the introduction of a contrast medium known as barium. Barium can be introduced by ingesting or by enema. After induction of the barium, x-rays are taken of the upper and lower gastrointestinal system structures (National Institute of Diabetes and Digestive and Kidney Diseases, n.d.-g, n.d.-h). To learn more, visit the National Institute of Diabetes and Digestive and Kidney Diseases' web pages on upper GI series and lower GI series.

Fecal Occult Blood Test

The fecal occult blood test is a test for hidden blood in a fecal sample. It can be performed at home and involves the patient putting a small segment of fecal output on a test card that is then mailed to their healthcare provider or a laboratory. Blood detection can be an indicator of bleeding along the digestive tract or an abnormal growth, such as colorectal cancer (MedlinePlus, 2020a).

Stool Culture

A stool culture procedure involves the collection of a small sample of feces. The sample is analyzed for abnormal bacterial growth and parasites through a culture check (MedlinePlus, 2020b).

Esophagogastroduodenoscopy

An EGD (upper endoscopy) is a procedure whereby a physician examines the upper gastrointestinal tract (esophagus, stomach, duodenum) using a special instrument called an endoscope. The physician examines the tissues and is able to take a biopsy, if needed (Ahlawat et al., 2021)

Digestive System Vocabulary

Abdominal: Pertaining to the abdomen.

Abdominoplasty: Surgical repair of the abdomen.

Ampulla: A sac-like enlargement of a canal or duct.

Anal: Pertaining to the anus.

Appendectomy: Excision of the appendix.

Appendicitis: Acute inflammation of the appendix.

Ascites: Abnormal buildup of fluid in the abdomen that may cause swelling.

Bicarbonate: A by-product of the body's metabolism.

Carbohydrates: Molecules composed of carbon, hydrogen, and oxygen. Carbohydrates are found in plant-based foods and dairy products and are an important fuel source.

Celiac: Pertaining to the abdomen.

Cholangioma: Tumor of the bile duct.

Cholangiography: Radiographic imaging of the bile duct.

Cholecystectomy: Excision of the gallbladder.

Cholecystitis: Inflammation of the gallbladder.

Choledocholithiasis: Condition of gallstones in the common bile duct.

Cholelithiasis: Condition of gallstones.

Cirrhosis: A type of chronic, progressive liver disease in which liver cells are replaced by scar tissue.

Colectomy: Excision of the colon.

Colitis: Inflammation of the colon.

Colonoscope: A thin, tube-like instrument used to examine the inside of the colon.

Colonoscopy: Examination of the inside of the colon using a colonoscope, inserted into the rectum.

Colorectal: Pertaining to the colon or rectum.

Colostomy: An opening into the colon from the outside of the body.

CT colonography: A method to examine the inside of the colon by taking a series of x-rays.

Distal: A position in a limb that is farther from the point of attachment or the trunk of the body.

Diverticulitis: Inflammation of one or more pouches or sacs that bulge out from the wall of a hollow organ, such as the colon.

Diverticulosis: A condition marked by small sacs or pouches in the walls of a hollow organ, such as the colon.

Dysentery: Acute inflammation of the intestine presenting with abdominal pain and bloody diarrhea.

Dysphagia: Difficulty swallowing.

Dyspepsia: Upset stomach.

Emesis: Vomiting.

Emulsification: The process of breaking down the fat into smaller blood cells, which makes it easy for enzymes to function and digest food.

Endoscope: A thin, tube-like instrument used to look at tissues inside the body.

Endoscopy: A procedure that uses an endoscope to examine the inside of the body.

Esophageal: Pertaining to the esophagus.

Esophagitis: Inflammation of the esophagus.

Esophagoscopy: Examination of the esophagus using an esophagoscope.

Exocrine gland: A gland whose secretions leave through a duct that opens directly, or indirectly, to the external environment.

Feces: Semisolid waste product of digestion.

Flatus: Gas in the intestine.

Fundus: The part of a hollow organ that is across from, or farthest away from, the organ's opening.

Gastrectomy: Stomach removal.

Gastric: Pertaining to the stomach.

Gastritis: Inflammation of the lining of the stomach.

Gastroenteritis: Inflammation of the lining of the stomach and the intestines.

Gastroenterologist: A doctor who has special training in diagnosing and treating disorders of the digestive system.

Gastroenterology: A subspecialty of internal medicine concerned with the study of the physiology and diseases of the digestive system and related structures.

Gastrojejunostomy: A surgical procedure that connects part of the stomach to the jejunum.

Gastroplasty: Surgical repair of the stomach.

Gastroscope: A thin, tube-like instrument used to examine the inside of the stomach.

Gastroscopy: Examination of the inside of the stomach using a gastroscope passed through the mouth and esophagus.

Gastrostomy: Creation of an artificial opening in the stomach.

Gingivectomy: Excision of the gums.

Gingivitis: Inflammation of the gums.

Glossitis: Inflammation of the tongue.

Hemorrhoid: An enlarged or swollen blood vessel, usually located near the anus or the rectum.

Hepatitis: Disease of the liver causing inflammation.

Hepatoma: Tumor of the liver.

Hepatomegaly: Enlarged liver.

Herniorrhaphy: Suturing of a hernia.

Ileostomy: A procedure in which the ileum is brought through the abdominal wall.

Labia: Lips of the mouth.

Lacteals: The lymphatic vessels of the small intestine which absorb digested fats.

Laparoscope: A thin, tube-like instrument used to look at tissues and organs inside the abdomen.

Laparoscopy: A procedure that uses a laparoscope, inserted through the abdominal wall, to examine the inside of the abdomen.

Laparotomy: A surgical incision made in the wall of the abdomen.

Lingual tonsil: Lymphoid tissue located at the base of the tongue.

Lymphoid: Referring to lymphocytes or tissue in which lymphocytes develop.

Melena: Black, tarry feces containing blood.

Nasal cavity: The inside of your nose.

Nasogastric: Describes the passage from the nose to the stomach.

Nausea: A feeling of sickness or discomfort in the stomach that may come with an urge to vomit.

Obesity: A common, chronic disease marked by an abnormally high, unhealthy amount of body fat.

Omentum: A fold of the peritoneum (the thin tissue that lines the abdomen) that surrounds the stomach and other organs in the abdomen.

Oral: By or pertaining to the mouth.

Palatine tonsils: A pair of soft tissue masses located at the rear of the throat (pharynx).

Palpation: Examination by pressing on the surface of the body to feel the organs or tissues underneath.

Pancreatic: Pertaining to the pancreas.

Pancreatitis: Inflammation of the pancreas.

Peritoneal: Having to do with the parietal peritoneum (the tissue that lines the abdominal wall and pelvic cavity) and visceral peritoneum (the tissue that covers most of the organs in the abdomen, including the intestines).

Peritonitis: Inflammation of the peritoneum.

Polyp: A growth that protrudes from a mucous membrane.

Polypectomy: Excision of polyps.

Polyposis: The development of numerous polyps.

Proctoscope: A thin, tube-like instrument used to look inside the anus and rectum.

Proctoscopy: A procedure that uses a proctoscope to look inside the anus and rectum.

Proximal: A position in a limb that is nearer to the point of attachment or the trunk of the body.

Pyloric sphincter: A band of smooth muscle at the junction between the pylorus of the stomach and the duodenum of the small intestine.

Pyloromyotomy: Incision into the pyloric muscle (used to correct pyloric stenosis).

Rectal: By or pertaining to the rectum.

Rectocele: Herniation of the rectum into the vagina.

Reflux: The backward flow of liquid from the stomach into the esophagus.

Sialolith: Stone in the salivary gland.

Sigmoidoscopy: Examination of the lower colon using a sigmoidoscope, inserted into the rectum.

Steatorrhea: Condition characterized by chronic fatty diarrhea.

Stoma: A surgically-created opening from an area inside the body to the outside.

Stomatitis: Inflammation or irritation of the mucous membranes in the mouth.

Stratified squamous epithelium: Cells arranged in layers upon a basal membrane.

Test Yourself

Query 1.13.9

This interactive element is not available in this format. Visit the link or scan the QR code to access it online.

View this Interactive Content online

References

Ahlawat, R., Hoilat, G. J., & Ross, A. B. (2021). Esophagogastroduodenoscopy. In *StatPearls [Internet]*. https://www.ncbi.nlm.nih.gov/books/NBK532268/

Bureau of Labor Statistics. (2021). Physicians and surgeons. In *Occupational outlook handbook*. U.S. Department of Labor. https://www.bls.gov/ooh/healthcare/physicians-and-surgeons.htm

Centers for Disease Control and Prevention. (n.d.-a). *What is viral hepatitis?* https://www.cdc.gov/hepatitis/abc/index.htm

Centers for Disease Control and Prevention. (n.d.-b). *Hepatitis D questions and answers for health professionals*. https://www.cdc.gov/hepatitis/hdv/hdvfaq.htm

Centers for Disease Control and Prevention. (n.d.-c). *Hepatitis E questions and answers for health professionals*. https://www.cdc.gov/hepatitis/hev/hevfaq.htm

CrashCourse. (2005, September 7). *Digestive System, Part 1: Crash Course A&P #33* [Video]. YouTube. https://www.youtube.com/watch?v=yIoTRGfcMqM

CrashCourse. (2005, September 22). Digestive System, Part 3: Crash Course A&P #35 [Video]. YouTube. https://www.youtube.com/watch?v=jGme7BRkpuQ

Jones, M. W., Genova, R., & O'Rourke, M. C. (2021). Acute cholecystitis. In *StatPearls [Internet]*. https://www.ncbi.nlm.nih.gov/books/NBK459171/

Jones, M. W., Gnanapandithan, K., Panneerselvam, D., & Ferguson, T. (2021). Chronic cholecystitis. In *StatPearls* [*Internet*]. https://www.ncbi.nlm.nih.gov/books/NBK470236/

MedlinePlus. (2021a). *Gerd*. U.S. National Library of Medicine. https://medlineplus.gov/gerd.html

MedlinePlus. (2021b). *Hernia*. U.S. National Library of Medicine. https://medlineplus.gov/hernia.html

MedlinePlus. (2020a). *Fecal occult blood test (FOBT)*. U.S. National Library of Medicine. https://medlineplus.gov/lab-tests/fecal-occult-blood-test-fobt/

MedlinePlus. (2020b). *Bacteria culture test*. U.S. National Library of Medicine. https://medlineplus.gov/lab-tests/bacteria-culture-test/

Mehta, P. & Reddivari, A. K. R. (2021). Hepatitis. In *StatPearls [Internet]*. https://www.ncbi.nlm.nih.gov/books/NBK554549/

National Cancer Institute. (n.d.). *Definition of gastroenterologist*. National Institutes of Health, U.S. Department of Health. https://www.cancer.gov/publications/dictionaries/cancer-terms/def/gastroenterologist

National Cancer Institute. (2021a). *Esophageal cancer treatment (adult) (PDQ®)–Patient Version*. National Institutes of Health, U.S. Department of Health. https://www.cancer.gov/types/esophageal/patient/esophageal-treatment-pdq

National Cancer Institute. (2021b). *Colon cancer treatment (PDDQ®)–Patient Version*. National Institutes of Health, U.S. Department of Health. https://www.cancer.gov/types/colorectal/patient/colon-treatment-pdq

National Institute of Diabetes and Digestive and Kidney Diseases. (n.d.-a). *Cirrhosis*. National Institutes of Health, U.S. Department of Health. https://www.niddk.nih.gov/health-information/liver-disease/cirrhosis/all-content

National Institute of Diabetes and Digestive and Kidney Diseases. (n.d.-b). *Celiac disease*. National Institutes of Health, U.S. Department of Health. https://www.niddk.nih.gov/health-information/digestive-diseases/celiac-disease/all-content

National Institute of Diabetes and Digestive and Kidney Diseases. (n.d.-c). *Crohn's disease*. National Institutes of Health, U.S. Department of Health. https://www.niddk.nih.gov/health-information/digestive-diseases/crohns-disease/all-content

National Institute of Diabetes and Digestive and Kidney Diseases. (n.d.-d). *Ulcerative colitis*. National Institutes of Health, U.S. Department of Health. https://www.niddk.nih.gov/health-information/digestive-diseases/ulcerative-colitis/all-content

National Institute of Diabetes and Digestive and Kidney Diseases. (n.d.-e). *Irritable bowel syndrome*. National Institutes of Health, U.S. Department of Health. https://www.niddk.nih.gov/health-information/digestive-diseases/irritable-bowel-syndrome/all-content

National Institute of Diabetes and Digestive and Kidney Diseases. (n.d.-f). *Colon polyps*. National Institutes of Health, U.S. Department of Health. https://www.niddk.nih.gov/health-information/digestive-diseases/colon-polyps/definition-facts

National Institute of Diabetes and Digestive and Kidney Diseases. (n.d.-g). *Upper GI series*. National Institutes of Health, U.S. Department of Health. https://www.niddk.nih.gov/health-information/diagnostic-tests/upper-gi-series

National Institute of Diabetes and Digestive and Kidney Diseases. (n.d.-h). *Lower GI series*. National Institutes of Health, U.S. Department of Health. https://www.niddk.nih.gov/health-information/diagnostic-tests/lower-gi-series

TED-Ed. (2014, November 25). *What does the liver do? – Emma Bryce* [Video]. YouTube. https://www.youtube.com/watch?v=wbh3SjzydnQ

Image Descriptions

Figure 13.1 image description: This diagram shows the digestive system of a human being, with the major organs labeled. Labels read (clockwise, from top): salivary glands: parotid gland, sublingual gland, submandibular gland; pharynx, stomach, spleen, pancreas, large intestine: transverse colon, ascending colon, descending colon, cecum, sigmoid colon, appendix, rectum, anal canal, anus; small intestine: duodenum, jejunum, ileum, gallbladder, liver, esophagus, tongue, mouth. [Return to Figure 13.1].

Figure 13.2 image description: This diagram shows an anterior view of the structure of the mouth. The teeth, lips, tongue, gums, and many other parts are labeled. Labels read (clockwise from top): superior lip, superior labial frenulum, gingivae, palatoglossal arch, fauces, palatopharyngeal arch, palatine tonsil, tongue, lingual frenulum, opening duct of the submandibular gland, gingivae, inferior labial frenulum, inferior lip, oral vestibule, incisors, cuspid, premolars, molars, cheek, uvula, soft palate, hard palate. [Return to Figure 13.2].

Figure 13.3 image description: This diagram shows the structures of the tongue and lingual papillae. Labels read (from top): epiglottis, palatopharyngeal arch, palatine tonsil, lingual tonsil, palatoglossal arch, terminal sulcus, foliate papillae, circumvallate papillae, dorsum of the tongue, fungiform papilla, filiform papillae. [Return to Figure 13.3].

Figure 13.4 image description: This diagram shows the esophagus, going from the mouth to the stomach. The upper and the lower esophageal sphincter are labeled. Labels read (from top): upper esophageal sphincter, trachea, esophagus, lower esophageal sphincter, stomach. [Return to Figure 13.4].

Figure 13.5 image description: This image shows a cross-section of the stomach, and the major parts: the cardia, fundus, body, and pylorus are labeled. Labels read (from top of the stomach): esophagus, muscularis externa (longitudinal layer, circular layer, oblique layer), cardia, fundus, serosa, lesser and greater curvatures, lumen, rugae of mucosa, pyloric antrum, pyloric canal, pyloric sphincter valve at the pylorus, duodenum. [Return to Figure 13.5].

Figure 13.6 image description: This diagram shows the small intestine. The different parts of the small intestine are labeled. Labels read (from top of the small intestine): duodenum, jejunum, ileum, large intestine, rectum. [Return to Figure 13.6].

Figure 13.7 image description: This image shows the large intestine; the major parts of the large intestine are labeled. Labels read (from the start of the large intestinal tract): vermiform complex, cecum, ileum, ascending colon, transverse colon, right colic hepatic flexure, left colic splenic flexure, descending colon, sigmoid colon, rectum, anal canal. [Return to Figure 13.7].

Figure 13.8 image description: This diagram shows the accessory organs of the digestive system. The liver, spleen, pancreas, gallbladder, and their major parts are shown. Labels read: liver (right lobe, quadrate lobe, left lobe, caudate lobe), spleen, pancreas, pancreatic duct, gallbladder right hepatic duct, cystic duct, common hepatic duct, common bile duct, left hepatic duct. [Return to Figure 13.8].

Figure 13.9 image description: This figure shows the pancreas and its major parts Labels read (from left to right): common bile duct, head of the pancreas, pancreatic duct, lobules, tail of the pancreas. A magnified view of a small region of the pancreas shows the pancreatic islet cells, the acinar cells, exocrine cells, and the pancreatic duct. [Return to Figure 13.9].

Figure 13.10 image description: This figure shows the gallbladder and its major parts are labeled. Labels read (starting in the gallbladder): body, fundus, neck, cystic duct, common hepatic duct, common bile duct, left and right hepatic ducts, liver. [Return to Figure 13.10].

Figure 13.11 image description: This image shows the peristaltic movement of food. In the left image, the food bolus is towards the top of the esophagus and arrows pointing downward show the direction of movement of the peristaltic wave. In the center image, the food bolus and the wave movement are closer to the center of the esophagus and in the right image, the bolus and the wave are close to the bottom end of the esophagus. [Return to Figure 13.11].

Figure 13.12 image description: This image shows the different processes involved in digestion. The image shows how food travels from the mouth through the major organs. Associated textboxes list the various digestive processes: Absorption (nutrients and water to blood vessels and lymph vessels (small intestine), water to blood vessels (large intestine)), propulsion (swallowing (oropharynx), peristalsis (esophagus, stomach, small intestine, large intestine), chemical digestion, mechanical digestion (chewing (mouth), churning (stomach), segmentation (small intestine)). Parts of the digestive tract are labeled: ingestion of food, pharynx, esophagus, stomach, small intestine, large intestine, feces, anus, defecation. [Return to Figure 13.12].

Unless otherwise indicated, this chapter contains material adapted from *Anatomy and Physiology* (on OpenStax), by Betts et al. and is used under a CC BY 4.0 international license. Download and access this book for free at https://openstax.org/books/anatomy-and-physiology/pages/1-introduction.

This page titled 1.13: Digestive System is shared under a CC BY 4.0 license and was authored, remixed, and/or curated by Andrea Nelson and Katherine Greene via source content that was edited to the style and standards of the LibreTexts platform.

1.14: Endocrine System

Learning Objectives

- Examine the anatomy of the endocrine system
- Determine the main functions of the endocrine system
- Differentiate the medical terms of the endocrine system and common abbreviations
- Recognize the medical specialties associated with the endocrine system
- Discover common diseases, disorders, and procedures related to the endocrine system

Endocrine System Word Parts

Click on prefixes, combining forms, and suffixes to reveal a list of word parts to memorize for the Endocrine System.

Query 1.14.1

This interactive element is not available in this format. Visit the link or scan the QR code to access it online.

View this Interactive Content online

Introduction to the Endocrine System



Figure 14.1 A Child Catches a Falling Leaf. Hormones of the endocrine system coordinate and control growth, metabolism, temperature regulation, the stress response, reproduction, and many other functions. (credit: "seenthroughmylense"/flickr.com). From Betts et al., 2013. Licensed under CC BY 4.0. [Image description.]

You may never have thought of it this way, but when you send a text message to two friends to meet you at the dining hall at six, you're sending digital signals that (you hope) will affect their behavior—even though they are some distance away. Similarly, certain cells send chemical signals to other cells in the body that influence their behavior. This long-distance intercellular

communication, coordination, and control are critical to maintaining equilibrium (homeostasis). This intercellular activity is the fundamental function of the endocrine system.

Watch this video:

YouTube Video

This interactive element is not available in this format. Visit the link or scan the QR code to access it online.

View this YouTube Video online

Media 14.1 Endocrine System, Part 1 – Glands & Hormones: Crash Course A&P #23 [Online video]. Copyright 2015 by CrashCourse.

Practice Medical Terms Related to the Endocrine System

Query 1.14.2

This interactive element is not available in this format. Visit the link or scan the QR code to access it online.

View this Interactive Content online

Anatomy (Structures) of the Endocrine System

The endocrine system consists of cells, tissues, and organs that secrete hormones as a primary or secondary function. The **endocrine gland** is the major player in this system. The primary function of the endocrine gland is to secrete hormones directly into the surrounding fluid. The surrounding fluid (interstitial fluid) and the blood vessels then transport the hormones throughout the body. The endocrine system includes the pituitary, thyroid, parathyroid, adrenal, and pineal glands (see Figure 14.2). Some of these glands have both endocrine and nonendocrine functions. For example, the pancreas contains cells that function in digestion as well as cells that secrete the endocrine hormones like insulin and glucagon, which regulate blood glucose levels. The hypothalamus, thymus, heart, kidneys, stomach, small intestine, liver, skin, female ovaries, and male testes are other organs that contain cells with endocrine function. Moreover, fat (adipose) tissue has long been known to produce hormones, and recent research has revealed that even bone tissue has endocrine functions.

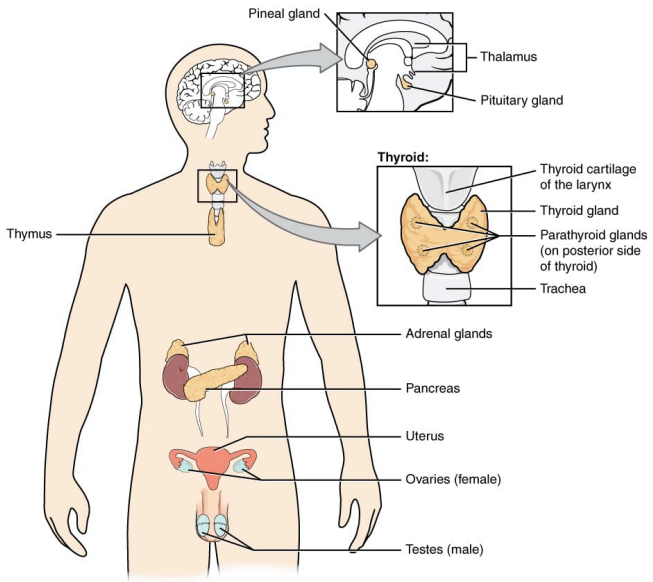

Figure 14.2 Endocrine System. Endocrine glands and cells are located throughout the body and play an important role in maintaining equilibrium (homeostasis). From Betts et al., 2013. Licensed under CC BY 4.0. [Image description.]

The ductless endocrine glands are not to be confused with the body's **exocrine system**, whose glands release their secretions through ducts. Examples of exocrine glands include the sebaceous and sweat glands of the skin. As just noted, the pancreas also has an exocrine function: most of its cells secrete pancreatic juice through the pancreatic and accessory ducts to the lumen of the small intestine.

Did you know?

The pancreas acts as an endocrine and exocrine gland.

Anatomy Labeling Activity

Query 1.14.3

This interactive element is not available in this format. Visit the link or scan the QR code to access it online.

View this Interactive Content online

Physiology (Function) of the Endocrine System

Endocrine Signaling

The **endocrine system** uses one method of communication called chemical signaling. These chemical signals are sent by the endocrine organs. The endocrine organs secrete chemicals—called **hormones**—into the fluid outside of the tissue cells (extracellular fluid). Hormones are then transported primarily via the bloodstream throughout the body, where they bind to receptors on target cells, creating a particular response. For example, when you are presented with a dangerous or a frightening situation, the fight-or-flight response prompts the release of hormones from the adrenal gland—epinephrine and

norepinephrine—within seconds. In contrast, it may take up to 48 hours for target cells to respond to certain reproductive hormones.

In addition, endocrine signaling is typically less specific than neural (nerve) signaling. The same hormone may also play a role in a variety of different physiological processes depending on the target cells involved. For example, the hormone oxytocin generates uterine contractions in women who are in labor. This hormone is also important in generating the milk release reflex during breastfeeding and may be involved in the sexual response and feelings of emotional attachment in both males and females.

Generally, the nervous system involves quick responses to rapid changes in the external environment, and the endocrine system is usually slower acting—taking care of the internal environment of the body, maintaining equilibrium (homeostasis), and controlling reproduction (see Table 14.1). So how does the fight-or-flight response, that was mentioned earlier, happen so quickly if hormones are usually slower acting? It is because the two systems are connected. It is the fast action of the nervous system in response to the danger in the environment that stimulates the adrenal glands to secrete their hormones, epinephrine, and norepinephrine. As a result, the nervous system can cause rapid endocrine responses to keep up with sudden changes in both the external and internal environments, when necessary.

Table 14.1: Endocrine and Nervous Systems. From Betts et al., 2013. Licensed under CC BY 4.0.

Characteristic	Endocrine System	Nervous System
Signaling mechanism(s)	Chemical	Chemical/electrical
Primary chemical signal	Hormones	Neurotransmitters
Distance traveled	Long or short	Always short
Response time	Fast or slow	Always fast
Environment targeted	Internal	Internal and external

Other Types of Chemical Signaling

There are four different types of chemical signaling occurring in multicellular organisms: endocrine signaling, autocrine signaling, paracrine signaling, and direct signaling.

In **endocrine signaling**, hormones secreted into the extracellular fluid spreads into the blood or lymphatic system, and can, therefore, travel great distances throughout the body.

In contrast, **autocrine signaling** occurs within the same cell. An **autocrine** (auto- = “self”) is a chemical that triggers a response in the same cell that secreted the chemical. For example, Interleukin-1 (or IL-1), is a chemical signaling molecule that plays a role in inflammation. The cells that release IL-1 also have receptors on their surface that bind IL-1, resulting in autocrine signaling.

Paracrine signaling occurs amongst neighboring cells. A **paracrine** (para- = “near”) is a chemical that triggers a response in neighboring cells. Although paracrines may enter the bloodstream, their concentration is generally too low to elicit a response from distant tissues. A familiar example for those with asthma is histamine, a paracrine that is released by immune cells. Histamine causes the smooth muscle cells of the lungs to constrict, narrowing the airways.

Direct signaling occurs between neighboring cells across gap junctions. Gap junctions are channels that connect neighboring cells, that allow small molecules to move between the neighboring cells.

Concept Check

- Describe the communication methods used by the endocrine system.
- Compare and contrast endocrine and exocrine glands.
- True or false: Neurotransmitters are a special class of paracrines? Explain your answer.

Hormones

Although a given hormone may travel throughout the body in the bloodstream, it will affect the activity only of its target cells; that is, cells with receptors for that particular hormone. Once the hormone binds to the receptor, a chain of events is initiated that leads to the target cell's response. Hormones play a critical role in the regulation of physiological processes because of the target cell responses they regulate. These responses contribute to human reproduction, growth and development of body tissues, metabolism, fluid, and electrolyte balance, sleep, and many other body functions. The major hormones of the human body and their effects are identified in Table 14.2.

Table 14.2: Endocrine Glands and Their Major Hormones. From Betts et al., 2013. Licensed under CC BY 4.0.

Endocrine Gland	Associated Hormones	Chemical Class	Effect
Pituitary (anterior)	Growth hormone (GH)	Protein	Promotes growth of body tissues
Pituitary (anterior)	Prolactin (PRL)	Peptide	Promotes milk production
Pituitary (anterior)	Thyroid-stimulating hormone (TSH)	Glycoprotein	Stimulates thyroid hormone release
Pituitary (anterior)	Adrenocorticotropic hormone (ACTH)	Peptide	Stimulates hormone released by the adrenal cortex
Pituitary (anterior)	Follicle-stimulating hormone (FSH)	Glycoprotein	Stimulates gamete production
Pituitary (anterior)	Luteinizing hormone (LH)	Glycoprotein	Stimulates androgen production by gonads
Pituitary (posterior)	Antidiuretic hormone (ADH)	Peptide	Stimulates water reabsorption by kidneys
Pituitary (posterior)	Oxytocin	Peptide	Stimulates uterine contractions during childbirth
Thyroid	Thyroxine (T_4), triiodothyronine (T_3)	Amine	Stimulate basal metabolic rate
Thyroid	Calcitonin	Peptide	Reduces blood Ca^{2+} levels
Parathyroid	Parathyroid hormone (PTH)	Peptide	Increases blood Ca^{2+} levels
Adrenal (cortex)	Aldosterone	Steroid	Increases blood Na^{+} levels
Adrenal (cortex)	Cortisol, corticosterone, cortisone	Steroid	Increase blood glucose levels
Adrenal (medulla)	Epinephrine, norepinephrine	Amine	Stimulate fight-or-flight response
Pineal	Melatonin	Amine	Regulates sleep cycles
Pancreas	Insulin	Protein	Reduces blood glucose levels
Pancreas	Glucagon	Protein	Increases blood glucose levels
Testes	Testosterone	Steroid	Stimulates development of male secondary sex characteristics and sperm production

Endocrine Gland	Associated Hormones	Chemical Class	Effect
Ovaries	Estrogens and progesterone	Steroid	Stimulate the development of female secondary sex characteristics and prepare the body for childbirth

Types of Hormones

The hormones of the human body can be divided into two major groups on the basis of their chemical structure. Hormones derived from amino acids include amines, peptides, and proteins. Those derived from lipids include steroids (see Table 14.3). These chemical groups affect a hormone's distribution, the type of receptors it binds to, and other aspects of its function.

Table 14.3 Amine, Peptide, Protein, and Steroid Hormone Structure. Adapted from Betts et al., 2013. Licensed under CC BY 4.0.

HORMONE CLASS	COMPONENTS	EXAMPLES
Amine Hormone	Amino acids with modified groups (e.g. norepinephrine's carboxyl group is replaced with a benzene ring)	Norepinephrine cellular structure.
Peptide Hormone	Short chains of linked amino acids	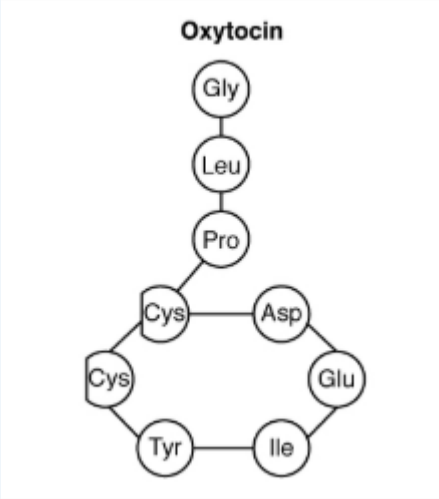 Oxytocin cellular structure.

HORMONE CLASS	COMPONENTS	EXAMPLES
Protein Hormone	Long chains of linked amino acids	Human growth hormone illustration.
Steroid Hormones	Derived from lipid cholesterol	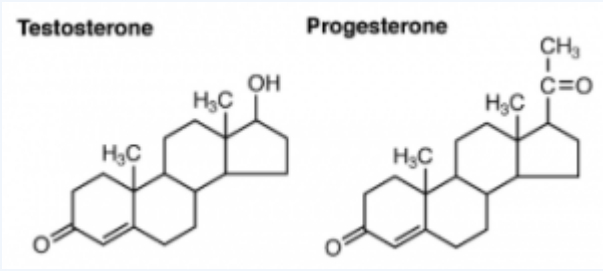 Testosterone and progesterone cellular structure.

Amine Hormones

Hormones derived from the modification of amino acids are referred to as amine hormones. Amine hormones are synthesized from the amino acids tryptophan or tyrosine. An example of a hormone derived from tryptophan is melatonin, which is secreted by the pineal gland and helps regulate circadian rhythm.

Peptide and Protein Hormones

Whereas the amine hormones are derived from a single amino acid, peptide and protein hormones consist of multiple amino acids that link to form an amino acid chain. Examples of peptide hormones include antidiuretic hormone (ADH), a pituitary hormone important in fluid balance. Some examples of protein hormones include growth hormone, which is produced by the pituitary gland, and follicle-stimulating hormone (FSH). FSH helps stimulate the maturation of eggs in the ovaries and sperm in the testes.

Steroid Hormones

The primary hormones derived from lipids are steroids. Steroid hormones are derived from lipid cholesterol. For example, the reproductive hormones testosterone and estrogens—which are produced by the gonads (testes and ovaries)—are steroid hormones. The adrenal glands produce the steroid hormone aldosterone, which is involved in osmoregulation, and cortisol, which plays a role in metabolism.

Like cholesterol, steroid hormones are not soluble in water (they are hydrophobic). Because blood is water-based, lipid-derived hormones must travel to their target cell bound to a transport protein.

Pathways of Hormone Action

The message a hormone sends is received by a **hormone receptor**, a protein located either inside the cell or within the cell

membrane. The receptor will process the message by initiating other signaling events or cellular mechanisms that result in the target cell's response. Hormone receptors recognize molecules with specific shapes and side groups and respond only to those hormones that are recognized. The same type of receptor may be located on cells in different body tissues, and trigger somewhat different responses. Thus, the response triggered by a hormone depends not only on the hormone but also on the target cell.

Once the target cell receives the hormone signal, it can respond in a variety of ways. The response may include the stimulation of protein synthesis, activation or deactivation of enzymes, alteration in the permeability of the cell membrane, altered rates of mitosis and cell growth, and stimulation of the secretion of products. Moreover, a single hormone may be capable of inducing different responses in a given cell.

Did you know?

Researchers say that one week of camping without electronics resets our biological body clock and synchronizes our melatonin hormones with sunrise and sunset (Wright et al., 2013).

Factors Affecting Target Cell Response

You will recall that target cells must have receptors specific to a given hormone if that hormone is to trigger a response, but several other factors influence the target cell response. For example, the presence of a significant level of a hormone circulating in the bloodstream can cause its target cells to decrease their number of receptors for that hormone. This process is called **downregulation**, and it allows cells to become less reactive to excessive hormone levels. When the level of a hormone is chronically reduced, target cells engage in **upregulation** to increase their number of receptors. This process allows cells to be more sensitive to the hormone that is present. Cells can also alter the sensitivity of the receptors themselves to various hormones.

Two or more hormones can interact to affect the response of cells in a variety of ways. The three most common types of interaction are as follows:

- The **permissive effect**, in which the presence of one hormone enables another hormone to act. For example, thyroid hormones have complex permissive relationships with certain reproductive hormones. A dietary deficiency of iodine, a component of thyroid hormones, can therefore affect reproductive system development and functioning.
- The **synergistic effect**, in which two hormones with similar effects produce an amplified response. In some cases, two hormones are required for an adequate response. For example, two different reproductive hormones—FSH from the pituitary gland and estrogens from the ovaries—are required for the maturation of female ova (egg cells).
- The **antagonistic effect**, in which two hormones have opposing effects. A familiar example is the effect of two pancreatic hormones, insulin and glucagon. Insulin increases the liver's storage of glucose as glycogen, decreasing blood glucose, whereas glucagon stimulates the breakdown of glycogen stores, increasing blood glucose.

Concept Check

- Describe how a hormone receptor functions and reacts to messages received.
- Contrast upregulation and downregulation. Are both of these processes necessary? Why or why not?

Regulation of Hormone Secretion

To prevent abnormal hormone levels and a potential disease state, hormone levels must be tightly controlled. The body maintains this control by balancing hormone production and degradation. Feedback loops govern the initiation and maintenance of most hormone secretion in response to various stimuli.

Role of Feedback Loops

The contribution of feedback loops to homeostasis will only be briefly reviewed here. Positive feedback loops are characterized by the release of additional hormones in response to an original hormone release. The release of oxytocin during childbirth

is a positive feedback loop. The initial release of oxytocin begins to signal the uterine muscles to contract, which pushes the fetus toward the cervix, causing it to stretch. This, in turn, signals the pituitary gland to release more oxytocin, causing labor contractions to intensify. The release of oxytocin decreases after the birth of the child.

The more common method of hormone regulation is the negative feedback loop. Negative feedback is characterized by the inhibition of further secretion of a hormone in response to adequate levels of that hormone. This allows blood levels of the hormone to be regulated within a narrow range. An example of a negative feedback loop is the release of glucocorticoid hormones from the adrenal glands, as directed by the hypothalamus and pituitary gland. As glucocorticoid concentrations in the blood rise, the hypothalamus and pituitary gland reduce their signaling to the adrenal glands to prevent additional glucocorticoid secretion (see Figure 14.3).

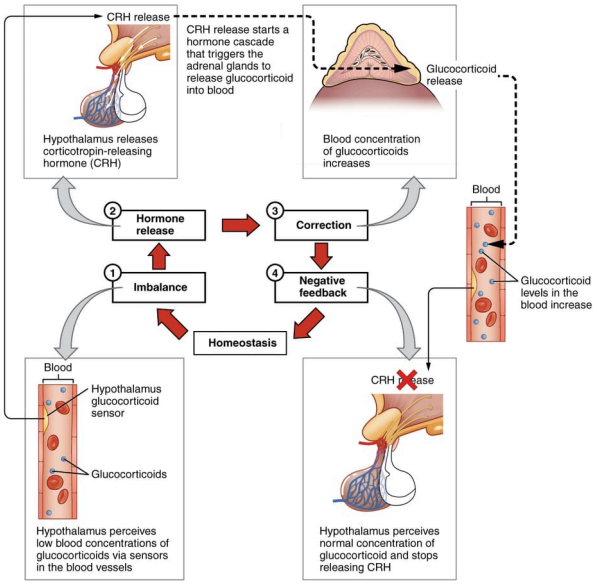

Figure 14.3 Negative Feedback Loop. The release of adrenal glucocorticoids is stimulated by the release of hormones from the hypothalamus and pituitary gland. This signaling is inhibited when glucocorticoid levels become elevated by causing negative signals to the pituitary gland and hypothalamus. From Betts et al., 2013. Licensed under CC BY 4.0. [Image description.]

Anterior Pituitary Gland

The anterior pituitary originates from the digestive tract in the embryo and migrates toward the brain during fetal development. There are three regions: the pars distalis is the most anterior, the pars intermedia is adjacent to the posterior pituitary, and the pars tuberalis is a slender “tube” that wraps the infundibulum.

Recall that the posterior pituitary does not synthesize hormones, but merely stores them. In contrast, the anterior pituitary does manufacture hormones. However, the secretion of hormones from the anterior pituitary is regulated by two classes of hormones. These hormones—secreted by the hypothalamus—are the releasing hormones that stimulate the secretion of hormones from the anterior pituitary and the inhibiting hormones that inhibit secretion.

Hypothalamic hormones are secreted by neurons but enter the anterior pituitary through blood vessels. Within the infundibulum is a bridge of capillaries that connects the hypothalamus to the anterior pituitary. This network, called the **hypophyseal portal system**, allows hypothalamic hormones to be transported to the anterior pituitary without first entering the systemic circulation. The system originates from the superior hypophyseal artery, which branches off the carotid arteries and transports blood to the hypothalamus. The branches of the superior hypophyseal artery form the hypophyseal portal system (see Figure 14.4). Hypothalamic releasing and inhibiting hormones travel through a primary capillary plexus to the portal veins, which carry them into the anterior pituitary. Hormones produced by the anterior pituitary (in response to releasing hormones) enter a secondary capillary plexus, and from there drain into the circulation.

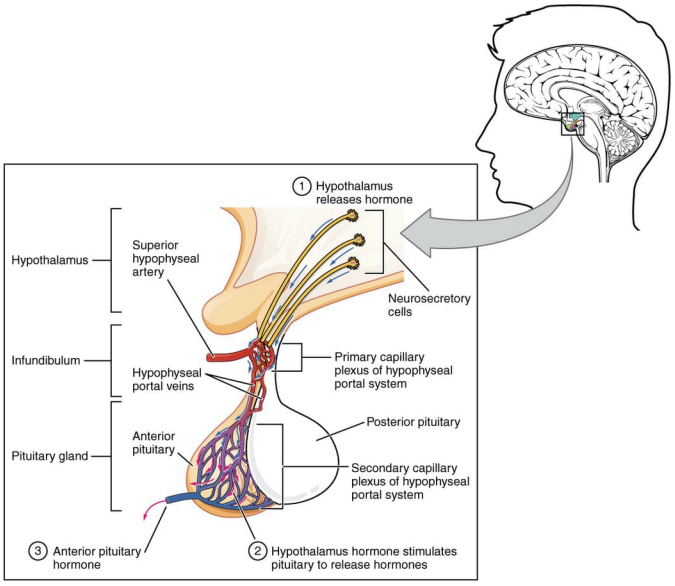

Figure 14.4 Anterior Pituitary. The anterior pituitary manufactures seven hormones. The hypothalamus produces separate hormones that stimulate or inhibit hormone production in the anterior pituitary. Hormones from the hypothalamus reach the anterior pituitary via the hypophyseal portal system. From Betts et al., 2013. Licensed under CC BY 4.0. [Image description.]

The anterior pituitary produces seven hormones. These are the growth hormone (GH), thyroid-stimulating hormone (TSH), adrenocorticotropic hormone (ACTH), follicle-stimulating hormone (FSH), luteinizing hormone (LH), beta-endorphin, and prolactin. Of the hormones of the anterior pituitary, TSH, ACTH, FSH, and LH are collectively referred to as tropic hormones (trope- = “turning”) because they turn on or off the function of other endocrine glands.

Growth Hormone

The endocrine system regulates the growth of the human body, protein synthesis, and cellular replication. A major hormone involved in this process is **growth hormone (GH)**, also called somatotropin—a protein hormone produced and secreted by the anterior pituitary gland. Its primary function is anabolic; it promotes protein synthesis and tissue building through direct and indirect mechanisms (see Figure 14.5). GH levels are controlled by the release of GHRH and GHIH (also known as somatostatin) from the hypothalamus.

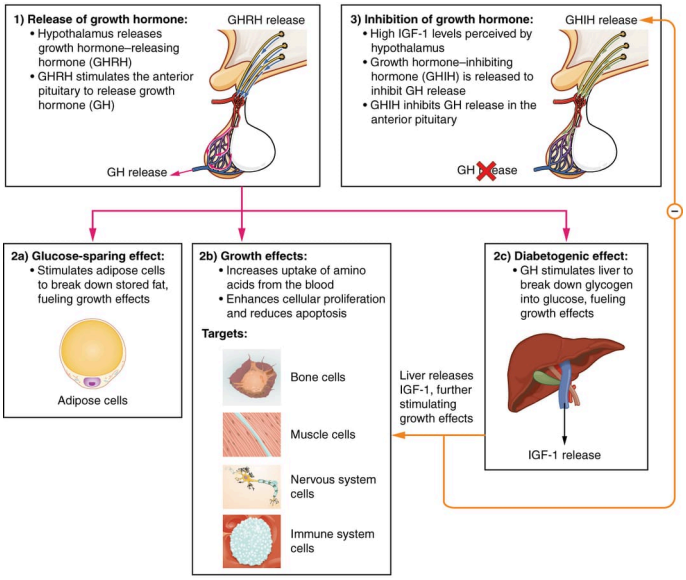

Figure 14.5 Hormonal Regulation of Growth. Growth hormone (GH) directly accelerates the rate of protein synthesis in skeletal muscle and bones. Insulin-like growth factor 1 (IGF-1) is activated by growth hormone and indirectly supports the formation of new proteins in muscle cells and bone. From Betts et al., 2013. Licensed under CC BY 4.0. [Image description.]

A glucose-sparing effect occurs when GH stimulates lipolysis, or the breakdown of adipose tissue, releasing fatty acids into the blood. As a result, many tissues switch from glucose to fatty acids as their main energy source, which means that less glucose is taken up from the bloodstream.

GH also initiates the diabetogenic effect in which GH stimulates the liver to break down glycogen to glucose, which is then deposited into the blood. The name “diabetogenic” is derived from the similarity in elevated blood glucose levels observed between individuals with untreated diabetes mellitus and individuals experiencing GH excess. Blood glucose levels rise as the result of a combination of glucose-sparing and diabetogenic effects.

GH indirectly mediates growth and protein synthesis by triggering the liver and other tissues to produce a group of proteins called **insulin-like growth factors (IGFs)**. These proteins enhance cellular proliferation and inhibit apoptosis, or programmed cell death. IGFs stimulate cells to increase their uptake of amino acids from the blood for protein synthesis. Skeletal muscle and cartilage cells are particularly sensitive to stimulation from IGFs.

Dysfunction of the endocrine system’s control of growth can result in several disorders. For example, **gigantism** is a disorder in children that is caused by the secretion of abnormally large amounts of GH, resulting in excessive growth. A similar condition in adults is **acromegaly**, a disorder that results in the growth of bones in the face, hands, and feet in response to excessive levels of GH in individuals who have stopped growing. Abnormally low levels of GH in children can cause growth impairment—a disorder called **pituitary dwarfism** (also known as growth hormone deficiency).

Posterior Pituitary Gland

The posterior pituitary is actually an extension of the neurons of the nuclei of the hypothalamus. The cell bodies of these regions rest in the hypothalamus, but their axons descend as the hypothalamic–hypophyseal tract within the infundibulum and end in axon terminals that comprise the posterior pituitary (see Figure 14.6).

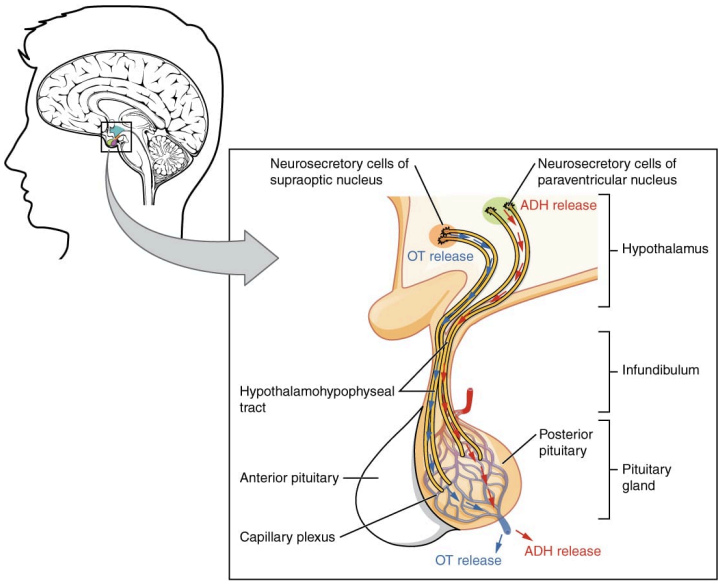

Figure 14.6 Posterior Pituitary. Neurosecretory cells in the hypothalamus release oxytocin (OT) or ADH into the posterior lobe of the pituitary gland. These hormones are stored or released into the blood via the capillary plexus. From Betts et al., 2013. Licensed under CC BY 4.0. [Image description.]

The posterior pituitary gland does not produce hormones, but rather stores and secretes hormones produced by the hypothalamus. The paraventricular nuclei produce the hormone oxytocin, whereas the supraoptic nuclei produce ADH. These hormones travel along the axons into storage sites in the axon terminals of the posterior pituitary. In response to signals from the same hypothalamic neurons, the hormones are released from the axon terminals into the bloodstream.

Oxytocin

When fetal development is complete, the peptide-derived hormone **oxytocin** (tocia- = “childbirth”) stimulates uterine contractions and dilation of the cervix. Throughout most of pregnancy, oxytocin hormone receptors are not expressed at high levels in the uterus. Toward the end of pregnancy, the synthesis of oxytocin receptors in the uterus increases, and the smooth muscle cells of the uterus become more sensitive to its effects. Oxytocin is continually released throughout childbirth through a positive feedback mechanism. As noted earlier, oxytocin prompts the uterine contractions that push the fetal head toward the cervix. In response, cervical stretching stimulates additional oxytocin to be synthesized by the hypothalamus and released from the pituitary. This increases the intensity and effectiveness of uterine contractions and prompts additional dilation of the cervix. The feedback loop continues until birth.

Although the mother’s high blood levels of oxytocin begin to decrease immediately following birth, oxytocin continues to play a role in maternal and newborn health. First, oxytocin is necessary for the milk ejection reflex (commonly referred to as “let-down”) in breastfeeding women. As the newborn begins suckling, sensory receptors in the nipples transmit signals to the hypothalamus. In response, oxytocin is secreted and released into the bloodstream. Within seconds, cells in the mother’s milk ducts contract, ejecting milk into the infant’s mouth. Secondly, in both males and females, oxytocin is thought to contribute to parent–newborn bonding, known as attachment. Oxytocin is also thought to be involved in feelings of love and closeness, as well as in the sexual response.

Did you know?

Oxytocin is used not only during childbirth but also during breastfeeding.

Antidiuretic Hormone (ADH)

The solute concentration of the blood, or blood osmolarity, may change in response to the consumption of certain foods and fluids, as well as in response to disease, injury, medications, or other factors. Blood osmolarity is constantly monitored by

osmoreceptors—specialized cells within the hypothalamus that are particularly sensitive to the concentration of sodium ions and other solutes. In response to high blood osmolarity, which can occur during dehydration or following a very salty meal, the osmoreceptors signal the posterior pituitary to release **antidiuretic hormone (ADH)**. The target cells of ADH are located in the tubular cells of the kidneys. Its effect is to increase epithelial permeability to water, allowing increased water reabsorption. The more water reabsorbed from the filtrate, the greater the amount of water that is returned to the blood and the less that is excreted in the urine. A greater concentration of water results in a reduced concentration of solutes. ADH is also known as vasopressin because, in very high concentrations, it causes constriction of blood vessels, which increases blood pressure by increasing peripheral resistance.

The release of ADH is controlled by a negative feedback loop. As blood osmolarity decreases, the hypothalamic osmoreceptors sense the change and prompt a corresponding decrease in the secretion of ADH. As a result, less water is reabsorbed from the urine filtrate. Interestingly, drugs can affect the secretion of ADH. For example, alcohol consumption inhibits the release of ADH, resulting in increased urine production that can eventually lead to dehydration and a hangover. A disease called diabetes insipidus is characterized by chronic underproduction of ADH that causes chronic dehydration. Because little ADH is produced and secreted, not enough water is reabsorbed by the kidneys. Although patients feel thirsty and increase their fluid consumption, this doesn't effectively decrease the solute concentration in their blood because ADH levels are not high enough to trigger water reabsorption in the kidneys. Electrolyte imbalances can occur in severe cases of diabetes insipidus.

Thyroid-Stimulating Hormone

The activity of the thyroid gland is regulated by **thyroid-stimulating hormone (TSH)**, also called thyrotropin. TSH is released from the anterior pituitary in response to thyrotropin-releasing hormone (TRH) from the hypothalamus. As discussed shortly, it triggers the secretion of thyroid hormones by the thyroid gland. In a classic negative feedback loop, elevated levels of thyroid hormones in the bloodstream then trigger a drop in production of TRH and subsequently TSH.

Adrenocorticotropic Hormone

The **adrenocorticotropic hormone (ACTH)**, also called corticotropin, stimulates the adrenal cortex (the more superficial "bark" of the adrenal glands) to secrete corticosteroid hormones such as cortisol. ACTH comes from a precursor molecule known as proopiomelanocortin (POMC) which produces several biologically active molecules when cleaved, including ACTH, melanocyte-stimulating hormone, and the brain opioid peptides known as endorphins. The release of ACTH is regulated by the corticotropin-releasing hormone (CRH) from the hypothalamus in response to normal physiologic rhythms. A variety of stressors can also influence its release, and the role of ACTH in the stress response is discussed later in this chapter.

Follicle-Stimulating Hormone and Luteinizing Hormone

The endocrine glands secrete a variety of hormones that control the development and regulation of the reproductive system (these glands include the anterior pituitary, the adrenal cortex, and the gonads—the testes in males and the ovaries in females). Much of the development of the reproductive system occurs during puberty and is marked by the development of sex-specific characteristics in both male and female adolescents. Puberty is initiated by gonadotropin-releasing hormone (GnRH), a hormone produced and secreted by the hypothalamus. GnRH stimulates the anterior pituitary to secrete **gonadotropins**—hormones that regulate the function of the gonads. The levels of GnRH are regulated through a negative feedback loop; high levels of reproductive hormones inhibit the release of GnRH. Throughout life, gonadotropins regulate reproductive function and, in the case of women, the onset and cessation of reproductive capacity.

The gonadotropins include two glycoprotein hormones: **follicle-stimulating hormone (FSH)** stimulates the production and maturation of sex cells, or gametes, including ova in women and sperm in men. FSH also promotes follicular growth; these follicles then release estrogens in the female ovaries. **Luteinizing hormone (LH)** triggers ovulation in women, as well as the production of estrogens and progesterone by the ovaries. LH stimulates production of testosterone by the male testes.

Prolactin

As its name implies, **prolactin (PRL)** promotes lactation (milk production) in women. During pregnancy, it contributes to the development of the mammary glands, and after birth, it stimulates the mammary glands to produce breast milk. However, the effects of prolactin depend heavily upon the permissive effects of estrogens, progesterone, and other hormones. And as noted earlier, the let-down of milk occurs in response to stimulation from oxytocin.

In a non-pregnant woman, prolactin secretion is inhibited by prolactin-inhibiting hormone (PIH), which is actually the neurotransmitter dopamine, and is released from neurons in the hypothalamus. Only during pregnancy do prolactin levels rise in response to prolactin-releasing hormone (PRH) from the hypothalamus.

Intermediate Pituitary: Melanocyte-Stimulating Hormone

The cells in the zone between the pituitary lobes secrete a hormone known as melanocyte-stimulating hormone (MSH) that is formed by cleavage of the proopiomelanocortin (POMC) precursor protein. Local production of MSH in the skin is responsible for melanin production in response to UV light exposure. The role of MSH made by the pituitary is more complicated. For instance, people with lighter skin generally have the same amount of MSH as people with darker skin. Nevertheless, this hormone is capable of darkening the skin by inducing melanin production in the skin's melanocytes. Women also show increased MSH production during pregnancy; in combination with estrogens, it can lead to darker skin pigmentation, especially the skin of the areolas and labia minora. Table 14.4 is a summary of the pituitary hormones and their principal effects.

Table 14.4 Major Pituitary Hormones. Major pituitary hormones and their target organs. Adapted from Betts et al., 2013. Licensed under CC BY 4.0.

IMAGE OF GLANDS	HORMONES			
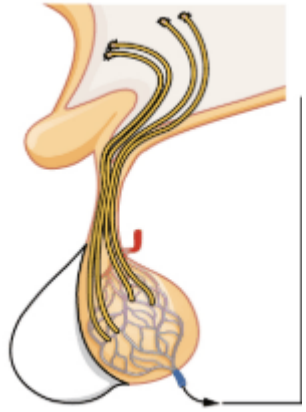 An image displaying the posterior pituitary gland	**Posterior Pituitary Hormones**			
	Releasing hormone (hypothalamus)	**Pituitary Hormone**	**Target**	**Effects**
	ADH	Stores ADH	Kidneys, sweat glands, circulatory system	Water balance
	–	OT	Female reproductive system	Triggers uterine contractions during childbirth
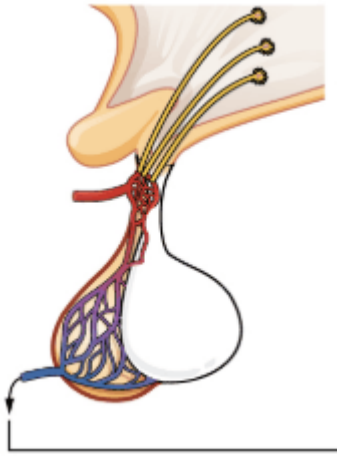 An image displaying the Anterior Pituitary Gland	**Anterior Pituitary Hormones**			
	Releasing hormone (hypothalamus)	**Pituitary Hormone**	**Target**	**Effects**
	GnRH	LH	Reproductive system	Stimulates production of sex hormones by gonads
	GnRH	FSH	Reproductive system	Stimulates production of sperm and eggs
	TRH	TSH	Thyroid gland	Stimulates the release of thyroid hormone (TH), TH regulates metabolism
	PRH (inhibited by PIH)	PRL	Mammary glands	Promotes milk production
	GHRH (inhibited by GHIH)	GH	Liver, bone, muscles	Induces targets to produce insulin-like growth factors (IGF). IGFs stimulate body growth and higher metabolic rate.
	CRH	ACTH	Adrenal glands	Induces targets to produce glucocorticoids, which regulate metabolism and stress response

Pineal Gland

The pineal gland is a tiny endocrine gland whose functions are not entirely clear. The **pinealocyte** cells that make up the pineal gland are known to produce and secrete the amine hormone **melatonin**, which is derived from serotonin. The secretion of melatonin varies according to the level of light received from the environment. When photons of light stimulate the retinas of the eyes, a nerve impulse is sent to a region of the hypothalamus which is important in regulating biological rhythms. When blood levels of melatonin fall they promote wakefulness. In contrast, as light levels decline—such as during the evening—melatonin production increases, boosting blood levels and causing drowsiness.

Melatonin

The secretion of melatonin may influence the body's circadian rhythms, the dark-light fluctuations that affect not only sleepiness and wakefulness but also appetite and body temperature. Interestingly, children have higher melatonin levels than adults, which may prevent the release of gonadotropins from the anterior pituitary, thereby inhibiting the onset of puberty. Finally, the antioxidant role of melatonin is the subject of current research. Jet lag occurs when a person travels across several time zones and feels sleepy during the day or wakeful at night. Traveling across multiple time zones significantly disturbs the light-dark cycle regulated by melatonin. It can take up to several days for melatonin synthesis to adjust to the light-dark patterns in the new environment, resulting in jet lag. Some air travelers take melatonin supplements to induce sleep.

Thyroid Gland

A butterfly-shaped organ, the **thyroid gland** is located anterior to the trachea, just inferior to the larynx (see Figure 14.7). The medial region, called the isthmus, is flanked by wing-shaped left and right lobes. Each of the thyroid lobes is embedded with parathyroid glands, primarily on their posterior surfaces. The tissue of the thyroid gland is composed mostly of thyroid follicles. The follicles are made up of a central cavity filled with a sticky fluid called **colloid**. Surrounded by a wall of epithelial follicle cells, the colloid is the center of thyroid hormone production, and that production is dependent on the hormones' essential and unique component: iodine.

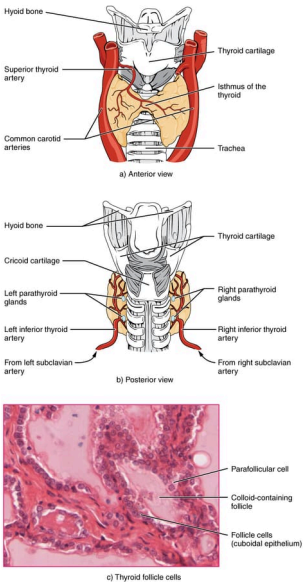

Figure 14.7 Thyroid Gland. The thyroid gland is located in the neck where it wraps around the trachea. (a) Anterior view of the thyroid gland. (b) Posterior view of the thyroid gland. (c) The glandular tissue is composed primarily of thyroid follicles. The larger parafollicular cells often appear within the matrix of follicle cells. LM × 1332. (Micrograph provided by the Regents of University of Michigan Medical School © 2012). From Betts et al., 2013. Licensed under CC BY 4.0. [Image description.]

Regulation of TH Synthesis

The release of T_3 and T_4 from the thyroid gland is regulated by thyroid-stimulating hormone (TSH). Low blood levels of T_3 and T_4 stimulate the release of thyrotropin-releasing hormone (TRH) from the hypothalamus, which triggers the secretion of TSH from

the anterior pituitary. In turn, TSH stimulates the thyroid gland to secrete T_3 and T_4. The levels of TRH, TSH, T_3, and T_4 are regulated by a negative feedback system in which increasing levels of T_3 and T_4 decrease the production and secretion of TSH. The thyroid hormones, T_3 and T_4, are often referred to as metabolic hormones because their levels influence the body's basal metabolic rate, the amount of energy used by the body at rest.

The thyroid gland also secretes a hormone called **calcitonin** that is produced by the parafollicular cells (also called C cells) that stud the tissue between distinct follicles. Calcitonin is released in response to a rise in blood calcium levels.

Parathyroid Gland

The **parathyroid glands** are tiny, round structures usually found embedded in the posterior surface of the thyroid gland. A thick connective tissue capsule separates the glands from the thyroid tissue. Most people have four parathyroid glands, but occasionally there are more in tissues of the neck or chest. The function of one type of parathyroid cells, the oxyphil cells, is not clear. The primary functional cells of the parathyroid glands are the chief cells. These epithelial cells produce and secrete the **parathyroid hormone (PTH)**, the major hormone involved in the regulation of blood calcium levels.

Adrenal Gland

The **adrenal glands** are wedges of glandular and neuroendocrine tissue adhering to the top of the kidneys by a fibrous capsule (see Figure 14.8). The adrenal glands have a rich blood supply and experience one of the highest rates of blood flow in the body. They are served by several arteries branching off the aorta, including the suprarenal and renal arteries. Blood flows to each adrenal gland at the adrenal cortex and then drains into the adrenal medulla. Adrenal hormones are released into the circulation via the left and right suprarenal veins.

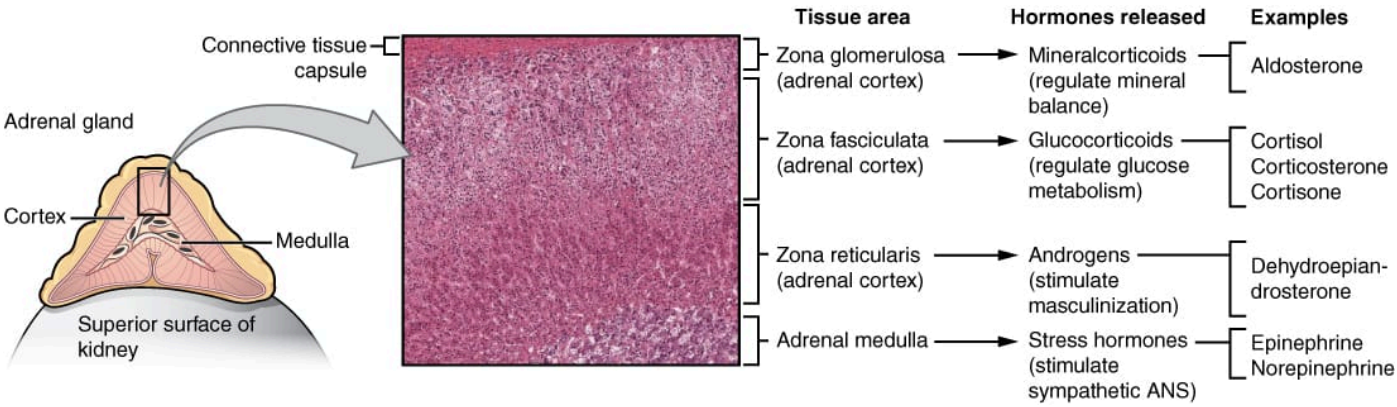

Figure 14.8 Adrenal Glands. Both adrenal glands sit atop the kidneys and are composed of an outer cortex and an inner medulla, all surrounded by a connective tissue capsule. The cortex can be subdivided into additional zones, all of which produce different types of hormones. LM × 204. (Micrograph provided by the Regents of University of Michigan Medical School © 2012). From Betts et al., 2013. Licensed under CC BY 4.0. [Image description.]

The **adrenal cortex** consists of multiple layers of lipid-storing cells that occur in three structurally distinct regions, each of which produces different hormones. As a component of the hypothalamic-pituitary-adrenal (HPA) axis, it secretes steroid hormones important for the regulation of the long-term stress response, blood pressure and blood volume, nutrient uptake and storage, fluid and electrolyte balance, and inflammation. The HPA axis involves the stimulation of hormone release of adrenocorticotropic hormone (ACTH) from the pituitary by the hypothalamus. ACTH then stimulates the adrenal cortex to produce the hormone cortisol. This pathway will be discussed in more detail below.

The **adrenal medulla** is neuroendocrine tissue composed of postganglionic sympathetic nervous system (SNS) neurons. It is really an extension of the autonomic nervous system, which regulates homeostasis in the body. The sympathomedullary (SAM) pathway involves the stimulation of the medulla by impulses from the hypothalamus via neurons from the thoracic spinal cord. The medulla is stimulated to secrete the amine hormones epinephrine and norepinephrine.

One of the major functions of the adrenal gland is to respond to stress. Stress can be either physical or psychological or both. Physical stresses include exposing the body to injury, walking outside in cold and wet conditions without a coat on, or malnutrition. Psychological stresses include the perception of a physical threat, a fight with a loved one, or just a bad day at school.

The body responds in different ways to short-term stress and long-term stress following a pattern known as the **general adaptation syndrome (GAS)**. Stage one of GAS is called the **alarm reaction**. This is short-term stress, the fight-or-flight response, mediated by the hormones epinephrine and norepinephrine from the adrenal medulla via the SAM pathway. Their function is to prepare the body for extreme physical exertion. Once this stress is relieved, the body quickly returns to normal. The section on the adrenal medulla covers this response in more detail.

If the stress is not soon relieved, the body adapts to the stress in the second stage called the **stage of resistance**. If a person is starving, for example, the body may send signals to the gastrointestinal tract to maximize the absorption of nutrients from food.

If the stress continues for a longer term, however, the body responds with symptoms quite different than the fight-or-flight response. During the **stage of exhaustion**, individuals may begin to suffer depression, the suppression of their immune response, severe fatigue, or even a fatal heart attack. These symptoms are mediated by the hormones of the adrenal cortex, especially cortisol, released as a result of signals from the HPA axis.

Adrenal hormones also have several non–stress-related functions, including the increase of blood sodium and glucose levels, which will be described in detail below.

Watch this video:

YouTube Video

This interactive element is not available in this format. Visit the link or scan the QR code to access it online.

View this YouTube Video online

Media 14.2 Endocrine System, Part 2 – Hormone Cascades: Crash Course A&P #24 [Online video]. Copyright 2015 by CrashCourse.

Practice Terms Related to the Endocrine System

Query 1.14.4

This interactive element is not available in this format. Visit the link or scan the QR code to access it online.

View this Interactive Content online

Concept Check

Which hormone produced by the adrenal glands is responsible for the mobilization of energy stores?

Hormones of the Zona Glomerulosa

The most superficial region of the adrenal cortex is the zona glomerulosa, which produces a group of hormones collectively referred to as **mineralocorticoids** because of their effect on body minerals, especially sodium and potassium. These hormones are essential for fluid and electrolyte balance.

Aldosterone is the major mineralocorticoid. It is important in the regulation of the concentration of sodium and potassium ions in urine, sweat, and saliva. For example, it is released in response to elevated blood K^+, low blood Na^+, low blood pressure, or low blood volume. In response, aldosterone increases the excretion of K^+ and the retention of Na^+, which in turn increases blood volume and blood pressure. Its secretion is prompted when CRH from the hypothalamus triggers ACTH release from the anterior pituitary.

Aldosterone is also a key component of the renin-angiotensin-aldosterone system (RAAS) in which specialized cells of the kidneys secrete the enzyme renin in response to low blood volume or low blood pressure. Renin then catalyzes the conversion of the blood protein angiotensinogen, produced by the liver, to the hormone angiotensin I. Angiotensin I is converted in the lungs to angiotensin II by **angiotensin-converting enzyme** (ACE). Angiotensin II has three major functions:

1. Initiating vasoconstriction of the arterioles, decreasing blood flow
2. Stimulating kidney tubules to reabsorb NaCl and water, increasing blood volume
3. Signaling the adrenal cortex to secrete aldosterone, the effects of which further contribute to fluid retention, restoring blood pressure and blood volume

For individuals with hypertension, or high blood pressure, drugs are available that block the production of angiotensin II. These drugs, known as ACE inhibitors, block the ACE enzyme from converting angiotensin I to angiotensin II, thus mitigating the latter's ability to increase blood pressure.

Hormones of the Zona Fasciculata

The intermediate region of the adrenal cortex is the zona fasciculata, named as such because the cells form small fascicles (bundles) separated by tiny blood vessels. The cells of the zona fasciculata produce hormones called **glucocorticoids** because of their role in glucose metabolism. The most important of these is **cortisol**, some of which the liver converts to cortisone. A glucocorticoid produced in much smaller amounts is corticosterone. In response to long-term stressors, the hypothalamus secretes CRH, which in turn triggers the release of ACTH by the anterior pituitary. ACTH triggers the release of glucocorticoids. Their overall effect is to inhibit tissue building while stimulating the breakdown of stored nutrients to maintain adequate fuel supplies. In conditions of long-term stress, for example, cortisol promotes the catabolism of glycogen to glucose, the catabolism of stored triglycerides into fatty acids and glycerol, and the catabolism of muscle proteins into amino acids. These raw materials can then be used to synthesize additional glucose and ketones for use as body fuels. The hippocampus, which is part of the temporal lobe of the cerebral cortices and important in memory formation, is highly sensitive to stress levels because of its many glucocorticoid receptors.

You are probably familiar with prescription and over-the-counter medications containing glucocorticoids, such as cortisone injections into inflamed joints, prednisone tablets, and steroid-based inhalers used to manage severe asthma, and hydrocortisone creams applied to relieve itchy skin rashes. These drugs reflect another role of cortisol—the downregulation of the immune system, which inhibits the inflammatory response.

Hormones of the Zona Reticularis

The deepest region of the adrenal cortex is the zona reticularis, which produces small amounts of a class of steroid sex hormones called androgens. During puberty and most of adulthood, androgens are produced in the gonads. The androgens produced in the zona reticularis supplement the gonadal androgens. They are produced in response to ACTH from the anterior pituitary and are converted in the tissues to testosterone or estrogens. In adult women, they may contribute to the sex drive, but their function in adult men is not well understood. In post-menopausal women, as the functions of the ovaries decline, the main source of estrogens becomes the androgens produced by the zona reticularis.

Adrenal Medulla

As noted earlier, the adrenal cortex releases glucocorticoids in response to long-term stress such as severe illness. In contrast, the adrenal medulla releases its hormones in response to acute, short-term stress mediated by the sympathetic nervous system (SNS).

The medullary tissue is composed of unique postganglionic SNS neurons called **chromaffin** cells, which are large and irregularly shaped, and produce the neurotransmitters **epinephrine** (also called adrenaline) and **norepinephrine** (or noradrenaline). Epinephrine is produced in greater quantities—approximately a 4 to 1 ratio with norepinephrine—and is the more powerful

hormone. Because the chromaffin cells release epinephrine and norepinephrine into the systemic circulation, where they travel widely and exert effects on distant cells, they are considered hormones. Derived from the amino acid tyrosine, they are chemically classified as catecholamines.

The secretion of medullary epinephrine and norepinephrine is controlled by a neural pathway that originates from the hypothalamus in response to danger or stress (the SAM pathway). Both epinephrine and norepinephrine signal the liver and skeletal muscle cells to convert glycogen into glucose, resulting in increased blood glucose levels. These hormones increase the heart rate, pulse, and blood pressure to prepare the body to fight the perceived threat or flee from it. In addition, the pathway dilates the airways, raising blood oxygen levels. It also prompts vasodilation, further increasing the oxygenation of important organs such as the lungs, brain, heart, and skeletal muscle. At the same time, it triggers vasoconstriction to blood vessels serving less essential organs such as the gastrointestinal tract, kidneys, and skin, and downregulates some components of the immune system. Other effects include a dry mouth, loss of appetite, pupil dilation, and a loss of peripheral vision.

Pancreas

The **pancreas** is a long, slender organ, most of which is located posterior to the bottom half of the stomach (see Figure 14.9). Although it is primarily an exocrine gland, secreting a variety of digestive enzymes, the pancreas has an endocrine function. Its **pancreatic islets**—clusters of cells formerly known as the islets of Langerhans—secrete the hormones glucagon, insulin, somatostatin, and pancreatic polypeptide (PP).

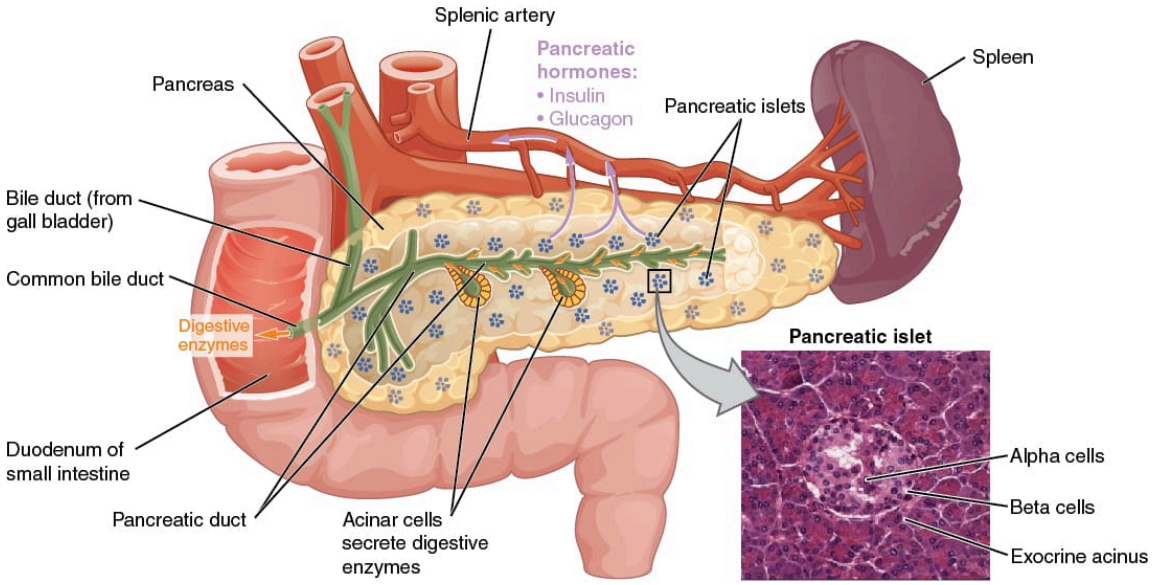

Figure 14.9 Pancreas. The pancreatic exocrine function involves the acinar cells secreting digestive enzymes that are transported into the small intestine by the pancreatic duct. Its endocrine function involves the secretion of insulin (produced by beta cells) and glucagon (produced by alpha cells) within the pancreatic islets. These two hormones regulate the rate of glucose metabolism in the body. The micrograph reveals pancreatic islets. LM × 760. (Micrograph provided by the Regents of University of Michigan Medical School © 2012). From Betts et al., 2013. Licensed under CC BY 4.0. [Image description.]

Cells and Secretions of the Pancreatic Islets

The pancreatic islets each contain four varieties of cells:

- The alpha cell produces the hormone glucagon and makes up approximately 20% of each islet. Glucagon plays an important role in blood glucose regulation; low blood glucose levels stimulate its release.
- The beta cell produces the hormone insulin and makes up approximately 75% of each islet. Elevated blood glucose levels stimulate the release of insulin.
- The delta cell accounts for 4% of the islet cells and secretes the peptide hormone somatostatin. Recall that somatostatin is also released by the hypothalamus (as GHIH), and the stomach and intestines also secrete it. An inhibiting hormone, pancreatic somatostatin inhibits the release of both glucagon and insulin.
- The PP cell accounts for about 1% of islet cells and secretes the pancreatic polypeptide hormone. It is thought to play a role

in appetite, as well as in the regulation of pancreatic exocrine and endocrine secretions. Pancreatic polypeptide released following a meal may reduce further food consumption; however, it is also released in response to fasting.

Regulation of Blood Glucose Levels by Insulin and Glucagon

Glucose is required for cellular respiration and is the preferred fuel for all body cells. The body derives glucose from the breakdown of the carbohydrate-containing foods and drinks we consume. Glucose not immediately taken up by cells for fuel can be stored by the liver and muscles as glycogen, or converted to triglycerides and stored in the adipose tissue. Hormones regulate both the storage and the utilization of glucose as required. Receptors located in the pancreas sense blood glucose levels, and subsequently the pancreatic cells secrete glucagon or insulin to maintain normal levels.

Gonadal Glands

The male testes and female ovaries—which produce the sex cells (sperm and ova) and secrete the gonadal hormones. The roles of the gonadotropins released from the anterior pituitary (FSH and LH) were discussed earlier.

The primary hormone produced by the male testes is **testosterone**, a steroid hormone important in the development of the male reproductive system, the maturation of sperm cells, and the development of male secondary sex characteristics such as a deepened voice, body hair, and increased muscle mass. Interestingly, testosterone is also produced in the female ovaries but at a much reduced level. In addition, the testes produce the peptide hormone **inhibin**, which inhibits the secretion of FSH from the anterior pituitary gland. FSH stimulates spermatogenesis.

The primary hormones produced by the ovaries are **estrogens**, which include estradiol, estriol, and estrone. Estrogens play an important role in a larger number of physiological processes, including the development of the female reproductive system, regulation of the menstrual cycle, the development of female secondary sex characteristics such as increased adipose tissue, and the development of breast tissue, and the maintenance of pregnancy. Another significant ovarian hormone is **progesterone**, which contributes to regulation of the menstrual cycle and is important in preparing the body for pregnancy as well as maintaining pregnancy. In addition, the granulosa cells of the ovarian follicles produce inhibin, which—as in males—inhibits the secretion of FSH. During the initial stages of pregnancy, an organ called the placenta develops within the uterus. The placenta supplies oxygen and nutrients to the fetus, excretes waste products, and produces and secretes estrogens and progesterone. The placenta produces human chorionic gonadotropin (hCG) as well. The hCG hormone promotes progesterone synthesis and reduces the mother's immune function to protect the fetus from immune rejection. It also secretes human placental lactogen (hPL), which plays a role in preparing the breasts for lactation and relaxin, which is thought to help soften and widen the pubic symphysis in preparation for childbirth.

Concept Check

- Do you recall the term which describes high levels of glucose in the blood?
- Do you recall the neurotransmitter responsible for assisting the response to danger or stress?
- Suggest what may happen if the adrenal cortex fails to secrete its hormones.

Common Abbreviations for the Endocrine System

Query 1.14.5

This interactive element is not available in this format. Visit the link or scan the QR code to access it online.

View this Interactive Content online

Diseases and Disorders of the Endocrine System

Acromegaly

Acromegaly is a rare disorder caused when abnormally high levels of GH trigger the growth of bones, cartilage, and body tissues. It is usually caused by a tumor in the pituitary gland. The condition is often characterized by enlarged ears, hands, and feet (National Institute of Diabetes and Digestive and Kidney Diseases, n.d.-a). For more information, visit the National Institute of Diabetes and Digestive and Kidney Diseases' web page on acromegaly.

Addison's Disease

Addison's disease is a rare disorder that causes low blood glucose levels and low blood sodium levels. The signs and symptoms of Addison's disease are vague and are typical of other disorders as well, making diagnosis difficult. They may include general weakness, abdominal pain, weight loss, nausea, vomiting, sweating, and cravings for salty food. For more information, visit the National Institute of Diabetes and Digestive and Kidney Diseases' web page on adrenal insufficiency and Addison's disease.

Cushing's Syndrome

Cushing's syndrome is characterized by high blood glucose levels and the accumulation of lipid deposits on the face and neck. It is caused by the hypersecretion of cortisol. The most common source of Cushing's disease is a pituitary tumor that secretes cortisol or ACTH in abnormally high amounts. For more information, visit the National Institute of Diabetes and Digestive and Kidney Diseases' web page on Cushing's syndrome.

Gigantism

Gigantism is a disorder in children caused when abnormally high levels of GH prompt excessive growth in the body. It is most often caused by a benign tumor of the pituitary gland. If the condition lasts into adulthood, it is referred to as acromegaly (Genetic and Rare Diseases Information Center, 2017). For more information, visit the Genetic and Rare Diseases Information Center's web page on gigantism.

Hirsutism

Hirsutism is a symptom of excessive production of androgens, causing hair growth in women where they typically do not have hair growth. It is usually caused by polycystic ovary syndrome (PCOS), although certain medications and tumors of the ovary or adrenal gland can cause hirsutism (Hafsi & Badri, 2021). For more information, visit the Mayo Clinic's web page on hirsutism.

Hyperthyroidism

Hyperthyroidism is a condition marked by excessively high levels of thyroid hormones. Signs and symptoms include weight loss, heat sensitivity, and an increased or irregular heart rate. It may be caused by Graves' disease (an autoimmune disorder), thyroiditis, or a diet high in iodine (National Institute of Diabetes and Digestive and Kidney Diseases, n.d.-b). For more information, visit the National Institute of Diabetes and Digestive and Kidney Diseases' web page on hyperthyroidism.

Hypothyroidism

Hypothyroidism is a condition marked by low levels of thyroid hormones. Signs and symptoms include weight gain, cold sensitivity, and a slowed heart rate. It may be caused by Hashimoto's disease (an autoimmune disorder), thyroiditis, or surgical removal of some or all of the thyroid. Although rare in the United States, a diet low in iodine can also lead to hypothyroidism (National Institute of Diabetes and Digestive and Kidney Diseases, n.d.-c). For more information, visit the National Institute of Diabetes and Digestive and Kidney Diseases' web page on hypothyroidism.

Graves' Disease

Graves' disease is a disorder of the thyroid gland, resulting in hyperthyroidism. The immune system attacks the thyroid, resulting

in excessive production of thyroid hormone. Researchers continue to investigate why some people develop Graves' disease (National Institute of Diabetes and Digestive and Kidney Diseases, n.d.-c). For more information, visit the National Institute of Diabetes and Digestive and Kidney Diseases' web page on Graves' disease.

Diabetes Insipidus

Diabetes insipidus is a condition caused by a lack of or hyposecretion of the antidiuretic hormone (ADH). The condition can also be caused by the failure of the kidneys to respond to ADH. Signs and symptoms include polyuria and excessive thirst (National Institute of Diabetes and Digestive and Kidney Diseases, n.d.-d). For more information, visit the National Institute of Diabetes and Digestive and Kidney Diseases' web page on diabetes insipidus.

Diabetes (Mellitus)

Diabetes mellitus is a condition marked by a disorder of the pancreas, resulting in high levels of glucose in the blood. There are three common types of diabetes mellitus:

- **Type 1 diabetes** occurs when the body mounts an autoimmune response against the pancreas cells that produce insulin. People with type 1 diabetes must take insulin every day.
- **Type 2 diabetes** occurs when the body does not utilize the insulin the body produces, causing unstable blood sugar levels. People at risk of type 2 diabetes can prevent or delay onset by making lifestyle changes.
- **Gestational diabetes** occurs in pregnant women who do not have a history of diabetes. Although it generally goes away after the child is born, both the child and mother are at an increased risk of developing type 2 diabetes (Centers for Disease Control and Prevention, n.d.).

Medical Terms in Context

Query 1.14.6

This interactive element is not available in this format. Visit the link or scan the QR code to access it online.

View this Interactive Content online

Query 1.14.7

This interactive element is not available in this format. Visit the link or scan the QR code to access it online.

View this Interactive Content online

Medical Specialties and Procedures Related to the Endocrine System

Endocrinology is a specialization in the field of medicine that focuses on the treatment of endocrine system disorders. Endocrinologists—medical doctors who specialize in this field—are experts in treating diseases associated with hormonal systems, ranging from thyroid disease to diabetes. Endocrine surgeons treat endocrine disease through the removal of the affected endocrine gland or tissue. Some patients experience health problems as a result of the normal decline in hormones that can accompany aging. These patients can consult with an endocrinologist to weigh the risks and benefits of hormone replacement therapy intended to boost their natural levels of reproductive hormones. In addition to treating patients, endocrinologists may be involved in research to improve the understanding of endocrine system disorders and develop new treatments for these diseases.

- A thyroid specialist is an endocrinologist whose sub-specialty is focused on the treatment and disorders of the thyroid gland such as hypothyroidism (too low secretion) and hyperthyroidism (too high secretion).
- A diabetes specialist is an endocrinologist whose sub-specialty is focused on the treatment of diabetic conditions.

Thyroid Scan

The thyroid scan is a procedure used to check the size, shape, and position of the thyroid. Before the procedure, a small amount of radioactive iodine is administered intravenously or by oral capsule. A special camera then takes images of the thyroid, allowing the technician to determine the cause of hyperthyroidism or identify thyroid nodules (National Institute of Diabetes and Digestive and Kidney Diseases, n.d.-e). To learn more, visit the National Institute of Diabetes and Digestive and Kidney Diseases' web page on thyroid tests.

Radioactive Iodine Uptake Test

Radioactive iodine uptake is a procedure used to check the function of the thyroid. Before the procedure, a small amount of radioactive iodine is administered in liquid or capsule form. The technician then uses a gamma probe to measure how much radioactive iodine the thyroid takes up from the blood, which can be an indication of Graves' disease or one or more thyroid nodules. The radioactive iodine uptake test can be performed at the same time as a thyroid scan (National Institute of Diabetes and Digestive and Kidney Diseases, n.d.-e). To learn more, visit the National Institute of Diabetes and Digestive and Kidney Diseases' web page on thyroid tests.

Blood Serum Testing

Blood serum tests are used to determine the concentration and presence of various endocrine hormones in the blood, including TSH, T4, and T3. Blood serum tests can also detect the presence of thyroid antibodies which can indicate an autoimmune thyroid disorder (National Institute of Diabetes and Digestive and Kidney Diseases, n.d.-e). To learn more, visit the National Institute of Diabetes and Digestive and Kidney Diseases' web page on thyroid tests.

Endocrine Surgical Procedures

Most of the surgeries and procedures performed with the endocrine system involve the removal of a gland or an incision into the gland. Once an endocrine gland is surgically removed, due to a tumor or enlargement, hormone replacement treatment is required. Medication is required to artificially or synthetically replace the hormone produced by the gland and the function it regulates.

Endocrine System Vocabulary

Acromegaly: A disorder that results in the growth of bones in the face, hands, and feet in response to excessive levels of growth hormone in individuals who have stopped growing.

Adenosis: A disease or abnormal change in a gland.

Adrenalectomy: Excision of one or both adrenal glands.

Autocrine: A chemical that elicits a response in the same cell that secreted it.

Endocrine gland: A ductless gland that releases secretions directly into surrounding tissues and fluids.

Endocrine system: Cells, tissues, and organs that secrete hormones as a primary or secondary function and play an integral role in normal bodily processes.

Endocrinologist: A doctor who has special training in diagnosing and treating disorders of the endocrine system.

Endocrinology: A specialty in the field of medicine that focuses on the treatment of endocrine system disorders.

Epinephrine: A hormone that causes the breakdown of glycogen into glucose; also known as adrenaline.

Exocrine system: Cells, tissues, and organs that secrete substances directly to target tissues via glandular ducts.

Glycemia: Sugar in the blood.

Histamine: A vasodilator involved in the inflammatory response.

Hormone: Secretion of an endocrine organ that travels via the bloodstream or lymphatics to induce a response in target cells or tissues in another part of the body.

Hypercalcemia: Excessive calcium in the blood.

Hyperglycemia: Abnormally high blood glucose levels.

Hyperkalemia: Higher-than-normal blood potassium levels.

Hyperthyroidism: The disease state caused by excessive production of hormones by the thyroid.

Hypocalcemia: Abnormally low blood levels of calcium.

Hypoglycemia: Low blood glucose levels.

Hypokalemia: Abnormally decreased blood levels of potassium.

Hyponatremia: Lower-than-normal levels of sodium in the blood.

Hypopituitarism: State of deficient pituitary gland activity.

Hypothyroidism: The disease state caused by insufficient production of thyroid hormone by the thyroid gland.

Neurotransmitters: Chemicals that are made by nerve cells and used to communicate with other cells, including other nerve cells and muscle cells.

Norepinephrine: A chemical in the body that can act as a neurotransmitter and a hormone. It is released from the adrenal gland in response to stress and low blood pressure and is also known as noradrenaline.

Panhypopituitarism: A rare condition in which the pituitary gland stops making most or all hormones.

Paracrine: Cellular signaling in which a factor secreted by a cell affects other cells in the local environment.

Parathyroidectomy: Surgery to remove one or more parathyroid glands.

Permeability: Property of membranes and other structures to permit passage of light, heat, gases, liquids, metabolites, and mineral ions.

Polydipsia: Condition of excessive thirst.

Proliferation: The multiplication or increase in number.

Syndrome: A set of symptoms or conditions that occur together and suggest the presence of a certain disease or an increased chance of developing the disease.

Synthesis: A chemical reaction that results in the synthesis (joining) of components that were formerly separate.

Thyroidectomy: Excision of all or part of the thyroid gland.

Thyroiditis: Inflammation of the thyroid gland.

Test Yourself

Query 1.14.8

This interactive element is not available in this format. Visit the link or scan the QR code to access it online.

View this Interactive Content online

References

Centers for Disease Control and Prevention. (n.d.). *What is diabetes?* https://www.cdc.gov/diabetes/basics/diabetes.html

CrashCourse. (2015, June 22). *Endocrine system, part 1 – glands & hormones: Crash course A&P #23* [Video]. YouTube. https://www.youtube.com/watch?v=eWHH9je2zG4

CrashCourse. (2015, June 29). *Endocrine system, part 2 – hormone cascade: Crash course A&P #24* [Video]. YouTube. https://www.youtube.com/watch?v=eWHH9je2zG4

Genetic and Rare Diseases Information Center. (2017). *Gigantism*. National Institutes of Health, U.S. Department of Health and Human Services. https://rarediseases.info.nih.gov/diseases/6506/gigantism

Hafsi, W., & Badri, T. (2021). Hirsutism. In *StatPearls [Internet]*. https://www.ncbi.nlm.nih.gov/books/NBK470417/

MedlinePlus. (2020). *Radioactive iodine uptake*. US National Library of Medicine. https://medlineplus.gov/ency/article/003689.htm

National Institute of Diabetes and Digestive and Kidney Diseases. (n.d.-a). *Acromegaly*. National Institutes of Health, U.S. Department of Health and Human Services. https://www.niddk.nih.gov/health-information/endocrine-diseases/acromegaly

National Institute of Diabetes and Digestive and Kidney Diseases. (n.d.-b). *Hyperthyroidism*. National Institutes of Health, U.S. Department of Health and Human Services. https://www.niddk.nih.gov/health-information/endocrine-diseases/hyperthyroidism

National Institute of Diabetes and Digestive and Kidney Diseases. (n.d.-c). *Graves' disease*. National Institutes of Health, U.S. Department of Health and Human Services. https://www.niddk.nih.gov/health-information/endocrine-diseases/graves-disease

National Institute of Diabetes and Digestive and Kidney Diseases. (n.d.-d). *Diabetes insipidus*. National Institutes of Health, U.S. Department of Health and Human Services. https://www.niddk.nih.gov/health-information/kidney-disease/diabetes-insipidus

National Institute of Diabetes and Digestive and Kidney Diseases. (n.d.-e). *Thyroid tests*. National Institutes of Health, U.S. Department of Health and Human Services. https://www.niddk.nih.gov/health-information/diagnostic-tests/thyroid

Wright Jr, K. P., McHill, A. W., Birks, B. R., Griffin, B. R., Rusterholz, T., & Chinoy, E. D. (2013). Entrainment of the human circadian clock to the natural light-dark cycle. *Current Biology*, *23*(16), 1554-1558. https://doi.org/10.1016/j.cub.2013.06.039

Image Descriptions

Figure 14.1 image description: This photo shows a young girl reaching for an orange leaf on an oak tree. She is on a walkway near a creek. The opposite shore is a deep slope covered with more trees in autumn colors. [Return to Figure 14.1].

Figure 14.2 image description: This diagram shows the endocrine glands and cells that are located throughout the body. The endocrine system organs include the pineal gland and pituitary gland in the brain. The pituitary is located on the anterior side of the thalamus while the pineal gland is located on the posterior side of the thalamus. The thyroid gland is a butterfly-shaped gland that wraps around the trachea within the neck. Four small, disc-shaped parathyroid glands are embedded into the posterior side

of the thyroid. The adrenal glands are located on top of the kidneys. The pancreas is located at the center of the abdomen. In females, the two ovaries are connected to the uterus by two long, curved, tubes in the pelvic region. In males, the two testes are located in the scrotum below the penis. [Return to Figure 14.2].

Figure 14.3 image description: This diagram shows a negative feedback loop using the example of glucocorticoid regulation in the blood. Step 1 in the cycle is when an imbalance occurs. The hypothalamus perceives low blood concentrations of glucocorticoids in the blood. This is illustrated by there being only 5 glucocorticoids floating in a cross-section of an artery. Step 2 in the cycle is hormone release, where the hypothalamus releases corticotropin-releasing hormone (CRH). Step 3 is labeled correction. Here, the CRH release starts a hormone cascade that triggers the adrenal gland to release glucocorticoid into the blood. This allows the blood concentration of glucocorticoid to increase, as illustrated by 8 glucocorticoid molecules now being present in the cross-section of the artery. Step 4 is labeled negative feedback. Here, the hypothalamus perceives normal concentrations of glucocorticoids in the blood and stops releasing CRH. This brings blood glucocorticoid levels back to homeostasis. [Return to Figure 14.3].

Figure 14.4 image description: This illustration zooms in on the hypothalamus and the attached pituitary gland. The anterior pituitary is highlighted. Three neurosecretory cells are secreting hormones into a web-like network of arteries within the infundibulum. The artery net is labeled the primary capillary plexus of the hypophyseal portal system. The superior hypophyseal artery enters the primary capillary plexus from outside of the infundibulum. The hypophyseal portal vein runs down from the primary capillary plexus, through the infundibulum, and connects to the secondary capillary plexus of the hypophyseal portal system. The secondary capillary plexus is located within the anterior pituitary. The hormones released from the neurosecretory cells of the hypothalamus travel through the primary capillary plexus, down the hypophyseal portal vein, and into the secondary capillary plexus. There, the hypothalamus hormones stimulate the anterior pituitary to release its hormones. The anterior pituitary hormones leave the primary capillary plexus from a single vein at the bottom of the anterior lobe. [Return to Figure 14.4].

Figure 14.5 image description: This flow chart illustrates the hormone cascade that stimulates human growth. In step 1, the hypothalamus releases growth hormone-releasing hormone (GHRH). GHRH travels into the primary capillary plexus of the anterior pituitary, where it stimulates the anterior pituitary to release growth hormone (GH). The release of growth hormone causes three types of effects. In the glucose-sparing effect, GH stimulates adipose cells to break down stored fat, fueling the growth effects (discussed next). The target cells for the glucose-sparing effects are adipose cells. In the growth effects, GH increases the uptake of amino acids from the blood and enhances cellular proliferation while also reducing apoptosis. The target cells for the growth effects are bone cells, muscle cells, nervous system cells, and immune system cells. In the diabetogenic effect, GH stimulates the liver to break down glycogen into glucose, fueling the growth effects. The liver also releases IGF in response to GH. The IGF further stimulates the growth effects but also negatively feeds back to the hypothalamus. When high IGF one levels are perceived by the hypothalamus, it releases growth hormone inhibiting hormone (GHIH). GHIH inhibits GH release by the anterior pituitary. [Return to Figure 14.5].

Figure 14.6 image description: This illustration zooms in on the hypothalamus and the attached pituitary gland. The posterior pituitary is highlighted. Two nuclei in the hypothalamus contain neurosecretory cells that release different hormones. The neurosecretory cells of the paraventricular nucleus release oxytocin (OT) while the neurosecretory cells of the supraoptic nucleus release antidiuretic hormone (ADH). The neurosecretory cells stretch down the infundibulum into the posterior pituitary. The tube-like extensions of the neurosecretory cells within the infundibulum are labeled the hypothalamohypophysial tracts. These tracts connect with a web-like network of blood vessels in the posterior pituitary called the capillary plexus. From the capillary plexus, the posterior pituitary secretes the OT or ADH into a single vein that exits the pituitary. [Return to Figure 14.6].

Figure 14.7 image description: Part A of this figure is a diagram of the anterior view of the thyroid gland. The thyroid gland is a butterfly-shaped gland wrapping around the trachea. It narrows at its center, just under the thyroid cartilage of the larynx. This narrow area is called the isthmus of the thyroid. Two large arteries, the common carotid arteries, run parallel to the trachea on the outer border of the thyroid. A small artery enters the superior edge of the thyroid, near the isthmus, and branches throughout the two “wings” of the thyroid. Part B of this figure is a posterior view of the thyroid. The posterior view shows that the thyroid does not completely wrap around the posterior of the trachea. The posterior sides of the thyroid wings can be seen protruding from under the cricoid cartilage of the larynx. The posterior sides of the thyroid “wings” each contain two small, disc-shaped parathyroid glands embedded in the thyroid tissue. Within each wing, one disc is located superior to the other. These are labeled the left and right parathyroid glands. Just under the inferior parathyroid glands are two arteries that bring blood to the thyroid from the left and right subclavian arteries. Part C of this figure is a micrograph of thyroid tissue. The thyroid follicle cells are cuboidal epithelial cells. These cells form a ring around irregular-shaped cavities called follicles. The follicles contain light-colored colloids. A larger parafollicular cell is embedded between two of the follicular cells near the edge of a follicle. [Return to Figure 14.7].

Figure 14.8 image description: This diagram shows the left adrenal gland located atop the left kidney. The gland is composed of an outer cortex and an inner medulla all surrounded by a connective tissue capsule. The cortex can be subdivided into

additional zones, all of which produce different types of hormones. The outermost layer is the zona glomerulosa, which releases mineralocorticoids, such as aldosterone, that regulate mineral balance. Underneath this layer is the zona fasciculata, which releases glucocorticoids, such as cortisol, corticosterone, and cortisone, that regulate glucose metabolism. Underneath this layer is the zona reticularis, which releases androgens, such as dehydroepiandrosterone, that stimulate masculinization. Below this layer is the adrenal medulla, which releases stress hormones, such as epinephrine and norepinephrine, that stimulate the sympathetic ANS. [Return to Figure 14.8].

Figure 14.9 image description: This diagram shows the anatomy of the pancreas. The left, larger side of the pancreas is seated within the curve of the duodenum of the small intestine. The smaller, rightmost tip of the pancreas is located near the spleen. The splenic artery is seen traveling to the spleen, however, it has several branches connecting to the pancreas. An interior view of the pancreas shows that the pancreatic duct is a large tube running through the center of the pancreas. It branches throughout its length into several horseshoe-shaped pockets of acinar cells. These cells secrete digestive enzymes, which travel down the bile duct and into the small intestine. There are also small pancreatic islets scattered throughout the pancreas. The pancreatic islets secrete the pancreatic hormones insulin and glucagon into the splenic artery. An inset micrograph shows that the pancreatic islets are small discs of tissue consisting of a thin, outer ring called the exocrine acinus, a thicker, inner ring of beta cells, and a central circle of alpha cells. [Return to Figure 14.9].

Unless otherwise indicated, this chapter contains material adapted from Anatomy and Physiology (on OpenStax), by Betts et al. and is used under a CC BY 4.0 international license. Download and access this book for free at https://openstax.org/books/anatomy-and-physiology/pages/1-introduction.

This page titled 1.14: Endocrine System is shared under a CC BY 4.0 license and was authored, remixed, and/or curated by Andrea Nelson and Katherine Greene via source content that was edited to the style and standards of the LibreTexts platform.

1.15: Urinary System

Learning Objectives

- Examine the anatomy of the urinary system
- Determine the main functions of the urinary system
- Differentiate urinary system medical terms and common abbreviations
- Recognize the medical specialties associated with the urinary system
- Discover common diseases, disorders, and procedures related to the urinary system

Urinary System Word Parts

Click on prefixes, combining forms, and suffixes to reveal a list of word parts to memorize for the urinary system.

Query 1.15.1

This interactive element is not available in this format. Visit the link or scan the QR code to access it online.

View this Interactive Content online

Introduction to the Urinary System

The urinary system has roles you may be well aware of on a daily basis. Cleansing the blood and ridding the body of wastes probably come to mind. However, there are additional, equally important functions, played by the system. Take, for example, regulation of pH, a function shared with the lungs and the buffers in the blood. Additionally, the regulation of blood pressure is a role shared with the heart and blood vessels. What about regulating the concentration of solutes in the blood? Did you know that the kidney is important in determining the concentration of red blood cells? Eighty-five percent of the erythropoietin (EPO) produced to stimulate red blood cell production is produced in the kidneys. The kidneys also perform the final synthesis step of vitamin D production, converting calcidiol to calcitriol, the active form of vitamin D. If the kidneys fail, these functions are compromised or lost altogether, with devastating effects on homeostasis.

Watch this video:

YouTube Video

This interactive element is not available in this format. Visit the link or scan the QR code to access it online.

View this YouTube Video online

Media 15.1. Urinary System, Part 1: Crash Course A&P #38 [Online video]. Copyright 2015 by CrashCourse.

Practice Medical Terms Related to the Urinary System

Query 1.15.2

This interactive element is not available in this format. Visit the link or scan the QR code to access it online.

View this Interactive Content online

Anatomy (Structures) of the Urinary System

Kidneys

The kidneys lie on either side of the spine in the retroperitoneal space between the parietal peritoneum and the posterior abdominal wall, well protected by muscle, fat, and ribs. They are roughly the size of your fist. The male kidney is typically a bit larger than the female kidney. The kidneys are well vascularized, receiving about 25% of the cardiac output at rest. Figure 15.1 displays the location of the kidneys.

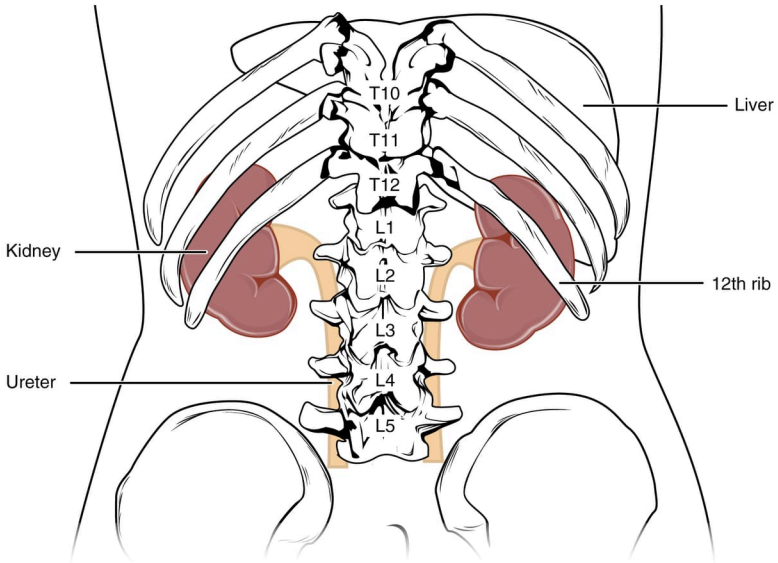

Figure 15.1 Kidneys. The kidneys are slightly protected by the ribs and are surrounded by fat for protection (not shown). From Betts et al., 2013. Licensed under CC BY 4.0. [Image description.]

Kidneys' Internal Structure

A frontal section through the kidney reveals an outer region called the renal cortex and an inner region called the medulla (see Figure 15.2). The renal columns are connective tissue extensions that radiate downward from the cortex through the medulla to separate the most characteristic features of the medulla, the renal pyramids and renal papillae. The papillae are bundles of collecting ducts that transport urine made by nephrons to the calyces of the kidney for excretion. The renal columns also serve to divide the kidney into 6 to 8 lobes and provide a supportive framework for vessels that enter and exit the cortex. The pyramids and renal columns taken together constitute the kidney lobes.

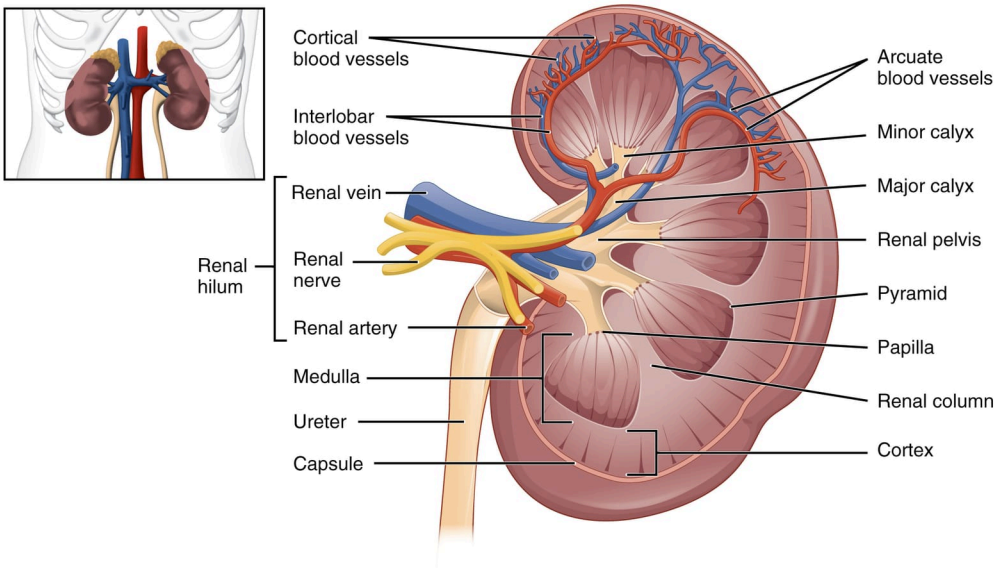

Figure 15.2 Left Kidney. From Betts et al., 2013. Licensed under CC BY 4.0. [Image description.]

Did you know?

The right kidney is smaller than the left. It also sits slightly lower to make room for the liver located on the right side of your body.

Renal Hilum

The **renal hilum** is the entry and exit site for structures servicing the kidneys: vessels, nerves, lymphatics, and ureters. The medial-facing hila are tucked into the sweeping convex outline of the cortex. Emerging from the hilum is the renal pelvis, which is formed from the major and minor **calyces** in the kidney. The smooth muscle in the renal pelvis funnels urine via **peristalsis** into the ureter. The renal arteries form directly from the descending aorta, whereas the renal veins return cleansed blood directly to the inferior vena cava. The artery, vein, and renal pelvis are arranged in an anterior-to-posterior order.

Nephrons and Vessels

The renal artery first divides into segmental arteries, followed by further branching to form interlobar arteries that pass through the renal columns to reach the cortex (see Figure 15.3). The **interlobar** arteries, in turn, branch into **arcuate** arteries, cortical **radiate** arteries, and then into afferent arterioles. The afferent arterioles service about 1.3 million nephrons in each kidney.

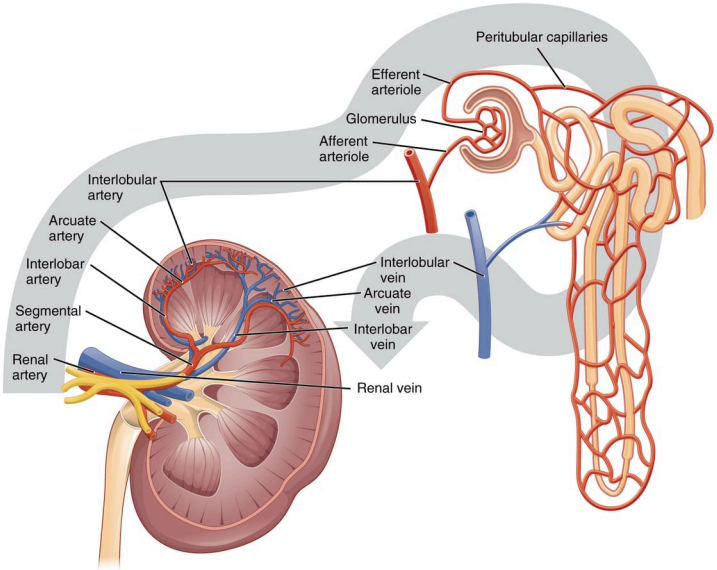

Figure 15.3 Blood Flow in the Kidney. From Betts et al., 2013. Licensed under CC BY 4.0. [Image description.]

Nephrons are the "functional units" of the kidney; they cleanse the blood and balance the constituents of the circulation. The afferent arterioles form a tuft of high-pressure capillaries about 200 µm in diameter, the **glomerulus**. The rest of the nephron consists of a continuous sophisticated tubule whose proximal end surrounds the glomerulus in an intimate embrace—this is **Bowman's capsule**. The glomerulus and Bowman's capsule together form the **renal corpuscle**. As mentioned earlier, these glomerular capillaries filter the blood based on particle size. After passing through the renal corpuscle, the capillaries form a second arteriole, the **efferent arteriole** (see Figure 15.4). These will next form a capillary network around the more distal portions of the nephron tubule, the **peritubular capillaries** and **vasa recta**, before returning to the venous system. As the glomerular filtrate progresses through the nephron, these capillary networks recover most of the solutes and water, and return them to the circulation. Since a capillary bed (the glomerulus) drains into a vessel that in turn forms a second capillary bed, the definition of a portal system is met. This is the only portal system in which an arteriole is found between the first and second capillary beds. Portal systems also link the hypothalamus to the anterior pituitary, and the blood vessels of the digestive viscera to the liver.

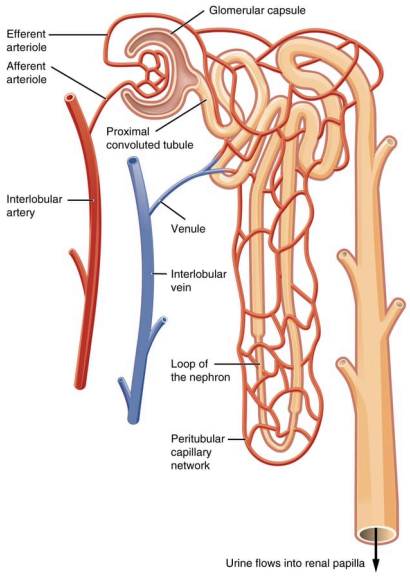

Figure 15.4. Blood Flow in the Nephron. The two capillary beds are clearly shown in this figure. The efferent arteriole is the connecting vessel between the glomerulus and the peritubular capillaries and vasa recta. From Betts et al., 2013. Licensed under CC BY 4.0. [Image description.]

Ureters

The kidneys and ureters are completely **retroperitoneal**, and the bladder has a **peritoneal** covering only over the dome. As urine is formed, it drains into the calyces of the kidney, which merge to form the funnel-shaped renal pelvis in the hilum of each kidney. The hilum narrows to become the **ureter** of each kidney. As urine passes through the ureter, it does not passively drain into the bladder but rather is propelled by waves of **peristalsis**. The ureters are approximately 30 cm long. The inner mucosa is lined with transitional epithelium and scattered **goblet** cells that secrete protective mucus. The muscular layer of the ureter consists of longitudinal and circular smooth muscles that create the peristaltic contractions to move the urine into the bladder without the aid of gravity. Finally, a loose adventitial layer composed of **collagen** and fat anchors the ureters between the parietal peritoneum and the posterior abdominal wall.

Bladder

The urinary bladder collects urine from both ureters (see Figure 15.5). The bladder lies anterior to the uterus in females, posterior to the pubic bone and anterior to the rectum. During late pregnancy, its capacity is reduced due to compression by the enlarging uterus, resulting in increased frequency of urination. In males, the anatomy is similar, minus the uterus, and with the addition of the prostate inferior to the bladder. The bladder is partially retroperitoneal (outside the peritoneal cavity) with its peritoneal-covered “dome” projecting into the abdomen when the bladder is distended with urine.

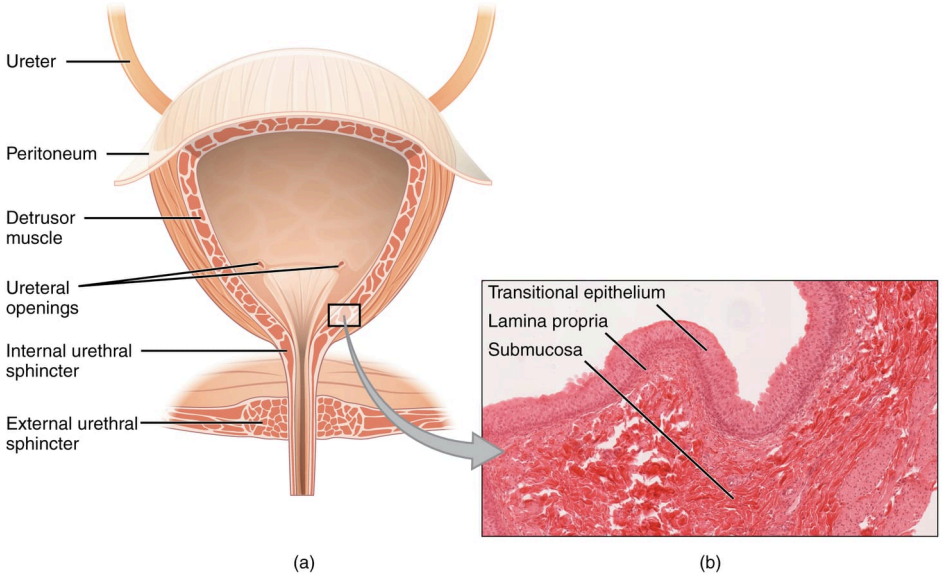

Figure 15.5 Bladder. (a) Anterior cross section of the bladder. (b) The detrusor muscle of the bladder (source: monkey tissue) LM × 448. (Micrograph provided by the Regents of the University of Michigan Medical School © 2012). From Betts et al., 2013. Licensed under CC BY 4.0. [Image description.]

Urethra

The urethra transports urine from the bladder to the outside of the body for disposal. The urethra is the only urologic organ that shows any significant anatomic difference between males and females; all other urine transport structures are identical (see Figure 15.6).

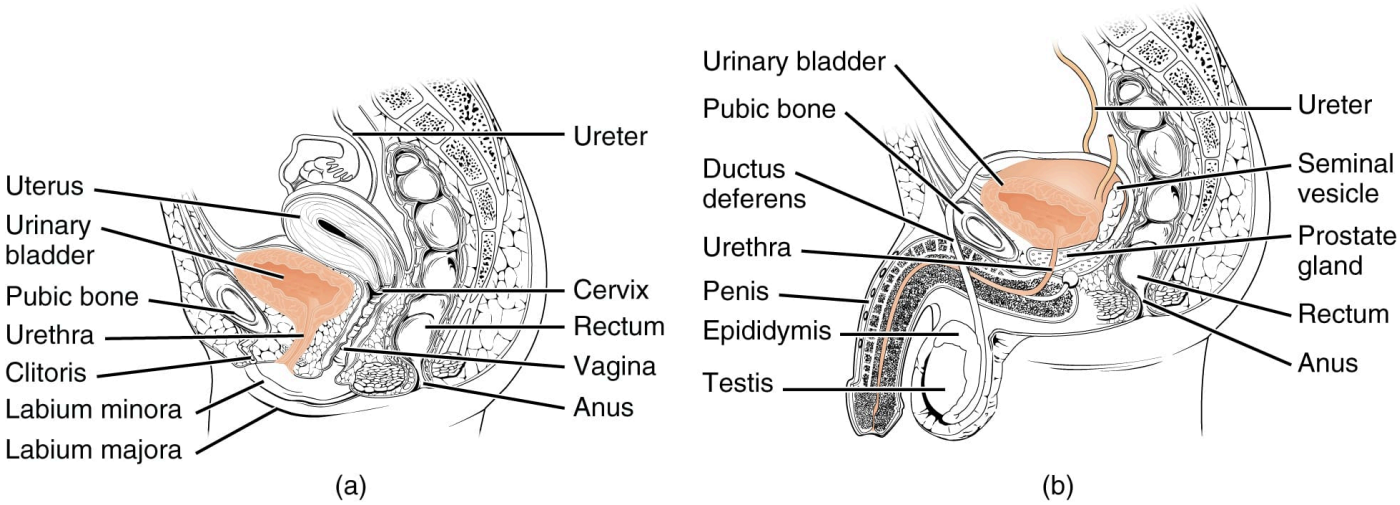

Figure 15.6. Female and Male Urethras. The urethra transports urine from the bladder to the outside of the body. This image shows (a) a female urethra and (b) a male urethra. From Betts et al., 2013. Licensed under CC BY 4.0. [Image description.]

The urethra in both males and females begins inferior and central to the two ureteral openings forming the three points of a triangular-shaped area at the base of the bladder called the trigone (Greek tri- = "triangle" and the root of the word "trigonometry"). The urethra tracks posterior and inferior to the pubic symphysis (see Figure 15.6). In both males and females, the proximal urethra is lined by transitional epithelium, whereas the terminal portion is a nonkeratinized, stratified squamous epithelium. In the male, pseudostratified columnar epithelium lines the urethra between these two cell types. Voiding is regulated by an involuntary autonomic nervous system-controlled internal urinary sphincter, consisting of smooth muscle and voluntary skeletal muscle that forms the external urinary sphincter below it.

Micturition Reflex

Micturition is a less-often used, but proper term for **urination** or **voiding**. It results from an interplay of involuntary and voluntary actions by the internal and external urethral sphincters. When bladder volume reaches about 150 mL, an urge to void is sensed but is easily overridden. Voluntary control of urination relies on consciously preventing relaxation of the external urethral sphincter to maintain urinary continence. As the bladder fills, subsequent urges become harder to ignore. Ultimately, voluntary constraint fails with resulting incontinence, which will occur as bladder volume approaches 300 to 400 ml.

- Normal micturition is a result of stretch **receptors** in the bladder wall that transmit nerve impulses to the sacral region of the spinal cord to generate a spinal reflex. The resulting parasympathetic neural outflow causes contraction of the detrusor muscle and relaxation of the involuntary internal urethral sphincter.
- At the same time, the spinal cord inhibits somatic motor neurons, resulting in the relaxation of the skeletal muscle of the external urethral **sphincter**.
- The micturition reflex is active in infants but with maturity, children learn to override the reflex by asserting external sphincter control, thereby delaying voiding (potty training). This reflex may be preserved even in the face of spinal cord injury that results in paraplegia or quadriplegia. However, relaxation of the external sphincter may not be possible in all cases, and therefore, periodic catheterization may be necessary for bladder emptying.

Nerves involved in the control of urination include the hypogastric, pelvic, and pudendal. Voluntary micturition requires an intact spinal cord and functional pudendal nerve arising from the sacral micturition center. Since the external urinary sphincter is voluntary skeletal muscle, actions by cholinergic neurons maintain contraction (and thereby continence) during filling of the bladder. At the same time, sympathetic nervous activity via the hypogastric nerves suppresses contraction of the detrusor muscle. With further bladder stretch, afferent signals traveling over sacral pelvic nerves activate parasympathetic neurons. This activates efferent neurons to release acetylcholine at the neuromuscular junctions, producing detrusor contraction and bladder emptying.

Did you know?

A healthy adult bladder can store up to 455 millilitres of urine for between two to five hours.

Concept Check

- Describe two organs or structures essential to the urinary system.
- Identify the structure within the kidneys which filters blood.
- Name a commonly used term for the **micturition reflex.**

Anatomy Labeling Activity

Query 1.15.3

This interactive element is not available in this format. Visit the link or scan the QR code to access it online.

View this Interactive Content online

Physiology (Function) of the Urinary System

- Remove waste products and medicines from the body
- Balance the body's fluids
- Balance a variety of electrolytes
- Release hormones to control blood pressure
- Release a hormone to control red blood cell production
- Help with bone health by controlling calcium and phosphorus

Having reviewed the anatomy of the urinary system now is the time to focus on physiology. You will discover that different parts of the **nephron** utilize specific processes to produce urine: **filtration**, **reabsorption**, and **secretion**. You will learn how each of these processes works and where they occur along the nephron and collecting ducts. The physiologic goal is to modify the composition of the plasma and, in doing so, produce the waste product urine.

Nephrons: The Functional Unit

Nephrons take a simple filtrate of the blood and modify it into urine. Many changes take place in the different parts of the nephron before urine is created for disposal. The term "forming urine" will be used hereafter to describe the **filtrate** as it is modified into true urine. The principal task of the nephron population is to balance the **plasma** to homeostatic set points and excrete potential toxins in the urine. They do this by accomplishing three principle functions—filtration, reabsorption, and secretion. They also have additional secondary functions that exert control in three areas: blood pressure (via the production of renin), red blood cell production (via the hormone EPO), and calcium absorption (via the conversion of calcidiol to calcitriol, the active form of vitamin D).

Loop of Henle

The descending and ascending portions of the loop of Henle (sometimes referred to as the **nephron loop**) are, of course, just continuations of the same tubule. They run adjacent and parallel to each other after having made a hairpin turn at the deepest point of their descent. The descending loop of Henle consists of an initial short, thick portion and long, thin portion, whereas the ascending loop consists of an initial short, thin portion followed by a long, thick portion. The descending and ascending thin portions consist of simple squamous epithelium. Different portions of the loop have different **permeabilities** for solutes and water.

Collecting Ducts

The collecting ducts are continuous with the nephron but are not technically part of it. In fact, each duct collects filtrate from several nephrons for final modification. Collecting ducts merge as they descend deeper in the medulla to form about 30 terminal ducts, which empty at a papilla.

Glomerular Filtration Rate (GFR)

The volume of filtrate formed by both kidneys per minute is termed the **glomerular filtration rate** (GFR). The heart pumps about 5 L blood per min under resting conditions. Approximately 20% or one liter enters the kidneys to be filtered. On average, this liter results in the production of about 125 mL/min filtrate produced in men (range of 90 to 140 mL/min) and 105 mL/min filtrate produced in women (range of 80 to 125 mL/min). This amount equates to a volume of about 180 L/day in men and 150 L/day in women. Ninety-nine percent of this filtrate is returned to the circulation by reabsorption so that only about 1 to 2 liters of urine are produced per day.

GFR is influenced by the hydrostatic pressure and colloid osmotic pressure on either side of the capillary membrane of the glomerulus. Recall that filtration occurs as pressure forces fluid and solutes through a **semipermeable** barrier with the solute movement constrained by particle size. Hydrostatic pressure is the pressure produced by a fluid against a surface. If you have fluid on both sides of a barrier, both fluids exert pressure in opposing directions. The net fluid movement will be in the direction of the lower pressure. Osmosis is the movement of solvent (water) across a membrane that is **impermeable** to a solute in the solution. This creates osmotic pressure which will exist until the solute concentration is the same on both sides of a semipermeable membrane. As long as the concentration differs, water will move. Glomerular filtration occurs when glomerular hydrostatic pressure exceeds the luminal **hydrostatic** pressure of Bowman's capsule. There is also an opposing force, the osmotic pressure, which is typically higher in the glomerular capillary. To understand why this is so, look more closely at the microenvironment on either side of the filtration membrane.

You will find osmotic pressure exerted by the solutes inside the lumen of the capillary as well as inside of Bowman's capsule. Since the filtration membrane limits the size of particles crossing the membrane, the osmotic pressure inside the glomerular **capillary** is higher than the osmotic pressure in Bowman's capsule. Recall that cells and the medium-to-large proteins cannot pass between the podocyte processes or through the fenestrations of the capillary endothelial cells. This means that red and white blood cells, platelets, **albumins**, and other proteins too large to pass through the filter remain in the capillary, creating an average **colloid** osmotic pressure of 30 mm Hg within the capillary. The absence of proteins in Bowman's space (the lumen within Bowman's capsule) results in an osmotic pressure near zero. Thus, the only pressure moving fluid across the capillary wall into the lumen of Bowman's space is hydrostatic pressure. Hydrostatic (fluid) pressure is sufficient to push water through the membrane despite the osmotic pressure working against it. The sum of all of the influences, both osmotic and hydrostatic, results in a net filtration pressure (NFP) of about 10 mm Hg (see Figure 15.7).

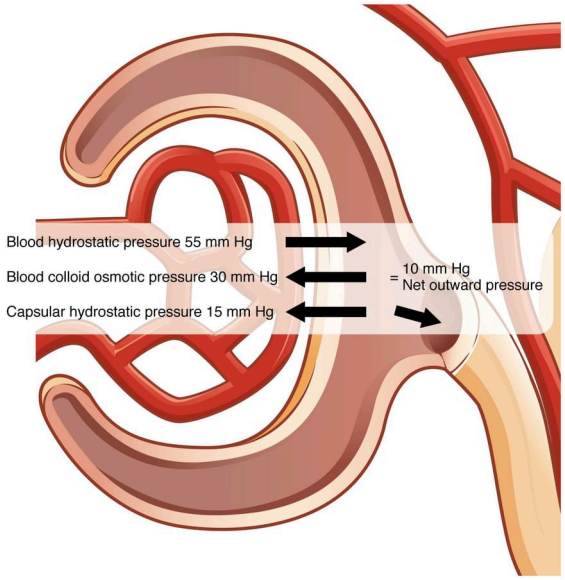

Figure 15.7 Net Filtration Pressure. The NFP is the sum of osmotic and hydrostatic pressures. From Betts et al., 2013. Licensed under CC BY 4.0. [Image description.]

A proper concentration of solutes in the blood is important in maintaining osmotic pressure both in the glomerulus and systemically. There are disorders in which too much protein passes through the filtration slits into the kidney filtrate. This excess protein in the filtrate leads to a deficiency of circulating **plasma** proteins. In turn, the presence of protein in the urine increases its osmolarity; this holds more water in the filtrate and results in an increase in urine volume. Because there is less circulating protein, principally albumin, the osmotic pressure of the blood falls. Less osmotic pressure pulling water into the capillaries tips the balance towards hydrostatic pressure, which tends to push it out of the capillaries. The net effect is that water is lost from the circulation to interstitial tissues and cells. This "plumps up" the tissues and cells, a condition termed **systemic edema**.

Reabsorption and Secretion

The renal corpuscle filters the blood to create a filtrate that differs from blood mainly in the absence of cells and large proteins. From this point to the ends of the collecting ducts, the filtrate or forming urine is undergoing modification through **secretion** and **reabsorption** before true urine is produced. Here, some substances are reabsorbed, whereas others are secreted. Note the use of the term "reabsorbed." All of these substances were "absorbed" in the digestive tract—99% of the water and most of the solutes filtered by the nephron must be reabsorbed. Water and substances that are reabsorbed are returned to the circulation by the peritubular and vasa recta capillaries.

It is vital that the flow of blood through the kidney is at a suitable rate to allow for filtration. This rate determines how much solute is retained or discarded, how much water is retained or discarded, and ultimately, the **osmolarity** of blood and the blood pressure of the body.

Urinalysis

Urinalysis (urine analysis) often provides clues to renal disease. Normally, only traces of protein are found in urine, and when higher amounts are found, damage to the glomeruli is the likely basis. Unusually large quantities of urine may point to diseases like diabetes mellitus or hypothalamic tumors that cause diabetes insipidus. The color of urine is determined mostly by the breakdown products of red blood cell destruction (see Figure 15.8). The "heme" of **hemoglobin** is converted by the liver into water-soluble forms that can be excreted into the **bile** and indirectly into the urine. This yellow pigment is urochrome. Urine color may also be affected by certain foods like beets, berries, and fava beans. A kidney stone or a cancer of the urinary system may produce sufficient bleeding to manifest as pink or even bright red urine. Diseases of the liver or obstructions of bile drainage from the liver impart a dark "tea" or "cola" hue to the urine. **Dehydration** produces darker, concentrated urine that may also possess the slight odor of **ammonia**. Most of the ammonia produced from protein breakdown is converted into **urea** by the liver, so ammonia is rarely detected in fresh urine. The strong ammonia odor you may detect in bathrooms or alleys is due to the breakdown of urea into ammonia by bacteria in the environment. About one in five people detect a distinctive odor in their urine after consuming asparagus; other foods such as onions, garlic, and fish can impart their own aromas. These food-caused odors are harmless.

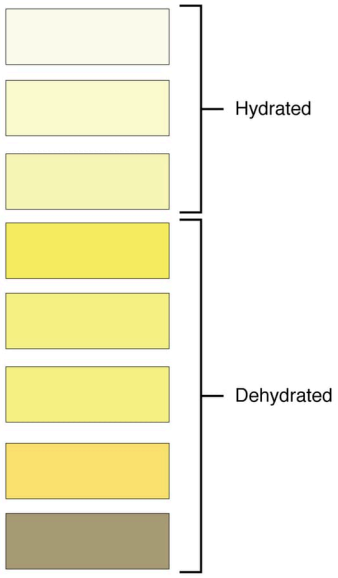

Figure 15.8 Urine Color. From Betts et al., 2013. Licensed under CC BY 4.0. [Image description.]

Urine volume varies considerably. The normal range is one to two liters per day. The kidneys must produce a minimum urine volume of about 500 mL/day to rid the body of wastes. Output below this level may be caused by severe dehydration or renal disease and is termed **oliguria**. The virtual absence of urine production is termed **anuria**. Excessive urine production is **polyuria**, which may be due to diabetes mellitus or diabetes insipidus. In diabetes mellitus, blood glucose levels exceed the number of available sodium-glucose transporters in the kidney, and glucose appears in the urine. The osmotic nature of glucose attracts water, leading to its loss in the urine. In the case of diabetes insipidus, insufficient pituitary antidiuretic hormone (ADH) release or insufficient numbers of ADH receptors in the collecting ducts means that too few water channels are inserted into the cell membranes that line the collecting ducts of the kidney. Insufficient numbers of water channels (aquaporins) reduce water absorption, resulting in high volumes of very dilute urine.

Concept Check

- Contrast the following terms: **oliguria**, **anuria** and **polyuria**. What are the differences between these terms as they describe urinary output?
- Explain how urine **color** varies based on food consumed and/or **hydration** levels.

Endocrine Urinary Function

Several hormones have specific, important roles in regulating kidney function. They act to stimulate or inhibit blood flow. Some of these are endocrine, acting from a distance, whereas others are paracrine, acting locally.

Renin–Angiotensin–Aldosterone

Renin is an **enzyme** that is produced by the granular cells of the afferent arteriole. It enzymatically converts angiotensinogen (made by the liver, freely circulating) into angiotensin I. Its release is stimulated by prostaglandins to decrease extracellular fluid volume.

Angiotensin II is a potent vasoconstrictor that plays an immediate role in the regulation of blood pressure. It acts systemically to cause vasoconstriction as well as constriction of both the **afferent** and **efferent** arterioles of the glomerulus. In instances of blood loss or dehydration, it reduces both GFR and renal blood flow, thereby limiting fluid loss and preserving blood volume. Its release is usually stimulated by decreases in blood pressure, and so the preservation of adequate blood pressure is its primary role.

Aldosterone, often called the “salt-retaining hormone,” is released from the **adrenal cortex** in response to angiotensin II or directly in response to increased plasma potassium. It promotes sodium reabsorption by the nephron, promoting the retention of water.

Antidiuretic Hormone (ADH)

Diuretics are drugs that can increase water loss by interfering with the recapture of solutes and water from the forming urine. They are often prescribed to lower blood pressure. Coffee, tea, and alcoholic beverages are familiar diuretics. ADH, released by the posterior pituitary, works to do the exact opposite. It promotes the recovery of water, decreases urine volume, and maintains plasma osmolarity and blood pressure. It does so by stimulating the movement of **aquaporin** proteins into the apical cell membrane of principal cells of the collecting ducts to form water channels, allowing the transcellular movement of water from the lumen of the collecting duct into the interstitial space in the medulla of the kidney by osmosis. From there, it enters the vasa recta capillaries to return to the circulation. Water is attracted by the high osmotic environment of the deep kidney **medulla.**

Parathyroid Hormone

Parathyroid hormone (PTH) is produced by the **parathyroid** glands in response to decreased circulating calcium levels.

Maintaining Homeostasis

Homeostasis requires that volume and **osmolarity** be preserved. Blood volume is important in maintaining sufficient blood pressure, and there are **nonrenal** mechanisms involved in its preservation, including vasoconstriction, which can act within seconds of a drop in pressure. Thirst mechanisms are also activated to promote the consumption of water lost through respiration, evaporation, or urination. Hormonal mechanisms are activated to recover volume while maintaining a normal osmotic environment. These mechanisms act principally on the kidney.

Diuretics and Fluid Volume

A diuretic is a compound that increases urine volume. Three familiar drinks contain diuretic compounds: coffee, tea, and alcohol. The caffeine in coffee and tea works by promoting vasodilation in the nephron, which increases GFR. Alcohol increases GFR by inhibiting ADH release from the posterior pituitary, resulting in less water recovery by the collecting duct. In cases of high blood pressure, diuretics may be prescribed to reduce blood volume and, thereby, reduce blood pressure. The most frequently prescribed anti-hypertensive diuretic is **hydrochlorothiazide.**

Regulation of Nitrogen Wastes

Nitrogen wastes are produced by the breakdown of proteins during normal **metabolism**. Proteins are broken down into amino acids, which in turn are deaminated by having their nitrogen groups removed. Deamination converts the amino (NH2) groups into ammonia (NH3), ammonium ion (NH4+), urea, or uric acid (Figure 15.9). Ammonia is extremely toxic, so most of it is very rapidly converted into urea in the liver. Human urinary wastes typically contain primarily urea with small amounts of ammonium and very little uric acid.

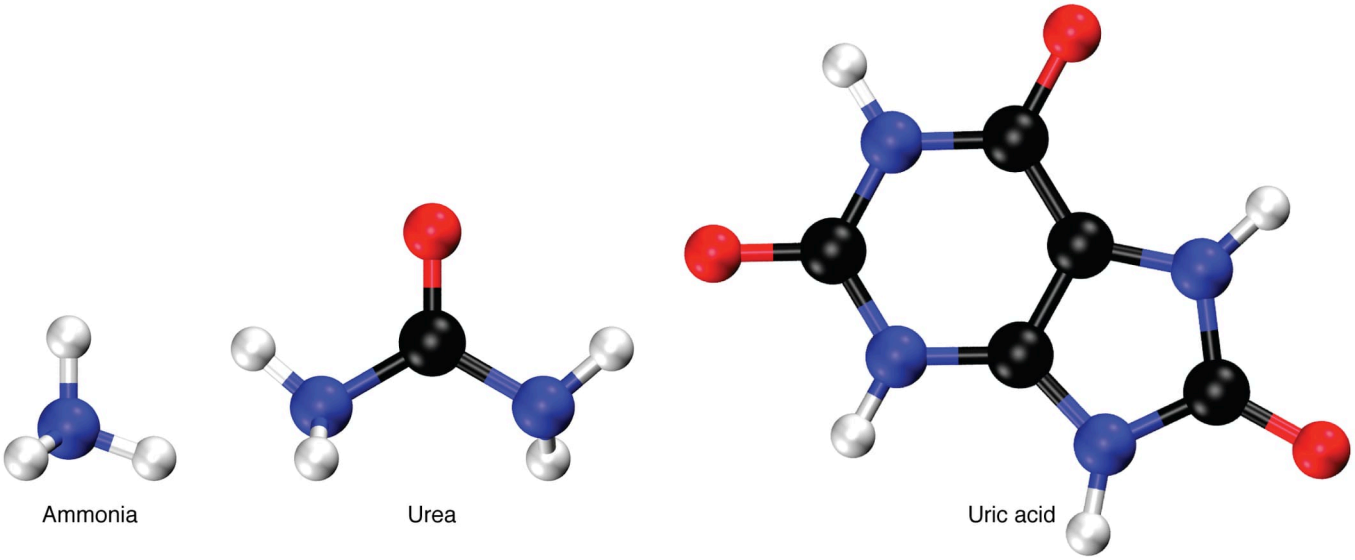

Figure 15.9 Nitrogen Wastes. From Betts et al., 2013. Licensed under CC BY 4.0. [Image description.]

Elimination of Drugs and Hormones

Water-soluble drugs may be excreted in the urine and are influenced by one or all of the following processes: glomerular filtration, tubular secretion, or tubular reabsorption. Drugs that are structurally small can be filtered by the glomerulus with the filtrate. Large drug molecules such as **heparin** or those that are bound to plasma proteins cannot be filtered and are not readily eliminated. Some drugs can be eliminated by carrier proteins that enable secretion of the drug into the tubule lumen. There are specific carriers that eliminate basic (such as dopamine or histamine) or acidic drugs (such as penicillin or indomethacin). As is the case with other substances, drugs may be both filtered and reabsorbed passively along a concentration gradient.

Watch this video:

YouTube Video

This interactive element is not available in this format. Visit the link or scan the QR code to access it online.

View this YouTube Video online

Media 15.2. Urinary System, Part 2: Crash Course A&P #39 [Online video]. Copyright 2015 by CrashCourse.

Practice Terms Related to the Urinary System

Query 1.15.4

This interactive element is not available in this format. Visit the link or scan the QR code to access it online.

View this Interactive Content online

Common Abbreviations for the Urinary System

Many terms and phrases related to the urinary system are abbreviated. Learn these common abbreviations by expanding the list below.

Query 1.15.5

This interactive element is not available in this format. Visit the link or scan the QR code to access it online.

View this Interactive Content online

Diseases and Disorders of the Urinary System

Diabetic Nephropathy

Diabetic nephropathy impacts the kidneys as a result of having diabetes mellitus type 1 or 2. Higher levels of blood sugar can lead to high blood pressure and this additional pressure exerted on the kidneys causes destruction of the small filtering structures within the kidney (Varghese & Jialal, 2021). To learn more, visit the Mayo Clinic's web page on diabetic nephropathy.

Glomerulonephritis

Glomerulonephritis refers to acute or chronic nephritis that involves inflammation of the capillaries of the renal glomeruli. It is characterized by blood or protein in the urine and edema. If untreated, it could lead to kidney failure. Glomerulonephritis may be caused by a variety of infections and immune conditions, as a result of genetic defects, or by unknown causes (Genetic and Rare Diseases Information Center, 2012). For more information, visit the Genetic and Rare Diseases Information Center's web page

on glomerulonephritis.

Hydronephrosis

Hydronephrosis is a condition whereby the kidneys begin to swell because of the retention of urine. Several conditions can cause hydronephrosis, such as a kidney stone or pregnancy. Treatment will vary, depending on the cause (Thotakura & Anjum, 2021). To learn more, visit the Cleveland Clinic's web page on hydronephrosis.

Polycystic Kidney Disease

Polycystic kidney disease (PKD) is a genetic disorder whereby cysts grow inside the kidneys. The kidneys enlarge from the cystic collections, and damage to the filtering structures of the kidneys can occur. As the disease progresses, it may lead to kidney failure (National Institute of Diabetes and Digestive and Kidney Diseases, n.d.-a). To learn more, visit the National Institute of Diabetes and Digestive and Kidney Diseases' web page on polycystic kidney disease.

Renal Cell Carcinoma

Renal cell carcinoma is a cancer occurring in the kidney tubes where urine is produced or collected. Signs and symptoms may include blood in the urine and the presence of a lump in the abdomen. Risk factors include smoking and the long-term misuse of pain medicine (National Cancer Institute, 2020). For more information, visit the National Cancer Institute's web page on renal cell carcinoma.

Renal Failure

Renal failure occurs when kidneys become unable to filter waste products from blood. When kidneys stop filtering, high levels of waste may build. Renal failure may be acute (sudden onset) or chronic (gradual onset) (Bindroo et al., 2021). For more information, visit the Cleveland Clinic's web page on renal failure.

Cystitis

Cystitis is inflammation of the urinary bladder, often caused by an infection. A chronic form of this condition is known as interstitial cystitis. Signs and symptoms of cystitis include bladder pressure, voiding frequently, and abdominal pain (Centers for Disease Control and Prevention, n.d.; Li & Leslie, 2021). To learn more, visit the Mayo Clinic's web page on cystitis.

Urinary Tract Infection

A urinary tract infection (UTI) is an infection caused by bacteria. The exact type of bacterial growth is determined by conducting a urine culture. Signs and symptoms include a burning sensation during urination and voiding frequently (National Institute of Diabetes and Digestive and Kidney Diseases, n.d.-b). For more information, visit the National Institute of Diabetes and Digestive and Kidney Diseases' web page on urinary tract infections.

Urinary Incontinence

Urinary incontinence is a loss of bladder control. Those afflicted with the condition will experience urine leakage from the bladder. Urinary incontinence may be related to another health issue, such as prostate problems, or it may be the result of weakened urinary tract muscles (National Institute of Diabetes and Digestive and Kidney Diseases, n.d.-c). For more information, visit the National Institute of Diabetes and Digestive and Kidney Diseases' web page on bladder incontinence.

Medical Terms in Context

Query 1.15.6

This interactive element is not available in this format. Visit the link or scan the QR code to access it online.

View this Interactive Content online

Query 1.15.7

This interactive element is not available in this format. Visit the link or scan the QR code to access it online.

View this Interactive Content online

Medical Specialties and Procedures Related to the Urinary System

Urology is a specialty that focuses on the diagnosis, treatment, and surgical repair of the urinary tract. To learn more about urology as a specialty, visit the American College of Surgeons' web page.

Urologist

A urologist is a medical specialist involved in the diagnosis and treatment of urinary and male genitourinary system conditions, disorders, and diseases (National Cancer Institute, n.d.-a). To learn more about what urologists do and how to become one, visit the Cleveland Clinic's web page about the specialty.

Procedures and Testing

Urinalysis

A urinalysis is the physical, chemical, and microscopic examination of urine. This test detects and measures several substances in the urine such as products of normal and abnormal metabolism and bacteria (Queremel Milani & Jialal, 2021). To learn more, visit the Mayo Clinic's web page on urinalysis.

Urine Culture and Sensitivity

A urine culture is a test that can detect and identify bacteria in the urine, which may be causing a urinary tract infection (UTI). If harmful bacteria is found, a sensitivity report is generated. A sensitivity test indicates which antibiotics will be effective in treating the infection (Sinawe & Casadesus, 2021; MedlinePlus, 2021). For more information, visit MedlinePlus' web page on urine cultures.

24-Hour Urinalysis

A 24-hour urinalysis is a test whereby all urinary output is collected over a 24-hour period of time. The analysis of urinary output over this extended period of time provides a greater indication of normal or abnormal kidney function (Corder et al., 2021). For more information, visit Johns Hopkins Medicine's web page on 24-hour urine collection.

CT Scan of Kidney

Computed tomography is a diagnostic imaging procedure that uses a combination of x-rays and computer technology to produce a variety of images (National Cancer Institute, n.d.-b). It provides detailed images of the kidney so that healthcare professionals can diagnose disease, obstructions, and other kidney conditions. To learn more, visit Johns Hopkins Medicine's page on computed tomography scan of the kidney.

Cystoscopy

A cystoscopy is a procedure allowing a physician to view the bladder and urethra. The procedure involves the use of a cystoscope, a long tube-like instrument that has a camera and light at the end. The camera's images are transmitted to a computer, where the urologist can determine whether the patient has bladder stones, cancer, or other urinary tract problems (National Institute of Diabetes and Digestive and Kidney Diseases, n.d.-d). For more information, view the National Institute of Diabetes and Digestive and Kidney Diseases' web page on cystoscopy.

Dialysis

Dialysis is a treatment that removes waste products from the blood when the kidneys are not fully functioning. This type of therapy is available at home, in a hospital, or clinic. There are two main types: peritoneal dialysis and hemodialysis (National Institute of Diabetes and Digestive and Kidney Diseases, n.d.-e). To learn more, visit the National Institute of Diabetes and Digestive and Kidney Diseases' web page on kidney failure treatment options.

Intravenous Pyelogram

An intravenous pyelogram (IVP) is a specialized x-ray designed to produce views of the entire urinary tract. Contrast dye is used to produce clear x-ray images. The x-rays can show how well the urinary tract is functioning and identify any blockages (MedlinePlus, 2020). For more information, visit MedlinePlus' web page on intravenous pyelogram.

Kidney Scan

A kidney scan is an imaging test which views the kidneys. It is considered a nuclear imaging test as it uses radioactive tracers to evaluate kidney function. A kidney scan may be performed if the patient is allergic to the contrast material used with CT or MRI tests (Banker et al., 2021). For more information, visit MedlinePlus' web page on renal scans.

Kidney Transplant

When a patient experiences kidney failure, a healthy kidney can be surgically transplanted from a donor to the patient. The donor may be living or recently deceased. Patients may have to wait for many years before a kidney is available and may have to go on dialysis in the meantime (National Institute of Diabetes and Digestive and Kidney Diseases, n.d.-f). For more information, visit the National Institute of Diabetes and Digestive and Kidney Diseases' web page on kidney transplant.

Urinary System Vocabulary

Adventitial: The outermost layer of organs, blood vessels, and other structures in the body.

Albuminuria: Albumin in the urine.

Anuria: The absence of urine production.

Autonomic: Involuntary or unconscious.

Azotemia: Urea in the blood.

Cystectomy: Excision of all or part of the bladder to remove a cyst.

Cystitis: Inflammation of the lining of the bladder.

Cystocele: A condition in which weakened pelvic muscles cause the bladder from its normal position.

Cystography: Radiographic imaging of the bladder.

Cystoscope: A thin, tube-like instrument used to look inside the bladder and urethra.

Cystoscopy: Examination of the bladder and urethra using a cystoscope, inserted into the urethra.

Cystostomy: Creation of an artificial opening into the bladder.

Cystotomy: Incision into the bladder.

Deamination: The removal of an amino group from a molecule.

Detrusor: A muscle which forms a layer of the wall of the bladder.

Diuresis: Excess production of urine.

Dysuria: Painful urination.

Enuresis: Involuntary urination.

Excretion: To get rid of waste material from the blood, tissues, or organs by a normal discharge (such as sweat, urine, or stool).

Glomerulonephritis: A condition in which the tissues in the kidney become inflamed and have problems filtering waste from the blood.

Glycosuria: Presence of glucose in the urine.

Hematuria: Blood in the urine.

Homeostasis: The state of steady internal conditions maintained by living things.

Hydronephrosis: Abnormal enlargement of a kidney, which may be caused by blockage of the ureter (such as by a kidney stone) or chronic kidney disease that prevents urine from draining into the bladder.

Hydrostatic: Relating to the equilibrium of liquids and the pressure exerted by liquid at rest.

Hypothalamus: A region of the forebrain below the thalamus; has function in both the autonomic and endocrine systems and regulates homeostasis.

Incontinence: Loss of ability to control micturition (urination).

Lethargy: A condition marked by drowsiness and an unusual lack of energy and mental alertness.

Micturition: Also called urination or voiding.

Lithotripsy: The destruction of a calculus (stone) of the kidney, ureter, bladder, or gallbladder by physical forces.

Mitochondria: A membranous, bean-shaped organelle that is the “energy transformer” of the cell.

Nephrectomy: Excision of all or part of the kidney.

Nephritis: A condition in which the tissues in the kidney become inflamed and have problems filtering waste from the blood.

Nephrolithiasis: Formation of stone(s) in the kidney.

Nephrolithotomy: Incision into the kidney to remove stone(s).

Nephrologist: A doctor who has special training in diagnosing and treating kidney disease.

Nephrology: A subspecialty of internal medicine concerned with the anatomy, physiology, and pathology of the kidney.

Nephrostomy: Surgery to make an opening from the outside of the body to the renal pelvis.

Nocturia: Frequent urination at night that interrupts sleep.

Oliguria: Below normal urine production of 400–500 mL/day.

Osmosis: A process by which molecules of a solvent tend to pass through a membrane from a less concentrated solution into a more concentrated one.

pH: A measure of how acidic or alkaline a substance is, as determined by the number of free hydrogen ions in the substance.

Polyuria: Excessive urine production.

Prostaglandins: Signaling molecules derived from unsaturated fatty acids with hormone-like effects.

Pseudostratified: Tissue with a single layer of irregularly shaped cells that give the appearance of more than one layer.

Pyelitis: Inflammation of the renal pelvis and kidney calices.

Pyelonephritis: Inflammation of the nephrons, renal pelvis, and kidney calices.

Pyuria: The presence of white blood cells in the urine.

Solutes: The minor component in a solution.

Stricture: Abnormal narrowing.

Ureterocele: A cystic dilatation of the end of a ureter.

Ureterolithiasis: Formation of stone(s) in the ureter.

Ureteroscopy: Examination of the inside of the kidney and ureter, using a ureteroscope.

Ureterostomy: Creation of an artificial opening into the ureter.

Urinal: Receptacle used for the collection of urine.

Urinary: Pertaining to urine or the organs of the body that produce and get rid of urine.

Urologist: A doctor who has special training in diagnosing and treating diseases of the urinary organs in females and the urinary and reproductive organs in males.

Urology: A surgical specialty concerned with the study, diagnosis, and treatment of diseases of the urinary tract in both sexes, and the genital tract in the male.

Voiding: Also known as urination or micturition.

Test Yourself

Query 1.15.8

This interactive element is not available in this format. Visit the link or scan the QR code to access it online.

View this Interactive Content online

References

Banker, H., Sheffield, E. G., & Cohen, H. L. (2021). Nuclear renal scan. In *StatPearls [Internet]*. https://www.ncbi.nlm.nih.gov/books/NBK562236/

Bindroo, S., Quintanilla Rodriguez, B.S., & Challa, H. J. (2021). Renal failure. In *StatPearls [Internet]*. https://www.ncbi.nlm.nih.gov/books/NBK519012/

Centers for Disease Control and Prevention. (n.d.). *Interstitial cystitis*. https://www.cdc.gov/ic/index.html

Corder, C. J., Rathi, B. M., Sharif, S., & Leslie, S. W. (2021). 24-hour urine collection. In *StatPearls [Internet]*. https://www.ncbi.nlm.nih.gov/books/NBK482482/

[CrashCourse]. (2015, October 12). *Urinary system, part 1: Crash course A&P #38* [Video]. YouTube. https://www.youtube.com/watch?v=l128tW1H5a8

CrashCourse. (2015, June 22). *Urinary system, part 2: Crash course A&P #39* [Video]. YouTube. https://youtu.be/DlqyyyvTI3k

Genetic and Rare Diseases Information Center. (2012). *Glomerulonephritis*. National Institutes of Health, U.S. Department of Health and Human Services. https://rarediseases.info.nih.gov/diseases/6516/glomerulonephritis

Li, R., & Leslie, S. W. (2021). Cystitis. In *StatPearls [Internet]*. https://www.ncbi.nlm.nih.gov/books/NBK482435/

MedlinePlus. (2021). *Antibiotic sensitivity test*. U.S. National Library of Medicine. https://medlineplus.gov/lab-tests/antibiotic-sensitivity-test/

MedlinePlus. (2020). *Intravenous pyelogram*. U.S. National Library of Medicine. https://medlineplus.gov/lab-tests/intravenous-pyelogram-ivp/

National Cancer Institute. (n.d.-a). *Definition of urologist*. National Institutes of Health, U.S. Department of Health and Human Services. https://www.cancer.gov/publications/dictionaries/cancer-terms/def/urologist

National Cancer Institute. (n.d.-b). *Computed tomography (CT) scans and cancer*. National Institutes of Health, U.S. Department of Health and Human Services. https://www.cancer.gov/about-cancer/diagnosis-staging/ct-scans-fact-sheet

National Cancer Institute. (2020). *Renal cell cancer treatment (PDQ®) – Patient version*. National Institutes of Health, U.S. Department of Health and Human Services. https://www.cancer.gov/types/kidney/patient/kidney-treatment-pdq

National Institute of Diabetes and Digestive and Kidney Diseases. (n.d.-a). *Polycystic kidney disease?* National Institutes of Health, U.S. Department of Health and Human Services. https://www.niddk.nih.gov/health-information/kidney-disease/polycystic-kidney-disease/all-content

National Institute of Diabetes and Digestive and Kidney Diseases. (n.d.-b). *Bladder infection (urinary tract infection) in adults*. National Institutes of Health, U.S. Department of Health and Human Services. https://www.niddk.nih.gov/health-information/urologic-diseases/bladder-infection-uti-in-adults/all-content

National Institute of Diabetes and Digestive and Kidney Diseases. (n.d.-c). *Urinary incontinence*. National Institutes of Health, U.S. Department of Health and Human Services. https://www.niddk.nih.gov/health-information/urologic-diseases/bladder-control-problems/all-content

National Institute of Diabetes and Digestive and Kidney Diseases. (n.d.-d). *Cystoscopy & ureteroscopy*. National Institutes of Health, U.S. Department of Health and Human Services. https://www.niddk.nih.gov/health-information/diagnostic-tests/cystoscopy-ureteroscopy

National Institute of Diabetes and Digestive and Kidney Diseases. (n.d.-e). *Choosing a treatment for kidney failure*. National Institutes of Health, U.S. Department of Health and Human Services. https://www.niddk.nih.gov/health-information/kidney-disease/kidney-failure/choosing-treatment

National Institute of Diabetes and Digestive and Kidney Diseases. (n.d.-f). *Kidney transplant*. National Institutes of Health, U.S. Department of Health and Human Services. https://www.niddk.nih.gov/health-information/kidney-disease/kidney-failure/kidney-transplant

Queremel Milani, D. A., & Jialal, I. (2021). Urinalysis. In *StatPearls [Internet]*. https://www.ncbi.nlm.nih.gov/books/NBK557685/

Sinawe, H., Casadesus, D. (2021). Urine culture. In *StatPearls [Internet]*. https://www.ncbi.nlm.nih.gov/books/NBK557569/

Thotakura, R., & Anjum, F. (2021). Hydronephrosis and hydroureter. In *StatPearls [Internet]*. https://www.ncbi.nlm.nih.gov/books/NBK563217/

Varghese, R. T., & Jialal, I. (2021). Diabetic nephropathy. In *StatPearls [Internet]*. https://www.ncbi.nlm.nih.gov/books/NBK534200/

Image Descriptions

Figure 15.1 image description: Diagram of a human torso showing the location of the kidneys within the torso. Callouts identify the liver, kidney, ureter, and 12th rib. [Return to Figure 15.1].

Figure 15.2 image description: The left panel of this figure shows the location of the kidneys in the abdomen. The right panel shows the cross-section of the kidney. [Return to Figure 15.2].

Figure 15.3 image description: This figure shows the network of blood vessels and the blood flow in the kidneys. Callouts identify the process as follows: renal artery, segmental artery, interlobar artery, arcuate artery, interlobular artery, afferent arteriole, glomerulus, efferent arteriole, peritubular capillaries, interlobular vein, arcuate vein, interlobar vein, and renal vein. [Return to Figure 15.3].

Figure 15.4 image description: This image shows the blood vessels and the direction of blood flow in the nephron. Callouts identify the process as involving the following structures: interlobular artery, afferent arteriole, efferent arteriole, glomerular capsule, proximal convoluted tubule, venule, interlobular vein, loop of the nephron, and peritubular capillary network. Urine then flows into the renal papilla. [Return to Figure 15.4].

Figure 15.5 image description: The left panel of this figure shows the cross-section of the bladder and the major parts are labeled. The right panel shows a micrograph of the bladder. [Return to Figure 15.5].

Figure 15.6 image description: Diagrams of the (a) female and (b) male genitalia highlighting the respective urethras. [Return to Figure 15.6].

Figure 15.7 image description: This figure shows the different pressures acting across the glomerulus including blood hydrostatic pressure, blood colloid osmotic pressure, capsular hydrostatic pressure. [Return to Figure 15.7].

Figure 15.8 image description: This color chart shows 8 different shades of yellow and associates each shade with stages of hydration (lightest 3 shades) or dehydration (remaining 5 darker shades). [Return to Figure 15.8].

Figure 15.9 image description: This figure shows the chemical structure of ammonia, urea, and uric acid. [Return to Figure 15.9].

Unless otherwise indicated, this chapter contains material adapted from *Anatomy and Physiology* (on OpenStax), by Betts et

al. and is used under a CC BY 4.0 international license. Download and access this book for free at https://openstax.org/books/anatomy-and-physiology/pages/1-introduction.

This page titled 1.15: Urinary System is shared under a CC BY 4.0 license and was authored, remixed, and/or curated by Andrea Nelson and Katherine Greene via source content that was edited to the style and standards of the LibreTexts platform.

1.16: Male Reproductive System

Learning Objectives

- Examine the anatomy of the male reproductive system
- Determine the main functions of the male reproductive system
- Differentiate male reproductive system medical terms and common abbreviations
- Recognize the medical specialties associated with the male reproductive system
- Discover common diseases, disorders, and procedures related to the male reproductive system

Male Reproductive System Word Parts

Click on prefixes, combining forms, and suffixes to reveal a list of word parts to memorize for the Male Reproductive System.

Query 1.16.1

This interactive element is not available in this format. Visit the link or scan the QR code to access it online.

View this Interactive Content online

Introduction to the Male Reproductive System

Gametes are the reproductive cells that combine to form a fetus. Organs called gonads produce the gametes, along with the hormones that regulate human reproduction. The male gametes are called sperm. Spermatogenesis occurs within the seminiferous tubules that make up most of the testis. The scrotum is a sac that holds the testes outside of the body cavity.

Watch this video:

YouTube Video

This interactive element is not available in this format. Visit the link or scan the QR code to access it online.

View this YouTube Video online

Media 16.1. Reproductive System, Part 2 – Male Reproductive System: Crash Course A&P 41 [Online video]. Copyright 2015 by CrashCourse.

Practice Medical Terms Related to the Male Reproductive System

Query 1.16.2

This interactive element is not available in this format. Visit the link or scan the QR code to access it online.

View this Interactive Content online

Anatomy (Structures) of the Male Reproductive System

The structures of the male reproductive system include the testes, the epididymis, the penis, and the ducts and glands that produce and carry semen. Sperm exit the scrotum through the vas deferens. The spermatic cord is an enclosed sheath which includes the vas deferens, arteries, veins and nerves. The seminal vesicles and prostate add fluids to the sperm to create semen.

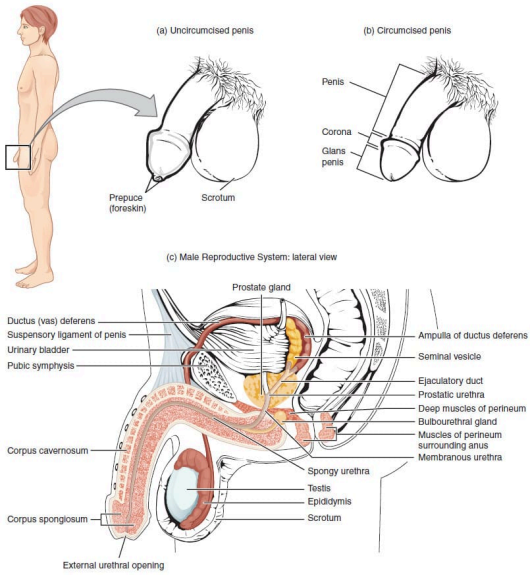

Figure 16.1. Male Reproductive System. From Betts et al., 2013. Licensed under CC BY 4.0. [Image description.]

Physiology (Function) of the Male Reproductive System

Spermatogenesis

Spermatogenesis occurs in the **seminiferous tubules** that form the bulk of each testis. The process begins at puberty, after which time sperm is produced constantly throughout a man's life. One production cycle takes approximately 64 days. One production cycle is considered from spermatogonia through to formed sperm. A new cycle starts approximately every 16 days, although this timing is not synchronous across the seminiferous tubules.

Sperm

Sperm is smaller than most cells in the body; in fact, the volume of a sperm cell is 85,000 times less than that of the female gamete. Approximately 100 to 300 million sperm are produced each day, whereas women typically ovulate only one oocyte per month as is true for most cells in the body, the structure of sperm cells speaks to their function. Sperm have a distinctive head, mid-piece, and tail region (see Figure 16.2).

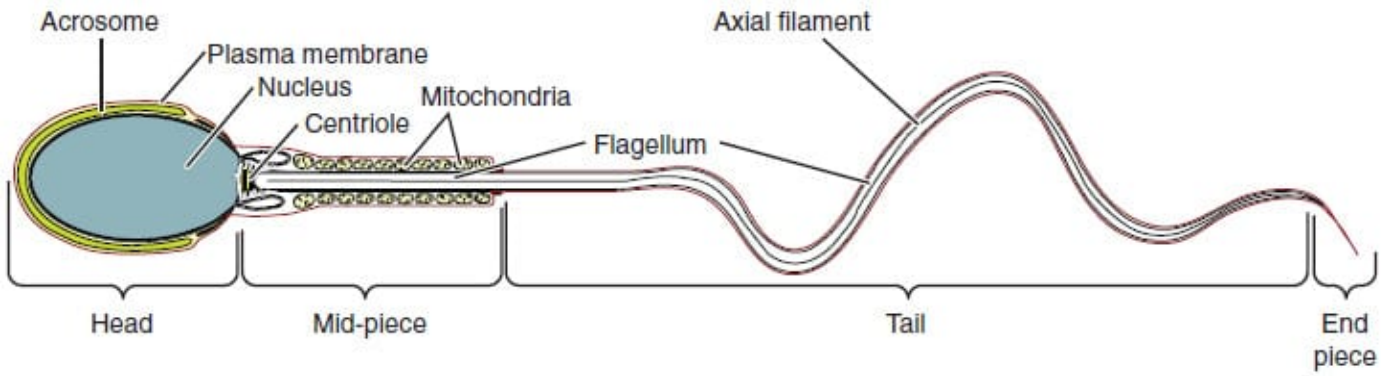

Figure 16.2. Structure of Sperm. Sperm cells are divided into a head, containing DNA; a mid-piece, containing mitochondria; and a tail, providing motility. The acrosome is oval and somewhat flattened. From Betts et al., 2013. Licensed under CC BY 4.0. [Image description.]

Sperm Transport

To fertilize an egg, sperm must be moved from the **seminiferous tubules** in the testes, through the **epididymis**, and—later during ejaculation—along the length of the penis and out into the female reproductive tract. It takes an average of 12 days for sperm to move through the coils of the epididymis, with the shortest recorded transit time in humans being one day.

> **Did you know?**
>
> Sperm counts slowly decline after age 35, and some studies suggest that smoking can lower sperm counts irrespective of age.

Epididymis

Sperm enter the head of the epididymis and are moved by the contraction of smooth muscles lining the epididymal tubes. As the sperm mature they acquire the ability to move under their own power. Once inside the female reproductive tract, they will use this ability to move independently toward the unfertilized egg. The more mature sperm are then stored in the tail of the epididymis until ejaculation occurs.

Ducts

During ejaculation, sperm exit the tail of the epididymis and are pushed by smooth muscle contraction to the **vas deferens** (also called the ductus deferens). The vas deferens is a thick, muscular tube that is bundled together inside the scrotum with connective tissue, blood vessels, and nerves into a structure called the **spermatic cord.** From each epididymis, each vas deferens extends through the inguinal canal in the abdominal wall and continues to a region called the ampulla. The sperm is mixed with fluid from the paired seminal vesicles and moves into its associated ejaculatory duct. The ejaculatory ducts transport the seminal fluid to the prostate gland.

Prostate Gland

The prostate gland secretes an alkaline, milky fluid to the passing seminal fluid (referred to as semen) to first coagulate and then decoagulate the semen following ejaculation. The temporary thickening of semen helps retain it within the female reproductive tract. Once decoagulated, the sperm can pass farther into the female reproductive tract.

Bulbourethral Glands

Bulbourethral glands release a thick, salty fluid that lubricates the end of the urethra and vagina, and helps to clean urine residues from the penile urethra.

Concept Check

- Write or draw out the components of the **pathway** that sperm takes from the beginning until the end.
- Consider fertility challenges that may be experienced if a large number of defective sperm are produced.

Anatomy Labeling Activity

Query 1.16.3

This interactive element is not available in this format. Visit the link or scan the QR code to access it online.

View this Interactive Content online

Practice Terms Related to the Male Reproductive System

Query 1.16.4

This interactive element is not available in this format. Visit the link or scan the QR code to access it online.

View this Interactive Content online

Common Abbreviations for the Male Reproductive System

Many terms and phrases related to the male reproductive system are abbreviated. Learn these common abbreviations by expanding the list below.

Query 1.16.5

This interactive element is not available in this format. Visit the link or scan the QR code to access it online.

View this Interactive Content online

Diseases and Disorders of the Male Reproductive System

Erectile Dysfunction Disorder (EDD)

Erectile dysfunction (ED) is a condition in which a male has difficulty either initiating or maintaining an erection. The combined prevalence of minimal, moderate, and complete ED is approximately 40% in men at age 40 and reaches nearly 70% by 70 years

of age. In addition to aging, ED is associated with diabetes, vascular disease, psychiatric disorders, prostate disorders, the use of some drugs such as certain antidepressants, and problems with the testes resulting in low testosterone concentrations. These physical and emotional conditions can lead to disruptions in the vasodilation pathway and result in an inability to achieve an erection.

Cancer

Prostate Cancer

According to the Centers for Disease Control and Prevention (CDC), prostate cancer is the second most common cancer occurring in men. However, some forms of prostate cancer grow very slowly and may not require treatment. Aggressive forms of prostate cancer, in contrast, involve metastasis to organs like the lungs and brain. There is no link between Benign Prostatic Hyperplasia (BPH) and prostate cancer, but the symptoms are similar. Prostate cancer is detected by medical history, a blood test, and a digital rectal exam that allows physicians to palpate the prostate and check for unusual masses. If a mass is detected, the cancer diagnosis is confirmed by biopsy of the cells (Betts et al., 2013; Centers for Disease Control, n.d-a.).

Testicular Cancer

Testicular cancer begins in the testicle or testis. It is most often found in men aged 20 to 35 years old, although it can occur at any age. Common signs and symptoms include a painless lump in the testicle, swelling, and a build-up of fluid in the scrotum. Testicular cancer is treatable when diagnosed early. An orchiectomy may be required for diagnosing and treating testicular cancer (National Cancer Institute, 2021a). For more information, visit the Cleveland Clinic's web page on testicular cancer.

> **Did you know?**
>
> Family history is a common risk factor for testicular cancer.

Sexually Transmitted Infections and Diseases (STIs and STDs)

Although the terms sexually transmitted infections (STI) and sexually transmitted diseases (STD) are often used interchangeably, they have distinct meanings. STIs refer to infections caused by a virus, bacteria, fungus, or parasite via sexual contact. STDs refer to the disease state that develops as a result of infection (U.S. Department of Health and Human Services, 2020).

Chlamydia

Chlamydia is one of the most common sexually transmitted diseases. It is caused by the bacteria *Chlamydia trachomatis*, which infects the urethra and prostate in men. Chlamydia spreads through unprotected oral, anal, or vaginal sex with an infected person. Many people with chlamydia do not have any symptoms and unknowingly pass the infection to their sexual partner(s). If symptoms develop, they may not appear for several weeks after sexual contact with an infected person. Males may have penile discharge, itching around the urethra, and pain in or swelling of the testicles. Chlamydia is easy to treat with antibiotics and can be cured. However, until a patient finishes their treatment, they continue to have the infection and can continue to pass it to others (Centers for Disease Control and Prevention, n.d.-b).

Gonorrhea (Gonococcus)

Gonorrhea is a sexually transmitted disease caused by the bacterium *Neisseria gonorrhoeae*. It infects the mucous membranes of the reproductive tract, including the urethra in men. Infections can also infect the mouth, throat, eyes, and anus. Gonorrhea is spread through unprotected oral, vaginal or anal sex with an infected person. Many people infected with gonorrhea have no symptoms and can unknowingly pass the infection on to their sexual partner(s). Symptoms vary depending on which part of the body is infected. Males may have yellowish-white discharge from the penis or dysuria. Gonorrhea infection from oral sex may lead to a sore throat, whereas infection from anal sex may cause itchiness and discharge from the anus. Gonorrhea can be treated and cured with antibiotics in combination with an intramuscular (IM) injection. However, until the patient finishes their treatment,

they continue to have the infection and can pass it to others (Centers for Disease Control and Prevention, n.d.-c).

Notifiable and Reportable Diseases

In every state in the United States, chlamydia and gonorrhea are notifiable and reportable diseases. This means that when a person tests positive for either of the STIs, public health departments and the CDC are informed so that they may monitor trends, identify outbreaks, and take the necessary steps to prevent further spread of the disease (Centers for Disease Control and Prevention, n.d.-d, n.d.-e).

Human Papillomavirus (HPV)

Human papillomavirus (HPV) is another common STI. Both males and females can be infected with HPV. There are over 200 strains of HPV. Some strains can cause visible genital warts, while others cause genital, anal, throat, and cervical cancers. HPV spreads through sexual activity and skin-to-skin contact in the genital area with an infected person. Since some people are asymptomatic, they don't know they have the virus and consequently pass the virus to their sexual partners. Treatments are available for genital warts, but there is no cure for HPV. However, in the United States, a vaccine called Gardasil® 9 is available, which prevents infection with HPV (MedlinePlus, 2021; National Cancer Institute, 2021b). For more information, visit the Centers for Disease Control and Prevention's web page on HPV.

Herpes Simplex Virus (HSV)

Genital herpes is a sexually transmitted disease that is caused by a virus called the herpes simplex virus (HSV). There are two types of herpes simplex viruses:

- Type 1- oral herpes or cold sores (HSV-1)
- Type 2- genital herpes (HSV-2)

Signs and symptoms might include dysuria, enlarged glands, myalgia, and fever. Once a patient is infected with HSV, the virus remains in their body even after the symptoms are gone and can cause recurring outbreaks. When the virus becomes active again, the symptoms return but are usually less painful and heal faster (Centers for Disease Control and Prevention, n.d.-f).

Herpes is spread through direct contact with the sores or blisters of an infected person. Contact (and transfer of the virus) can occur from genitals-to-genitals, mouth-to-genitals, or mouth-to-mouth. Herpes can also be passed to the anal area. Herpes spreads easily during sexual contact while symptoms are present or just before an outbreak of symptoms. An infected person may spread herpes even when they have no symptoms; this is called asymptomatic shedding. One can spread the herpes virus to other parts of their body after touching the sores. The fingers, eyes, and other body areas can accidentally become infected in this way. Hand washing after touching sores and blisters is recommended to prevent spreading the virus (Centers for Disease Control and Prevention, n.d.-f).

There is no cure for herpes. Antiviral pills help to reduce symptoms and speed the healing of blisters or sores and are prescribed by a doctor. All sexual partner(s) should be informed. The only way to reduce the risk of transmission of herpes is to avoid direct contact with the sores and to use condoms. Condoms will reduce but not eliminate risk, as the virus can be present and shed from the skin in the genital area (Centers for Disease Control and Prevention, n.d.-f).

Common Abbreviations for Reproductive Sexually Transmitted Infections (STIs)

Query 1.16.6

This interactive element is not available in this format. Visit the link or scan the QR code to access it online.

View this Interactive Content online

Medical Terms in Context

Query 1.16.7

This interactive element is not available in this format. Visit the link or scan the QR code to access it online.

View this Interactive Content online

Medical Specialties and Procedures Related to the Male Reproductive System

Urology

Urology is a specialty that focuses on the diagnosis, treatment, and surgical repair of the urinary tract. To learn more about urology as a specialty, visit the American College of Surgeons' web page.

Vasectomy

A vasectomy is a procedure in which a small section of the ductus (vas) deferens is removed from the scrotum. This cuts off the path taken by sperm through the ductus deferens. Although it can be reversed, clinicians consider it permanent and advise men to undergo it only if they are certain that they no longer wish to father children. For more information, view this video from MedlinePlus on vasectomies.

Male Reproductive Vocabulary

Ablation: The removal or destruction of a body part or tissue or its function. Ablation may be performed by surgery, hormones, drugs, radiofrequency, heat, or other methods.

Arthralgia: Joint pain.

Aspermia: Condition of the complete absence of sperm.

Balanitis: Inflammation of the glans penis.

Benign prostatic hyperplasia (BPH): A benign condition in which an overgrowth of prostate tissue pushes against the urethra

and the bladder, blocking the flow of urine.

Bulbourethral glands: Glands that secrete a lubricating mucus that cleans and lubricates the urethra prior to and during ejaculation; also called Cowper's glands.

Circumcision: The surgical removal of the prepuce.

Coitus: Sexual intercourse between a male and female.

Condom: A sheath that is worn over the penis during sexual behavior in order to prevent pregnancy or spread of sexually transmitted disease.

Corpus cavernosum: Either of two columns of erectile tissue in the penis that fill with blood during an erection.

Corpus spongiosum: Column of erectile tissue in the penis that fills with blood during an erection and surrounds the penile urethra on the ventral portion of the penis.

Cryptorchidism: The failure of one or both testes to descend into the scrotum prior to birth.

Ductus deferens: Duct that transports sperm from the epididymis through the spermatic cord and into the ejaculatory duct; also referred to as the vas deferens.

Dysuria: Painful urination.

Ejaculatory duct: Duct that connects the ampulla of the ductus deferens with the duct of the seminal vesicle at the prostatic urethra.

Enucleation: Excision of a whole organ or mass without cutting into it.

Epididymis: A coiled tubular structure in which sperm start to mature and are stored until ejaculation.

Epididymitis: Inflammation of the epididymis.

Gamete: A specialized sex cell carrying 23 chromosomes.

Glans penis: Bulbous end of the penis that contains a large number of nerve endings.

Gonadotropin-releasing hormone (GnRH): Hormone released by the hypothalamus that regulates the production of follicle-stimulating hormone and luteinizing hormone from the pituitary gland.

Gonads: Reproductive organs (testes in men and ovaries in women) that produce gametes and reproductive hormones.

Hydrocele: Accumulation of serous fluid between the layers of membrane covering the testis.

Infertility: The inability to produce children.

Inguinal canal: Opening in the abdominal wall that connects the testes to the abdominal cavity.

Leydig cells: Cells between the seminiferous tubules of the testes that produce testosterone; a type of interstitial cell.

Myalgia: Pain in a muscle or group of muscles.

Oligospermia: Condition of a suboptimal concentration of spermatozoa in the ejaculated semen to ensure successful fertilization of an ovum.

Orchidectomy: Surgery to remove one or both testicles; also called orchiectomy.

Orchiectomy: Surgery to remove one or both testicles; also called orchidectomy.

Orchiopexy: Surgical fixation of the testicle.

Orchitis: Inflammation of a testis.

Penis: Male organ of copulation.

Polyuria: Excessive urine production.

Prepuce: Flap of skin that forms a collar around, and thus protects and lubricates, the glans penis; also referred to as the foreskin.

Prostate gland: A gland at the base of the bladder surrounding the urethra that contributes fluid to semen during ejaculation.

Prostatitis: Inflammation of the prostate gland.

Scrotum: An external pouch of skin and muscle that houses the testes.

Semen: Ejaculatory fluid composed of sperm and secretions from the seminal vesicles, prostate, and bulbourethral glands.

Seminal vesicle: Gland that produces seminal fluid, which contributes to semen.

Seminiferous tubules: Structures within the testes where spermatogenesis occurs.

Sertoli cells: Cells that support germ cells through the process of spermatogenesis; a type of sustentacular cell.

Sperm: Male gamete.

Spermatic cord: Bundle of nerves and blood vessels that supplies the testes; contains ductus deferens.

Spermatid: Immature sperm cells produced by meiosis II of secondary spermatocytes.

Spermatocyte: A male gametocyte from which a spermatozoon develops.

Spermatogenesis: The process of producing sperm.

Spermatogonia: The diploid precursor cells that become sperm.

Spermiogenesis: Transformation of spermatids to spermatozoa during spermatogenesis.

Sterility: A condition of being unable to produce children.

Testes: Male gonads.

Urethritis: Inflammation of the urethra.

Varicocele: Distended veins of the spermatic cord.

Vasectomy: A procedure in which a small section of the ductus deferens is cut and sealed to interrupt sperm delivery. It is an effective form of male birth control.

Vasovasostomy: Creation of an artificial opening between ducts to restore fertility to males who have had a vasectomy.

Test Yourself

Query 1.16.8

This interactive element is not available in this format. Visit the link or scan the QR code to access it online.

View this Interactive Content online

References

Centers for Disease Control and Prevention. (n.d.-a). *Prostate cancer statistics*. https://www.cdc.gov/cancer/prostate/statistics/index.htm

Centers for Disease Control and Prevention. (n.d.-b). *Chlamydia – CDC fact sheet (Detailed)*. https://www.cdc.gov/std/chlamydia/stdfact-chlamydia-detailed.htm

Centers for Disease Control and Prevention. (n.d.-c). *Gonorrhea – CDC fact sheet (Detailed)*. https://www.cdc.gov/std/gonorrhea/stdfact-gonorrhea-detailed.htm

Centers for Disease Control and Prevention. (n.d.-d). *Reporting and confidentiality*. https://www.cdc.gov/std/treatment-guidelines/clinical-reporting.htm

Centers for Disease Control and Prevention. (n.d.-e). *What is case surveillance?* https://www.cdc.gov/nndss/about/index.html

Centers for Disease Control and Prevention. (n.d.-f). *Genital herpes fact sheet*. https://www.cdc.gov/std/herpes/stdfact-herpes.htm

CrashCourse. (2015, November 9). *Reproductive system, part 2 – Male reproductive system: Crash course A&P 41*. YouTube. https://youtu.be/-XQcnO4iX_U

MedlinePlus. (2021). *HPV*. U.S. National Library of Medicine. https://medlineplus.gov/hpv.html

National Cancer Institute. (2021a). *Testicular cancer treatment (PDQ®)-Patient version*. National Institutes of Health, U.S. Department of Health and Human Services. https://www.cancer.gov/types/testicular/patient/testicular-treatment-pdq

National Cancer Institute. (2021b). *Human papillomavirus (HPV) vaccines*. National Institutes of Health, U.S. Department of Health and Human Services. https://www.cancer.gov/about-cancer/causes-prevention/risk/infectious-agents/hpv-vaccine-fact-sheet

U.S. Department of Health and Human Services. (2020). *Sexually transmitted infections National Strategic Plan for the United States: 2021-2025*. https://www.hhs.gov/sites/default/files/STI-National-Strategic-Plan-2021-2025.pdf

Image Descriptions

Figure 16.1 image description: This figure shows the different organs in the male reproductive system. The top panel shows the side view of a man and an uncircumcised and a circumcised penis. The bottom panel shows the lateral view of the male reproductive system and the major parts are labeled. [Return to Figure 16.1].

Figure 16.2 image description: This diagram shows the structure of sperm; the major parts are labeled (from left to right): head section (acrosome, plasma membrane, nucleus), mid-piece (centriole, mitochondria, flagellum), tail (flagellum, axial filament), end piece (end piece). [Return to Figure 16.2].

Unless otherwise indicated, this chapter contains material adapted from *Anatomy and Physiology* (on OpenStax), by Betts et al. and is used under a CC BY 4.0 international license. Download and access this book for free at https://openstax.org/books/anatomy-and-physiology/pages/1-introduction.

This page titled 1.16: Male Reproductive System is shared under a CC BY 4.0 license and was authored, remixed, and/or curated by Andrea Nelson and Katherine Greene via source content that was edited to the style and standards of the LibreTexts platform.

1.17: Female Reproductive System

Learning Objectives

- Examine the anatomy of the female reproductive system
- Determine the main functions of the female reproductive system
- Differentiate the medical terms of the female reproductive system and common abbreviations
- Recognize the medical specialties associated with the female reproductive system
- Discover common diseases, disorders, and procedures related to the female reproductive system

Female Reproductive System Word Parts

Click on prefixes, combining forms, and suffixes to reveal a list of word parts to memorize for the female reproductive system.

Query 1.17.1

This interactive element is not available in this format. Visit the link or scan the QR code to access it online.

View this Interactive Content online

Introduction to the Female Reproductive System

The female reproductive system produces gametes and reproductive hormones. In addition, the female reproductive system supports the developing fetus and delivers it to the outside world. The female reproductive system is located primarily inside the pelvic cavity. The female gonads are called ovaries and the gamete they produce is called an oocyte.

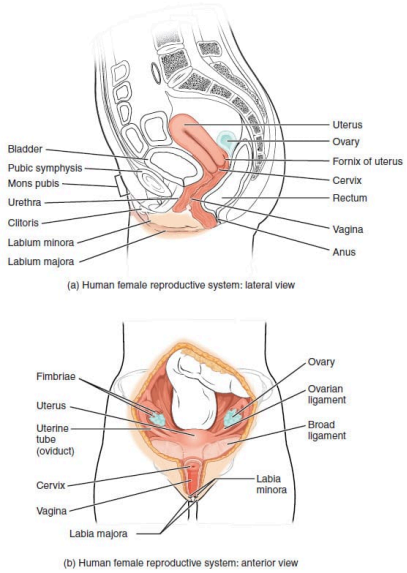

Figure 17.1 Female Reproductive System. The major organs of the female reproductive system are located inside the pelvic cavity. From Betts et al., 2013. Licensed under CC BY 4.0. [Image description.]

Watch this video:

YouTube Video

This interactive element is not available in this format. Visit the link or scan the QR code to access it online.

View this YouTube Video online

Media 17.1. Reproductive System, Part 1 – Female Reproductive System: Crash Course A&P #40 [Online video]. Copyright 2015 by CrashCourse.

Practice Medical Terms Related to the Female Reproductive System

Query 1.17.2

This interactive element is not available in this format. Visit the link or scan the QR code to access it online.

View this Interactive Content online

Anatomy (Structures) of the Female Reproductive System

External Female Genitals

The external female reproductive structures are referred to collectively as the **vulva** and they include:

- The **mons pubis,** a pad of fat that is located at the anterior, over the pubic bone. After puberty, it becomes covered in pubic hair.
- The **labia majora** (labia = “lips”; majora = “larger”), folds of hair-covered skin that begin just posterior to the mons pubis.
- The **labia minora** (labia = “lips”; minora = “smaller”), which is thinner and more pigmented and extends medially to the labia majora.
  - Although they naturally vary in shape and size from woman to woman, the labia minora serve to protect the female urethra and the entrance to the female reproductive tract.
  - The superior, anterior portions of the labia minora come together to encircle the **clitoris** (or glans clitoris), an organ that originates from the same cells as the glans penis and has abundant nerves that make it important in sexual sensation and orgasm. The **hymen** is a thin membrane that sometimes partially covers the entrance to the **vagina**.
- The vaginal opening is located between the opening of the urethra and the anus. It is flanked by outlets to the **Bartholin’s glands**.

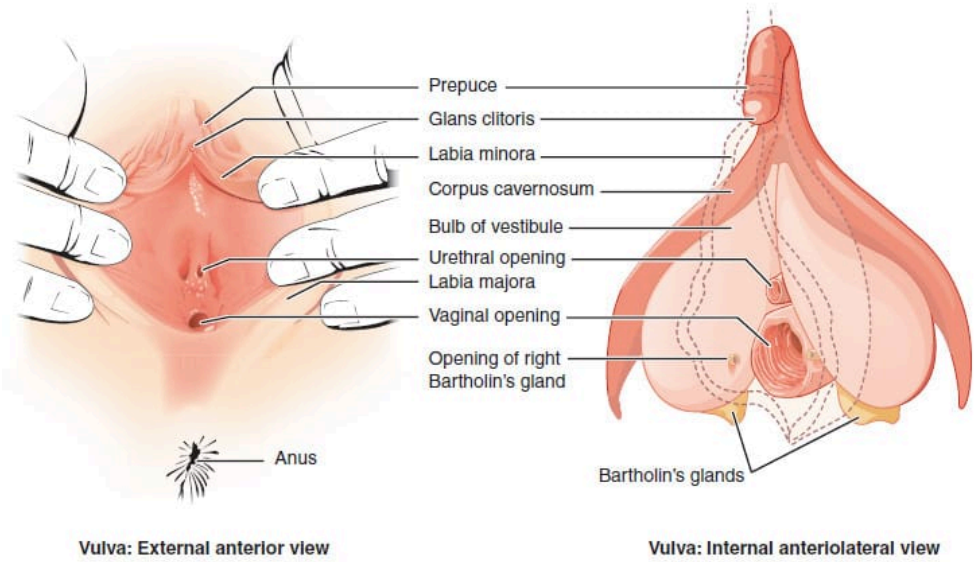

Figure 17.2. The Vulva. The external female genitalia is referred to collectively as the vulva. From Betts et al., 2013. Licensed under CC BY 4.0. [Image description.]

Internal Female Reproductive Organs

Vagina

The **vagina** is a muscular canal (approximately 10 cm long) that is the entrance to the reproductive tract. It also serves as the exit from the uterus during menses and childbirth. The outer walls of the anterior and posterior vagina are columns with ridges. The superior fornix meets the uterine cervix. The cervix is the opening to the uterus.

The walls of the vagina are lined with:

- An outer, fibrous adventitia
- A middle layer of smooth muscle
- An inner mucous membrane with transverse folds called **rugae**.

Together, the middle and inner layers allow the expansion of the vagina to accommodate intercourse and childbirth. The thin, perforated hymen can partially surround the opening to the vaginal orifice. The Bartholin's glands and the lesser vestibular glands (located near the clitoris) secrete mucus, which keeps the vestibular area moist.

The vagina has a normal population of microorganisms that help to **protect** against infection. There are both pathogenic bacteria and yeast in the vagina. In a healthy woman, the most predominant type of vaginal bacteria is from the genus *Lactobacillus,* which secretes lactic acid. The lactic acid protects the vagina by maintaining an acidic pH (below 4.5).

Lactic acid, in combination with other vaginal secretions, makes the vagina a self-cleansing organ. However, douching can disrupt the normal balance of healthy microorganisms, and increase a woman's risk for infections and irritation. It is recommended that women do not douche and that they allow the vagina to maintain its normal healthy population of protective microbial flora.

Ovaries

The **ovaries** are the female gonads. There are two, one at each entrance to the fallopian tube. They are each about 2 to 3 cm in length, about the size of an almond. The ovaries are located within the pelvic cavity. The ovary itself is attached to the uterus via the ovarian ligament. The ovarian stroma forms the bulk of the adult ovary. Oocytes develop within the outer layer of this stroma, each surrounded by supporting cells. This grouping of an oocyte and its supporting cells is called a **follicle.**

The Fallopian Tubes

The fallopian tubes, also known as uterine tubes, are the conduit of the oocyte from the ovary to the uterus. Each of the two fallopian tubes is close to, but not directly connected to, the ovary.

- The **isthmus** is the narrow medial end of each fallopian tube that is connected to the uterus.
- The wide distal **infundibulum** flares out with slender, finger-like projections called **fimbriae**.
- The middle region of the tube, called the **ampulla**, is where fertilization often occurs.

The fallopian tubes have three layers:

- An outer serosa.
- A middle smooth muscle layer.
- An inner mucosal layer.
  - In addition to its mucus-secreting cells, the inner mucosa contains ciliated cells that beat in the direction of the uterus, producing a current that will be critical to moving the oocyte.

> **Did you know?**
>
> Fallopian tubes are not connected to the ovaries. Instead, fimbriae catch the oocyte like a baseball in a glove.

The Uterus and Cervix

The **uterus** is the muscular organ that nourishes and supports the growing embryo. Its average size is approximately 5 cm wide by 7 cm long, and it has three sections.

- The portion of the uterus superior to the opening of the uterine tubes is called the **fundus**.
- The middle section of the uterus is called the **body of the uterus** (or corpus).
- The **cervix** is the narrow inferior portion of the uterus that projects into the vagina.
  - The cervix produces mucus secretions that become thin and stringy under the influence of high systemic plasma estrogen concentrations, and these secretions can facilitate sperm movement through the reproductive tract.

The wall of the uterus is made up of three layers:

- **Perimetrium:** the most superficial layer and serous membrane.
- **Myometrium:** a thick layer of smooth muscle responsible for uterine contractions.
- **Endometrium:** the innermost layer containing a connective tissue lining covered by epithelial tissue that lines the lumen. It provides the site of implantation for a fertilized egg and sheds during menstruation if no egg is fertilized.

> Concept Check
>
> - Write or draw out the components of the pathway that an **oocyte** takes from beginning to end.
> - Why do you think the **fallopian tubes** are not connected to the **ovaries**?

Physiology (Function) of the Female Reproductive System-Ovulation

Following ovulation, the Fallopian tube receives the oocyte. Oocytes lack flagella, and therefore cannot move on their own.

- High concentrations of estrogen that occur around the time of ovulation induce contractions of the smooth muscle along the length of the fallopian tube.
- These contractions occur every 4 to 8 seconds, causing the oocyte to flow towards the uterus, through the coordinated beating of the cilia that line the outside and lumen of the length of the fallopian tube which pulls the oocyte into the interior of the tube.

- Once inside, the muscular contractions and beating cilia move the oocyte slowly toward the uterus.
- When fertilization does occur, sperm typically meet the egg while it is still moving through the ampulla.

Watch this video:

YouTube Video

This interactive element is not available in this format. Visit the link or scan the QR code to access it online.

View this YouTube Video online

Media 17.2. The ovarian cycle | Reproductive system physiology | NCLEX-RN | Khan Academy [Online video]. Copyright 2014 by Khan Academy Medicine.

The Menstrual Cycle

The three phases of the menstrual cycle are:

1. The **menses phase** of the menstrual cycle is the phase during which reproductive hormone levels are low, the woman menstruates, and the lining is shed. The menses phase lasts between 2 to 7 days with an average of 5 days.
2. The **proliferative phase** is when menstrual flow ceases and the endometrium begins to proliferate. During this phase reproductive hormones are working in homeostasis to trigger ovulation on approximately day 14 of a typical 28-day menstrual cycle. Ovulation marks the end of the proliferative phase.
3. The **secretory phase** is when the endometrial lining prepares for the implantation of a fertilized egg. If no pregnancy occurs within approximately 10 to 12 days the endometrium will grow thinner and shed starting the first day of the next cycle.

Menopause

Menopause is the cessation of the menstrual cycle that occurs as a result of the loss of ovarian follicles and the hormones that they produce, namely estrogen. The earliest changes occur during the menopausal transition, often referred to as **perimenopause**, when a woman's cycle becomes irregular but does not stop entirely. As estrogen levels change, other signs and symptoms that occur are hot flashes and night sweats, trouble sleeping, vaginal dryness, mood swings, difficulty focusing, and thinning of hair on the head along with the growth of more hair on the face. Depending on the individual, these symptoms can be entirely absent, moderate, or severe.

A woman is considered to have completed menopause if she has not menstruated in a full year. After that point, she is considered postmenopausal. The average age for this change is consistent worldwide at between 50 and 52 years of age, but it can normally occur in a woman's forties or later in her fifties. Poor health, including smoking, can lead to earlier loss of fertility and earlier menopause. After menopause, low levels of estrogen increase women's risks of high cholesterol, cardiovascular disease, and osteoporosis.

Anatomy Labeling Activity

Query 1.17.3

This interactive element is not available in this format. Visit the link or scan the QR code to access it online.

View this Interactive Content online

Practice Terms Related to the Female Reproductive System

Query 1.17.4

This interactive element is not available in this format. Visit the link or scan the QR code to access it online.

View this Interactive Content online

Common Abbreviations for the Female Reproductive System

Many terms and phrases related to the female reproductive system are abbreviated. Learn these common abbreviations by expanding the list below.

Query 1.17.5

This interactive element is not available in this format. Visit the link or scan the QR code to access it online.

View this Interactive Content online

Diseases and Disorders of the Female Reproductive System

Breast Cancer

Breast cancer is the second most common cancer among women in the United States. It starts in the cells that line the ducts or the lobule of the breast. Some warning signs include a new lump in the breast or axilla, thickening or swelling, dimpling of the breast skin, redness or flaky skin, discharge, and change in breast size. Risk factors include a familial or personal history of breast cancer, obesity, hormonal treatment, and mutations in breast cancer-related genes (BRCA1 or BRCA2) (Centers for Disease Control and Prevention, n.d.-a; National Cancer Institute, 2021a).

Treatment options include chemotherapy, hormone therapy, immunotherapy, radiation, and surgical interventions such as mastectomy, and biopsy (National Cancer Institute, 2021a). To learn more about breast cancer, view the National Cancer Institute's web page on breast cancer.

Cervical Cancer

Cervical cancer is typically slow-growing cancer and is highly curable when found and treated early. Advanced cervical cancer may cause abnormal bleeding or discharge from the vagina such as bleeding after sex. It is diagnosed during a Papanicolaou test (or Pap smear), which looks for precancerous lesions on the cervix. The Pap test can find cervical cancer early when treatment is most effective. Almost all cervical cancers are caused by human papillomavirus (HPV). The HPV test looks for HPV strains which is the virus that can cause precancerous cell changes. In the United States, a vaccine called Gardasil® 9 is available, which prevents infection with HPV and significantly reduces the risk of cervical cancer (National Cancer Institute, 2021b, 2021c). To learn more, visit the National Cancer Institute's web page on cervical cancer.

Endometriosis

Endometriosis is an abnormal condition of the endometrium. Endometriosis occurs when this tissue grows and implants outside the uterus. The female hormone estrogen causes these implants to grow, bleed, and become inflamed. The inflammation causes scar tissue around nearby organs, which can interfere with their normal functioning and cause pain (Office on Women's Health, 2019a).

Endometriosis generally appears in women in their 30s and 40s. Signs and symptoms may include dysmenorrhea, dyspareunia, menstrual irregularity, and infertility. Diagnosis may include laparoscopy and endometrial biopsy. There is no cure for endometriosis. Treatment may include hormonal birth control, surgical interventions such as hysterectomy and oophorectomy. The cause of endometriosis is unknown (MedlinePlus, 2021; Office on Women's Health, 2019a). For more information, visit the Office on Women's Health web page on endometriosis.

Polycystic Ovary Syndrome (PCOS)

Polycystic ovary syndrome (PCOS) has no known etiology, but researchers have linked it to excessive production of insulin and androgens. Excessive insulin in the body can cause insulin resistance and lead to type 2 diabetes. High levels of androgens can prevent the ovaries from releasing an egg during the menstrual cycle. The most common signs and symptoms of PCOS include oligomenorrhea, amenorrhea, polymenorrhea, one or both ovaries with multiple small painless cysts, acrochordons, acanthosis nigricans, hirsutism, thinning hair, acne, weight gain, anxiety, depression, hyperglycemia, and infertility. Treatments like medications such as birth control pills or antiandrogens can help balance the hormones in your body and relieve some of the symptoms (Office on Women's Health, 2019b). To learn more, visit the Office on Women's Health's web page on endometriosis.

Sexually Transmitted Infections and Diseases (STIs and STDs)

Although the terms sexually transmitted infections (STI) and sexually transmitted diseases (STD) are often used interchangeably, they have distinct meanings. STIs refer to infections caused by a virus, bacteria, fungus, or parasite via sexual contact. STDs refer to the disease state that develops as a result of infection (U.S. Department of Health and Human Services, 2020).

Chlamydia

Chlamydia is one of the most common sexually transmitted diseases. It is caused by the bacterium *Chlamydia trachomatis,* which infects the cervix and other organs of the reproductive tract in women. Chlamydia spreads through unprotected oral, anal, or vaginal sex with an infected person. Chlamydia can also spread from mother to child during childbirth. Many people with chlamydia do not have any symptoms and unknowingly pass the infection to their sexual partner(s). If symptoms develop, they may not appear for several weeks after sexual contact with an infected person. Women may have abnormal vaginal discharge, polyuria, and painful intercourse. Untreated chlamydia in women can cause pelvic inflammatory disease, which can cause permanent damage to the reproductive tract and infertility. Chlamydia is easy to treat with antibiotics and can be cured. However, until a patient finishes their treatment, they continue to have the infection and can continue to pass it to others. Patients should be re-tested three months after treatment, as re-infection is common (Centers for Disease Control and Prevention, n.d.-b).

Gonorrhea (Gonococcus)

Gonorrhea is a sexually transmitted disease caused by the bacterium *Neisseria gonorrhoeae*. It infects the mucous membranes of the reproductive tract, including the cervix, uterus, and fallopian tubes in women. Infections can also infect the mouth, throat,

eyes, and anus. Gonorrhea is spread through unprotected oral, vaginal or anal sex with an infected person. It can also spread from mother to child during childbirth. Many people infected with gonorrhea have no symptoms and can unknowingly pass the infection on to their sexual partner(s). Signs and symptoms vary depending on which part of the body is infected. Women may have dysuria, increased vaginal discharge, or vaginal bleeding not related to their menstrual cycle. Gonorrhea infection from oral sex may lead to a sore throat, whereas infection from anal sex may cause itchiness and discharge from the anus. Untreated chlamydia can cause pelvic inflammatory disease. Gonorrhea can be treated and cured with antibiotics in combination with an intramuscular (IM) injection. However, until the patient finishes their treatment, they continue to have the infection and can pass it to others. Patients should be re-tested three months after treatment, as re-infection is common (Centers for Disease Control and Prevention, n.d.-c).

Notifiable and Reportable Diseases

In every state in the United States, chlamydia and gonorrhea are notifiable and reportable diseases. This means that when a person tests positive for either of the STIs, public health departments and the Centers for Disease Control and Prevention (CDC) are informed so that they may monitor trends, identify outbreaks, and take the necessary steps to prevent further spread of the disease (Centers for Disease Control and Prevention, n.d.-d, n.d.-e).

Human Papillomavirus (HPV)

Human papillomavirus (HPV) is another common sexually transmitted infection (STI). Both males and females can be infected with HPV. There are over 200 strains of HPV. Some strains can cause visible genital warts, while others cause genital, anal, throat, and cervical cancers. HPV spreads through sexual activity and skin-to-skin contact in the genital area with an infected person. Since some people are asymptomatic, they don't know they have the virus and consequently pass the virus to their sexual partners. Treatments are available for genital warts but there is no cure for HPV (MedlinePlus, 2021). For more information, visit the CDC's web page on HPV.

Herpes Simplex Virus (HSV)

Genital herpes is a sexually transmitted disease that is caused by a virus called the herpes simplex virus (HSV). There are two types of herpes simplex viruses:

- Type 1- oral herpes or cold sores (HSV-1)
- Type 2- genital herpes (HSV-2).

Signs and symptoms might include dysuria, enlarged glands, myalgia, and fever. Once a patient is infected with HSV, the virus remains in their body even after the symptoms are gone and can cause recurring outbreaks. When the virus becomes active again, the symptoms return but are usually less painful and heal faster (Centers for Disease Control and Prevention, n.d.-f).

Herpes is spread through direct contact with the sores or blisters of an infected person. Contact (and transfer of the virus) can occur from genitals-to-genitals, mouth-to-genitals, or mouth-to-mouth. Herpes can also be passed to the anal area. Herpes spreads easily during sexual contact while symptoms are present or just before an outbreak of symptoms. An infected person may spread herpes even when they have no symptoms; this is called asymptomatic shedding. One can spread the herpes virus to other parts of their body after touching the sores. The fingers, eyes, and other body areas can accidentally become infected in this way. Hand washing after touching sores and blisters is recommended to prevent spreading the virus (Centers for Disease Control and Prevention, n.d.-f).

There is no cure for herpes. Antiviral pills help to reduce symptoms and speed the healing of blisters or sores and are prescribed by a doctor. All sexual partner(s) should be informed. The only way to reduce the risk of transmission of herpes is to avoid direct contact with the sores and to use condoms. Condoms will reduce but not eliminate risk, as the virus can be present and shed from the skin in the genital area (Centers for Disease Control and Prevention, n.d.-f).

Common Abbreviations for Reproductive Sexually Transmitted Infections (STIs)

Query 1.17.6

This interactive element is not available in this format. Visit the link or scan the QR code to access it online.

View this Interactive Content online

Medical Terms in Context

Query 1.17.7

This interactive element is not available in this format. Visit the link or scan the QR code to access it online.

View this Interactive Content online

Query 1.17.8

This interactive element is not available in this format. Visit the link or scan the QR code to access it online.

View this Interactive Content online

Query 1.17.9

This interactive element is not available in this format. Visit the link or scan the QR code to access it online.

View this Interactive Content online

Medical Specialties and Procedures Related to the Female Reproductive System

Obstetrics and Gynecology

Obstetrics and gynecology, also known as OB/GYN, is a branch of medicine focusing on the diagnosis, treatment, management, and prevention of diseases and disorders of the female reproductive system, as well as the care of women during pregnancy and

childbirth. Subspecialties in women's health include contraception, reproductive endocrinology, and infertility (National Cancer Institute, n.d.-a). To learn more, visit the American College of Surgeons' web page on obstetrics and gynecology.

Hysterectomy

A hysterectomy is performed to stage or treat endometriosis, cancers, and precancers of the female reproductive tract, and some non-cancerous conditions that have not responded to other forms of treatment. There are three types of hysterectomy:

- A **total hysterectomy** removes both the uterus and the cervix.
- A **subtotal hysterectomy** removes the uterus only.
- A **radical hysterectomy** removes the uterus, cervix, part of the vagina, and ligaments (Office on Women's Health, 2019b).

Sometimes the ovaries and fallopian tubes are removed at the same time that a hysterectomy is done. A bilateral salpingo-oophorectomy (BSO) removes both ovaries and fallopian tubes. A unilateral salpingo-oophorectomy removes one ovary and one fallopian tube (National Cancer Institute, n.d.-b, n.d.-c). For more information, visit the Cleveland Clinic's web page on hysterectomy.

Female Reproductive System Vocabulary

Acanthosis nigricans: A disorder that causes darkening and thickening of the armpit and other body folds.

Acrochordons: Common benign skin growths that appear as small, raised, brown or skin-colored bumps; also called skin tags.

Amenorrhea: Absence of menstruation.

Androgens: Male sex hormones; for example, testosterone.

Antiandrogens: Substances that keep androgens (male sex hormones) from binding to proteins called androgen receptors. Preventing this binding blocks the effects of these hormones in the body.

Antibiotics: A drug used to treat infections caused by bacteria and other microorganisms.

Antiretrovirals: Drugs that inhibit the ability of the human immunodeficiency virus (HIV) or other types of retroviruses to multiply in the body.

Asymptomatic: Having no signs or symptoms of disease.

Axilla: The underarm or armpit.

Bartholin's glands: Glands that produce a thick mucus that maintains moisture in the vulva area; also referred to as the greater vestibular glands.

Bilateral: Affecting both the right and left sides of the body.

Cervicitis: Inflammation of the cervix.

Colposcope: A lighted magnifying instrument used to check the cervix, vagina, and vulva for signs of disease.

Colposcopy: A procedure in which a lighted, magnifying instrument called a colposcope is used to examine the cervix, vagina, and vulva.

Contraception: The use of drugs, devices, or surgery to prevent pregnancy.

Douching: Washing the vagina with fluid.

Dysmenorrhea: Painful menstruation.

Dyspareunia: Genital pain before, during, or after intercourse.

Dysuria: Painful urination.

Endocrinology: A specialty in the field of medicine that focuses on the treatment of endocrine system disorders.

Endometriosis: A disease characterized by the presence of endometrial-like tissue found outside the uterus.

Endometritis: Inflammation of the endometrium.

Endometrium: The innermost layer of the uterus. It provides the site of implantation for a fertilized egg and sheds during menstruation if no egg is fertilized.

Endoscopy: A procedure that uses an endoscope to examine the inside of the body.

Fistula: An abnormal opening or passage between two organs or between an organ and the surface of the body.

Fornix: The superior portion of the vagina.

Gamete: A specialized sex cell carrying 23 chromosomes.

Gynecologist: A doctor who has special training in diagnosing and treating diseases of the female reproductive organs.

Gynecology: A medical-surgical specialty concerned with the physiology and disorders primarily of the female genital tract, as well as female endocrinology and reproductive physiology.

Hirsutism: A condition in which women and children have excess coarse body hair of an adult male distribution pattern as a result of elevated androgen levels.

Homeostasis: The state of steady internal conditions maintained by living things.

Hysterectomy: Surgery to remove the uterus and, sometimes, the cervix.

Hysterosalpingogram: A radiographic image of the uterus and fallopian (uterine) tubes.

Hysteroscope: An endoscope used for examining the interior of the uterus.

Hysteroscopy: Endoscopic examination of the uterus.

Inferior: A position below or lower than another part of the body proper.

Intramuscular: Within or into muscle.

Laparoscopy: A procedure that uses a laparoscope, inserted through the abdominal wall, to examine the inside of the abdomen.

Leukorrhea: White discharge from the vagina.

Lumbago: Acute or chronic pain in the lumbar or sacral regions.

Mammography: The use of film or a computer to create a picture of the breast.

Mammogram: Radiographic image of the breast.

Mammoplasty: Surgical reconstruction of the breast, including both augmentation and reduction.

Mastalgia: Pain or discomfort in one or both breasts.

Mastectomy: The surgical procedure to remove all or part of a breast.

Mastitis: A condition in which breast tissue is inflamed.

Menarche: First menstruation in a pubertal female.

Menopause: The cessation of the menstrual cycle; is considered complete when a woman has not menstruated in a full year.

Menorrhagia: Excessive bleeding at menstruation.

Metrorrhagia: Excessive bleeding from the uterus not related to menstruation.

Oligomenorrhea: Abnormally infrequent menstruation.

Oocyte: Immature egg cell.

Oophorectomy: Surgery to remove one or both ovaries.

Oophoritis: Inflammation of the ovary.

Ovulation: Release of a secondary oocyte and associated granulosa cells from an ovary.

Papanicolaou smear (Pap test): A procedure in which a small brush is used to gently remove cells from the surface of the cervix and the area around it so they can be checked under a microscope for cervical cancer or cell changes that may lead to cervical cancer.

Perimenopause: The transitional period before and after menopause wherein the menstrual cycle is irregular and hormone levels widely fluctuate.

Polyuria: Excessive urine production.

Prolapse: The protrusion of an organ or part of an organ into a natural or artificial orifice.

Proliferate: The ability to reproduce rapidly.

Puerperium: Time directly after childbirth.

Salpingectomy: Excision of one or both of the fallopian (uterine) tubes.

Salpingitis: Inflammation of a fallopian (uterine) tube.

Salpingo-oophorectomy: Surgical removal of the fallopian (uterine) tubes and ovaries.

Salpingostomy: Creation of an artificial opening in the fallopian (uterine) tube.

Speculum: An instrument used to widen an opening of the body to make it easier to look inside.

Superior: A position above or higher than another part of the body proper.

Trachelectomy: Excision of the cervix.

Tubal ligation: Surgical closure of the fallopian (uterine) tubes for sterilization.

Unilateral: Pertaining to one side.

Urethritis: Inflammation of the urethra.

Vaginal: Pertaining to the vagina.

Vaginosis: Abnormal condition of the vagina.

Vulvectomy: Excision of the vulva.

Vulvovaginitis: Inflammation of the vulva and vagina.

Test Yourself

Query 1.17.10

This interactive element is not available in this format. Visit the link or scan the QR code to access it online.

View this Interactive Content online

References

Centers for Disease Control and Prevention. (n.d.-a). *Breast cancer statistics*. https://www.cdc.gov/cancer/breast/statistics/index.htm

CrashCourse. (2015, October 2015). *Reproductive system, part 1 – female reproductive system: Crash course A&P #40* [Video]. YouTube. https://www.youtube.com/watch?v=RFDatCchpus

MedlinePlus. (2021). *Endometriosis*. U.S. National Library of Medicine. https://medlineplus.gov/endometriosis.html

National Cancer Institute. (n.d.-a). *Definition of obstetrics and gynecology*. National Institutes of Health, U.S. Department of Health and Human Services. https://www.cancer.gov/publications/dictionaries/cancer-terms/def/obstetrics-and-gynecology

National Cancer Institute. (n.d.-b). *Definition of bilateral salpingo-oophorectomy*. National Institutes of Health, U.S. Department of Health and Human Services. https://www.cancer.gov/publications/dictionaries/cancer-terms/def/bilateral-salpingo-oophorectomy

National Cancer Institute. (n.d.-c). *Definition of unilateral salpingo-oophorectomy. National Institutes of Health, U.S. Department of Health and Human Services.* https://www.cancer.gov/publications/dictionaries/cancer-terms/def/unilateral-salpingo-oophorectomy

National Cancer Institute. (2021a). *Breast cancer treatment (adult) (PDQ®)–Patient version. National Institutes of Health, U.S. Department of Health and Human Services.* https://www.cancer.gov/types/breast/patient/breast-treatment-pdq

National Cancer Institute. (2021b). *Cervical cancer treatment (adult) (PDQ®)–Patient version. National Institutes of Health, U.S. Department of Health and Human Services.* https://www.cancer.gov/types/cervical/patient/cervical-treatment-pdq

National Cancer Institute. (2021c). *Human papillomavirus (HPV) vaccines*. National Institutes of Health, U.S. Department of Health and Human Services. https://www.cancer.gov/about-cancer/causes-prevention/risk/infectious-agents/hpv-vaccine-fact-sheet

Office on Women's Health. (2019a). *Endometriosis*. U.S. Department of Health and Human Services. https://www.womenshealth.gov/a-z-topics/endometriosis

Office on Women's Health. (2019b). *Hysterectomy*. U.S. Department of Health and Human Services. https://www.womenshealth.gov/a-z-topics/hysterectomy

Image Descriptions

Figure 17.1 image description: This figure shows the structure and the different organs in the female reproductive system. The top panel shows the lateral view with labels (clockwise from top): uterus, ovary, fornix of uterus, cervix, rectum, vagina, anus, labia majora, labium minora, clitoris, urethra, mons pubis, pubic symphysis, bladder; and the bottom panel shows the anterior view with labels (clockwise from top): ovary, ovarian ligament, broad ligament, labia minora, labia majora, vagina, cervix, uterine tube, uterus, fimbriae. [Return to Figure 17.1].

Figure 17.2 image description: This figure shows the parts of the vulva. The right panel shows the external anterior view and the left panel shows the internal anterolateral view. The major parts are labeled (from top): prepuce, glans clitoris, labia minora, corpus cavernosum, bulb of vestibule, urethral opening, labia majora, vaginal opening, the opening of right Bartholin's gland, Bartholin's glands, anus. [Return to Figure 17.2].

Unless otherwise indicated, this chapter contains material adapted from *Anatomy and Physiology* (on OpenStax), by Betts et al. and is used under a CC BY 4.0 international license. Download and access this book for free at https://openstax.org/books/anatomy-and-physiology/pages/1-introduction.

This page titled 1.17: Female Reproductive System is shared under a CC BY 4.0 license and was authored, remixed, and/or curated by Andrea Nelson and Katherine Greene via source content that was edited to the style and standards of the LibreTexts platform.

1.18: Obstetrics

Learning Objectives

- Identify the processes involved in human reproduction and childbirth
- Evaluate the specialty of obstetrics
- Differentiate the medical terms used in obstetrics and use correct abbreviations
- Recognize the medical specialties associated with obstetrics
- Discover common complications and procedures related to obstetrics

Obstetrics Word Parts

Click on prefixes, combining forms, and suffixes to reveal a list of word parts to memorize related to obstetrics.

Query 1.18.1

This interactive element is not available in this format. Visit the link or scan the QR code to access it online.

View this Interactive Content online

Introduction to Obstetrics

Obstetrics is a specialty that is concerned with the mother and fetus during pregnancy, childbirth, and the immediate postpartum period. Obstetricians study obstetrics and gynecology and are referred to as OB/GYN, Obstetrics and Gynecology.

Watch this video:

YouTube Video

This interactive element is not available in this format. Visit the link or scan the QR code to access it online.

View this YouTube Video online

Media 18.1. Reproductive System, Part 4 – Pregnancy & Development: Crash Course A&P #43 [Online video]. Copyright 2015 by CrashCourse.

Practice Medical Terms Related to Obstetrics

Query 1.18.2

This interactive element is not available in this format. Visit the link or scan the QR code to access it online.

View this Interactive Content online

Fertilization

Fertilization occurs when sperm and an oocyte combine. Because each of these reproductive cells is a haploid cell containing half of the genetic material needed to form a human being, their combination forms a diploid cell. This new single cell is called a zygote.

Most of the time, a woman releases a single egg during an ovulation cycle.

- In approximately 1% pof ovulation cycles, two eggs are released and both are fertilized.
  - Two zygotes form, implant, and develop, resulting in the birth of **dizygotic (or fraternal) twins**. Because dizygotic twins develop from two eggs fertilized by two sperm, they are no more identical than siblings born at different times.
- Less common, one zygote can divide into two separate offspring during early development. This results in the birth of **monozygotic (or identical) twins**.

A full-term pregnancy lasts approximately 270 days (approximately 38.5 weeks) from conception to birth. Because it is easier to remember the first day of the last menstrual period (LMP) than to estimate the date of conception, obstetricians set the due date as 284 days (approximately 40.5 weeks) from the LMP. This assumes that conception occurred on day 14 of the woman's cycle, which is usually a good approximation. The 40 weeks of an average pregnancy are usually discussed in terms of three trimesters, each approximately 13 weeks. During the second and third trimesters, the pre-pregnancy uterus is about the size of a fist and grows dramatically to contain the fetus, causing a number of anatomical changes in the mother.

Stages of Childbirth

The process of childbirth can be divided into three stages (see Figure 18.1):

- cervical dilation
- expulsion of the newborn
- after birth

For vaginal birth to occur, the cervix must dilate fully to 10 cm in diameter, wide enough to deliver the newborn's head. The dilation stage is the longest stage of labor and typically takes 6 to 12 hours. However, it varies widely and may take minutes, hours, or days, depending in part on whether the mother has given birth before. In each subsequent labor, this stage tends to be shorter.

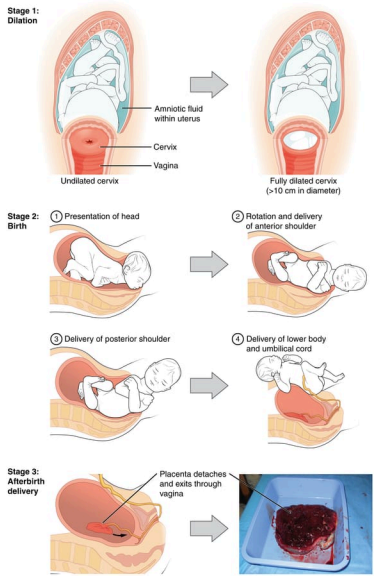

Figure 18.1 Stages of Childbirth. The stages of childbirth include Stage 1, early cervical dilation; Stage 2, full dilation and expulsion of the newborn; and Stage 3, delivery of the placenta and associated fetal membranes. (The position of the newborn's shoulder is described relative to the mother). From Betts et al., 2013. Licensed under CC BY 4.0. [Image description.]

Concept Check

- How is a **due date** determined?
- Explain the difference between a **monozygotic pregnancy** and a **dizygotic pregnancy**.

Homeostasis in the Newborn: Apgar Score

In the minutes following birth, a newborn must undergo dramatic systemic changes to be able to survive outside the womb. An obstetrician, midwife, or nurse can estimate how well a newborn is doing by obtaining an **Apgar score**. The Apgar score was introduced in 1952 by the anesthesiologist Dr. Virginia Apgar as a method to assess the effects on the newborn of anesthesia given to the laboring mother. Healthcare providers now use it to assess the general well-being of the newborn, whether or not analgesics or anesthetics were used.

The five criteria, skin color, heart rate, reflex, muscle tone, and respiration, are assessed and each criterion is assigned a score of 0, 1, or 2. Scores are taken one minute after birth and again five minutes after birth. Each time scores are taken, the five scores are added together. High scores (out of a possible 10) indicate the baby has made the transition from the womb well, whereas lower scores indicate that the baby may be in distress.

The technique for determining an Apgar score is quick and easy, painless for the newborn, and does not require any instruments except for a stethoscope. A convenient way to remember the five scoring criteria is to apply the mnemonic APGAR:

- **A**ppearance (skin color)
- **P**ulse (heart rate)
- **G**rimace (reflex)
- **A**ctivity (muscle tone)
- **R**espiration

Of the five Apgar criteria, heart rate and respiration are the most critical. Poor scores for either of these measurements may indicate the need for immediate medical attention to resuscitate or stabilize the newborn. In general, any score lower than 7 at the 5-minute mark indicates that medical assistance may be needed. A total score below 5 indicates an emergency. Normally, a newborn will get an intermediate score of 1 for some of the Apgar criteria and will progress to a 2 by the five-minute assessment. Scores of 8 or above are normal.

Did you know?

The Apgar score was introduced in 1952 by Dr. Virginia Apgar to assess the effect of anesthesia on newborns and mothers in labor.

Practice Terms Related to Obstetrics

Query 1.18.3

This interactive element is not available in this format. Visit the link or scan the QR code to access it online.

View this Interactive Content online

Common Abbreviations for Obstetrics

Many terms and phrases related to obstetrics are abbreviated. Learn these common abbreviations by expanding the list below.

Query 1.18.4

This interactive element is not available in this format. Visit the link or scan the QR code to access it online.

View this Interactive Content online

Medical Terms in Context

Query 1.18.5

This interactive element is not available in this format. Visit the link or scan the QR code to access it online.

View this Interactive Content online

Diseases and Disorders Related to Obstetrics

Preeclampsia and Eclampsia

Preeclampsia and eclampsia refer to hypertensive disorders that occur during pregnancy among women without a history of high blood pressure. Signs and symptoms of preeclampsia include blood pressure at or greater than 140/90 mmHg at or after 20 weeks of pregnancy, edema, and protein in the urine. Women with preeclampsia are at risk of preterm birth. If the condition is

severe enough to cause seizures or a coma, it is referred to as eclampsia. If not treated, preeclampsia and eclampsia can be fatal (Office of Communications, n.d.).

Ectopic Pregnancy

An ectopic pregnancy occurs when a fertilized egg implants outside of the uterus, usually in the fallopian tube. Risk factors include older age, smoking, the use of an intrauterine device, in vitro fertilization, and prior pelvic infections, including chlamydia. Signs and symptoms include pain in the abdomen or shoulder, vaginal bleeding, and dizziness. Treatment may involve surgery or the use of medication to stop the growth of ectopic tissue (Mummert & Gnugnoli, 2021; MedlinePlus, 2021a).

Miscarriage

Miscarriage, also known as spontaneous abortion, refers to the loss of pregnancy before the 20th week. It is the most common form of pregnancy loss. Risk factors include older maternal age, a history of miscarriages, disorders of the uterus or cervix, and chronic diseases such as polycystic ovary syndrome. Signs and symptoms include vaginal spotting, abdominal pain, and cramping. However, these symptoms can be confused with symptoms of an ectopic or normal pregnancy. Treatment is generally not required in women who miscarry early in their pregnancy. If tissue remains in the uterus after miscarriage, treatment includes the use of medication to aid expulsion or a surgical procedure called **dilation and curettage (D&C)** (Dugas & Slane, 2021; MedlinePlus, 2021b).

Medical Procedures Related to Obstetrics

In Vitro Fertilization (IVF)

IVF, which stands for in vitro fertilization, is an assisted reproductive technology. In vitro, which in Latin translates to in glass, refers to a procedure that takes place outside of the body. There are many different indications for IVF. For example, a woman may produce normal eggs, but the eggs cannot reach the uterus because the uterine tubes are blocked or otherwise compromised. A man may have a low sperm count, low sperm motility, sperm with an unusually high percentage of morphological abnormalities, or sperm that are incapable of penetrating the zona pellucida of an egg. Figure 18.2 illustrates the steps involved in IVF.

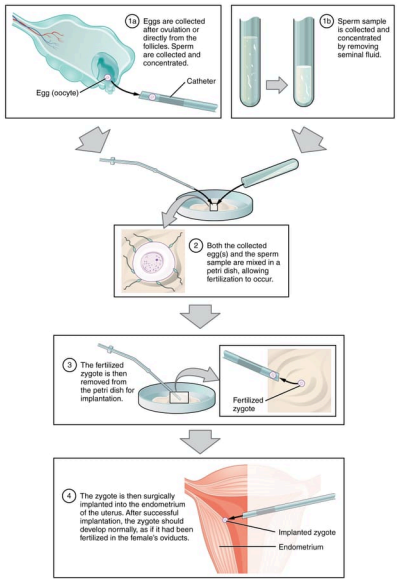

Figure 18.2 IVF. In vitro fertilization involves egg collection from the ovaries, fertilization in a petri dish, and the transfer of embryos into the uterus. From Betts et al., 2013. Licensed under CC BY 4.0. [Image description.]

Did you know?

According to the Centers for Disease Control and Prevention (n.d.-a), 6% of married women aged 15 to 44 years in the U.S. experience infertility.

Prenatal Screening and Diagnostic Testing

Approximately 3% of babies born in the United States are born with a congenital anomaly. The most common anomalies include structural heart defects, brain/spine defects, cleft lip/palate, or anomalies like Down syndrome. Prenatal testing may include blood work, ultrasound, chorionic villus sampling (CVS) and amniocentesis (Centers for Disease Control and Prevention, n.d.-b, n.d.-c).

Obstetrics Vocabulary

Abortion: Intentional removal of a fetus from the uterus.

Alpha-fetoprotein test: Alpha-fetoprotein (AFP) is a protein that is produced during fetal development. The AFP test is an analysis of the mother's blood serum to determine whether the level of AFP denotes a risk of a birth defect.

Amenorrhea: Absence of menstruation.

Amniocentesis: A procedure for obtaining amniotic fluid.

Amniotomy: Incision into the amnion to induce labor.

Apgar score: A technique used to assess the general wellbeing of a newborn. The newborn is assessed one minute after birth and again five minutes after birth.

Artificial insemination: A process where the semen is introduced into the vagina by mechanical means.

Breech: The position of the fetus is feet first. Ideally, the position of the fetus should be headfirst for a safer delivery.

Cesarean section: Delivery of the fetus through an abdominal incision.

Cephalopelvic disproportion: A condition where the infant's head is larger than the mother's pelvis.

Cerclage: A suture inserted into the cervix to prevent dilation and prevention miscarriage.

Chorioamnionitis: Inflammation of the chorion and amnion.

Choriocarcinoma: A malignant, fast-growing tumor that develops from trophoblastic cells (cells that help an embryo attach to the uterus and help form the placenta).

Chorionic villus sampling: A procedure in which tissue from the placenta is tested for fetal chromosomal disorders.

Colostrum: A thick, yellowish substance secreted from a mother's breasts in the first postpartum days.

Dilation and curettage (D&C): A procedure to scrape and remove tissue from the inner lining of the uterus. The cervix is dilated (made larger) and a curette (spoon-shaped instrument) is inserted into the uterus to remove tissue. The procedure is used to test tissue for signs of disease, after a miscarriage, or to treat certain conditions.

Dystocia: Slow or difficult labor.

Eclampsia: A very serious condition in pregnant women with hypertension; patients are at high risk of coma, convulsions, and even death.

Ectopic pregnancy: A pregnancy in which the fertilized ovum is implanted in any tissue other than the uterine wall.

Episiotomy: Incision made in the posterior vaginal wall and perineum that facilitates vaginal birth.

Fetal: Pertaining to the fetus.

Gestation: The period required for embryonic and fetal development in utero; pregnancy.

Gestational diabetes: Diabetes mellitus that occurs during pregnancy but resolves by the end of pregnancy in women without a history of diabetes.

Gestational hypertension: Elevated systolic and diastolic blood pressure in pregnant women.

Gravidity: The number of pregnancies, complete or incomplete, experienced by a woman.

Hyperemesis gravidarum: Excessive vomiting during pregnancy. Hyperemesis can occur with any pregnant woman, even a woman who miscarried. Often these women may require hospitalization for fluid and electrolyte intake.

Induction: The process of bringing on or starting labor through artificial means.

In vitro fertilization: A process where the ova is fertilized outside the body and then implanted into the uterus.

Lactic acid: A substance produced by the body, such as during strenuous exercise, that aids in various chemical processes in the body.

Meconium: Fetal wastes consisting of ingested amniotic fluid, cellular debris, mucus, and bile.

Microcephaly: A congenital abnormality where the head is small.

Midwifery: Practice of assisting in childbirth.

Natal: Pertaining to being born or birth.

Neonatal: Pertaining to the newborn's first thirty days of life outside of the uterus.

Neonate: An infant during the first 28 days after birth.

Neonatologist: Physician who studies and treats disorders of the newborn.

Neonatology: A subspecialty of pediatric medicine concerned with the newborn.

Obstetrician: A doctor who specializes in caring for women during pregnancy and childbirth.

Obstetrics and gynecology: A branch of medicine that specializes in the care of women during pregnancy and childbirth and in the diagnosis and treatment of diseases of the female reproductive organs; also called OB/GYN.

Oligohydramnios: A condition of abnormally low amniotic fluid volume.

Oocyte: Immature egg cell.

Parturition: Childbirth.

Placenta abruptio: Occurs when the placenta prematurely becomes detached from the uterine wall, resulting in uterine bleeding, fetal distress, or fetal death; also known as abruptio placenta.

Placenta previa: Low placement of fetus within the uterus, which causes the placenta to partially or completely cover the opening of the cervix as it grows.

Polyhydramnios: A condition where there is excessive amniotic fluid in the placenta.

Postnatal: Pertaining to after birth.

Postpartum: The period of approximately 6 weeks immediately following childbirth.

Preeclampsia: The abnormal condition in pregnancy where the patient experiences hypertension, edema, and proteinuria.

Prenatal: Having to do with the time a female is pregnant, before birth occurs; also called antenatal.

Primigravida: First pregnancy.

Pseudocyesis: False pregnancy.

Puerperal: Pertaining to immediately after childbirth.

Puerperium: Time directly after childbirth (6 to 8 weeks after giving birth).

Sperm: Male gamete (spermatozoon).

Stillbirth: An infant who is born dead.

Teratogen: An agent capable of producing malformations in a developing embryo.

Teratology: A branch of embryology for the study of congenital malformations and developmental abnormalities.

Vaginal birth following a C-section: Delivery of an infant through the vagina in a female who has had a prior cesarean section.

Zygote: A single cell formed by the fusion of an egg and sperm; also called the fertilized egg.

Test Yourself

Query 1.18.6

This interactive element is not available in this format. Visit the link or scan the QR code to access it online.

View this Interactive Content online

References

Centers for Disease Control and Prevention. (n.d.-a). Infertility FAQs. https://www.cdc.gov/reproductivehealth/infertility/index.htm

Centers for Disease Control and Prevention. (n.d.-b). Data & statistics on birth defects. https://www.cdc.gov/ncbddd/birthdefects/data.html

Centers for Disease Control and Prevention. (n.d.-c). Diagnosis of birth defects. https://www.cdc.gov/ncbddd/birthdefects/diagnosis.html

CrashCourse. (2019, November 23). Reproductive System, Part 4 – Pregnancy & Development: Crash Course A&P #43 [Video]. YouTube. https://youtu.be/BtsSbZ85yiQ

Dugas, C., & Slane, V. H. (2021). Miscarriage. In StatPearls [Internet]. https://www.ncbi.nlm.nih.gov/books/NBK532992/

MedlinePlus. (2021a). Ectopic pregnancy. U.S. National Library of Medicine. https://medlineplus.gov/ectopicpregnancy.html

MedlinePlus. (2021b). Miscarriage. U.S. National Library of Medicine. https://medlineplus.gov/miscarriage.html

Mummert, T., & Gnugnoli, D. M. (2021). Ectopic pregnancy. In StatPearls [Internet]. https://www.ncbi.nlm.nih.gov/books/NBK539860/

Office of Communications. (n.d.). About preeclampsia and eclampsia. Eunice Kennedy Shriver National Institute of Child Health and Human Development, National Institutes of Health. https://www.nichd.nih.gov/health/topics/preeclampsia/conditioninfo

Image Descriptions

Figure 18.1 image description: This multi-part figure shows the different stages of childbirth. The top panel shows dilation of the cervix (undilated vs fully dilated), the middle panel shows birth (presentation of the head, rotation and delivery of anterior shoulder, delivery of posterior shoulder, delivery of lower body, and umbilical cord), and the bottom panel shows afterbirth delivery. [Return to Figure 18.1].

Figure 18.2 image description: This multi-part figure shows the different steps in in vitro fertilization. The top panel shows how the oocytes and the sperm are collected and prepared (text reads: 1a) eggs are collected after ovulation or directly from the follicles. Sperm is collected and concentrated. 1b) Sperm sample is collected and concentrated by removing seminal fluid). The next panel shows the sperm and oocytes being mixed in a petri dish (text labels read: 2) both the collected eggs and the sperm sample are mixed in a petri dish, allowing fertilization to occur). The panel below shows the fertilized zygote being prepared for implantation (text labels read: 3a) the fertilized zygote is then removed from the petri dish for implantation. 3b) fertilized zygote). The last panel shows the fertilized zygote being implanted into the uterus (text label reads: 4) The zygote is then surgically implanted into the endometrium of the uterus. After successful implantation, the zygote should develop normally, as if it had been fertilized in the female's oviducts). [Return to Figure 18.2].

Unless otherwise indicated, this chapter contains material adapted from Anatomy and Physiology (on OpenStax), by Betts et al. and is used under a CC BY 4.0 international license. Download and access this book for free at https://openstax.org/books/anatomy-and-physiology/pages/1-introduction.

This page titled 1.18: Obstetrics is shared under a CC BY 4.0 license and was authored, remixed, and/or curated by Andrea Nelson and Katherine Greene via source content that was edited to the style and standards of the LibreTexts platform.

INDEX

No index terms found.

This page titled Index is shared under a CC BY 4.0 license and was authored, remixed, and/or curated by Andrea Nelson and Katherine Greene via source content that was edited to the style and standards of the LibreTexts platform.

GLOSSARY

Interactive Content

This interactive element is not available in this format. Visit the link or scan the QR code to access it online.

View this Interactive Content online

If the glossary does not display above, open it in a new tab.

This page titled Glossary is shared under a CC BY 4.0 license and was authored, remixed, and/or curated by Andrea Nelson and Katherine Greene via source content that was edited to the style and standards of the LibreTexts platform.

DETAILED LICENSING

Overview

Title: Medical Terminology for Healthcare Professions (Nelson and Greene)

Webpages: 31

All licenses found:

- CC BY 4.0: 96.8% (30 pages)
- Undeclared: 3.2% (1 page)

By Page

- Medical Terminology for Healthcare Professions (Nelson and Greene) - *CC BY 4.0*
  - Front Matter - *CC BY 4.0*
    - TitlePage - *CC BY 4.0*
    - InfoPage - *CC BY 4.0*
    - Table of Contents - *Undeclared*
    - Introduction - *CC BY 4.0*
    - Acknowledgements - *CC BY 4.0*
    - Licensing - *CC BY 4.0*
  - Chapters - *CC BY 4.0*
    - 1.1: Word Parts and Rules - *CC BY 4.0*
    - 1.2: Prefixes and Suffixes - *CC BY 4.0*
    - 1.3: Body Terminology - *CC BY 4.0*
    - 1.4: Sensory Systems - *CC BY 4.0*
    - 1.5: Integumentary System - *CC BY 4.0*
    - 1.6: Skeletal System - *CC BY 4.0*
    - 1.7: Muscular System - *CC BY 4.0*
    - 1.8: Nervous System - *CC BY 4.0*
    - 1.9: Cardiovascular System - *CC BY 4.0*
    - 1.10: Blood Vessels and Blood - *CC BY 4.0*
    - 1.11: Lymphatic and Immune Systems - *CC BY 4.0*
    - 1.12: Respiratory System - *CC BY 4.0*
    - 1.13: Digestive System - *CC BY 4.0*
    - 1.14: Endocrine System - *CC BY 4.0*
    - 1.15: Urinary System - *CC BY 4.0*
    - 1.16: Male Reproductive System - *CC BY 4.0*
    - 1.17: Female Reproductive System - *CC BY 4.0*
    - 1.18: Obstetrics - *CC BY 4.0*
  - Back Matter - *CC BY 4.0*
    - Index - *CC BY 4.0*
    - Glossary - *CC BY 4.0*
    - Detailed Licensing - *CC BY 4.0*

This page titled Medical Terminology for Healthcare Professions (Nelson and Greene) is shared under a CC BY 4.0 license and was authored, remixed, and/or curated by Andrea Nelson and Katherine Greene via source content that was edited to the style and standards of the LibreTexts platform.