GENERAL HUMAN ANATOMY (LANGE ET AL.)

Jennifer Lange et al.

General Human Anatomy

This text is disseminated via the Open Education Resource (OER) LibreTexts Project (https://LibreTexts.org) and like the thousands of other texts available within this powerful platform, it is freely available for reading, printing, and "consuming."

The LibreTexts mission is to bring together students, faculty, and scholars in a collaborative effort to provide an accessible, and comprehensive platform that empowers our community to develop, curate, adapt, and adopt openly licensed resources and technologies; through these efforts we can reduce the financial burden borne from traditional educational resource costs, ensuring education is more accessible for students and communities worldwide.

Most, but not all, pages in the library have licenses that may allow individuals to make changes, save, and print this book. Carefully consult the applicable license(s) before pursuing such effects. Instructors can adopt existing LibreTexts texts or Remix them to quickly build course-specific resources to meet the needs of their students. Unlike traditional textbooks, LibreTexts' web based origins allow powerful integration of advanced features and new technologies to support learning.

LibreTexts is the adaptable, user-friendly non-profit open education resource platform that educators trust for creating, customizing, and sharing accessible, interactive textbooks, adaptive homework, and ancillary materials. We collaborate with individuals and organizations to champion open education initiatives, support institutional publishing programs, drive curriculum development projects, and more.

The LibreTexts libraries are Powered by NICE CXone Expert and were supported by the Department of Education Open Textbook Pilot Project, the California Education Learning Lab, the UC Davis Office of the Provost, the UC Davis Library, the California State University Affordable Learning Solutions Program, and Merlot. This material is based upon work supported by the National Science Foundation under Grant No. 1246120, 1525057, and 1413739.

Any opinions, findings, and conclusions or recommendations expressed in this material are those of the author(s) and do not necessarily reflect the views of the National Science Foundation nor the US Department of Education.

Have questions or comments? For information about adoptions or adaptions contact info@LibreTexts.org or visit our main website at https://LibreTexts.org.

The LibreTexts name, logo, and book covers are trademarked by LibreTexts, Inc. (a 501(c)(3) not-for-profit organization) and protected against unauthorized use.

This text was compiled on 10/19/2026

This page titled ProgramPage is shared under a CC BY-NC-SA 4.0 license and was authored, remixed, and/or curated by Jennifer Lange et al..

TABLE OF CONTENTS

ProgramPage

Licensing

Preface and Acknowledgements

About the Authors

1: An Introduction to the Human Body

1.1: Introduction to the Human Body

1.2: Overview of Anatomy

1.3: Structural Organization of the Human Body

1.4: Anatomical Terminology

1.5: Medical Imaging

1.6: Anatomical Atlas - Anatomical Terminology

1.7: Practice Practical - Anatomy Introduction

2: Cellular Level of Organization

2.1: Introduction to the Cellular Level of Organization

2.2: The Cell Membrane

2.3: The Cytoplasm and Cellular Organelles

2.4: The Nucleus

2.5: Cell Growth and Division

2.6: Cellular Differentiation

3: Tissue Level of Organization

3.1: Introduction to the Tissue Level of Organization

3.2: Types of Tissues

3.3: Epithelial Tissue

3.4: Connective Tissue

3.5: Muscle Tissue

3.6: Nervous Tissue

3.7: Tissue Injury and Aging

3.8: Anatomical Atlas - Tissues

3.9: Practice Practical- Tissues

4: Integumentary System

4.1: Introduction to the Integumentary System

4.2: Layers of the Skin

4.3: Accessory Structures of the Skin

4.4: Functions of the Integumentary System

4.5: Diseases, Disorders, and Injuries of the Integumentary System

4.6: Anatomical Atlas - Integumentary System

4.7: Practice Practical - Integumentary System

5: Bone Tissue and Skeletal System

5.1: Introduction to Bone Tissue and the Skeletal System
5.2: Functions of the Skeletal System
5.3: Bone Structure
5.4: Bone Formation and Development
5.5: Fractures and Bone Repair
5.6: Exercise, Nutrition, Hormones, and Bone Tissue Health
5.7: Bone Classification
5.8: Anatomical Atlas - Bone Tissue and Bone Structure
5.9: Practice Practical - Bone Tissue and Bone Structure

6: Axial and Appendicular Skeleton

6.1: Introduction to the Skeleton System
6.2: Divisions of the Skeletal System
6.3: The Skull
6.4: The Vertebral Column
6.5: The Thoracic Cage
6.6: The Pectoral Girdle
6.7: Bones of the Upper Limb
6.8: The Pelvic Girdle and Pelvis
6.9: Bones of the Lower Limb
6.10: Embryonic Development of the Skeleton
6.11: Anatomical Atlas - Skeleton
6.12: Practice Practical - Skeleton

7: Joints

7.1: Introduction
7.2: Classification of Joints
7.3: Synovial Joints
7.4: Types of Body Movements
7.5: Anatomy of Selected Synovial Joints
7.6: Diseases and Injuries of Joints
7.7: Anatomical Atlas - Joints
7.8: Practice Practical - Joints

8: Muscle Tissues and Muscle Structure

8.1: Introduction to Muscle Tissue
8.2: Muscle Tissues
8.3: Skeletal Muscle Organ Structure
8.4: Development and Regeneration of Muscle Tissue
8.5: Anatomical Atlas - Muscle Tissues

8.6: Practice Practical- Muscle Tissues

9: Muscular System

9.1: Introduction to the Muscular System

9.2: Interactions of Skeletal Muscles, Their Fascicle Arrangement, and Their Lever Systems

9.3: Naming Skeletal Muscles

9.4: Axial Muscles of the Head, Neck, and Back

9.5: Axial Muscles of the Abdominal Wall and Thorax

9.6: Appendicular Muscles of the Pectoral Girdle and Upper Limbs

9.7: Appendicular Muscles of the Pelvic Girdle and Lower Limbs

9.8: Anatomical Atlas - Muscular System

9.9: Practice Practical- Muscles

10: Nervous System and Nervous Tissue

10.1: Introduction to the Nervous System

10.2: Organization and Functions of the Nervous System

10.3: Anatomy of Nervous Tissue

10.4: Synapses

10.5: Development of the Nervous System

10.6: Anatomical Atlas - Nervous Tissue

10.7: Practice Practical - Nervous Tissue

11: Central Nervous System

11.1: Introduction to the Central Nervous System

11.2: Support and Protection of the Brain

11.3: Brain - Cerebrum

11.4: Brain - Diencephalon, Brainstem, Cerebellum and Limbic System

11.5: Spinal Cord

11.6: Anatomical Atlas - Central Nervous System

11.7: Practice Practical - Central Nervous System

12: Peripheral Nervous System

12.1: Introduction to the Peripheral Nervous System

12.2: Nerve and Ganglion Structure

12.3: Cranial Nerves

12.4: Spinal Nerves and Their Branches

12.5: Anatomical Atlas - Peripheral Nervous System

12.6: Practice Practical

13: Somatic Senses

13.1: Introduction to the Somatic Senses

13.2: Sensory Modalities and General Senses

13.3: Hearing and Balance

13.4: Vision

13.5: Taste and Smell
13.6: Anatomical Atlas - Somatic Senses
13.7: Practice Practical - Somatic Senses

14: Autonomic Nervous System
14.1: Introduction to the Autonomic Nervous System
14.2: Divisions of the Autonomic Nervous System
14.3: Autonomic Synapses and Effects
14.4: Central Control of Autonomic Function
14.5: Anatomical Atlas - Autonomic Nervous System
14.6: Practice Practical - ANS

15: Endocrine System
15.1: Introduction to the Endocrine System
15.2: An Overview of the Endocrine System
15.3: Pituitary Gland and Hypothalamus
15.4: Thyroid Gland and Parathyroid Glands
15.5: Adrenal Glands
15.6: Pineal Gland
15.7: Gonadal and Placental Hormones
15.8: Endocrine Pancreas
15.9: Organs with Secondary Endocrine Functions
15.10: Development and Aging of the Endocrine System
15.11: Anatomical Atlas - Endocrine System
15.12: Practice Practical- Endocrine System

16: Cardiovascular System - Blood
16.1: Introduction to Blood
16.2: An Overview of Blood
16.3: Erythrocytes
16.4: Leukocytes and Platelets
16.5: Production of the Formed Elements
16.6: Anatomical Atlas - Blood
16.7: Practice Practical- Blood

17: Cardiovascular System - Heart
17.1: Introduction to the Heart
17.2: Heart Anatomy
17.3: Cardiac Muscle and Electrical Activity
17.4: Coronary Circulation
17.5: Development of the Heart
17.6: Anatomical Atlas - Heart
17.7: Practice Practical- Heart

18: Cardiovascular System - Blood Vessels

18.1: Introduction to Blood Vessels and Circulation

18.2: Structure and Function of Blood Vessels

18.3: Circulatory Pathways

18.4: Development of Blood Vessels and Fetal Circulation

18.5: Anatomical Atlas - Blood Vessels and Circulation

18.6: Practice Practical- Blood Vessels and Circulation

19: Lymphatic System

19.1: Introduction to the Lymphatic System

19.2: Functions of the Lymphatic System

19.3: Anatomy of Lymphatic Vessels

19.4: Anatomy of Lymphatic Organs and Tissues

19.5: Anatomical Atlas - Lymphatic System

19.6: Practice Practical- Lymphatic System

20: Respiratory System

20.1: Introduction to the Respiratory System

20.2: The Lungs

20.3: Conducting Zone

20.4: Respiratory Zone

20.5: Embryonic Development of the Respiratory System

20.6: Anatomical Atlas - Respiratory System

20.7: Practice Practical - the Respiratory System

21: Digestive System

21.1: Introduction to the Digestive System

21.2: Organs of the Digestive System

21.3: Digestive System Processes and Regulation

21.4: Mouth, Pharynx, and Esophagus

21.5: Stomach

21.6: Small and Large Intestines

21.7: Accessory Organs - Liver, Pancreas, and Gallbladder

21.8: Anatomical Atlas - Digestive System

21.9: Practice Practical- Digestive system

22: Urinary System

22.1: Introduction to the Urinary System

22.2: Overview of the Kidney

22.3: Microscopic Anatomy of the Kidney

22.4: Urinary Tract

22.5: Anatomical Atlas - Urinary System

22.6: Practice Practical- Urinary System

23: Reproductive Systems

23.1: Introduction to the Reproductive System

23.2: Anatomy of the Male Reproductive System

23.3: Anatomy of the Female Reproductive System

23.4: Development of the Male and Female Reproductive Systems

23.5: Practice Practical- the Reproductive System

23.6: Anatomical Atlas - Reproductive Systems

24: Embryology and Fetal Development

24.1: Overview of Embryology and Fetal Development

24.2: Fertilization

24.3: Embryonic Development

24.4: Fetal Development

24.5: Maternal Changes During Pregnancy, Labor, and Birth

24.6: Adjustments of the Infant at Birth and Postnatal Stages

24.7: Lactation

Index

Glossary

Detailed Licensing

This page titled General Human Anatomy (Lange et al.) is shared under a CC BY-NC-SA 4.0 license and was authored, remixed, and/or curated by Jennifer Lange et al..

- Human Anatomy (OERI) by Whitney Menefee, Julie Jenks, Chiara Mazzasette, and Kim-Leiloni Nguyen is licensed CC BY 4.0.

Licensing

A detailed breakdown of this resource's licensing can be found in ***Back Matter/Detailed Licensing***.

This page titled Licensing is shared under a CC BY-NC-SA 4.0 license and was authored, remixed, and/or curated by Jennifer Lange et al..

Preface and Acknowledgements

The purpose of this textbook is to serve as a resource for students who are taking a first semester human anatomy course. All efforts were made to ensure the material covered in this resource is consistent, accurate, and accessible. This material was also designed to be equitable, diverse, and inclusive.

Image Accessibility

This resource makes use of complex images that may not be accessible. Please work with your instructor and local campus resources to identify accommodations for images that are not accessible.

Terminology

Bolded text is used to indicate vocabulary terminology. Students are encouraged to use this formatting to help them identify key words to know for learning anatomy.

Acknowledgments

Content support:

This book is a product of a curation of the OER content from many sources. We would like to specifically thank Whitney Menefee, Julie Jenks, Chiara Mazasette, and Kim-Leiloni Nguyen for their work creating the Human Anatomy OERI textbook, based on OpenStax content, which served as the starting point for this project.

This page titled Preface and Acknowledgements is shared under a CC BY-NC-SA 4.0 license and was authored, remixed, and/or curated by Jennifer Lange et al..

- Preface and Acknowledgements by Whitney Menefee, Julie Jenks, Chiara Mazzasette, and Kim-Leiloni Nguyen is licensed CC BY 4.0.

About the Authors

Jennifer Lange - Project Lead, Author, Illustrator

Jennifer Lange is a full-time instructor in the Biological Sciences Department of Chabot College in Hayward, CA who has been teaching undergraduate human anatomy for over 20 years. She holds an B.S. and an M.S. in Physiological Science from UCLA and an M.A. in Curriculum and Teacher Education from Stanford University, and she is currently a doctoral student in Kent State University's Interprofessional Leadership Ed.D. Program. She is fascinated by how the complex systems of nature seem to work so effortlessly and is passionate about figuring out how to simply explain the human body and making this knowledge relevant to students interested in health care careers.

John Polos - Author

Yancy Aquino - Author

Cheri Calcagno - Author

Cheri Calcagno is a college health and biological sciences instructor as well as a health educator specializing in disease prevention, weight management, and behavioral modification. She holds a Master of Science degree in Kinesiology, emphasis in Exercise Physiology, and a Bachelor of Science in Kinesiology, emphasis in Exercise, Nutrition, and Wellness, in addition to continuing education in the field of psychology focusing on the science of change, positive psychology, and mental wellness. Professor Calcagno is a San Francisco Bay Area native with the mission to educate future health professionals and equip first-generation, underrepresented students to pursue careers in health, medicine, and science.

Justin Greene - Medical Illustrator

Mark Schaeffer - Illustrator

Mark Schaeffer is an emeritus faculty member at Chabot College, where he guided the college's Digital Media program from its inception in 2003 until 2016. He holds a B.A. from Princeton University, and is the author of several books for Peachpit Press and Adobe Press. He currently works independently in image editing, video post-production, and motion graphics.

Sophia Elizondo - Illustrator

Sofia Elizondo is passionate about the intersections of healthcare and graphic design. She is a Graphic Design Associate at Heller Agency which specializes in the pharmaceutical and healthcare space. Previously she was honored to be a UX Design Apprentice at BRIDGEGOOD over the summer of 2023. Through her time there she learned to create social change by working with teams to research, understand, and design for the needs of emerging creatives. At the nonprofit, she worked on projects to embody the BRIDGEGOOD motto #DesignForSocialGood by making web and mobile applications that were accessible and inclusive. She

enjoys using her creativity to design experiences that help people feel inspired and confident in themselves.

Gabrielle Spurlock - Illustrator

Claire McGuire - Illustrator

This page titled About the Authors is shared under a CC BY-NC-SA 4.0 license and was authored, remixed, and/or curated by Jennifer Lange et al..

- About the Authors by Whitney Menefee, Julie Jenks, Chiara Mazzasette, and Kim-Leiloni Nguyen is licensed CC BY 4.0.

1: AN INTRODUCTION TO THE HUMAN BODY

1.1: Introduction to the Human Body

1.2: Overview of Anatomy

1.3: Structural Organization of the Human Body

1.4: Anatomical Terminology

1.5: Medical Imaging

1.6: Anatomical Atlas - Anatomical Terminology

1.7: Practice Practical - Anatomy Introduction

This page titled 1: An Introduction to the Human Body is shared under a CC BY-NC-SA 4.0 license and was authored, remixed, and/or curated by Jennifer Lange et al..

- 1: An Introduction to the Human Body by Whitney Menefee, Julie Jenks, Chiara Mazzasette, and Kim-Leiloni Nguyen is licensed CC BY 4.0.

1.1: Introduction to the Human Body

Figure 1.1.1: Blood Pressure. The image above shows a patient getting their blood pressure read by a health care professional. A proficiency in anatomy and physiology is fundamental to any career in the health professions. (Image credit:"100 Blood Pressure" by OpenStax and Bryan Mason/flickr is licensed under CC BY 4.0)

Chapter Learning Objectives

After studying this chapter, you will be able to:

- Distinguish between anatomy and physiology, and identify several branches of each
- Describe the structure of the body, from simplest to most complex, in terms of the six levels of organization
- Use appropriate anatomical terminology to identify key body structures, body regions, and directions in the body

Though you may approach the subjects of anatomy and physiology strictly as a requirement for your field of study, the knowledge you gain in these subjects will serve you well in many aspects of your life. An understanding of anatomy and physiology is not only fundamental to any career in the health professions, but it can also benefit your own health. Familiarity with the human body can help you make healthful choices and prompt you to take appropriate action when signs of illness arise. Your knowledge in this field will help you understand news about nutrition, medications, medical devices, and procedures and help you understand genetic or infectious diseases. At some point, everyone will have a problem with some aspect of his or her body and your knowledge can help you to be a better parent, spouse, partner, friend, colleague, or caregiver.

Contributors and Attributions

- OpenStax Anatomy & Physiology (CC BY 4.0). Access for free at https://openstax.org/books/anatomy-and-physiology

This page titled 1.1: Introduction to the Human Body is shared under a CC BY-NC-SA 4.0 license and was authored, remixed, and/or curated by Jennifer Lange et al..

- 1.1: Introduction to the Human Body by Whitney Menefee, Julie Jenks, Chiara Mazzasette, and Kim-Leiloni Nguyen is licensed CC BY 4.0.

1.2: Overview of Anatomy

By the end of the section, you will be able to:

- Differentiate between the fields of anatomy and physiology, and explain the relationship between them
- Explain the structural level at which the the subfields of anatomy study the body

Human **anatomy** is the scientific study of the body's structures. Some of these structures are very small and can only be observed and analyzed with the assistance of a microscope. Other larger structures can readily be seen, manipulated, measured, and weighed. The word "anatomy" comes from a Greek root that means "to cut apart." Human anatomy was first studied by observing the exterior of the body and observing the wounds of soldiers and other injuries. Later, physicians were allowed to dissect bodies of the dead to augment their knowledge. When a body is dissected, its structures are cut apart in order to observe their physical attributes and their relationships to one another. Dissection is still used in medical schools, anatomy courses, and in pathology labs. In order to observe structures in living people, however, a number of imaging techniques have been developed. These techniques allow clinicians to visualize structures inside the living body such as a cancerous tumor or a fractured bone.

Like most scientific disciplines, anatomy has areas of specialization. **Gross anatomy** is the study of the larger structures of the body, those visible without the aid of magnification (Figure $1.2.1.a$). Macro- means "large," thus, gross anatomy is also referred to as macroscopic anatomy. In contrast, micro- means "small," and **microscopic anatomy** is the study of structures that can be observed only with the use of a microscope or other magnification devices (Figure $1.2.1.b$). Microscopic anatomy includes cytology, the study of cells and histology, the study of tissues. As the technology of microscopes has advanced, anatomists have been able to observe smaller and smaller structures of the body, from slices of large structures like the heart, to the three-dimensional structures of large molecules in the body.

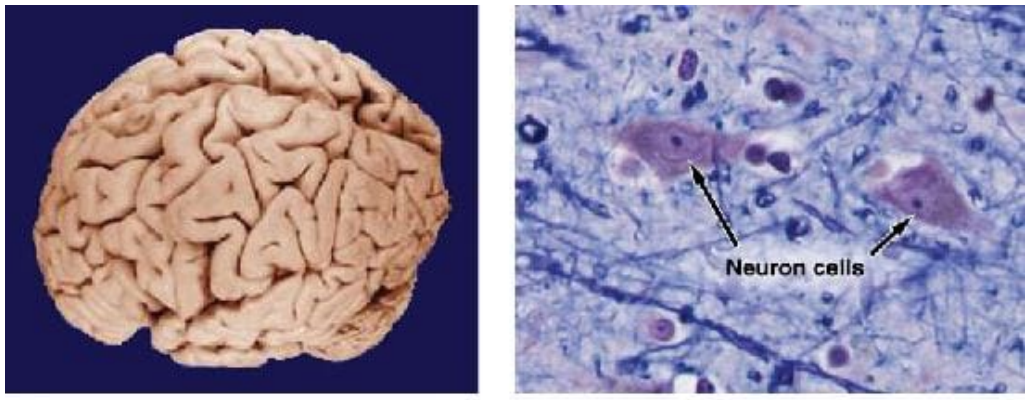

Figure $1.2.1$: Gross and Microscopic Anatomy. (a) Gross anatomy considers large structures such as the brain. (b) Microscopic anatomy can deal with the same structures, though at a different scale. This is a micrograph of nerve cells from the brain. LM × 1600. (Image credits (a) "Brain" by WriterHound is licensed under CC BY 3.0 (b) Micrograph provided by the Regents of University of Michigan Medical School © 2012)

Anatomists take two general approaches to the study of the body's structures: regional and systemic. **Regional anatomy** is the study of the interrelationships of all of the structures in a specific body region, such as the abdomen. Studying regional anatomy helps us appreciate the interrelationships of body structures, such as how muscles, nerves, blood vessels, and other structures work together to serve a particular body region. In contrast, **systemic anatomy** is the study of the structures that make up a discrete body system—that is, a group of structures that work together to perform a unique body function. For example, a systemic anatomical study of the muscular system would consider all of the skeletal muscles of the body.

Whereas anatomy is about structure, physiology is about function. Human **physiology** is the scientific study of the chemistry and physics of the structures of the body and the ways in which they work together to support the functions of life. Much of the study of physiology centers on the body's tendency toward homeostasis. **Homeostasis** is the state of steady internal conditions maintained by living things. The study of physiology certainly includes observation, both with the naked eye and with microscopes, as well as manipulations and measurements. However, current advances in physiology usually depend on carefully designed

laboratory experiments that reveal the functions of the many structures and chemical compounds that make up the human body.

Like anatomists, physiologists typically specialize in a particular branch of physiology. For example, neurophysiology is the study of the brain, spinal cord, and nerves and how these work together to perform functions as complex and diverse as vision, movement, and thinking. Physiologists may work from the organ level (exploring, for example, what different parts of the brain do) to the molecular level (such as exploring how an electrochemical signal travels along nerves).

Form is closely related to function in all living things. For example, the thin flap of your eyelid can snap down to clear away dust particles and almost instantaneously slide back up to allow you to see again. At the microscopic level, the arrangement and function of the nerves and muscles that serve the eyelid allow for its quick action and retreat. At a smaller level of analysis, the function of these nerves and muscles likewise relies on the interactions of specific molecules and ions. Even the three-dimensional structure of certain molecules is essential to their function.

While extensive study of both anatomy and physiology is required to fully understand the overall workings of the human body, this textbook will focus mainly on anatomy. By first studying anatomy, you will gain a comprehensive understanding of the structural characteristics of the human body, which will build a solid foundation for your proceeding studies of human physiology.

Concept Review

Human anatomy is the scientific study of the body's structures. In the past, anatomy has primarily been studied via observing injuries, and later by the dissection of anatomical structures of cadavers, but in the past century, computer-assisted imaging techniques have allowed clinicians to look inside the living body. Human physiology is the scientific study of the chemistry and physics of the structures of the body. Physiology explains how the structures of the body work together to maintain life.

Review Questions

Query 1.2.1

This interactive element is not available in this format. Visit the link or scan the QR code to access it online.

View this Interactive Content online

Critical Thinking Questions

Query 1.2.2

This interactive element is not available in this format. Visit the link or scan the QR code to access it online.

View this Interactive Content online

Query 1.2.3

This interactive element is not available in this format. Visit the link or scan the QR code to access it online.

View this Interactive Content online

Glossary

Query 1.2.4

This interactive element is not available in this format. Visit the link or scan the QR code to access it online.

View this Interactive Content online

Contributors and Attributions

- OpenStax Anatomy & Physiology (CC BY 4.0). Access for free at https://openstax.org/books/anatomy-and-physiology

This page titled 1.2: Overview of Anatomy is shared under a CC BY-NC-SA 4.0 license and was authored, remixed, and/or curated by Jennifer Lange et al..

- 1.2: Overview of Anatomy and Physiology by Whitney Menefee, Julie Jenks, Chiara Mazzasette, and Kim-Leiloni Nguyen is licensed CC BY 4.0.

1.3: Structural Organization of the Human Body

Learning Objectives

By the end of the section, you will be able to:

- Describe the structure of the human body in terms of six levels of organization
- List the eleven organ systems of the human body and identify at least one organ and one major function of each

Before you begin to study the different structures and functions of the human body, it is helpful to consider its basic architecture; that is, how its smallest parts are assembled into larger structures. It is convenient to consider the structures of the body in terms of fundamental levels of organization that increase in complexity: atoms, molecules, organelles, cells, tissues, organs, organ systems, and organisms (Figure 1.3.1).

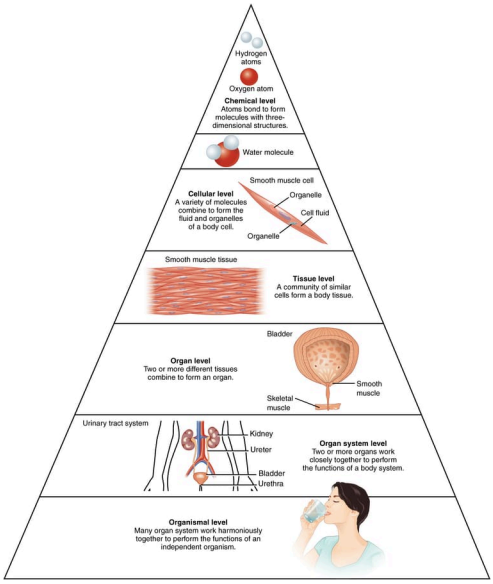

Figure 1.3.1: Levels of Structural Organization of the Human Body. The organization of the body often is discussed in terms of six distinct levels of increasing complexity, from the smallest chemical building blocks to a unique human organism. (Image credit: "Levels of Org in Body" by OpenStax is licensed under CC BY 4.0)

The Levels of Organization

To study the smallest level of organization, scientists consider the simplest building blocks of matter: atoms and molecules. The **chemical level** of organization considers these two building block as atoms bond to form molecules with three dimensional structures. All matter in the universe is composed of one or more unique pure substances called elements, familiar examples of which are hydrogen, oxygen, carbon, nitrogen, calcium, and iron. The smallest unit of any of these pure substances (elements) is an atom. Atoms are made up of subatomic particles such as the proton, electron and neutron. Two or more atoms combine to form a molecule, such as the water molecules, proteins, and sugars found in living things. Molecules are the chemical building blocks of all body structures.

The **cellular level** is considered when a variety of molecules combine to form the fluid and organelles of a body cell. A **cell** is the smallest independently functioning unit of a living organism. Even bacteria, which are extremely small, independently-living organisms, have a cellular structure. Each bacterium is a single cell. All living structures of human anatomy contain cells, and almost all functions of human physiology are performed in cells or are initiated by cells. A human cell, such as a smooth muscle cell, typically consists of flexible membranes that enclose **cytoplasm**, a water-based cellular fluid together with a variety of tiny functioning units called **organelles**.

The **tissue level** can be studied when a community of similar cells and the extracellular material surrounding the cells form a body tissue. A **tissue** is a group of many similar cells and the surrounding extracellular material that work together to perform a specific function. For example, when many smooth muscle cells come together and adhere to the proteins in their extracellular matrix, these cells and proteins collectively form a layer of smooth muscle tissue.

An **organ** is an anatomically distinct structure of the body composed of two or more tissue types, which forms the **organ level** of organization. Each organ performs one or more specific physiological functions. The human bladder, which is composed of smooth muscle tissue, transitional epithelial tissue, and several types of connective tissue serves the function of storing urine produced by the kidneys.

An **organ system level** is a group of organs that work together to perform major functions or meet physiological needs of the body. In the organ example above, both the kidneys and the bladder are organs of the urinary system. The kidneys produce urine, which is moved to the bladder by the ureters. Urine can then leave the bladder, and the body, through the urethra. These four organs work together to rid the body of liquid waste.

This book organized by organ systems in the human body (Figure 1.3.2). Assigning organs to organ systems can be imprecise since organs that "belong" to one system can also have functions integral to another system. In fact, most organs contribute to more than one system. The organ systems in the human body covered in this book include:

- The **integumentary system** functions to enclose internal body structures and is the site of many sensory receptors. Some organs of this system include skin, hair, sweat glands, and nails.
- The **skeletal system** supports the body and enables movement (with the help of the muscular system). Bones are the major organs of this system.
- The **muscular system** enables movement (with the help of the skeletal system) and also helps to maintain body temperature. Skeletal muscles are the major organs of this system, which are connected to bones by tendons.

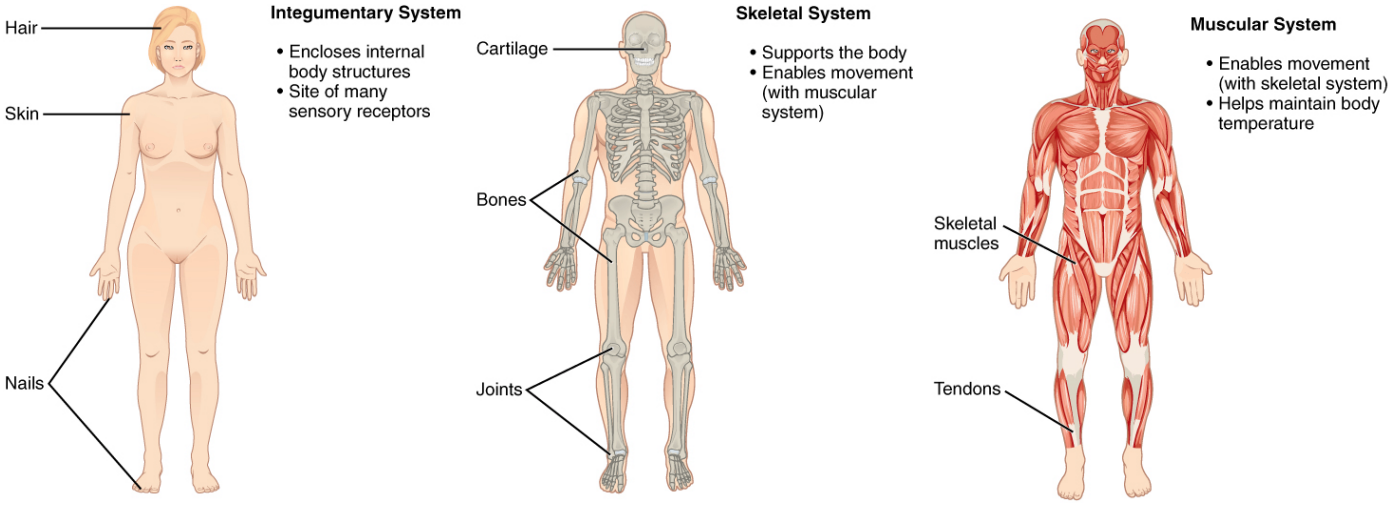

Figure 1.3.2A: Organ Systems. Organization of organs into systems and and the major functions of that system. *(Image credit: "Organ Systems I" by OpenStax is licensed under CC BY 3.0)*

- The **nervous system** detects and processes sensory information and activates bodily responses. The main organs that perform these functions are the brain, spinal cord, and peripheral nerves. It also includes sensory organs such as the eyes.
- The **endocrine system** is responsible for secreting hormones to regulate bodily processes. Some major organs of the endocrine system include the pituitary gland, thyroid gland, pancreas, adrenal glands, testes, and ovaries.
- The **cardiovascular system** delivers oxygen and nutrients to tissues while also removing wastes, and helps to distribute heat around the body. This is accomplished by the heart and blood vessels.

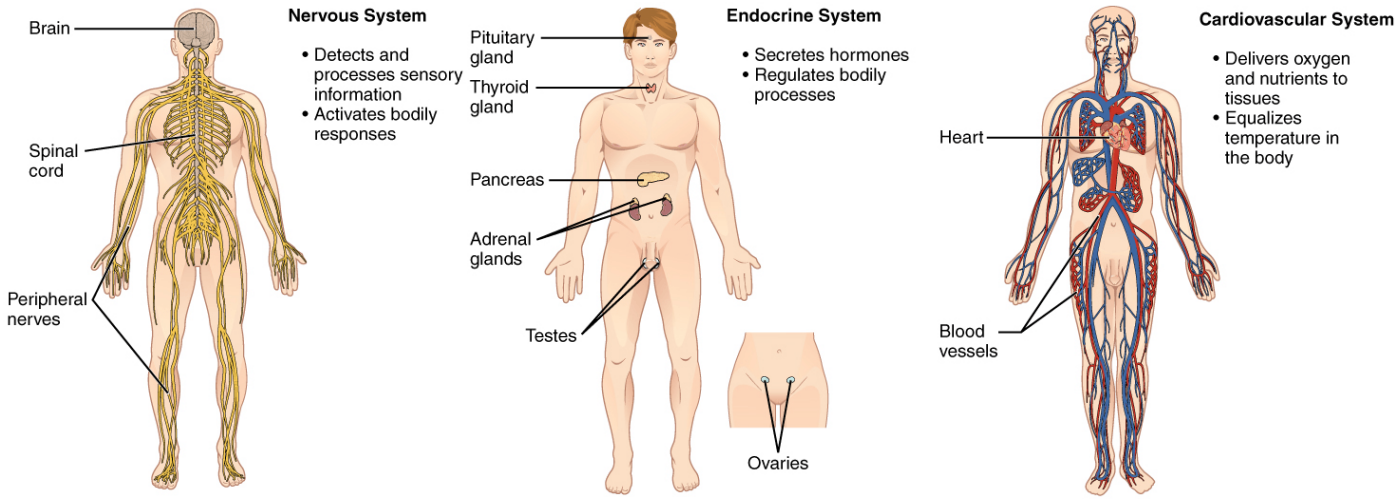

Figure 1.3.2*B*: Organ Systems. Organization of organs into systems and and the major functions of that system. *(Image credit: "Organ Systems I" by OpenStax is licensed under CC BY 3.0)*

- The **lymphatic system** functions to return fluids back to the blood and defends the body against pathogens. Major structures and organs of this system include the thymus, lymph nodes, the spleen, and lymphatic vessels.
- The **respiratory system** delivers oxygen to blood and removes carbon dioxide from the body. The nasal cavity, trachea, and lungs all work together to carry out these functions.
- The **digestive system** processes food for use by the body and removes wastes from undigested foods. Some organs of the digestive system include the stomach, liver, gallbladder, large intestine, and small intestine.

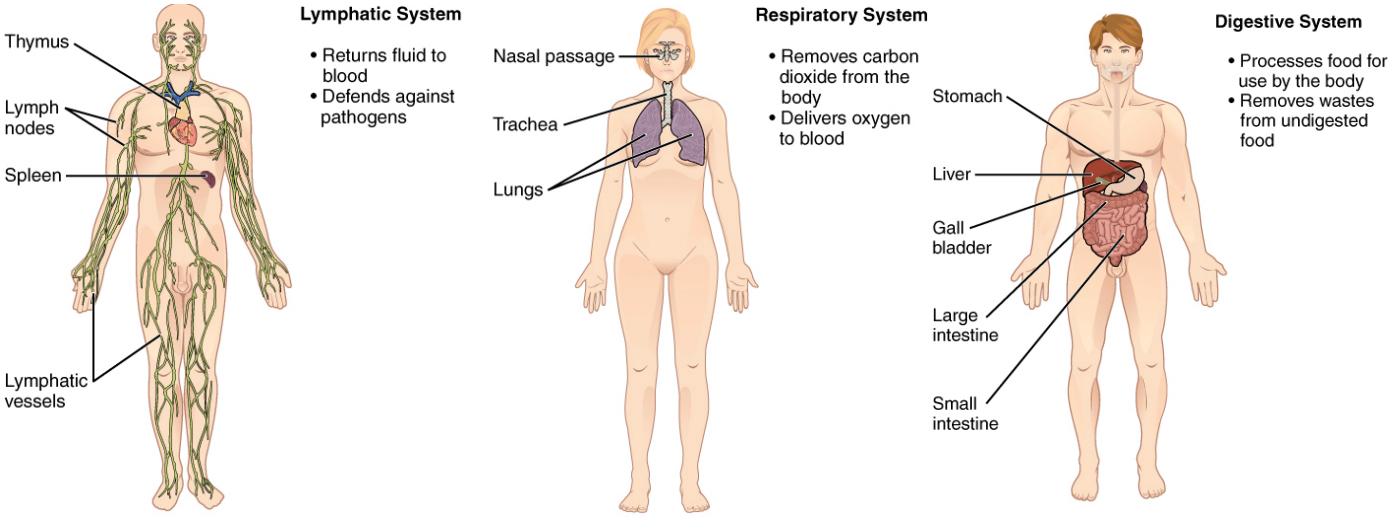

Figure 1.3.2*C*: Organ Systems. Organization of organs into systems and and the major functions of that system. *(Image credit: "Organ Systems I" by OpenStax is licensed under CC BY 3.0)*

- The **urinary system** controls water balance in the body and removes wastes from the blood and excretes them. The kidneys and bladder are major organs of this system.
- The **reproductive systems** produces sex hormones and gametes. The male reproductive system also functions to deliver gametes to the female, while the female reproductive system supports an embryo/fetus until birth and produces milk for an infant. Organs of the male reproductive system include the testes, penis, and prostate gland. Organs of the female reproductive system include the mammary glands, ovaries, uterine tubes, and the uterus.

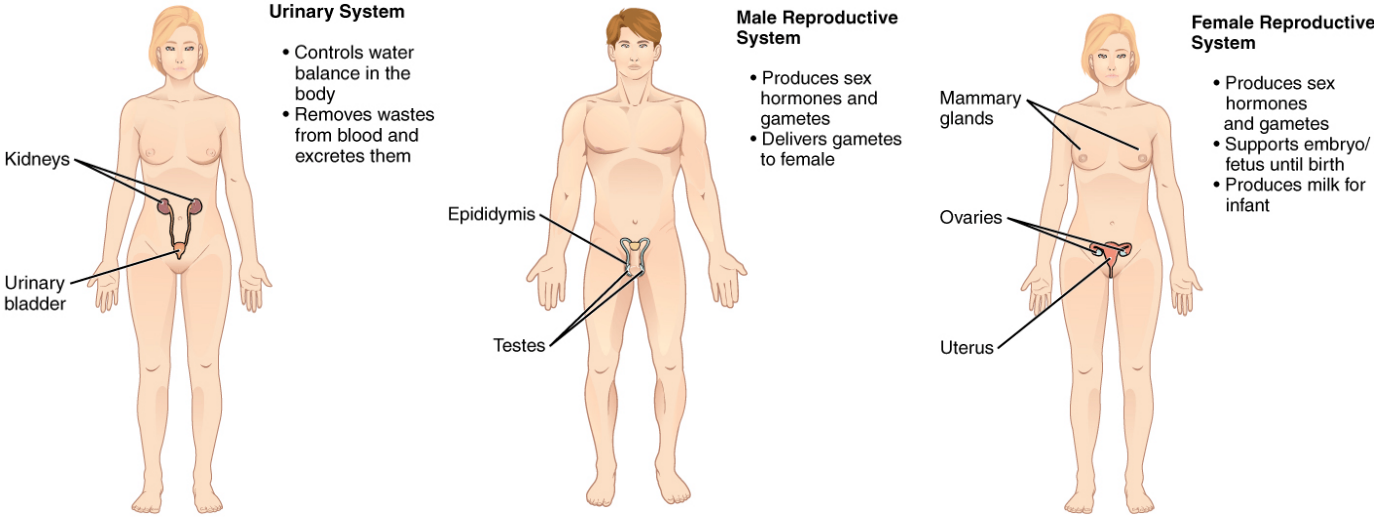

Figure 1.3.2*D*: Organ Systems. Organization of organs into systems and and the major functions of that system. *(Image credit: "Organ Systems I" by OpenStax is licensed under CC BY 3.0)*

While only some functions and major organs of each system have been listed above, each of these organ systems will be covered in much greater detail in the following chapters of this book.

The **organism level**, when many organ systems work harmoniously together to perform the functions of an independent organism, is the highest level of organization in the study of human anatomy. An **organism** is a living being that has a cellular structure and that can independently perform all physiologic functions necessary for life. In multicellular organisms, including humans, all cells, tissues, organs, and organ systems of the body work together to maintain the life and health of the organism.

Concept Review

Life processes of the human body are maintained at several levels of structural organization. These include the chemical, cellular, tissue, organ, organ system, and the organism level. Higher levels of organization are built from lower levels. Therefore, molecules combine to form cells, cells combine to form tissues, tissues combine to form organs, organs combine to form organ systems, and organ systems combine to form organisms.

Review Questions

Query 1.3.1

This interactive element is not available in this format. Visit the link or scan the QR code to access it online.

View this Interactive Content online

Critical Thinking Questions

Query 1.3.2

This interactive element is not available in this format. Visit the link or scan the QR code to access it online.

View this Interactive Content online

Glossary

Query 1.3.3

This interactive element is not available in this format. Visit the link or scan the QR code to access it online.

View this Interactive Content online

Contributors and Attributions

- OpenStax Anatomy & Physiology (CC BY 4.0). Access for free at https://openstax.org/books/anatomy-and-physiology

This page titled 1.3: Structural Organization of the Human Body is shared under a CC BY-NC-SA 4.0 license and was authored, remixed, and/or curated by Jennifer Lange et al..

- 1.3: Structural Organization of the Human Body by Whitney Menefee, Julie Jenks, Chiara Mazzasette, and Kim-Leiloni Nguyen is licensed CC BY 4.0.

1.4: Anatomical Terminology

By the end of the section, you will be able to:

- Demonstrate the anatomical position
- Describe the human body using directional and regional terms
- Identify three planes most commonly used in the study of anatomy
- Distinguish between the posterior (dorsal) and anterior (ventral) body cavities, identifying their subdivisions and representative organs found in each
- Describe a serous membrane and explain its function

Anatomists and health care providers use terminology that can be bewildering to the uninitiated. However, the purpose of this language is not to confuse, but rather to increase precision and reduce medical errors. For example, is a scar “above the wrist” located on the forearm two or three inches away from the hand? Or is it at the base of the hand? Is it on the palm-side or back-side? By using precise anatomical terminology, we eliminate ambiguity. Anatomical terms derive from ancient Greek and Latin words. Because these languages are no longer used in everyday conversation, the meaning of their words does not change.

Anatomical terms are made up of roots, prefixes, and suffixes. The root of a term often refers to an organ, tissue, or condition, whereas the prefix or suffix often describes the root. For example, in the disorder hypertension, the prefix “hyper-” means “high” or “over,” and the root word “tension” refers to pressure, so the word “hypertension” refers to abnormally high blood pressure.

Anatomical Position

To further increase precision, anatomists standardize the way in which they view the body. Just as maps are normally oriented with north at the top, the standard body “map,” or **anatomical position**, is that of the body standing upright, with the feet at shoulder width and parallel, toes forward. The upper limbs are held out to each side, and the palms of the hands face forward as illustrated in Figure 1.4.1. Using this standard position reduces confusion. It does not matter how the body being described is oriented, the terms are used as if it is in anatomical position. For example, a scar in the “anterior (front) carpal (wrist) region” would be present on the palm side of the wrist. The term “anterior” would be used even if the hand were palm down on a table.

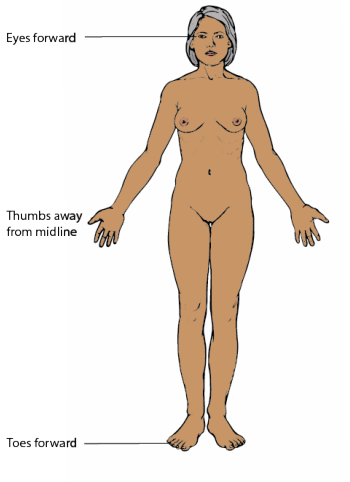

Figure 1.4.1: Anatomical Position. The human body is shown in anatomical position: 1) facing viewer, 2) arms straight with palms forward, 3) legs straight with toes forward. *(Image credit: "Anatomical Position" by Sofia Elizondo is licensed under CC BY-NC-SA 4.0.)*

A body that is lying down is described as either prone or supine. **Prone** describes a face-down orientation, and **supine** describes a face up orientation. These terms are sometimes used in describing the position of the body during specific physical examinations

or surgical procedures.

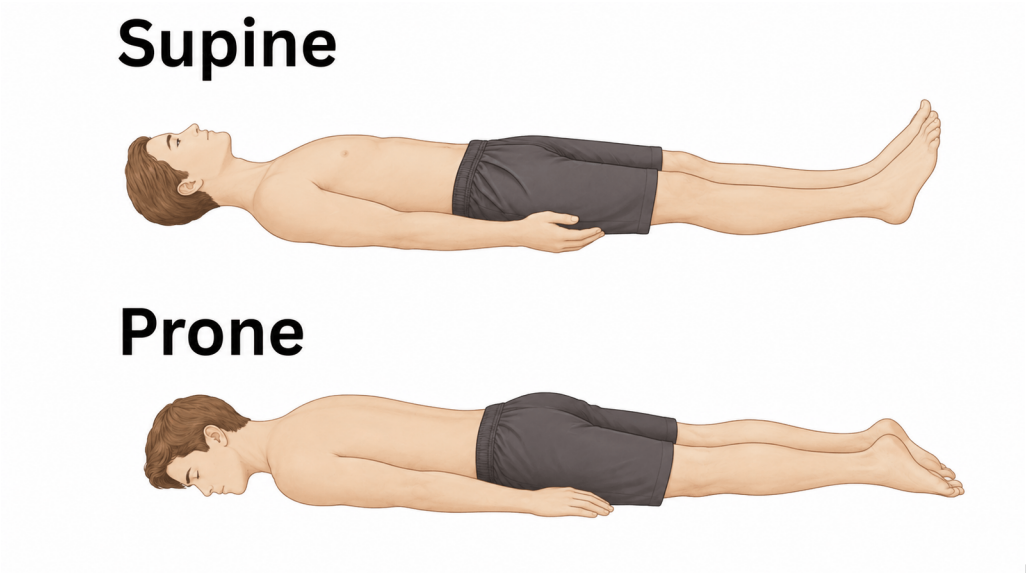

Figure 1.4.2: Supine and Prone. Terms for postions of the body while lying down: supine is face up, lying on the back; prone is face down, lying on the stomach. *(Image credit: "Supine and Prone Body Positions" by Jennifer Lange is licensed under CC BY-NC-SA 4.0, created with ChatGPT.*

Regional Terms

The human body's numerous regions have specific terms to help increase precision. Figure 1.4.3 has labeled each region with the specific anatomical term in its adjective form. You will be able to describe the body's regions using the terms from the figure as well as from the following chart:

Anatomical Terminology Used for Regions of the Body

Anatomical Term (Adjective)	Anatomical Term (Noun)	Common Name/Description
Abdominal	Abdominus	Belly
Antebrachial	Antebrachium	Forearm
Antecubital		Front of elbow
Axillary	Axilla	Armpit
Brachial	Brachium	Upper arm
Calcaneal	Calcaneus	Heel
Carpal	Carpus	Wrist
Cephalic		Head
Cervical		Neck
Coxal	Coxa	Hip
Cranial	Cranium	Skull
Crural	Crux	Lower leg (between knee and ankle)
Digital	Digit	Fingers and toes
Femoral		Thigh
Frontal		Forehead
Gluteal		Butt

Anatomical Term (Adjective)	Anatomical Term (Noun)	Common Name/Description
Inguinal		Groin - junction of trunk and thigh
Lumbar		Lower back
Mammary		Breast
Manual	Manus	Hand
Nasal		Nose
Occipital		Back of the Head
Olecranal		Point/posterior side of the elbow
Oral		Mouth
Orbital	Orbit	Eye socket
Palmar	Palm	Palm - anterior side of hand
Patellar		Kneecap
Pelvic		Pelvis - hip bones
Pedal	Pes	Foot
Plantar		Sole of the foot
Popliteal		Back of the knee
Pubic		Anterior, inferior pelvis
Sacral		Triangular region at the base of the spine
Sternal		Breastbone
Sural		Calf
Tarsal	Tarsus	Posterior foot
Thoracic	Thorax	Chest and upper back; ribcage
Vertebral		Spine

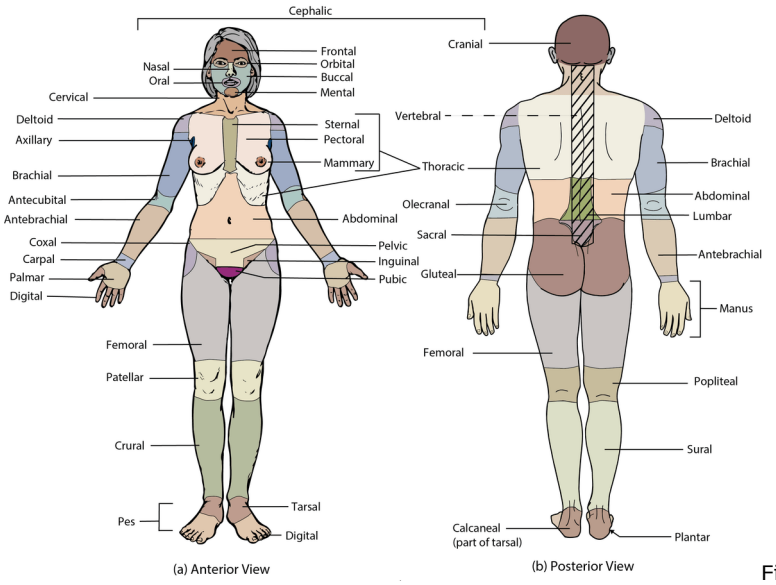

Figure 1.4.3: Anatomical Terms for Body Regions. Note that some regions are on both the anterior (a) aspect and the posterior (b) aspect, while others are on one side or the other only. *(Image credit: "Regions of the Body" by Sofia Elizondo is licensed under CC BY-NC-SA 4.0.)*

Directional Terms

Certain directional anatomical terms appear throughout this and any other anatomy textbook (Figure 1.4.4). These terms are essential for describing the relative locations of different body structures. For instance, an anatomist might describe one band of tissue as “inferior to” another or a physician might describe a tumor as “superficial to” a deeper body structure. Commit these terms to memory to avoid confusion when you are studying or describing the locations of particular body parts.

- **Anterior** (or **ventral**) describes the front or direction toward the front of the body. The toes are anterior to the foot.
- **Posterior** (or **dorsal**) describes the back or direction toward the back of the body. The popliteus is posterior to the patella.
- **Superior** (or **cranial**) describes a position above or higher than another part of the body proper. The orbits are superior to the oris.
- **Inferior** (or **caudal**) describes a position below or lower than another part of the body proper; near or toward the tail (in humans, the coccyx, or lowest part of the spinal column). The pelvis is inferior to the abdomen.
- **Lateral** describes the side or direction toward the side of the body. The pollex (thumb) is lateral to the digits.
- **Medial** describes the middle or direction toward the middle of the body. The hallux (big toe) is the medial toe.
- **Proximal** describes a position in a limb that is nearer to the point of attachment or the trunk of the body. The brachium is proximal to the antebrachium.
- **Distal** describes a position in a limb that is farther from the point of attachment or the trunk of the body. The crus is distal to the femur.
- **Superficial** describes a position closer to the surface of the body. The skin is superficial to the bones.
- **Deep** describes a position farther from the surface of the body. The brain is deep to the skull.

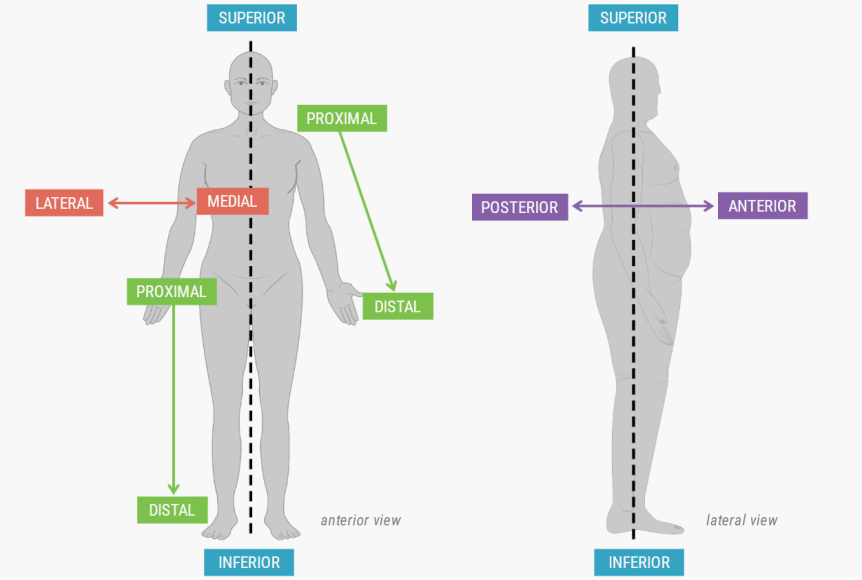

Figure 1.4.4: Directional Terms Applied to the Human Body. Paired, but opposite, directional terms are shown as applied to the human body at either end of the same arrow. *(Image credit: "Anatomical Positioning" by Clinical Anatomy is licensed under CC BY-NC-SA 4.0.)*

Body Planes

A section is a two-dimensional surface of a three-dimensional structure that has been cut. Modern medical imaging devices enable clinicians to obtain “virtual sections” of living bodies. We call these scans. Body sections and scans can be correctly interpreted, however, only if the viewer understands the plane along which the section was made. A **plane** is an imaginary two-dimensional surface that passes through the body. There are three planes commonly referred to in anatomy and medicine, as illustrated in Figure 1.4.5.

- The **sagittal plane** is the plane that divides the body or an organ vertically into right and left sides. If this vertical plane runs directly down the middle of the body, it is called the midsagittal or median plane. If it divides the body into unequal right and left sides, it is called a parasagittal plane or less commonly a longitudinal section.
- The **frontal plane** is the plane that divides the body or an organ vertically into an anterior (front) portion and a posterior (rear) portion. The frontal plane is also referred to as a coronal plane. (“Corona” is Latin for “crown.”)

- The **transverse plane** is the plane that divides the body or organ horizontally into upper and lower portions. Transverse planes produce images referred to as cross sections.

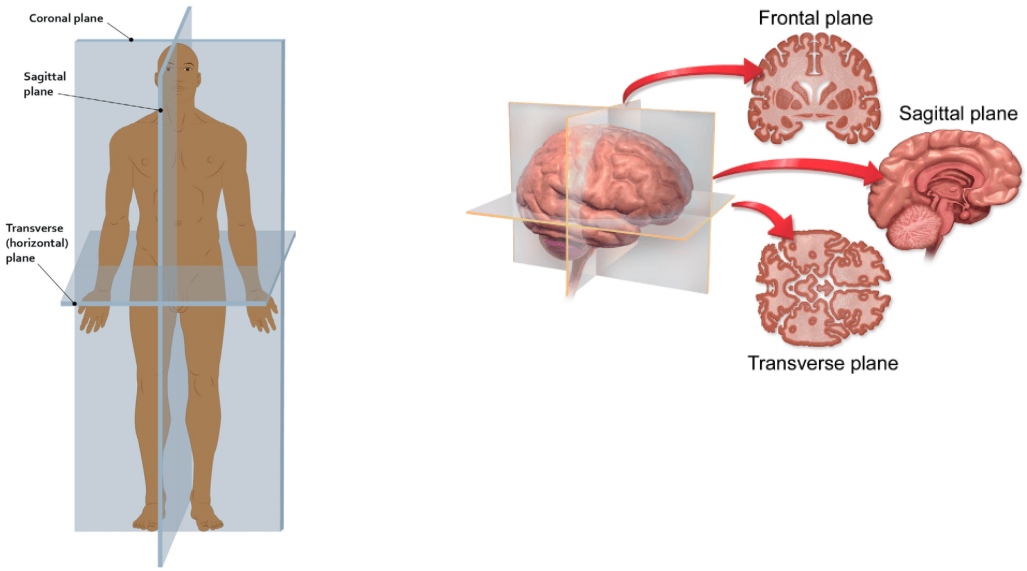

Figure 1.4.5: Planes of the human body. The three planes most commonly used in anatomical and medical imaging are the sagittal, frontal (or coronal), and transverse plane. *(Image credits: "Planes of Section" by University of British Columbia Clinical Anatomy is licensed under CC BY-NC-SA 4.0; "Blausen 0104 Brain x-secs SectionalPlanes" by Blausen.com staff (2014). "Medical gallery of Blausen Medical 2014". WikiJournal of Medicine 1 (2). DOI:10.15347/wjm/2014.010. ISSN 2002-4436. is licensed under CC BY 3.0)*

Video

Watch the video “Anatomical Terms and Body Planes Explained (Directional Terms)” below to learn more about anatomical terminology and body planes used in anatomy.

This interactive element is not available in this format. Visit the link or scan the QR code to access it online.

View this YouTube Video online

Body Cavities and Serous Membranes

The body maintains its internal organization by means of membranes, sheaths, and other structures that separate compartments. The **dorsal (posterior) cavity** and the **ventral (anterior) cavity** are the largest body compartments (Figure 1.4.4). These cavities contain and protect delicate internal organs, and the ventral cavity allows for significant changes in the size and shape of the organs as they perform their functions. The lungs, heart, stomach, and intestines, for example, can expand and contract without distorting other tissues or disrupting the activity of nearby organs.

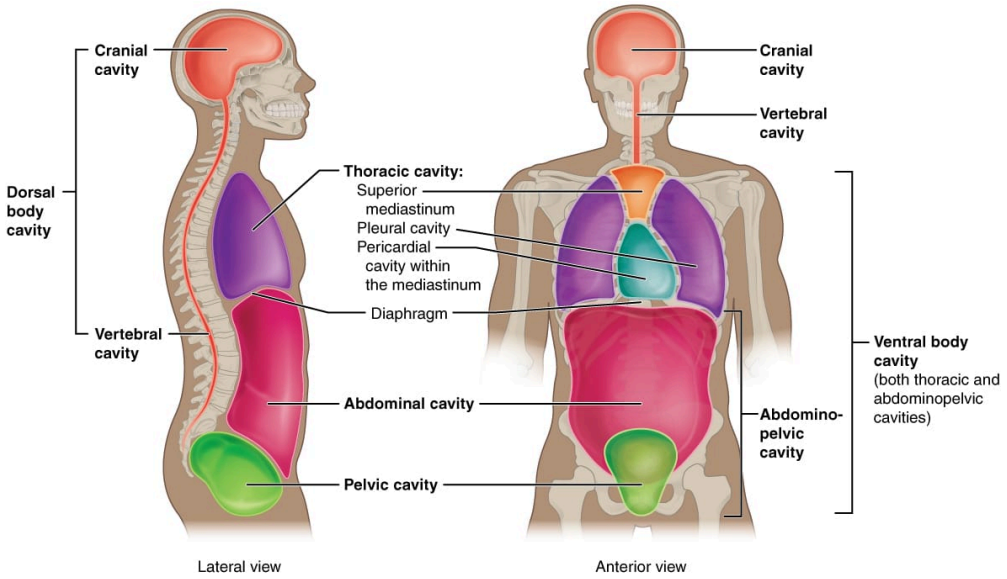

Figure 1.4.4: Dorsal and Ventral Body Cavities. The ventral cavity includes the thoracic and abdominopelvic cavities and their subdivisions. The dorsal cavity includes the cranial and spinal cavities. (Image credit: "Dorsal Ventral Body Cavities" by OpenStax is licensed under CC BY 3.0)

Subdivisions of the Posterior (Dorsal) and Anterior (Ventral) Cavities

The posterior (dorsal) and anterior (ventral) cavities are each subdivided into smaller cavities. In the posterior (dorsal) cavity, the **cranial cavity** houses the brain, and the **spinal cavity** (or vertebral cavity) encloses the spinal cord. Just as the brain and spinal cord make up a continuous, uninterrupted structure, the cranial and spinal cavities that house them are also continuous. The brain and spinal cord are protected by the bones of the skull and vertebral column and by cerebrospinal fluid, a colorless fluid produced by the brain, which cushions the brain and spinal cord within the posterior (dorsal) cavity.

The anterior (ventral) cavity has two main subdivisions: the thoracic cavity and the abdominopelvic cavity (see Figure 1.4.4). The **thoracic cavity** is the more superior subdivision of the anterior cavity, and it is enclosed by the rib cage. It contains the pleural cavities, which house the lungs, and the mediastinum, the space between the lungs in the thoracic cavity. The mediastinum has a superior portion, which contains the trachea and esophagus, and an inferior portion containing the pericardial cavity, which surrounds the heart. The diaphragm forms the floor of the thoracic cavity and separates it from the more inferior abdominopelvic cavity. The **abdominopelvic cavity** is the largest cavity in the body. Although no membrane physically divides the abdominopelvic cavity into more specific compartments, it can be useful to distinguish between the abdominal cavity, the division that houses the digestive organs, and the pelvic cavity, the division that houses the organs of reproduction.

Abdominal Regions and Quadrants

To promote clear communication, for instance about the location of a patient's abdominal pain or a suspicious mass, health care providers typically divide up the cavity into either nine regions or four quadrants (Figure 1.4.5).

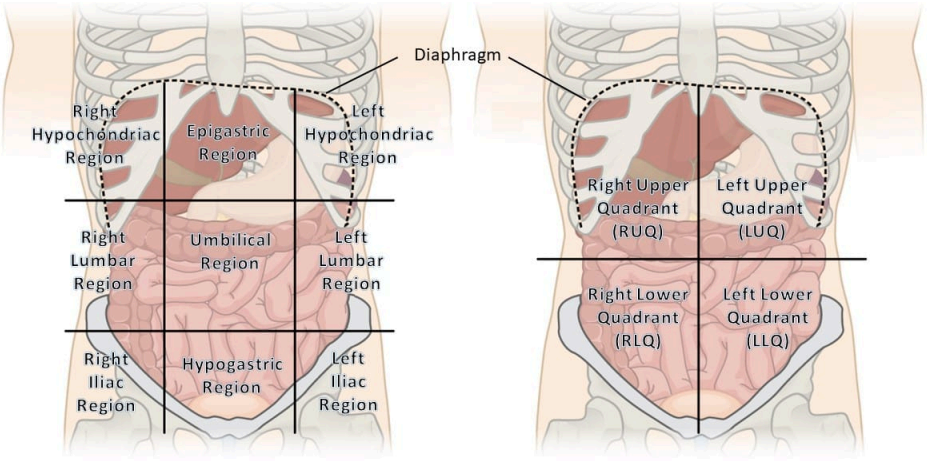

Figure 1.4.5: Regions and Quadrants of the Peritoneal Cavity. There are (a) nine abdominal regions and (b) four abdominal quadrants in the peritoneal cavity. (Image credit: "Abdominal Quadrant and Regions" by Whitney Menefee is licensed under CC BY 4.0 / A derivative from the original work)

The more detailed regional approach subdivides the cavity with one horizontal line immediately inferior to the ribs and one immediately superior to the pelvis, and two vertical lines drawn as if dropped from the midpoint of each clavicle (collarbone). There are nine resulting regions:

- Right hypochondriac region containing a portion of liver.
- Right lumbar region containing the ascending colon and a portion of the small intestine.
- Right iliac region containing the appendix, the cecum and a portion of the small intestine.
- Epigastric region containing the pancreas, gall bladder, and portions of the stomach and liver.
- Umbilical region containing the transverse colon and a portion of the small intestine.
- Hypogastric region containing a portion of the small intestine and the bladder.
- Left hypochondriac region containing the spleen and portion of the stomach
- Left lumbar region containing the descending colon and a portion of the small intestine.
- Left iliac region containing the sigmoid colon and a portion of the small intestine.

The simpler quadrants approach, which is more commonly used in medicine, subdivides the cavity with one horizontal and one vertical line that intersect at the patient's umbilicus (navel). This results in four quadrants:

- Right upper quadrant (RUQ) containing the right lobe of liver, the gall bladder, the duodenum, head of the pancreas, the right kidney and adrenal gland, portions of the colon.
- Right lower quadrant (RLQ) containing the cecum, the appendix, the ascending colon, and the right ureter.
- Left upper quadrant (LUQ) containing the stomach, the spleen, left lobe of the liver, body of the pancreas, the left kidney and adrenal gland, and portions of the colon.
- Left lower quadrant (LLQ) containing the descending colon, the sigmoid colon, portions of the small intestine, and the left ureter.

Membranes of the Anterior (Ventral) Body Cavity

A **serous membrane** (also referred to a serosa) is one of the thin membranes that cover the walls and organs in the thoracic and abdominopelvic cavities. The parietal layers of the membranes line the walls of the body cavity (pariet- refers to a cavity wall). The visceral layer of the membrane covers the organs (the viscera). Between the parietal and visceral layers is a very thin, fluid-filled serous space, or cavity (Figure 1.4.6).

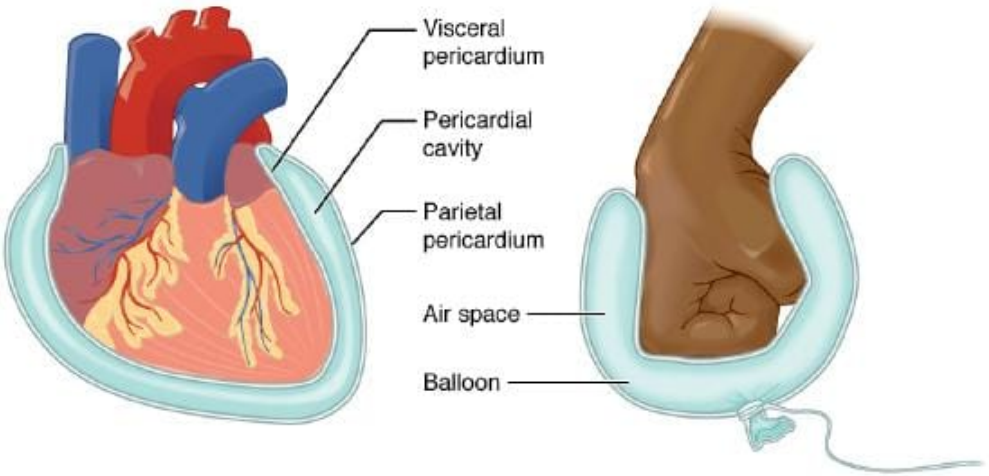

Figure 1.4.6: Serous Membrane. Serous membrane lines the pericardial cavity and reflects back to cover the heart—much the same way that an under inflated balloon would form two layers surrounding a fist. (Image credit: "Serous Membrane" by OpenStax is licensed under CC BY 3.0)

There are three serous cavities and their associated membranes. The **pleura** is the serous membrane that surrounds the lungs in the pleural cavity; the **pericardium** is the serous membrane that surrounds the heart in the pericardial cavity; and the **peritoneum** is the serous membrane that surrounds several organs in the abdominopelvic cavity. The serous fluid produced by the serous membranes reduces friction between the walls of the cavities and the internal organs when they move, such as when the lungs inflate or the heart beats. Both the parietal and visceral serosa secrete the thin, slippery serous fluid that prevents friction when an organ slides past the walls of a cavity. In the pleural cavities, pleural fluid prevents friction between the lungs and the walls of the cavity. In the pericardial sac, pericardial fluid prevents friction between the heart and the walls of the pericardial sac. And in the peritoneal cavity, peritoneal fluid prevents friction between abdominal and pelvic organs and the wall of the cavity. The serous membranes therefore provide additional protection to the viscera they enclose by reducing friction that could lead to inflammation of the organs.

Concept Review

A standard reference position for mapping the body's structures is the normal anatomical position. Regions of the body are identified using terms such as "occipital" that are more precise than common words and phrases such as "the back of the head." Directional terms such as anterior and posterior are essential for accurately describing the relative locations of body structures. Images of the body's interior commonly align along one of three planes: the sagittal, frontal, or transverse. The body's organs are organized in one of two main cavities — dorsal and ventral — which are further sub-divided according to the structures present in each area. The serous membranes have two layers — parietal and visceral — surrounding a fluid filled space. Serous membranes cover the lungs (pleural serosa), heart (pericardial serosa), and some abdominopelvic organs (peritoneal serosa).

Review Questions

Query 1.4.1

This interactive element is not available in this format. Visit the link or scan the QR code to access it online.

View this Interactive Content online

Critical Thinking Questions

Query 1.4.2

This interactive element is not available in this format. Visit the link or scan the QR code to access it online.

View this Interactive Content online

Glossary

Query 1.4.3

This interactive element is not available in this format. Visit the link or scan the QR code to access it online.

View this Interactive Content online

Contributors and Attributions

- OpenStax Anatomy & Physiology (CC BY 4.0). Access for free at https://openstax.org/books/anatomy-and-physiology

This page titled 1.4: Anatomical Terminology is shared under a CC BY-NC-SA 4.0 license and was authored, remixed, and/or curated by Jennifer Lange et al..

- 1.6: Anatomical Terminology by Whitney Menefee, Julie Jenks, Chiara Mazzasette, and Kim-Leiloni Nguyen is licensed CC BY 4.0.

1.5: Medical Imaging

By the end of the section, you will be able to:

- Discuss the uses and drawbacks of X-ray imaging
- Identify four modern medical imaging techniques and how they are used

For thousands of years, fear of the dead and legal sanctions limited the ability of anatomists and physicians to study the internal structures of the human body. An inability to control bleeding, infection, and pain made surgeries infrequent, and those that were performed—such as wound suturing, amputations, tooth and tumor removals, skull drilling, and cesarean births—did not greatly advance knowledge about internal anatomy. Theories about the function of the body and about disease were therefore largely based on external observations and imagination. During the fourteenth and fifteenth centuries, however, the detailed anatomical drawings of Italian artist and anatomist Leonardo da Vinci and Flemish anatomist Andreas Vesalius were published, and interest in human anatomy began to increase. Medical schools began to teach anatomy using human dissection; although some resorted to grave robbing to obtain corpses. Laws were eventually passed that enabled students to dissect the corpses of criminals and those who donated their bodies for research. Still, it was not until the late nineteenth century that medical researchers discovered non-surgical methods to look inside the living body.

X-Rays

German physicist Wilhelm Röntgen (1845–1923) was experimenting with electrical current when he discovered that a mysterious and invisible “ray” would pass through his flesh but leave an outline of his bones on a screen coated with a metal compound. In 1895, Röntgen made the first durable record of the internal parts of a living human: an “X-ray” image (as it came to be called) of his wife’s hand. Scientists around the world quickly began their own experiments with X-rays, and by 1900, X-rays were widely used to detect a variety of injuries and diseases. In 1901, Röntgen was awarded the first Nobel Prize for physics for his work in this field.

The **X-ray** is a form of high energy electromagnetic radiation with a short wavelength capable of penetrating solids and ionizing gases. As they are used in medicine, X-rays are emitted from an X-ray machine and directed toward a specially treated metallic plate placed behind the patient’s body. The beam of radiation results in darkening of the X-ray plate. X-rays are slightly impeded by soft tissues, which show up as gray on the X-ray plate, whereas hard tissues, such as bone, largely block the rays, producing a light-toned “shadow.” Thus, X-rays are best used to visualize hard body structures such as teeth and bones (Figure 1.5.1). Like many forms of high energy radiation, however, X-rays are capable of damaging cells and initiating changes that can lead to cancer. This danger of excessive exposure to X-rays was not fully appreciated for many years after their widespread use.

Figure 1.5.1: X-Ray of a Hand. High energy electromagnetic radiation allows the internal structures of the body, such as bones, to be seen in X-rays like these. (Image credit:"X-Ray of Hand" by OpenStax is licensed under CC BY 3.0)

Refinements and enhancements of X-ray techniques have continued throughout the twentieth and twenty-first centuries. Although often supplanted by more sophisticated imaging techniques, the X-ray remains a “workhorse” in medical imaging, especially for viewing fractures and for dentistry. The disadvantage of irradiation to the patient and the operator is now attenuated by proper shielding and by limiting exposure.

Modern Medical Imaging

X-rays can depict a two-dimensional image of a body region, and only from a single angle. In contrast, more recent medical imaging technologies produce data that is integrated and analyzed by computers to produce three-dimensional images or images that reveal aspects of body functioning.

Computed Tomography

Tomography refers to imaging by sections. **Computed tomography (CT)** is a noninvasive imaging technique that uses computers to analyze several cross-sectional X-rays in order to reveal minute details about structures in the body (Figure 1.5.2.a). The technique was invented in the 1970s and is based on the principle that, as X-rays pass through the body, they are absorbed or reflected at different levels. In the technique, a patient lies on a motorized platform while a computerized axial tomography (CAT) scanner rotates 360 degrees around the patient, taking X-ray images. A computer combines these images into a two-dimensional view of the scanned area, or “slice.”

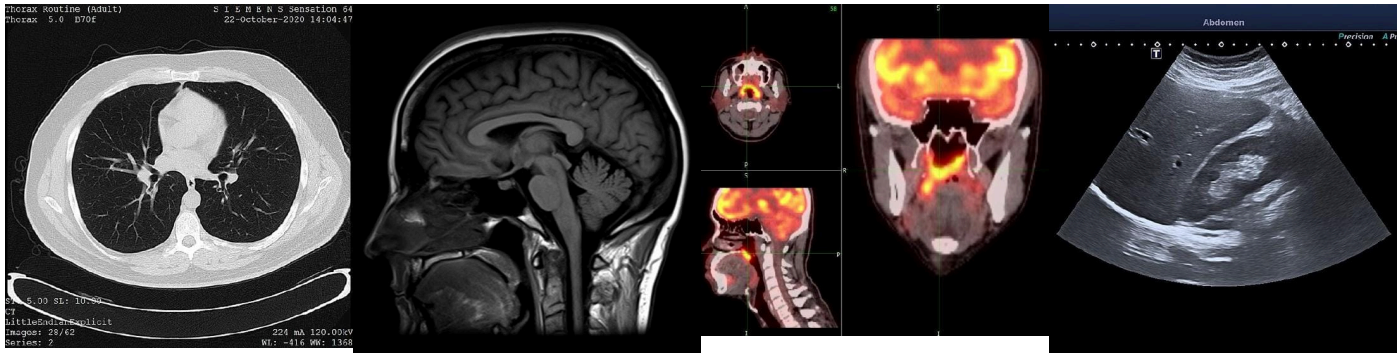

Figure 1.5.2: Medical Imaging Techniques. (a) CT scan of the thorax. (b) MRI of the head. (c) PET scan of the head. (d) Ultrasound of the upper abdomen. *(Image credit: "Medical Imaging Techniques" by Jennifer Lange is licensed under CC BY-NC-SA 4.0, a compendium of images: CT scan from Ptrump16, CC BY-SA 4.0, via Wikimedia Commons; MRI from Case courtesy of Assoc Prof Frank Gaillard, Radiopaedia.org, from the case rID: 2756; PET scan from Sanko, CC BY-SA 3.0, via Wikimedia Commons; Ultrasound from Ptrump16, CC BY-SA 4.0, via Wikimedia Commons.)*

Since 1970, the development of more powerful computers and more sophisticated software has made CT scanning routine for many types of diagnostic evaluations. It is especially useful for soft tissue scanning, such as of the brain and the thoracic and abdominal viscera. Its level of detail is so precise that it can allow physicians to measure the size of a mass down to a millimeter. The main disadvantage of CT scanning is that it exposes patients to a dose of radiation many times higher than that of X-rays. In fact, children who undergo CT scans are at increased risk of developing cancer, as are adults who have multiple CT scans.

Magnetic Resonance Imaging

Magnetic resonance imaging (MRI) is a noninvasive medical imaging technique based on a phenomenon of nuclear physics discovered in the 1930s, in which matter exposed to magnetic fields and radio waves was found to emit radio signals. In 1970, a physician and researcher named Raymond Damadian noticed that malignant (cancerous) tissue gave off different signals than normal body tissue. He applied for a patent for the first MRI scanning device, which was in use clinically by the early 1980s. The early MRI scanners were crude, but advances in digital computing and electronics led to their advancement over any other technique for precise imaging, especially to discover tumors. The images created are really a set of hundreds of images that can be scrolled through section by section. To see this visualization visit Radiopedia.org and scroll up and down through the brain images related to this case - several views are available using different techniques and running in each of the three planes. MRI also has the major advantage of not exposing patients to radiation.

Drawbacks of MRI scans include their much higher cost, and patient discomfort with the procedure. The MRI scanner subjects

the patient to such powerful electromagnets that the scan room must be shielded. The patient must be enclosed in a metal tube-like device for the duration of the scan (see Figure $1.5.2.b$), sometimes as long as thirty minutes, which can be uncomfortable and impractical for ill patients. The device is also so noisy that, even with earplugs, patients can become anxious or even fearful. These problems have been overcome somewhat with the development of "open" MRI scanning, which does not require the patient to be entirely enclosed in the metal tube. Patients with iron-containing metallic implants (internal sutures, some prosthetic devices, and so on) cannot undergo MRI scanning because it can dislodge these implants.

Functional MRIs (fMRIs), which detect the concentration of blood flow in certain parts of the body, are increasingly being used to study the activity in parts of the brain during various body activities. This has helped scientists learn more about the locations of different brain functions and more about brain abnormalities and diseases.

Positron Emission Tomography

Positron emission tomography (PET) is a medical imaging technique involving the use of so-called radiopharmaceuticals, substances that emit radiation that is short-lived and therefore relatively safe to administer to the body. Although the first PET scanner was introduced in 1961, it took 15 more years before radiopharmaceuticals were combined with the technique and revolutionized its potential. The main advantage is that PET (see Figure $1.5.2.c$) can illustrate physiologic activity—including nutrient metabolism and blood flow—of the organ or organs being targeted, whereas CT and MRI scans can only show static images. PET is widely used to diagnose a multitude of conditions, such as heart disease, the spread of cancer, certain forms of infection, brain abnormalities, bone disease, and thyroid disease.

Ultrasonography

Ultrasonography is an imaging technique that uses the transmission of high-frequency sound waves into the body to generate an echo signal that is converted by a computer into a real-time image of anatomy and physiology (see Figure $1.5.2.d$). Ultrasonography is the least invasive of all imaging techniques, and it is therefore used more freely in sensitive situations such as pregnancy. The technology was first developed in the 1940s and 1950s. Ultrasonography is used to study heart function, blood flow in the neck or extremities, certain conditions such as gallbladder disease, and fetal growth and development. The main disadvantages of ultrasonography are that the image quality is heavily operator-dependent and that it is unable to penetrate bone and gas.

Concept Review

Detailed anatomical drawings of the human body first became available in the fifteenth and sixteenth centuries; however, it was not until the end of the nineteenth century, and the discovery of X-rays, that anatomists and physicians discovered non-surgical methods to look inside a living body. Since then, many other techniques, including CT scans, MRI scans, PET scans, and ultrasonography, have been developed, providing more accurate and detailed views of the form and function of the human body.

Review Questions

Query $1.5.1$

This interactive element is not available in this format. Visit the link or scan the QR code to access it online.

View this Interactive Content online

Query 1.5.2

This interactive element is not available in this format. Visit the link or scan the QR code to access it online.

View this Interactive Content online

Critical Thinking Questions

Query 1.5.3

This interactive element is not available in this format. Visit the link or scan the QR code to access it online.

View this Interactive Content online

Query 1.5.4

This interactive element is not available in this format. Visit the link or scan the QR code to access it online.

View this Interactive Content online

Query 1.5.5

This interactive element is not available in this format. Visit the link or scan the QR code to access it online.

View this Interactive Content online

Glossary

Query 1.5.6

This interactive element is not available in this format. Visit the link or scan the QR code to access it online.

View this Interactive Content online

Contributors and Attributions

- OpenStax Anatomy & Physiology (CC BY 4.0). Access for free at https://openstax.org/books/anatomy-and-physiology

This page titled 1.5: Medical Imaging is shared under a CC BY-NC-SA 4.0 license and was authored, remixed, and/or curated by Jennifer Lange et al..

- 1.7: Medical Imaging by Whitney Menefee, Julie Jenks, Chiara Mazzasette, and Kim-Leiloni Nguyen is licensed CC BY 4.0.

1.6: Anatomical Atlas - Anatomical Terminology

A compendium of anatomical images: slides, models, and/or cadavers.

Anatomical Regions

(All images are from Clinical Anatomy, licensed under CC BY-NC-SA 4.0.)

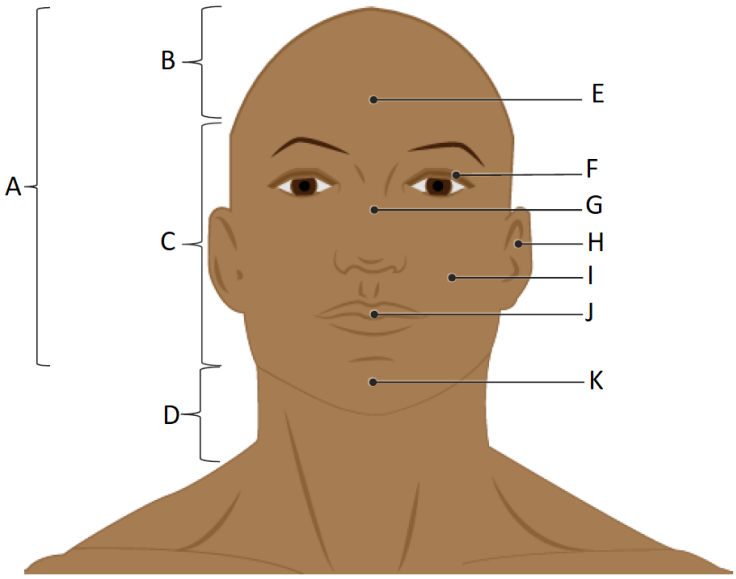

Answer Key (click to show/hide answers)

A - cephalic

B - cranial

C - facial

D - cervical

E - frontal

F - ocular/orbital

G - nasal

H - otic

I - buccal

J - oral

K - mental

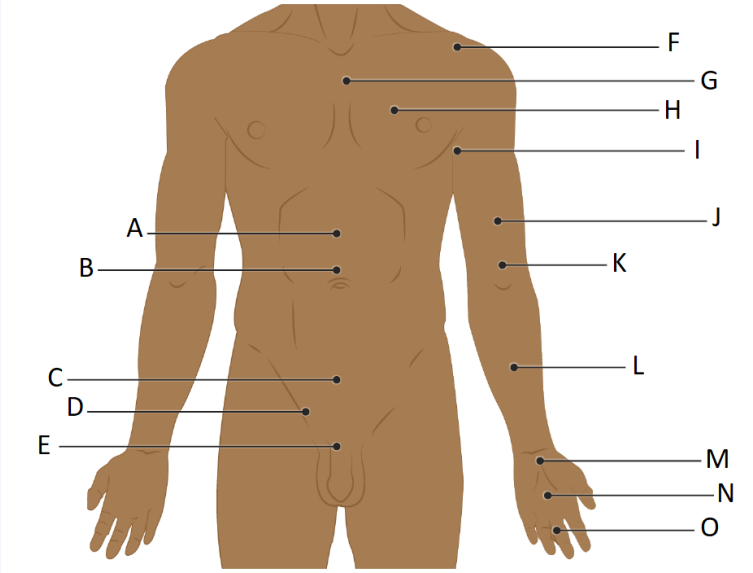

Answer Key (click to show/hide answers)

A - abdominal

B - umbilical

C - pelvic

D - inguinal

E - pelvic

F - acromial

G - thoracic

H - pectoral

I - axillary

J - brachial

K - antecubital

L - antebrachial

M - carpal

N - palmar

O - digital

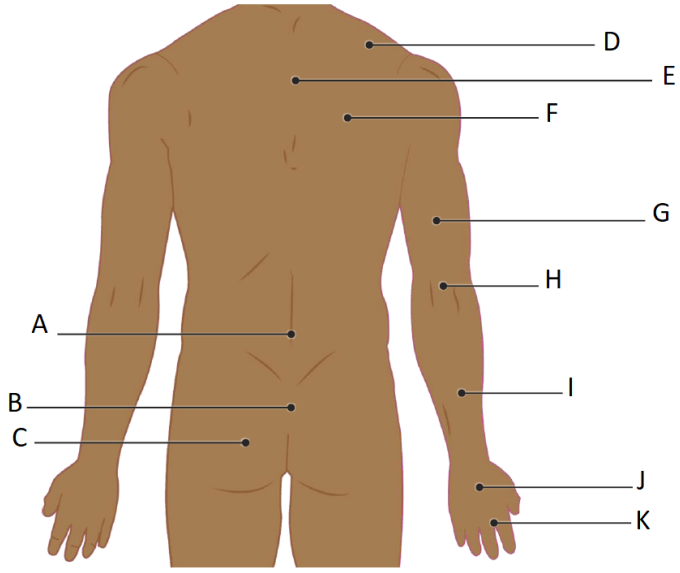

Answer Key (click to show/hide answers)

A - lumbar

B - sacral

C - gluteal

D - acromial

E - vertebral

F - thoracic

G - brachial

H - olecranal

I - antebrachial

J - manual

K - digital

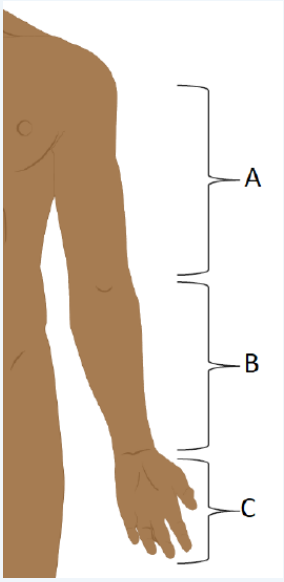	**Answer Key (click to show/hide answers)** A - brachial B - antebrachial C - manual
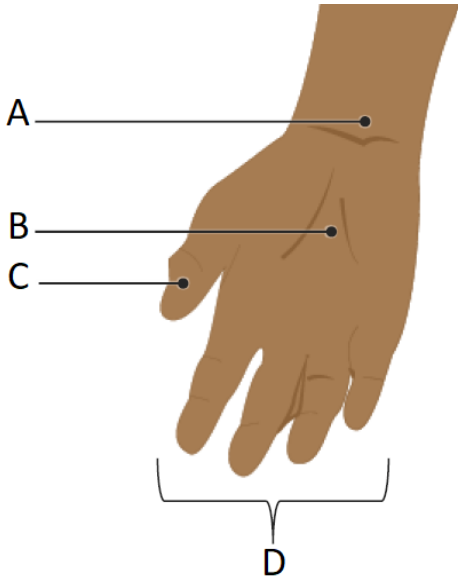	**Answer Key (click to show/hide answers)** A - carpal B - palmar C - pollex D - digital

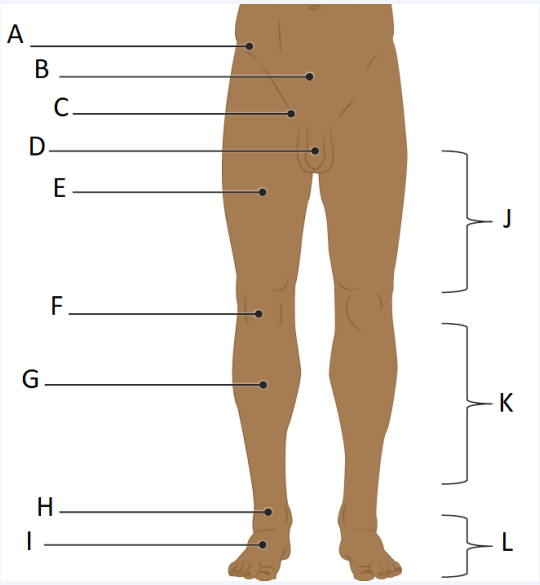

Answer Key (click to show/hide answers)

A - coxal

B - pelvic

C - inguinal

D - genital

E - femoral

F - patellar

G - crural

H - tarsal

I - pedal

J - femoral

K - crural

L - pedal

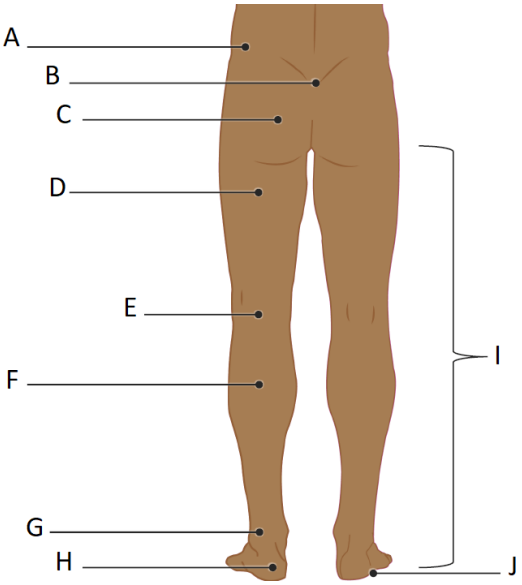

Answer Key (click to show/hide answers)

A - coxal

B - sacral

C - gluteal

D - femoral

E - popliteal

F - sural

G - tarsal

H - calcaneal

I - lower limb

J - calcaneal

This page titled 1.6: Anatomical Atlas - Anatomical Terminology is shared under a CC BY-NC-SA 4.0 license and was authored, remixed, and/or curated by Jennifer Lange et al..

1.7: Practice Practical - Anatomy Introduction

To answer each of the questions below, type your answer in the box(es).

Query 1.7.1

This interactive element is not available in this format. Visit the link or scan the QR code to access it online.

View this Interactive Content online

Query 1.7.1

This interactive element is not available in this format. Visit the link or scan the QR code to access it online.

View this Interactive Content online

Query 1.7.1

This interactive element is not available in this format. Visit the link or scan the QR code to access it online.

View this Interactive Content online

This page titled 1.7: Practice Practical - Anatomy Introduction is shared under a CC BY-NC-SA 4.0 license and was authored, remixed, and/or curated by Jennifer Lange et al..

2: CELLULAR LEVEL OF ORGANIZATION

2.1: Introduction to the Cellular Level of Organization
2.2: The Cell Membrane
2.3: The Cytoplasm and Cellular Organelles
2.4: The Nucleus
2.5: Cell Growth and Division
2.6: Cellular Differentiation

This page titled 2: Cellular Level of Organization is shared under a CC BY-NC-SA 4.0 license and was authored, remixed, and/or curated by Jennifer Lange et al..

- 2: Cellular Level of Organization by Whitney Menefee, Julie Jenks, Chiara Mazzasette, and Kim-Leiloni Nguyen is licensed CC BY 4.0.

2.1: Introduction to the Cellular Level of Organization

Chapter Learning Objectives

After studying this chapter, you will be able to:

- Describe the structure and function of the cell membrane, including its regulation of materials into and out of the cell
- Describe the functions of the various cytoplasmic organelles
- Explain the structure and contents of the nucleus
- List the stages of the cell cycle in order, including the steps of cell division in somatic cells
- Discuss how a cell differentiates and becomes more specialized

You developed from a single fertilized egg cell into the complex organism containing trillions of cells that you see when you look in a mirror. During this developmental process, early, undifferentiated cells differentiate and become specialized in their structure and function. These different cell types form specialized tissues that work in concert to perform all of the functions necessary for the living organism. Cellular and developmental biologists study how the continued division of a single cell leads to such complexity and diversity in form and function.

Consider the difference between a structural cell in the skin and a nerve cell. A structural skin cell may be shaped like a flat plate (squamous) and live only for a short time before it is shed and replaced. Packed tightly into rows and sheets, the squamous skin cells provide a protective barrier for the cells and tissues that lie beneath. A nerve cell, on the other hand, may be shaped something like a star, sending out long processes up to a meter in length and may live for the entire lifetime of the organism. With their long winding appendages, nerve cells can communicate with one another and with other types of body cells and send rapid signals that inform the organism about its environment and allow it to interact with that environment. These differences illustrate one very important theme that is consistent at all organizational levels of biology: the form of a structure is optimally suited to perform particular functions assigned to that structure. Keep this theme in mind as you tour the inside of a cell and are introduced to the various types of cells in the body.

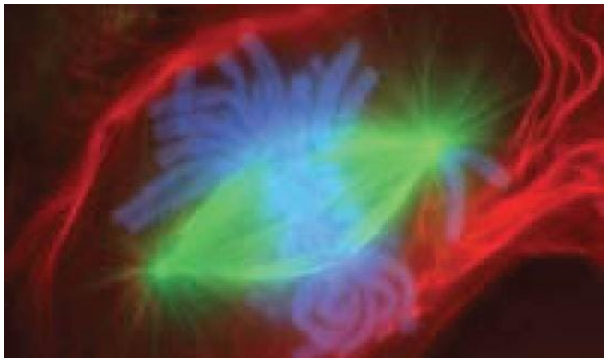

Figure 2.1.1: Fluorescence-stained Cell Undergoing Mitosis. A lung cell from a newt, commonly studied for its similarity to human lung cells, is stained with fluorescent dyes. The green stain reveals mitotic spindles, red is the cell membrane and part of the cytoplasm, and the structures that appear light blue are chromosomes. This cell is in anaphase of mitosis. (Image credit: "Flourescence Stained new" by OpenStax is licensed under CC BY 4.0)

In spite of their diversity, a primary responsibility of every cell is to contribute to homeostasis. Homeostasis is a term used in biology that refers to a dynamic state of balance within parameters that are compatible with life. For example, living cells require a water-based environment to survive in, and there are various physical (anatomical) and physiological mechanisms that keep all of the trillions of living cells in the human body moist. This is one aspect of homeostasis. When a particular parameter, such as blood pressure or blood oxygen content, moves far enough *out* of homeostasis (generally becoming too high or too low), illness or disease—and sometimes death—inevitably results.

Contributors and Attributions

- OpenStax Anatomy & Physiology (CC BY 4.0). Access for free at https://openstax.org/books/anatomy-and-physiology

This page titled 2.1: Introduction to the Cellular Level of Organization is shared under a CC BY-NC-SA 4.0 license and was authored, remixed, and/or curated by Jennifer Lange et al..

- 2.1: Introduction to the Cellular Level of Organization by Whitney Menefee, Julie Jenks, Chiara Mazzasette, and Kim-Leiloni Nguyen is licensed CC BY 4.0.

2.2: The Cell Membrane

By the end of the section, you will be able to:

- Describe the molecular components that make up the cell membrane
- Explain the major features and properties of the cell membrane

Despite differences in structure and function, all living cells in multicellular organisms have a surrounding cell membrane. As the outer layer of your skin separates your body from its environment, the cell membrane (also known as the plasma membrane) separates the inner contents of a cell from its exterior environment. This cell membrane provides a protective barrier around the cell and regulates which materials can pass in or out.

Structure and Composition of the Cell Membrane

The **cell membrane** is an extremely pliable structure composed primarily of back-to-back phospholipids (a "bilayer"). Cholesterol is also present, which contributes to the fluidity of the membrane, and there are various proteins embedded within the membrane that have a variety of functions.

A single phospholipid molecule has a phosphate group on one end, called the "head," and two side-by-side chains of fatty acids that make up the lipid tails (Figure 2.2.1). The phosphate group, which includes a phosphate and glycerol, is negatively charged, making the head polar and hydrophilic—or "water loving." A **hydrophilic** molecule (or region of a molecule) is one that is attracted to water. The phosphate heads are thus attracted to the water molecules of both the extracellular and intracellular environments. The lipid tails, on the other hand, are uncharged, or nonpolar, and are hydrophobic—or "water fearing." A **hydrophobic** molecule (or region of a molecule) repels and is repelled by water. Some lipid tails consist of saturated fatty acids, which form straight tails, and some contain unsaturated fatty acids, which form kinked tails. This combination adds to the fluidity of the tails that are constantly in motion. Phospholipids are thus amphipathic molecules. An **amphipathic** molecule is one that contains both a hydrophilic and a hydrophobic region. In fact, soap works to remove oil and grease stains because it has amphipathic properties. The hydrophilic portion can dissolve in water while the hydrophobic portion can trap grease in micelles that then can be washed away.

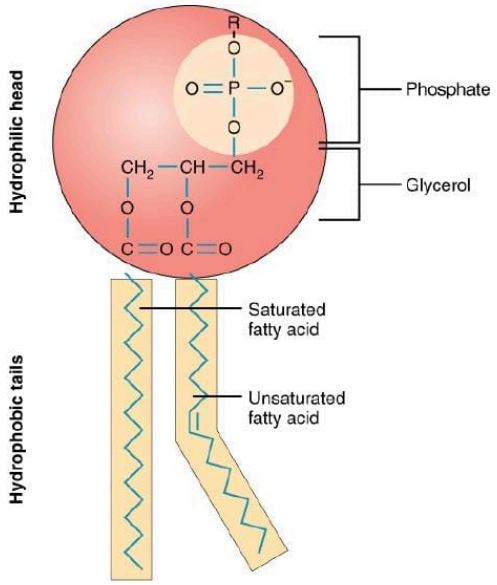

Figure 2.2.1: Phospholipid Structure. A phospholipid molecule consists of a polar phosphate "head," which is hydrophilic and a non-polar lipid "tail," which is hydrophobic. Unsaturated fatty acids result in kinks in the hydrophobic tails. (Image credit: "Phospholipid Structure" by OpenStax is licensed under CC BY 4.0)

The cell membrane consists of two adjacent layers of phospholipids. The lipid tails of one layer face the lipid tails of the other

layer, meeting at the interface of the two layers. The phospholipid heads face outward, one layer exposed to the interior of the cell and one layer exposed to the exterior (Figure 2.2.2). Because the phosphate groups are polar and hydrophilic, they are attracted to water in the intracellular fluid. **Intracellular fluid (ICF)** is the fluid interior of the cell. The phosphate groups are also attracted to the extracellular fluid. **Extracellular fluid (ECF)** is the fluid environment outside the enclosure of the cell membrane. **Interstitial fluid (ISF)** is the term given to extracellular fluid not contained within blood vessels. Because the lipid tails are hydrophobic, they meet in the inner region of the membrane, excluding watery intracellular and extracellular fluid from this space. The cell membrane has many proteins, as well as other lipids (such as cholesterol), that are associated with the phospholipid bilayer. An important feature of the membrane is that it remains fluid; the lipids and proteins in the cell membrane are not rigidly locked in place.

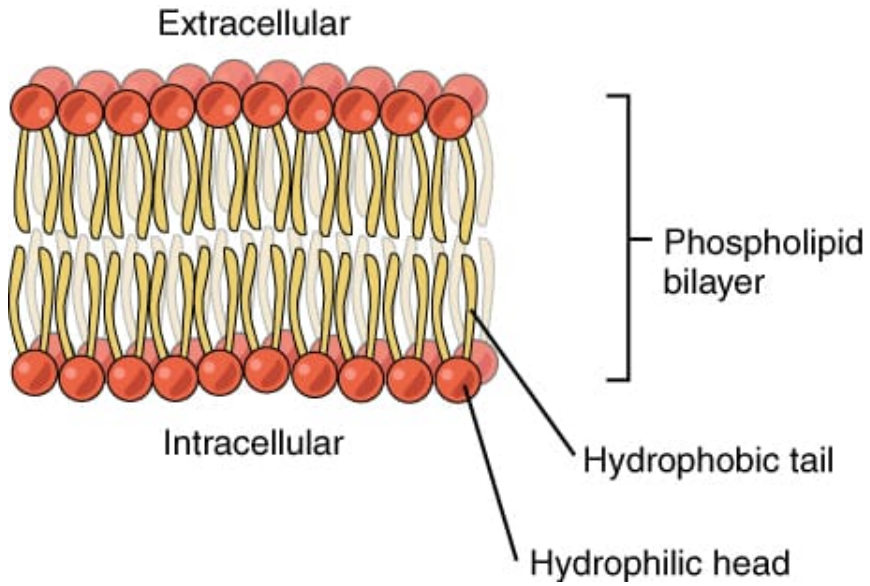

Figure 2.2.2: Phospholipid Bilayer. The phospholipid bilayer consists of two adjacent sheets of phospholipids, arranged tail to tail. The hydrophobic tails associate with one another, forming the interior of the membrane. The polar heads contact the fluid inside and outside of the cell. *(Image credit: "Phospholipid Bilayer" by OpenStax is licensed under CC BY 4.0)*

Membrane Proteins

The lipid bilayer forms the basis of the cell membrane, but it is peppered throughout with various proteins. Two different types of proteins that are commonly associated with the cell membrane are the integral proteins and peripheral proteins (Figure 2.2.3). As its name suggests, an **integral protein** is a protein that is embedded in the membrane. A **channel protein** is an example of an integral protein that selectively allows particular materials, such as certain ions, to pass into or out of the cell.

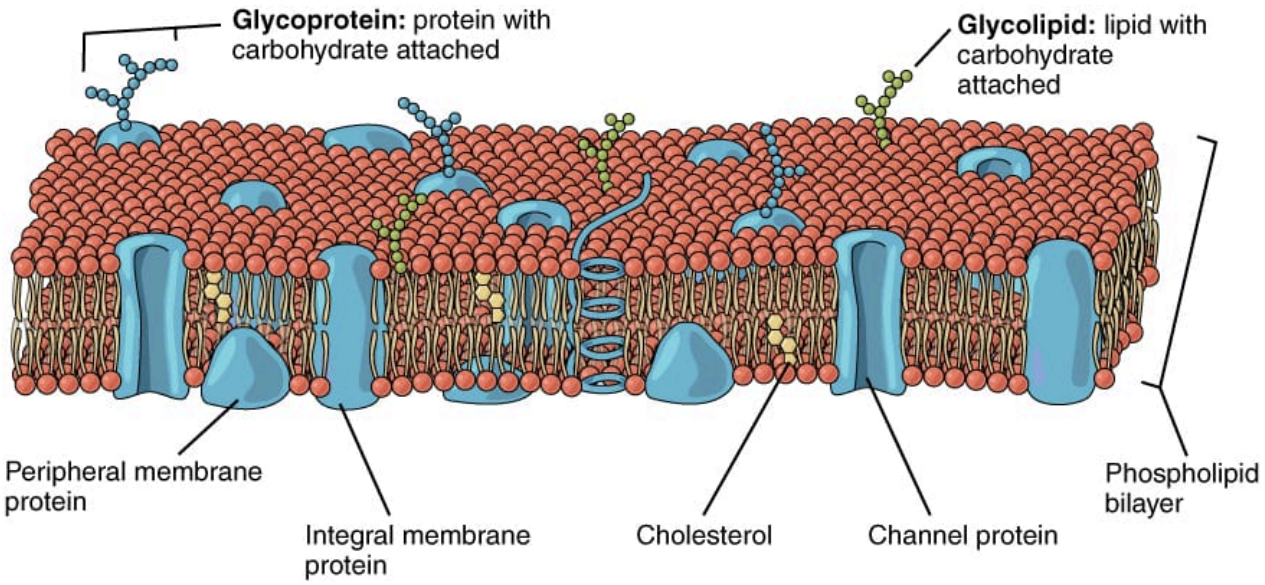

Figure 2.2.3: Cell Membrane. The cell membrane of the cell is a phospholipid bilayer containing many different molecular components, including proteins and cholesterol, some with carbohydrate groups attached. *(Image credit: "Lipid Bilayer With Various Components" by OpenStax is licensed under CC BY 4.0)*

Another important group of integral proteins are cell recognition proteins, which serve to mark a cell's identity so that it can be recognized by other cells. A **receptor** is a type of recognition protein that can selectively bind a specific molecule outside the cell, and this binding induces a chemical reaction within the cell. A **ligand** is the specific molecule that binds to and activates a receptor. Some integral proteins serve dual roles as both a receptor and an ion channel. One example of a receptor-ligand interaction is the receptors on nerve cells that bind neurotransmitters, such as dopamine. When a dopamine molecule binds to a dopamine receptor protein, a channel within the transmembrane protein opens to allow certain ions to flow into the cell.

Some integral membrane proteins are glycoproteins. A **glycoprotein** is a protein that has carbohydrate molecules attached, which extend into the extracellular matrix. The attached carbohydrate tags on glycoproteins aid in cell recognition. The carbohydrates that extend from membrane proteins and even from some membrane lipids collectively form the glycocalyx. The **glycocalyx** is a fuzzy-appearing coating around the cell formed from glycoproteins and other carbohydrates attached to the cell membrane. The glycocalyx can have various roles. For example, it may have molecules that allow the cell to bind to another cell, it may contain receptors for hormones, or it might have enzymes to break down nutrients. The glycocalyces found in your body are products of your genetic makeup. They give each of your trillions of cells the "identity" of belonging in your body. This identity is the primary way that your immune defense cells "know" not to attack your own body cells, but it also is the reason organs donated by another person might be rejected.

Peripheral proteins are typically found on the inner or outer surface of the lipid bilayer but can also be attached to the internal or external surface of an integral protein. These proteins typically perform a specific function for the cell. Some peripheral proteins on the surface of intestinal cells, for example, act as digestive enzymes to break down nutrients to sizes that can pass through the cells and into the bloodstream.

Extensions of the Plasma Membrane

The plasma membrane is not always just a smooth round surface. Some cells may have extensions or folds of the plasma membrane, such as microvilli, flagella, or cilia. **Microvilli** are small folds in the plasma membrane that help to increase the surface area for purpose of transport of materials. Extensions like **flagellum** and **cilia** can be used to produce movement by the cytoskeleton, which is discussed further in another section of this chapter. You can compare the structure of these three extensions in Figure 2.2.4 below.

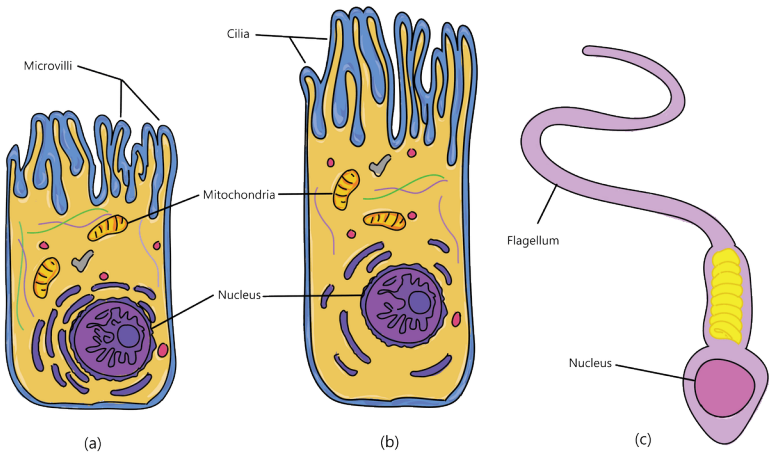

Figure 2.2.4: Extensions of the Plasma Membrane. Cells with specialized functions may have extensions of their plasma membrane including (a) microvilli (b) cilia or (c) a flagellum. *(Image credit: "Extensions of the Plasma Membrane" by Whitney Menefee is a derivative from the original work of Daniel Donnelly and is licensed under CC BY 4.0)*

Transport across the Cell Membrane

One of the great wonders of the cell membrane is its ability to regulate the concentration of substances inside the cell. These substances include ions such as Ca^{++}, Na^{+}, K^{+}, and Cl^{-}; nutrients including sugars, fatty acids, and amino acids; and waste products, particularly carbon dioxide (CO_2), that must leave the cell.

The membrane's lipid bilayer structure provides the first level of control. The phospholipids are tightly packed together, and the membrane has a hydrophobic interior. This structure causes the membrane to be selectively permeable. A membrane that has **selective permeability** allows only substances meeting certain criteria to pass through it unaided. In the case of the cell membrane, only relatively small, nonpolar materials can move through the lipid bilayer (remember, the lipid tails of the membrane are nonpolar). Some examples of these are other lipids, oxygen and carbon dioxide gases, and alcohol. However, water-soluble materials—like glucose, amino acids, and electrolytes—need some assistance to cross the membrane because they are repelled by the hydrophobic tails of the phospholipid bilayer. All substances that move through the membrane do so by one of two general methods, which are categorized based on whether or not energy is required. **Passive transport** is the movement of substances across the membrane without the expenditure of cellular energy. In contrast, **active transport** is the movement of substances across the membrane using energy from adenosine triphosphate (ATP).

Passive Transport

In order to understand how substances move passively across a cell membrane, it is necessary to understand concentration gradients and diffusion. A **concentration gradient** is the difference in concentration of a substance across a space. Molecules (or ions) will spread/diffuse from where they are more concentrated to where they are less concentrated until they are equally distributed in that space. (When molecules move in this way, they are said to move down their concentration gradient.) **Diffusion** is the movement of particles from an area of higher concentration to an area of lower concentration. A couple of common examples will help to illustrate this concept. Imagine being inside a closed bathroom. If a bottle of perfume were sprayed, the scent molecules would naturally diffuse from the spot where they left the bottle to all corners of the bathroom, and this diffusion would go on until no more concentration gradient remains. Another example is a spoonful of sugar placed in a cup of tea. Eventually the sugar will diffuse throughout the tea until no concentration gradient remains. In both cases, if the room is warmer or the tea hotter, diffusion occurs even faster as the molecules are bumping into each other and spreading out faster than at cooler temperatures. Having an internal body temperature around 98.6 °F thus also aids in diffusion of particles within the body.

Whenever a substance exists in greater concentration on one side of a semipermeable membrane, such as the cell membrane, any substance that can move down its concentration gradient across the membrane will do so. Consider substances that can easily diffuse through the lipid bilayer of the cell membrane, such as the gases oxygen (O_2) and CO_2. O_2 generally diffuses into

cells because it is more concentrated outside of them, and CO_2 typically diffuses out of cells because it is more concentrated inside of them. Neither of these examples requires any energy on the part of the cell, and therefore they use passive transport to move across the membrane. Solutes dissolved in water on either side of the cell membrane will tend to diffuse down their concentration gradients, but because most substances cannot pass freely through the lipid bilayer of the cell membrane, their movement is restricted to protein channels and specialized transport mechanisms in the membrane. **Facilitated diffusion** is the diffusion process used for those substances that cannot cross the lipid bilayer due to their size and/or polarity.

Active Transport

For all of the transport methods described above as passive transport, the cell expends no energy. Membrane proteins that aid in the passive transport of substances do so without the use of ATP. During active transport however, ATP is required to move a substance across a membrane. Whenever ATP is expended to actively move substances in or out of a cell, one or more membrane proteins will be involved in the transport process. Active transport is used when moving substances against their concentration gradient or for larger molecules that cannot easily pass through a protein channel.

One of the most common types of active transport involves proteins that serve as pumps. The word “pump” probably conjures up thoughts of using energy to pump up the tire of a bicycle or a basketball, when energy is used to move air against a pressure gradient and inflate the tire or ball. Similarly, energy from ATP is required for these membrane proteins to transport substances—molecules or ions—across the membrane, usually against their concentration gradients (from an area of low concentration to an area of high concentration).

Other forms of active transport do not involve membrane carriers. **Endocytosis** (bringing “into the cell”) is the process of a cell ingesting material by enveloping it in a portion of its cell membrane, and then pinching off that portion of membrane (Figure 2.2.5). Once pinched off, the portion of membrane and its contents becomes an independent, intracellular vesicle. A **vesicle** is a membranous sac—a spherical and hollow organelle bounded by a lipid bilayer membrane. Endocytosis often brings materials into the cell that must to be broken down or digested. **Phagocytosis** (“cell eating”) is the endocytosis of large particles. Many immune cells engage in phagocytosis of invading pathogens. Like little Pac-men, their job is to patrol body tissues for unwanted matter, such as invading bacterial cells, phagocytize them, and digest them. In contrast to phagocytosis, **pinocytosis** (“cell drinking”) brings fluid containing dissolved substances into a cell through membrane vesicles.

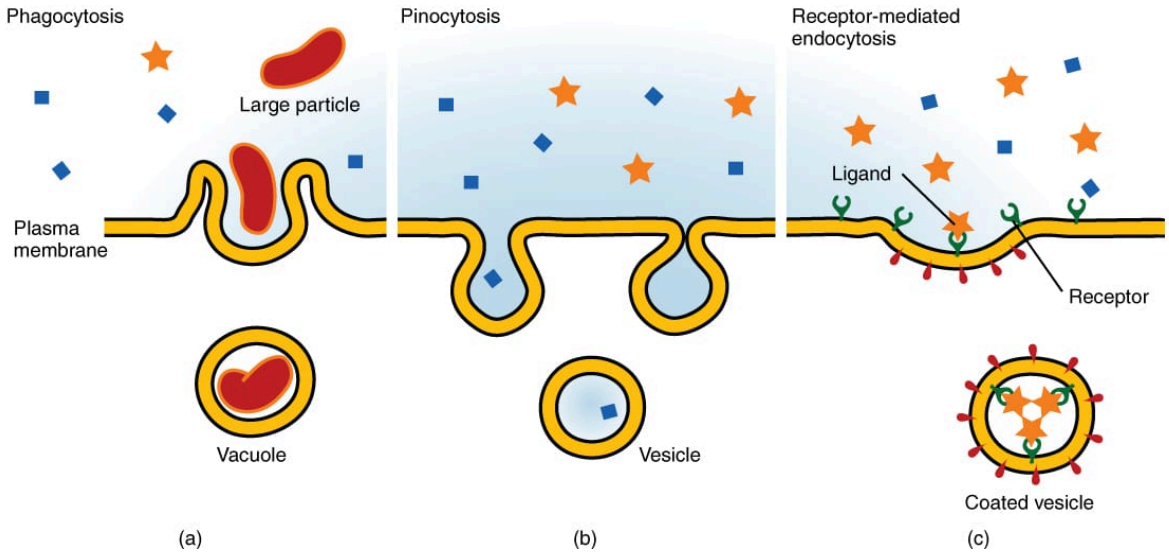

Figure 2.2.5: Three Forms of Endocytosis. Endocytosis is a form of active transport in which a cell envelopes extracellular materials using its cell membrane. (a) In phagocytosis, which is relatively nonselective, the cell takes in a large particle. (b) In pinocytosis, the cell takes in small particles in fluid. (c) In contrast, receptor-mediated endocytosis is quite selective. When external receptors bind a specific ligand, the cell responds by endocytosing the ligand. (Image credit: "Three Forms of Endocytosis" by OpenStax is licensed under CC BY 4.0)

In contrast with endocytosis, exocytosis (taking “out of the cell”) is the process of a cell exporting material using vesicular transport (Figure 2.2.6). Many cells manufacture substances that must be secreted, like a factory manufacturing a product for export. These substances are typically packaged into membrane-bound vesicles within the cell. When the vesicle membrane fuses with the cell membrane, the vesicle releases its contents into the interstitial fluid. The vesicle membrane then becomes part of the cell membrane. Examples of excocytosis include: cells of the stomach and pancreas produce and secrete digestive enzymes,

endocrine cells produce and secrete hormones that are sent throughout the body, and certain immune cells produce and secrete large amounts of histamine, a chemical important for immune responses.

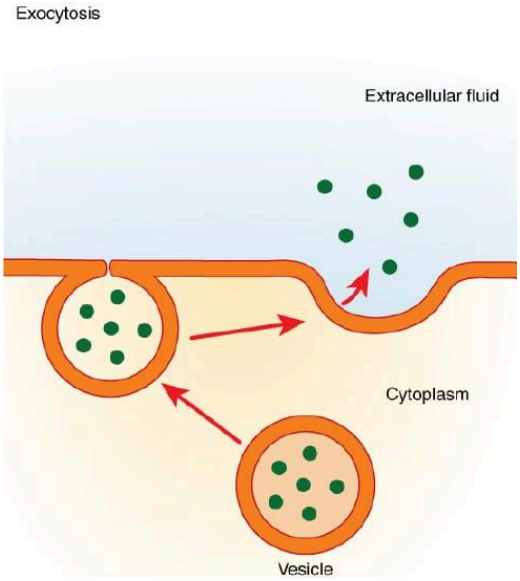

Figure 2.2.11: Exocytosis. Exocytosis is much like endocytosis in reverse. Material destined for export is packaged into a vesicle inside the cell. The membrane of the vesicle fuses with the cell membrane, and the contents are released into the extracellular space. (Image credit: "Exocytosis" by OpenStax is licensed under CC BY 4.0)

DISEASES OF THE CELL: Cystic Fibrosis

Cystic fibrosis (CF) affects approximately 30,000 people in the United States, with about 1,000 new cases reported each year. The genetic disease is most well known for its damage to the lungs, causing breathing difficulties and chronic lung infections, but it also affects the liver, pancreas, and intestines. Only about 50 years ago, the prognosis for children born with CF was very grim—a life expectancy rarely over 10 years. Today, with advances in medical treatment, average life expectancy for CF patients is in the late 30s and many live much longer.

The symptoms of CF result from a malfunctioning membrane ion channel called the cystic fibrosis transmembrane conductance regulator, or CFTR. In healthy people, the CFTR protein is an integral membrane protein that transports chloride (Cl^-) ions out of the cell. In a person who has CF, the gene for the CFTR is mutated, thus, the cell manufactures a defective channel protein that typically is not incorporated into the membrane, but is instead degraded by the cell.

The CFTR requires ATP in order to function, making its Cl^- transport a form of active transport. This characteristic puzzled researchers for a long time because the Cl^- ions are actually flowing *down* their concentration gradient when transported out of cells. Active transport generally pumps ions *against* their concentration gradient, but the CFTR presents an exception to this rule.

In normal lung tissue, the movement of Cl^- out of the cell maintains a Cl^--rich, negatively charged environment immediately outside of the cell. This is particularly important in the epithelial lining of the respiratory system. Respiratory epithelial cells secrete mucus, which serves to trap dust, bacteria, and other debris. A cilium (plural = cilia) is one of the hair-like appendages found on certain cells. Cilia on the epithelial cells move the mucus and its trapped particles up the airways away from the lungs and toward the outside. In order to be effectively moved upward, the mucus cannot be too viscous; rather it must have a thin, watery consistency. The transport of Cl^- and the maintenance of an electronegative environment outside of the cell attract positive ions such as Na^+ to the extracellular space. The accumulation of both Cl^- and Na^+ ions in the extracellular space creates solute-rich mucus, which has a low concentration of water molecules. As a result, through osmosis, water moves from cells and extracellular matrix into the mucus, “thinning” it out. This is how, in a normal respiratory system, the mucus is kept sufficiently watered-down to be propelled out of the respiratory system.

If the CFTR channel is absent, Cl^- ions are not transported out of the cell in adequate numbers, thus preventing them from drawing positive ions. The absence of ions in the secreted mucus results in the lack of a normal water concentration gradient. Thus, there is no osmotic pressure pulling water into the mucus. The resulting mucus is thick and sticky, and the ciliated epithelia cannot effectively remove it from the respiratory system. Passageways in the lungs become blocked with mucus, along with the debris it carries. Bacterial infections occur more easily because bacterial cells are not effectively carried away from the lungs.

Concept Review

The cell membrane provides a barrier around the cell, separating its internal components from the extracellular environment. It is composed of a phospholipid bilayer, with hydrophobic internal lipid "tails" and hydrophilic external phosphate "heads." Various membrane proteins are scattered throughout the bilayer, both inserted within it and attached to it peripherally. The cell membrane is selectively permeable, allowing only a limited number of materials to diffuse through its lipid bilayer. All materials that cross the membrane do so using passive (non energy-requiring) or active (energy-requiring) transport processes. During passive transport, materials move by simple diffusion or by facilitated diffusion through the membrane, down their concentration gradient. Water passes through the membrane in a diffusion process called osmosis. During active transport, energy is expended to assist material movement across the membrane. Active transport may take place with the help of protein pumps or through the use of vesicles.

Review Questions

Query 2.2.1

This interactive element is not available in this format. Visit the link or scan the QR code to access it online.

View this Interactive Content online

Query 2.2.2

This interactive element is not available in this format. Visit the link or scan the QR code to access it online.

View this Interactive Content online

Critical Thinking Questions

Query 2.2.3

This interactive element is not available in this format. Visit the link or scan the QR code to access it online.

View this Interactive Content online

Query 2.2.4

This interactive element is not available in this format. Visit the link or scan the QR code to access it online.

View this Interactive Content online

Query 2.2.5

This interactive element is not available in this format. Visit the link or scan the QR code to access it online.

View this Interactive Content online

Glossary

Query 2.2.6

This interactive element is not available in this format. Visit the link or scan the QR code to access it online.

View this Interactive Content online

Contributors and Attributions

- OpenStax Anatomy & Physiology (CC BY 4.0). Access for free at https://openstax.org/books/anatomy-and-physiology

---

This page titled 2.2: The Cell Membrane is shared under a CC BY-NC-SA 4.0 license and was authored, remixed, and/or curated by Jennifer Lange et al..

- 2.2: The Cell Membrane by Whitney Menefee, Julie Jenks, Chiara Mazzasette, and Kim-Leiloni Nguyen is licensed CC BY 4.0.

2.3: The Cytoplasm and Cellular Organelles

By the end of the section, you will be able to:

- Describe the structure and function of the cellular organelles associated with the endomembrane system, including the endoplasmic reticulum, Golgi apparatus, and lysosomes
- Describe the structure and function of mitochondria and peroxisomes
- Explain the three components of the cytoskeleton, including their composition and functions

Now that you have learned that the cell membrane surrounds all cells, you can dive inside of a prototypical human cell to learn about its internal components and their functions. All living cells in multicellular organisms contain an internal cytoplasmic compartment, and a nucleus within the cytoplasm. **Cytosol**, the jelly-like substance within the cell, provides the fluid medium necessary for biochemical reactions. Eukaryotic cells, including all animal cells, also contain various cellular organelles. An **organelle** ("little organ") is one of several different types of specialized structures in the cell, each performing a unique function. Just as the various bodily organs work together in harmony to perform all of a human's functions, the many different cellular organelles work together to keep the cell healthy and performing all of its important functions. The organelles and cytosol, taken together, compose the cell's **cytoplasm**. The **nucleus** is a cell's central organelle, which contains the cell's DNA (Figure 2.3.1).

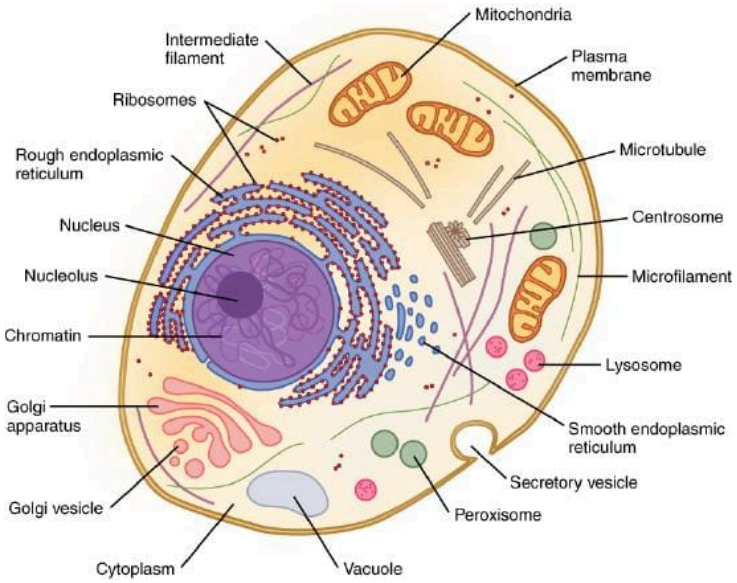

Figure 2.3.1: Prototypical Human Cell. While this image is not indicative of any one particular human cell, it is a prototypical example of a cell containing the primary organelles and internal structures. (Image credit: "Animal Cell and Components" by OpenStax is licensed under CC BY 4.0)

Organelles of the Endomembrane System

A set of three major organelles together form a system within the cell called the endomembrane system. These organelles work together to perform various cellular jobs, including the task of producing, packaging, and exporting certain cellular products. The organelles of the endomembrane system include the endoplasmic reticulum, Golgi apparatus, and vesicles.

Endoplasmic Reticulum

The **endoplasmic reticulum (ER)** is a system of channels that is continuous with the nuclear membrane (or "envelope") covering the nucleus and composed of the same lipid bilayer material. The ER can be thought of as a series of winding thoroughfares similar to the waterway canals in Venice. The ER provides passages throughout much of the cell that function in transporting, synthesizing, and storing materials. The winding structure of the ER results in a large membranous surface area that supports its

many functions (Figure 2.3.2).

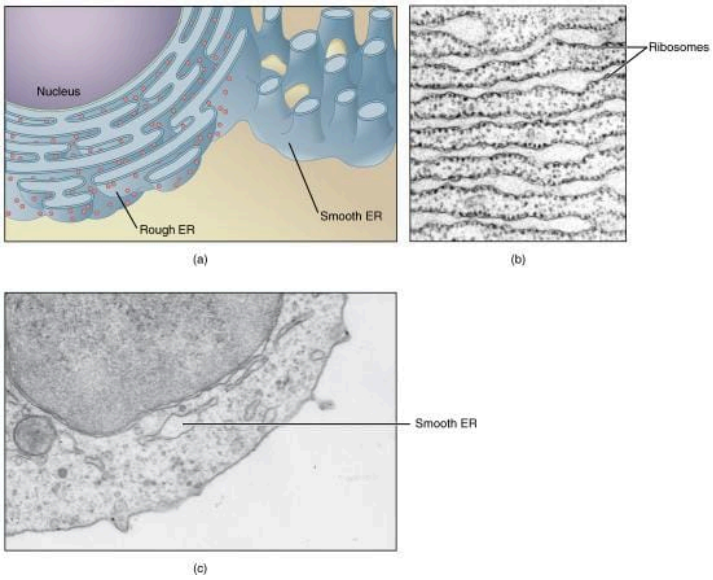

Figure 2.3.2: Endoplasmic Reticulum (ER). (a) The ER is a winding network of thin membranous sacs found in close association with the cell nucleus. The smooth and rough endoplasmic reticula are very different in appearance and function. (b) Rough ER is studded with numerous ribosomes, which are sites of protein synthesis (source: mouse tissue). EM × 110,000. (c) Smooth ER synthesizes phospholipids, steroid hormones, regulates the concentration of cellular Ca^{++},metabolizes some carbohydrates, and breaks down certain toxins (source: mouse tissue). EM × 110,510. (Image credit: "Endoplasmic Reticulum" by OpenStax is licensed under CC BY 4.0/ Micrographs provided by the Regents of University of Michigan Medical School © 2012)

Endoplasmic reticulum can exist in two forms: rough ER and smooth ER. These two types of ER perform some very different functions and can be found in very different amounts depending on the type of cell. Rough ER (RER) is so-called because its membrane is dotted with embedded granules—organelles called ribosomes, giving the RER a bumpy appearance. A **ribosome** is an organelle that serves as the site of protein synthesis. Smooth ER (SER) lacks these ribosomes.

One of the main functions of the smooth ER is in the synthesis of lipids. The smooth ER synthesizes phospholipids, the main component of biological membranes, as well as steroid hormones. For this reason, cells that produce large quantities of such hormones, such as those of the female ovaries and male testes, contain large amounts of smooth ER. In addition to lipid synthesis, the smooth ER also sequesters (i.e., stores) and regulates the concentration of cellular Ca^{++}, a function extremely important in cells of the nervous system where Ca^{++} is the trigger for neurotransmitter release. The smooth ER additionally metabolizes some carbohydrates and performs a detoxification role, breaking down certain toxins.

In contrast with the smooth ER, the primary job of the rough ER is the modification of proteins destined for the cell membrane or for export from the cell. For this protein synthesis, many ribosomes attach to the ER (giving it the studded appearance of rough ER). Typically, a protein is synthesized within the ribosome and released inside the channel of the rough ER, where sugars can be added to it (by a process called glycosylation) before it is transported within a vesicle to the next stage in the packaging and shipping process: the Golgi apparatus.

The Golgi Apparatus

The **Golgi apparatus** is responsible for sorting, modifying, and shipping off the products that come from the rough ER, much like a post-office. The Golgi apparatus looks like stacked flattened discs, almost like stacks of oddly shaped pancakes. Like the ER, these discs are membranous. The Golgi apparatus has two distinct sides, each with a different role. One side of the apparatus receives products in vesicles from the ER. These products are modified as needed and sorted as they move through the apparatus, and then they are released from the opposite side after being repackaged into new vesicles. If the product is to be exported from the cell, the vesicle migrates to the cell surface and fuses to the cell membrane, and the cargo is secreted via exocytosis (Figure 2.3.3).

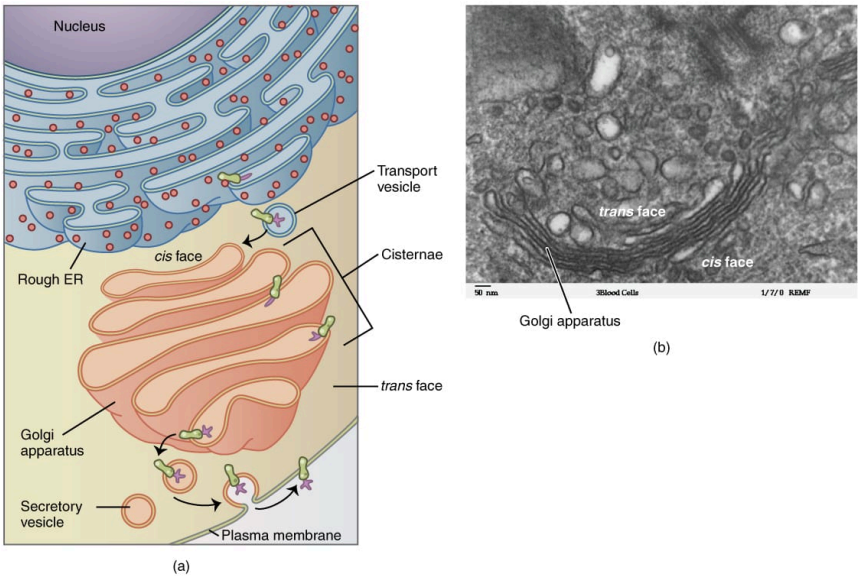

Figure 2.3.3: Golgi Apparatus. (a) Proteins and other products of the ER are sent to the Golgi apparatus, which organizes, modifies, packages, and tags them. Some of these products are transported to other areas of the cell and some are exported from the cell through exocytosis. Enzymatic proteins are packaged as new lysosomes (or packaged and sent for fusion with existing lysosomes). (b) An electron micrograph of the Golgi apparatus. (Image credit: "Golgi Apparatus" by OpenStax is licensed under CC BY 4.0)

Lysosomes

Some of the protein products packaged by the Golgi will function in a membrane-bound organelle inside the cell. For example, when the Golgi packages digestive enzymes that are meant to remain inside the cell for use in breaking down certain materials into a vesicle, that vesicle may become a new lysosome, or it may fuse with an existing lysosome. A **lysosome** is an organelle that contains enzymes that break down and digest unneeded cellular components, such as a damaged organelle. A lysosome is similar to a wrecking crew that takes down old and unsound buildings in a neighborhood. **Autophagy** ("self-eating") is the process of a cell digesting its own structures. Lysosomes are also important for breaking down foreign material. For example, when certain immune defense cells (white blood cells) phagocytize bacteria, the bacterial cell is transported into a lysosome and digested by the enzymes inside. As one might imagine, such phagocytic defense cells contain large numbers of lysosomes.

Under certain circumstances, lysosomes perform a more grand and dire function. In the case of damaged or unhealthy cells, lysosomes can be triggered to open up and release their digestive enzymes into the cytoplasm of the cell, killing the cell. This "self-destruct" mechanism is called **autolysis**, and makes the process of cell death controlled (a mechanism called "apoptosis").

Organelles for Energy Production and Detoxification

In addition to the jobs performed by the endomembrane system, the cell has many other important functions. Just as you must consume nutrients to provide yourself with energy, so must each of your cells take in nutrients, some of which convert to chemical energy that can be used to power biochemical reactions. Another important function of the cell is detoxification. Humans take in all sorts of toxins from the environment and also produce harmful chemicals as byproducts of cellular processes. Cells called hepatocytes in the liver detoxify many of these toxins.

Mitochondria

A **mitochondrion** (plural = mitochondria) is a membranous, bean-shaped organelle that is the "energy transformer" of the cell. Mitochondria consist of an outer lipid bilayer membrane as well as an additional inner lipid bilayer membrane (Figure 2.3.4). The inner membrane is highly folded into winding structures with a great deal of surface area, called cristae. It is along this inner membrane that a series of proteins, enzymes, and other molecules perform the biochemical reactions of cellular respiration. These reactions convert energy stored in nutrient molecules (such as glucose) into adenosine triphosphate (ATP), which provides usable cellular energy to the cell. Cells use ATP constantly, and so the mitochondria are constantly at work. Oxygen molecules are required during cellular respiration, which is why you must constantly breathe it in. One of the organ systems in the body that has high demands for ATP is the muscular system because ATP is required to sustain muscle contraction. As a result, muscle cells

are packed full of mitochondria. Nerve cells also need large quantities of ATP to run their sodium-potassium pumps. Therefore, an individual neuron will be loaded with over a thousand mitochondria. On the other hand, a bone cell, which is not nearly as metabolically-active, might only have a couple hundred mitochondria.

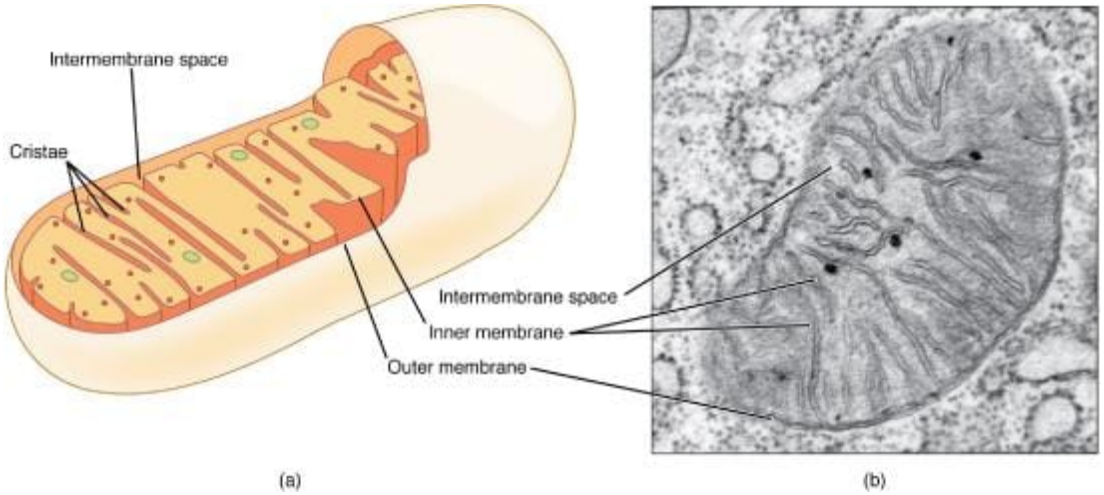

Figure 2.3.4: Mitochondrion. The mitochondria are the energy-conversion factories of the cell. (a) A mitochondrion is composed of two separate lipid bilayer membranes. Along the inner membrane are various molecules that work together to produce ATP, the cell's major energy currency. (b) An electron micrograph of mitochondria. EM × 236,000. (Image credit: "Mitochondrion" by OpenStax is licensed under CC BY 4.0/ Micrograph provided by the Regents of University of Michigan Medical School © 2012)

Peroxisomes

Like a lysosome, a **peroxisome** is a membrane-bound cellular organelle that contains mostly enzymes (Figure 2.3.5). Peroxisomes perform a couple of different functions, including lipid metabolism and chemical detoxification. In contrast to the digestive enzymes found in lysosomes, the enzymes within peroxisomes serve to transfer hydrogen atoms from various molecules to oxygen, producing hydrogen peroxide (H_2O_2). In this way, peroxisomes neutralize free radicals that are produced during many normal cellular processes. Free radicals are reactive because they contain free unpaired electrons typically associated with oxygen (so they are also called reactive oxygen species). Free radicals can easily oxidize other molecules throughout the cell, causing cellular damage and even cell death.

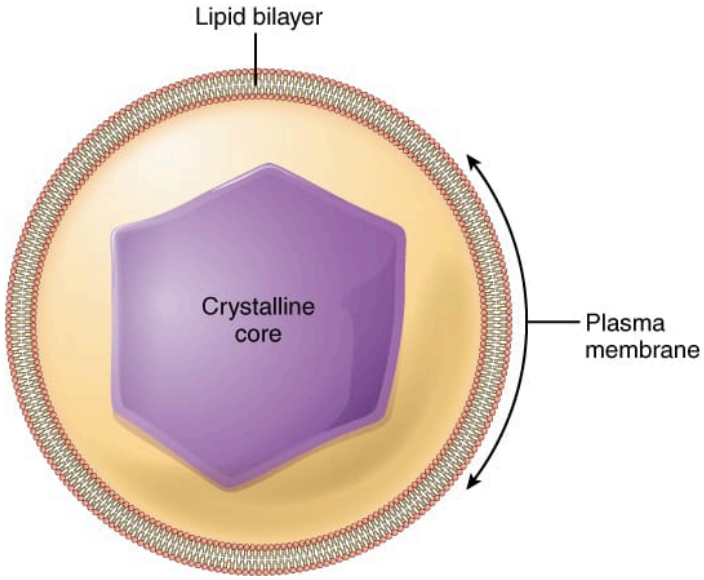

Figure 2.3.5: Peroxisome. Peroxisomes are membrane-bound organelles that contain an abundance of enzymes for detoxifying harmful substances and lipid metabolism. (Image credit: "Peroxisome" by OpenStax is licensed under CC BY 4.0)

AGING AND THE CELL: The Free Radical Theory

The free radical theory on aging was originally proposed in the 1950s, and still remains under debate. Generally speaking, the free radical theory of aging suggests that accumulated cellular damage from oxidative stress contributes to the physiological and anatomical effects of aging. There are two significantly different versions of this theory: one states that the aging process itself is a result of oxidative damage, and the other states that oxidative damage causes age-related disease and disorders. The latter version of the theory is more widely accepted than the former. However, many lines of evidence suggest that oxidative damage does contribute to the aging process. Research has shown that reducing oxidative damage can result in a longer lifespan in certain organisms such as yeast, worms, and fruit flies. Conversely, increasing oxidative damage can shorten the lifespan of mice and worms. Interestingly, a manipulation called calorie-restriction (moderately restricting the caloric intake) has been shown to increase life span in some laboratory animals. It is believed that this increase is at least in part due to a reduction of oxidative stress. However, a long-term study of primates with calorie-restriction showed no increase in their lifespan. A great deal of additional research will be required to better understand the link between reactive oxygen species and aging.

The Cytoskeleton

Much like the bony skeleton structurally supports the human body, the cytoskeleton helps the cells to maintain their structural integrity. The **cytoskeleton** is a group of fibrous proteins that provide structural support for cells, but this is only one of the functions of the cytoskeleton. Cytoskeletal components are also critical for cell motility, cell reproduction, and transportation of substances within the cell.

The cytoskeleton forms a complex thread-like network throughout the cell consisting of three different kinds of protein-based filaments: microfilaments, intermediate filaments, and microtubules (Figure 2.3.6). The thickest of the three is the **microtubule**, a structural filament composed of subunits of a protein called tubulin. Microtubules maintain cell shape and structure, help resist compression of the cell, and play a role in positioning the organelles within the cell. Microtubules also make up two types of cellular appendages important for motion: cilia and flagella (seen previously in this chapter). **Cilia** are found on many cells of the body, including the epithelial cells that line the airways of the respiratory system. Cilia move rhythmically; they beat constantly, moving waste materials such as dust, mucus, and bacteria upward through the airways, away from the lungs and toward the mouth. Beating cilia on cells lining the female fallopian tubes move egg cells from the ovary towards the uterus. A **flagellum** (plural = flagella) is an appendage larger than a cilium and specialized for cell locomotion. The only flagellated cell in humans is the sperm cell that must propel itself towards female egg cells.

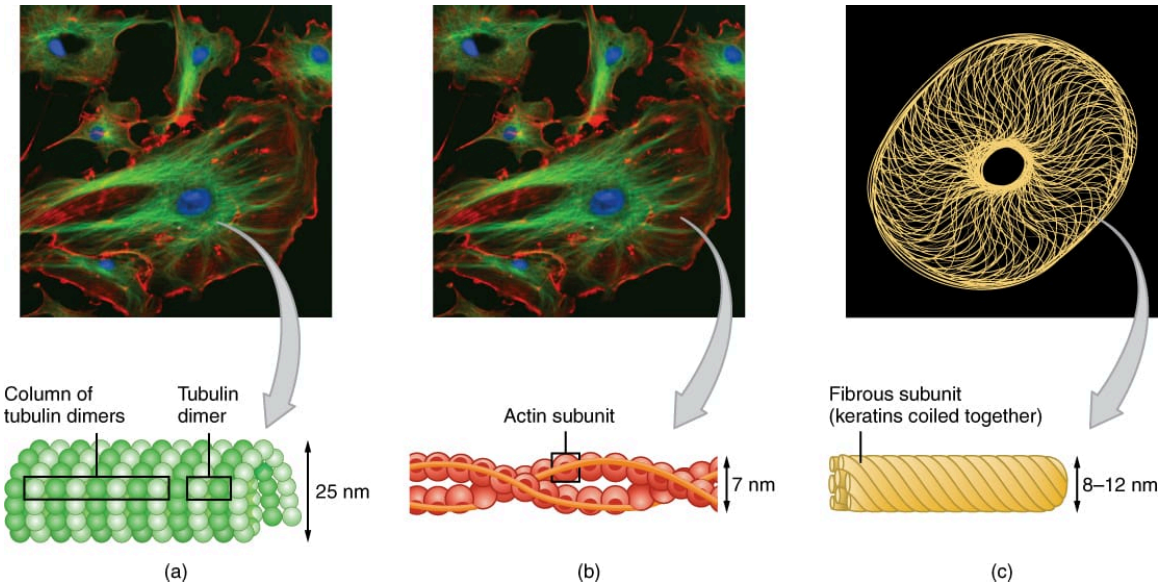

Figure 2.3.6: The Three Components of the Cytoskeleton. The cytoskeleton consists of (a) microtubules, (b) microfilaments, and (c) intermediate filaments. The cytoskeleton plays an important role in maintaining cell shape and structure, promoting cellular movement, and aiding cell division. (Image credit: "Cytoskeleton Components" by OpenStax is licensed under CC BY 4.0)

A very important function of microtubules is to set the paths (somewhat like railroad tracks) along which the genetic material can be pulled (a process requiring ATP) during cell division, so that each new daughter cell receives the appropriate set of chromosomes. Two short, identical microtubule structures called centrioles are found near the nucleus of cells. A **centriole** can serve as the cellular origin point for microtubules extending outward as cilia or flagella or can assist with the separation of DNA during cell division. Microtubules grow out from the centrioles by adding more tubulin subunits, like adding additional links to a chain.

In contrast with microtubules, the **microfilament** is a thinner type of cytoskeletal filament (see Figure $2.3.6.b$). Actin, a protein that forms chains, is the primary component of these microfilaments. Actin fibers, twisted chains of actin filaments, constitute a large component of muscle tissue and, along with the protein myosin, are responsible for muscle contraction. Like microtubules, actin filaments are long chains of single subunits (called actin subunits). In muscle cells, these long actin strands, called thin filaments, are “pulled” by thick filaments of the myosin protein to contract the cell.

Actin also has an important role during cell division. When a cell is about to split in half during cell division, actin filaments work with myosin to create a cleavage furrow that eventually splits the cell down the middle, forming two new cells from the original cell.

The final cytoskeletal filament is the intermediate filament. As its name would suggest, an **intermediate filament** is a filament intermediate in thickness between the microtubules and microfilaments (see Figure $2.3.6.c$). Intermediate filaments are made up of long fibrous subunits of a protein called keratin that are wound together like the threads that compose a rope. Intermediate filaments, in concert with the microtubules, are important for maintaining cell shape and structure. Unlike the microtubules, which resist compression, intermediate filaments resist tension—the forces that pull apart cells. There are many cases in which cells are prone to tension, such as when epithelial cells of the skin are compressed, tugging them in different directions. Intermediate filaments help anchor organelles together within a cell and also link cells to other cells by forming special cell-to-cell junctions.

Concept Review

The internal environmental of a living cell is made up of a fluid, jelly-like substance called cytosol, which consists mainly of water, but also contains various dissolved nutrients and other molecules. The cell contains an array of cellular organelles, each one performing a unique function and helping to maintain the health and activity of the cell. The cytosol and organelles together compose the cell’s cytoplasm. Most organelles are surrounded by a lipid membrane similar to the cell membrane of the cell. The endoplasmic reticulum (ER), Golgi apparatus, and lysosomes share a functional connectivity and are collectively referred to as the endomembrane system. There are two types of ER: smooth and rough. While the smooth ER performs many functions, including lipid synthesis and ion storage, the rough ER is mainly responsible for protein synthesis using its associated ribosomes. The rough ER sends newly made proteins to the Golgi apparatus where they are modified and packaged for delivery to various locations within or outside of the cell. Some of these protein products are enzymes destined to break down unwanted material and are packaged as lysosomes for use inside the cell.

Cells also contain mitochondria and peroxisomes, which are the organelles responsible for producing the cell’s energy supply and detoxifying certain chemicals, respectively. Biochemical reactions within mitochondria transform energy-carrying molecules into the usable form of cellular energy known as ATP. Peroxisomes contain enzymes that transform harmful substances such as free radicals into oxygen and water. Cells also contain a miniaturized “skeleton” of protein filaments that extend throughout its interior. Three different kinds of filaments compose this cytoskeleton (in order of increasing thickness): microfilaments, intermediate filaments, and microtubules. Each cytoskeletal component performs unique functions as well as provides a supportive framework for the cell.

Review Questions

Query 2.3.1

This interactive element is not available in this format. Visit the link or scan the QR code to access it online.

View this Interactive Content online

Query 2.3.2

This interactive element is not available in this format. Visit the link or scan the QR code to access it online.

View this Interactive Content online

.

Critical Thinking Questions

Query 2.3.3

This interactive element is not available in this format. Visit the link or scan the QR code to access it online.

View this Interactive Content online

Query 2.3.4

This interactive element is not available in this format. Visit the link or scan the QR code to access it online.

View this Interactive Content online

Glossary

Query 2.3.5

This interactive element is not available in this format. Visit the link or scan the QR code to access it online.

View this Interactive Content online

Contributors and Attributions

OpenStax Anatomy & Physiology (CC BY 4.0). Access for free at https://openstax.org/books/anatomy-and-physiology

This page titled 2.3: The Cytoplasm and Cellular Organelles is shared under a CC BY-NC-SA 4.0 license and was authored, remixed, and/or curated by Jennifer Lange et al..

- 2.3: The Cytoplasm and Cellular Organelles by Whitney Menefee, Julie Jenks, Chiara Mazzasette, and Kim-Leiloni Nguyen is licensed CC BY 4.0.

2.4: The Nucleus

By the end of the section, you will be able to:

- Describe the structure and features of the nuclear membrane
- List the contents of the nucleus
- Explain the organization of the DNA molecule within the nucleus

The nucleus is the largest and most prominent of a cell's organelles (Figure 2.4.1). The nucleus is generally considered the control center of the cell because it stores all of the genetic instructions for manufacturing proteins. Interestingly, some cells in the body, such as muscle cells, contain more than one nucleus (Figure 2.4.2), so they are referred to as multinucleated cells. Other cells, such as mammalian red blood cells (RBCs), do not contain nuclei at all. RBCs eject their nuclei as they mature, making space for the large numbers of hemoglobin molecules that carry oxygen throughout the body (Figure 2.4.3). Without nuclei, the life span of RBCs is short, and so the body must produce new ones constantly.

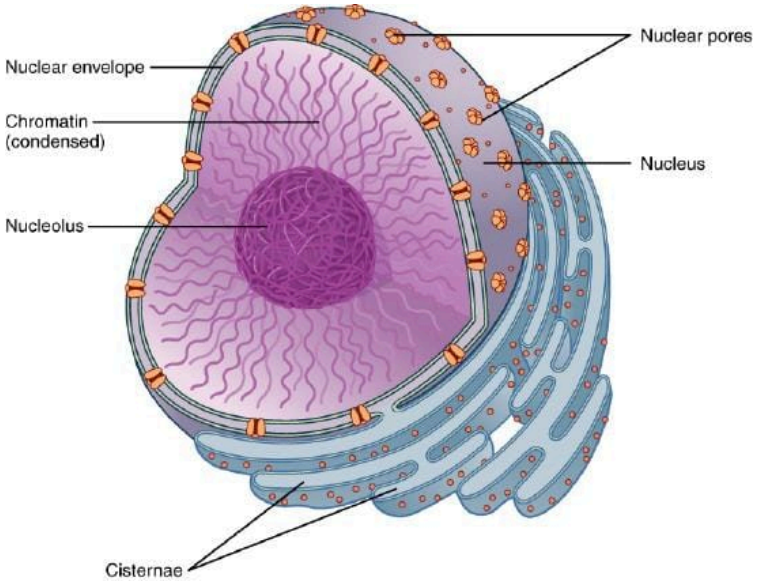

Figure 2.4.1: The Nucleus. The nucleus is the control center of the cell. The nucleus of living cells contains the genetic material that determines the entire structure and function of that cell. (Image credit: "Nucleus" by OpenStax is licensed under CC BY 4.0)



Figure 2.4.2: Multinucleate Muscle Cell. Unlike cardiac muscle cells and smooth muscle cells, which have a single nucleus, a skeletal muscle cell contains many nuclei, and is referred to as “multinucleated.” These muscle cells are long and fibrous (often referred to as muscle fibers). During development, many smaller cells fuse to form a mature muscle fiber. The nuclei of the fused cells are conserved in the mature cell, thus imparting a multinucleate characteristic to mature muscle cells. LM × 1004.3. (Image credit: "Multinucleate Muscle Tissue Micrograph" by OpenStax is licensed under CC BY 4.0/ Micrograph provided by the Regents of University of Michigan Medical School © 2012)

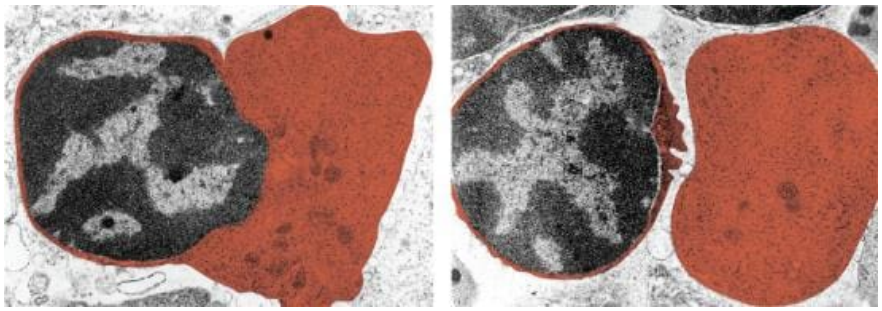

Figure 2.4.3: Red Blood Cell Extruding Its Nucleus. Mature red blood cells lack a nucleus. As they mature, erythroblasts extrude their nucleus, making room for more hemoglobin. The two panels here show an erythroblast before and after ejecting its nucleus, respectively. (Image credit: "RBC Extruding Nucleus Micrograph" by OpenStax is licensed under CC BY 4.0/ Modification of micrograph provided by the Regents of University of Michigan Medical School © 2012)

Inside the nucleus lies the blueprint that dictates everything a cell will do and all of the products it will make. This information is stored within DNA, deoxyribonucleic acid. The nucleus sends “commands” to the cell via molecular messengers that translate the information from DNA. Each nucleated cell in your body (with the exception of germ cells, also known as eggs and sperm) contains the complete set of your DNA. When a cell divides, the DNA must be duplicated so that the each new cell receives a full complement of DNA.

Organization of the Nucleus and Its DNA

Like most other cellular organelles, the nucleus is surrounded by a membrane. The membrane surrounding the nucleus, called the **nuclear envelope,** consists of two adjacent lipid bilayers with a thin fluid space in between them. Spanning these two bilayers are nuclear pores. A **nuclear pore** is a tiny passageway for the passage of proteins, RNA (ribonucleic acid), and solutes between the nucleus and the cytoplasm. Proteins called pore complexes lining the nuclear pores regulate the passage of materials into and out of the nucleus.

Inside the nuclear envelope is a gel-like nucleoplasm with solutes that include the building blocks of nucleic acids. There also can be a dark-staining mass often visible under a simple light microscope, called a **nucleolus** (plural = nucleoli). The nucleolus is a region of the nucleus that is responsible for manufacturing the RNA necessary for construction of ribosomes. Once synthesized, newly made ribosomal subunits exit the cell’s nucleus through the nuclear pores.

The genetic instructions that are used to build and maintain an organism are arranged in an orderly manner in strands of DNA. Within the nucleus are threads of **chromatin** composed of DNA and associated proteins (Figure 2.4.4). Along the chromatin

threads, the DNA is wrapped around a set of **histone** proteins. A **nucleosome** is a single, wrapped DNA-histone complex. Multiple nucleosomes along the entire molecule of DNA appear like a beaded necklace, in which the string is the DNA and the beads are the associated histones. When a cell is in the process of division, the chromatin condenses into chromosomes, so that the DNA can be safely transported to the "daughter cells." The **chromosome** is composed of DNA and proteins; it is the condensed form of chromatin. It is estimated that humans have almost 22,000 genes distributed on 46 chromosomes.

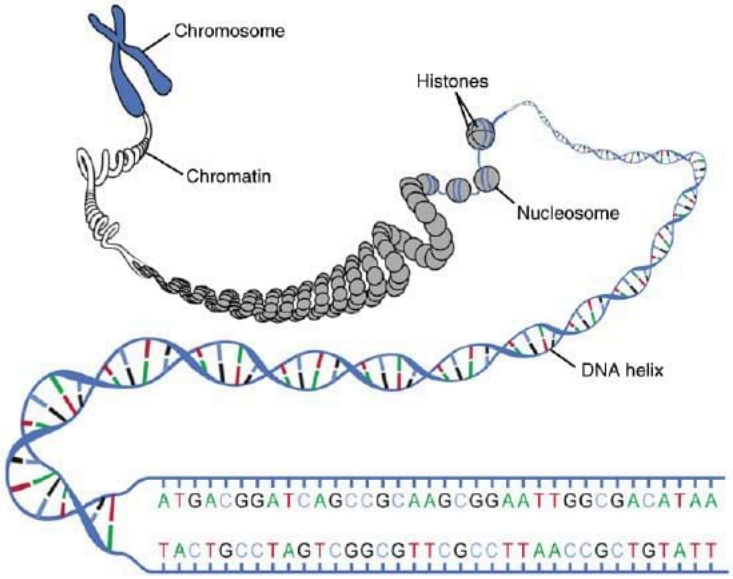

Figure 2.4.4: DNA Macrostructure. Strands of DNA are wrapped around supporting histones. These proteins are increasingly bundled and condensed into chromatin, which is packed tightly into chromosomes when the cell is ready to divide. (Image credit: "DNA Macrostructure" by OpenStax is licensed under CC BY 4.0)

Concept Review

The nucleus is the command center of the cell, containing the genetic instructions for all of the materials a cell will make (and thus all of its functions it can perform). The nucleus is encased within a membrane of two interconnected lipid bilayers, side-by-side. This nuclear envelope is studded with protein-lined pores that allow materials to be trafficked into and out of the nucleus. The nucleus contains one or more nucleoli, which serve as sites for ribosome synthesis. The nucleus houses the genetic material of the cell: DNA. DNA is normally found as a loosely contained structure called chromatin within the nucleus, where it is wound up and associated with a variety of histone proteins. When a cell is about to divide, the chromatin coils tightly and condenses to form chromosomes.

Review Questions

Query 2.4.1

This interactive element is not available in this format. Visit the link or scan the QR code to access it online.

View this Interactive Content online

Query 2.4.2

This interactive element is not available in this format. Visit the link or scan the QR code to access it online.

View this Interactive Content online

Critical Thinking Questions

Query 2.4.3

This interactive element is not available in this format. Visit the link or scan the QR code to access it online.

View this Interactive Content online

Query 2.4.4

This interactive element is not available in this format. Visit the link or scan the QR code to access it online.

View this Interactive Content online

Glossary

Query 2.4.5

This interactive element is not available in this format. Visit the link or scan the QR code to access it online.

View this Interactive Content online

Contributors and Attributions

- OpenStax Anatomy & Physiology (CC BY 4.0). Access for free at https://openstax.org/books/anatomy-and-physiology

---

This page titled 2.4: The Nucleus is shared under a CC BY-NC-SA 4.0 license and was authored, remixed, and/or curated by Jennifer Lange et al..

- 2.4: The Nucleus by Whitney Menefee, Julie Jenks, Chiara Mazzasette, and Kim-Leiloni Nguyen is licensed CC BY 4.0.

2.5: Cell Growth and Division

By the end of the section, you will be able to:

- Describe, in order, the stages of the cell cycle
- Discuss how the cell cycle is regulated
- Describe the implications of losing control over the cell cycle
- Describe the stages of mitosis and cytokinesis, in order

So far in this chapter, you have read numerous times of the importance and prevalence of cell division. While there are a few cells in the body that do not undergo cell division (such as gametes, red blood cells, most neurons, and some muscle cells), most somatic cells divide regularly. A **somatic cell** is a general term for a body cell, and all human cells, except for the cells that produce eggs and sperm (which are referred to as germ cells), are somatic cells. Somatic cells contain two copies of each of their chromosomes (one copy received from each parent). Each **homologous pair** of chromosomes includes the two copies of a single chromosome found in each somatic cell. The human is a **diploid** organism, having 23 homologous pairs of chromosomes in each of the somatic cells. The condition of having pairs of chromosomes is known as diploidy.

Cells in the body replace themselves over the lifetime of a person. For example, the cells lining the gastrointestinal tract must be frequently replaced when constantly "worn off" by the movement of food through the gut. But what triggers a cell to divide, and how does it prepare for and complete cell division? The **cell cycle** is the sequence of events in the life of the cell from the moment it is created at the end of a previous cycle of cell division until it then divides itself, generating two new cells.

The Cell Cycle

One "turn" or cycle of the cell cycle consists of two general phases: interphase, followed by mitosis and cytokinesis. **Interphase** is the period of the cell cycle during which the cell is not dividing. The majority of cells are in interphase most of the time. **Mitosis** is the division of genetic material, during which the cell nucleus breaks down and two new, fully functional, nuclei are formed. **Cytokinesis** divides the cytoplasm into two distinctive cells.

Interphase

A cell grows and carries out all normal metabolic functions and processes in a period called G_1 (Figure 2.5.1). **G_1 phase** (gap 1 phase) is the first gap, or growth phase in the cell cycle. For cells that will divide again, G_1 is followed by replication of the DNA, during the S phase. The **S phase** (synthesis phase) is period during which a cell replicates its DNA.

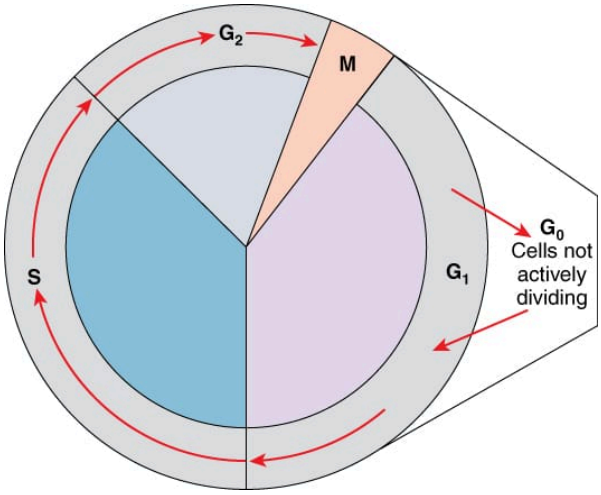

Figure 2.5.1: Cell Cycle. The two major phases of the cell cycle include mitosis (cell division), and interphase, when the cell grows and performs all of its normal functions. Interphase is further subdivided into G_1, S, and G_2 phases. (Image credit: "Cell Cycle" by OpenStax is licensed under CC BY 4.0)

After the synthesis phase, the cell proceeds through the G_2 phase. The **G_2 phase** is a second gap phase, during which the cell continues to grow and makes the necessary preparations for mitosis. Between G_1, S, and G_2 phases, cells will vary the most in their duration of the G1 phase. It is here that a cell might spend a couple of hours, or many days. The S phase typically lasts between 8-10 hours and the G_2 phase approximately 5 hours. In contrast to these phases, the **G_0 phase** is a resting phase of the cell cycle. Cells that have temporarily stopped dividing and are resting (a common condition) and cells that have permanently ceased dividing (like nerve cells) are said to be in G_0.

The Structure of Chromosomes

Billions of cells in the human body divide every day. During the synthesis phase (S, for DNA synthesis) of interphase, the amount of DNA within the cell precisely doubles. Therefore, after DNA replication but before cell division, each cell actually contains *two* copies of each chromosome. Each copy of the chromosome is referred to as a **sister chromatid** and is physically bound to the other copy. The **centromere** is the structure that attaches one sister chromatid to another. Because a human cell has 46 chromosomes, during this phase, there are 92 chromatids (46 × 2) in the cell. Make sure not to confuse the concept of a pair of chromatids (one chromosome and its exact copy attached during mitosis) and a homologous pair of chromosomes (two paired chromosomes which were inherited separately, one from each parent) (Figure 2.5.2).

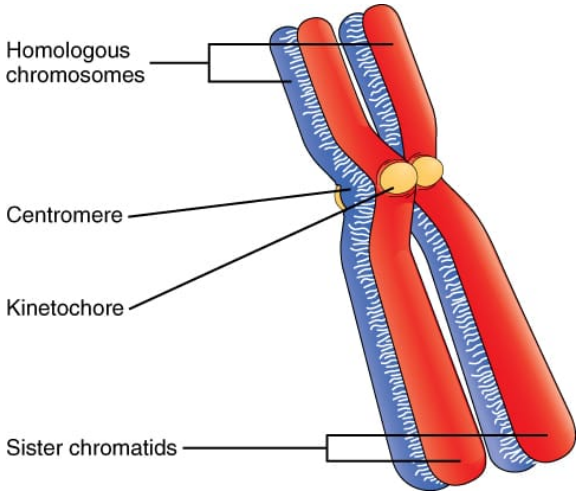

Figure 2.5.2: A Homologous Pair of Chromosomes with their Attached Sister Chromatids. The red and blue colors correspond to a homologous pair of chromosomes. Each member of the pair was separately inherited from one parent. Each chromosome in the homologous pair is also bound to an identical sister chromatid, which is produced by DNA replication, and results in the familiar "X" shape. ("Homologous Pair of Chromosomes" by OpenStax is licensed under CC BY 4.0)

Mitosis and Cytokinesis

The **mitotic phase** of the cell typically takes between 1 and 2 hours. During this phase, a cell undergoes two major processes. First, it completes mitosis, during which the contents of the nucleus are equitably pulled apart and distributed between its two halves. Cytokinesis then occurs, dividing the cytoplasm and cell body into two new cells. Mitosis is divided into four major stages that take place after interphase (Figure 2.5.3) and in the following order: prophase, metaphase, anaphase, and telophase. The process is then followed by cytokinesis.

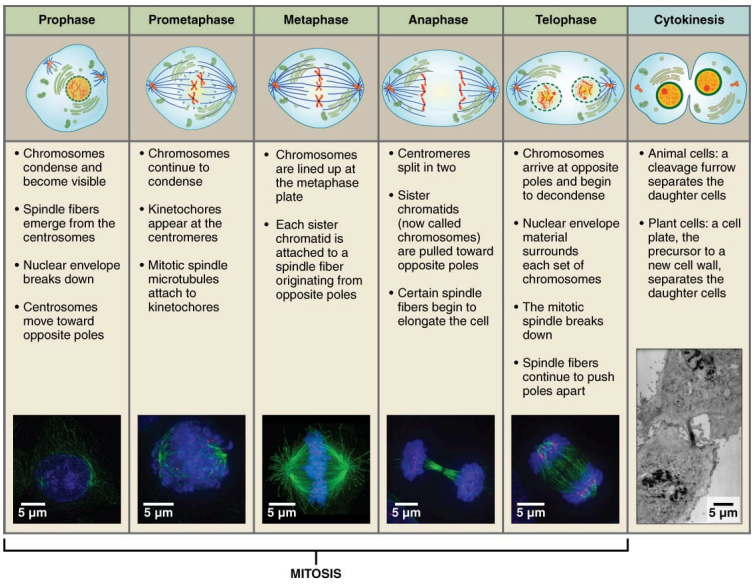

Figure 2.5.3: Cell Division: Mitosis Followed by Cytokinesis. The stages of cell division oversee the separation of identical genetic material into two new nuclei, followed by the division of the cytoplasm. (Image credit: "Stages of Mitosis and Cytokinesis" by OpenStax is licensed under CC BY 4.0)

Prophase is the first phase of mitosis, during which the loosely packed chromatin coils and condenses into visible chromosomes. During prophase, each chromosome becomes visible with its identical partner attached, forming the familiar X-shape of sister chromatids. The nucleolus disappears early during this phase, and the nuclear envelope also disintegrates.

A major occurrence during prophase concerns a very important structure that contains the origin site for microtubule growth. Recall the cellular structures called centrioles that serve as origin points from which microtubules extend. These tiny structures also play a very important role during mitosis. A **centrosome** is a pair of centrioles together. The cell contains two centrosomes side-by-side, which begin to move apart during prophase. As the centrosomes migrate to two different sides of the cell, microtubules begin to extend from each like long fingers from two hands extending toward each other. The **mitotic spindle** is the structure composed of the centrosomes and their emerging microtubules.

Near the end of prophase there is an invasion of the nuclear area by microtubules from the mitotic spindle. The nuclear membrane has disintegrated, and the microtubules attach themselves to the centromeres that adjoin pairs of sister chromatids. The **kinetochore** is a protein structure on the centromere that is the point of attachment between the mitotic spindle and the sister chromatids. This stage is referred to as late prophase or “prometaphase” to indicate the transition between prophase and metaphase.

Metaphase is the second stage of mitosis. During this stage, the sister chromatids, with their attached microtubules, line up along a linear plane in the middle of the cell. A metaphase plate forms between the centrosomes that are now located at either end of the cell. The **metaphase plate** is the name for the plane through the center of the spindle on which the sister chromatids are positioned. The microtubules are now poised to pull apart the sister chromatids and bring one from each pair to each side of the cell.

Anaphase is the third stage of mitosis. Anaphase takes place over a few minutes, when the pairs of sister chromatids are separated from one another, forming individual chromosomes once again. These chromosomes are pulled to opposite ends of the cell by their kinetochores, as the microtubules shorten. Each end of the cell receives one partner from each pair of sister chromatids, ensuring that the two new daughter cells will contain identical genetic material.

Telophase is the final stage of mitosis. Telophase is characterized by the formation of two new daughter nuclei at either end of the dividing cell. These newly formed nuclei surround the genetic material, which uncoils such that the chromosomes return to loosely packed chromatin. Nucleoli also reappear within the new nuclei, and the mitotic spindle breaks apart, each new cell receiving its own complement of DNA, organelles, membranes, and centrioles. At this point, the cell is already beginning to split in half as cytokinesis begins.

The **cleavage furrow** is a contractile band made up of microfilaments that forms around the midline of the cell during cytokinesis. (Recall that microfilaments consist of actin.) This contractile band squeezes the two cells apart until they finally separate. Two new cells are now formed. One of these cells (the “stem cell”) enters its own cell cycle; able to grow and divide again at some future time. The other cell transforms into the functional cell of the tissue, typically replacing an “old” cell there.

Imagine a cell that completed mitosis but never underwent cytokinesis. In some cases, a cell may divide its genetic material and grow in size, but fail to undergo cytokinesis. This results in larger cells with more than one nucleus. Usually this is an unwanted aberration and can be a sign of cancerous cells.

Cell Cycle Control

A very elaborate and precise system of regulation controls direct the way cells proceed from one phase to the next in the cell cycle and begin mitosis. The control system involves molecules within the cell as well as external triggers. These internal and external control triggers provide “stop” and “advance” signals for the cell. Precise regulation of the cell cycle is critical for maintaining the health of an organism, and loss of cell cycle control can lead to cancer.

Mechanisms of Cell Cycle Control

As the cell proceeds through its cycle, each phase involves certain processes that must be completed before the cell should advance to the next phase. A **checkpoint** is a point in the cell cycle at which the cycle can be signaled to move forward or stopped. At each of these checkpoints, different varieties of molecules provide the stop or go signals, depending on certain conditions within the cell. A **cyclin** is one of the primary classes of cell cycle control molecules. A **cyclin-dependent kinase (CDK)** is one of a group of molecules that work together with cyclins to determine progression past cell checkpoints. Major cyclin-CDK complexes involved in regulating the cell cycle include Cyclin D - CDK4, Cyclin E - CDK2, Cyclin A - CDK2, and Cyclin B - CDK1 (Figure 2.5.4). By interacting with many additional molecules, these triggers push the cell cycle forward unless prevented from doing so by “stop” signals, if for some reason the cell is not ready. At the G_1 checkpoint, the cell must be ready for DNA synthesis to occur. At the G_2 checkpoint the cell must be fully prepared for mitosis. Even during mitosis, a crucial stop and go checkpoint in metaphase ensures that the cell is fully prepared to complete cell division. The metaphase checkpoint ensures that all sister chromatids are properly attached to their respective microtubules and lined up at the metaphase plate before the signal is given to separate them during anaphase.

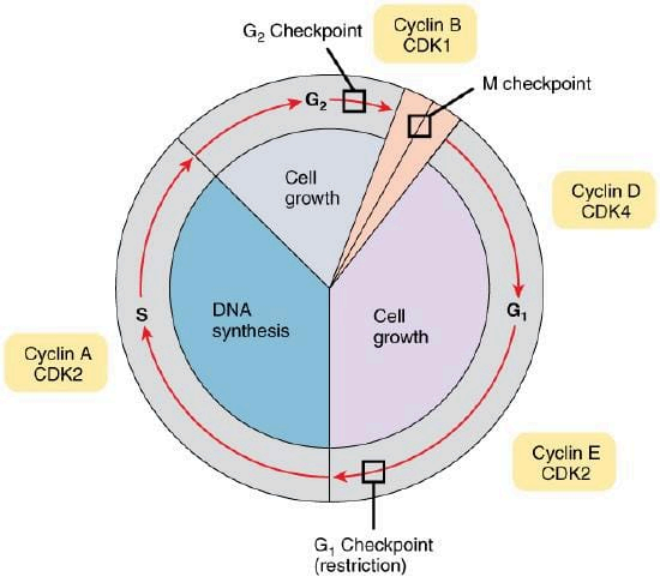

Figure 2.5.4: Control of the Cell Cycle. Cells proceed through the cell cycle under the control of a variety of molecules, such as cyclins and cyclin-dependent kinases. These control molecules determine whether or not the cell is prepared to move into the following stage. (Image credit: "Cell Cycle With Cyclins and Checkpoints" by OpenStax is licensed under CC BY 4.0)

The Cell Cycle Out of Control: Implications

Most people understand that cancer or tumors are caused by abnormal cells that multiply continuously. If the abnormal cells continue to divide unstopped, they can damage the tissues around them, spread to other parts of the body, and eventually result in death. In healthy cells, the tight regulation mechanisms of the cell cycle prevent this from happening, while failures of cell cycle control can cause unwanted and excessive cell division. Failures of control may be caused by inherited genetic abnormalities that compromise the function of certain “stop” and “go” signals. Environmental insult that damages DNA can also cause dysfunction in those signals. Often, a combination of both genetic predisposition and environmental factors lead to cancer.

The process of a cell escaping its normal control system and becoming cancerous may actually happen throughout the body quite frequently. Fortunately, certain cells of the immune system are capable of recognizing cells that have become cancerous and destroying them. However, in certain cases the cancerous cells remain undetected and continue to proliferate. If the resulting tumor does not pose a threat to surrounding tissues, it is said to be benign and can usually be easily removed. If capable of damage, the tumor is considered malignant and the patient is diagnosed with cancer.

HOMEOSTATIC IMBALANCES

Cancer Arises from Homeostatic Imbalances

Cancer is an extremely complex condition, capable of arising from a wide variety of genetic and environmental causes. Typically, mutations or aberrations in a cell’s DNA that compromise normal cell cycle control systems lead to cancerous tumors. Cell cycle control is an example of a homeostatic mechanism that maintains proper cell function and health. While progressing through the phases of the cell cycle, a large variety of intracellular molecules provide stop and go signals to regulate movement forward to the next phase. These signals are maintained in an intricate balance so that the cell only proceeds to the next phase when it is ready. This homeostatic control of the cell cycle can be thought of like a car’s cruise control. Cruise control will continually apply just the right amount of acceleration to maintain a desired speed, unless the driver hits the brakes, in which case the car will slow down. Similarly, the cell includes molecular messengers, such as cyclins, that push the cell forward in its cycle.

In addition to cyclins, a class of proteins that are encoded by genes called proto-oncogenes provide important signals that regulate the cell cycle and move it forward. Examples of proto-oncogene products include cell-surface receptors for growth factors, or cell-signaling molecules, two classes of molecules that can promote DNA replication and cell division. In contrast, a second class of genes known as tumor suppressor genes sends stop signals during a cell cycle. For example, certain protein products of tumor suppressor genes signal potential problems with the DNA and thus stop

the cell from dividing, while other proteins signal the cell to die if it is damaged beyond repair. Some tumor suppressor proteins also signal a sufficient surrounding cellular density, which indicates that the cell need not presently divide. The latter function is uniquely important in preventing tumor growth: normal cells exhibit a phenomenon called “contact inhibition;” thus, extensive cellular contact with neighboring cells causes a signal that stops further cell division.

These two contrasting classes of genes, proto-oncogenes and tumor suppressor genes, are like the accelerator and brake pedal of the cell’s own “cruise control system,” respectively. Under normal conditions, these stop and go signals are maintained in a homeostatic balance. Generally speaking, there are two ways that the cell’s cruise control can lose control: a malfunctioning (overactive) accelerator, or a malfunctioning (underactive) brake. When compromised through a mutation, or otherwise altered, proto-oncogenes can be converted to oncogenes, which produce oncoproteins that push a cell forward in its cycle and stimulate cell division even when it is undesirable to do so. For example, a cell that should be programmed to self-destruct (a process called apoptosis) due to extensive DNA damage might instead be triggered to proliferate by an oncoprotein. On the other hand, a dysfunctional tumor suppressor gene may fail to provide the cell with a necessary stop signal, also resulting in unwanted cell division and proliferation.

A delicate homeostatic balance between the many proto-oncogenes and tumor suppressor genes delicately controls the cell cycle and ensures that only healthy cells replicate. Therefore, a disruption of this homeostatic balance can cause aberrant cell division and cancerous growths.

Concept Review

The life of cell consists of stages that make up the cell cycle. After a cell is born, it passes through an interphase before it is ready to replicate itself and produce daughter cells. This interphase includes two gap phases (G_1 and G_2), as well as an S phase, during which its DNA is replicated in preparation for cell division. The cell cycle is under precise regulation by chemical messengers both inside and outside the cell that provide “stop” and “go” signals for movement from one phase to the next. Failures of these signals can result in cells that continue to divide uncontrollably, which can lead to cancer.

Once a cell has completed interphase and is ready for cell division, it proceeds through four separate stages of mitosis (prophase, metaphase, anaphase, and telophase). Telophase is followed by the division of the cytoplasm (cytokinesis), which generates two daughter cells. This process takes place in all normally dividing cells of the body except for the germ cells that produce eggs and sperm.

Review Questions

Query 2.5.1

This interactive element is not available in this format. Visit the link or scan the QR code to access it online.

View this Interactive Content online

Query 2.5.2

This interactive element is not available in this format. Visit the link or scan the QR code to access it online.

View this Interactive Content online

Critical Thinking Questions

Query 2.5.3

This interactive element is not available in this format. Visit the link or scan the QR code to access it online.

View this Interactive Content online

Query 2.5.4

This interactive element is not available in this format. Visit the link or scan the QR code to access it online.

View this Interactive Content online

Glossary

Query 2.5.5

This interactive element is not available in this format. Visit the link or scan the QR code to access it online.

View this Interactive Content online

Contributors and Attributions

- OpenStax Anatomy & Physiology (CC BY 4.0). Access for free at https://openstax.org/books/anatomy-and-physiology

---

This page titled 2.5: Cell Growth and Division is shared under a CC BY-NC-SA 4.0 license and was authored, remixed, and/or curated by Jennifer Lange et al..

- 2.5: Cell Growth and Division by Whitney Menefee, Julie Jenks, Chiara Mazzasette, and Kim-Leiloni Nguyen is licensed CC BY 4.0.

2.6: Cellular Differentiation

By the end of the section, you will be able to:

- Discuss how the generalized cells of a developing embryo or the stem cells of an adult organism become differentiated into specialized cells
- Distinguish between the categories of stem cells

How does a complex organism such as a human develop from a single cell—a fertilized egg—into the vast array of cell types such as nerve cells, muscle cells, and epithelial cells that characterize the adult? Throughout development and adulthood, the process of cellular differentiation leads cells to assume their final morphology and physiology. Differentiation is the process by which unspecialized cells become specialized to carry out distinct functions.

Stem Cells

A **stem cell** is an unspecialized cell that can divide without limit as needed and can, under specific conditions, differentiate into specialized cells. Stem cells are divided into several categories according to their potential to differentiate.

The first embryonic cells that arise from the division of the zygote are the ultimate stem cells; these stems cells are described as **totipotent** because they have the potential to differentiate into any of the cells needed to enable an organism to grow and develop.

The embryonic cells that develop from totipotent stem cells and are precursors to the fundamental tissue layers of the embryo are classified as pluripotent. A **pluripotent** stem cell is one that has the potential to differentiate into any type of human tissue but cannot support the full development of an organism. These cells then become slightly more specialized, and are referred to as multipotent cells.

A **multipotent** stem cell has the potential to differentiate into different types of cells within a given cell lineage or small number of lineages, such as a red blood cell or white blood cell.

Finally, multipotent cells can become further specialized oligopotent cells. An **oligopotent** stem cell is limited to becoming one of a few different cell types. In contrast, a **unipotent** cell is fully specialized and can only reproduce to generate more of its own specific cell type.

Stem cells are unique in that they can also continually divide and regenerate new stem cells instead of further specializing. There are different stem cells present at different stages of a human's life. They include the embryonic stem cells of the embryo, fetal stem cells of the fetus, and adult stem cells in the adult. One type of adult stem cell is the epithelial stem cell, which gives rise to the keratinocytes in the multiple layers of epithelial cells in the epidermis of skin. Adult bone marrow has three distinct types of stem cells: hematopoietic stem cells, which give rise to red blood cells, white blood cells, and platelets (Figure $2.6.1$); endothelial stem cells, which give rise to the endothelial cell types that line blood and lymph vessels; and mesenchymal stem cells, which give rise to the different types of muscle cells.

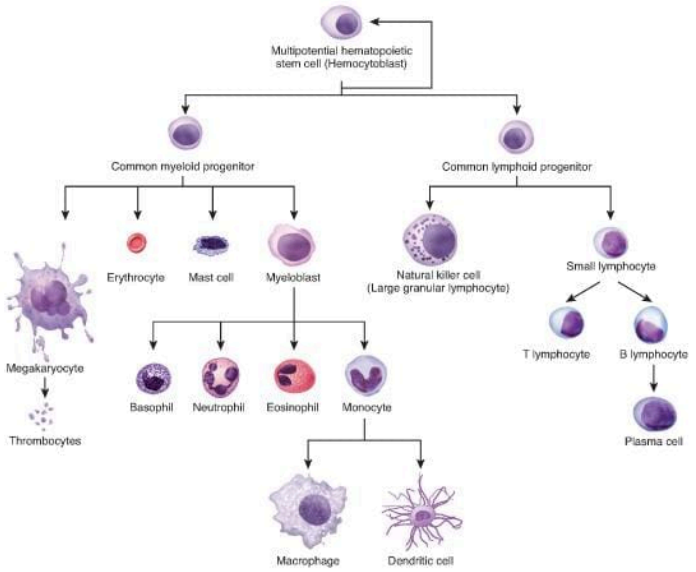

Figure 2.6.1: Hematopoiesis. The process of hematopoiesis involves the differentiation of multipotent cells into blood and immune cells. The multipotent hematopoietic stem cells give rise to many different cell types, including the cells of the immune system and red blood cells. (Image credit: "Hematopoiesis new" by OpenStax is licensed under CC BY 4.0)

Differentiation

When a cell differentiates (becomes more specialized), it may undertake major changes in its size, shape, metabolic activity, and overall function. Because all cells in the body, beginning with the fertilized egg, contain the same DNA, how do the different cell types come to be so different? The answer is analogous to a movie script. The different actors in a movie all read from the same script, however, they are each only reading their own part of the script. Similarly, all cells contain the same full complement of DNA, but each type of cell only "reads" the portions of DNA that are relevant to its own function. In biology, this is referred to as the unique genetic expression of each cell.

In order for a cell to differentiate into its specialized form and function, it need only manipulate those genes (and thus those proteins) that will be expressed, and not those that will remain silent. The primary mechanism by which genes are turned "on" or "off" is through transcription factors. A **transcription factor** is one of a class of proteins that bind to specific genes on the DNA molecule and either promote or inhibit their transcription (Figure 2.6.2).

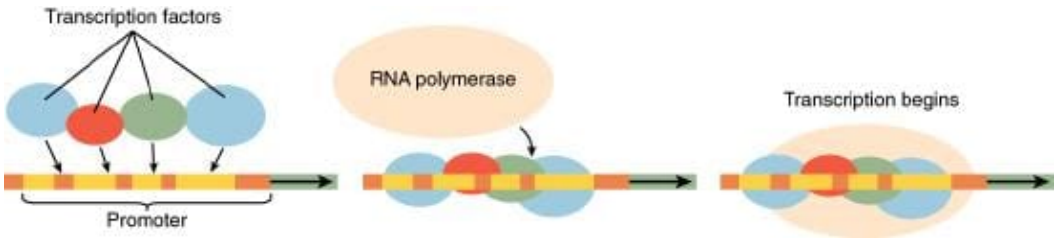

Figure 2.6.2: Transcription Factors Regulate Gene Expression. While each body cell contains the organism's entire genome, different cells regulate gene expression with the use of various transcription factors. Transcription factors are proteins that affect the binding of RNA polymerase to a particular gene on the DNA molecule. (Image credit: "RNA Polymerase Binding" by OpenStax is licensed under CC BY 4.0)

EVERYDAY CONNECTION

Stem Cell Research

Stem cell research aims to find ways to use stem cells to regenerate and repair cellular damage. Over time, most adult cells undergo the wear and tear of aging and lose their ability to divide and repair themselves. Stem cells do not display a particular morphology or function. Adult stem cells, which exist as a small subset of cells in most tissues, keep dividing and can differentiate into a number of specialized cells generally formed by that tissue. These cells enable the body to renew and repair body tissues.

The mechanisms that induce a non-differentiated cell to become a specialized cell are poorly understood. In a laboratory setting, it is possible to induce stem cells to differentiate into specialized cells by changing the physical and chemical conditions of growth. Several sources of stem cells are used experimentally and are classified according to their origin and potential for differentiation. Human embryonic stem cells (hESCs) are extracted from embryos and are pluripotent. The adult stem cells that are present in many organs and differentiated tissues, such as bone marrow and skin, are multipotent, being limited in differentiation to the types of cells found in those tissues. The stem cells isolated from umbilical cord blood are also multipotent, as are cells from deciduous teeth (baby teeth). Researchers have recently developed induced pluripotent stem cells (iPSCs) from mouse and human adult stem cells. These cells are genetically reprogrammed multipotent adult cells that function like embryonic stem cells; they are capable of generating cells characteristic of all three germ layers.

Because of their capacity to divide and differentiate into specialized cells, stem cells offer a potential treatment for diseases such as diabetes and heart disease (Figure 2.6.3). Cell-based therapy refers to treatment in which stem cells induced to differentiate in a growth dish are injected into a patient to repair damaged or destroyed cells or tissues. Many obstacles must be overcome for the application of cell-based therapy. Although embryonic stem cells have a nearly unlimited range of differentiation potential, they are seen as foreign by the patient's immune system and may trigger rejection. Also, the destruction of embryos to isolate embryonic stem cells raises considerable ethical and legal questions.

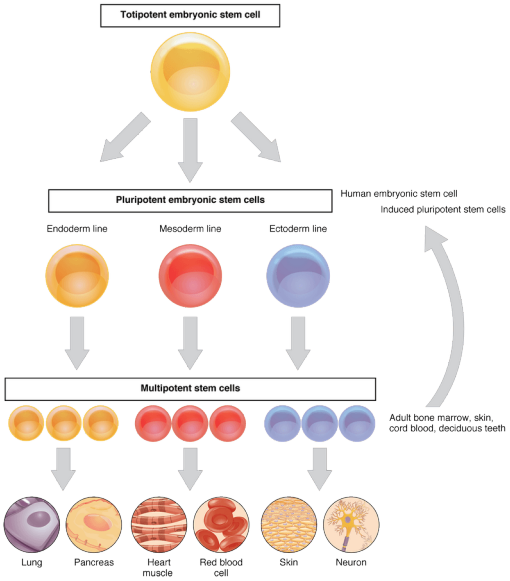

Figure 2.6.3: Stem Cells. The capacity of stem cells to differentiate into specialized cells make them potentially valuable in therapeutic applications designed to replace damaged cells of different body tissues. (Image credit: "Stem Cell" by OpenStax is licensed under CC BY 4.0)

In contrast, adult stem cells isolated from a patient are not seen as foreign by the body, but they have a limited range of differentiation. Some individuals bank the cord blood or deciduous teeth of their child, storing away those sources of stem cells for future use, should their child need it. Induced pluripotent stem cells are considered a promising advance in the field because using them avoids the legal, ethical, and immunological pitfalls of embryonic stem cells.

Concept Review

One of the major areas of research in biology is that of how cells specialize to assume their unique structures and functions, since all cells essentially originate from a single fertilized egg. Cell differentiation is the process of cells becoming specialized as the body develops. A stem cell is an unspecialized cell that can divide without limit as needed and can, under specific conditions,

differentiate into specialized cells. Stem cells are divided into several categories according to their potential to differentiate. While all somatic cells contain the exact same genome, different cell types only express some of those genes at any given time. These differences in gene expression ultimately dictate a cell's unique morphological and physiological characteristics. The primary mechanism that determines which genes will be expressed and which ones will not is through the use of different transcription factor proteins, which bind to DNA and promote or hinder the transcription of different genes. Through the action of these transcription factors, cells specialize into one of hundreds of different cell types in the human body.

Review Questions

Query 2.6.1

This interactive element is not available in this format. Visit the link or scan the QR code to access it online.

View this Interactive Content online

Critical Thinking Questions

Query 2.6.2

This interactive element is not available in this format. Visit the link or scan the QR code to access it online.

View this Interactive Content online

Query 2.6.3

This interactive element is not available in this format. Visit the link or scan the QR code to access it online.

View this Interactive Content online

Glossary

Query 2.6.4

This interactive element is not available in this format. Visit the link or scan the QR code to access it online.

View this Interactive Content online

Contributors and Attributions

- OpenStax Anatomy & Physiology (CC BY 4.0). Access for free at https://openstax.org/books/anatomy-and-physiology

This page titled 2.6: Cellular Differentiation is shared under a CC BY-NC-SA 4.0 license and was authored, remixed, and/or curated by Jennifer Lange et al..

- 2.6: Cellular Differentiation by Whitney Menefee, Julie Jenks, Chiara Mazzasette, and Kim-Leiloni Nguyen is licensed CC BY 4.0.

3: TISSUE LEVEL OF ORGANIZATION

3.1: Introduction to the Tissue Level of Organization

3.2: Types of Tissues

3.3: Epithelial Tissue

3.4: Connective Tissue

3.5: Muscle Tissue

3.6: Nervous Tissue

3.7: Tissue Injury and Aging

3.8: Anatomical Atlas - Tissues

3.9: Practice Practical- Tissues

This page titled 3: Tissue Level of Organization is shared under a CC BY-NC-SA 4.0 license and was authored, remixed, and/or curated by Jennifer Lange et al..

- 3: Tissue Level of Organization by Whitney Menefee, Julie Jenks, Chiara Mazzasette, and Kim-Leiloni Nguyen is licensed CC BY 4.0.

3.1: Introduction to the Tissue Level of Organization

Chapter Objectives:

After studying this chapter, you will be able to:

- Identify the main tissue types and discuss their roles in the human body
- Identify the four types of tissue membranes and the characteristics of each that make them functional
- Explain the functions of various epithelial tissues and how their forms enable their functions
- Explain the functions of various connective tissues and how their forms enable their functions
- Describe the characteristics of muscle tissue and how these enable function
- Discuss the characteristics of nervous tissue and how these enable information processing and control of muscular and glandular activities

The body contains at least 200 distinct cell types. These cells contain essentially the same organelles, yet they vary enormously in shape and function. The different types of cells are not randomly distributed throughout the body; rather they are found in specific locations and arrangements, a level of structural organization referred to as tissue. **Tissues** are groups of similar cells and extracellular materials that carry out a common function. The micrograph below (Figure 3.1.1) shows the high degree of organization among different cells in the tissues of the skin; they are organized into a dense, thick sheet to provide protection for your body. You can also see how that organization breaks down when cancer takes over the regular mitotic functioning of a cell (at arrow).

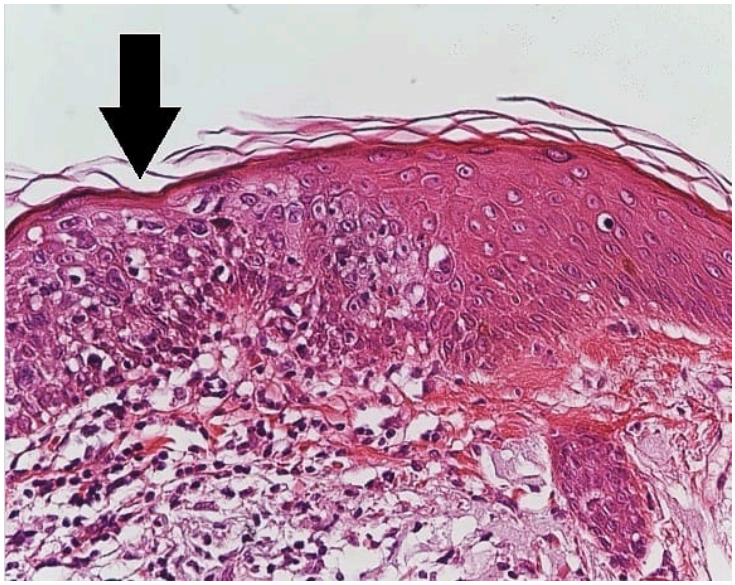

Figure 3.1.1: Micrograph of Skin Cancer. This figure is a view of the regular architecture of normal tissue contrasted with the irregular arrangement of cancerous cells (arrow). (Image credit: Mikael Häggström, M.D. licensed under CC0 Univeral Public Domain Dedication, via Wikimedia Commons)

Among cells, the variety in shape reflects the many different roles that cells fulfill in your body. The human body starts as a single cell at fertilization. As this fertilized egg divides, it gives rise to trillions of cells, each built from the same blueprint, but organizing into tissues and becoming irreversibly committed to a developmental pathway.

Contributors and Attributions

- OpenStax Anatomy & Physiology (CC BY 4.0). Access for free at https://openstax.org/books/anatomy-and-physiology

This page titled 3.1: Introduction to the Tissue Level of Organization is shared under a CC BY-NC-SA 4.0 license and was authored, remixed, and/or curated by Jennifer Lange et al..

- 3.1: Introduction to the Tissue Level of Organization by Whitney Menefee, Julie Jenks, Chiara Mazzasette, and Kim-Leiloni Nguyen is licensed CC BY 4.0.

3.2: Types of Tissues

By the end of the section, you will be able to:

- Identify the four main tissue types
- Discuss the general functions of each tissue type
- Discuss the embryonic origin of tissue
- Identify the three major germ layers
- Identify the main types of tissue membranes

Although there are hundreds of types of cells in the human body, they are organized into four broad categories of tissues: epithelial, connective, muscle, and nervous (Figure 3.2.1). Each of these categories is characterized by specific functions that contribute to the overall health and maintenance of the body. A disruption of the structure is a sign of injury or disease. Such changes can be detected through **histology**, the microscopic study of tissue appearance, organization, and function.

The Four Types of Tissues

1. **Epithelial tissue**, also referred to as epithelium (plural = epithelia), refers to the sheets of cells that cover exterior surfaces of the body (e.g. the skin surface), line internal body cavities (e.g. the pericardium), and form the lining of internal and many external surfaces of organs (e.g. the GI tract organs), and forms certain glands (e.g the adrenal glands).
2. **Connective tissue**, as its name implies, binds the cells and organs of the body together and functions in the protection, support, and integration of all parts of the body. Some examples include fat, bones, and tendons.
3. **Muscle tissue** is excitable, responding to stimulation and contracting to provide movement, and occurs as three major types: skeletal muscle, smooth muscle, and cardiac muscle. Skeletal muscle is under the voluntary control of the brain, but cardiac muscle and smooth muscle are involuntary so you cannot control their actions.
4. **Nervous tissue,** which can be found in the brain, spinal cord, and nerves, is also excitable, allowing the propagation of electrochemical signals in the form of nerve impulses that communicate between different regions of the body.

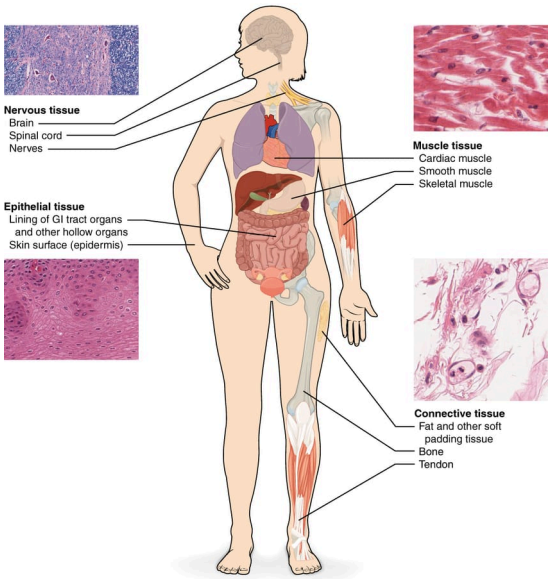

Figure 3.2.1: Four Types of Tissue: Body. The four types of tissues are exemplified in nervous tissue, stratified squamous epithelial tissue, cardiac muscle tissue, and connective tissue in small intestine. Clockwise from nervous tissue, LM × 872, LM × 282, LM × 460, LM × 800. *(Image credit: "Types of Tissue" by OpenStax is licensed under CC BY-NC 3.0/ Micrographs provided by the Regents of University of Michigan Medical School © 2012.)*

The next level of organization is the organ, where several types of tissues come together to form a working unit. Just as knowing the structure and function of cells helps you in your study of tissues, knowledge of tissues will help you understand how organs

function.

Embryonic Origin of Tissues

The zygote, or fertilized egg, is a single cell formed by the fusion of an egg and sperm. After fertilization the zygote gives rise to rapid mitotic cycles, generating many cells to form the embryo. The first embryonic cells generated have the ability to differentiate into any type of cell in the body and, as such, are called **totipotent**, meaning each has the capacity to divide, differentiate, and develop into a new organism. As cell proliferation progresses, three major cell lineages are established within the embryo. Each of these lineages of embryonic cells forms the distinct germ layers from which all the tissues and organs of the human body eventually form. Each germ layer is identified by its relative position: **ectoderm** (ecto- = "outer"), **mesoderm** (meso- = "middle"), and **endoderm** (endo- = "inner").

Figure 3.2.2 shows the types of tissues and organs associated with the each of the three germ layers. The ectoderm gives rise to the epidermis, glands on the skin, some cranial bones, the pituitary gland and adrenal medulla, the nervous system, the mouth between cheek and gums, and the anus. The mesoderm gives rise to connective tissues proper, bone, cartilage, blood, endothelium of blood vessels, muscle, synovial membranes, serous membranes lining body cavities, kidneys, and the lining of the gonads. The endoderm gives rise to the lining of the airways and digestive system, (except the mouth and distal portion (rectum and anal canal)), and some glands including digestive glands, endocrine glands, and the adrenal cortex. Note that epithelial tissue originates in all three layers, whereas nervous tissue derives primarily from the ectoderm and muscle tissue from mesoderm.

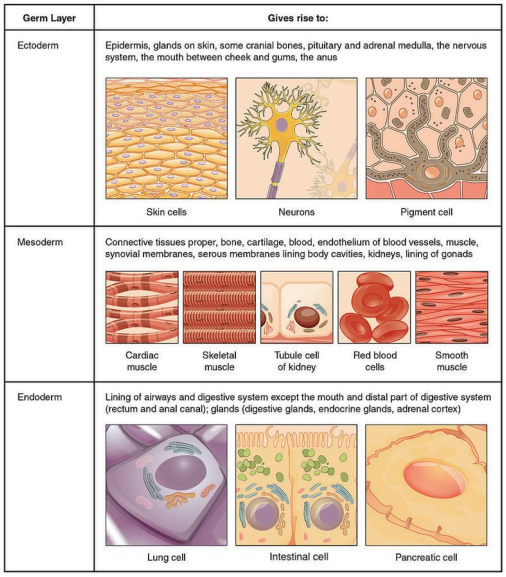

Figure 3.2.2: Embryonic Origin of Tissues and Major Organs. Tissues and organs are derived from three distinct germ layers, the ectoderm, mesoderm, and endoderm. *(Image credit: "419 420 421 Table 04 01 updated" by OpenStax is licensed under CC BY-NC 3.0.)*

Interactive Link

Stem Cells

Query 3.2.1

This interactive element is not available in this format. Visit the link or scan the QR code to access it online.

View this Interactive Content online

Tissue Membranes

A tissue membrane is a thin layer or sheet of cells that covers the outside of the body (for example, skin), the organs (for example, pericardium), internal passageways that lead to the exterior of the body (for example, the digestive tract), and the lining of the moveable joint cavities. There are two basic types of tissue membranes: epithelial membranes and connective tissue membranes (Figure 3.2.3).

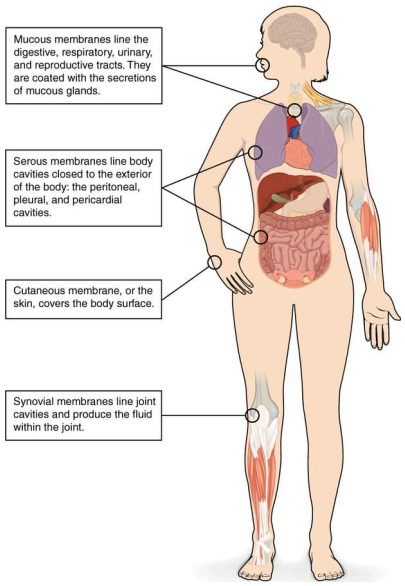

Figure 3.2.3: Tissue Membranes. The two broad categories of tissue membranes in the body are (1) epithelial membranes, which include mucous membranes, serous membranes, and the cutaneous membrane, in other words, the skin, and (2) connective tissue membranes, which include synovial membranes. (Image credit: "Types of Membranes" by OpenStax is licensed under CC BY-NC 3.0)

Epithelial Membranes

The **epithelial membrane** is composed of epithelium attached to a layer of connective tissue, for example, your skin. The **mucous membrane** is also a composite of connective and epithelial tissues. Sometimes called mucosae (singular mucosa), these epithelial membranes line the body cavities and hollow passageways that open to the external environment, and include the digestive, respiratory, urinary, and reproductive tracts. Mucous, produced by the epithelial exocrine glands, covers the epithelial layer and protects it in a variety of specific ways. The underlying connective tissue, called the **lamina propria** (literally “own layer”), help support the fragile epithelial layer.

A **serous membrane** is an epithelial membrane composed of mesodermally derived epithelium called the mesothelium that is supported by connective tissue. These membranes line the coelomic cavities of the body, that is, those cavities that do not open to the outside, and they cover the organs located within those cavities. They are essentially membranous bags, with mesothelium lining the inside and connective tissue on the outside. Serous fluid secreted by the cells of the thin squamous mesothelium lubricates the membrane and reduces abrasion and friction between organs. Serous membranes are identified according to location. Three serous membranes line the thoracic cavity: the two pleura that cover the lungs and the pericardium that covers the heart. A fourth, the peritoneum, is the serous membrane in the abdominal cavity that covers abdominal organs and forms double sheets of mesenteries that suspend many of the digestive organs.

The skin is an epithelial membrane also called the **cutaneous membrane**. It is a stratified squamous epithelial membrane resting on top of connective tissue. The apical surface of this membrane is exposed to the external environment and is covered with dead, keratinized cells that help protect the body from desiccation (drying out) and pathogens.

Connective Tissue Membranes

The **connective tissue membrane** is formed solely from connective tissue. These membranes encapsulate organs, such as the kidneys, and line our movable joints, so each is typically referred to as a **capsule**. A **synovial membrane** is a type of connective tissue membrane that lines the cavity of a freely movable joint. For example, synovial membranes surround the joints of the

shoulder, elbow, and knee. Fibroblasts in the inner layer of the synovial membrane release hyaluronan into the joint cavity. The hyaluronan effectively traps available water to form the synovial fluid, a natural lubricant that enables the bones of a joint to move freely against one another without much friction. This synovial fluid readily exchanges water and nutrients with blood, as do all body fluids.

Concept Review

The human body contains more than 200 types of cells that can all be classified into four types of tissues: epithelial, connective, muscle, and nervous.

- Epithelial tissues act as coverings.
- Connective tissue integrates the various parts of the body and provides support and protection to organs.
- Muscle tissue allows the body to move.
- Nervous tissues propagate information.

The study of the shape and arrangement of cells in tissue is called histology.

All cells and tissues in the body derive from three germ layers in the embryo: the ectoderm, mesoderm, and endoderm.

Different types of tissues form membranes that enclose organs, provide a friction-free interaction between organs, and keep organs together.

- Synovial membranes are connective tissue membranes that protect and line the joints.
- Epithelial membranes are formed from epithelial tissue attached to a layer of connective tissue. There are three types of epithelial membranes:
  - mucous, which contain glands;
  - serous, which secrete fluid; and
  - cutaneous which makes up the skin.

Review Questions

Query 3.2.2

This interactive element is not available in this format. Visit the link or scan the QR code to access it online.

View this Interactive Content online

Critical Thinking Questions

Query 3.2.3

This interactive element is not available in this format. Visit the link or scan the QR code to access it online.

View this Interactive Content online

Query 3.2.4

This interactive element is not available in this format. Visit the link or scan the QR code to access it online.

View this Interactive Content online

Query 3.2.5

This interactive element is not available in this format. Visit the link or scan the QR code to access it online.

View this Interactive Content online

Glossary

Query 3.2.6

This interactive element is not available in this format. Visit the link or scan the QR code to access it online.

View this Interactive Content online

Contributors and Attributions

- OpenStax Anatomy & Physiology (CC BY 4.0). Access for free at https://openstax.org/books/anatomy-and-physiology

This page titled 3.2: Types of Tissues is shared under a CC BY-NC-SA 4.0 license and was authored, remixed, and/or curated by Jennifer Lange et al..

- 3.2: Types of Tissues by Whitney Menefee, Julie Jenks, Chiara Mazzasette, and Kim-Leiloni Nguyen is licensed CC BY 4.0.

3.3: Epithelial Tissue

By the end of the section, you will be able to:

- Explain the structure and function of epithelial tissue
- Distinguish between tight junctions, anchoring junctions, and gap junctions
- Distinguish between simple epithelia and stratified epithelia, as well as between squamous, cuboidal, and columnar epithelia
- Describe the structure and function of endocrine and exocrine glands and their respective secretions

Most epithelial tissues are essentially large sheets of cells covering all the surfaces of the body exposed to the outside world and lining the outside of organs. Epithelium also forms much of the glandular tissue of the body. Skin is not the only area of the body exposed to the outside. Other areas include the airways, the digestive tract, as well as the urinary and reproductive systems, all of which are lined by an epithelium. Hollow organs and body cavities that do not connect to the exterior of the body, which includes, blood vessels and the heart, are lined by endothelium (plural = endothelia), which is a type of epithelium.

Epithelial cells derive from all three major embryonic layers. The epithelia lining the skin, parts of the mouth and nose, and the anus develop from the ectoderm. Cells lining the airways and most of the digestive system originate in the endoderm. The epithelium that lines vessels in the lymphatic and cardiovascular system derives from the mesoderm and is called an endothelium.

Characteristics of Epithelial Tissues

All epithelia share some important structural and functional features:

- **Cellularity:** This tissue is highly cellular, with no extracellular material present between cells. Adjoining cells are held tightly together by specialized intercellular connections between their cell membranes.
- **Polarity:** The epithelial cells exhibit polarity with differences in structure and function between the exposed surface of the cell and the attached surface adjacent to the underlying body structures.
- **Attachment:** The basal surface of an epithelium is anchored to the underlying connective tissue by a complex structure of collagen and proteoglycans that is produced jointly by both tissues.
- **Avascularity:** Epithelial tissues are nearly completely avascular. No blood vessels cross the basement membrane to enter the tissue and nutrients must come by diffusion or absorption from underlying tissues or the surface.
- **Regeneration:** Many epithelial tissues are capable of rapidly replacing damaged and dead cells by quickly and continuously undergoing mitosis. Sloughing off of damaged or dead cells is a characteristic of surface epithelium and allows our airways and digestive tracts to rapidly replace damaged cells with new cells.
- **Innervation:** Many sensory receptors are attached to the basal cells or are present in the underlying connective tissue to detect changes in the environment at both the external and internal surfaces of the body.

Generalized Functions of Epithelial Tissue

- **Physical Protection:** Epithelial tissues provide the body's first line of protection from physical, chemical, and biological wear and tear.
- **Selective Permeability:** The cells of an epithelium can act as gatekeepers of the body controlling permeability and allowing selective transfer of materials across a physical barrier. All substances that enter the body must cross an epithelium. Some epithelia often include structural features that allow the selective transport of molecules and ions across their cell membranes.
- **Secretion:** Many epithelial cells are capable of producing substances and releasing (secreting) them onto their apical surfaces. The epithelium of the small intestine releases digestive enzymes, for example. Cells lining the respiratory tract secrete mucous that traps incoming microorganisms and particles. A glandular epithelium may contain many secretory cells, such as the alpha and beta cells of the pancreas that produce hormones.
- **Sensation:** Some epithelial tissues also provide sensation. Nerve supply to epithelial tissues can alert the body to pressure, pain, and temperature from external or internal stimuli. This can help the body to maintain homeostasis or avoid harmful situations in the environment.

Epithelium Structure

Since epithelia are located at all free surfaces they separate the outside of the body from the inside of the body and have distinct structural specializations that allow them to fulfill this unique role. Both the individual cells and the sheet of cells exhibit a characteristic polarity: they have an **apical surface** that is exposed and is in contact with the outside as well as a **basal surface** that is attached to an underlying proteinaceous layer called the **basement membrane**. This membrane allows the epithelial cells to hook onto one side of it and the underlying connective tissue, called the **lamina propria**, to attach to the other (Figure 3.3.1). This keeps the epithelium firmly anchored in place and helps prevent distortions and tearing.

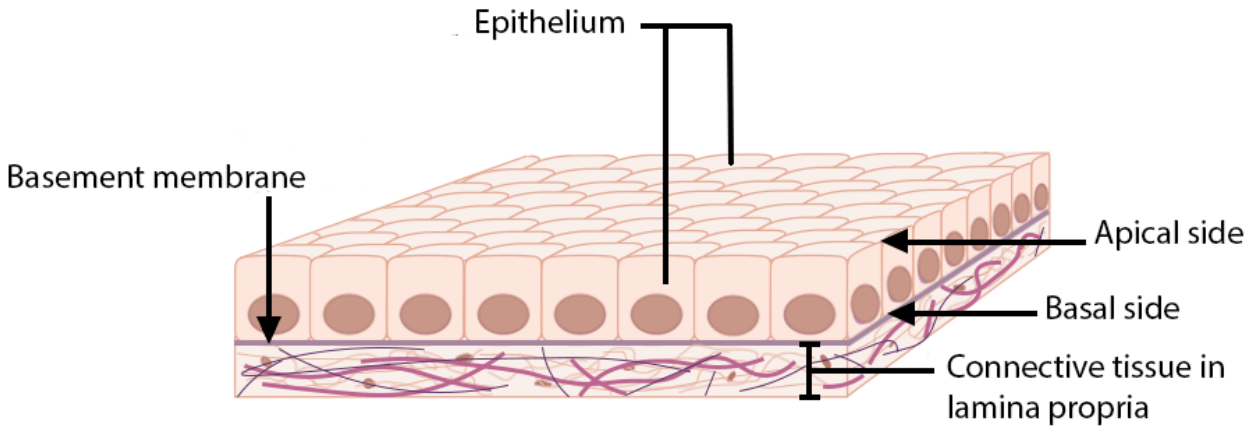

Figure 3.3.1: ABC's of an Epithelium. From the exterior toward the interior the structures of an epithelium are: **A**pical surface, **B**asal surface and **B**asement membrane, **C**onnective Tissue of the lamina propria. *(Image credit: "ABC's of an Epithelium" by Jennifer Lange is licensed under CC-BY-NC-SA 4.0, modified from original by Cancer Research UK via Wikimedia Commons.)*

Epithelial cells also have a polarized distribution of organelles and membrane-bound proteins between their basal and apical surfaces. Particular structures found in some epithelial cells are an adaptation to specific functions. Certain organelles are segregated to the basal sides, whereas other organelles and extensions, such as cilia, when present, are on the apical surface. The transport channels within the cell membranes also differ between the two sides. For example, if you want to absorb a glucose molecule you have ingested you need two transporters - one to bring the molecule into the cell on the apical side and another to kick it out of the cell so it can enter into the bloodstream. If both transporters were exactly the same you could only, for example, move sugar into the cell!

Cell to Cell Junctions

Cells of epithelia are closely connected and are not separated by intracellular material. Three basic types of connections allow varying degrees of interaction between the cells: tight junctions, anchoring junctions, and gap junctions (Figure 3.3.2).

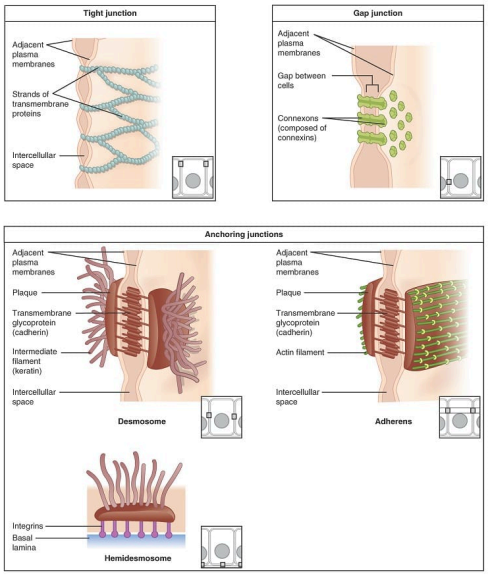

Figure 3.3.2: Types of Cell Junctions. The three basic types of cell-to-cell junctions are tight junctions, gap junctions, and anchoring junctions. *(Image credit: "Types of Cell Junctions" by OpenStax is licensed under CC BY 3.0.)*

- At one end of the spectrum is the **tight junction**, which separates the cells into apical and basal compartments. Tight junctions essentially "stitch" adjacent cell together, forming an impermeable barrier.
- An **anchoring junction** includes several types of cell junctions that help stabilize epithelial tissues. Anchoring junctions are common on the lateral and basal surfaces of cells where they provide strong and flexible connections. There are three types of anchoring junctions: desmosomes, hemidesmosomes, and adherens.
  - **Desmosomes** occur in patches on the membranes of cells. The patches are structural proteins on the inner surface of the cell's membrane. The adhesion molecule, cadherin, is embedded in these patches and projects through the cell membrane to link with the cadherin molecules of adjacent cells. These connections are especially important in holding cells together.
  - **Hemidesmosomes**, which look like half a desmosome, link cells to the extracellular matrix, for example, the basal lamina. While similar in appearance to desmosomes, they include the adhesion proteins called integrins rather than cadherins.
  - **Adherens** junctions use either cadherins or integrins depending on whether they are linking to other cells or matrix. The junctions are characterized by the presence of the contractile protein actin located on the cytoplasmic surface of the cell membrane. The actin can connect isolated patches or form a belt-like structure inside the cell. These junctions influence the shape and folding of the epithelial tissue.

In contrast with the tight and anchoring junctions, a **gap junction** forms an intercellular passageway between the membranes of adjacent cells to facilitate the movement of small molecules and ions between the cytoplasm of adjacent cells. These junctions allow electrical and metabolic coupling of adjacent cells, which coordinates function in large groups of cells.

Classification of Epithelial Tissues

Epithelial tissues are classified according to the shape of the cells and number of the cell layers formed (Figure 3.3.3). Cell shapes can be squamous (flattened and thin), cuboidal (boxy, as wide as it is tall), or columnar (rectangular, taller than it is wide). Similarly, the number of cell layers in the tissue can be one—where every cell rests on the basal lamina—which is a simple epithelium, or more than one, which is a stratified epithelium and only the basal layer of cells rests on the basal lamina with the remaining layers attaching to the more basal cells. Pseudostratified (pseudo- = "false") describes tissue with a single layer of irregularly shaped cells that give the appearance of more than one layer. Transitional describes a form of specialized stratified epithelium in which the shape of the cells can vary.

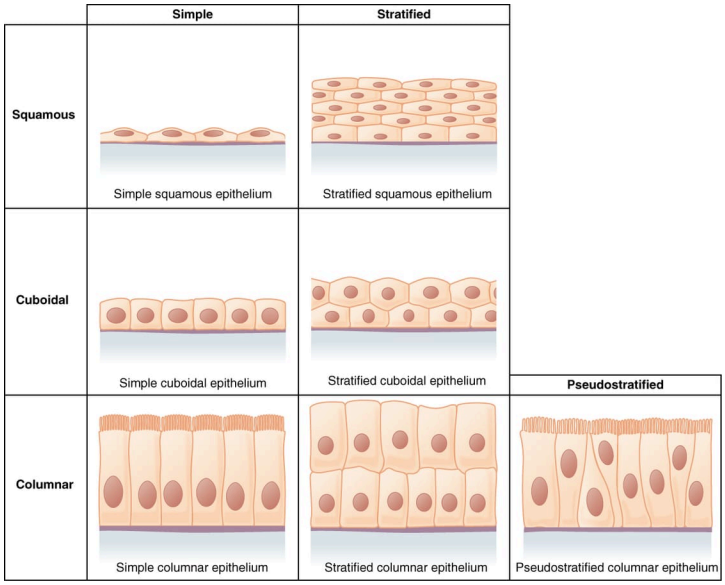

Figure 3.3.3: Epithelial Tissues. Simple epithelial tissue is organized as a single layer of cells and stratified epithelial tissue is formed by several layers of cells. *(Image credit: "Epithelial Tissue" by OpenStax is licensed under CC BY 3.0.)*

Simple Epithelia

The shape of the cells in the single cell layer of simple epithelium reflects the functioning of those cells. The cells in **simple squamous epithelium** (Figure 3.3.3 and Figure 3.3.4) have the appearance of thin scales. Squamous cell nuclei tend to be flat, horizontal, and elliptical, mirroring the form of the cell. The **endothelium** is the epithelial tissue that lines vessels of the lymphatic and cardiovascular system, and it is made up of a single layer of squamous cells. Simple squamous epithelium, because of the thinness of the cell, is present where rapid passage of chemical compounds is observed. The alveoli of lungs where gases diffuse, segments of kidney tubules, and the lining of capillaries are also made of simple squamous epithelial tissue. The **mesothelium** is a simple squamous epithelium that forms the surface layer of the serous membrane that lines body cavities and internal organs. Its primary function is to provide a smooth and protective surface. Mesothelial cells are squamous epithelial cells that secrete a fluid that lubricates the mesothelium.

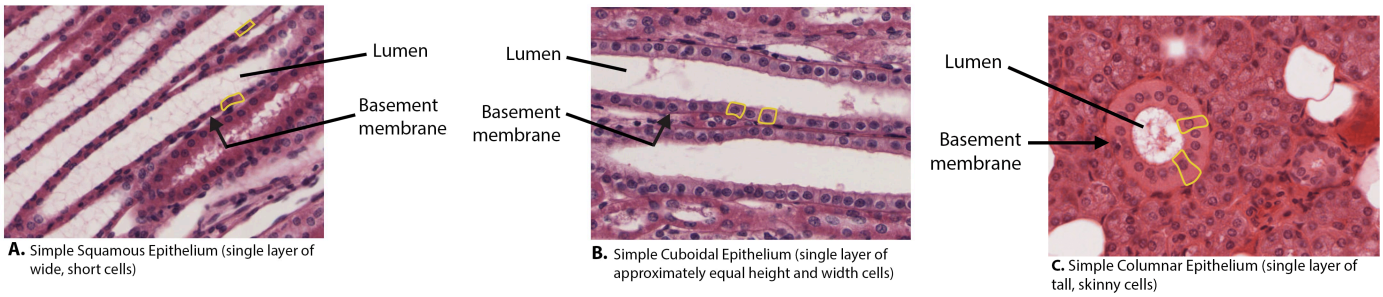

A. Simple Squamous Epithelium (single layer of wide, short cells)

B. Simple Cuboidal Epithelium (single layer of approximately equal height and width cells)

C. Simple Columnar Epithelium (single layer of tall, skinny cells)

Figure 3.3.4: Histology of Simple Epithelia @ 400x. All simple epithelia have a single layer of cells between the lumen and the basal side and all cells attach to the basement membrane. Individual cells are outlined in yellow to illustrate their characteristic shape: A. simple squamous epithelium in the kidney, B. simple cuboidal epithelium in the kidney, C. simple columnar epithelium in the salivary glands. *(Image credit: "Histology of Simple Epithelia" by Jennifer Lange is licensed under CC-BY-NC-SA 4.0, images provided by the Regents of the University of Michigan Medical School under CC-BY-NC-SA 4.0 © 2022.)*

In **simple cuboidal epithelium** (Figure 3.3.3 and Figure 3.3.4), the nucleus of the box-like cells appears round and is generally located near the center of the cell. These epithelia are active in the secretion and absorption of molecules. Simple cuboidal epithelia are observed in the lining of the kidney tubules and in the ducts of glands.

In **simple columnar epithelium** (Figure 3.3.3 and Figure 3.3.4), the nucleus of the tall column-like cells tends to be elongated and located in the basal end of the cells. Like the cuboidal epithelia, this epithelium is active in the absorption and secretion of molecules. Simple columnar epithelium forms the lining of some sections of the digestive system and parts of the female reproductive tract. Ciliated columnar epithelium is composed of simple columnar epithelial cells with cilia on their apical surfaces.

These epithelial cells are found in the lining of the Fallopian tubes and parts of the respiratory system, where the beating of the cilia helps remove particulate matter.

Pseudostratified columnar epithelium (Figure 3.3.3 and Figure 3.3.5) is a type of epithelium that appears to be stratified but instead consists of a single layer of irregularly shaped and differently sized columnar cells. In pseudostratified epithelium, nuclei of neighboring cells appear at different levels rather than clustered toward the basal side. The arrangement gives the appearance of stratification; but in fact all the cells are in contact with the basement membrane, although some do not reach the apical surface. Pseudostratified columnar epithelium is found in the respiratory tract, where some of these cells have cilia.

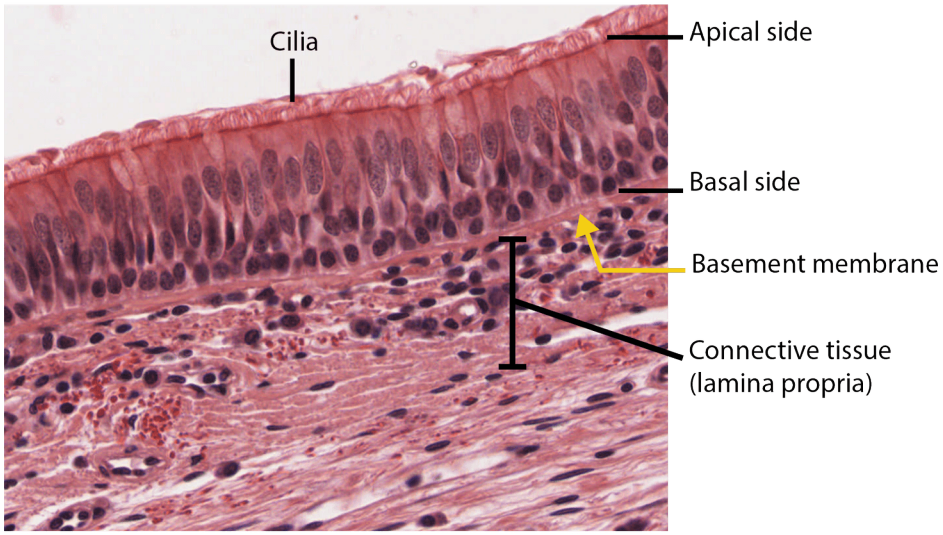

Figure 3.3.5: Histology of Pseudostratified Columnar Epithelium @ 400x. Although it appears to have multiple layers because of the postion of the nuclei, all cells attach to the basement membrane. *(Image credit: "Histology of Pseudostratified Columnar Epithelium" by Jennifer Lange, is licensed under CC-BY-NC-SA 4.0, image provided by the Regents of the University of Michigan Medical School under CC-BY-NC-SA 4.0 © 2022).*

Both simple and pseudostratified columnar epithelia can include additional types of cells interspersed among the epithelial cells. For example, a **goblet cell** is a mucous-secreting unicellular “gland” interspersed between the columnar epithelial cells of mucous membranes (Figure 3.3.6).

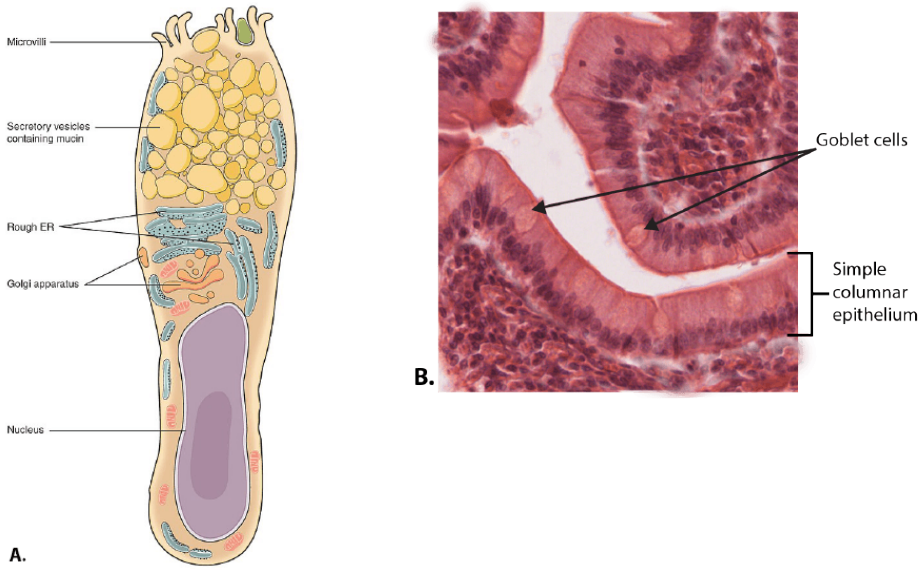

Figure 3.3.6: Goblet Cells. A. Goblet cells are specialized for the production and secretion of the protein mucin that becomes mucous when it is mixed with water. B. In the lining of the small intestine, goblet cells are scattered amoungst the columnar cells. LM × 1000. *(Image credits: A. "Goblet Cell" by OpenStax is licensed under CC BY 3.0; B. "Goblet Cell Histology" by Jennifer Lange is licensed under CC-BY-NC-SA 4.0, micrograph provided by the Regents of the University of Michigan Medical School under CC-BY-NC-SA 4.0 © 2022.)*

Stratified Epithelia

A stratified epithelium consists of several stacked layers of cells. This epithelium protects against physical and chemical wear and tear. The stratified epithelium is named by the shape of the most apical layer of cells, closest to the free space.

Stratified squamous epithelium (Figure 3.3.7*C*) is the most common type of stratified epithelium in the human body. The apical cells are squamous, whereas the basal layer contains either columnar or cuboidal cells. The top layer may be covered with dead cells filled with the protein keratin. The epidermis of mammalian skin is an example of this dry, keratinized, stratified squamous epithelium. The lining of the oral cavity is an example of an non-keratinized, stratified squamous epithelium.

Stratified cuboidal epithelium and **stratified columnar epithelium** (Figure 3.3.7.*A*.*B*) can be found in certain glands and ducts. Both are uncommon in the human body.

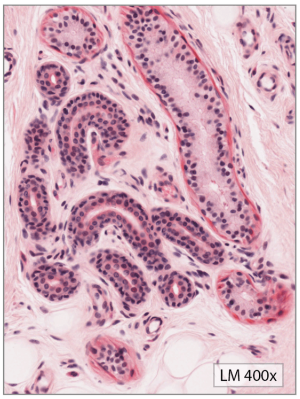

A. Stratified Cuboidal Epithelium (multiple layers of cells, apical cells are approximately equal height and width)

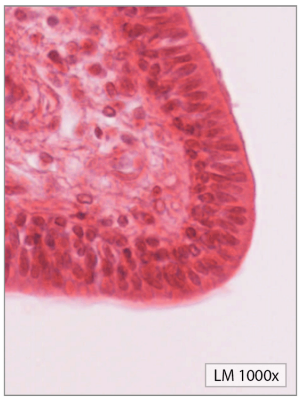

B. Stratified Columnar Epithelium (multiple layers of cells, apical cells are tall and narrow)

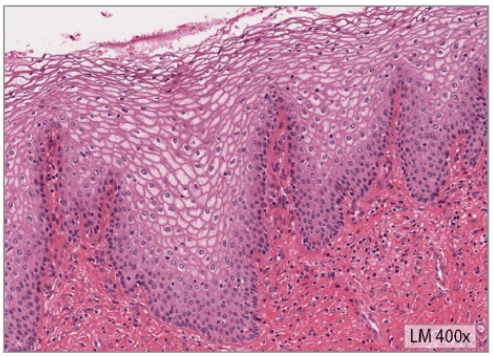

C. Stratified Squamous Epithelium (multiple layers of cells, cells at apical surface are wide and short)

Figure 3.3.7: Stratified Epithelia Histology. All stratified epithelia have multiple layers of cells between the apical surface and basal sur with the superficial cells attaching to the deeper cells instead of to the basement membrane. A. stratified cuboidal epithelium of a sv gland, B. stratified columnar epithelium of the male urethra, C. stratified squamous epithelium of the vagina. *(Image credit: "Histolog Stratified Epithelia" by Jennifer Lange is licensed under CC-BY-NC-SA 4.0, images provided by the Regents of the University of Mich Medical School under CC-BY-NC-SA 4.0 © 2022.)*

Another kind of stratified epithelium is **transitional epithelium** (Figure 3.3.8), so-called because of the gradual changes in the shapes of the apical cells as the bladder fills with urine. It is found only in the urinary system, specifically the ureters and urinary bladder. When the bladder is empty, this epithelium is convoluted and has cuboidal apical cells with convex, umbrella shaped, apical surfaces. As the bladder fills with urine, this epithelium loses its convolutions and the apical cells transition from cuboidal to squamous. It appears thicker and more multi-layered when the bladder is empty, and more stretched out and less stratified when the bladder is full and distended.

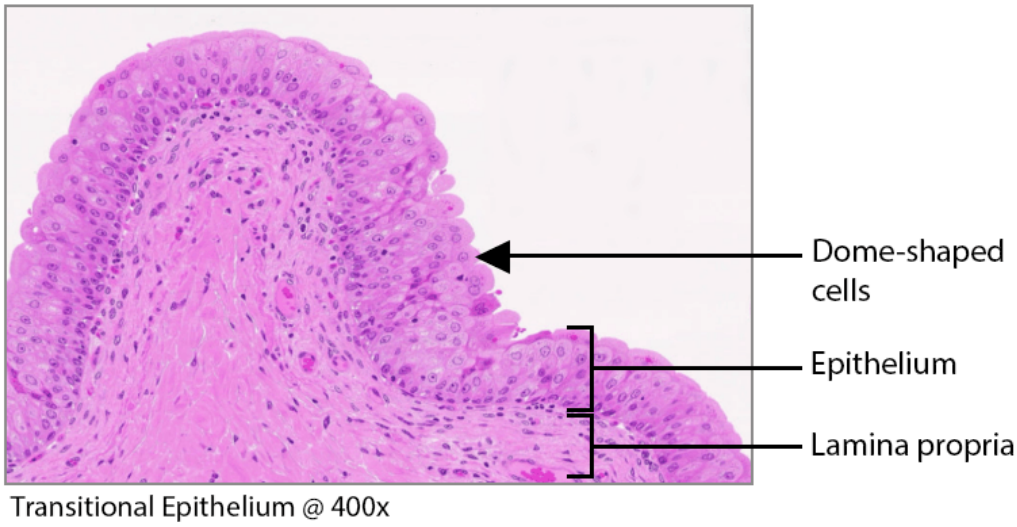

Figure 3.3.8: Transitional Epithelium. Transitional epithelium is found lining organs of the urinary system. These organs are able to stretch because the rounded epithelial cells will flatten out. *(Image credit:"Histology of Transitional Epithelium" by Jennifer Lange is licensed under, image provided by the Regents of the University of Michigan Medical School under CC-BY-NC-SA 4.0 © 2022.)*

Table 3.3.1: Summary of Epithelial Tissues. *The cell shape and number of layers determines an epithelial tissue's location and function.*

Tissue	Location	Function
Simple Squamous Epithelium	Air sacs of lungs, tubules of the kidneys, and lining of the heart, blood vessels, and lymphatic vessels.	Allows material to pass through by diffusion and filtration, and secretes lubricating substance

Tissue	Location	Function
Simple Cuboidal Epithelium	In ducts and secretory portions of small glands and in the kidney tubules	Secretes and absorbs
Simple Columnar Epithelium 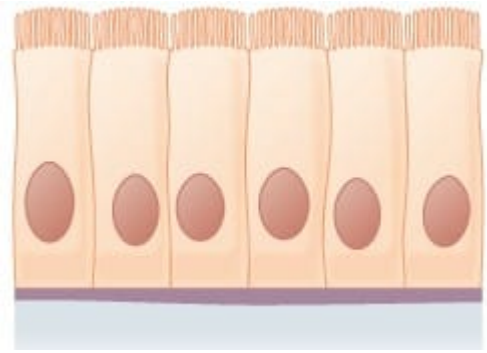	Ciliated tissues are in bronchi, uterine tubes, and uterus Smooth (nonciliated tissues) are in the digestive tract, gallbladder	Absorbs; it also secretes mucous and enzymes May have goblet cells
Pseudostratified Columnar Epithelium 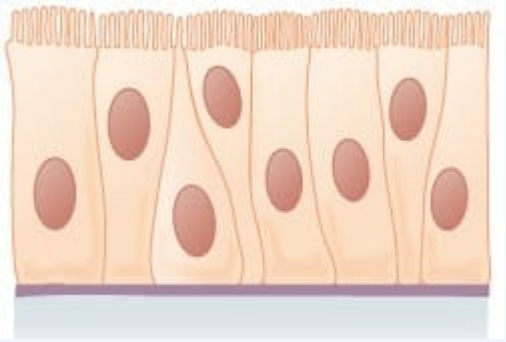	Ciliated tissue lines the trachea and much of the upper respiratory tract Nonciliated tissue is found in the middle regions of the male urethra	Secretes mucus, ciliated tissue moves mucus Has goblet cells
Stratified Squamous Epithelium 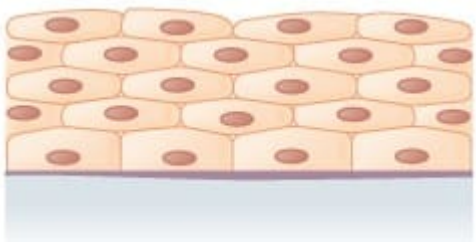	Lines the esophagus, mouth, anus, vagina, and distal urethra; forms epidermis of the skin	Protects against abrasion

Tissue	Location	Function
Stratified Cuboidal Epithelium 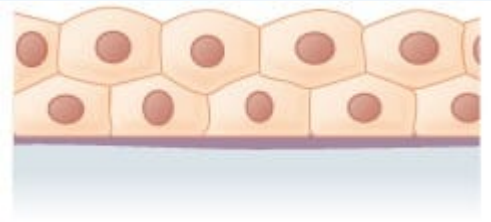	Sweat glands, salivary glands, and the mammary glands	Secretory tissue
Stratified Columnar Epithelium 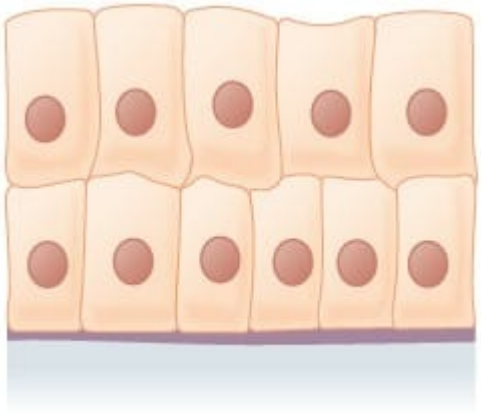	The ducts of some glands	Secretes and protects
Transitional Epithelium 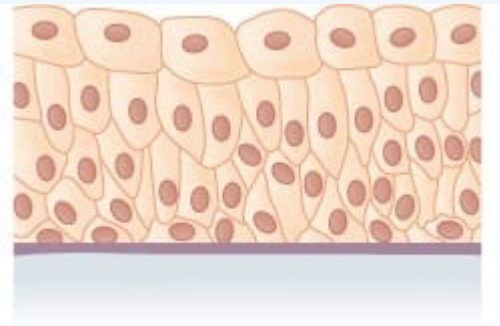	Lines the urinary bladder, proximal urethra, and the ureters	Allows the urinary organs to expand and stretch

Glandular Epithelium

A gland is a structure made up of one or more cells modified to synthesize and secrete chemical substances. Most glands consist of groups of epithelial cells. A gland can be classified as an **endocrine gland**, a ductless gland that releases secretions directly into surrounding tissues and fluids (endo- = “inside”), or an **exocrine gland** whose secretions leave through a duct that opens directly, or indirectly, to the external environment (exo- = “outside”).

Endocrine Glands

The secretions of endocrine glands are called hormones. Hormones are released into the interstitial fluid, diffused into the bloodstream, and delivered to targets, in other words, cells that have receptors to bind the hormones. The endocrine system is part of a major regulatory system coordinating the regulation and integration of body responses. A few examples of endocrine glands include the anterior pituitary, thymus, adrenal cortex, and gonads (ovaries and testes).

Exocrine Glands

Exocrine glands release their contents through a duct that leads to the epithelial surface. Mucous, sweat, saliva, and breast milk are all examples of secretions from exocrine glands. They are all discharged through tubular ducts. Secretions into the lumen of the gastrointestinal tract, technically outside of the body, are of the exocrine category.

Glandular Structure

Exocrine glands are classified as either unicellular or multicellular. The unicellular glands are scattered single cells, such as goblet cells, found in the mucous membranes of the small and large intestine.

The multicellular exocrine glands known as serous glands develop from simple epithelium to form a secretory surface that secretes directly into an inner cavity. These glands line the internal cavities of the abdomen and chest and release their secretions directly into the cavities. Other multicellular exocrine glands release their contents through a tubular duct. The duct is singular in a simple gland but in compound glands it is divided into one or more branches (Figure 3.3.9). The shape of the duct can be either tubular (uniform diameter) or alveolar (rounded pockets). In tubular glands, the ducts can be straight or coiled. Combinations of tubes and pockets are known as tubuloalveolar (tubuloacinar) compound glands. In a branched gland, a duct is connected to more than one secretory group of cells.

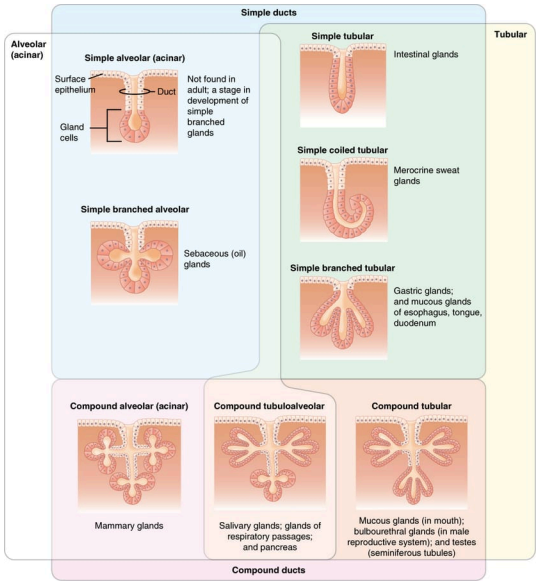

Figure 3.3.9: Types of Exocrine Glands. Exocrine glands are classified by their structure. *(Image credit: "Types of Glands" by OpenStax is licensed under CC BY 3.0.)*

Methods and Types of Secretion

Exocrine glands can be classified by their mode of secretion and the nature of the substances released, as well as by the structure of the glands and shape of ducts (Figure 3.3.10). **Merocrine secretion** is the most common type of exocrine secretion. The secretions are enclosed in vesicles that move to the apical surface of the cell where the contents are released by exocytosis. For example, watery mucous containing the glycoprotein mucin, a lubricant that offers some pathogen protection is a merocrine secretion. The eccrine glands that produce and secrete sweat are another example.

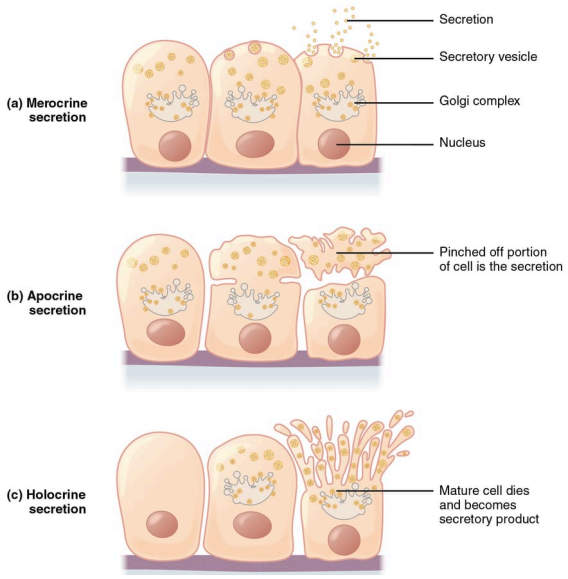

Figure 3.3.10: Modes of Glandular Secretion. (a) In merocrine secretion, the cell remains intact. (b) In apocrine secretion, the apical portion of the cell contining the product is released. (c) In holocrine secretion, the cell is destroyed as it releases its product and the cell itself becomes part of the secretion. *(Image credit: "Modes of Secretion by Glands" by OpenStax is licensed under CC BY 3.0.)*

In **apocrine secretion** the secretory product accumulates near the apical portion of the cell. That portion of the cell and its secretory contents pinch off from the cell and are released. Some sweat glands of the axillary region are classified as apocrine glands. Both merocrine and apocrine glands continue to produce and secrete their contents with little damage caused to the cell because the nucleus, rER and Golgi regions remain intact after secretion.

In contrast, the process of **holocrine secretion** involves the rupture and destruction of the entire gland cell. The cell accumulates its secretory products and releases them only when it bursts. New gland cells differentiate from cells in the surrounding tissue to replace those lost by secretion. The sebaceous glands that produce the oils on the skin and hair are holocrine glands/cells (Figure 3.3.11).

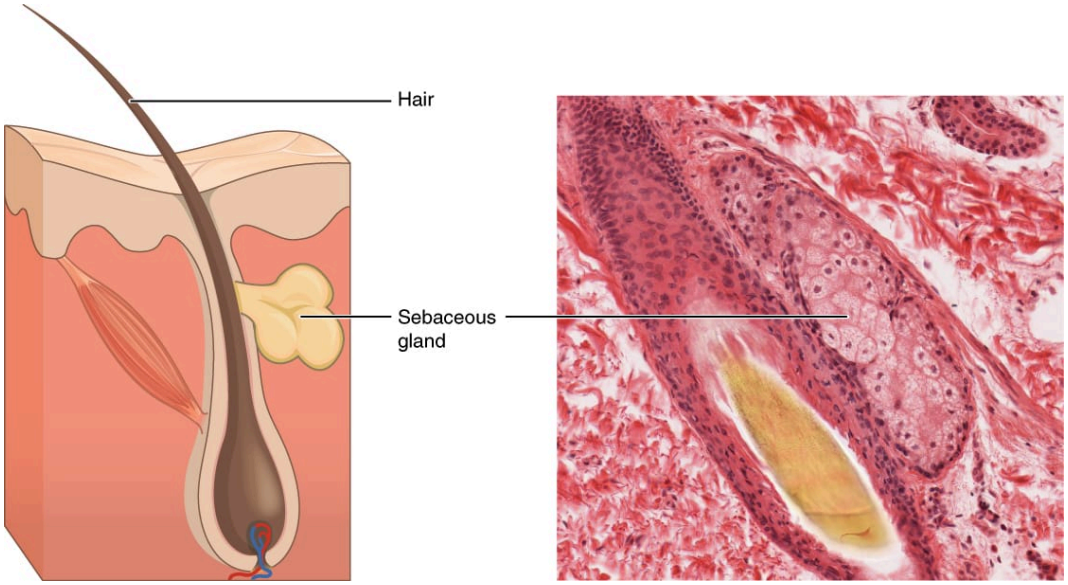

Figure 3.3.11: Sebaceous Glands. These glands secrete oils that lubricate and protect the skin. They are holocrine glands and they are destroyed after releasing their contents. New glandular cells form to replace the cells that are lost. LM × 400. *(Image credit: "Sebaceous Glands" by OpenStax is licensed under CC BY 3.0/ Micrograph provided by the Regents of University of Michigan Medical School © 2012.)*

Concept Review

In epithelial tissue, cells are closely packed with little or no extracellular matrix except for the basal lamina that separates the epithelium from underlying tissue.

The main functions of epithelia are: protection from the environment, coverage, secretion and excretion, absorption, and filtration.

Cells are bound together by tight junctions that form an impermeable barrier. They can also be connected by gap junctions, which allow free exchange of soluble molecules between cells, and anchoring junctions, which attach cell to cell or cell to matrix.

The different types of epithelial tissues are characterized by their cellular shapes and arrangements: squamous, cuboidal, or columnar epithelia. Single cell layers form simple epithelia, whereas stacked cells form stratified epithelia.

Very few capillaries penetrate these tissues.

Glands are secretory tissues and organs that are derived from epithelial tissues.

- Exocrine glands release their products through ducts.
- Endocrine glands secrete hormones directly into the interstitial fluid and blood stream.

Review Questions

Query 3.3.1

This interactive element is not available in this format. Visit the link or scan the QR code to access it online.

View this Interactive Content online

Query 3.3.2

This interactive element is not available in this format. Visit the link or scan the QR code to access it online.

View this Interactive Content online

Critical Thinking Questions

Query 3.3.3

This interactive element is not available in this format. Visit the link or scan the QR code to access it online.

View this Interactive Content online

Glossary

Query 3.3.4

This interactive element is not available in this format. Visit the link or scan the QR code to access it online.

View this Interactive Content online

Contributors and Attributions

- OpenStax Anatomy & Physiology (CC BY 4.0). Access for free at https://openstax.org/books/anatomy-and-physiology

This page titled 3.3: Epithelial Tissue is shared under a CC BY-NC-SA 4.0 license and was authored, remixed, and/or curated by Jennifer Lange et al..

- 3.3: Epithelial Tissue by Whitney Menefee, Julie Jenks, Chiara Mazzasette, and Kim-Leiloni Nguyen is licensed CC BY 4.0.

3.4: Connective Tissue

By the end of the section, you will be able to:

- Explain how connective tissues are classified.
- Identify and distinguish between the individual types of connective tissue within each category: proper, supportive, and fluid
- Identify the cellular and extracellular matrix features of each connective tissue type
- Explain the functions of each type of connective tissue relate to their structure

As may be obvious from its name, one of the major functions of connective tissue is to connect tissues together to form an organ. Unlike epithelial tissue, which is composed of cells closely packed with little or no extracellular space in between, connective tissue cells are dispersed in a **matrix**. The matrix usually includes a large amount of extracellular material produced by the connective tissue cells that are embedded within it. The extracellular matrix plays a major role in the functioning of this tissue. The two components of the matrix are a **ground substance** and **protein fibers**. This ground substance is usually a liquid of varying viscosity, but it can also be mineralized and solid, as in bones. Connective tissues come in a vast variety of forms, yet they typically have in common three characteristic components: scattered cells, large amounts of amorphous ground substance, and protein fibers. The amount and structure of each component correlates with the function of the tissue, from the rigid ground substance in bones supporting the body to the inclusion of specialized cells; for example, phagocytic cells that engulf pathogens and also rid tissue of cellular debris are common in many connective tissues.

Functions of Connective Tissues

Connective tissues perform many functions in the body, but most importantly, they support and connect other tissues; from the connective tissue sheath that surrounds muscle cells, to the tendons that attach muscles to bones, and to the skeleton that supports the positions of the body. Protection is another major function of connective tissue, in the form of fibrous capsules and bones that protect delicate organs and, of course, the skeletal system. Specialized cells in connective tissue defend the body from microorganisms that enter the body. Transport of fluid, nutrients, waste, and chemical messengers is ensured by specialized fluid connective tissues, such as blood and lymph. Adipose cells store surplus energy in the form of fat and contribute to the thermal insulation of the body.

Embryonic Connective Tissue

All connective tissues derive from the mesodermal layer of the embryo. The first connective tissue to develop in the embryo is **mesenchyme**, the stem cell line from which all connective tissues are later derived. Clusters of mesenchymal cells are scattered throughout adult tissue and supply the cells needed for replacement and repair after a connective tissue injury. A second type of embryonic connective tissue forms in the umbilical cord, called **mucous connective tissue** or Wharton's jelly. This tissue is no longer present after birth, leaving only scattered mesenchymal cells throughout the body.

Connective Tissue Fibers and Ground Substance

Three main types of fibers in the extracellular matrix are: collagen fibers, elastic fibers, and reticular fibers (see Figure 3.4.1 and Figure 3.4.2).

- **Collagen fibers** are made from fibrous protein subunits linked together to form a long and straight fiber. Collagen fibers, while flexible, have great tensile strength, resist stretching, and give ligaments and tendons their characteristic resilience and strength. These fibers hold connective tissues together, even during the movement of the body.
- **Elastic fibers** contain the protein elastin along with lesser amounts of other proteins and glycoproteins. The main property of elastin is that after being stretched or compressed, it will return to its original shape. Elastic fibers are prominent in elastic tissues found in skin and the elastic ligaments of the vertebral column.
- **Reticular fibers** are formed from the same protein subunits as collagen fibers; however, these fibers remain narrow and are arrayed in a branching network. They are found throughout the body, but are most abundant in the reticular tissue of soft

organs, such as liver and spleen, where they anchor and provide structural support to the the functional cells, blood vessels, and nerves of the organ.

Visualizing Protein Fibers in Connective Tissue

In order to see the protein fibers on a slide they needed to be stained. Which fibers you can see depends on which staining technique is used, but you will not see all three types with any one stain.

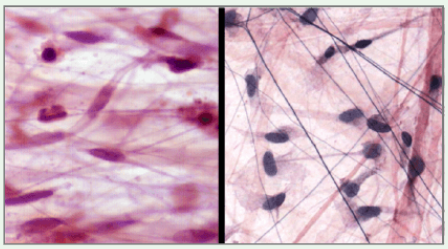

A. Areolar tissue @ 1000x - collagen and elastin

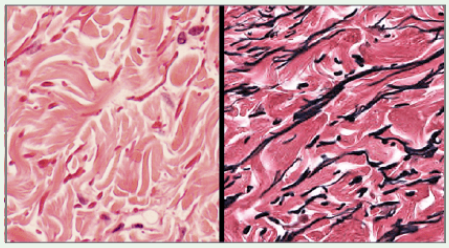

B. Dense irregular tissue @ 400x - collagen and elastin

(Figure 3.4.1): The most common stain seen in introductory anatomy courses is hematoxylin and eosin (H&E) that shows both collagen and elastin, but the elastin is harder to distinguish (both left-hand images). Both elastin and collagen can be visualized using the Verhoeff method in which collagen appears pink/red and elastin is dark purple/black. *(Image credit: "Collagen and Elastin Staining" by Jennifer Lange is licensed under CC-BY-NC-SA 4.0. Micrographs provided by Virginia Commonwealth University.)*

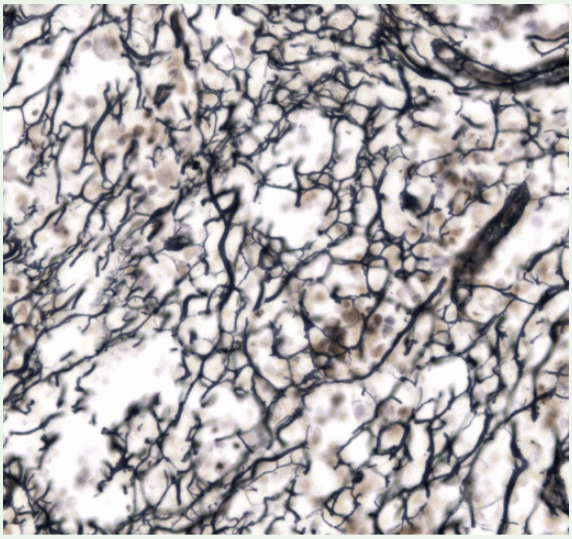

Reticular tissue - reticular fibers

(Figure 3.4.2): Reticular fibers need a different stain to show on the slide - either silver or Periodic Acid Schiff (PAS). Both techniques show the branching nature of the fibers. *(Image credit: "Reticulin Staining" by Jennifer Lange is licensed under CC-BY-NC-SA 4.0. Micrograph provided by Virginia Commonwealth University.)*

All of these fiber types are embedded in ground substance. Secreted by the connective tissue cells, ground substance is made of polysaccharides and proteins. These combine and the resultant structure attracts and traps available moisture. This forms the clear, viscous, colorless matrix you now know as ground substance.

Classification of Connective Tissues

The three broad categories of connective tissue are classified according to the characteristics of their ground substance and the types of fibers found within the matrix (Figure 3.4.3).

- **Connective tissue proper** includes **loose connective tissue** and **dense connective tissue**. Both tissues have a variety of cell types and protein fibers suspended in a viscous ground substance.
  - Dense connective tissue is reinforced by bundles of fibers that provide tensile strength, elasticity, and protection. It has lots of protein fibers and little or very little ground substance.
  - In loose connective tissue, the fibers are loosely organized, leaving large spaces in between that are filled with ground substance.
- **Supportive connective tissue**—bone and cartilage—provide structure and strength to the body and protect soft tissues. A few distinct cell types and densely packed fibers in a matrix characterize these tissues. In **bone** the matrix is solid and described as calcified because of the deposited calcium salts. In **cartilage** the matrix is semi-solid, with abundant collagen and proteoglycans and lesser amounts of water, other proteins, and glycoproteins.
- In **fluid connective tissue**, lymph and blood, various specialized cells circulate in a watery fluid containing salts, nutrients, and dissolved proteins. This group of connective tissues do not have protein fibers in their matrix.

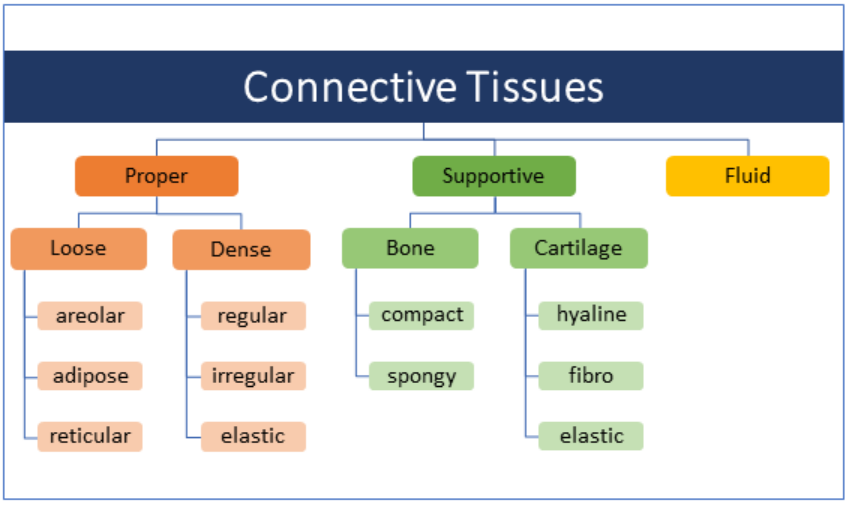

Figure 3.4.3: Classification of Connective Tissues. Connective tissues are divided into groups based on the viscosity (thickness) of their ground substance and then into sub-groups based on their fiber types and arrangement. *(Image Credit: "Classification of Connective Tissues" by Jennifer Lange, licensed under CC-BY-NC-SA 4.0)*

Connective Tissue Proper

Connective tissue proper include the types of connective tissues that have a mixture of the possible cell types, varying amounts and types of protein fibers, and a ground substance that has a gel-like consistency. Because of their variety in structure, they can perform a variety of functions.

Cell Types

Fibroblasts/fibrocytes, adipocytes, and mesenchymal cells are fixed cells, which means they remain within the connective tissue. Other cells move in and out of the connective tissue in response to chemical signals. Macrophages, mast cells, lymphocytes, and plasma cells are found in connective tissue proper but are actually part of the immune system protecting the body. The most abundant cell in connective tissue proper is the **fibroblast** (Figure 3.4.4). Blast cells are builders, they are producing the components of the extracellular matrix. **Fibrocytes**, a less active form of fibroblast, is the second most common cell type in connective tissue proper.

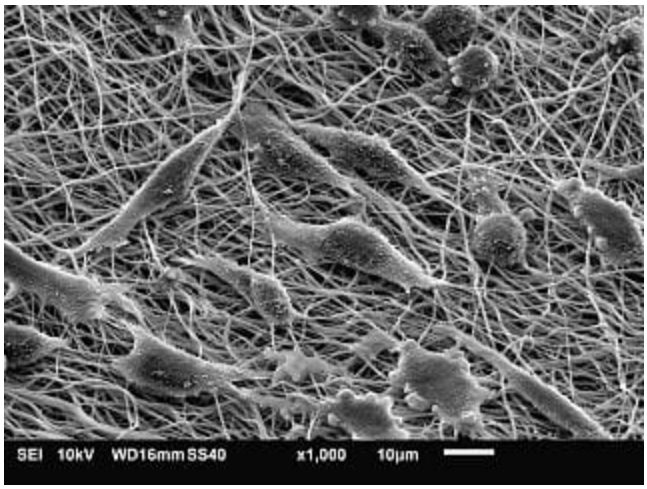

Figure 3.4.4: Cells of Connective Tissue Proper: Fibroblasts. Fibroblasts produce materials in the extracellular matrix of proper connective tissues. C SEM × 1000. *(Image credit: "SEM of fibroblasts" by Judyta Dulnik is licensed under CC-BY-SA 4.0)*

Adipocytes are cells that store lipids as droplets that fill most of the cytoplasm. There are two basic types of adipocytes: white and brown. The brown adipocytes store lipids as many droplets, and have high metabolic activity. In contrast, white fat adipocytes store lipids as a single large drop and are metabolically less active. Their effectiveness at storing large amounts of fat is witnessed in obese individuals. The number and type of adipocytes depends on the tissue and location, and vary among individuals in the population.

The **mesenchymal cell** is a multipotent adult stem cell. These cells can differentiate into any type of connective tissue cells needed for repair and healing of damaged tissue.

The **macrophage** cell is a large cell derived from a monocyte, a type of white blood cell, which enters the connective tissue matrix from the blood vessels. The macrophage cells are an essential component of the immune system, which is the body's defense against potential pathogens and degraded host cells.

The **mast cell**, another type of white blood cell found in proper connective tissues, releases inflammatory chemicals.

Loose Connective Tissues

Loose connective tissue is found between many organs where it acts both to absorb shock and bind tissues together. It allows water, salts, and various nutrients to diffuse through to adjacent or embedded cells and tissues.

- **Adipose tissue** consists mostly of fat storage cells, with little extracellular matrix (Figure 3.4.5). A large number of capillaries allow rapid storage and mobilization of lipid molecules. White adipose tissue is most abundant. It can appear yellow and owes its color to carotene and related pigments from plant food. White fat contributes mostly to lipid storage and can serve as insulation from cold temperatures and mechanical injuries. White adipose tissue can be found protecting the kidneys and cushioning the back of the eye. Brown adipose tissue is more common in infants, hence the term "baby fat." In adults, there is a reduced amount of brown fat and it is found mainly in the neck and clavicular regions of the body. The many mitochondria in the cytoplasm of brown adipose tissue help explain its efficiency at metabolizing stored fat. Brown adipose tissue is thermogenic, meaning that as it breaks down fats, it releases metabolic heat, rather than producing adenosine triphosphate (ATP), a key molecule used in metabolism.

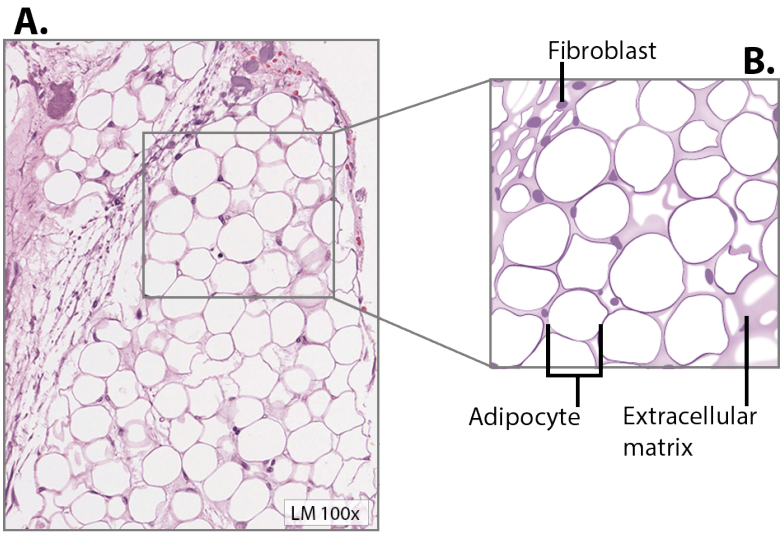

Figure 3.4.5: Adipose Tissue. This is a loose connective tissue that consists of adipocytes and limited extracellular matrix. Adipocytes store fat for energy and provides insulation. The number of adipocytes stays constant after adolescence, the cells just change in size. *(Image credit: "Adipose Tissue" by Jennifer Lange, illustration by Claire McGuire, is licensed under CC-BY-NC-SA 4.0. Micrograph provided by Berkshire Community College Bioscience Image Library is in the Public Domain.)*

- **Areolar tissue** shows little specialization, yet is it found almost everywhere in the body. It is like an all purpose glue. It contains all the cell types and fibers previously described. The fibers are distributed in a random, web-like fashion (Figure 3.4.6). It fills the spaces between muscle fibers, surrounds blood and lymph vessels, and supports organs in the abdominal cavity. Areolar tissue underlies most epithelia and represents the connective tissue component of epithelial membranes, which are described further in a later section.

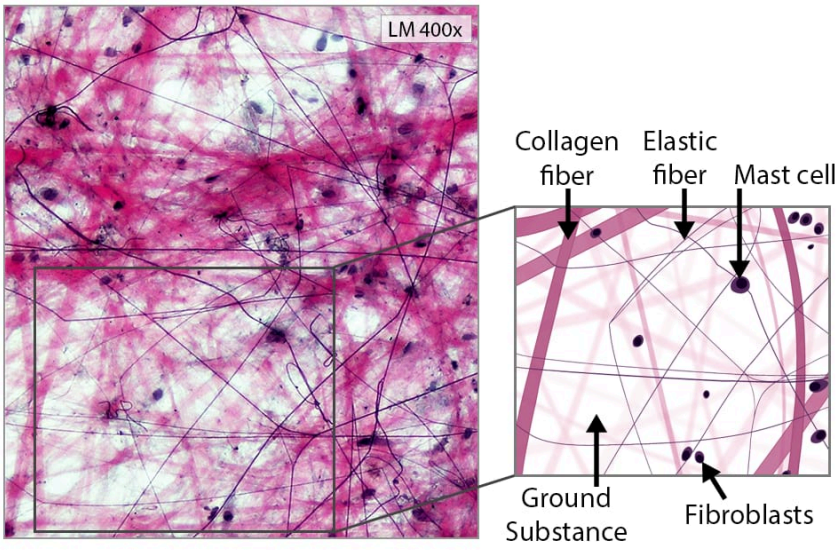

Figure 3.4.6: Areolar Connective Tissue. This is a loose connective tissue containing all components found in connective tissue proper, though not all are visible at the same time on a slide. Reticulin fibers are visualized using a different staining technique than in this image. *(Image credit: "Areolar Connective Tissue" by Jennifer Lange, illustration by Claire McGuire, is licensed under CC BY-NC-SA 4.0. Micrograph provided by Berkshire Community College Bioscience Image Library is in the Public Domain.)*

- **Reticular tissue** is a mesh-like, supportive framework for soft organs such as lymphatic tissue, the spleen, and the liver (Figure 3.4.7). Fibroblasts (and a specialized subtype call reticular cells) produce the reticular fibers that form the network onto which other cells attach. It derives its name from the Latin *reticulus*, which means "little net."

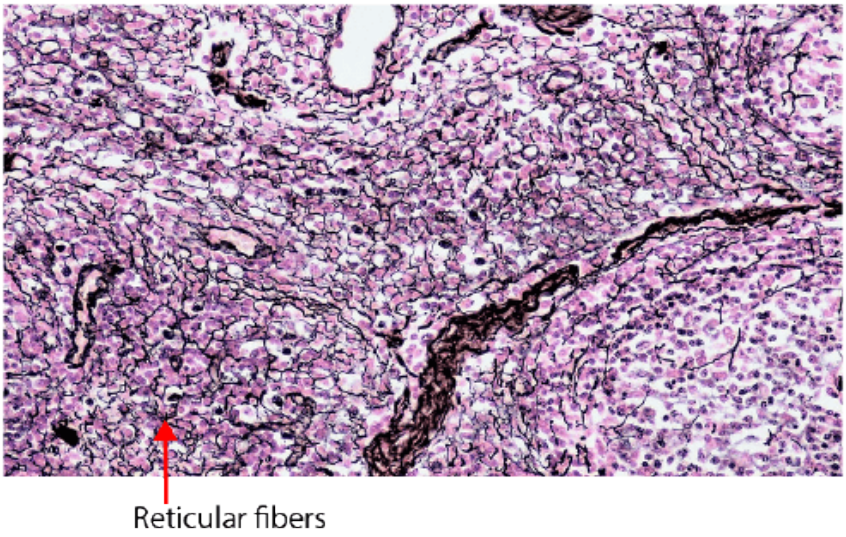

Figure 3.4.6: Reticular Tissue. This is a loose connective tissue made up of a network of reticular fibers that provides a supportive framework for soft organs. LM × 200x. *(Image credit: "Reticular Tissue" by Jennifer Lange is licensed under CC BY-NC-SA 4.0. Micrograph provided by Berkshire Community College Bioscience Image Library is in the Public Domain.)*

Dense Connective Tissue

Dense connective tissues contain more protein fibers than do loose connective tissues. As a consequence, visually they have little "white space" filled with ground substance and the fibers are more densely packed. There are three major categories of dense connective tissue: elastic, regular and irregular.

- **Dense regular connective tissue**'s abundant collagen fibers are parallel to each other, enhancing tensile strength and resistance to stretching in the direction of the fiber orientation (Figure 3.4.7). Ligaments and tendons are made of dense regular connective tissue.

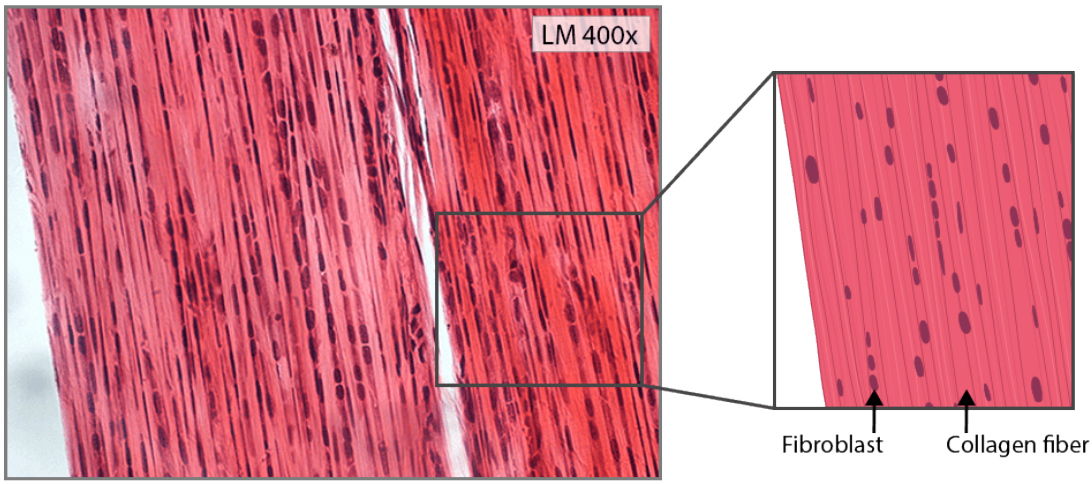

Figure 3.4.7: Dense Regular Connective Tissue. Dense connective tissues have small amounts of ground substance; dense regular has almost none that is visible on a slide using a light microscope. The collagen fibers are arranged in thick, parallel bundles and the fibroblasts are often oval as they are compressed between the fibers. *(Image credit: "Dense Regular Connective Tissue" by Jennifer Lange, illustration by Claire McGuire, is licensed under CC BY-NC-SA 4.0. Micrograph by J Jana, CC BY-SA 4.0, via Wikimedia Commons.)*

- In **dense irregular connective tissue**, the direction of fiber bundles is random (Figure 3.4.8*A*). This arrangement gives the tissue greater strength in all directions and less strength than dense regular connective tissue in one particular direction.

The majority of the fibers are collagen, with a smaller quantity of elastin also present. The dermis of the skin is an example of dense irregular connective tissue rich in collagen fibers.

- Some applications require a balance between tensile strength and elasticity, and thus contain **elastic connective tissue** with abundant elastin fibers in addition to collagen fibers (Figure 3.4.8*B*). The ligaments in the vocal folds and between the vertebrae in the cervical vertebral column are composed of elastic connective tissue. This type of tissue also gives the walls of large arteries both strength and the ability to regain original shape after stretching.

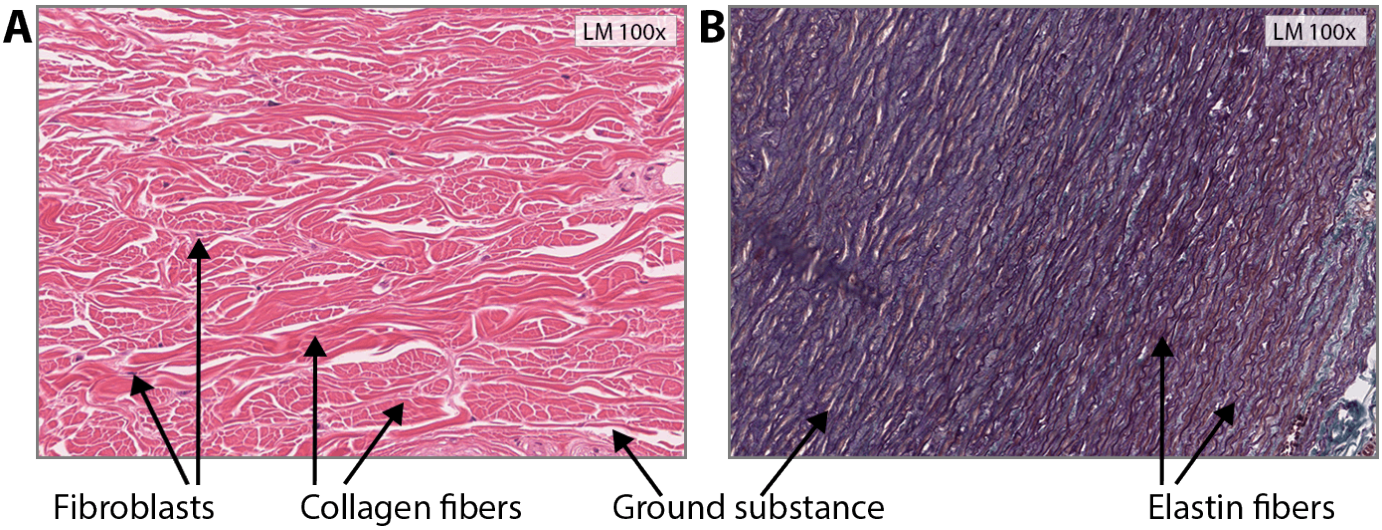

Figure 3.4.8: Dense Connective Tissues: Dense Irregular and Elastic. (A) Dense irregular connective tissue consists of collagenous fibers interwoven into a mesh-like network. Of the dense connective tissues, this one has the most ground substance. (B) Elastin fibers are visualized here using a different dye, appearing as wavy, parallel dark lines. (*Image credit: "Dense Connective Tissues: Irregular and Elastic" by Jennifer Lange is licensed under CC BY-NC-SA 4.0. Micrographs provided by the Regents of the University of Michigan Medical School* © 2022.)

DISORDERS OF THE.....

Connective Tissue: Tendinitis

Your opponent stands ready as you prepare to hit the serve, but you are confident that you will smash the ball past your opponent. As you toss the ball high in the air, a burning pain shoots across your arm and you drop the tennis racket. That dull ache in the elbow that you ignored through the summer is now an unbearable pain. The game is over for now.

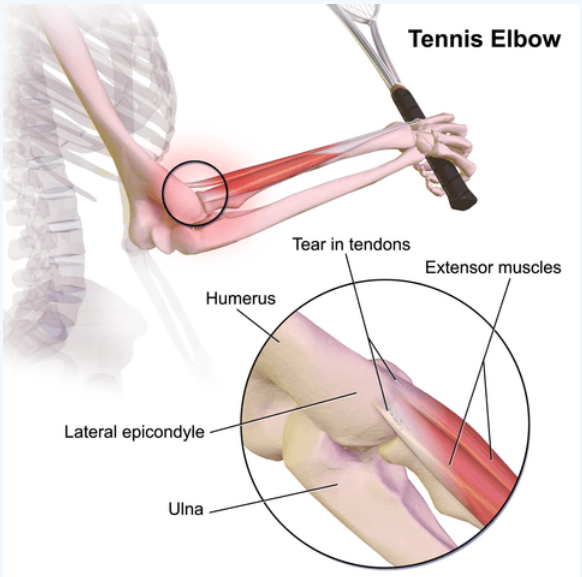

After examining your painful elbow, the doctor in the emergency room announces that you have developed extensor tendinitis, commonly called tennis elbow. She recommends icing the tender area, taking non-steroidal anti-inflammatory medication to ease the pain and to reduce swelling, and completely rest for a few weeks. She interrupts your protests that you cannot stop playing. She issues a stern warning about the risk of aggravating the condition and the possibility of surgery. She consoles you by mentioning that well known tennis players such as Venus and Serena Williams and Rafael Nadal have also suffered from tendinitis related injuries.

What is tendinitis and how did it happen? Tendinitis is the inflammation of a tendon, the thick band of dense regular connective tissue that attaches a muscle to a bone. The condition causes pain and tenderness in the area around a joint. On rare occasions, a sudden serious injury will cause tendinitis. Most often, the condition results from repetitive motions over time that strain the tendons needed to perform the tasks.

Persons whose jobs and hobbies involve performing the same movements over and over again are often at the greatest risk of tendinitis. You hear of tennis and golfer's elbow, jumper's knee, and swimmer's shoulder. In all cases, overuse of the joint causes a microtrauma that initiates the inflammatory response. Tendinitis is routinely diagnosed through a clinical examination. In case of severe pain, X-rays can be examined to rule out the possibility of a bone injury. Severe cases of tendinitis can even tear loose a tendon. Surgical repair of a tendon is painful. Connective tissue in the tendon does not have abundant blood supply and heals slowly.

While older adults are at risk for tendinitis because the elasticity of tendon tissue decreases with age, active people of all ages can develop tendinitis. Young athletes, dancers, and computer operators; anyone who performs the same movements constantly is at risk for tendinitis. Although repetitive motions are unavoidable in many activities and may lead to tendinitis, precautions can be taken that can lessen the probability of developing tendinitis. For active individuals, dynamic stretches before exercising and cross training or changing exercises are recommended. For the passionate athlete, it may be time to take some lessons to improve technique. All of the preventive measures aim to increase the strength of the tendon and decrease the stress put on it. With proper rest and managed care, you will be back on the court to hit that slice-spin serve over the net.

Supportive Connective Tissues

Two major forms of supportive connective tissue, **cartilage** and **bone**, allow the body to maintain its posture and protect internal organs.

Cartilage

The distinctive extracellular matrix composition of cartilage is due to polysaccharides called chondroitin sulfates, which bind with ground substance proteins to form proteoglycans. Embedded within the cartilage matrix are **chondrocytes**, or cartilage cells, and the spaces they occupy are called **lacunae** (singular = lacuna). Cartilaginous tissue is avascular, thus all nutrients need to diffuse through the matrix to reach the chondrocytes. This is a factor contributing to the very slow healing of cartilaginous tissues.

The three main types of cartilage are hyaline cartilage, fibrocartilage, and elastic cartilage (Figure 3.4.9).

- **Hyaline cartilage**, the most common type of cartilage in the body, consists of short and dispersed collagen fibers and contains large amounts of proteoglycans. Under the microscope, tissue samples appear clear. The surface of hyaline cartilage is smooth. Both strong and flexible, it is found in the rib cage and nose and it covers bones where they meet to form moveable joints. It makes up a template of the embryonic skeleton before bone formation. A plate of hyaline cartilage at the ends of bone allows continued growth until adulthood. A layer of dense irregular connective tissue, the **perichondrium**, encapsulates the cartilage.
- **Fibrocartilage** is tough because it has thick bundles of collagen fibers dispersed through its matrix, which allows it to resist compression and absorb shock. The knee and jaw joints and the intervertebral discs are examples of fibrocartilage. This type of cartilage does not have a perichondrium
- **Elastic cartilage** contains elastic fibers as well as collagen and proteoglycans. This tissue gives rigid support as well as elasticity. Tug gently at your ear lobes, and notice that the lobes return to their initial shape. The external ear contains elastic cartilage. This type of cartilage also has a perichondrium.

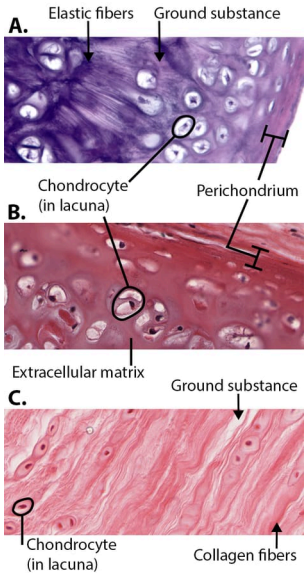

Figure 3.4.9: Types of Cartilage @ 600x. Cartilage is a supportive connective tissue with a semi-solid ground substance. A. Elastic cartilage has elastin fibers oriented in multiple directions that are densest near the cells. B. Hyaline cartilage does not have visible protein fibers. C. Fibrocartilage has fewer cells and thin, wavy collagen fibers. *(Image credit: "Types of Cartilage" by Jennifer Lange is licensed under CC-BY-NC-SA 4.0.; micrographs provided by the Regents of University of Michigan Medical School © 2022, under CC-BY-NC-SA 4.0.)*

Bone

Bone is the hardest connective tissue. It provides protection to internal organs and supports the body. Bone's rigid extracellular matrix contains mostly collagen fibers embedded in a mineralized ground substance containing hydroxyapatite, a form of calcium phosphate. Both components of the matrix, organic and inorganic, contribute to the unusual properties of bone. Without organic collagen, bones would be brittle and shatter easily. Without inorganic mineral crystals, bones would flex and provide little support. **Osteocytes**, bone cells like chondrocytes, are located within lacunae. Bone is a highly vascularized tissue. Unlike cartilage, bone tissue can recover from injuries in a relatively short time.

The histology of transverse tissue from long bone (Figure $3.4.10A$) shows a typical arrangement of osteocytes in concentric circles around a central canal. This compact bone arrangement is solid and has great structural strength. Cancellous bone, also known as spongy bone, looks like a sponge under the microscope (Figure $3.4.10B$) and contains empty spaces between trabeculae, or arches of bone tissue. It is lighter than compact bone and found in the interior of some bones and at the end of long bones. Compact bone is solid and has greater structural strength. The specific arrangement of cells and extracellular matrix within each bone tissue type will be further discussed in Chapter 5.

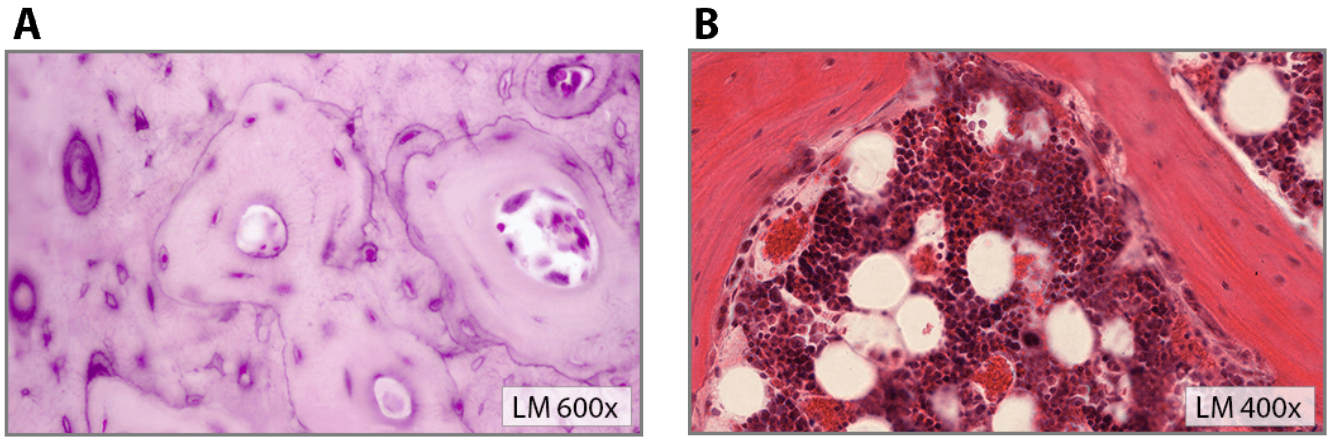

Figure 3.4.10: Bone Tissue. (A) Compact bone only has spaces for the passage of nerves and blood vessels. (B) Cancellous bone has large spaces filled with bone marrow. (*Image credit: "Bone Tissue Arrangements" by Jennifer Lange is licensed under CC-BY-NC-SA 4.0; micrographs provided by Virginia Commonwealth University under CC-BY-NC-SA 4.0.*)

Fluid Connective Tissue

Blood and lymph are fluid connective tissues. Cells circulate in a liquid extracellular matrix. The formed elements circulating in blood are all derived from stem cells located in bone marrow (Figure 3.4.11). These formed elements include erythrocytes, called red blood cells, leukocytes, called white blood cells, and cell fragments called platelets involved in blood clotting. Nutrients, salts, and wastes are dissolved in the liquid ground substance and transported through the body. The details of the both the formed elements and the ground substance of blood will be discussed in Chapter 15.

Lymph contains a liquid matrix and white blood cells. Lymphatic capillaries are extremely permeable, allowing larger molecules and excess fluid from interstitial spaces to enter the lymphatic vessels. Lymph drains into blood vessels, delivering molecules to the blood that could not otherwise directly enter the bloodstream. In this way, specialized lymphatic capillaries transport absorbed fats away from the intestine and deliver these molecules to the blood.

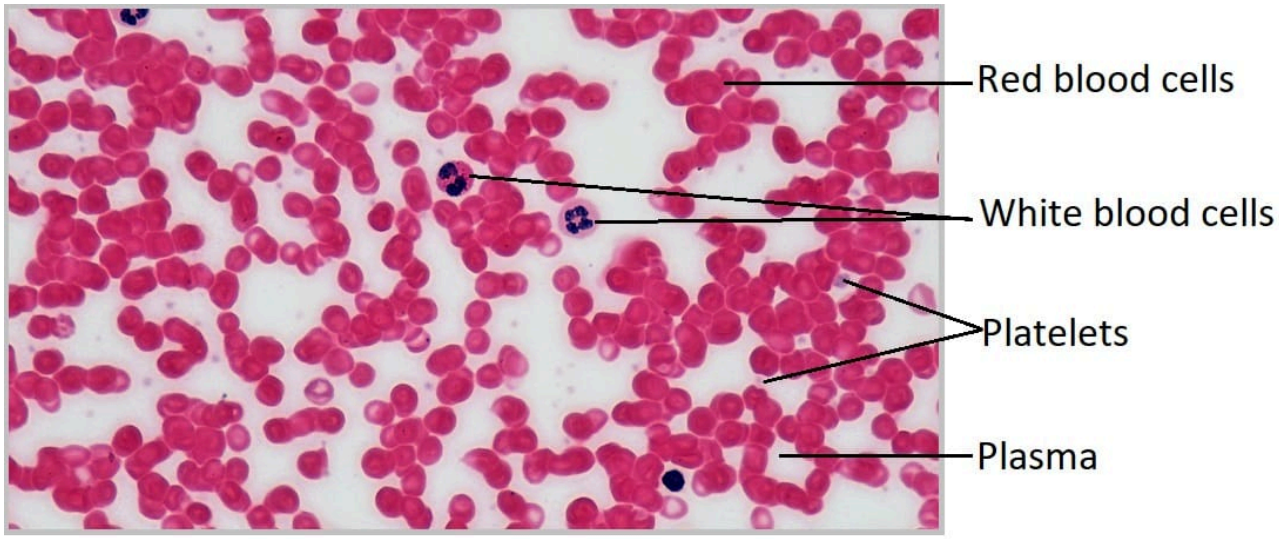

Figure 3.4.11: Fluid Connective Tissue: Blood. Blood is a fluid connective tissue containing various types of blood cells that circulate in a liquid extracellular matrix. LM × 400. *(Image credit: "Fluid Connective Tissue" by Jennifer Lange is licensed under CC-BY-NC-SA 4.0. Micrograph provided by Berkshire Community College Bioscience Image Library is in the Public Domain.)*

Concept Review

Connective tissue is a heterogeneous tissue class with assorted cell shapes and tissue architecture. Structurally, all connective tissues contain cells that are embedded in an extracellular matrix stabilized by proteins. The chemical nature and physical layout of the extracellular matrix and proteins vary enormously among tissues, reflecting the variety of functions that connective tissue fulfills in the body. Connective tissues separate and cushion organs, protecting them from shifting or traumatic injury. Connective tissues provide support and assist movement, store and transport energy molecules, protect against infections, and contribute to temperature homeostasis.

Many different cells contribute to the formation of connective tissues. They originate in the mesodermal germ layer and differentiate from mesenchyme and hematopoietic tissue in the bone marrow. Fibroblasts are the most abundant and secrete many protein fibers, adipocytes specialize in fat storage, hematopoietic cells from the bone marrow give rise to all the blood cells, chondrocytes form cartilage, and osteocytes form bone. The extracellular matrix contains fluid, proteins, polysaccharide derivatives, and, in the case of bone, mineral crystals. Protein fibers fall into three major groups: collagen fibers that are thick, strong, flexible, and resist stretch; reticular fibers that are thin and form a supportive mesh; and elastin fibers that are thin and elastic.

The major types of connective tissue are connective tissue proper, supportive tissue, and fluid tissue. Loose connective tissue proper includes adipose tissue, areolar tissue, and reticular tissue. These serve to hold organs and other tissues in place and, in the case of adipose tissue, isolate and store energy reserves. The matrix is the most abundant feature for loose tissue although adipose tissue does not have much extracellular matrix. Dense connective tissue proper is richer in fibers and may be regular, with fibers oriented in parallel as in ligaments and tendons, or irregular, with fibers oriented in several directions. Organ capsules (collagenous type) and walls of arteries (elastic type) contain dense irregular connective tissue. Cartilage and bone are supportive tissue. Cartilage contains chondrocytes and is somewhat flexible. Hyaline cartilage is smooth and clear, covers the articulating surfaces of bones, and is found in the growing portion of bones. Fibrocartilage is tough because of extra collagen fibers and forms, among other things, the intervertebral discs. Elastic cartilage can stretch and recoil to its original shape because of its high content of elastic fibers. The matrix contains very few blood vessels. Bones are made of a rigid, mineralized matrix containing calcium salts, crystals, and osteocytes lodged in lacunae. Bone tissue is highly vascularized. Cancellous bone is spongy and less solid than compact bone. Fluid tissue, for example blood and lymph, is characterized by a liquid matrix and no supporting fibers.

Review Questions

Query 3.4.1

This interactive element is not available in this format. Visit the link or scan the QR code to access it online.

View this Interactive Content online

Critical Thinking Questions

Query 3.4.2

This interactive element is not available in this format. Visit the link or scan the QR code to access it online.

View this Interactive Content online

Query 3.4.3

This interactive element is not available in this format. Visit the link or scan the QR code to access it online.

View this Interactive Content online

Glossary

Query 3.4.4

This interactive element is not available in this format. Visit the link or scan the QR code to access it online.

View this Interactive Content online

Contributors and Attributions

- OpenStax Anatomy & Physiology (CC BY 4.0). Access for free at https://openstax.org/books/anatomy-and-physiology

This page titled 3.4: Connective Tissue is shared under a CC BY-NC-SA 4.0 license and was authored, remixed, and/or curated by Jennifer Lange et al..

- 3.4: Connective Tissue by Whitney Menefee, Julie Jenks, Chiara Mazzasette, and Kim-Leiloni Nguyen is licensed CC BY 4.0.

3.5: Muscle Tissue

By the end of the section, you will be able to:

- Identify the three types of muscle tissue
- Compare and contrast the structure and functions of each muscle tissue type
- Explain how muscle tissue can enable motion

Muscle tissue is characterized by properties that allow movement:

- Muscle cells are **excitable**; they respond to a stimulus that is either electrical or chemical.
- They are **contractile**, meaning they can shorten and generate a pulling force. When attached between two movable objects, such as bones on either side of a joint, contractions of the muscles cause the bones to move.
- They are **extensible**, meaning they and stretch out/lengthen.
- They are **elastic** and will return to their resting length after stretching.

Some muscle movement is voluntary, which means it is under conscious control. For example, a person decides to open a book and read a chapter on anatomy. Other movements are involuntary, meaning they are not under conscious control, such as the contraction of your pupil in bright light. Muscle tissue is classified into three types according to structure and function: skeletal, cardiac, and smooth (Table 3.5.1 and Figure 3.5.2). Each type is introduced here and will be discussed in more detail in Chapter 8.2.

Table 3.5.1: Comparison of Structure and Properties of Muscle Tissue Types

Tissue	Histology	Functions	Locations
Skeletal	• Long, cylindrical myofiber • Striated • Many peripherally located nuclei	• Voluntary movement of skeleton and skin • Produces heat • Protects organs	• Attached to bones • Attached to skin • Around entrance/exit points to body (e.g., mouth, anus)
Cardiac	• Short, branched fiber • Striated • Single central nucleus	• Involuntary, rhythmic movement of heart	Heart
Smooth	• Short, spindle-shaped fiber • No evident striations • Single central nucleus	• Involuntary contraction controls rate and volume of passage through a tube (food, air, blood, urine, etc.)	• Walls of major tubular visceral organs • Intraocular muscles

Skeletal Muscle

Skeletal muscle is attached to bones and its contraction makes possible locomotion, facial expressions, posture, and other

voluntary movements of the body. Forty percent of your body mass is made up of skeletal muscle. Skeletal muscles generate heat as a byproduct of their contraction and thus participate in thermal homeostasis. Shivering is an involuntary contraction of skeletal muscles in response to perceived lower than normal body temperature. The muscle cell, or **myofiber**, develops from the fusion of myoblasts derived from the mesoderm. The number of myofibers you have stays relatively constant throughout life. Under the light microscope, muscle cells appear striped (striated) and have many nuclei squeezed along the membranes (Figure $3.5.1.A$). The **striations** are due to the regular alternation of the contractile proteins actin and myosin along the length of each cell. The cells are multinucleated as a result of the fusion of the many myoblasts that join to form each long muscle fiber. Skeletal muscle is discussed in much greater detail in a later chapter.

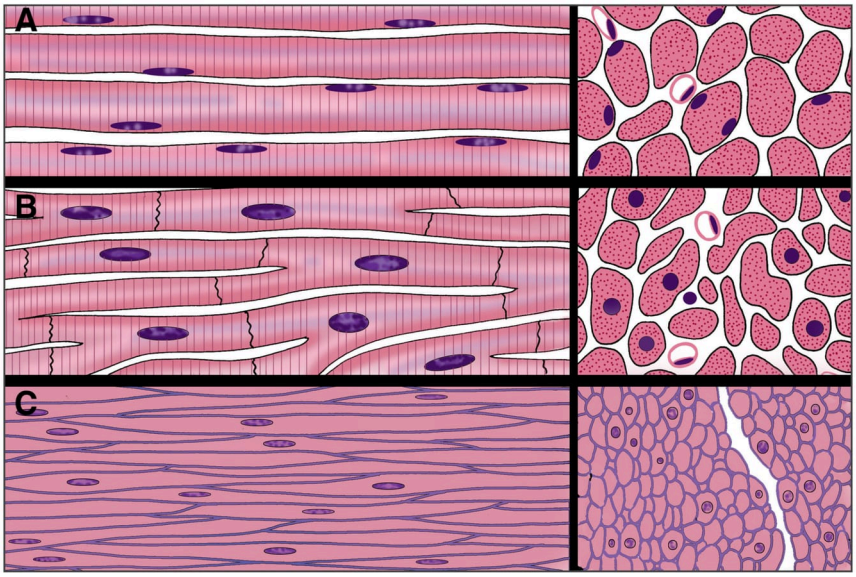

Figure $3.5.1$: Muscle Tissues Overview. All muscle tissue types have elongated cells that are arranged parallel to each other, giving them a singular axis for contraction. In skeletal muscle (A) the myofibers are long, skinny rods with nuclei on the periphery of the cell. In cardiac muscle (B) the cells are shorter and branched with a centrally located nucleus. Smooth muscle (C) is the only type that is not striated. It has cells that taper at each end and a central nucleus. *(Image credit: "Muscle Tissue Overview" by Virginia Commonwealth University is licensed under CC BY-NC-SA 4.0)*

Cardiac Muscle

Cardiac muscle forms the contractile walls of the heart. The cells of cardiac muscle, known as cardiomyocytes or cardiac myofibers, also appear striated under the microscope, but their striations are not as prominent as those in skeletal muscle. Unlike skeletal muscle fibers, cardiac myofibers typically have a single, centrally located nucleus. A principal characteristic of cardiac muscle is that the cells contract without any external stimulation. They are described as **autorhythmic**, but their contraction rate can be altered by the nervous system. Cardiac myofibers attach to multiple neighbors with specialized cell junctions called **intercalated discs** (Figure $3.5.1.B$). Intercalated discs have both anchoring junctions and gap junctions. Attached cells form long, branching cardiac muscle fibers that are, essentially, a mechanical and electrochemical syncytium (interconnected mass of fibers) allowing the cells to synchronize their actions. The cardiac muscle pumps blood through the body and is under involuntary control.

Smooth Muscle

Smooth muscle tissue contraction is responsible for involuntary movements in the internal organs. It forms the contractile component of the digestive, urinary, and reproductive systems as well as the airways and arteries. Smooth muscle is also present in the eyes, where it functions to change the size of the iris and alter the shape of the lens; and in the skin where it causes hair to stand erect in response to cold temperature or fear. Each cell is spindle shaped with a single nucleus and no visible striations (Figure $3.5.1.C$).

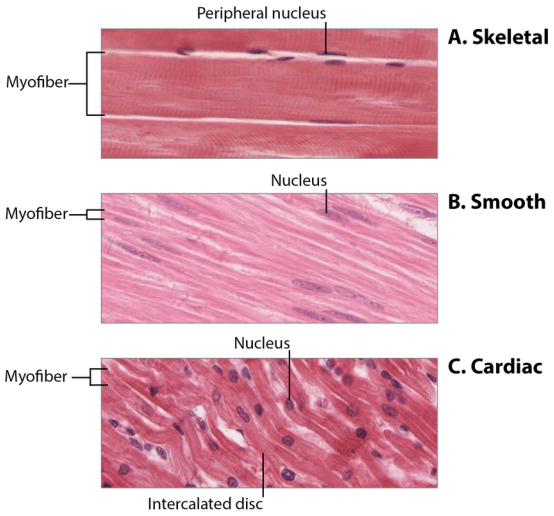

Figure 3.5.2: Histology of Muscle Tissue Types at 400x. (a) Skeletal muscle cells have prominent striations and nuclei on their periphery. (b) Smooth muscle cells have a single nucleus and no visible striations. (c) Cardiac muscle cells appear faintly striated and have a single nucleus. *(Image credit: "Histology of Muscle Tissue Types" by Jennifer Lange, based on micrographs provided by the Regents of University of Michigan Medical School © 2022 under CC-BY-NC-SA.)*

Concept Review

The three types of muscle cells are skeletal, cardiac, and smooth. Their structure and shape match their specific functions in the body - elongated cells that shorten and lengthen.

- Skeletal muscle is voluntary and responds to conscious stimuli. The cells are striated and multinucleated appearing as long, unbranched cylinders.
- Cardiac muscle is involuntary and found only in the heart. Each cell is striated with a single nucleus and they attach to one another to form long fibers. Cells are attached to one another at intercalated discs. The cells are interconnected physically and electrochemically to act as a unit. Cardiac muscle cells contract autonomously and involuntarily.
- Smooth muscle is involuntary. Each cell is a spindle-shaped fiber and contains a single nucleus. No striations are evident because the protein filaments do not a parallel arrangement.

Review Questions

Query 3.5.1

This interactive element is not available in this format. Visit the link or scan the QR code to access it online.

View this Interactive Content online

Query 3.5.2

This interactive element is not available in this format. Visit the link or scan the QR code to access it online.

View this Interactive Content online

Critical Thinking Questions

Query 3.5.3

This interactive element is not available in this format. Visit the link or scan the QR code to access it online.

View this Interactive Content online

Query 3.5.4

This interactive element is not available in this format. Visit the link or scan the QR code to access it online.

View this Interactive Content online

Glossary

Query 3.5.5

This interactive element is not available in this format. Visit the link or scan the QR code to access it online.

View this Interactive Content online

Contributors and Attributions

- OpenStax Anatomy & Physiology (CC BY 4.0). Access for free at https://openstax.org/books/anatomy-and-physiology

---

This page titled 3.5: Muscle Tissue is shared under a CC BY-NC-SA 4.0 license and was authored, remixed, and/or curated by Jennifer Lange et al..

- 3.5: Muscle Tissue by Whitney Menefee, Julie Jenks, Chiara Mazzasette, and Kim-Leiloni Nguyen is licensed CC BY 4.0.

3.6: Nervous Tissue

By the end of the section, you will be able to:

- Identify the types of cells that make up nervous tissue
- Explain the general function of neurons and their parts
- Explain the general function of neuroglia

Nervous tissue is characterized as being **excitable** and capable of sending and receiving electrochemical signals that provide the body with information.

Two main classes of cells make up nervous tissue: the **neuron** and **neuroglia** (Figure 3.6.1 and Figure 3.6.2). Neurons propagate information via electrochemical impulses, called action potentials, which are biochemically linked to the release of chemical signals. Neuroglia play essential roles in structurally and physically supporting neurons, stabilizing synapses, and modulating their information propagation.

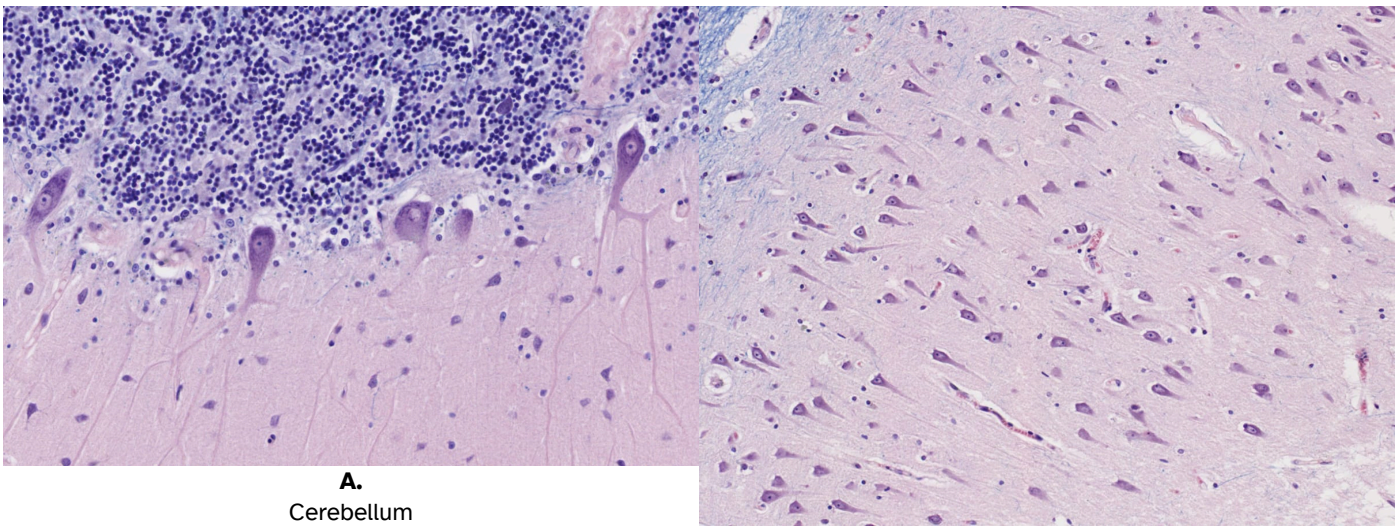

A.
Cerebellum

B.
Cerebral Cortex

Figure 3.6.1: Nervous Tissue. Neurons are large cells with a variety of shapes and sizes, but all have a cell body that contains the nucleus and projections. Neuroglia are tiny cells and show up as dots on the slides. *(Image credit: "Nervous Tissue of Cerebellum and Cerebrum" images provided by the Regents of the University of Michigan Medical School under CC-BY-NC-SA 4.0 © 2022)*

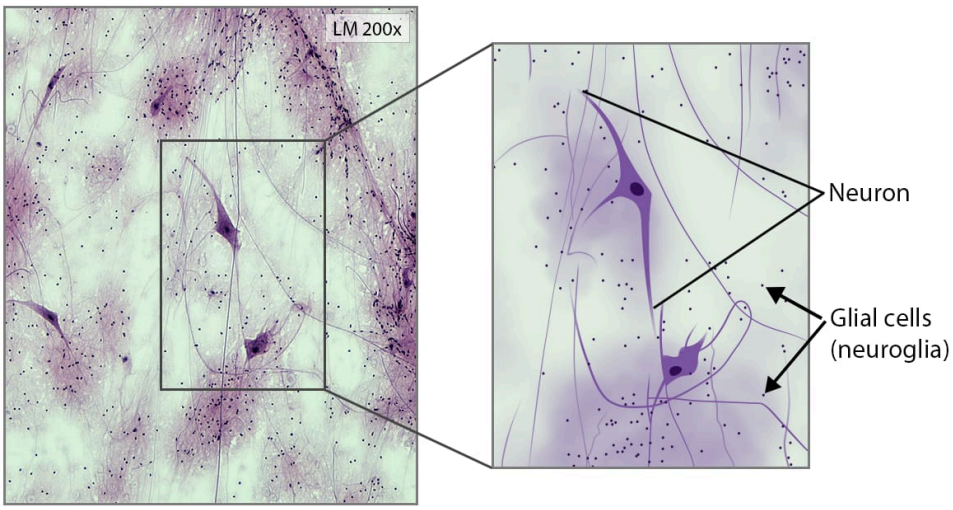

Figure 3.6.2: Nervous Tissue Cells. In this image tissue from the spinal cord has been smeared on the slide so you can see the neuron structure. *(Image credit: "Nervous Tissue Cells" by Jennifer Lange, illustration by Claire McGuire is licensed under CC-BY-NC-SA 4.0. Micrograph provided by Berkshire Community College Bioscience Image Library is in the Public Domain.)*

Neurons

Neurons display distinctive morphology, well suited to their role as conducting cells, with three main parts:

- The **cell body** (soma) includes most of the cytoplasm, the organelles, and the nucleus.
- **Dendrites** branch off the cell body and appear as thin extensions. They transfer the incoming signals to the soma.
- A long "tail," the **axon**, extends from the cell body and can be wrapped in an insulating layer, called myelin, formed by neuroglia. It carries the outgoing action potential away to another excitable cell.

Axons split into multiple **axon terminals** when they are close to their target. At the end of each terminal is a synaptic knob that will pass the electrical signal to the next cell (usually another neuron, muscle fiber, or gland) by stimulating the release of a **neurotransmitter**. (Figure 3.6.3) The specific classes of neurons and their functions will be discussed in a later chapter.

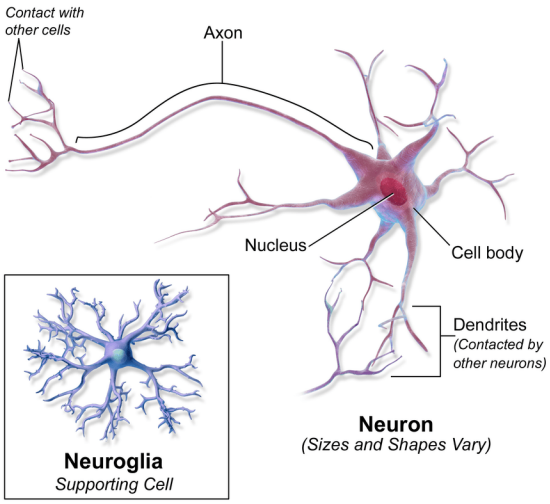

Neural Tissue

Figure 3.6.3: Neural Tissue. Neurons receive, process, and send messages throughout the nervous system and to effectors, such as the heart or stomach. Neuroglia, greatly enlarged here, come in six different types that each have a specific function and a unique shape. This one is a microglia, which clears cellular debris as well as pathogens. *(Image credit: "Blausen 0672 - Neurvous tissue - English labels" by Blausen.com staff (2014), license: CC BY. Source: "Medical gallery of Blausen Medical 2014")*

Neuroglia

The second class of neural cells comprises the neuroglia or glial cells, which formerly have been characterized as having a simple support role. (Figure 3.6.4) The word “glia” comes from the Greek word for glue. Recent research is shedding light on the more complex role of neuroglia in the function of the brain and nervous system. These cells were harder to study initially because they did not generate the electrical signals that neurons did, but with more recent techniques we now know that these cells do a lot more than glue the neurons together! Currently known functions include:

- defining synaptic contacts and maintaining the signaling ability of neurons
- maintaining the chemical environment around the neurons
- modulating the rate of signal propagation
- controlling the uptake of neurotransmitters
- providing a scaffold for neurodevelopment
- healing damaged neurons
- regulating fluid transport in the glymphatic pathway
- production and circulation of cerebrospinal fluid

Glial cells outnumber neurons by an approximate 3:1 ratio. The specific types of glial cells and their functions will be discussed in a later chapter.

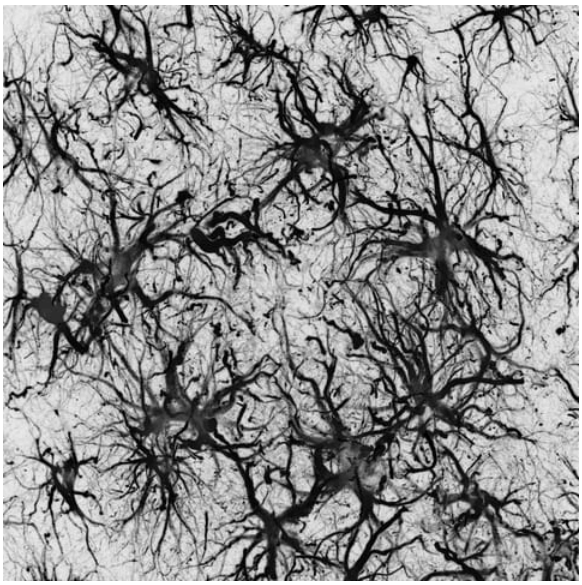

Figure 3.6.4: Astrocytes. Special imaging techniques are used for visualizing the tiny glial cells. This image uses confocal microscopy to display the characteristic star-like shape of one type of glial cell: the astrocyte. *(Image Credit: "Activated Astrocytes" by Pics56, CC BY-SA 4.0, via Wikimedia Commons)*

Glia - what are they good for?

Two neurological mysteries may be partly explained by glial cells: why do we need to sleep? and what makes a person a genius?

Why must we sleep? In terms of survival, sleeping does not make sense. Why would *all* animals risk not being conscious of their environment for hours every day - what predators might be able to walk up un-noticed?! All animals sleep, even though some sleep with only half their brain at a time, so this brain down time must be crucial to life. Indeed, if deprived of sleep you will die faster than if you are deprived of food or water.

In 2013, a study by Maiken Nedergaard and colleagues at the University of Rochester in New York discovered a system that flushes waste products from the brain. Only while sleeping the cerebrospinal fluid, the liquid surrounding the brain and spinal cord, moves through the brain along a series of channels surrounding the blood vessels flushing out the toxins that accumulated during the waking hours. Since the channels are controlled by the brain's glial cells, the research team called it the glymphatic system. Nedergaard's team discovered this system in mice, and it has subsequently been shown in humans as well. This raises the interesting possibility that a lack of sleep could lead to neurological diseases such as Alzheimer's, or that sleep disturbances that go along with neurological conditions could lead to further brain damage due to the build up of harmful toxins. For more detailed information about the original study visit https://www.science.org/content/article/sleep-ultimate-brainwasher. To see a video of the pulses of CSF in the human brain visit https://www.bu.edu/articles/2019/cerebrospinal-fluid-washing-in-brain-during-sleep/.

Is genius all in the brain? A long standing question for neuroscientists and philosophers alike is where does genius come from? Some people are just levels above everyone else in terms of their ability to create, discover, and change future knowledge within their field - Galileo Galilei, Leonardo Da Vinci, Johann Wolfgang van Goethe, and, of course, Albert Einstein. Shortly after Einstein's death in 1955, the physician conducting his autopsy, Thomas Harvey, secretly removed and preserved his brain. Photographs were taken and then Harvey supervised the division of the brain into 240 blocks, and created 12 sets of 200 slides containing tissue samples indexed to the blocks. Many of these were sent to eminent neuropathologists of the 1950's, but no studies were published. They did not find anything worth publishing.

In 1978 a young reporter tracked down Thomas Harvey and rediscovered Einstein's brain. Once news got out, Harvey was inundated with requests for samples. The first study to be published based on these samples was by neuroanatomist Marian Diamond of U.C. Berkeley in 1985. She received four sections of the cerebral cortex association regions from both hemispheres and compared the ratio of glial cells in Einstein's brain with that of the preserved brains of 11 other males. Einstein's brain had more glial cells relative to neurons in all areas studied, but in only one area was the difference statistically significant, one that is part of the brain regions responsible for incorporating and synthesizing information from multiple other brain regions. The question remains though - was it the additional glial cells that made Einstein a genius, or was it Einstein's genius that caused him to have more glial cells? To read more about the strange journey of Einstein's brain visit https://www.bbc.com/news/magazine-32354300.

Concept Review

The most prominent cell of the nervous tissue, the neuron, is characterized mainly by its ability to receive stimuli and respond by generating an electrical signal, known as an action potential, which can travel rapidly over great distances in the body. A typical neuron displays a distinctive morphology: a large cell body branches out into short extensions called dendrites, which receive chemical signals from other neurons, and a long tail called an axon, which relays signals away from the cell to other neurons, muscles, or glands. Other cells in the nervous tissue, the neuroglia, function to keep these neural connections stable and to support signal transmission.

Review Questions

Query 3.6.1

This interactive element is not available in this format. Visit the link or scan the QR code to access it online.

View this Interactive Content online

Query 3.6.2

This interactive element is not available in this format. Visit the link or scan the QR code to access it online.

View this Interactive Content online

Critical Thinking Questions

Query 3.6.3

This interactive element is not available in this format. Visit the link or scan the QR code to access it online.

View this Interactive Content online

Query 3.6.4

This interactive element is not available in this format. Visit the link or scan the QR code to access it online.

View this Interactive Content online

Glossary

Query 3.6.5

This interactive element is not available in this format. Visit the link or scan the QR code to access it online.

View this Interactive Content online

Contributors and Attributions

- OpenStax Anatomy & Physiology (CC BY 4.0). Access for free at https://openstax.org/books/anatomy-and-physiology

This page titled 3.6: Nervous Tissue is shared under a CC BY-NC-SA 4.0 license and was authored, remixed, and/or curated by Jennifer Lange et al..

- 3.6: Nervous Tissue by Whitney Menefee, Julie Jenks, Chiara Mazzasette, and Kim-Leiloni Nguyen is licensed CC BY 4.0.

3.7: Tissue Injury and Aging

By the end of the section, you will be able to:

- Identify the cardinal signs of inflammation
- List the body's response to tissue injury
- Explain the process of tissue repair
- Discuss the progressive impact of aging on tissue
- Describe cancerous mutations' effect on tissue

Tissues of all types are vulnerable to injury and, inevitably, aging. In the former case, understanding how tissues respond to damage can guide strategies to aid repair. In the latter case, understanding the impact of aging can help in the search for ways to diminish its effects.

Tissue Injury and Repair

Inflammation is the standard, initial response of the body to injury. Whether biological, chemical, physical, or radiation burns, all injuries lead to the same sequence of physiological events. Inflammation limits the extent of injury, partially or fully eliminates the cause of injury, and initiates repair and regeneration of damaged tissue. **Necrosis**, or accidental cell death, causes inflammation. **Apoptosis** is programmed cell death, a normal step-by-step process that destroys cells no longer needed by the body. By mechanisms still under investigation, apoptosis does not initiate the inflammatory response. Acute inflammation resolves over time by the healing of tissue. If inflammation persists, it becomes chronic and leads to diseased conditions. Arthritis and tuberculosis are examples of chronic inflammation. The suffix "-itis" denotes inflammation of a specific organ or type, for example, peritonitis is the inflammation of the peritoneum, and meningitis refers to the inflammation of the meninges, the tough membranes that surround the central nervous system.

The four cardinal signs of inflammation—redness, swelling, pain, and local heat—were first recorded in antiquity. Cornelius Celsus is credited with documenting these signs during the days of the Roman Empire, as early as the first century AD. A fifth sign, loss of function, may also accompany inflammation.

Upon tissue injury, damaged cells release inflammatory chemical signals that evoke local **vasodilation**, the widening of the blood vessels. Increased blood flow results in apparent redness and heat. In response to injury, mast cells present in tissue degranulate, releasing the potent vasodilator **histamine**. Increased blood flow and inflammatory mediators recruit white blood cells to the site of inflammation. The endothelium lining the local blood vessel becomes "leaky" under the influence of histamine and other inflammatory mediators allowing neutrophils, macrophages, and fluid to move from the blood into the interstitial tissue spaces. The excess liquid in tissue causes swelling, more properly called edema. The swollen tissues squeezing pain receptors cause the sensation of pain. Prostaglandins released from injured cells also activate pain neurons. Non-steroidal anti-inflammatory drugs (NSAIDs) reduce pain because they inhibit the synthesis of prostaglandins. High levels of NSAIDs reduce inflammation. Antihistamines decrease allergies by blocking histamine receptors and as a result the histamine response.

After containment of an injury, the tissue repair phase starts with removal of toxins and waste products. **Clotting** (coagulation) reduces blood loss from damaged blood vessels and forms a network of fibrin proteins that trap blood cells and bind the edges of the wound together. A scab forms when the clot dries, reducing the risk of infection. Sometimes a mixture of dead leukocytes and fluid called pus accumulates in the wound. As healing progresses, fibroblasts from the surrounding connective tissues replace the collagen and extracellular material lost by the injury. Angiogenesis, the growth of new blood vessels, results in vascularization of the new tissue known as granulation tissue. The clot retracts pulling the edges of the wound together, and it slowly dissolves as the tissue is repaired. When a large amount of granulation tissue forms and capillaries disappear, a pale scar is often visible in the healed area. A **primary union** describes the healing of a wound where the edges are close together. When there is a gaping wound, it takes longer to refill the area with cells and collagen. The process called **secondary union** occurs as the edges of the wound are pulled together by what is called **wound contraction**. When a wound is more than one quarter of an inch deep, sutures (stitches) are recommended to promote a primary union and avoid the formation of a disfiguring scar. Regeneration is the addition of new cells of the same type as the ones that were injured (Figure 3.7.1).

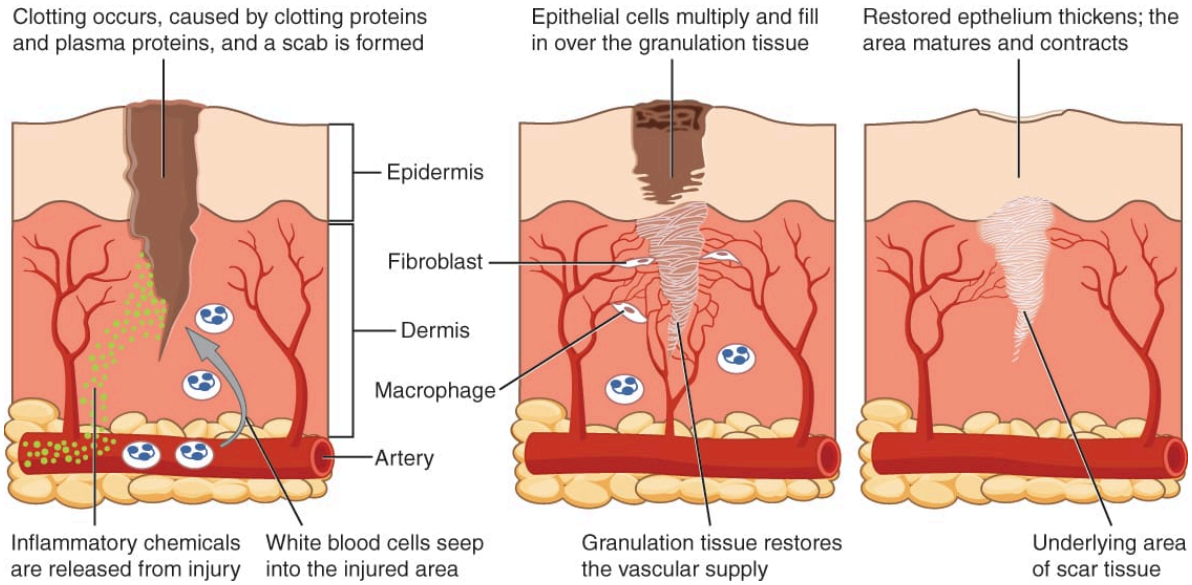

Figure 3.7.1: Tissue Healing. During wound repair, collagen fibers are laid down randomly by fibroblasts that move into repair the area. *(Image credit: "Tissue Repair" by OpenStax is licensed under CC BY 3.0)*

Interactive Link

Wound healing on a hand

Query 3.7.1

This interactive element is not available in this format. Visit the link or scan the QR code to access it online.

View this Interactive Content online

Tissue and Aging

According to poet Ralph Waldo Emerson, “The surest poison is time.” In fact, biology confirms that many functions of the body decline with age. All the cells, tissues, and organs are affected by senescence (deterioration with age), with noticeable variability between individuals owing to different genetic makeup and lifestyles. The outward signs of aging are easily recognizable. The skin and other tissues become thinner and drier, reducing their elasticity, contributing to wrinkles and high blood pressure. Hair turns gray because follicles produce less melanin, the brown pigment of hair and the iris of the eye. The face looks flabby because elastic and collagen fibers decrease in connective tissue and muscle tone is lost. Glasses and hearing aids may become parts of life as the senses slowly deteriorate, all due to reduced elasticity. Overall height decreases as the bones lose calcium and other minerals. With age, fluid decreases in the intervertebral discs of fibrocartilage between the vertebrae in the spine. Joints lose cartilage and stiffen. Many tissues, including those in muscles, lose mass through a process called **atrophy**. Lumps and rigidity become more widespread. As a consequence, the passageways, blood vessels, and airways become more rigid. The brain and spinal cord lose mass. Nerves do not transmit impulses with the same speed and frequency as in the past. Some loss of thought clarity and memory can accompany aging. More severe problems are not necessarily associated with the aging process and may be symptoms of underlying illness.

As exterior signs of aging increase, so do the interior signs, which are not as noticeable. The incidence of heart diseases, respiratory syndromes, and type 2 diabetes increases with age, though these are not necessarily age-dependent effects. Wound healing is slower in the elderly, accompanied by a higher frequency of infection as the capacity of the immune system to fend off pathogen declines.

Aging is also apparent at the cellular level because all cells experience changes with aging. Telomeres, regions of the chromosomes necessary for cell division, shorten each time cells divide. As they do, cells are less able to divide and regenerate. Because of alterations in cell membranes, transport of oxygen and nutrients into the cell and removal of carbon dioxide and waste products from the cell are not as efficient in the elderly. Cells may begin to function abnormally, which may lead to diseases associated with aging, including arthritis, memory issues, and some cancers.

The progressive impact of aging on the body varies considerably among individuals, but studies indicate, however, that exercise and healthy lifestyle choices can slow down the deterioration of the body that comes with old age.

HOMEOSTATIC IMBALANCES

Tissues and Cancer

Cancer is a generic term for many diseases in which cells escape regulatory signals. Uncontrolled growth, invasion into adjacent tissues, and colonization of other organs, if not treated early enough, are its hallmarks. Health suffers when tumors “rob” blood supply from the “normal” organs.

A mutation is defined as a permanent change in the DNA of a cell. Epigenetic modifications, changes that do not affect the code of the DNA but alter how the DNA is decoded, are also known to generate abnormal cells. Alterations in the genetic material may be caused by environmental agents, infectious agents, or errors in the replication of DNA that accumulate with age. Many mutations do not cause any noticeable change in the functions of a cell. However, if the modification affects key proteins that have an impact on the cell’s ability to proliferate in an orderly fashion, the cell starts to divide abnormally. As changes in cells accumulate, they lose their ability to form regular tissues. A tumor, a mass of cells displaying abnormal architecture, forms in the tissue. Many tumors are benign, meaning they do not metastasize nor cause disease. A tumor becomes malignant, or cancerous, when it breaches the confines of its tissue, promotes angiogenesis, attracts the growth of capillaries, and metastasizes to other organs (Figure 3.7.2). The specific names of cancers reflect the tissue of origin. Cancers derived from epithelial cells are referred to as carcinomas. Cancer in myeloid tissue or blood cells form myelomas. Leukemias are cancers of white blood cells, whereas sarcomas derive from connective tissue. Cells in tumors differ both in structure and function. Some cells, called cancer stem cells, appear to be a subtype of cell responsible for uncontrolled growth. Recent research shows that contrary to what was previously assumed, tumors are not disorganized masses of cells, but have their own structures.

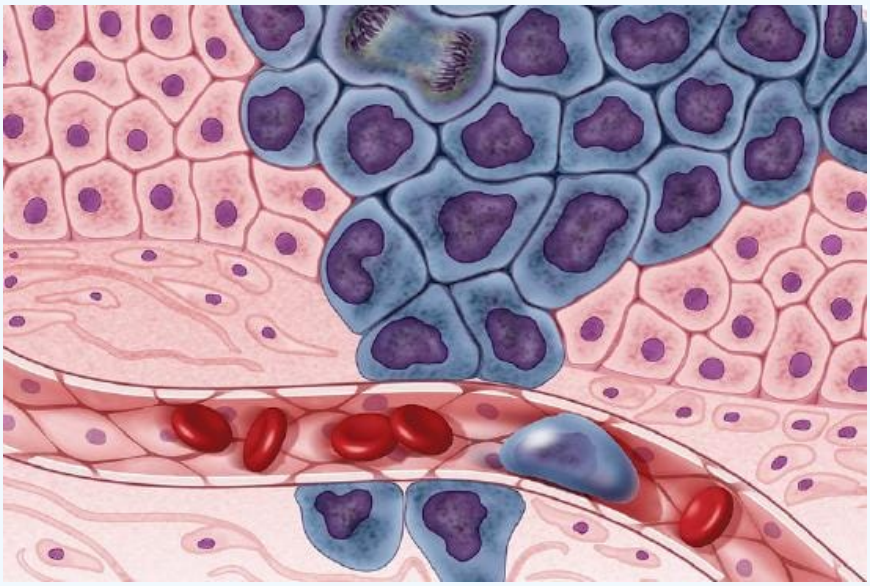

Figure 3.7.2: Development of Cancer. Growing cancer cells (in purple) are surrounded by healthy cells (in pink), illustrating a primary tumor spreading to other parts of the body through the circulatory system. *(Image credit: "Cancer Cells" by Darryl Leja, National Human Genome Research Institute, NIH, is in the public domain.)*

Interactive Link

Tumors

Query 3.7.2

This interactive element is not available in this format. Visit the link or scan the QR code to access it online.

View this Interactive Content online

Cancer treatments vary depending on the disease's type and stage. Traditional approaches, including surgery, radiation, chemotherapy, and hormonal therapy, aim to remove or kill rapidly dividing cancer cells, but these strategies have their limitations. Depending on a tumor's location, for example, cancer surgeons may be unable to remove it. Radiation and chemotherapy are difficult, and it is often impossible to target only the cancer cells. The treatments inevitably destroy healthy tissue as well. To address this, researchers are working on pharmaceuticals that can target specific proteins implicated in cancer-associated molecular pathways.

Concept Review

Inflammation is the classic response of the body to injury and follows a common sequence of events. The area is red, feels warm to the touch, swells, and is painful. Injured cells, mast cells, and resident macrophages release chemical signals that cause vasodilation and fluid leakage in the surrounding tissue. The repair phase includes blood clotting, followed by regeneration of tissue as fibroblasts deposit collagen. Some tissues regenerate more readily than others. Epithelial and connective tissues replace damaged or dead cells from a supply of adult stem cells. Muscle and nervous tissues undergo either slow regeneration or do not repair at all.

Age affects all the tissues and organs of the body. Damaged cells do not regenerate as rapidly as in younger people. Perception of sensation and effectiveness of response are lost in the nervous system. Muscles atrophy, and bones lose mass and become brittle. Collagen decreases in some connective tissue, and joints stiffen.

Review Questions

Query 3.7.3

This interactive element is not available in this format. Visit the link or scan the QR code to access it online.

View this Interactive Content online

Critical Thinking Questions

Query 3.7.4

This interactive element is not available in this format. Visit the link or scan the QR code to access it online.

View this Interactive Content online

Query 3.7.5

This interactive element is not available in this format. Visit the link or scan the QR code to access it online.

View this Interactive Content online

Query 3.7.6

This interactive element is not available in this format. Visit the link or scan the QR code to access it online.

View this Interactive Content online

Query 3.7.7

This interactive element is not available in this format. Visit the link or scan the QR code to access it online.

View this Interactive Content online

References

Emerson, RW. Old age. Atlantic. 1862 [cited 2012 Dec 4]; 9(51):134–140.

Glossary

Query 3.7.8

This interactive element is not available in this format. Visit the link or scan the QR code to access it online.

View this Interactive Content online

Contributors and Attributions

- OpenStax Anatomy & Physiology (CC BY 4.0). Access for free at https://openstax.org/books/anatomy-and-physiology

This page titled 3.7: Tissue Injury and Aging is shared under a CC BY-NC-SA 4.0 license and was authored, remixed, and/or curated by Jennifer Lange et al..

- 3.7: Tissue Injury and Aging by Whitney Menefee, Julie Jenks, Chiara Mazzasette, and Kim-Leiloni Nguyen is licensed CC BY 4.0.

3.8: Anatomical Atlas - Tissues

A compendium of anatomical images: slides, models, and/or cadavers.

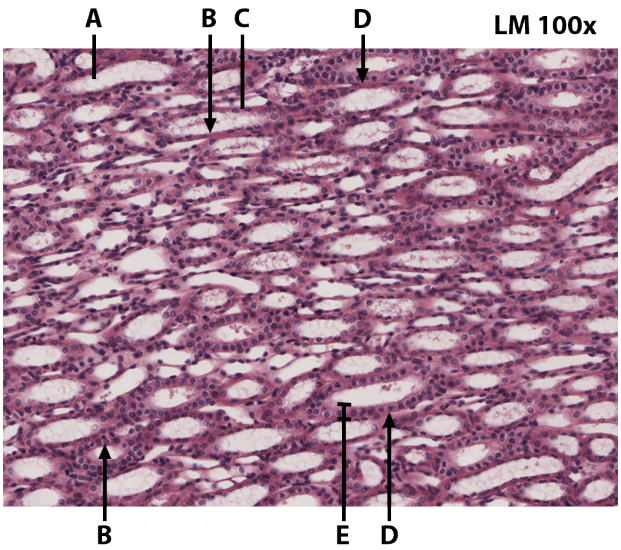

Image credit:

"Histology of Simple Squamous and Simple Cuboidal Epithelia" by Jennifer Lange, slide provided by the Regents of the University of Michigan Medical School under CC BY-NC-SA 4.0 © 2022.

Answer Key (click to show/hide answers)

A - lumen

B - apical side

C - simple squamous epithelium

D - basal side

E - simple cuboidal epithelium

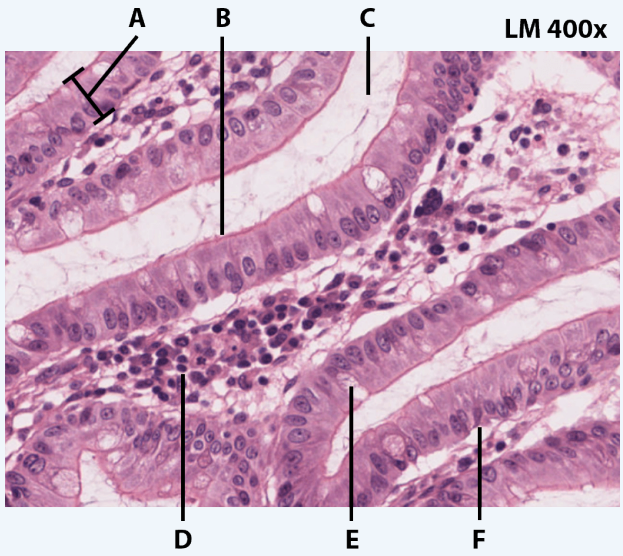

Image credit:

"Histology of Simple Columnar Epithelium" by Jennifer Lange, slide provided by the Regents of the University of Michigan Medical School under CC BY-NC-SA 4.0 © 2022.

Answer Key (click to show/hide answers)

A - simple columnar epithelium

B - apical side

C - lumen

D - connective tissue of lamina propria

E - goblet cell

F - basal side

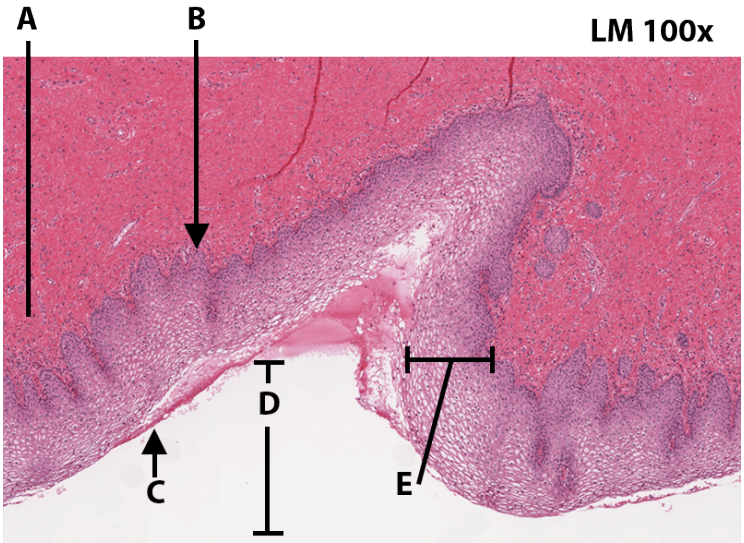

Image credit:

"Histology of Stratified Squamous Epithelium" by Jennifer Lange, slide provided by the Regents of the University of Michigan Medical School under CC BY-NC-SA 4.0 © 2022.

Answer Key (click to show/hide answers)

A - connective tissue of the lamina propria

B - basal side/ basement membrane

C - apical side

D - lumen

E - stratified squamous epithelium

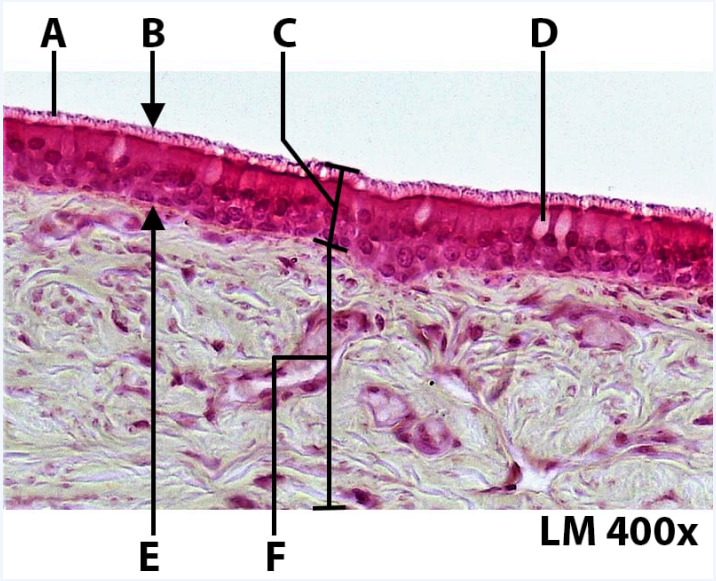

Image credit:

"Pseudostratified Columnar Epithelium Histology" by Jennifer Lange is licensed under CC BY-NC-SA 4.0, Micrograph provided by Berkshire Community College Bioscience Image Library is in the Public Domain.

Answer Key (click to show/hide answers)

A - cilia

B - apical side

C - pseudostratified columnar epithelium

D - goblet cell

E - basal side/ basement membrane

F - connective tissue of lamina propria

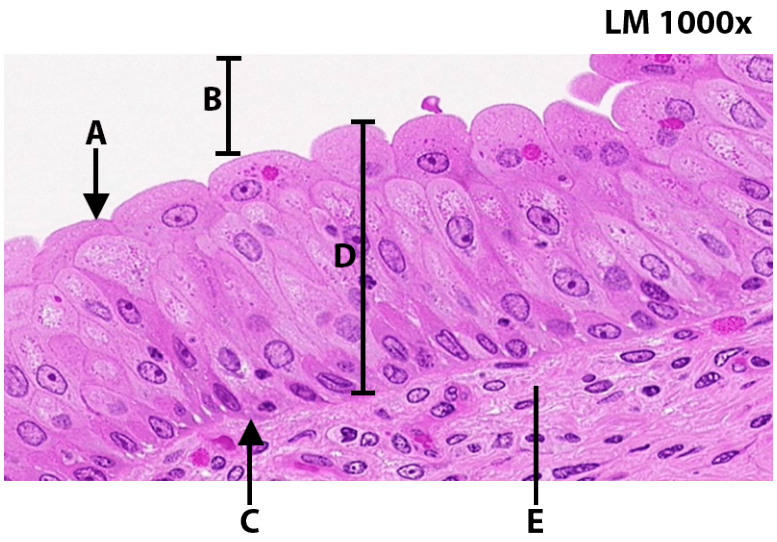

Image credit:

"Histology of Transitional Epithelium" by Jennifer Lange, slide provided by the Regents of the University of Michigan Medical School under CC BY-NC-SA 4.0 © 2022.

Answer Key (click to show/hide answers)

A - apical side

B - lumen

C - basal side/ basement membrane

D - transitional epithelium

E - connective tissue of the lamina propria

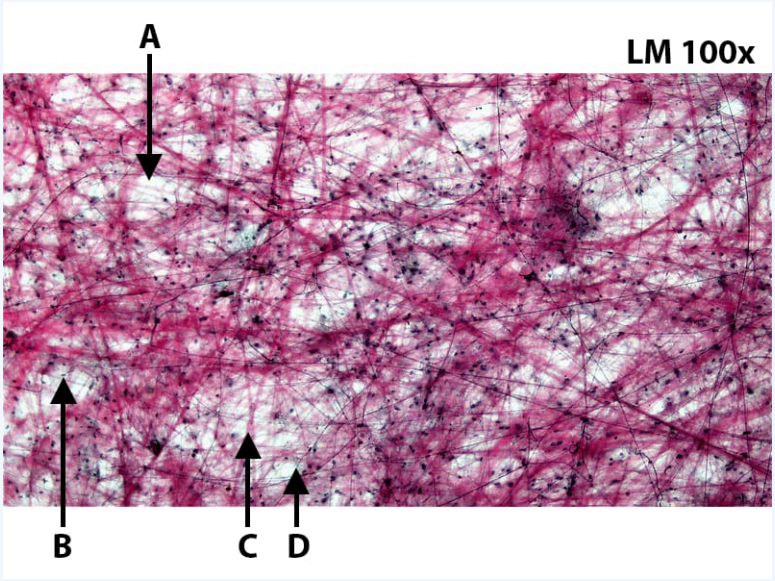

Image credit:

"Areolar Connective Tissue Histology" by Jennifer Lange is licensed under CC BY-NC-SA 4.0, Micrograph provided by Berkshire Community College Bioscience Image Library is in the Public Domain.

Answer Key (click to show/hide answers)

Areolar Connective Tissue

A - ground substance

B - fibroblast

C - collagen fiber

D - elastin fiber

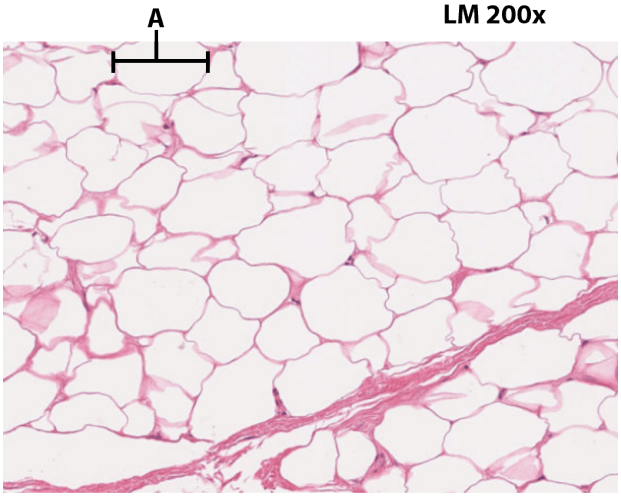

Image credit:

"Histology of Adipose Connective Tissue" by Jennifer Lange, slide provided by the Regents of the University of Michigan Medical School under CC BY-NC-SA 4.0 © 2022.

Answer Key (click to show/hide answers)

Adipose Connective Tissue

A - adipocyte

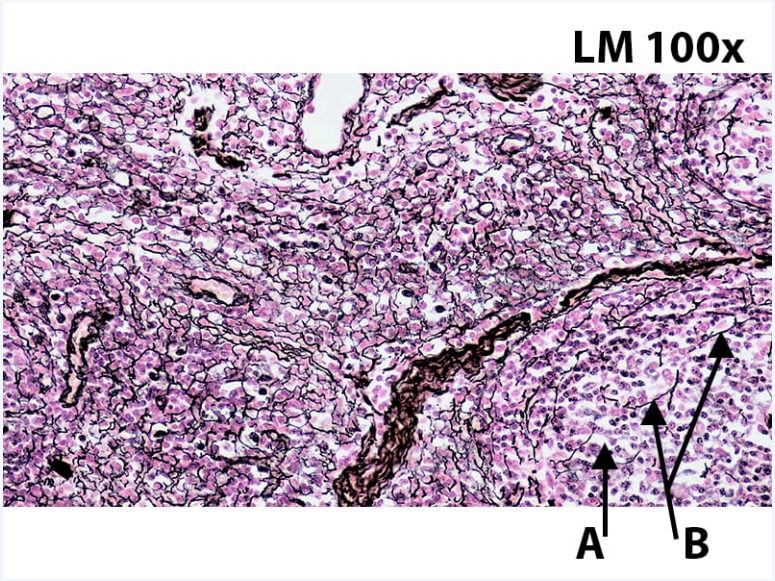

Image credit:

"Reticular Connective Tissue Histology" by Jennifer Lange is licensed under CC BY-NC-SA 4.0, Micrograph provided by Berkshire Community College Bioscience Image Library is in the Public Domain.

Answer Key (click to show/hide answers)

A - ground substance

B - reticulin fibers

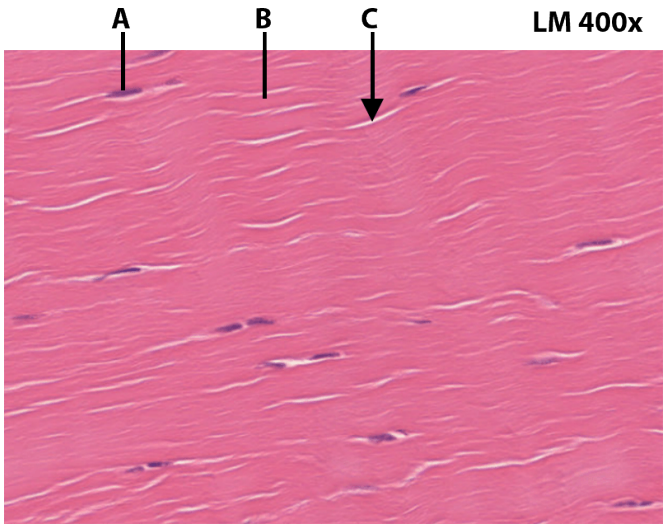

Image credit:

"Histology of Dense Regular Connective Tissue" by Jennifer Lange, slide provided by the Regents of the University of Michigan Medical School under CC BY-NC-SA 4.0 © 2022.

Answer Key (click to show/hide answers)

Dense Regular Connective Tissue

A - fibroblast

B - collagen fiber (bundle)

C - ground substance

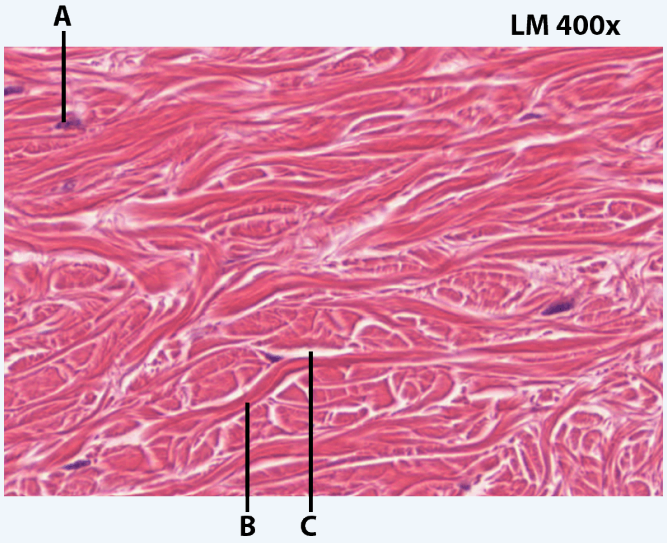

Image credit:

"Histology of Dense Irregular Connective Tissue" by Jennifer Lange, slide provided by the Regents of the University of Michigan Medical School under CC BY-NC-SA 4.0 © 2022.

Answer Key (click to show/hide answers)

Dense Irregular Connective Tissue

A - fibroblast

B - collagen fiber (bundle)

C - ground substance

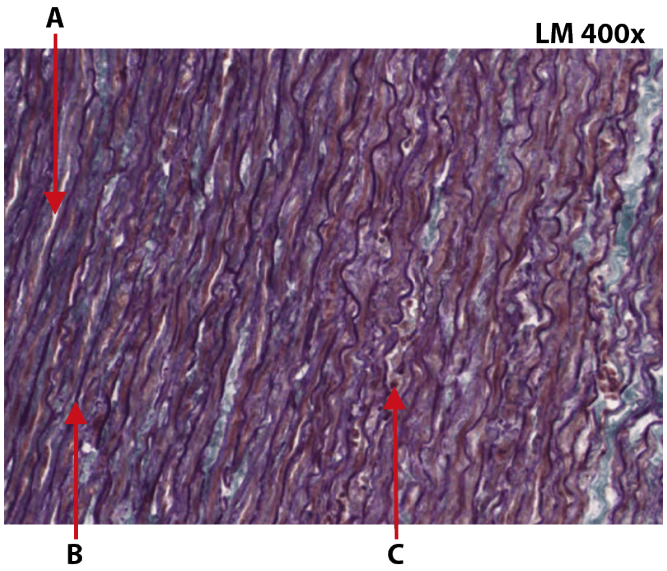

Image credit:

"Histology of Elastic Connective Tissue" by Jennifer Lange, slide provided by the Regents of the University of Michigan Medical School under CC BY-NC-SA 4.0 © 2022.

Answer Key (click to show/hide answers)

Elastic Connective Tissue

A - ground substance

B - elastic fiber

C - fibroblast

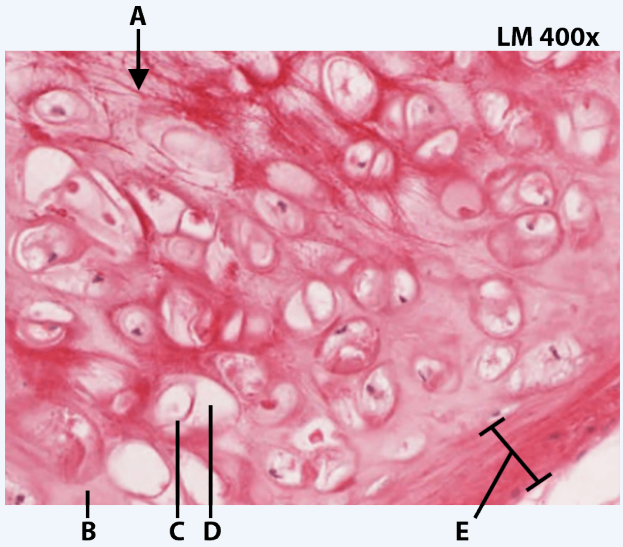

Image credit:

"Histology of Elastic Cartilage" by Jennifer Lange, slide provided by the Regents of the University of Michigan Medical School under CC BY-NC-SA 4.0 © 2022.

Answer Key (click to show/hide answers)

Elastic Cartilage

A - elastic fiber

B - ground substance

C - chondrocyte

D - lacuna

E - perichondrium

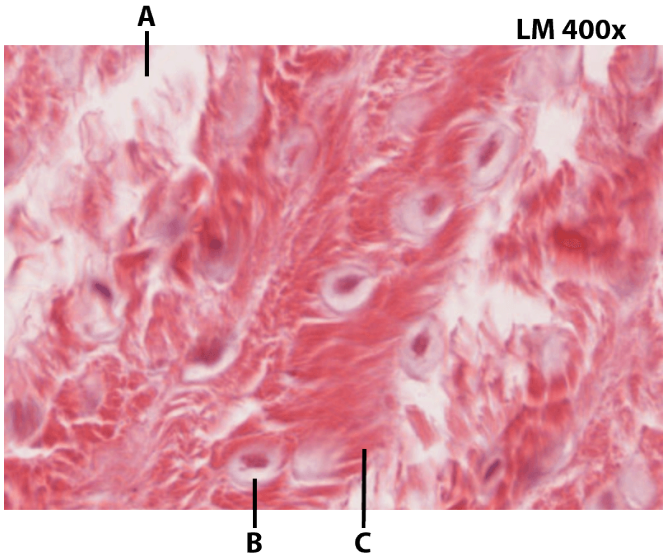

Image credit:

"Histology of Fibrocartilage" by Jennifer Lange, slide provided by the Regents of the University of Michigan Medical School under CC BY-NC-SA 4.0 © 2022.

Answer Key (click to show/hide answers)

Fibrocartilage

A - ground substance

B - chondrocyte

C - collagen fiber

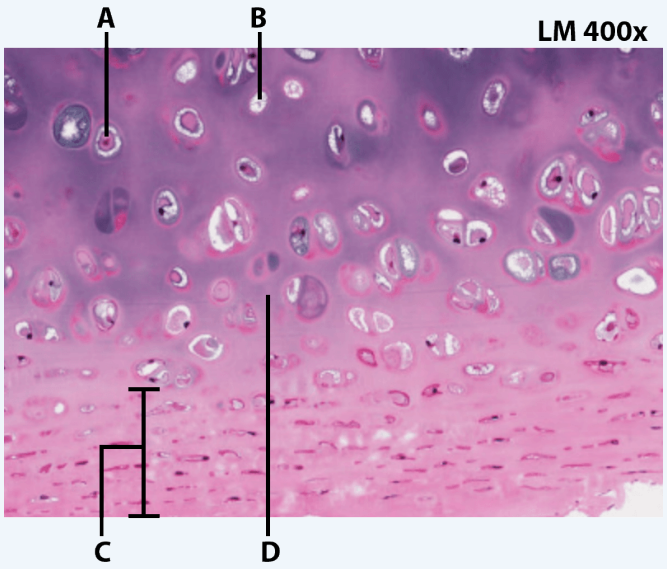

Image credit:

"Histology of Hyaline Cartilage" by Jennifer Lange, slide provided by the Regents of the University of Michigan Medical School under CC BY-NC-SA 4.0 © 2022.

Answer Key (click to show/hide answers)

Hyaline Cartilage

A - chondrocyte

B - lacuna

C - perichondrium

D - extracellular matrix

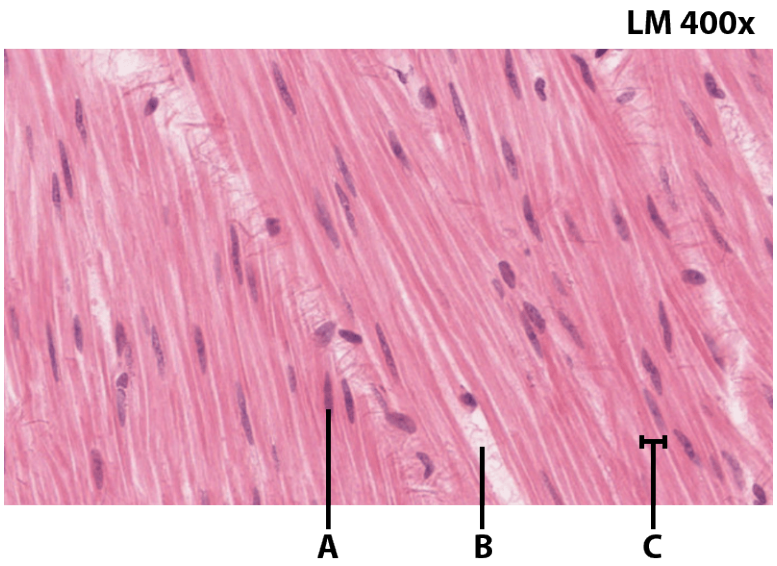

Image credit:

"Histology of Smooth Muscle" by Jennifer Lange, slide provided by the Regents of the University of Michigan Medical School under CC BY-NC-SA 4.0 © 2022.

Answer Key (click to show/hide answers)

Smooth Muscle Longitudinal Section

A - nucleus

B - endomysium

C - myofiber

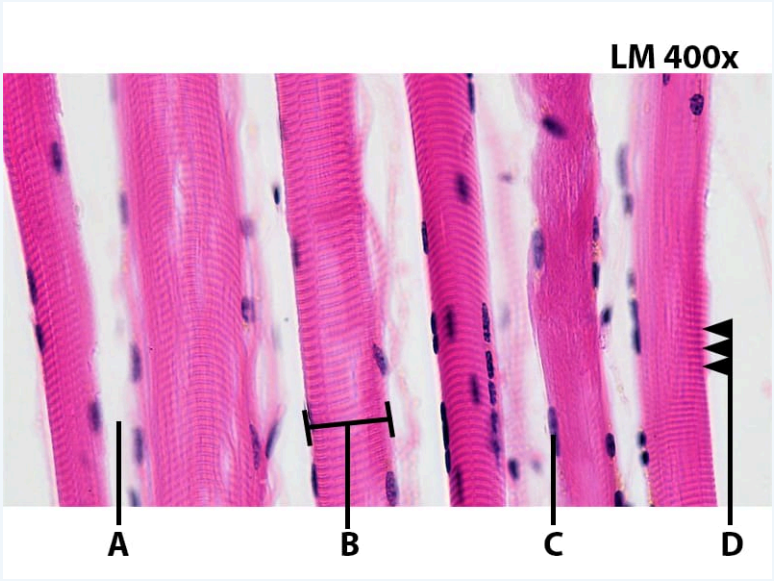

Image credit:

"Skeletal Muscle Histology - Longitudinal Section" by Jennifer Lange is licensed under CC BY-NC-SA 4.0, Micrograph provided by Berkshire Community College Bioscience Image Library is in the Public Domain.

Answer Key (click to show/hide answers)

Skeletal Muscle Longitudinal Section

A - endomysium

B - myofiber

C - nucleus (peripheral)

D - striations

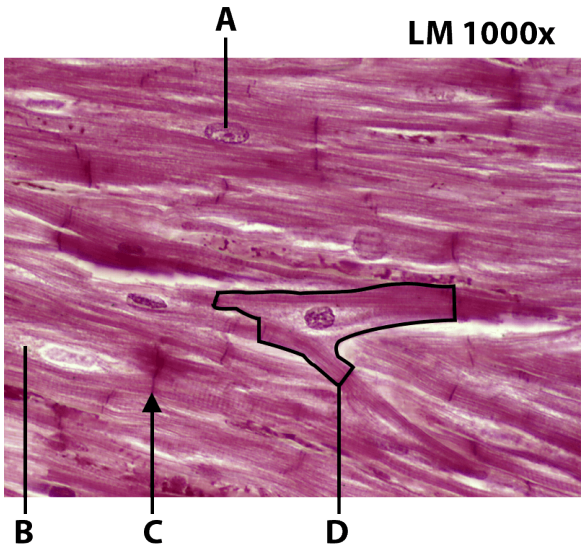

Image credit:

"Cardiac Muscle Histology" by Jennifer Lange; micrographs provided by Virginia Commonwealth University under CC BY-NC-SA 4.0.

Answer Key (click to show/hide answers)

Cardiac Muscle Tissue

A - nucleus (central)

B - endomysium

C - intercalated disc

D - myofiber

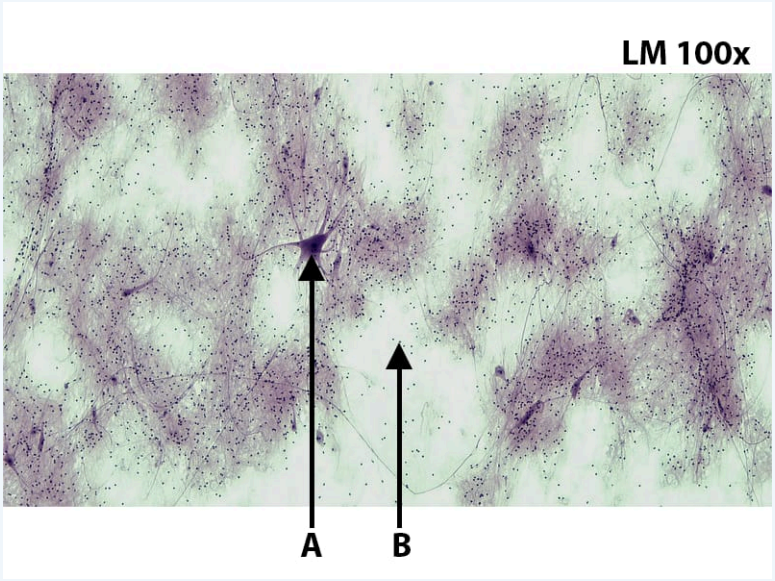

Image credit:

"Nervous Tissue Histology - Spinal Cord Smear" by Jennifer Lange is licensed under CC BY-NC-SA 4.0, Micrograph provided by Berkshire Community College Bioscience Image Library is in the Public Domain.

Answer Key (click to show/hide answers)

Nervous Tissue - Grey Matter, Spinal Cord Smear

A - neuron

B - neuroglia

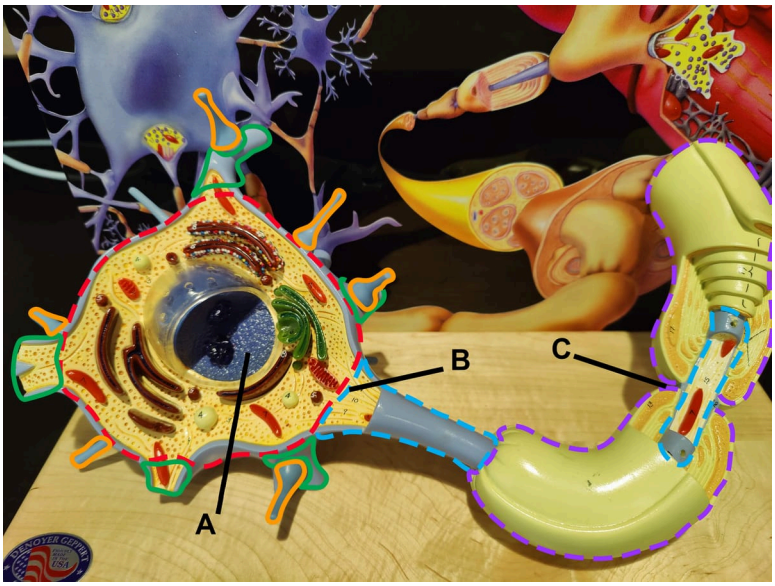

Image credit:

"Neuron Model" by Jennifer Lange is licensed under CC BY-NC-SA 4.0.

Answer Key (click to show/hide answers)

Red - soma/cell body

Blue - axon

Purple - myelin sheath/ neurolemmocytes

Green - dendrites

Orange - axon/ synaptic terminals

A - nucleus

B - axon hillock

C - neurofibril node (of Ranvier)

This page titled 3.8: Anatomical Atlas - Tissues is shared under a CC BY-NC-SA 4.0 license and was authored, remixed, and/or curated by Jennifer Lange et al..

3.9: Practice Practical- Tissues

Answer each of the following questions by typing your answer into the box(es).

Query 3.9.1

This interactive element is not available in this format. Visit the link or scan the QR code to access it online.

View this Interactive Content online

Query 3.9.1

This interactive element is not available in this format. Visit the link or scan the QR code to access it online.

View this Interactive Content online

Query 3.9.1

This interactive element is not available in this format. Visit the link or scan the QR code to access it online.

View this Interactive Content online

Query 3.9.1

This interactive element is not available in this format. Visit the link or scan the QR code to access it online.

View this Interactive Content online

Query 3.9.1

This interactive element is not available in this format. Visit the link or scan the QR code to access it online.

View this Interactive Content online

Query 3.9.1

This interactive element is not available in this format. Visit the link or scan the QR code to access it online.

View this Interactive Content online



Query 3.9.1

This interactive element is not available in this format. Visit the link or scan the QR code to access it online.

View this Interactive Content online

Query 3.9.1

This interactive element is not available in this format. Visit the link or scan the QR code to access it online.

View this Interactive Content online

Query 3.9.1

This interactive element is not available in this format. Visit the link or scan the QR code to access it online.

View this Interactive Content online

Query 3.9.1

This interactive element is not available in this format. Visit the link or scan the QR code to access it online.

View this Interactive Content online

This page titled 3.9: Practice Practical- Tissues is shared under a CC BY-NC-SA 4.0 license and was authored, remixed, and/or curated by Jennifer Lange et al..

4: INTEGUMENTARY SYSTEM

4.1: Introduction to the Integumentary System

4.2: Layers of the Skin

4.3: Accessory Structures of the Skin

4.4: Functions of the Integumentary System

4.5: Diseases, Disorders, and Injuries of the Integumentary System

4.6: Anatomical Atlas - Integumentary System

4.7: Practice Practical - Integumentary System

This page titled 4: Integumentary System is shared under a CC BY-NC-SA 4.0 license and was authored, remixed, and/or curated by Jennifer Lange et al..

- 4: Integumentary System by Whitney Menefee, Julie Jenks, Chiara Mazzasette, and Kim-Leiloni Nguyen is licensed CC BY 4.0.

4.1: Introduction to the Integumentary System

Chapter Learning Objectives

After studying the chapter, you will be able to:

- Describe the functions of the integumentary system and the role it plays in homeostasis
- Describe the layers of the skin and the functions of each layer
- Describe the accessory structures of the skin and the functions of each
- Describe the changes that occur in the integumentary system during the aging process
- Discuss several common diseases, disorders, and injuries that affect the integumentary system

Figure 4.1.1: A grandmother, in Villas Flores Mexico, having described her love for her granddaughter. Our skin is the first line barrier between us and the outside world, with damages accumulating over time. Chronologically aged skin is characterized by decreased recovery capacity, altered permeability of the superficial epithelial cells, epithelial cell atrophy, and decreased amounts of fibroblasts and collagen in the underlying connective tissues. *(Image credit: "Granddaughter's Love for the Grandmother Raising Her" by Jim McKinney is licensed under CC BY-SA 4.0, via Wikimedia Commons.)*

What do you think when you look at your skin in the mirror? Do you think about covering it with makeup, adding a tattoo, or maybe a body piercing? Or do you think about the fact that the skin belongs to one of the body's most essential and dynamic systems: the integumentary system? The integumentary system refers to the skin and its accessory structures, and it is responsible for much more than simply lending to your outward appearance. In the adult human body, the skin makes up about 16 percent of body weight and covers an area of 1.5 to 2 m^2. In fact, the skin and accessory structures are the largest organ system in the human body. As such, the skin protects your inner organs and it is in need of daily care and protection to maintain its health. This chapter will introduce the structure and functions of the integumentary system, as well as some of the diseases, disorders, and injuries that can affect this system.

Contributors and Attributions

- OpenStax Anatomy & Physiology (CC BY 4.0). Access for free at https://openstax.org/books/anatomy-and-physiology

This page titled 4.1: Introduction to the Integumentary System is shared under a CC BY-NC-SA 4.0 license and was authored, remixed, and/or curated by Jennifer Lange et al..

- 4.1: Introduction to the Integumentary System by Whitney Menefee, Julie Jenks, Chiara Mazzasette, and Kim-Leiloni Nguyen is licensed CC BY 4.0.

4.2: Layers of the Skin

By the end of the section, you will be able to:

- Identify the components of the integumentary system
- Describe the layers of the skin and the functions of each layer
- Identify and describe the hypodermis
- Describe the role of keratinocytes and their life cycle
- Describe the role of melanocytes in skin pigmentation

Although you may not typically think of the skin as an organ, it is in fact made of tissues that work together as a single structure to perform unique and critical functions. The skin and its accessory structures make up the **integumentary system**, which provides the body with overall protection. The skin is made of multiple layers of cells and tissues, which are held to underlying structures by connective tissue (Figure 4.2.1). The superficial layer, known as the **epidermis**, is composed primarily of tightly packed epithelial cells. The deeper layer of skin, the **dermis**, is well vascularized (has numerous blood vessels) and is where several accessory structures, such as hair follicles, sweat glands, and oil glands, can be found. It also has numerous sensory and motor nerve fibers ensuring communication to and from the brain. Below the dermis lies the superficial fascia, or **hypodermis**, which is not technically part of the skin, but serves to connect the skin to the underlying fascia. This layer is mainly composed of areolar and adipose connective tissues.

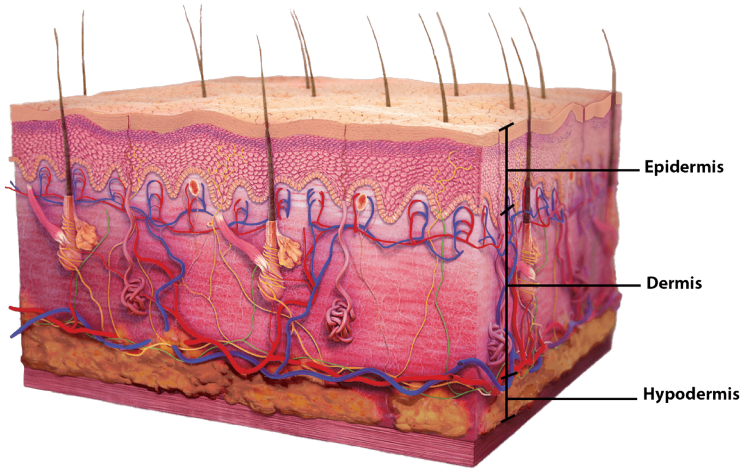

Figure 4.2.1: Layers of Skin. The skin is composed of two main layers: the epidermis and the dermis. The epidermis is a keratinized stratified squamous epithelium. The dermis contains blood vessels, hair follicles, sweat glands, and other structures. Beneath the dermis lies the hypodermis.

Image credit:

"Layers of the Skin" by Sophia Elizondo and Jennifer Lange is licensed under CC BY-NC-SA 4.0, modification of original by Scientific Animations.

The Epidermis

The **epidermis** is composed of keratinized, stratified squamous epithelium. It is made of four or five layers of epithelial cells, depending on its location in the body. It does not have any blood vessels within it (i.e., it is avascular). From deep to superficial, these layers are:

- the stratum basale (basal layer)

- stratum spinosum (spiny layer)
- stratum granulosum (grainy layer)
- stratum lucidum (clear layer)
- stratum corneum (horny layer)

Most of the skin can be classified as thin skin. Thin skin measures between 0.07-0.15 mm from apical to basal side of the epithelium. It has four layers (no stratum lucidum) and has fewer layers of cells in the stratum corneum. Thick skin is found on the palms of the hands and the soles of the feet, where it measures approximately 1.5 mm between the apical and basal sides. It has the fifth layer, the stratum lucidum, as well as more cells in the stratum corneum that contribute to extra depth (Figure 4.2.2).

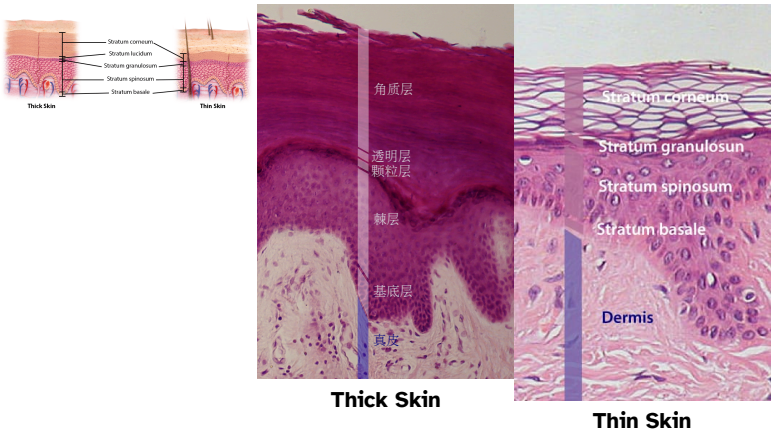

Figure 4.2.2: Layers of the Epidermis. The keratinocytes in the different layers of the epidermis originate from basal cells located in the stratum basale, yet the cells of each layer change as they are pushed up through the layers of the epidermis.

Image credits:

"Epidermal Strata Thick Skin vs. Thin Skin" illustration by Jennifer Lange is licensed under CC BY-NC-SA 4.0, modification of original by Scientific Animations; "Epidermal Layers Micrograph" by Wbensmith, CC BY 3.0 via Wikimedia Commons; "Epidermal Layers Micrograph Thin Skin" by Gabrielle Spurlock, modification of original by Kilbad, Public domain, via Wikimedia Commons.

The majority of cells in the epidermis are called keratinocytes. A **keratinocyte** is a cell that manufactures and stores the protein keratin. **Keratin** is an intracellular fibrous protein that gives hair, nails, and skin their hardness and water-resistant properties. The keratinocytes on the apical surface are dead and regularly slough away, being replaced by cells from the deeper layers.

Stratum Basale

The **stratum basale** (also called the stratum germinativum) is the deepest epidermal layer and attaches the epidermis to the basal lamina, below which lie the layers of the dermis. The cells in the stratum basale bond to the dermis via intertwining collagen fibers, referred to as the basement membrane. A finger-like projection, or fold, known as the **dermal papilla** (plural = dermal papillae) is found in the superficial portion of the dermis. Dermal papillae increase the strength of the connection between the epidermis and dermis; the greater the surface area conveyed by folding, the stronger the connections made (Figure 4.2.3).

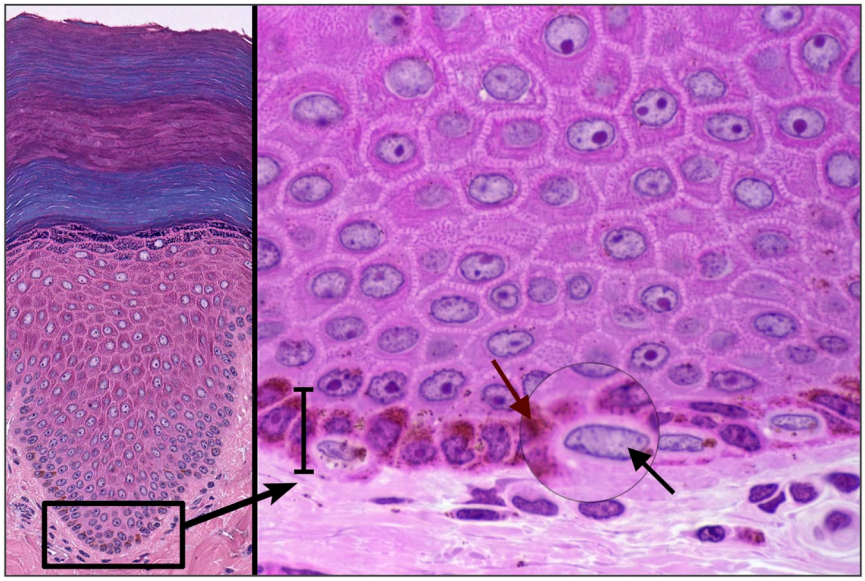

Figure 4.2.3: Stratum Basale. The stratum basale contains a layer of keratinocytes with melanocytes and Merkel cells dispersed throughout. In the enlargement you can see four melanocytes (at arrow - nuclei are more horizontal) and the reddish-brown melanin granules. LM @200x and LM @1000x.

Image credit:
"Stratum Basale" by Jennifer Lange, micrographs provided by Virginia Commonwealth University under CC-BY-NC-SA 4.0.

The stratum basale is a single layer of cells primarily made of basal cells. A **basal cell** is a cuboidal-shaped stem cell that is a precursor of the keratinocytes of the epidermis. All of the keratinocytes are produced from this single layer of cells, which are constantly going through mitosis to produce new cells. As new cells are formed, the existing cells are pushed superficially away from the stratum basale. Two other cell types are found dispersed among the basal cells in the stratum basale. The first is a **Merkel cell,** also known as a tactile cell, which functions as a receptor and is responsible for stimulating sensory nerves that the brain perceives as touch. These cells are especially abundant on the surfaces of the hands and feet. The second is a **melanocyte**, a cell that produces the pigment melanin. **Melanin** gives hair and skin its color, and also helps protect the living cells of the epidermis from ultraviolet (UV) radiation damage.

In a growing fetus, fingerprints form where the cells of the stratum basale meet the papillae of the underlying dermal layer (papillary layer), resulting in the formation of the ridges on your fingers that you recognize as fingerprints. Fingerprints are unique to each individual and are used for forensic analyses because the patterns do not change with the growth and aging processes.

Stratum Spinosum

As the name suggests, the **stratum spinosum** is spiny in appearance due to the protruding cell processes that join the cells via an anchoring junction common in epithelial tissues called a **desmosome**. The desmosomes interlock with each other and strengthen the bond between the cells. It is interesting to note that the “spiny” nature of this layer is an artifact of the staining process. Unstained epidermis samples do not exhibit this characteristic appearance. The stratum spinosum is composed of eight to ten layers of keratinocytes, formed as a result of cell division in the stratum basale (Figure 4.2.4). The keratinocytes in the stratum spinosum begin the synthesis of keratin and release a water-repelling glycolipid that helps prevent water loss from the body, making the skin relatively waterproof. As new keratinocytes are produced atop the stratum basale, the keratinocytes of the stratum spinosum are pushed into the stratum granulosum. Wandering among the keratinocytes of this layer is a type of dendritic cell called the **Langerhans cell** which differentiates from and functions similarly to a macrophage (type of white blood cell) by engulfing bacteria, foreign particles, and damaged cells that occur in this layer.

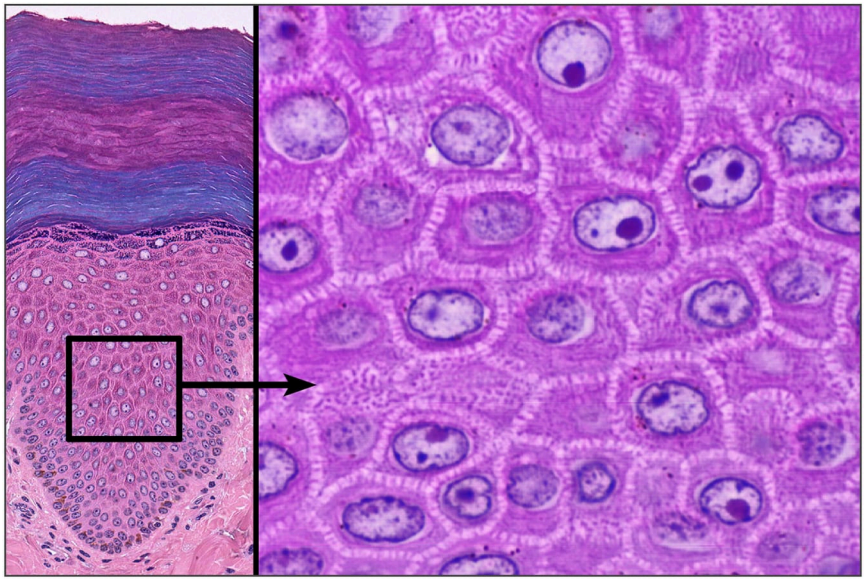

Figure 4.2.4: Intercellular Junctions in the Stratum Spinosum. The enlargement of this slide shows the filaments of the desmosomes anchoring each cell to its neighbors. These "spines" give this layer its name. LM @200x and @1000x.

Image credit:

"Stratum Spinosum" micrographs provided by Virginia Commonwealth University under CC-BY-NC-SA 4.0.

Stratum Granulosum

The **stratum granulosum** has a grainy appearance due to further changes to the keratinocytes as they are pushed from the stratum spinosum. The cells here (three to five layers thick) become flatter and they contain large, dark purple staining (basophilic) granules that give the layer its grainy appearance (see Figure 4.2.5). The **keratohyalin granules** contain keratin precursors that eventually aggregate, crosslink, and form bundles. The nuclei and other cell organelles degenerate as the cells die, leaving behind the keratin and lipid-coated cell membranes that will form the stratum lucidum, the stratum corneum, and the accessory structures of hair and nails.

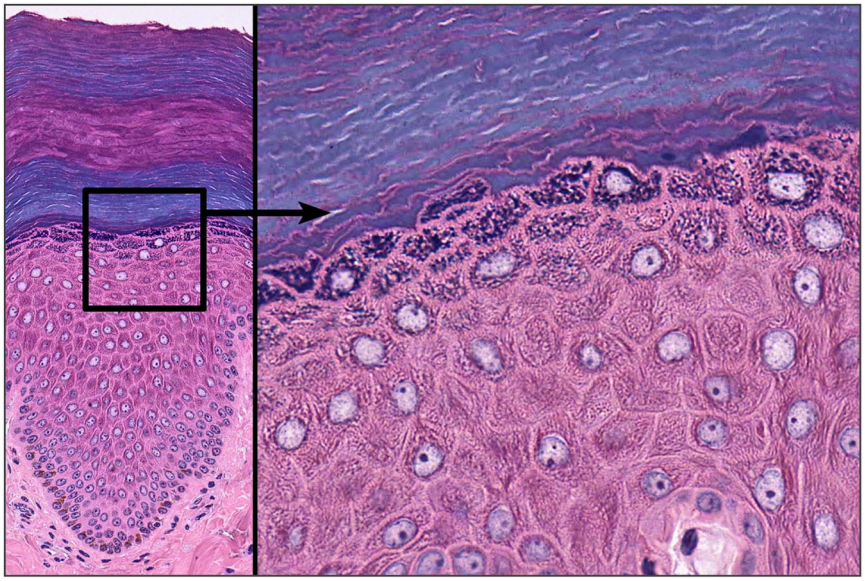

Figure 4.2.5: Stratum Granulosum. The dark granules give this layer its grainy appearance. LM @ 200x; LM @1000x.

Image credit:

"Stratum Granulosum" micrographs provided by Virginia Commonwealth University under CC BY-NC-SA 4.0.

Stratum Lucidum

The **stratum lucidum** is a smooth, seemingly translucent layer of the epidermis located just above the stratum granulosum and below the stratum corneum. This thin layer of cells is found only in the thick skin of the palms, soles, and digits. The keratinocytes that compose the stratum lucidum are dead and flattened (see Figure 4.2.6). These cells are densely packed with **eleiden**, a clear protein rich in lipids, derived from keratohyalin, which gives these cells their transparent (i.e., lucid) appearance and provides a barrier to water.

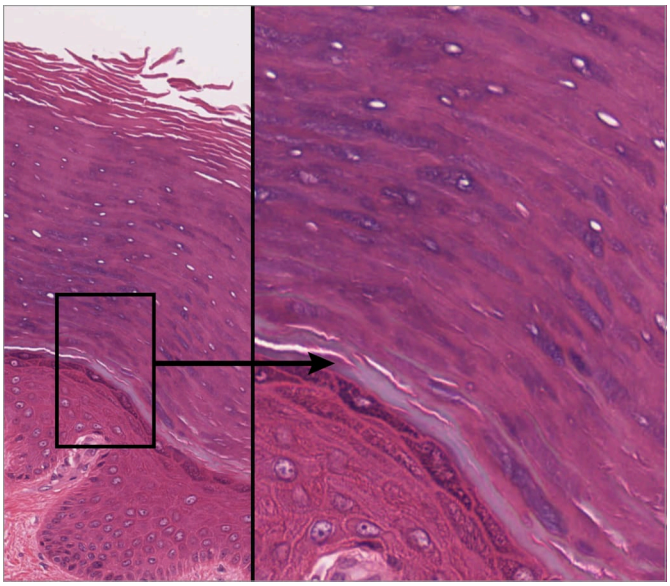

Figure 4.2.6: Stratum Lucidum and Stratum Corneum. Stratum lucidum typically does not stain well so it appears lighter than the surrounding layers. In the stratum corneum the nucleus is indistinct in the deeper cells because it is degrading; in the superficial cells it is absent. LM @ 200x; LM @1000x.

Image credit:

"Stratum Lucidum and Stratum Granulosum" by Jennifer Lange is licensed under CC BY-NC-SA 4.0, micrographs provided by Virginia Commonwealth University under CC-BY-NC-SA 4.0.

Stratum Corneum

The **stratum corneum** is the most superficial layer of the epidermis and is the layer exposed to the outside environment (see Figure 4.2.6). The increased keratinization (also called cornification) of the cells in this layer gives it its name. There are usually 10 to 30 layers (or 35 in thick skin) of anucleate cells in the stratum corneum. This dry, dead layer helps prevent the penetration of microbes and the dehydration of underlying tissues, and provides a mechanical protection against abrasion for the more delicate, underlying layers. Cells in this layer are shed periodically and are replaced by cells pushed up from the stratum granulosum (or stratum lucidum in the case of the palms and soles of feet). The entire layer is replaced during a period of about 4 weeks. Cosmetic procedures, such as microderm abrasion, help remove some of the dry, upper layer and aim to keep the skin looking “fresh” and healthy.

Dermis

The **dermis** might be considered the “core” of the integumentary system (derma- = “skin”), as distinct from the epidermis (epi- = “upon” or “over”) and hypodermis (hypo- = “below”). It contains blood and lymph vessels, nerves, and other structures, such as hair follicles and sweat glands. The dermis is made of two layers of connective tissue, the superficial **papillary layer** and deep **reticular layer**, that compose an interconnected mesh of elastic and collagen fibers, produced by fibroblasts (Figure 4.2.7).

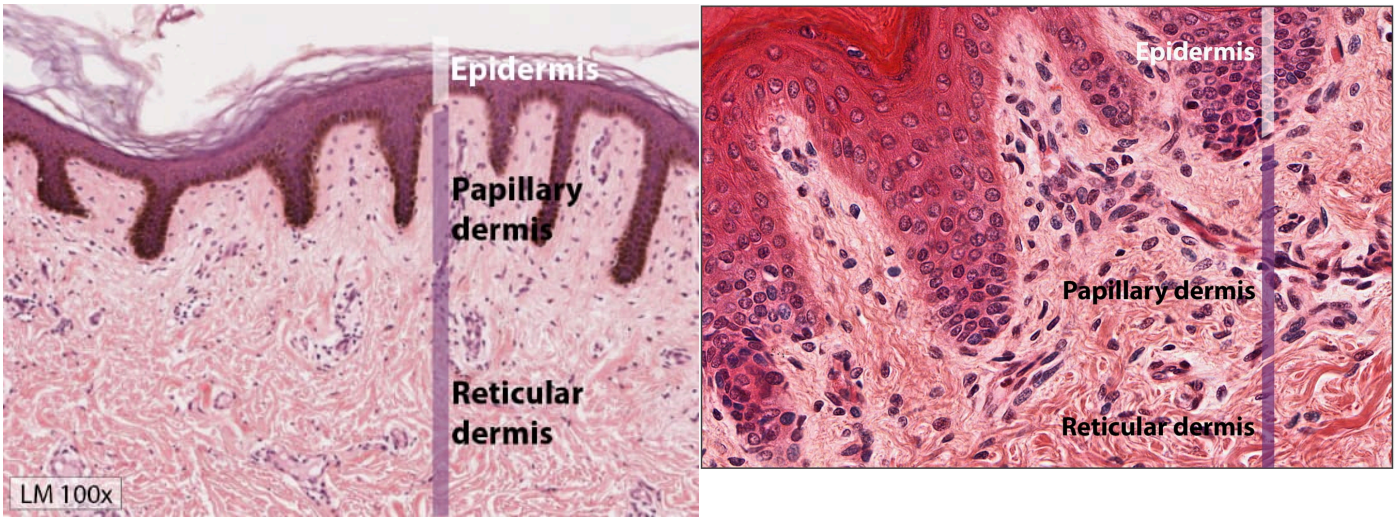

Figure 4.2.7: Layers of the Dermis. These slides show the two sections of the dermis—the papillary layer and the reticular layer. Both layers are made of connective tissue with fibers of collagen extending from one to the other, making the border between the two somewhat indistinct @ 100x. The collagen fibers in the areolar connective tissue of the papillary layer are finer whereas the thick collagen fiber bundles belong to the dense irregular connective tissue of the reticular layer, which is easier to see @ 1000x.

Image credit:

"Layers of the Dermis @100x" by Jennifer Lange is licensed under CC-BY-NC-SA 4.0, slide provided by the Regents of theUniversity of Michigan Medical School underCC BY-NC-SA 4.0 © 2022. "Layers of the Dermis @1000x by Jennifer Lange is licensed under CC BY-NC-SA 4.0, micrograph provided byVirginia Commonwealth University, is licensed under CC-BY-NC-SA 4.0.

Papillary Layer

The **papillary layer** is made of loose, areolar connective tissue, which means the fibers of this layer form a loose mesh. This superficial layer of the dermis projects up under the stratum basale of the epidermis to form finger-like dermal papillae. Within the papillary layer are fibroblasts, a small number of fat cells (adipocytes), an abundance of small blood vessels, and phagocytes, defensive cells that help fight bacteria or other infections that have breached the epidermis. This layer also contains lymphatic capillaries, nerve fibers, and touch receptors called the Meissner corpuscles. Also known as tactile corpuscles, Meissner corpuscles can be found located in the dermal papillae, and are responsible for sensing light touch. More details on the sensory functions of skin are covered later in this chapter.

Reticular Layer

Underlying the papillary layer is the much thicker **reticular layer**, composed of dense irregular connective tissue. This layer is well vascularized and has a rich sensory and sympathetic nerve supply. The reticular layer appears reticulated (net-like) due to a tight meshwork of fibers with small amounts of ground substance. **Elastic fibers** provide some elasticity to the skin, enabling movement. Collagen fibers provide structure and tensile strength, with strands of collagen extending into both the papillary layer and the hypodermis. In addition, collagen binds water to keep the skin hydrated. Collagen injections and Retin-A creams help restore skin turgor by either introducing collagen externally or stimulating blood flow and repair of the dermis, respectively.

Hypodermis

The **hypodermis** (also called the subcutaneous layer) is a layer directly deep to the dermis that serves to connect the skin to the underlying fascia (fibrous tissue) of the bones and muscles. It is not strictly a part of the skin, although some of the accessory organs of the integument as well as sensory receptors are located in the hypodermis. The hypodermis consists of well-vascularized, areolar connective tissue and adipose tissue that function as a mode of fat storage and provides insulation and cushioning for the skin.

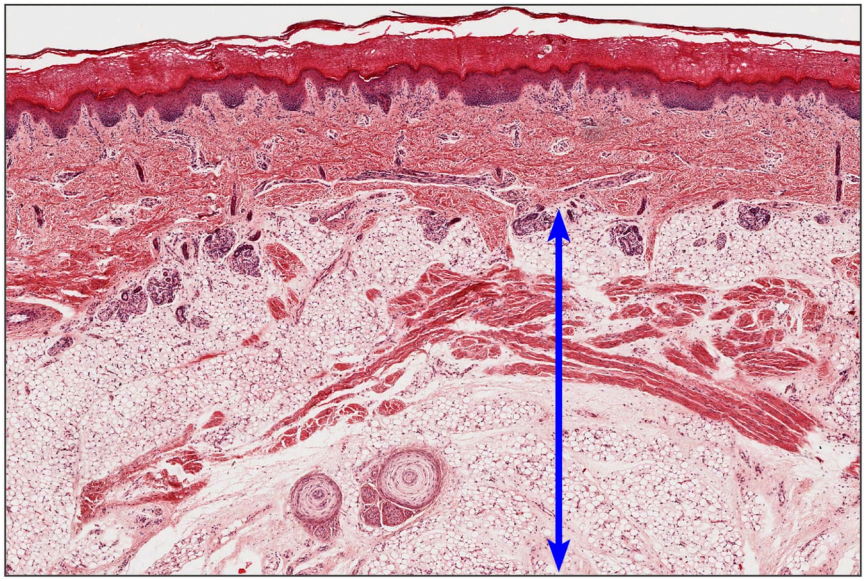

Figure 4.2.8: The hypodermis is comprised mainly of adipose tissue that joins the integument with the underlying tissues. LM @40x.

Image credit:

"Hypodermis" micrograph provided by Virginia Commonwealth University, is licensed under CC-BY-NC-SA 4.0.

EVERYDAY CONNECTION

Lipid Storage

The hypodermis is home to most of the fat that concerns people when they are trying to keep their weight under control. Adipose tissue present in the hypodermis consists of fat-storing cells called adipocytes. This stored fat can serve as an energy reserve, insulate the body to prevent heat loss, and act as a cushion to protect underlying structures from trauma.

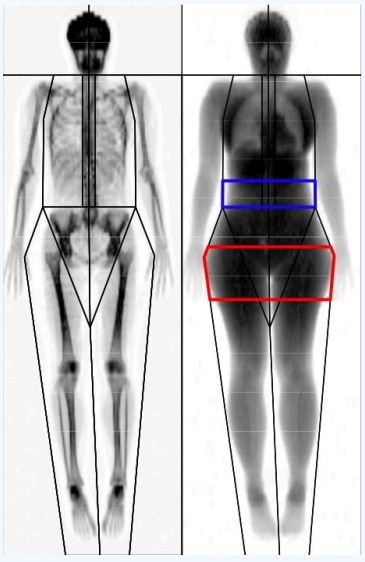

This full body scan highlights the different locations of body fat deposition in males (outlined in blue) and females (outlined in red). *Image credit: "Typical Full Body DXA Scan" from ResearchGate.net is licensed under CC BY 2.0.*

Where the fat is deposited and accumulates within the hypodermis depends on hormones (testosterone, estrogen, insulin, glucagon, leptin, and others), as well as genetic factors. Fat distribution changes as our bodies mature and age. Men tend to accumulate fat in different areas (neck, arms, lower back, and abdomen) than do women (breasts, hips, thighs, and buttocks). The body mass index (BMI) is often used as a measure of fat, although this measure is, in fact, derived from a mathematical formula that compares body weight (mass) to height. Therefore, its accuracy as a health indicator can be called into question in individuals who are extremely physically fit.

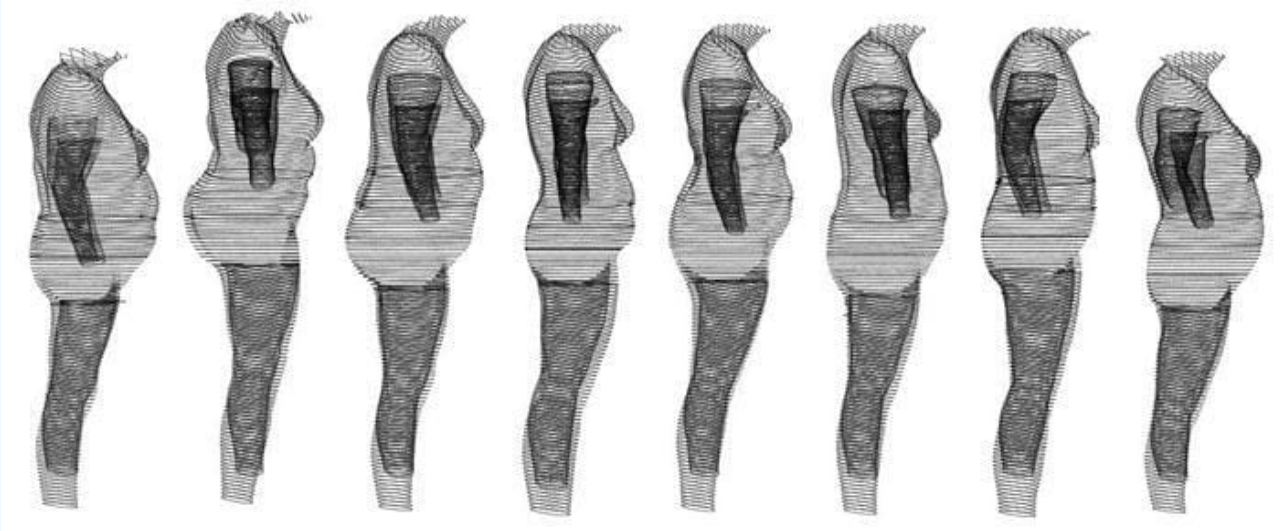

Body Mass Index (BMI) only looks at the ratio of body weight to height, not how that weight is distributed in the body. Each of these eight women have a BMI of 30. *Image credit: Richard2902 at English Wikipedia, Public domain, via Wikimedia Commons.*

In many animals, there is a pattern of storing excess calories as fat to be used in times when food is not readily available. In much of the developed world, insufficient exercise coupled with the ready availability and consumption of high-calorie foods have resulted in unwanted accumulations of stored lipids in adipose tissue in many people. Although periodic accumulation of excess fat may have provided an evolutionary advantage to our ancestors, who experienced unpredictable bouts of famine, it is now becoming chronic and considered a major health threat. Recent studies indicate that a distressing percentage of our population is overweight and/or clinically obese. Not only is this a problem for the individuals affected, but it also has a severe impact on our healthcare system. Changes in lifestyle, specifically in diet and exercise, are the best ways to control body fat accumulation, especially when it reaches levels that increase the risk of heart disease and diabetes.

Pigmentation

The color of skin is influenced by a number of pigments, including melanin, carotene, and hemoglobin. Recall that melanin is produced by cells called melanocytes, which are found scattered throughout the stratum basale of the epidermis. The melanin is transferred into the keratinocytes via a cellular vesicle called a **melanosome** (Figure 4.2.3) and (Figure 4.2.9).

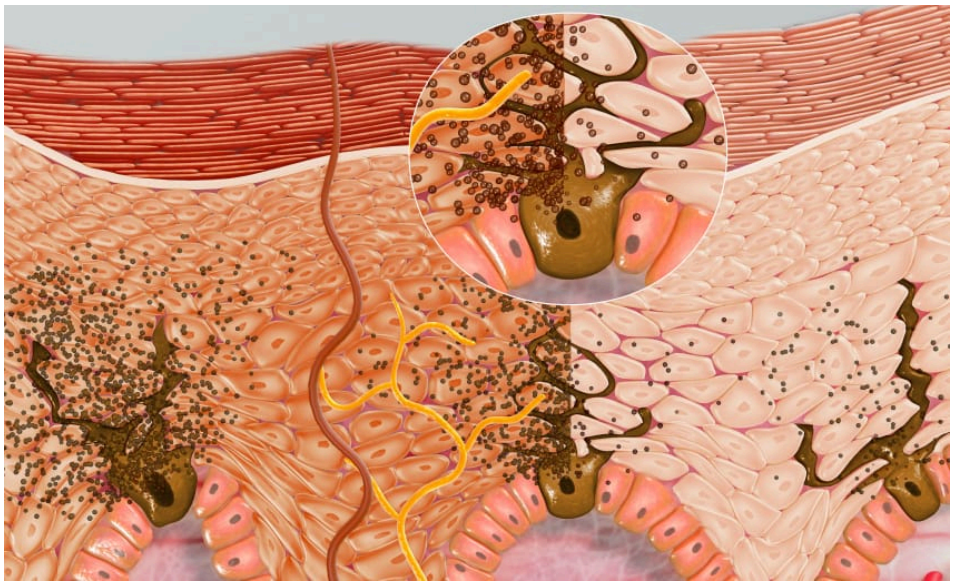

Figure 4.2.9: Skin Pigmentation. The relative coloration of the skin depends of the amount of melanin produced by melanocytes that is then taken up by keratinocytes. Tanning darkens the skin by increasing melanin production.

Image credit:

"Skin Pigmentation" by Scientific Animations is licensed under CC BY-SA 4.0 International.

Melanin occurs in two primary forms: eumelanin exists as black and brown whereas pheomelanin provides a red color. Multiple genes are involved in determining how much and which type of melanin are produced, with dark-skinned individuals producing more melanin than those with pale skin. Exposure to the UV rays of the sun or a tanning salon causes melanin to be manufactured and built up in keratinocytes, as sun exposure stimulates keratinocytes to secrete chemicals that stimulate melanocytes. The accumulation of melanin in keratinocytes results in the darkening of the skin, or a tan. This increased melanin accumulation is protection from UV radiation, which could damage the DNA of epidermal cells and breakdown folic acid, a nutrient necessary for our health and well-being, circulating through the bloodstream in the dermis. In contrast, too much melanin can interfere with the production of vitamin D, an important nutrient involved in calcium absorption, since UV radiation is required for its production. Thus, the amount of melanin present in our skin is dependent on a balance between available sunlight and folic acid destruction, and protection from UV radiation and vitamin D production.

It requires about 10 days after initial sun exposure for melanin synthesis to peak, which is why pale-skinned individuals tend to suffer sunburns of the epidermis initially. Dark-skinned individuals can also get sunburns, but are more protected than are pale-skinned individuals. Melanosomes are temporary structures that are eventually destroyed by fusion with lysosomes; this fact, along with melanin-filled keratinocytes in the stratum corneum sloughing off, makes tanning impermanent.

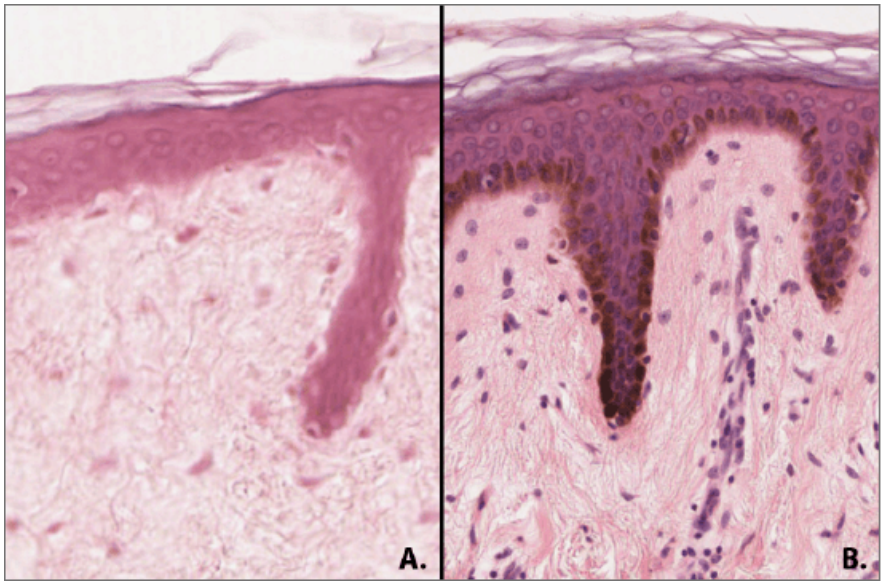

Figure 4.2.10: Melanocytes. Genetics determines how many melanocytes are in the epidermis and how actively they produce and secrete melanin. The epidermis in slide A shows few melanocytes, while that in slide B has abundant melanocytes.

Image credit:

"Melanocytes" by Jennifer Lange is licensed under CC BY-NC-SA 4.0, slide provided by the Regents of the University of Michigan Medical School under CC BY-NC-SA 4.0 © 2022.

Too much sun exposure can eventually lead to wrinkling due to the destruction of the cellular structure of the skin, and in severe cases, can cause sufficient DNA damage to result in skin cancer. When there is an irregular accumulation of melanocytes in the skin, freckles appear. Moles are larger masses of melanocytes, and although most are benign, they should be monitored for changes that might indicate the presence of cancer (Figure 4.2.11).

Figure 4.2.11: Moles. Moles can range in size, shape, and color. These structures populate the landscape of our skin. *Image credit: "Moles" by OpenStax and the National Cancer Institute is licensed under CC BY 3.0.*

Carotene, an orange/red pigment found in many vegetables such as carrots, can also have an affect on skin pigmentation. Once consumed, carotene is converted by the human body into vitamin A, which in turn is used for vision, immune system function, and to stimulate fibroblasts in the skin. Recall that fibroblasts produce the elastic and collagen fibers of the dermis, so having active fibroblast helps with the firmness of skin. However, the over intake of carotene can cause the skin to turn yellowish-orange in color, as a result of the excess being stored just under the skin.

Another factor that can affect the appearance of skin is the activity of hemoglobin in the blood stream. Hemoglobin is a pigment found in red blood cells that is responsible for carrying oxygen throughout the body. A sudden drop in oxygenation

can affect skin color, causing the skin to initially turn ashen (white). With a prolonged reduction in oxygen levels, dark red deoxyhemoglobin (hemoglobin not carrying oxygen) becomes dominant in the blood, making the skin appear blue, a condition referred to as cyanosis (kyanos is the Greek word for “blue”). This happens when the oxygen supply is restricted, as when someone is experiencing difficulty in breathing because of asthma or a heart attack. However, in these cases the effect on skin color has nothing do with the skin’s pigmentation.

DISORDERS OF THE.....

Integumentary System Pigmentation

The first thing a clinician sees is the skin, and so the examination of the skin should be part of any thorough physical examination. Most skin disorders are relatively benign, but a few, including melanomas, can be fatal if untreated. Two disorders, albinism and vitiligo, affect the pigmentation of the skin and its accessory organs. Neither albinism nor vitiligo directly affects the lifespan of an individual.

Albinism is a rare, inherited condition that affects (completely or partially) the coloring of skin, hair, and eyes. The functional change is primarily due to the inability of melanocytes to produce melanin. Individuals with this genotype tend to appear white or very pale due to the lack of melanin in their skin and hair. Recall that melanin helps protect the skin from the harmful effects of UV radiation. Because of the lack of melanin, individuals with albinism tend to need more protection from UV radiation, as they are more prone to sunburns and skin cancer. They also tend to be more sensitive to light and have vision problems due to the lack of pigmentation on the retinal wall. Living with albinism usually involves addressing the harmful environmental factors, such as limiting UV light exposure to the skin and eyes with clothing and sunglasses.

Human Rights Advocate Profile:

Ikponwosa "I.K." Lauretta Ero is a lawyer and advocate in the field of international human rights. She is the first United Nations Independent Expert on the enjoyment of human rights by persons with albinism. Ero was a key player in drawing global attention to the human rights issues faced by people with albinism worldwide, particularly in the region of Africa where they were being attacked for their body parts.

Her work on the elimination of harmful practices—particularly her organization of the first international workshop on harmful practices related to accusation of witchcraft and ritual attacks (HPAWR) -- ultimately culminated in draft guidelines issued by the African Union's Pan African Parliament, and a resolution by the UN Human Rights Council to address these practices.

Ikponmwosa Ero initiated the Global Albinism Alliance and the Africa Albinism Network. She currently serves as Director of Human Rights of Under The Same Sun, as well as a Technical Adviser to the Africa Albinism Network. She is the author of scores of articles in the field of human rights and is the co-lead of the multi-country research on Mothering and Albinism.

This interactive element is not available in this format. Visit the link or scan the QR code to access it online.

View this YouTube Video online

In **vitiligo**, the melanocytes in certain areas lose their ability to produce melanin. Vitiligo occurs when the body's own immune cells mistakenly attack and destroy melanocytes. This destruction is believed to be due to an autoimmune disorder, but its exact cause is unknown. Vitiligo can occur at any age and may appear gradually or suddenly. The primary symptom is the appearance of white or light-colored patches of otherwise normal skin, which can occur on any part of the body. These patches can vary in size and number, have a well-defined darker border, and are most likely to appear on the face, elbows, knees, back of the hands a feet, and genitals. In some cases, hair in the affected areas may also turn white. (Figure 4.2.12).

Figure 4.2.12: Vitiligo. Individuals with vitiligo experience depigmentation that results in lighter colored patches of skin. The condition is especially noticeable on darker skin. *(Image credits: "vitiligo-41" and "figure-66-face" by DermNet NZ are licensed under CC BY-CN-ND 3.0 NZ.)*

Other changes in the appearance of skin coloration can be indicative of diseases associated with other body systems. Liver disease or liver cancer can cause the accumulation of bile and the yellow pigment bilirubin, leading to the skin appearing yellow or jaundiced (*jaune* is the French word for "yellow"). Tumors of the pituitary gland can result in the secretion of large amounts of melanocyte-stimulating hormone (MSH), which results in a darkening of the skin. Similarly, Addison's disease can stimulate the release of excess amounts of adrenocorticotropic hormone (ACTH), which can give the skin a deep bronze color.

Concept Review

The skin is composed of two major layers: a superficial epidermis and a deeper dermis. The epidermis consists of several layers beginning with the innermost (deepest) stratum basale (germinatum), followed by the stratum spinosum, stratum granulosum, stratum lucidum (when present), and ending with the outermost layer, the stratum corneum. The topmost layer, the stratum corneum, consists of dead cells that shed periodically and is progressively replaced by cells formed from the basal layer. The stratum basale also contains melanocytes, cells that produce melanin, the pigment primarily responsible for giving skin its color. Melanin is transferred to keratinocytes in the stratum spinosum to protect from UV rays.

The dermis connects the epidermis to the hypodermis, and provides strength and elasticity due to the presence of collagen and elastic fibers. It has only two layers: the papillary layer composed of loose connective tissue with papillae that extend into the epidermis and the lower, reticular layer composed of dense irregular connective tissue. The hypodermis, deep to the dermis of skin, is the connective tissue that connects the dermis to underlying structures; it also harbors adipose tissue for fat storage and protection.

Review Questions

Query 4.2.1

This interactive element is not available in this format. Visit the link or scan the QR code to access it online.

View this Interactive Content online

Query 4.2.2

This interactive element is not available in this format. Visit the link or scan the QR code to access it online.

View this Interactive Content online

Query 4.2.3

This interactive element is not available in this format. Visit the link or scan the QR code to access it online.

View this Interactive Content online

Query 4.2.4

This interactive element is not available in this format. Visit the link or scan the QR code to access it online.

View this Interactive Content online

Query 4.2.5

This interactive element is not available in this format. Visit the link or scan the QR code to access it online.

View this Interactive Content online

Critical Thinking Questions

Query 4.2.6

This interactive element is not available in this format. Visit the link or scan the QR code to access it online.

View this Interactive Content online

Query 4.2.7

This interactive element is not available in this format. Visit the link or scan the QR code to access it online.

View this Interactive Content online

Glossary

Query 4.2.8

This interactive element is not available in this format. Visit the link or scan the QR code to access it online.

View this Interactive Content online

Contributors and Attributions

- OpenStax Anatomy & Physiology (CC BY 4.0). Access for free at https://openstax.org/books/anatomy-and-physiology

This page titled 4.2: Layers of the Skin is shared under a CC BY-NC-SA 4.0 license and was authored, remixed, and/or curated by Jennifer Lange et al..

- 4.2: Layers of the Skin by Whitney Menefee, Julie Jenks, Chiara Mazzasette, and Kim-Leiloni Nguyen is licensed CC BY 4.0.

4.3: Accessory Structures of the Skin

By the end of the section, you will be able to:

- Identify the accessory structures of the skin
- Describe the structure and function of hair and nails
- Describe the structure and function of sweat glands and sebaceous glands

Accessory structures of the skin include hair, nails, sweat glands, and sebaceous glands. These structures embryologically originate from the epidermis and can extend down through the dermis into the hypodermis.

Hair

Aside from the body regions with thick skin, e.g. the palms of our hands or the soles of our feet, the entire surface of our body has hair. The two main types of hair are the shorter and thinner "vellus" hairs (peach fuzz) and the longer and thicker "terminal" hairs. Examples of terminal hairs include the hair on your head, facial hair, eyelashes, eyebrows, pubic hair, chest/abdominal hair, nose hair and ear hair.

Hair is a keratinous filament growing out of the epidermis. It is primarily made of dead, keratinized cells. Strands of hair originate in an epidermal penetration of the dermis called the **hair follicle**. The **hair shaft** is the part of the hair not anchored to the follicle, and much of this is exposed at the skin's surface. The rest of the hair, which is anchored in the follicle, lies below the surface of the skin and is referred to as the **hair root**. The hair root ends deep in the dermis at the **hair bulb**, and includes a layer of mitotically active basal cells called the **hair matrix** (Figure 4.3.1) and (Figure 4.3.2).

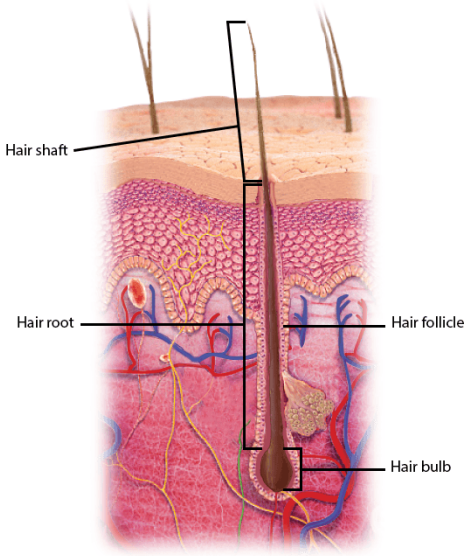

Figure 4.3.1: Hair Follicles and Hair. Hair follicles originate in the dermis and extend to to apical surface of the epidermis. The hair root and bulb are enclosed within an epithelial and connective tissue follicle, while the shaft extends beyond the surface. *(Image credit: "Hair Follicles and Hair" by Jennifer Lange is licensed under CC BY-NC-SA 4.0, modification of original by Scientific Animations.)*

Just as the basal layer of the epidermis forms the layers of epidermis that get pushed to the surface as the dead skin on the surface sheds, the basal cells of the hair bulb divide and push cells outward in the hair root and shaft as the hair grows. Hair growth begins with the production of keratinocytes by the basal cells of the hair bulb. As new cells are deposited at the hair bulb, the hair shaft is pushed through the follicle toward the surface. Keratinization is completed as the cells are pushed to the skin surface to form the shaft of hair that is externally visible. The external hair is completely dead and composed entirely of keratin. For this reason, our hair does not have sensation. Furthermore, you can cut your hair or shave without damaging the hair structure because the cut is superficial. Most chemical hair removers also act superficially; however, electrolysis and yanking both attempt

to destroy the hair bulb so hair cannot grow.

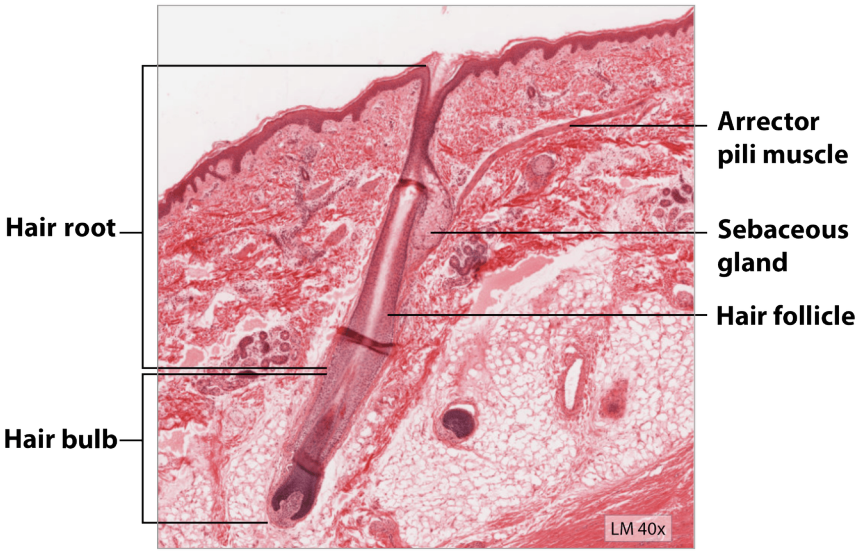

Figure 4.3.2: Hair Follicle Histology. The slide shows a cross-section of a hair follicle and its associated structures. Often the hair itself is not seen on the slide, but it would occupy the center of the follicle. *(Image credit: "Hair Follicle Histology" by Jennifer Lange, slide provided by the Regents of the University of Michigan Medical School under CC BY-NC-SA 4.0 © 2022)*

Hair serves a variety of functions, including protection, sensory input, thermoregulation, and communication. For example, hair on the head protects the skull from the sun. The hair in the nose and ears, and around the eyes (eyelashes) defends the body by trapping and excluding dust particles that may contain allergens and microbes. Hair of the eyebrows prevents sweat and other particles from dripping into and bothering the eyes. Hair also has a sensory function due to sensory innervation by a hair root plexus surrounding the base of each hair follicle. Hair is extremely sensitive to air movement or other disturbances in the environment, much more so than the skin surface. This feature is also useful for the detection of the presence of insects or other potentially damaging substances on the skin surface. Each hair root is connected to a smooth muscle called the **arrector pili** that contracts in response to nerve signals from the sympathetic nervous system, making the external hair shaft "stand up." The primary purpose for this is to trap a layer of air to add insulation. This is visible in humans as goose bumps and even more obvious in animals with a heavier coat than most humans, such as dogs and cats that raise their fur when alarmed.

Hair Growth

On average, 50 hairs are lost and replaced per day. Hair loss occurs if there is more hair shed than what is replaced and can happen due to hormonal or dietary changes. Hair loss can also result from the aging process, or the influence of hormones.

Hair Color and Texture

Similar to the skin, hair gets its color from the pigment melanin, produced by melanocytes in the hair papilla. Different hair color results from differences in the type and amounts of melanin produced, which is determined by our genetics. Two forms of melanin are found in human hair: eumelanin and pheomelanin. Eumelanin is a black/brown form of the pigment and is the dominant pigment in brown hair and black hair while pheomelanin is a red pigments that is the dominant pigment in red hair. Blond hair results when you have only a small amount of melanin in the hair. As a person ages, the melanin production decreases, and hair tends to lose its color and becomes gray and/or white.

The shape of the hair follicle determines the shape of the hair shaft: round hair follicles produce straight hair while ovoid follicles produce varying degrees of waviness or curl. Wavy hair tends to have a "D" shape to the shaft while curly hair is more oval, and the flatter the oval the curlier the hair. As a rough measure of curl, when you examine a slide from the scalp look at the angle of the hair follicle relative to the epidermal surface - the sharper the angle the more likely the hair is curly.

Glands

Glands perform the secretory functions of the integumentary system: producing and releasing sweat, pheromones, and oils. (Figure 4.3.3)

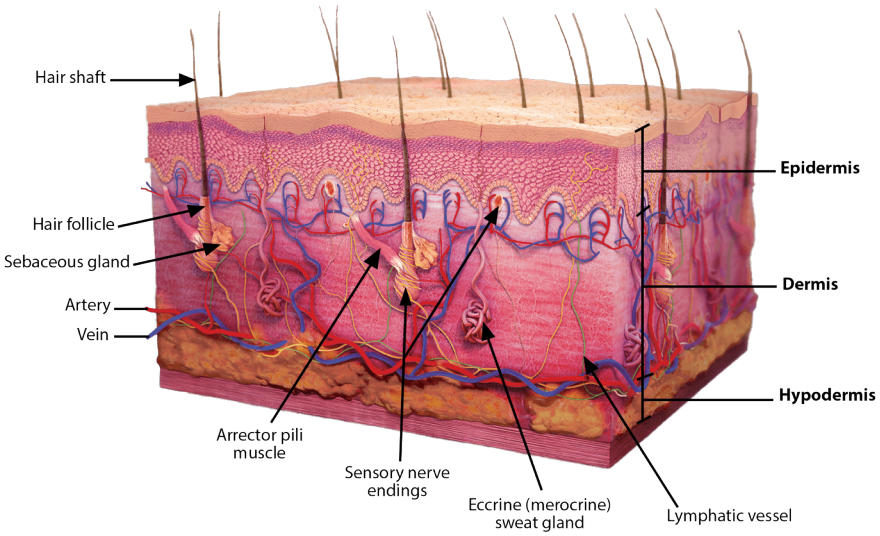

Figure 4.3.3: Accessory Organs of the Integument. Merocrine sweat glands and sebaceous glands are found in all regions of the body that have hair. *(Image credit: "Integumentary System - Accessory Organs" by Sofia Elizondo and Jennifer Lange is licensed under CC BY-NC-SA 4.0, modification of original by Scientific Animations.)*

Sweat Glands

Sweat glands develop from epidermal projections into the dermis. There are two types of sweat glands, eecrine (merocrine) sweat glands and apocrine sweat glands, each secreting slightly different products. Both types of glands are coiled tubes of cuboidal epithelial tissue that secrete their products into ducts.

An **eccrine (merocrine) sweat gland** is type of gland that produces a sweat for thermoregulation. These glands are found all over the skin's surface, but are especially abundant on the palms of the hand, the soles of the feet, and the forehead (Figure 4.3.4). They are coiled glands lying deep in the dermis, with the duct rising up to a pore on the skin surface, where the sweat is released. This type of sweat, released by exocytosis, is hypotonic and composed mostly of water, with some salt, antibodies, traces of metabolic waste, and an antimicrobial peptide. Eccrine glands are a primary component of thermoregulation in humans and thus help to maintain homeostasis.

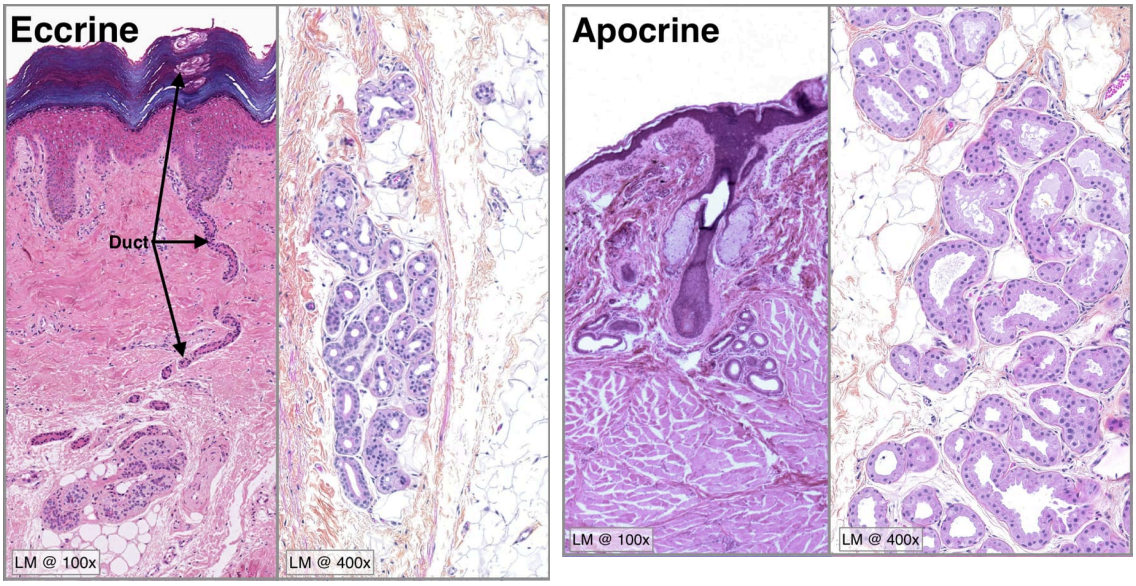

Figure 4.3.4: Eccrine and Apocrine Glands. Histologically eccrine sweat glands have fewer coils of tube with smaller lumens than apocrine sweat glands. Apocrine sweat glands are located deeper in the dermis/hypodermis than eccrine sweat glands. *(Image credit: At 400x - "Eccrine et Apocrine" by Le-prof-histo, CC BY-SA 4.0, via Wikimedia Commons; at 100x "Eccrine and Apocrine Sweat Glands" by Jennifer Lange; micrographs provided by Virginia Commonwealth University under CC-BY-NC-SA 4.0))*

An **apocrine sweat gland** is usually associated with hair follicles in densely hairy areas, such as armpits and genital regions. Apocrine sweat glands are larger than eccrine sweat glands and lie deeper in the dermis, sometimes even reaching the hypodermis, with the duct normally emptying into the hair follicle (Figure 4.3.5). In addition to water and salts, apocrine sweat includes organic compounds that make the sweat thicker and subject to bacterial decomposition and subsequent smell. The release of this sweat is under both nervous and hormonal control, and plays a role in the poorly understood human pheromone response. Most commercial antiperspirants use an aluminum-based compound as their primary active ingredient to stop sweat. When the antiperspirant enters the sweat gland duct, the aluminum-based compounds precipitate due to a change in pH and form a physical block in the duct, which prevents sweat from coming out of the pore.

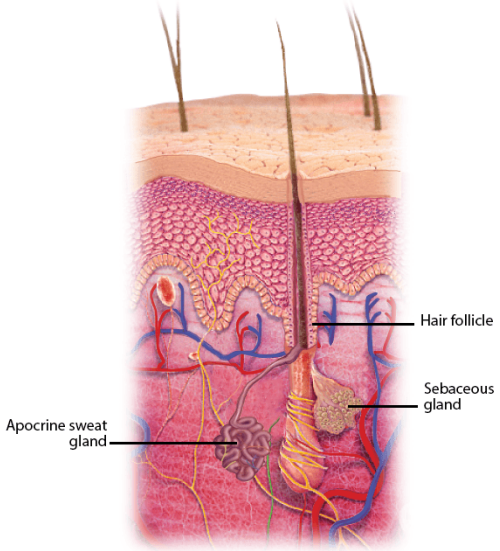

Figure 4.3.5: Glands of the Hair Follicle. Apocrine sweat glands and sebaceous glands secrete their products directly into the hair follicle. *(Image credit: "Hair Follicle and Glands" by Jennifer Lange is licensed under CC BY-NC-SA 4.0, modification of original by Scientific Animations.)*

Sebaceous Glands

A **sebaceous gland** is a type of oil gland that is found all over the body and helps to lubricate and waterproof the skin and hair. Most sebaceous glands are associated with hair follicles and the hair acts as a wick to draw the oils to the skin surface (Figure 4.3.6).

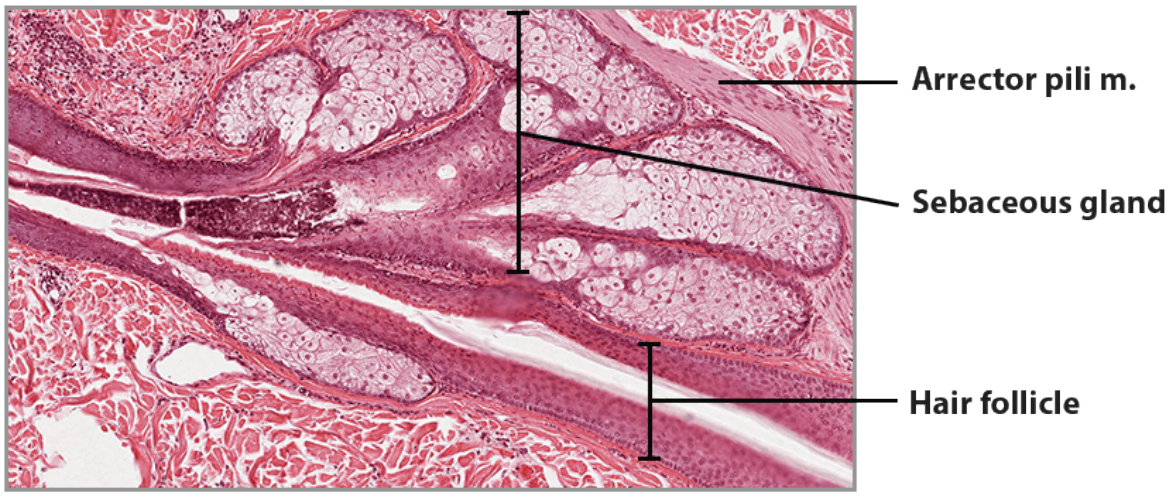

Figure 4.3.6: Sebaceous Gland. The oils from a sebaceous gland are secreted directly into the hair follicle. Histologically they appear as clusters of white circles with a stained ring (plasma membrane) on the outside and a dark central dot (nucleus). LM @ 100x. *(Image credit: "Sebaceous Gland" by Jennifer Lange; micrographs provided by Virginia Commonwealth University under CC-BY-NC-SA 4.0)*

They generate and excrete **sebum**, a mixture of lipids, onto the skin surface, thereby naturally lubricating the dry and dead layer of keratinized cells of the stratum corneum, keeping it pliable and preventing drying and cracking. The fatty acids of sebum also have antibacterial properties, and prevent water loss from the skin in low-humidity environments. The secretion of sebum is stimulated by hormones, many of which do not become active until puberty. Thus, sebaceous glands are relatively inactive during childhood.

Nails

The nail bed is a specialized structure of the epidermis that is found at the tips of our fingers and toes. The **nail body** is formed on the **nail bed**, and protects the tips of our fingers and toes as they are the farthest extremities and the parts of the body that experience the maximum mechanical stress (Figure 4.3.7). In addition, the nail body forms a back-support for picking up small objects with the fingers. The nail body is composed of densely packed dead keratinocytes. The epidermis in this part of the body has evolved a specialized structure upon which nails can form. The nail body forms at the **nail root**, which has a matrix of proliferating cells from the stratum basale that enables the nail to grow continuously. The nail bed is rich in blood vessels, making it appear pink, except at the base, where a thick layer of epithelium over the nail matrix forms a crescent-shaped region called the **lunula** (the “little moon”).

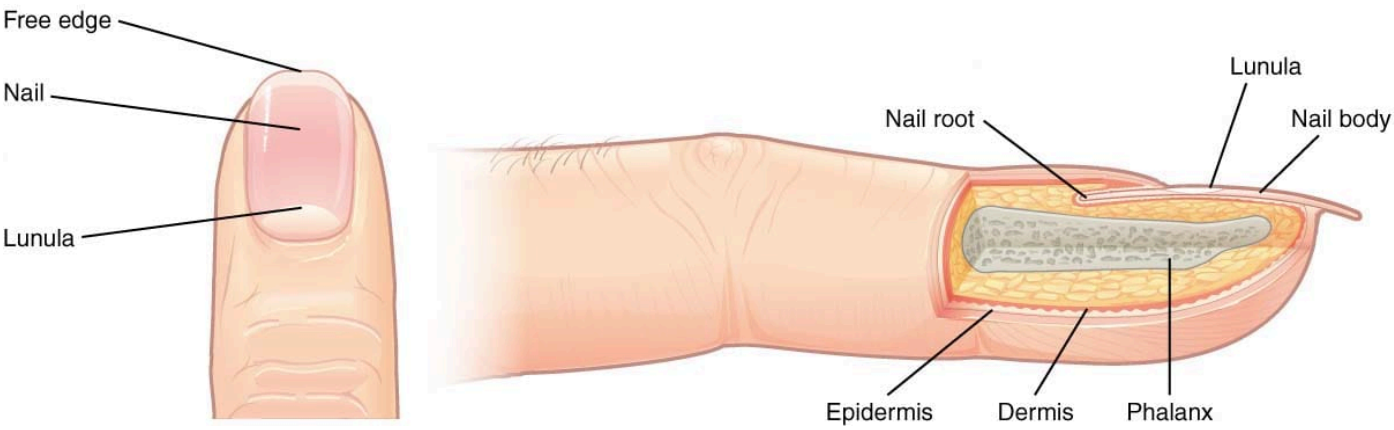

Figure 4.3.7: Nails. The nail is an accessory structure of the integumentary system. *(Image credit: "Nails" by OpenStax is licensed under CC BY 4.0, labeling modifications by Jennifer Lange.)*

Concept Review

Accessory structures of the skin include hair, nails, sweat glands, and sebaceous glands. Hair is made of dead keratinized cells, and gets its color from melanin pigments. Nails, also made of dead keratinized cells, protect the extremities of our fingers and toes from mechanical damage. Sweat glands and sebaceous glands produce sweat and sebum, respectively. Each of these fluids has a role to play in maintaining homeostasis. Sweat cools the body surface when it gets overheated and helps excrete small amounts of metabolic waste. Sebum acts as a natural moisturizer and keeps the dead, flaky, outer keratin layer healthy.

Review Questions

Query 4.3.1

This interactive element is not available in this format. Visit the link or scan the QR code to access it online.

View this Interactive Content online

Critical Thinking Questions

Query 4.3.2

This interactive element is not available in this format. Visit the link or scan the QR code to access it online.

View this Interactive Content online

Query 4.3.3

This interactive element is not available in this format. Visit the link or scan the QR code to access it online.

View this Interactive Content online

Glossary

Query 4.3.4

This interactive element is not available in this format. Visit the link or scan the QR code to access it online.

View this Interactive Content online

Contributors and Attributions

- OpenStax Anatomy & Physiology (CC BY 4.0). Access for free at https://openstax.org/books/anatomy-and-physiology

This page titled 4.3: Accessory Structures of the Skin is shared under a CC BY-NC-SA 4.0 license and was authored, remixed, and/or curated by Jennifer Lange et al..

- 4.3: Accessory Structures of the Skin by Whitney Menefee, Julie Jenks, Chiara Mazzasette, and Kim-Leiloni Nguyen is licensed CC BY 4.0.

4.4: Functions of the Integumentary System

By the end of the section, you will be able to:

- Describe the different functions of the skin and the structures that enable them
- Explain how the skin helps maintain body temperature

The skin and accessory structures perform a variety of essential functions, such as protecting the body from invasion by microorganisms, chemicals, and other environmental factors; preventing dehydration; acting as a sensory organ; modulating body temperature and electrolyte balance; and synthesizing vitamin D. The underlying hypodermis has important roles in storing fats, forming a "cushion" over underlying structures, and providing insulation from cold temperatures.

Protection

The skin protects the rest of the body from the basic elements of nature such as wind, water, and UV sunlight. It acts as a protective barrier against water loss, due to the presence of layers of keratin and glycolipids in the stratum corneum. It also is the first line of defense against abrasive activity due to contact with grit, microbes, or harmful chemicals. Sweat excreted from sweat glands deters microbes from over-colonizing the skin surface by generating dermicidin, which has antibiotic properties.

Everyday Connection

Tattoos and Piercings

The word "armor" evokes several images. You might think of a Roman centurion or a medieval knight in a suit of armor. The skin, in its own way, functions as a form of armor—body armor. It provides a barrier between your vital, life-sustaining organs and the influence of outside elements that could potentially damage them.

For any form of armor, a breach in the protective barrier poses a danger. The skin can be breached when a child skins a knee or an adult has blood drawn—one is accidental and the other medically necessary. However, you also breach this barrier when you choose to "accessorize" your skin with a tattoo or body piercing. Because the needles involved in producing body art and piercings must penetrate the skin, there are dangers associated with the practice. These include allergic reactions; skin infections; blood-borne diseases, such as tetanus, hepatitis C, and hepatitis D; and the growth of scar tissue. Despite the risk, the practice of piercing the skin for decorative purposes has become increasingly popular. According to the American Academy of Dermatology, 24 percent of people from ages 18 to 50 have a tattoo.

Watch this video about tattooing. Tattooing has a long history, dating back thousands of years ago. The dyes used in tattooing typically derive from metals. A person with tattoos should be cautious when having a magnetic resonance imaging (MRI) scan because an MRI machine uses powerful magnets to create images of the soft tissues of the body, which could react with the metals contained in the tattoo dyes.

Sensation

You can feel an ant crawling on your skin, allowing you to flick it off before it bites, because the skin, and especially the hairs projecting from hair follicles in the skin, can sense changes in the environment. The hair root plexus surrounding the base of the hair follicle senses a disturbance, and then transmits the information to the central nervous system (brain and spinal cord), which can then respond by activating the skeletal muscles of your eyes to see the ant and the skeletal muscles of the body to act against the ant.

The skin acts as a sense organ because the epidermis, dermis, and the hypodermis contain specialized sensory nerve structures that detect touch, surface temperature, and pain. These receptors are more concentrated on the tips of the fingers, which are most sensitive to touch, especially the **Meissner corpuscle** (tactile corpuscle) (Figure 4.4.1), which responds to light touch, and

the **Pacinian corpuscle** (lamellated corpuscle), which responds to vibration. Merkel cells, seen scattered in the stratum basale, are also touch receptors. In addition to these specialized receptors, there are sensory nerves connected to each hair follicle, pain and temperature receptors scattered throughout the skin, and motor nerves innervating the arrector pili muscles and glands. This rich innervation helps you sense your environment and react accordingly.

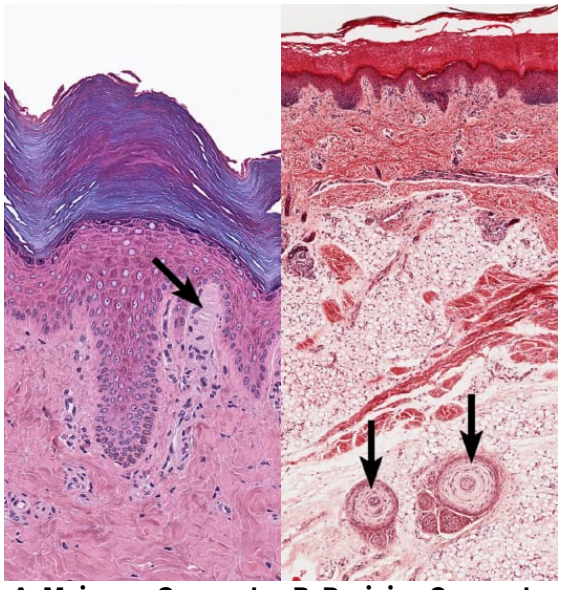

Figure 4.4.1: Sensory Receptors in Skin. A) A Meissner corpuscle (arrow) is a light-touch receptor located in a dermal papilla adjacent to the basement membrane and stratum basale of the overlying epidermis. LM @200x. B) Pacinian corpuscles (arrows) detect pressure and vibration and are located deep in the dermis or in the hypodermis. LM @100x. *(Image credit: micrographs provided by Virginia Commonwealth University under CC-BY-NC-SA 4.0)*

Thermoregulation

The integumentary system helps regulate body temperature through its tight association with the sympathetic nervous system, the division of the nervous system involved in our fight-or-flight responses. The sympathetic nervous system is continuously monitoring body temperature and initiating appropriate motor responses. Recall that sweat glands, accessory structures to the skin, secrete water, salt, and other substances to cool the body when it becomes warm. Even when the body does not appear to be noticeably sweating, approximately 500 mL of sweat (insensible perspiration) are secreted a day. If the body becomes excessively warm due to high temperatures, vigorous activity (Figure 4.4.2), or a combination of the two, sweat glands will be stimulated by the sympathetic nervous system to produce large amounts of sweat, as much as 0.7 to 1.5 L per hour for an active person. When the sweat evaporates from the skin surface, the body is cooled as body heat is dissipated.

In addition to sweating, arterioles (small blood vessels) in the dermis dilate so that excess heat carried by the blood can dissipate through the skin and into the surrounding environment (Figure 4.4.2). This accounts for the skin redness that many people experience when exercising as the red pigment of the blood more visibly contributes to skin tone.

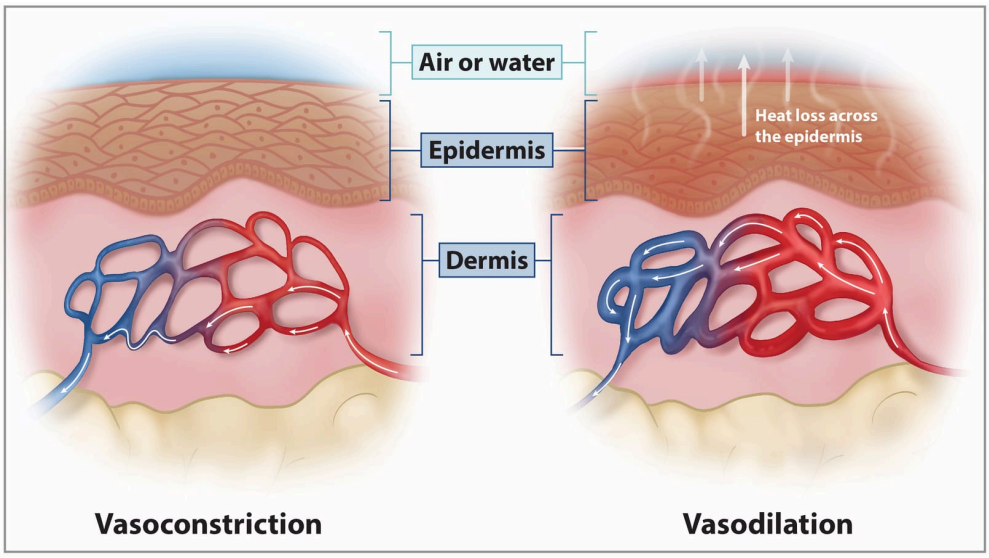

Figure 4.4.2: Thermoregulation. During strenuous physical activities, such as skiing or running, the dermal blood vessels dilate and sweat secretion increases. These mechanisms prevent the body from overheating. In contrast, the dermal blood vessels constrict to minimize heat loss in response to low temperatures. *(Image credit: "Thermoregulation" by BlueLink is licensed under CC BY-NC 4.0 with notification of the original authors.)*

Conversely, when body temperatures drop, the arterioles constrict to minimize heat loss, particularly in the ends of the digits and tip of the nose. This reduced circulation can result in the skin taking on a paler hue. Although the temperature of the skin drops as a result, passive heat loss is prevented, and internal organs and structures remain warm. If the temperature of the skin drops too much (such as environmental temperatures below freezing), the conservation of body core heat can result in the skin actually freezing, a condition called frostbite.

Secretion

Have you ever noticed that your skin is gritty or salty after strenuous exercise or on a very hot day? While the composition of your sweat is 99% water, the 1% that is comprised of salts, ammonia and urea can accumulate during perfuse sweating. A comprehensive review of studies on sweat composition concluded that this excretion pathway is very minor compared to that of the kidneys and gastrointestinal tract and that in healthy individuals the amount and composition of sweat are not regulated by homeostatic mechanisms other than thermoregulation. Certain diseases, such as cystic fibrosis, result in high NaCl concentrations in sweat and put the individual at risk for salt imbalances during prolonged periods of heavy sweating.

Vitamin D Synthesis

The epidermal layer of human skin synthesizes the inactive form of **vitamin D** when exposed to UV radiation, which is eventually converted to calcitriol (the active chemical form of the vitamin) in the kidneys (Figure 4.4.3). Vitamin D is essential for normal absorption of calcium and phosphorus, which are required for healthy bones. The absence of sun exposure can lead to a lack of vitamin D in the body, leading to a condition called **rickets**, a painful condition in children where the bones are misshapen due to a lack of calcium, causing bowleggedness. Elderly individuals who suffer from vitamin D deficiency can develop a condition called osteomalacia, a softening of the bones. In present day society, vitamin D is added as a supplement to many foods, including milk and orange juice, compensating for the need for sun exposure.

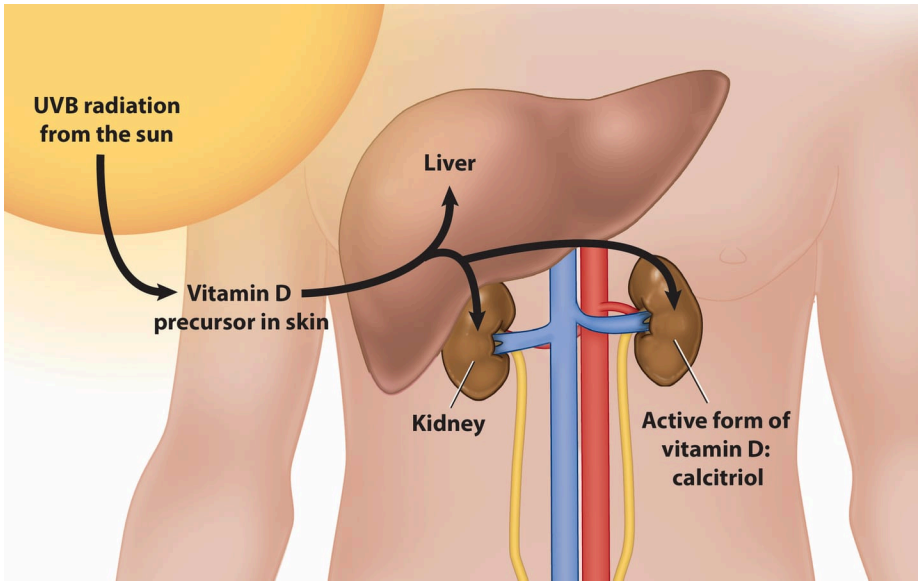

Figure 4.4.3: Vitamin D Synthesis: Humans cannot produce adequate amounts of vitamin D without exposure of the skin to the UVB light from the sun. *(Image credit: "Vitamin D Synthesis" by BlueLink is licensed under CC BY-NC 4.0 with notification of the original authors.)*

In addition to its essential role in bone health, vitamin D is essential for general immunity against bacterial, viral, and fungal infections. Recent studies are also finding a link between insufficient vitamin D and cancer.

AGING AND THE.....

Integumentary System

All systems in the body accumulate subtle and some not-so-subtle changes as a person ages. Among these changes are reductions in cell division, metabolic activity, blood circulation, hormonal levels, and muscle strength (Figure 4.4.3). In the skin, these changes are reflected in decreased mitosis in the stratum basale, leading to a thinner epidermis. The dermis, which is responsible for the elasticity and resilience of the skin, also exhibits a reduced ability to regenerate, which leads to slower wound healing. The hypodermis, with its fat stores, loses structure due to the reduction and redistribution of fat, which in turn contributes to the thinning and sagging of skin.

Figure 4.4.3: A grandmother teases her granddaughter. Skin changes are among the most visible signs of aging. The skin of infants and young children is usually characterized as smoother and softer than in adults. *(Image credit: "Japanese-American Friendship Festival 150919-F-WE773-006" by Staff Sgt. Cody Ramirez is in the public domain, via Wikimedia Commons.)*

The accessory structures also have lowered activity, generating thinner hair and nails, and reduced amounts of sebum and sweat. A reduced sweating ability can cause some elderly to be intolerant to extreme heat. Other cells in the skin, such as melanocytes and dendritic cells, also become less active, leading to a paler skin tone and lowered immunity. Wrinkling of the skin occurs due to breakdown of its structure, which results from decreased collagen and elastin production in the dermis, weakening of muscles lying under the skin, and the inability of the skin to retain adequate moisture.

Many anti-aging products can be found in stores today. In general, these products try to rehydrate the skin and thereby fill out the wrinkles, and some stimulate skin growth using hormones and growth factors. Additionally, invasive techniques include collagen injections to plump the tissue and injections of BOTOX® (the name brand of the botulinum neurotoxin) that paralyze the muscles that crease the skin and cause wrinkling.

Concept Review

The skin plays important roles in protection, sensing stimuli, thermoregulation, and vitamin D synthesis. It is the first layer of defense to prevent dehydration, infection, and injury to the rest of the body. Sweat glands in the skin allow the skin surface to cool when the body gets overheated. Thermoregulation is also accomplished by the dilation or constriction of heat-carrying blood vessels in the skin. Immune cells present among the skin layers patrol the areas to keep them free of foreign materials. Fat stores in the hypodermis aid in both thermoregulation and protection. Finally, the skin plays a role in the synthesis of vitamin D, which is necessary for our well-being but not easily available in natural foods.

Review Questions

Query 4.4.1

This interactive element is not available in this format. Visit the link or scan the QR code to access it online.

View this Interactive Content online

Critical Thinking Questions

Query 4.4.2

This interactive element is not available in this format. Visit the link or scan the QR code to access it online.

View this Interactive Content online

Query 4.4.3

This interactive element is not available in this format. Visit the link or scan the QR code to access it online.

View this Interactive Content online

Glossary

Query 4.4.4

This interactive element is not available in this format. Visit the link or scan the QR code to access it online.

View this Interactive Content online

Contributors and Attributions

- OpenStax Anatomy & Physiology (CC BY 4.0). Access for free at https://openstax.org/books/anatomy-and-physiology

This page titled 4.4: Functions of the Integumentary System is shared under a CC BY-NC-SA 4.0 license and was authored, remixed, and/or curated by Jennifer Lange et al..

- 4.4: Functions of the Integumentary System by Whitney Menefee, Julie Jenks, Chiara Mazzasette, and Kim-Leiloni Nguyen is licensed CC BY 4.0.

4.5: Diseases, Disorders, and Injuries of the Integumentary System

By the end of the section, you will be able to:

- Describe several different diseases and disorders of the skin
- Describe the effect of injury to the skin and the process of healing

The integumentary system is susceptible to a variety of diseases, disorders, and injuries. These range from annoying but relatively benign bacterial or fungal infections that are categorized as disorders, to skin cancer and severe burns, which can be fatal. In this section, you will learn several of the most common skin conditions.

Diseases

One of the most talked about diseases is skin cancer. Cancer is a broad term that describes diseases caused by abnormal cells in the body dividing uncontrollably. Most cancers are identified by the organ or tissue in which the cancer originates. One common form of cancer is skin cancer. The Skin Cancer Foundation reports that one in five Americans will experience some type of skin cancer in their lifetime. The degradation of the ozone layer in the atmosphere and the resulting increase in exposure to UV radiation has contributed to its rise. Overexposure to UV radiation damages DNA, which can lead to the formation of cancerous lesions. Although melanin offers some protection against DNA damage from the sun, often it is not enough. The fact that cancers can also occur on areas of the body that are normally not exposed to UV radiation suggests that there are additional factors that can lead to cancerous lesions.

In general, cancers result from an accumulation of DNA mutations. These mutations can result in cell populations that do not die when they should and uncontrolled cell proliferation that leads to tumors. Although many tumors are benign (harmless), some produce cells that can mobilize and establish tumors in other organs of the body; this process is referred to as **metastasis**. Cancers are characterized by their ability to metastasize.

Basal Cell Carcinoma

Basal cell carcinoma is a form of cancer that affects the mitotically active stem cells in the stratum basale of the epidermis. It is the most common of all cancers that occur in the United States and is frequently found on the head, neck, arms, and back, which are areas that are most susceptible to long-term sun exposure. Although UV rays are the main culprit, exposure to other agents, such as radiation and arsenic, can also lead to this type of cancer. Wounds on the skin due to open sores, tattoos, burns, etc. may be predisposing factors as well. Basal cell carcinomas start in the stratum basale and usually spread along this boundary. At some point, they begin to grow toward the surface and become an uneven patch, bump, growth, or scar on the skin surface (Figure 4.5.1). Like most cancers, basal cell carcinomas respond best to treatment when caught early. Treatment options include surgery, freezing (cryosurgery), and topical ointments (Mayo Clinic 2012).

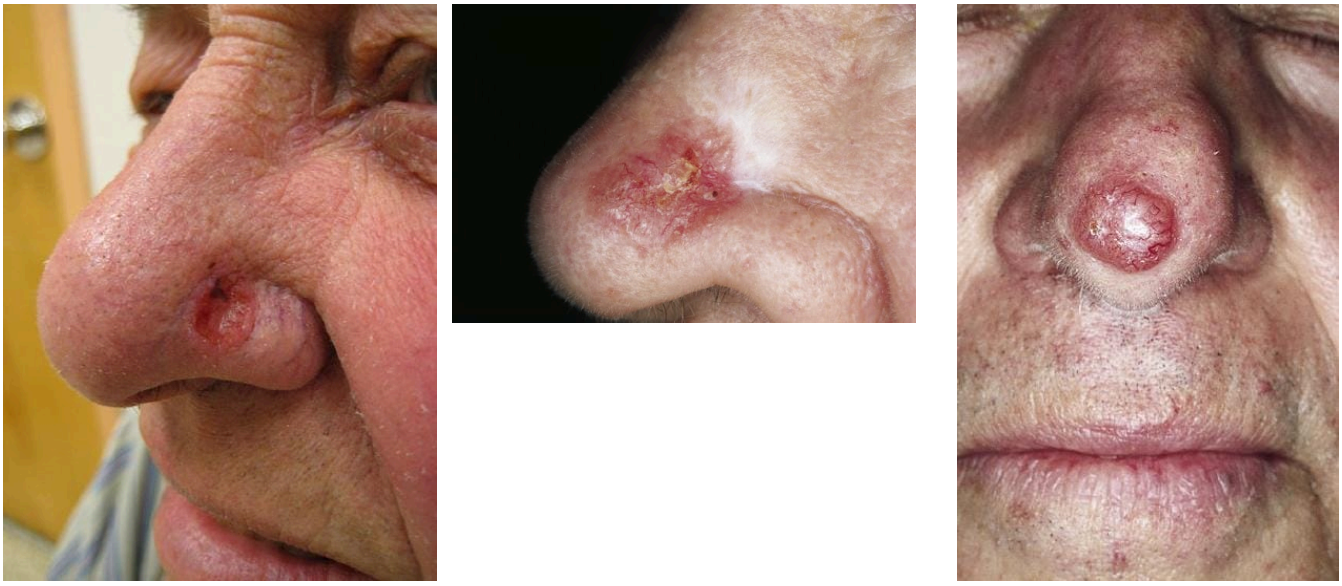

Figure 4.5.1: Basal Cell Carcinoma. Basal cell carcinoma can take several different forms from slightly sunken, to flat and scaly, to nodular.

Squamous Cell Carcinoma

Cutaneous squamous cell carcinoma (CSCC) is a cancer that affects the keratinocytes of the stratum spinosum and presents as lesions commonly found on the scalp, ears, and hands (Figure 4.5.2). It is the second most common skin cancer. The American Cancer Society reports that two of ten (20%) skin cancers are squamous cell carcinomas, and it is more aggressive than basal cell carcinoma. If not removed, these carcinomas can metastasize. Surgery and radiation are used to cure squamous cell carcinoma.

Figure 4.5.2: Cutaneous Squamous Cell Carcinoma. cSCCs can appear as scaly red patches, open sores, rough, thickened or wart-like skin, or raised growths with a central depression that may crust over, itch or bleed.

Melanoma

A **melanoma** is a cancer characterized by the uncontrolled growth of melanocytes, the pigment-producing cells in the epidermis. Typically, a melanoma develops from a mole. It is the most fatal of all skin cancers, as it is highly metastatic and can be difficult to detect before it has spread to other organs. Melanomas usually appear as asymmetrical brown and black patches with uneven borders and a raised surface (Figure 4.5.3). Treatment typically involves surgical excision and immunotherapy.

Figure 4.5.3: Melanoma. Melanomas typically present as large brown and/or black patches with uneven borders and a raised surface.

Doctors often give their patients the following ABCDE mnemonic to help with the diagnosis of early-stage melanoma. If you observe a mole on your body displaying these signs, consult a doctor.

- **A**symmetry – the two sides are not symmetrical
- **B**orders – the edges are irregular in shape
- **C**olor – the color is varied shades of brown or black
- **D**iameter – it is larger than 6 mm (0.24 in)
- **E**volving – its shape has changed

Some specialists cite the following additional signs for the most serious form, nodular melanoma:

- **E**levated – it is raised on the skin surface
- **F**irm – it feels hard to the touch
- **G**rowing – it is getting larger

Having lighter skin color is a major risk factor for melanoma. According to the American Cancer Society (January 16, 2025) the lifetime risk of getting melanoma is about 3% (1 in 33) for White people, 0.1% (1 in 1,000) for Black people, and 0.5% (1 in 200) for Hispanic people. Melanoma is the deadliest skin cancer and represents about 5% of all cancer diagnoses in the United States each year. While people of color (POC) are diagnosed with melanoma less often, they are up to four times more likely to be diagnosed with advanced melanoma due to delay in detection or to presentation. When melanoma is diagnosed at a more advanced stage, treatment is more difficult. This makes POC 1.5 times more likely to die from the disease (Gupta, Bharadwaj, and Mehrotra, 2016).

YouTube Video

This interactive element is not available in this format. Visit the link or scan the QR code to access it online.

View this YouTube Video online

Skin Disorders

Three common skin disorders are eczema, acne, and psoriasis. Eczema is an inflammatory condition and occurs in individuals

of all ages. Acne involves the clogging of pores, which can lead to infection and inflammation, and is often seen in adolescents. Other disorders, not discussed here, include seborrheic dermatitis (on the scalp), cold sores, impetigo, scabies, hives, and warts.

Eczema

Eczema is an allergic reaction that manifests as dry, itchy patches of skin that resemble rashes (Figure 4.5.4). It may be accompanied by swelling of the skin, flaking, and in severe cases, bleeding. Many who suffer from eczema have antibodies against dust mites in their blood, but the link between eczema and allergy to dust mites has not been proven. Symptoms are usually managed with moisturizers, corticosteroid creams, and immunosuppressants.

Figure 4.5.4: Eczema. Eczema is a common skin disorder that presents as a red, flaky rash.

Acne

Acne is a skin disturbance that typically occurs on areas of the skin that are rich in sebaceous glands (face and back). It is most common along with the onset of puberty due to associated hormonal changes, but can also occur in infants and continue into adulthood. Hormones, such as androgens, stimulate the release of sebum. An overproduction and accumulation of sebum along with keratin can block hair follicles. This blockage of the pore and build up of materials allows acne-causing bacteria (*Propionibacterium* and *Staphylococcus*) to proliferate causing an infection, which can lead to redness and potential scarring due to the natural wound healing process (Figure 4.5.5). The plug is initially white, due to the accumulation of pus, which is a combination of the sebum, keratin, and dead white blood cells trying to fight off the infection. The sebum, when oxidized by exposure to air, turns black.

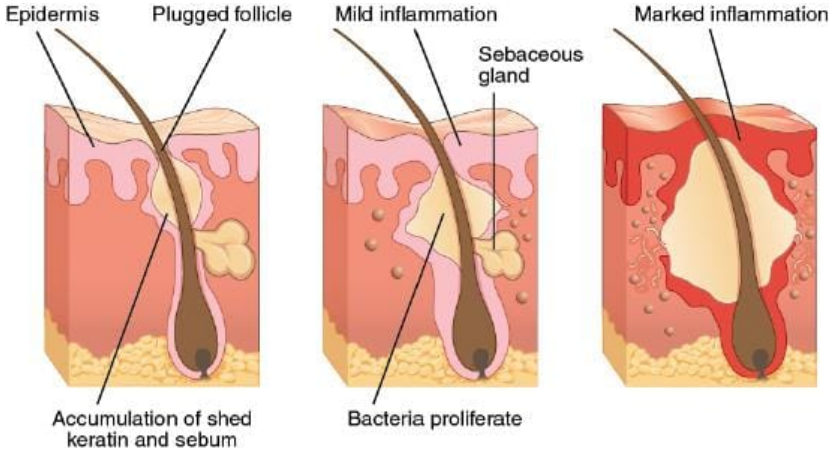

Figure 4.5.5: Acne. Acne is a result of over-productive sebaceous glands, which leads to formation of blackheads and inflammation of the skin.

Psoriasis

Keratinocyte proliferation, maturation, and shedding are critical processes in developing and maintaining healthy skin. In the skin's normal cycle, keratinocytes are produced in the stratum basale, migrate superficially through multiple strata, and eventually shed off at the surface. In healthy skin this process takes approximately 14 days, with some areas going faster and others slower. Keratinocyte proliferation disorders are skin disorders characterized by excessive and rapid keratinocyte production. Psoriasis, the most common condition in this group, is a chronic autoimmune disorder that leads to a seven-fold increase in the number of cycling epidermal cells. In the most common form, plaque psoriasis, patches of skin become scaly and inflamed. The most common locations for these plaques are on the scalp, elbows, or knees, but other parts of the body can be affected as well. In pustular psoriasis pus-filled bumps surrounded by red skin appear, typically on the hands and feet. The cause of psoriasis is unknown, but it involves a mix of genetics and environmental factors.

A. plaque psoriasis

B. plaque psoriasis

C. pustular psoriasis

Figure 4.5.6: Psoriasis. Excessive production of keratinocytes can appear as white, dry, scaley plaques (A), raised red patches (B), or raised, fluid-filled bumps. *(Image credits: (A) "Psoriasis" by James Heilman, MD is licensed under CC BY-SA 3.0; (B) "Psoriasis Plaque" by Eisfelder is licensed under CC BY-SA 3.0; (C) "Psoriasis pustuleux digital posterieur" by Pangolin06 is licensed under CC BY-SA 4.0.*

CAREER CONNECTION

Dermatologist

Have you ever had a skin rash that did not respond to over-the-counter creams, or a mole that you were concerned about? Dermatologists help patients with these types of problems and more, on a daily basis. Dermatologists are medical doctors who specialize in diagnosing and treating skin disorders. Like all medical doctors, dermatologists earn a medical degree and then complete several years of residency training. In addition, dermatologists may then participate in a dermatology fellowship or complete additional, specialized training in a dermatology practice. If practicing in the United States, dermatologists must pass the United States Medical Licensing Exam (USMLE), become licensed in their state of practice, and be certified by the American Board of Dermatology.

Most dermatologists work in a medical office or private-practice setting. They diagnose skin conditions and rashes, prescribe oral and topical medications to treat skin conditions, and may perform simple procedures, such as mole or wart removal. In addition, they may refer patients to an oncologist if skin cancer that has metastasized is suspected. Recently, cosmetic procedures have also become a prominent part of dermatology. Botox injections, laser treatments, and collagen and dermal filler injections are popular among patients, hoping to reduce the appearance of skin aging.

Dermatology is a competitive specialty in medicine. Limited openings in dermatology residency programs mean that many medical students compete for a few select spots. Dermatology is an appealing specialty to many prospective doctors, because unlike emergency room physicians or surgeons, dermatologists generally do not have to work excessive hours or be "on-call" weekends and holidays. Moreover, the popularity of cosmetic dermatology has made it a growing field with many lucrative opportunities. It is not unusual for dermatology clinics to market themselves exclusively as cosmetic dermatology centers, and for dermatologists to specialize exclusively in these procedures.

Consider visiting a dermatologist to talk about why he or she entered the field and what the field of dermatology is like.

Injuries

Because the skin is the part of our bodies that meets the world most directly, it is especially vulnerable to injury. Injuries include burns and wounds, and the healing process can cause bothersome scars and calluses. They can be caused by sharp objects, heat, or excessive pressure or friction to the skin.

Skin injuries set off a healing process that occurs in several overlapping stages. The first step to repairing damaged skin is the formation of a blood clot that helps stop the flow of blood and scabs over with time. Many different types of cells are involved in wound repair, especially if the surface area that needs repair is extensive. Before the basal stem cells of the stratum basale can recreate the epidermis, fibroblasts mobilize and divide rapidly to repair the damaged tissue by collagen deposition, forming granulation tissue. Blood capillaries follow the fibroblasts and help increase blood circulation and oxygen supply to the area. Immune cells, such as macrophages, roam the area and engulf any foreign matter to reduce the chance of infection.

Burns

A burn results when the skin is damaged by intense heat, radiation, electricity, or chemicals. The damage results in the death of skin cells, which can lead to a massive loss of fluid. Dehydration, electrolyte imbalance, and renal and circulatory failure follow, which can be fatal. Burn patients are treated with intravenous fluids to offset dehydration, as well as intravenous nutrients that enable the body to repair tissues and replace lost proteins. Another serious threat to the lives of burn patients is infection. Burned skin is extremely susceptible to bacteria and other pathogens, due to the loss of protection by intact layers of skin.

Burns are sometimes measured in terms of the size of the total surface area affected. This is referred to as the “rule of nines,” which associates specific anatomical areas with a percentage that is a factor of nine (Figure 4.5.6). Burns are also classified by the degree of their severity. A **first-degree burn** is a superficial burn that affects only the epidermis. Although the skin may be painful and swollen, these burns typically heal on their own within a few days. Mild sunburn fits into the category of a first-degree burn. A **second-degree burn** goes deeper and affects both the epidermis and a portion of the dermis. These burns result in swelling and a painful blistering of the skin. It is important to keep the burn site clean and sterile to prevent infection. If this is done, the burn will heal within several weeks. A **third-degree burn** fully extends into the epidermis and dermis, destroying the tissue and affecting the nerve endings and sensory function. These are serious burns that may appear white, red, or black; they require medical attention and will heal slowly without it. A **fourth-degree burn** is even more severe, affecting the underlying muscle and bone. Oddly, third and fourth-degree burns are usually not as painful because the nerve endings themselves are damaged. Full-thickness burns cannot be repaired by the body, because the local tissues used for repair are damaged and require excision (debridement), or amputation in severe cases, followed by grafting of the skin from an unaffected part of the body, or from skin grown in tissue culture for grafting purposes.

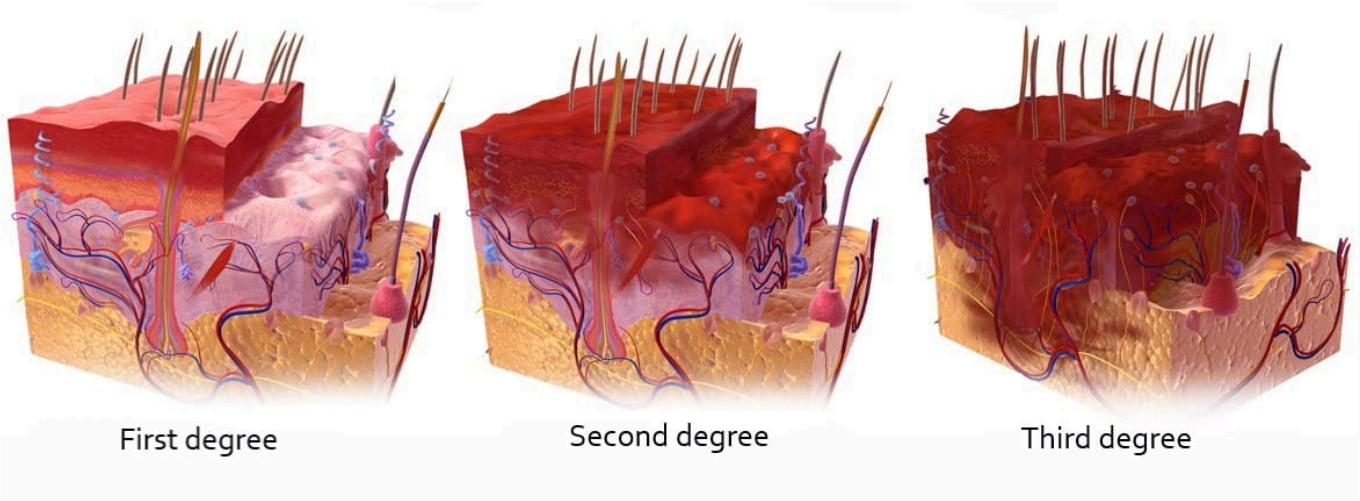

Figure 4.5.6: Degree of a Burn. The severity of a burn is classified according to how deep into the integument that it penetrates.

Scars and Keloids

Most cuts or wounds, with the exception of ones that only scratch the surface (the epidermis), lead to scar formation. A **scar** is collagen-rich skin formed after the process of wound healing that differs from normal skin. (Figure 4.5.7) Scarring occurs in cases in which there is repair of skin damage, but the skin fails to regenerate the original skin structure. Fibroblasts generate scar tissue in the form of collagen, and the bulk of repair is due to the basket-weave pattern generated by collagen fibers and does not result in regeneration of the typical cellular structure of skin. Instead, the tissue is fibrous in nature and does not allow for the regeneration of accessory structures, such as hair follicles, sweat glands, or sebaceous glands.

Figure 4.5.7: Cutaneous Scar: Scars are pink for a few months as blood vessels are abundant as collagen is forming. In time the blood supply will decrease and the scar will become white.

Sometimes, there is an overproduction of scar tissue, because the process of collagen formation does not stop when the wound is healed; this results in the formation of a raised or hypertrophic scar called a **keloid**. In contrast, scars that result from acne and chickenpox have a sunken appearance and are called atrophic scars.

Scarring of skin after wound healing is a natural process and does not need to be treated further. Application of mineral oil and lotions may reduce the formation of scar tissue. However, modern cosmetic procedures, such as dermabrasion, laser treatments, and filler injections have been invented as remedies for severe scarring. All of these procedures try to reorganize the structure of the epidermis and underlying collagen tissue to make it look more natural.

Bedsores and Stretch Marks

Skin and its underlying tissue can be affected by excessive pressure. One example of this is called a **bedsore**. Bedsores, also called decubitis ulcers, are caused by constant, long-term, unrelieved pressure on certain body parts that are bony, reducing blood flow to the area and leading to necrosis (tissue death). Bedsores are most common in elderly patients who have debilitating conditions that cause them to be immobile. Most hospitals and long-term care facilities have the practice of turning the patients every few hours to prevent the incidence of bedsores. If left untreated by removal of necrotized tissue, bedsores can be fatal if they become infected.

The skin can also be affected by pressure associated with rapid growth. A **stretch mark** results when the dermis is stretched beyond its limits of elasticity, as the skin stretches to accommodate the excess pressure. Stretch marks usually accompany rapid weight gain during puberty and pregnancy. They initially have a reddish hue, but lighten over time. (Figure 4.5.8) Other than for cosmetic reasons, treatment of stretch marks is not required. They occur most commonly over the hips and abdomen.

Figure 4.5.8: Stretch Marks. Stretch marks on the middle of the back on a 13 year old male that are about a day old.

Corns and Calluses

When you wear shoes that do not fit well and are a constant source of abrasion on your toes, you tend to form a **callus** or a **corn** at the point of contact. (Figure 4.5.9) This occurs because the basal stem cells in the stratum basale are triggered to divide more often to increase the thickness of the skin at the point of abrasion to protect the rest of the body from further damage. This is an example of a minor or local injury, and the skin manages to react and treat the problem independent of the rest of the body. Calluses can also form on your fingers if they are subject to constant mechanical stress, such as long periods of yard work, writing, playing string instruments, or video games. A corn is a specialized form of callus. Corns form from abrasions on the skin that result from an elliptical-type motion.

- **Corns** are deeper than calluses and have swollen skin surrounding a hard center. They can be painful when pressed. They occur on the feet: hard corns usually form on the superior surface of the toes or the lateral edge of the small toe; soft corns generally form between the toes.

A. Corns

B. Calluses

Figure 4.5.9: Corns and Calluses. Both corns and calluses are caused by friction and result in the laying down of additional cell layers. The best treatment is to adjust your activities and/or footwear! Calluses could be a benefit for those working with tools or regularly walking long distances.

- **Calluses** tend to develop on pressure spots and build up to protect that spot damage. The most common locations are the heels, the balls of the feet, the big toe, and the palmar side of the hands. They vary in size and shape and are often larger than corns. They tend to not be painful unless they also have a blister within them.

Concept Review

Skin cancer is a result of damage to the DNA of skin cells, often due to excessive exposure to UV radiation. Basal cell carcinoma and squamous cell carcinoma are highly curable, and arise from cells in the stratum basale and stratum spinosum, respectively. Melanoma is the most dangerous form of skin cancer, affecting melanocytes, which can spread/metastasize to other organs. Burns are an injury to the skin that occur as a result of exposure to extreme heat, radiation, or chemicals. First-degree and second-degree burns usually heal quickly, but third-degree burns can be fatal because they penetrate the full thickness of the skin. Scars occur when there is repair of skin damage. Fibroblasts generate scar tissue in the form of collagen, which forms a basket-weave pattern that looks different from normal skin.

Bedsores and stretch marks are the result of excessive pressure on the skin and underlying tissue. Bedsores are characterized by necrosis of tissue due to immobility, whereas stretch marks result from rapid growth. Eczema is an allergic reaction that manifests as a rash, and acne results from clogged sebaceous glands. Eczema and acne are usually long-term skin conditions that may be treated successfully in mild cases. Calluses and corns are the result of abrasive pressure on the skin.

Review Questions

Query 4.5.1

This interactive element is not available in this format. Visit the link or scan the QR code to access it online.

View this Interactive Content online

Critical Thinking Questions

Query 4.5.2

This interactive element is not available in this format. Visit the link or scan the QR code to access it online.

View this Interactive Content online

Query 4.5.3

This interactive element is not available in this format. Visit the link or scan the QR code to access it online.

View this Interactive Content online

Glossary

Query 4.5.4

This interactive element is not available in this format. Visit the link or scan the QR code to access it online.

View this Interactive Content online

Contributors and Attributions

- OpenStax Anatomy & Physiology (CC BY 4.0). Access for free at https://openstax.org/books/anatomy-and-physiology

Figure	Attribution(s)
4.5.1	A. Basal Cell Carcinoma by James Heilman, MD is licensed under CC BY 3.0, via Wikimedia Commons. B. Scarlike Basal Cell Carcinoma by Michael Sand, Daniel Sand, Christina Thrandorf, Volker Paech, Peter Altmeyer, and Falk G Bechara is licensed under CC BY 2.5, via Wikimedia Commons. C. Basal Cell Carcinoma by Michael Sand, Daniel Sand, Christina Thrandorf, Volker Paech, Peter Altmeyer, and Falk G Bechara is lisenced under CC BY 2.5, via Wikimedia Commons.
4.5.2	A. Squamous Cell Carcinoma by Kelly Nelson (Photographer), Public domain, via Wikimedia Commons. B. "Squamous Cell Carcinoma" by OpenStax and the National Cancer Institute is licensed under CC BY 4.0. C. Spinaliom by Klaus D. Peter is licensed under CC BY 3.0 DE, via Wikimedia Commons. Thank you for your email to klausdpeter@gmail.com in case of using this picture.
4.5.3	A. Nodular Melanoma by 0x6adb015, CC BY-SA 3.0, via Wikimedia Commons B. Melanoma by Klaus D. Peter is licensed under CC BY 3.0 DE, via Wikimedia Commons C. Lintigo Maligna Melanoma by Omar Bari and Philip R. Cohen is licensed under CC BY 3.0, via Wikimedia Commons
4.5.4	"Eczema-arms" by Jambula is in the Public Domain, CC 0.
4.5.5	"Acne Formation" by OpenStax is licensed under CC BY 4.0.
4.5.6	"1st, 2nd, and 3rd Degree Burns" by BruceBlaus, is licensed under CC BY-SA 4.0, via Wikimedia Commons.
4.5.7	"Scar on Arm" by Svdmolen is licensed under CC BY-SA 3.0, via Wikimedia Commons.
4.5.8	"Stretch Marks" by Josephrockz4, Public domain, via Wikimedia Commons.
4.5.9	A. "Corns" by Marionette is licensed under CC BY-SA 3.0, via Wikimedia Commons; B. "Calluses" by Jmarchn is licensed under CC BY-SA 3.0, via Wikimedia Commons.

This page titled 4.5: Diseases, Disorders, and Injuries of the Integumentary System is shared under a CC BY-NC-SA 4.0 license and was authored, remixed, and/or curated by Jennifer Lange et al..

- 4.5: Diseases, Disorders, and Injuries of the Integumentary System by Whitney Menefee, Julie Jenks, Chiara Mazzasette, and Kim-Leiloni Nguyen is licensed CC BY 4.0.

4.6: Anatomical Atlas - Integumentary System

A compendium of anatomical images: slides, models, and/or cadavers.

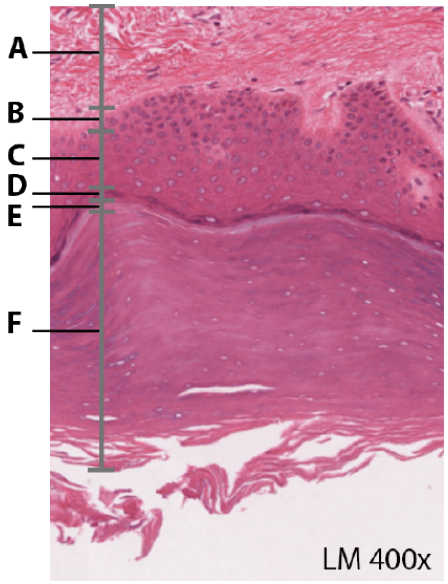

Image credit

"Thick Skin Histology - Atlas" by Jennifer Lange, slide provided by the Regents of the University of Michigan Medical School under CC BY-NC-SA 4.0 © 2022.

Answer Key (click to show/hide answers)

A - dermis

B - stratum basale

C - stratum spinosum

D - stratum granulosum

E - stratum lucidum

F - stratum corneum

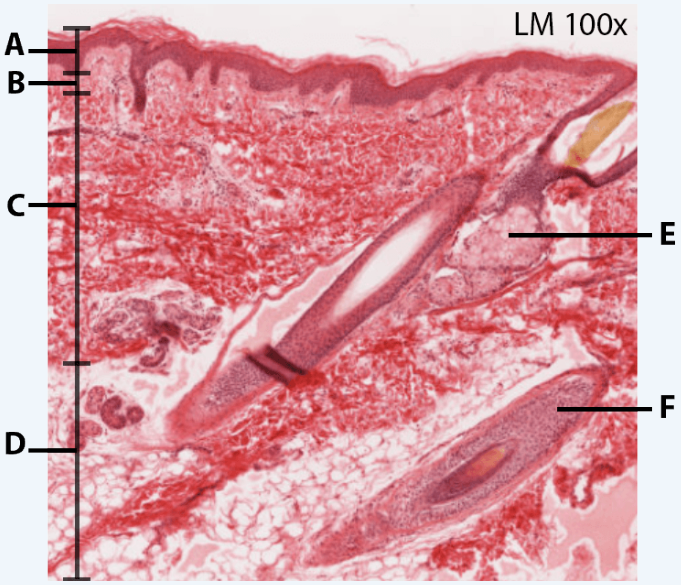

Image credit

"Thin Skin Histology 1 - Atlas" by Jennifer Lange, slide provided by the Regents of the University of Michigan Medical School under CC BY-NC-SA 4.0 © 2022.

Answer Key (click to show/hide answers)

A - epidermis

B - papillary dermis

C - reticular dermis

D - hypodermis

E - sebaceous gland

F - hair follicle

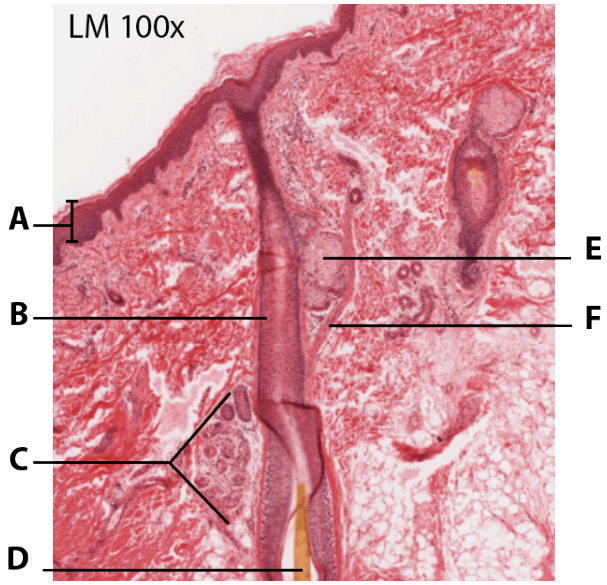

Image credit

"Thin Skin Histology 2 - Atlas" by Jennifer Lange, slide provided by the Regents of the University of Michigan Medical School under CC BY-NC-SA 4.0 © 2022.

Answer Key (click to show/hide answers)

A - epidermis

B - hair follicle

C - eccrine sweat gland (merocrine sweat gland)

D - hair (hair shaft)

E - sebaceous gland

F - arrector pili muscle

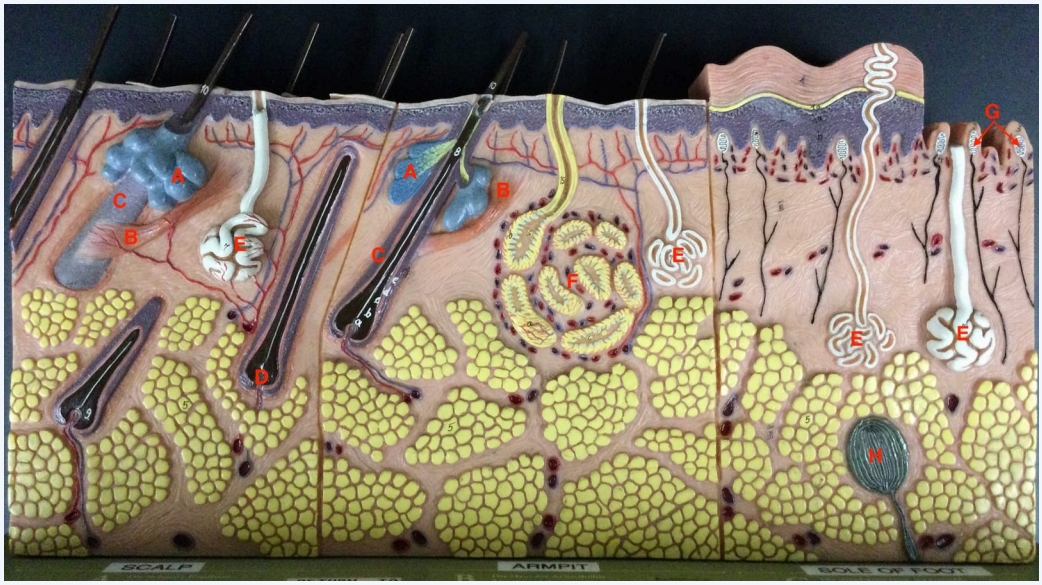

Image credit

"*Skin Model - Accessory Structures Labeled*" by Jennifer Lange is licensed under CC BY-NC-SA 4.0.

Answer Key (click to show/hide answers)

A - sebaceous gland

B - arrector pili muscle

C - hair follicle

D - hair root

E - eccrine sweat gland (merocrine sweat gland)

F - apocrine sweat gland

G - Meissner corpuscles

H - Pacinian corpuscle

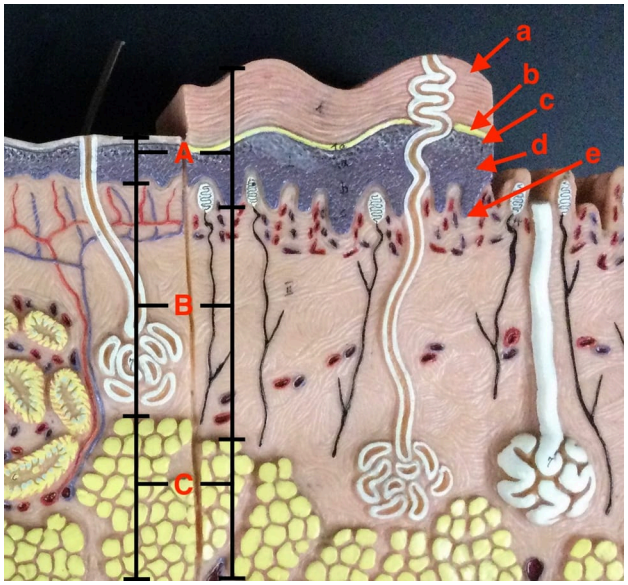

Image credit

"*Skin Model - Layers Labeled*" by Jennifer Lange is licensed under CC BY-NC-SA 4.0.

Answer Key (click to show/hide answers)

A - epidermis

B - dermis

C - hypodermis

a - stratum corneum

b - stratum lucidum

c - stratum granulosum

d - stratum spinosum

e - stratum basale

This page titled 4.6: Anatomical Atlas - Integumentary System is shared under a CC BY-NC-SA 4.0 license and was authored, remixed, and/or curated by Jennifer Lange et al..

4.7: Practice Practical - Integumentary System

Please answer each of the following questions by typing your answer into the blanks.

Query 4.7.1

This interactive element is not available in this format. Visit the link or scan the QR code to access it online.

View this Interactive Content online

Query 4.7.1

This interactive element is not available in this format. Visit the link or scan the QR code to access it online.

View this Interactive Content online

Query 4.7.1

This interactive element is not available in this format. Visit the link or scan the QR code to access it online.

View this Interactive Content online

Query 4.7.1

This interactive element is not available in this format. Visit the link or scan the QR code to access it online.

View this Interactive Content online

Query 4.7.1

This interactive element is not available in this format. Visit the link or scan the QR code to access it online.

View this Interactive Content online

This page titled 4.7: Practice Practical - Integumentary System is shared under a CC BY-NC-SA 4.0 license and was authored, remixed, and/or curated by Jennifer Lange et al..

5: BONE TISSUE AND SKELETAL SYSTEM

5.1: Introduction to Bone Tissue and the Skeletal System

5.2: Functions of the Skeletal System

5.3: Bone Structure

5.4: Bone Formation and Development

5.5: Fractures and Bone Repair

5.6: Exercise, Nutrition, Hormones, and Bone Tissue Health

5.7: Bone Classification

5.8: Anatomical Atlas - Bone Tissue and Bone Structure

5.9: Practice Practical - Bone Tissue and Bone Structure

This page titled 5: Bone Tissue and Skeletal System is shared under a CC BY-NC-SA 4.0 license and was authored, remixed, and/or curated by Jennifer Lange et al..

- 5: Bone Tissue and Skeletal System by Whitney Menefee, Julie Jenks, Chiara Mazzasette, and Kim-Leiloni Nguyen is licensed CC BY 4.0.

5.1: Introduction to Bone Tissue and the Skeletal System

Chapter Learning Objectives

After studying this chapter, you will be able to:

- List and describe the functions of bones
- Describe the classes of bones
- Discuss the process of bone formation and development
- Explain how bone repairs itself after a fracture
- Discuss the effects of exercise, nutrition, and hormones on bone tissues

We have learned much about our extinct hominin relatives and solved many murder cases based on skeletal remains. Why do bones last so long after death? Depending on the environmental conditions bones can last anywhere from a few years to hundreds of years after death due to the slow decay of the mineralized collagen that forms their basic structure. If bones are completely buried in certain materials, like volcanic ash, soon after death they can become fossilized and remain for millions of years! Unlike a fossil skeleton, however, your skeleton is a structure of living tissue that grows, repairs, and renews itself. The bones within it are dynamic and complex organs that serve a number of important functions, including some necessary to maintain homeostasis.

Figure 5.1.1: The Paris Catacombs. Due to public health concerns stemming from the cemeteries in Paris, starting in 1785 the remains were dug up and transferred to underground tunnels of an abandoned quarry outside the city limits, a practice that continued through 1860 as the city expanded. Visitors could access the ossuary starting in 1809, so to make it more attractive the bones were organized and arranged. The site is now part of the Museums of Paris, with an audio tour and a gift shop. (Image credit: "The Paris Catacombs - 30 June 2015" by Joe deSousa, CC0, via Wikimedia Commons)

Contributors and Attributions

- OpenStax Anatomy & Physiology (CC BY 4.0). Access for free at https://openstax.org/books/anatomy-and-physiology

This page titled 5.1: Introduction to Bone Tissue and the Skeletal System is shared under a CC BY-NC-SA 4.0 license and was authored, remixed, and/or curated by Jennifer Lange et al..

- 5.1: Introduction to Bone Tissue and the Skeletal System by Whitney Menefee, Julie Jenks, Chiara Mazzasette, and Kim-Leiloni Nguyen is licensed CC BY 4.0.

5.2: Functions of the Skeletal System

By the end of this section, you will be able to:

- Define bone, cartilage, and the skeletal system
- List and describe the functions of the skeletal system

Bone, or **osseous tissue**, is a hardened connective tissue that forms most of the adult skeleton, the support structure of the body. In the areas of the skeleton where bones move (for example, the ribcage and joints), **cartilage**, a semi-rigid form of connective tissue, provides flexibility and smooth surfaces for movement. The **skeletal system** is the body system composed of bones and cartilage and performs the following critical functions for the human body: supports the body, facilitates movement, protects internal organs, produces blood cells, stores and releases minerals and fat (Figure 5.2.1).

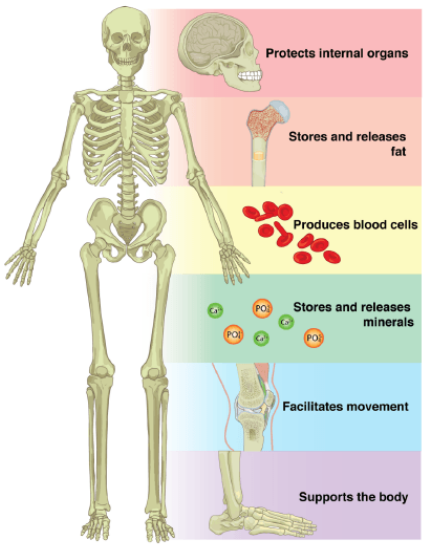

Figure 5.2.1: Functions of the skeletal system. *("Functions of the skeletal system" by OpenStax is licensed under CC-BY.)*

Support, Movement, and Protection

The most apparent functions of the skeletal system are the gross functions—those visible by observation. Simply by looking at a person, you can see how the bones support, facilitate movement, and protect the human body.

Just as the steel beams of a building provide a scaffold to support its weight, the bones and cartilage of your skeletal system compose the scaffold that supports the rest of your body. Without the skeletal system, you would be a limp mass of organs, muscle, and skin.

Bones facilitate movement by serving as points of attachment for your muscles. While some bones only serve as a support for the muscles, others also transmit the forces produced when your muscles contract. From a mechanical point of view, bones act as levers and articulations (where two bones come together, also known as joints) serve as fulcrums. Unless a muscle spans an articulation and contracts, a bone is not going to move. Information on the interactions of the skeletal and muscular systems, that is the musculoskeletal system, will be covered in the upcoming chapters of this book.

Bones also protect internal organs from injury by covering or surrounding them. For example, your ribs protect your lungs and heart, the bones of your vertebral column (spine) protect your spinal cord, and the bones of your cranium (skull) protect your brain (Figure 5.2.2).

Figure 5.2.2: Bones Protecting the Spinal Cord . Bone of the vertebral column surround the spinal cord, protecting it from traumatic injury. *(Image credit: by Amada44, CC BY-SA 3.0, via Wikimedia Commons)*

CAREER CONNECTION

Orthopedist

An **orthopedist** is a doctor who specializes in diagnosing and treating disorders and injuries related to the musculoskeletal system. Some orthopedic problems can be treated with medications, exercises, braces, and other devices, but others may be best treated with surgery (Figure 5.2.3).

Figure 5.2.3: Applying a posterior upper-extremity plaster splint. Plaster splints are often used immediately following an injury due to the swelling in the area. *(Image credit: "Orthopedic Clinic Keeps Patients Happy and Active [Image 3 of 3], by CPO Brannon Deugan, identified by DVIDS, is in the Public Domain.)*

While the origin of the word “orthopedics” (ortho- = “straight”; paed- = “child”), literally means “straightening of the child,” orthopedists can have patients who range from pediatric to geriatric. In recent years, orthopedists have even performed prenatal surgery to correct spina bifida, a congenital defect in which the neural canal in the spine of the fetus fails to close completely during embryologic development.

Orthopedists commonly treat bone and joint injuries but they also treat other bone conditions including curvature of the spine. Lateral curvatures (scoliosis) can be severe enough to slip under the shoulder blade (scapula) forcing it up as a hump. Spinal curvatures can also be excessive dorsoventrally (kyphosis) causing a hunch back and thoracic compression. These curvatures often appear in preteens as the result of poor posture, abnormal growth, or indeterminate causes. Mostly, they are readily treated by orthopedists. As people age, accumulated spinal column injuries and diseases like osteoporosis can also lead to curvatures of the spine, hence the stooping you sometimes see in the elderly.

Some orthopedists sub-specialize in sports medicine, which addresses both simple injuries, such as a sprained ankle, and complex injuries, such as a torn rotator cuff in the shoulder. Treatment can range from exercise to surgery.

Mineral Storage, Energy Storage, and Hematopoiesis

On a metabolic level, bone tissue performs several critical functions. For one, the bone matrix acts as a reservoir for a number of minerals important to the functioning of the body, especially calcium, and potassium. These minerals, incorporated into bone tissue, can be released back into the bloodstream to maintain levels needed to support physiological processes. Calcium ions, for example, are essential for muscle contractions and controlling the flow of other ions involved in the transmission of nerve impulses.

Bone also serves as a site for fat storage and blood cell production. The softer connective tissue that fills the interior of most bones is referred to as bone marrow (Figure 5.2.4). There are two types of bone marrow: yellow marrow and red marrow (Figure 5.2.5). **Yellow marrow** contains adipose tissue; the triglycerides (lipids) stored in the adipocytes of the tissue can serve as a source of energy. **Red marrow** is where **hematopoiesis**—the production of blood cells—takes place. Red blood cells, white blood cells, and platelets are all produced in the red marrow.

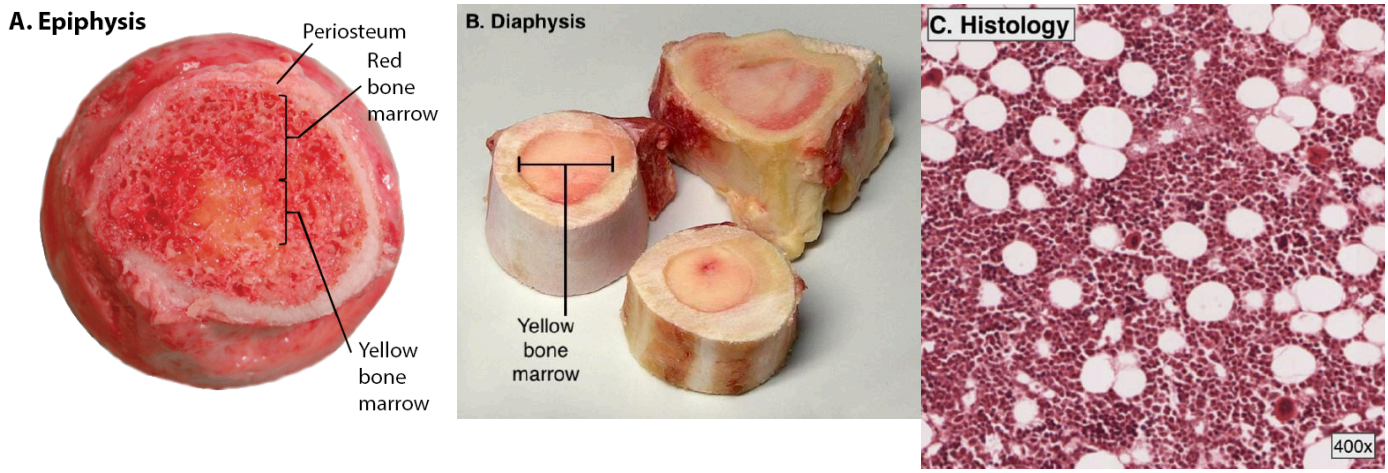

Figure 5.2.4: Red and Yellow Bone Marrow. (A) The epiphysis of the femur contains both yellow marrow (stores fat) and red marrow (responsible for hematopoiesis. (B) The diaphysis of the bone contains only yellow bone marrow. (C) Histologically, we can see that red bone marrow contains numerous developing blood cells as well as scattered adipocytes. *(Image credits: (A) "Bone Marrow - Epiphysis" by Jennifer Lange is licensed under CC BY-NC-SA 4.0, modification of original by OpenStax; (B) "Bone Marrow - Diaphysis" by Jennifer Lange is licensed under CC BY-NC-SA 4.0, modification of original by by Rainer Zenz assumed (based on copyright claims), via Wikimedia Commons; (C) "Red Bone Marrow Histology" by Jennifer Lange is licensed under CC BY-NC-SA 4.0, slide provided by the Regents of the University of Michigan Medical School under CC BY-NC-SA 4.0 © 2022)*

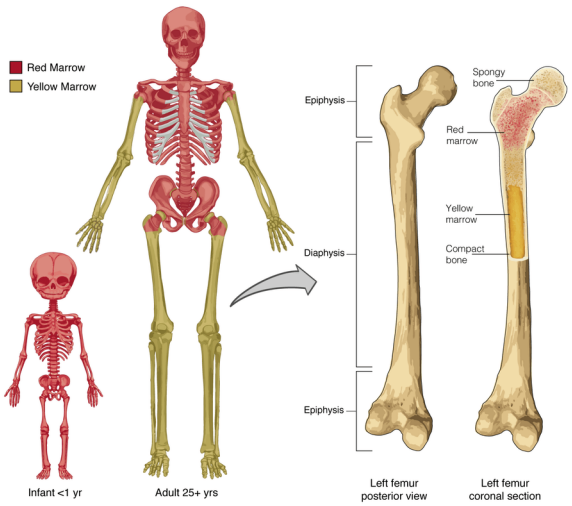

Figure 5.2.5: Bone Marrow. In young children red bone marrow fills the internal spaces of the entire skeleton. In adults it only is found in the axial skeleton and the proximal epiphyses of the humerus and femur, with yellow bone marrow occupying all other areas in the limbs. *("Marrow Locations" by OpenStax is licensed under CC-BY.)*

Concept Review

The major functions of the bones are body support, facilitation of movement, protection of internal organs, storage of minerals and fat, and hematopoiesis. Together, the muscular system and skeletal system are known as the musculoskeletal system.

Review Questions

Query 5.2.1

This interactive element is not available in this format. Visit the link or scan the QR code to access it online.

View this Interactive Content online

Critical Thinking Questions

Query 5.2.2

This interactive element is not available in this format. Visit the link or scan the QR code to access it online.

View this Interactive Content online

Glossary

Query 5.2.3

This interactive element is not available in this format. Visit the link or scan the QR code to access it online.

View this Interactive Content online

Contributors and Attributions

- OpenStax Anatomy & Physiology (CC BY 4.0). Access for free at https://openstax.org/books/anatomy-and-physiology

This page titled 5.2: Functions of the Skeletal System is shared under a CC BY-NC-SA 4.0 license and was authored, remixed, and/or curated by Jennifer Lange et al..

- 5.2: Functions of the Skeletal System by Whitney Menefee, Julie Jenks, Chiara Mazzasette, and Kim-Leiloni Nguyen is licensed CC BY 4.0.

5.3: Bone Structure

By the end of this section, you will be able to:

- Identify the gross anatomical features of a bone
- Describe the cells of bone tissue
- Compare and contrast the structure and function of compact and spongy bone
- Identify the microscopic structures that compose compact and spongy bone
- Describe how bones are nourished and innervated
- Define and list examples of bone landmarks

Bone tissue (osseous tissue) differs greatly from other tissues in the body. Bone is hard and many of its functions depend on that characteristic hardness. Later discussions in this chapter will show that bone is also dynamic in that its shape adjusts to accommodate stresses. This section will examine the gross anatomy of bone first and then move on to its histology.

Gross Anatomy of Bone

The structure of a long bone allows for the best visualization of all of the parts of a bone (Figure 5.3.1). A long bone has five zones: the **diaphysis**, two **metaphyses**, and two **epiphyses**. The diaphysis is the narrow, tubular shaft that runs between the two bulbous ends of the bone. These bulbous ends are the epiphyses (proximal and distal) and metaphyses (proximal and distal). Within the diaphysis is a hollow region called the **medullary cavity**, which is filled with yellow marrow (in adults). The walls of the diaphysis are composed of dense, hard **compact bone**. The epiphyses contain the bone parts that make up the joint structures, so they are covered with articular cartilage. The epiphysis extends from the end of the bone to the epiphyseal plate (growth plate in children) or epiphyseal line (in adults). The metaphyses extend from the epiphyseal plate/line to the diaphysis. Both the epiphyses and metaphyses have a thin cortical layer of compact bone that is filled with a porous bone arrangement called **spongy bone**. The spaces within the spongy bone are filled with **red bone marrow** containing the stem cells for blood cell production (the process of hematopoesis).

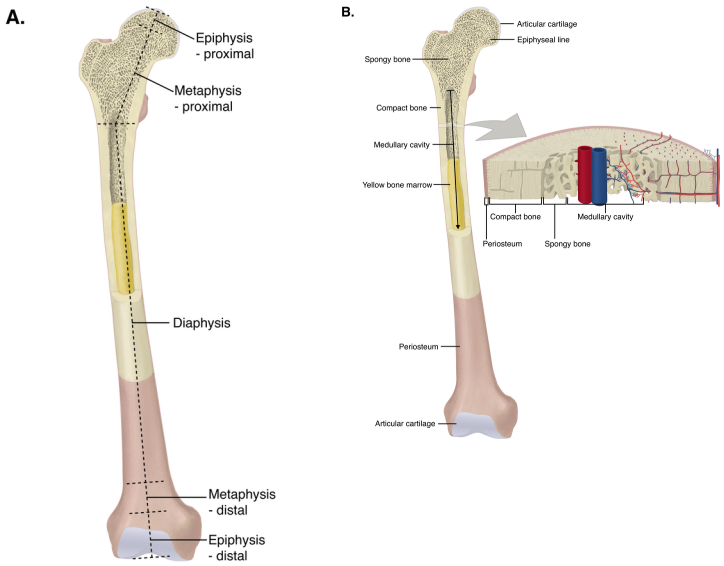

Figure 5.3.1: Anatomy of a Long Bone. Structures characteristic of a long bone, no matter how long or short it is, are the hollow diaphysis and the two metaphyses and epiphyses filled with compact bone. *(Image credit: "Anatomy of a Long Bone" illustration by Justin Greene and composition by Jennifer Lange is licensed under CC BY-NC-SA 4.0.)*

The **epiphyseal plate** (growth plate) is a layer of hyaline cartilage in a growing bone. When the bone stops growing in early adulthood (approximately 18–21 years), the cartilage is replaced by osseous tissue and the epiphyseal plate becomes an

epiphyseal line. The process of longitudinal bone growth is covered in more detail in section 5.4.

The medullary cavity has a delicate membranous lining called the **endosteum** (end- = “inside”; oste- = “bone”), where bone growth, repair, and remodeling occur. The outer surface of the bone is covered with a fibrous membrane called the **periosteum** (peri- = “around” or “surrounding”) (Figure 5.3.2). The periosteum consists of two layers; a superficial fibrous layer and a deeper cellular layer. Like the endosteum, the periosteum plays a role in bone growth, repair, and remodeling. It contains blood vessels, nerves, and lymphatic vessels that nourish compact bone, and also serves as a point of attachment for tendons and ligaments. The periosteum covers the entire outer surface except where the epiphyses meet other bones to form joints (Figure 5.3.1). In this region, the epiphyses are covered with **articular cartilage**, a thin layer of hyaline cartilage that reduces friction and acts as a shock absorber.

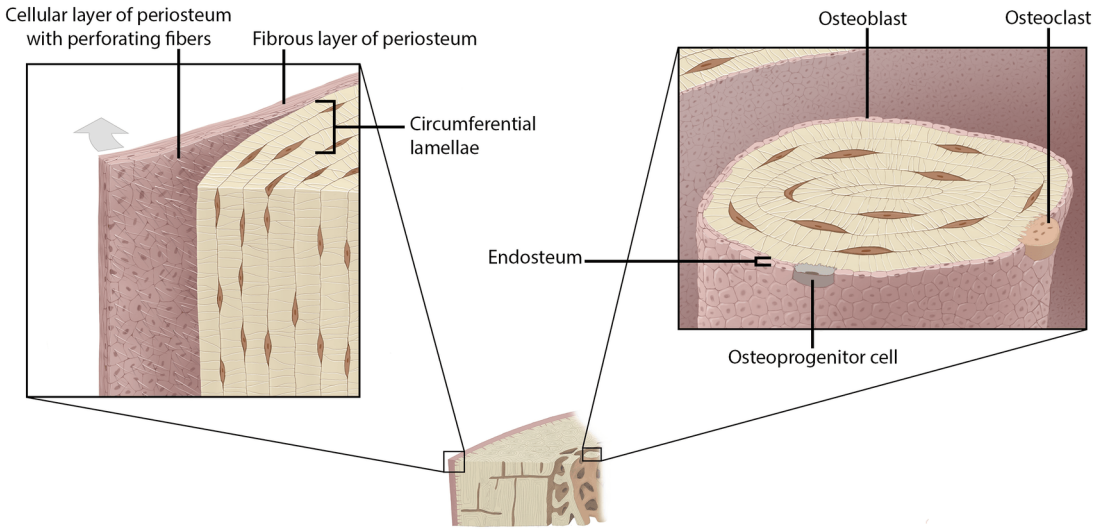

Figure 5.3.2: Periosteum and Endosteum. The periosteum forms the outer surface of bone, and the endosteum lines the medullary cavity. *(Image credit: "Periosteum and Endosteum" illustration by Justin Greene and composition by Jennifer Lange is licensed under CC BY-NC-SA 4.0.)*

Flat bones, like those of the cranium, consist of a layer of spongy bone lined on either side by a layer of compact bone (Figure 5.3.3). The two layers of compact bone and the interior spongy bone work together to protect the internal organs. If the outer layer of a cranial bone fractures, the brain is still protected by the intact inner layer.

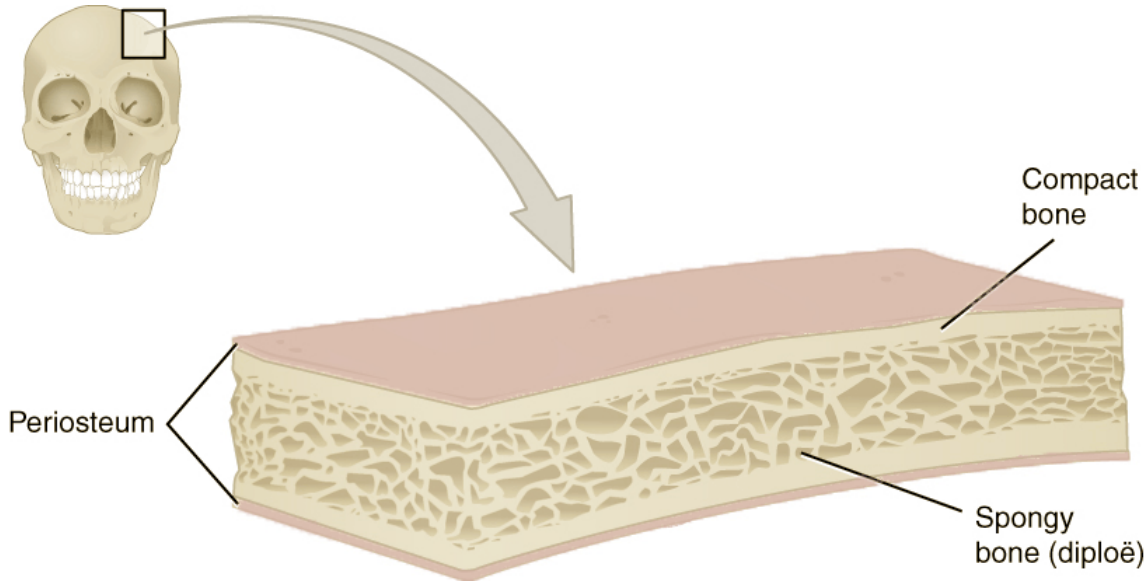

Figure 5.3.3: Anatomy of a Flat Bone. This cross-section of a flat bone shows the spongy bone (diploë) lined on either side by a layer of compact bone. *(Image credit: "Anatomy of a Long Bone" by Jennifer Lange is licensed under CC BY-NC-SA 4.0, modification of original by OpenStax.)*

Bone Cells and Tissue

Bone contains a relatively small number of cells entrenched in a matrix of collagen fibers that provide a framework to which inorganic salts adhere. These salt crystals form when calcium phosphate and calcium carbonate combine to create hydroxyapatite, which incorporates other inorganic salts like magnesium hydroxide, fluoride, and sulfate as it crystallizes, or calcifies, on the collagen fibers. The hydroxyapatite crystals give bones their hardness and strength, while the collagen fibers give them flexibility so that they are not brittle.

Although bone cells compose a small amount of the bone volume, they are crucial to the function of bones. Four types of cells are found within bone tissue: osteoblasts, osteocytes, osteogenic cells (osteoprogenitors), and osteoclasts (Figure 5.3.4).

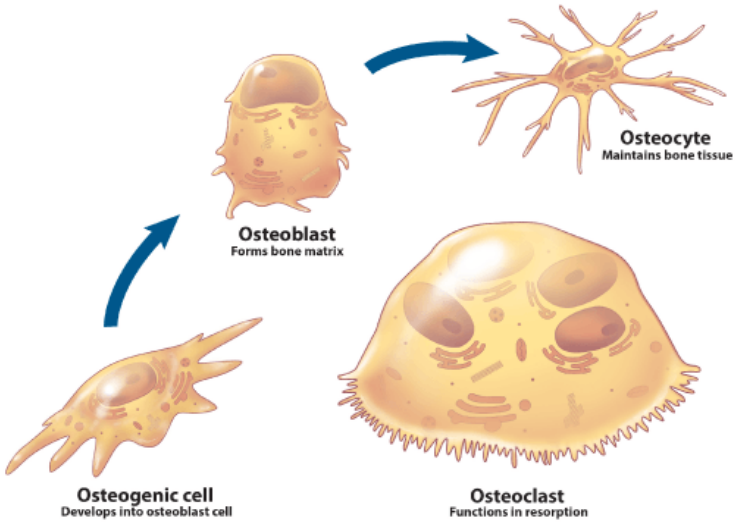

Figure 5.3.4: Bone Cells. Four types of cells are found within bone tissue. Osteogenic cells are undifferentiated and develop into osteoblasts. When osteoblasts get trapped within the calcified matrix, their structure and function changes, and they become osteocytes. Osteoclasts develop from monocytes and macrophages and differ in appearance from other bone cells. *(Image credit: "Bone Cells" by BlueLink is licensed under CC BY-NC 4.0 with notification of the original authors.)*

The **osteoblast** is the bone cell responsible for forming new bone and is found in the growing portions of bone, including the periosteum and endosteum. Osteoblasts, which do not divide, synthesize and secrete the collagen matrix and calcium salts. As the secreted matrix surrounding the osteoblast calcifies the osteoblast becomes trapped within it. As a result, it changes in structure and becomes an **osteocyte**, the primary cell of mature bone and the most common type of bone cell. Each osteocyte is located in a space called a **lacuna** and is surrounded by bone extracellular matrix. Osteocytes maintain the mineral concentration of the matrix via the secretion of enzymes. Like osteoblasts, osteocytes lack mitotic activity. As osteoblasts differentiate into osteocytes structural changes occur that increase the surface area of the osteocyte cell membrane. Once trapped in lacunae, this increased surface area enables adjacent osteocytes to communicate with each other and receive nutrients via long cytoplasmic processes that extend through **canaliculi** (singular = canaliculus), tiny channels within the bone matrix.

If osteoblasts and osteocytes are incapable of mitosis, then how are they replenished when old ones die? The answer lies in the properties of a third category of bone cells—the **osteogenic cell (osteoprogenitor)**. These osteogenic cells are undifferentiated with high mitotic activity and they are the only bone cells that divide. Immature osteogenic cells are found in the deep layers of the periosteum and the endosteum. They differentiate and develop into osteoblasts.

The dynamic nature of bone means that new tissue is constantly formed, and old, injured, or unnecessary bone is dissolved for repair or for calcium release. The cell responsible for bone resorption, or breakdown, is the **osteoclast**. They are found on bone surfaces, are multinucleated, and originate from monocytes and macrophages, two types of white blood cells, not from osteogenic cells. Osteoclasts are continually breaking down old bone while osteoblasts are continually forming new bone. The ongoing balance between osteoblasts and osteoclasts is responsible for the constant but subtle reshaping of bone. Table 5.3.1 reviews the bone cells, their functions, and locations.

Table 5.3.1: Bone Cells

Cell type	Function	Location
Osteogenic cells (osteoprogenitor cells)	Undergo mitosis and develop into osteoblasts	Deep layers of the periosteum and the endosteum
Osteoblasts	Bone matrix formation	Growing portions of bone, including periosteum and endosteum
Osteocytes	Maintain mineral concentration of matrix	Entrapped in matrix within lacunae
Osteoclasts	Bone matrix resorption	Bone surfaces and at sites of old, injured, or unneeded bone

Compact and Spongy Bone

The differences between compact and spongy bone arrangements are best explored via their histology. Most bones contain compact and spongy osseous tissue, but their distribution and concentration vary based on the bone's overall function. Compact bone is dense so that it can withstand compressive, bending, and twisting forces. Spongy (cancellous) bone distributes and transfers stress in the epiphyses and metaphyses. Its open spaces make the tissue lighter weight and, thus, easier to move (Figure 5.3.5).

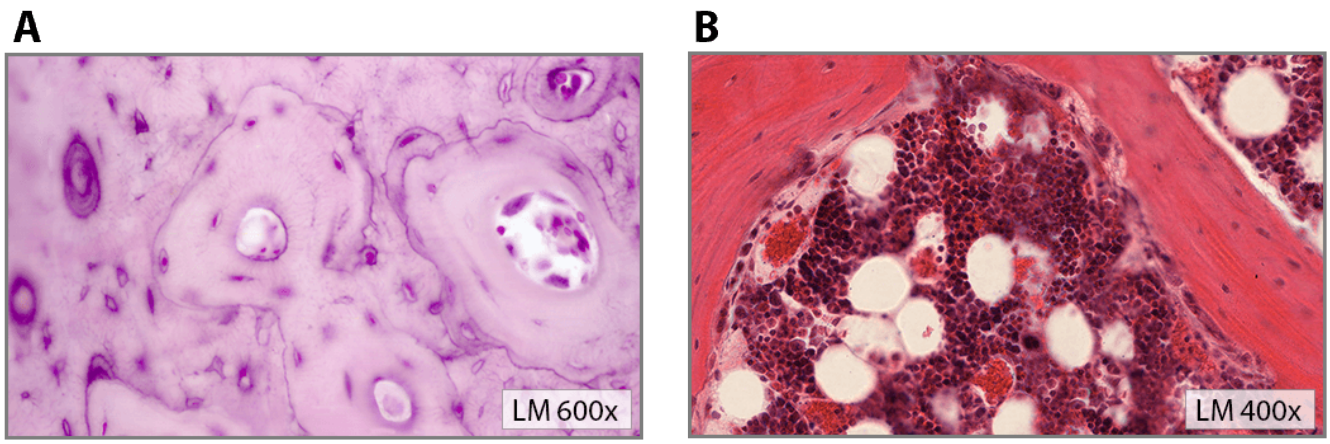

Figure 5.3.5: Compact and Spongy Bone. Compact bone (A) bone is much denser than spongy bone (B). The spaces in spongy bone are filled with bone marrow. *(Image credits: " Compact and Spongy Bone" micrographs provided by Virginia Commonwealth University under CC BY-NC-SA 4.0)*

Compact Bone

Compact bone is the denser, stronger of the two types of bone tissue (Figure 5.3.6). It can be found deep to the periosteum and in the diaphyses of long bones, where it provides support and protection.

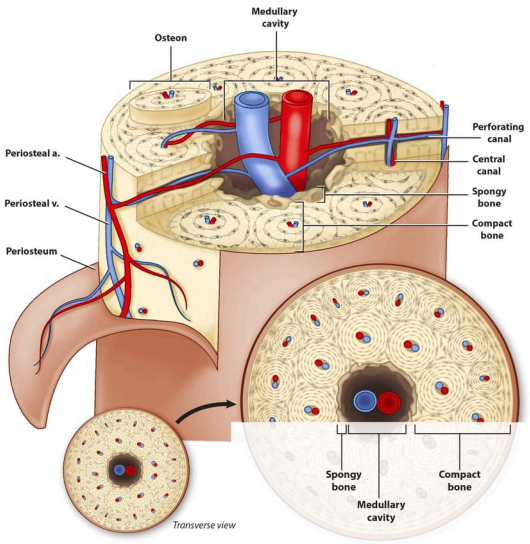

Figure 5.3.6: Diagram of Long Bone Diaphysis. These oblique and transverse views of the diaphysis of a long bone show the internal structure of compact bone. Compact bone is found deep to the periosteum and is comprised of structural units called osteons. *(Image credit: "Diagram of Long Bone Diaphysis" original by BlueLink, modified by Mark Schaeffer is licensed under CC BY-NC-SA 4.0.)*

The microscopic structural unit of compact bone is called an **osteon**, or Haversian system (Figure 5.3.7). Each osteon is composed of concentric rings of calcified matrix called **concentric lamellae** (singular = lamella). The arrangement of collagen fibers within each lamella are aligned in a direction that is diagonal with respect to the osteon for added strength in that direction. Then in adjacent lamellae, the directionality of the collagen fibers is perpendicular to those in the first so that when the lamellae are sandwiched together as concentric rings, the alternating pattern conveys triangulated strength to the osteon. Running down the center of each osteon, mostly parallel to the medullary cavity, is the **central canal**, or Haversian canal, which contains blood vessels, nerves, and lymphatic vessels. These vessels and nerves branch off at right angles through a **perforating canal**, also known as Volkmann's canals, to extend to the periosteum and endosteum.

Other layers of extracellular matrix in compact bone surround and encircle the osteons. The **interstitial lamellae** are found

between the osteons. These are remnants of old osteons that have been remodeled, leaving various shapes and layer numbers essentially filling in the gaps. Located deep to the periosteum are the **circumferential lamellae** (external and internal) that completely encircle the entire bone and are superficial to the osteons (Figure 5.3.7).

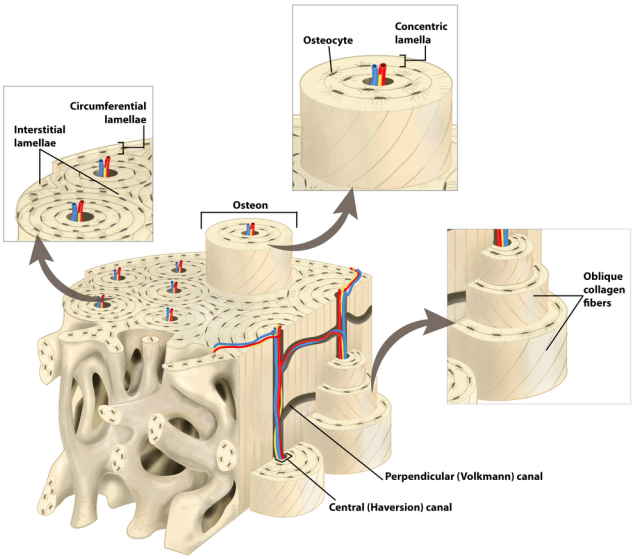

Figure 5.3.7: Enlargements of Long Bone Diaphysis. An expanded section of the diaphysis shows the arrangement of the extracellular matrix into circumferential, concentric, and interstitial lamellae. The concentric lamella of an osteon form rings around the central canal, with the osteocytes located between adjacent lamellae. *(Image credit: "Enlargements of Long Bone Diaphysis" by Mark Schaeffer and Jennifer Lange is licensed under CC BY-NC-SA 4.0, a derivative from the original work of "Slagter - Drawing Bone matrix - no labels" by Ron Slagter.)*

The osteocytes are located inside spaces called lacunae (singular = lacuna), found at the borders of adjacent lamellae. As described earlier, canaliculi radiating out from each lacuna connect with the canaliculi of other lacunae and eventually with the central canal (Figure 5.3.8). This system allows nutrients to be transported to the osteocytes and wastes to be removed from them.

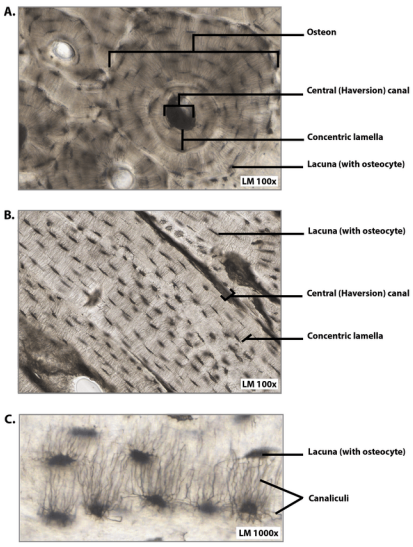

Figure 5.3.8: Microscopic Anatomy of Compact Bone. Three light micrographs of compact bone. In a ground bone preparation organic components are not preserved, so bone cells and organic matrix are not present. What remains is the inorganic matrix of calcium phosphate (hydroxyapatite) with the canals and cellular spaces highlighted. A. osteons in cross section showing circular pattern of the concentric lamellae; B. osteons in long section showing linear pattern of concentric lamellae; C. enlargement of lacunae (osteocytes no longer present) showing connecting canaliculi. *(Image credit: "Microscopic Anatomy of Compact Bone" by Jennifer Lange, slide provided by the Regents of the University of Michigan Medical School under CC BY-NC-SA 4.0 © 2022)*

Spongy (Cancellous) Bone

Like compact bone, **spongy bone**, also known as cancellous bone, contains osteocytes housed in lacunae, arranged in concentric lamellae. Unlike the osteons of compact bone, the sets of lamellae do not surround a hollow central canal and they are not arranged in parallel columns alongside each other, but rather in a lattice-like network of matrix spikes called **trabeculae** (singular = trabecula) (Figure 5.3.9). Each trabecula is wrapped in a layer of endosteum. The trabeculae may appear to be a random network, but each trabeculae forms along lines of stress to provide strength to the bone. If the stress on the bone changes, the trabeculae can be quickly remodeled to adapt to the new forces. The spaces of the trabeculated network provide balance to the dense and heavy compact bone by making bones lighter so that muscles can move them more easily. In addition, the spaces in some spongy bones contain red marrow, protected by the trabeculae, where hematopoiesis occurs.

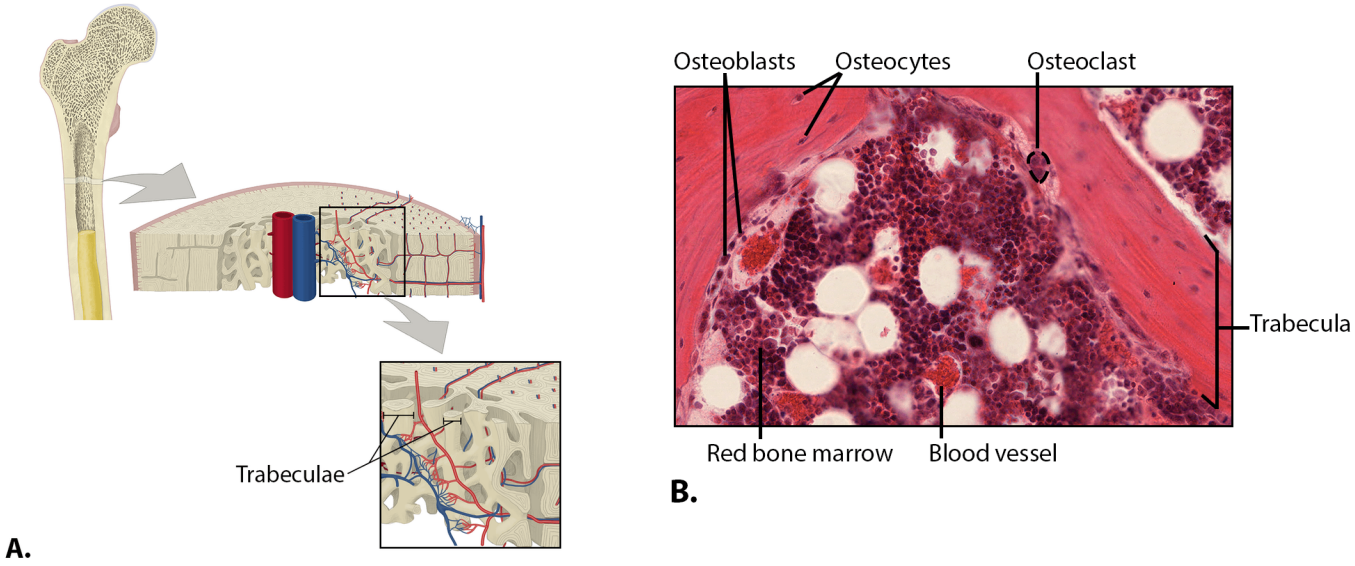

Figure 5.3.9: Spongy Bone Structure. A. Spongy bone is composed of trabeculae that contain the osteocytes. B. Histologically we can see each trabeculae has an exterior cellular layer containing osteoblasts and/or osteoclasts, depending on the need for their functions. *(Image credits: "Spongy Bone Structure Illustration" illustration by Justin Greene and composition by Jennifer Lange is licensed under CC BY-NC-SA 4.0 ; "Spongy Bone Histology @ 400x" by Jennifer Lange is licensed under CC BY-NC-SA 4.0; micrograph provided by Virginia Commonwealth University under CC BY-NC-SA 4.0.)*

AGING AND THE....

Skeletal System: Paget's Disease

Paget's disease affects approximately 4% of adults over age 40 that are of European descent. It is a chronic metabolic disorder of characterized by excessive abnormal bone remodeling that begins with overactive osteoclasts. This means more bone is resorbed than is laid down. The osteoblasts try to compensate but the new bone they lay down is weak and brittle and therefore prone to fracture.

While most people with Paget's disease have no symptoms upon diagnosis (discovery is incidental finding on imaging for something unrelated), others experience pain, bone fractures, and bone deformities (Figure 5.3.10). The pelvis, spine, skull, and proximal long bones are most frequently affected. When occurring in the skull, Paget's disease can cause headaches and hearing loss. The classic radiological appearances are expanded bone with a coarsened trabecular pattern, but appearance varies depending upon which bones are affected and the stage of the disease.

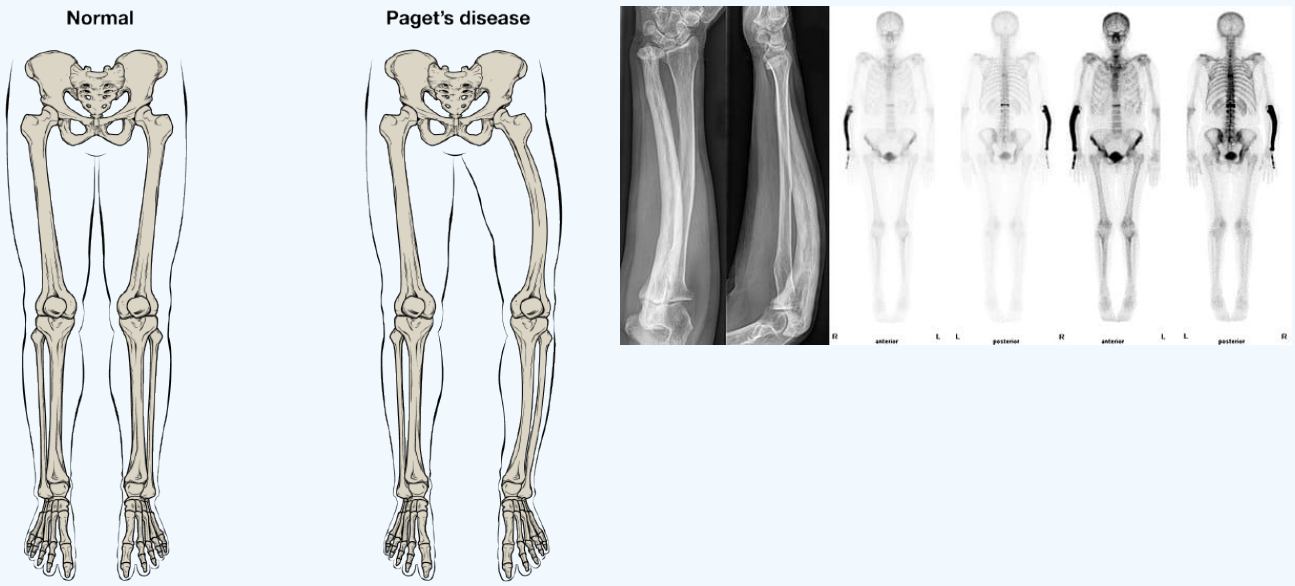

Figure 5.3.10: Paget's Disease. Normal bones are relatively straight, but those affected by Paget's disease are porous and curved. These structural changes can be seen using both x-ray and radiographic tracing imaging. *(Image credits: Illustration - "Feature Pagets Disease" by OpenStax is licensed under CC BY 4.0. Imaging - "Paget_Ulna_69jw_-_Roe_Unterarm_2_Eb_und_Szinti_frueh_spaet_-_001", is licensed under CC BY-SA 3.0, via Wikimedia Commons)*

What causes the osteoclasts to become overactive? The answer is still unknown, but hereditary factors seem to play a role. Some scientists believe Paget's disease is due to an as-yet-unidentified virus.

Paget's disease is diagnosed via imaging studies and lab tests. X-rays may show bone deformities or areas of bone resorption. Bone scans are also useful. In these studies, a dye containing a radioactive ion is injected into the body. Areas of bone resorption have an affinity for the ion, so they will light up on the scan if the ions are absorbed. In addition, blood levels of an enzyme called alkaline phosphatase are typically elevated in people with Paget's disease.

Bisphosphonates, drugs that decrease the activity of osteoclasts, are often used in the treatment of Paget's disease. However, in a small percentage of cases, bisphosphonates themselves have been linked to an increased risk of fractures because the old bone that is left after bisphosphonates are administered becomes worn out and brittle. Still, most doctors feel that the benefits of bisphosphonates more than outweigh the risk; the medical professional has to weigh the benefits and risks on a case-by-case basis. Bisphosphonate treatment can reduce the overall risk of deformities or fractures, which in turn reduces the risk of surgical repair and its associated complications.

Blood and Nerve Supply

The spongy bone and medullary cavity receive nourishment from three major groups of arteries that pass through the periosteum and compact bone. The nutrient artery enters through the **nutrient foramen**, a small opening in the diaphysis (Figure 5.3.11), where it branches to provide blood supply to the entire diaphysis. At the metaphyseal regions, the metaphyseal arteries enter the bone, while epiphyseal arteries enter and provide blood flow to the epiphyseal regions. As the blood passes through the marrow cavities, it is collected by veins, which then pass out of the bone through the same foramina that the arteries entered through.

In addition to the blood vessels, nerves follow the same paths into the bone where they tend to concentrate in the more metabolically active regions of the bone. The nerves sense pain, and it appears the nerves also play roles in regulating blood supplies and in bone growth, hence their concentrations in metabolically active sites of the bone.

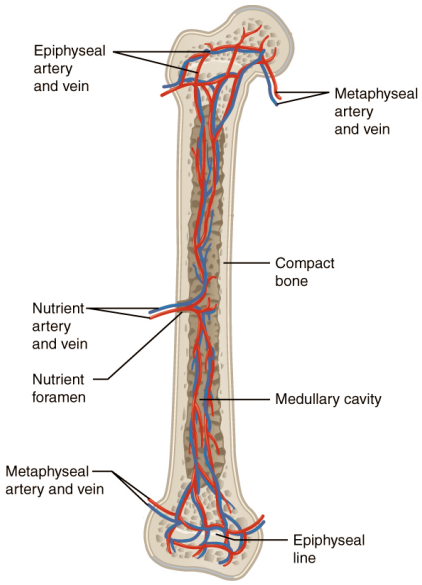

Figure 5.3.11: Diagram of Blood Supply to Bone. Three major groups of blood vessels, the nutrient, metaphyseal, and epiphyseal arteries and veins, supply bones with blood. *(Image credit: "Blood Supply to a Long Bone" original by OpenStax and modified by Jennifer Lange is licensed under CC BY-NC-SA 4.0.)*

Bone Landmarks

The surface features of bones vary considerably, depending on the function and location in the body. Table 5.3.2 describes the bone landmarks, which are illustrated in (Figure 5.3.12). There are three general classes of bone landmarks: (1) articular surfaces, (2) projections, and (3) holes/openings. As the name implies, an **articular surface** is where two bone surfaces come together (articulus = "joint"). These surfaces tend to conform to one another, such as one being rounded and the other cupped, to facilitate the function of the articulation. A **projection** is an area of a bone that projects above the surface of the bone. These are the attachment points for tendons and ligaments. In general, their size and shape is an indication of the forces exerted through the attachment to the bone. A **hole** is an opening or groove in the bone that allows blood vessels and nerves to enter or pass through the bone. As with the other landmarks, their size and shape reflect the size of the vessels and nerves that penetrate the bone at these points.

Table 5.3.2: Bone Landmarks: Articular Surfaces, Projections, and Depressions/Openings.

Landmark Type	Description	Examples
Articular Surfaces	**Smooth surfaces where two bone slide past each other**	
Head	Large, smooth, and rounded prominence typically located at an epiphyseal end	Head of femur
Facet	Very slight depression/flat area with smooth surface	Superior articular facet of vertebrae
Condyle	Rounded, smooth projection (often described as knuckle-like); in some cases, the condyle is slightly depressed	Occipital condyles; tibial condyles
Projections	**Raised markings for tendon/ligament attachment**	
Epicondyle	Projection adjacent to a condyle	Medial epicondyle of the femur
Process	Projection of varying length	Transverse process of vertebra
Spine	Sharp, often thin, process	Ischial spine
Tubercle	Small, rounded projection	Tubercle of humerus
Tuberosity	Large, rough projection	Deltoid tuberosity

Landmark Type	Description	Examples
Trochanter	Massive, rough projection	Greater trochanter of the femur
Line	Slight, elongated ridge	Temporal lines of the parietal bones
Crest	Narrow, prominent ridge	Iliac crest
Holes and depressions	**Allow for passage of soft tissue through/along bone or for the formation of joints**	
Fossa	Smooth depressions of varying depth	Subscapular fossa
Cavity	Depression associated with joint articulation	Glenoid cavity
Fovea	Small pit	Fovea capitis on the head of the femur
Sulcus	Narrow groove	Sigmoid sulcus of the temporal bones
Canal	Passageway through a bone	Vertebral canal
Fissure	Slit through bone	Superior orbital fissure
Foramen	Round passageway through bone	Foramen magnum of the occipital bone
Sinus	Air-filled space in bone	Frontal sinus

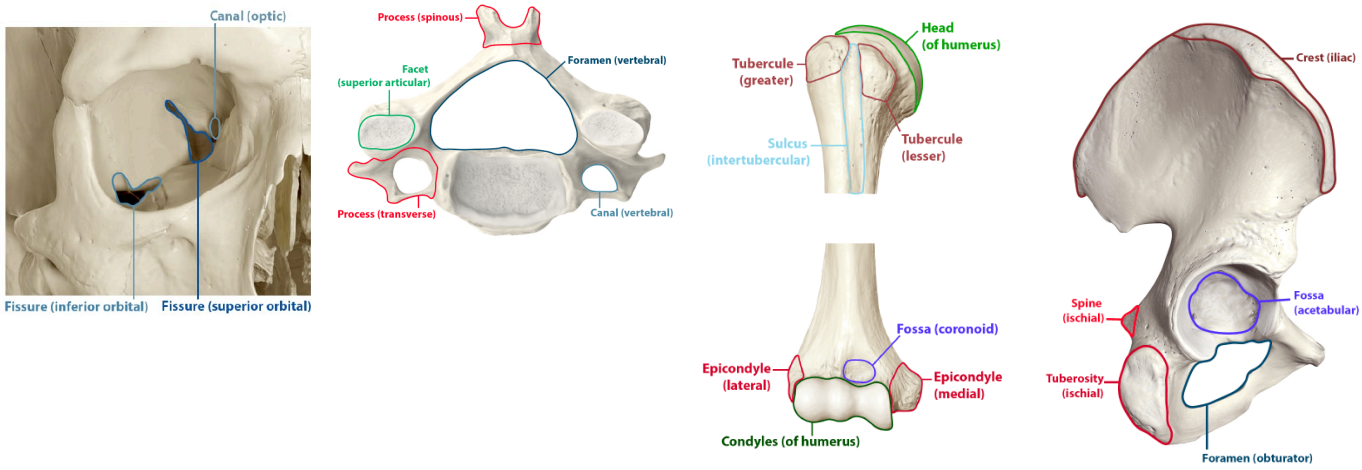

Figure 5.3.12: Examples of Bone Landmarks. The surface features of bones depend on their function, location, attachment of ligaments and tendons, or the penetration of blood vessels and nerves. Green = articular surfaces; Red = projections; Blue = holes and depressions. *(Image credits: "Bone Landmarks" by Jennifer Lange are licensed under CC BY-NC-SA 4.0, modification of images from Anatomy Standard under CC BY-NC 4.0.)*

Concept Review

A hollow medullary cavity filled with yellow marrow runs the length of the diaphysis of a long bone. The walls of the diaphysis are compact bone. The epiphyses, which are wider sections at each end of a long bone, are filled with spongy bone and red marrow. The epiphyseal plate, a layer of hyaline cartilage, is replaced by osseous tissue as the organ grows in length. The medullary cavity has a delicate membranous lining called the endosteum. The outer surface of bone, except in regions covered with articular cartilage, is covered with a fibrous membrane called the periosteum. Flat bones consist of two layers of compact bone surrounding a layer of spongy bone. Bone markings depend on the function and location of bones. Articulations are places where two bones meet. Projections stick out from the surface of the bone and provide attachment points for tendons and ligaments.

Holes are openings or depressions in the bones, and can serve as routes for blood vessels and nerves.

Bone matrix consists of collagen fibers and ground substance, primarily hydroxyapatite formed from calcium salts. Osteogenic cells develop into osteoblasts. Osteoblasts are cells that make new bone. They become osteocytes, the cells of mature bone, when they get trapped in the matrix. Osteoclasts engage in bone resorption. Compact bone is dense and composed of osteons, while spongy bone is less dense and made up of trabeculae. Blood vessels and nerves enter the bone through the nutrient foramina to nourish and innervate bones.

Review Questions

Query 5.3.1

This interactive element is not available in this format. Visit the link or scan the QR code to access it online.

View this Interactive Content online

Critical Thinking Questions

Query 5.3.2

This interactive element is not available in this format. Visit the link or scan the QR code to access it online.

View this Interactive Content online

Query 5.3.3

This interactive element is not available in this format. Visit the link or scan the QR code to access it online.

View this Interactive Content online

Glossary

Query 5.3.4

This interactive element is not available in this format. Visit the link or scan the QR code to access it online.

View this Interactive Content online

Contributors and Attributions

- OpenStax Anatomy & Physiology (CC BY 4.0). Access for free at https://openstax.org/books/anatomy-and-physiology

This page titled 5.3: Bone Structure is shared under a CC BY-NC-SA 4.0 license and was authored, remixed, and/or curated by Jennifer Lange et al..

- 5.3: Bone Structure by Whitney Menefee, Julie Jenks, Chiara Mazzasette, and Kim-Leiloni Nguyen is licensed CC BY 4.0.

5.4: Bone Formation and Development

By the end of this section, you will be able to:

- Explain the function of cartilage
- List the steps of intramembranous ossification
- List the steps of endochondral ossification
- Explain the growth activity at the epiphyseal plate
- Compare and contrast the processes of modeling and remodeling

In the early stages of embryonic development, the embryo's skeleton consists of fibrous membranes and hyaline cartilage. By the sixth or seventh week of embryonic life, the actual process of bone development, **ossification** (osteogenesis), begins. There are two osteogenic pathways—intramembranous ossification and endochondral ossification—but bone is the same regardless of the pathway that produces it.

Cartilage Templates

Bone is a replacement tissue; that is, it uses a model tissue on which to lay down its mineral matrix. For skeletal development, the most common template is cartilage. During fetal development, a framework is laid down that determines where bones will form. This framework is a flexible, semi-solid matrix produced by chondroblasts and consists of hyaluronic acid, chondroitin sulfate, collagen fibers, and water. As the matrix surrounds and isolates chondroblasts, they are called chondrocytes, which are surrounded by a lacuna. Unlike most connective tissues, cartilage is avascular, meaning that it has no blood vessels supplying nutrients and removing metabolic wastes. These functions are carried on by diffusion through the matrix. This is why damaged cartilage does not repair itself as readily as most tissues do.

Throughout fetal development and into childhood growth and development, bone forms on the cartilaginous matrix. By the time a fetus is born, most of the cartilage has been replaced with bone. Some additional cartilage will be replaced throughout childhood, and some cartilage remains in the adult skeleton.

Intramembranous Ossification

During **intramembranous ossification**, compact and spongy bone develops directly from sheets of mesenchymal (undifferentiated) connective tissue. The flat bones of the face, most of the cranial bones, and the clavicles (collarbones) are formed via intramembranous ossification.

The process begins when mesenchymal cells in the embryonic skeleton gather together and begin to differentiate into specialized cells (Figure $5.4.1.a$). Some of these cells differentiate and form the tissues of capillaries, while others will become osteogenic cells and then osteoblasts. Although they will ultimately be spread out by the formation of bone tissue, early osteoblasts appear in a cluster called an **ossification center**.

The osteoblasts secrete **osteoid**, uncalcified matrix, which calcifies (hardens) within a few days as mineral salts are deposited on it, thereby entrapping the osteoblasts within. Once entrapped, the osteoblasts become osteocytes (Figure $5.4.1.b$). As osteoblasts transform into osteocytes, osteogenic cells in the surrounding connective tissue differentiate into new osteoblasts.

Osteoid (unmineralized bone matrix) secreted around the capillaries results in a trabecular matrix. At the surfaces of the forming osseus tissue mesenchymal cells differentiate into fibroblasts which surround the forming structure with fibrous periosteum while osteoblasts, osteoclasts and osteogenic cells form the cellular (osteogenic) layer. (Figure $5.4.1.c$). The periosteum then creates a protective layer of compact bone superficial to the trabecular bone. The trabecular bone crowds nearby blood vessels, which eventually condense into red marrow (Figure $5.4.1.d$).

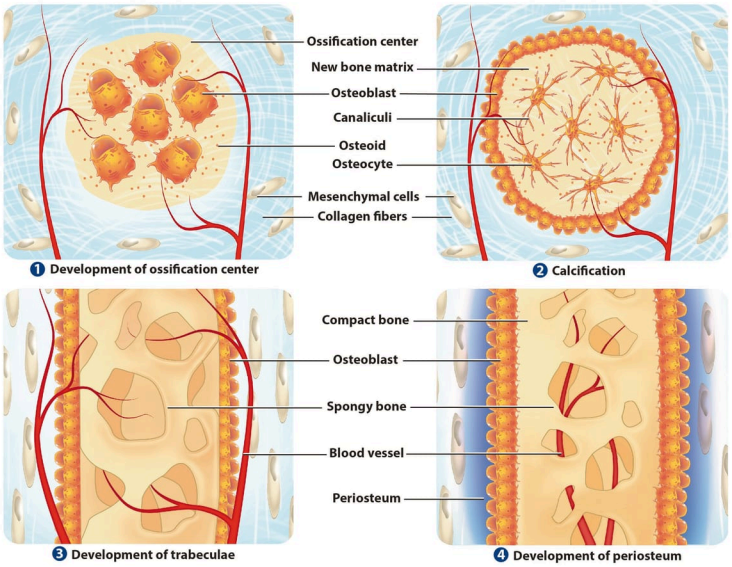

Figure 5.4.1: Intramembranous Ossification. Intramembranous ossification follows four steps. (1) Cells group into clusters and ossification centers form. (2) Secreted osteoid traps osteoblasts, which then become osteocytes. (3) Trabeculae of cancellous (spongy) form. (d) Compact bone develops superficial to the cancellous bone, and periosteum forms. *(Image credit: "Intramembraneous Ossification" by BlueLink is licensed under CC BY-NC 4.0 with notification of the original authors.)*

Intramembranous ossification begins *in utero* during fetal development and continues on into adolescence. At birth, the skull and clavicles are not fully ossified nor are the sutures of the skull closed. This allows the skull and shoulders to deform during passage through the birth canal. The last bones to ossify via intramembranous ossification are the flat bones of the face, which reach their adult size at the end of the adolescent growth spurt.

Endochondral Ossification

In **endochondral ossification**, bone develops by *replacing* hyaline cartilage. Cartilage does not become bone. Instead, cartilage serves as a template to be completely replaced by new bone. Endochondral ossification takes much longer than intramembranous ossification. Bones at the base of the skull and long bones are examples of bones that form via endochondral ossification.

In a long bone, for example, at about 6 to 8 weeks after conception, some of the mesenchymal cells differentiate into chondrocytes (cartilage cells) that form the cartilaginous skeletal precursor of the bones (Figure 5.4.2.1). Soon after, cellular differentiation produces cells that form the **perichondrium**, a membrane that covers the cartilage.

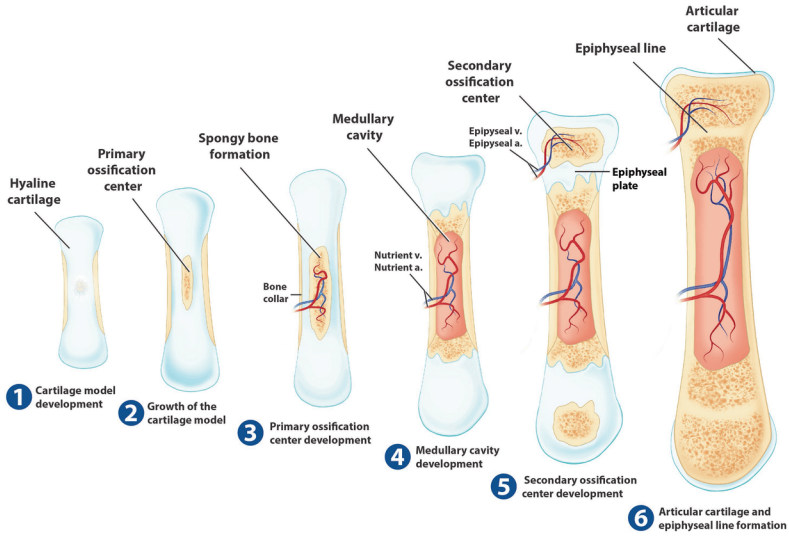

Figure 5.4.2: Endochondral Ossification. Endochondral ossification follows five steps. (1) Mesenchymal cells differentiate into chondrocytes and form the cartilage model. (2) The cartilage model of the future bony skeleton and the perichondrium grows. (3) Capillaries penetrate cartilage. Periosteal bone collar develops and primary ossification center develops. (4) Cartilage and chondrocytes continue to grow at ends of the bone; the medullary cavity forms. (5) Secondary ossification centers develop in the epiphyses; cartilage remains at epiphyseal (growth) plate. (6) Epiphyseal plate ossifies and becomes epiphyseal line; cartilage remains only at joint surface as articular cartilage. *(Image credit: "Endochondral Ossification" by BlueLink is licensed under CC BY-NC 4.0 with notification of the original authors.)*

As more matrix is produced, the chondrocytes in the center of the cartilaginous model grow in size. As the matrix calcifies, nutrients can no longer reach the chondrocytes. This results in their death and the disintegration of the surrounding cartilage. Blood vessels invade the resulting spaces, not only enlarging the cavities but also carrying osteogenic cells with them, many of which will become osteoblasts. These enlarging spaces eventually combine to become the medullary cavity.

This invasion of blood vessels initiates the transformation of the perichondrium into the bone-producing periosteum. Here, the osteoblasts form a periosteal collar of compact bone around the cartilage of the diaphysis. By the second or third month of fetal life, bone cell development and ossification ramps up and creates the **primary ossification center**, a region deep in the periosteal collar where ossification begins (Figure 5.4.2.3).

While these deep changes are occurring, chondrocytes and cartilage continue to grow at the ends of the bone (the future epiphyses), which increases the bone's length at the same time bone is replacing cartilage in the diaphyses. By the time the fetal skeleton is fully formed, cartilage only remains at the joint surface as articular cartilage and between the diaphysis and epiphysis as the epiphyseal plate, the latter of which is responsible for the longitudinal growth of bones. After birth, this same sequence of events (matrix mineralization, death of chondrocytes, invasion of blood vessels from the periosteum, and seeding with osteogenic cells that become osteoblasts) occurs in the epiphyseal regions, and each of these centers of activity is referred to as a **secondary ossification center** (Figure 5.4.2.5).

How Bones Grow in Length

The epiphyseal plate is the area of growth in a long bone. It is a layer of hyaline cartilage where ossification occurs in immature bones. On the epiphyseal side of the epiphyseal plate, cartilage is formed. On the diaphyseal side, cartilage is ossified, and the diaphysis grows in length. The epiphyseal plate is composed of four zones of cells and activity (Figure 5.4.3). The **reserve zone** is the region closest to the epiphyseal end of the plate and contains small chondrocytes within the matrix. These chondrocytes do not participate in bone growth but secure the epiphyseal plate to the osseous tissue of the epiphysis.

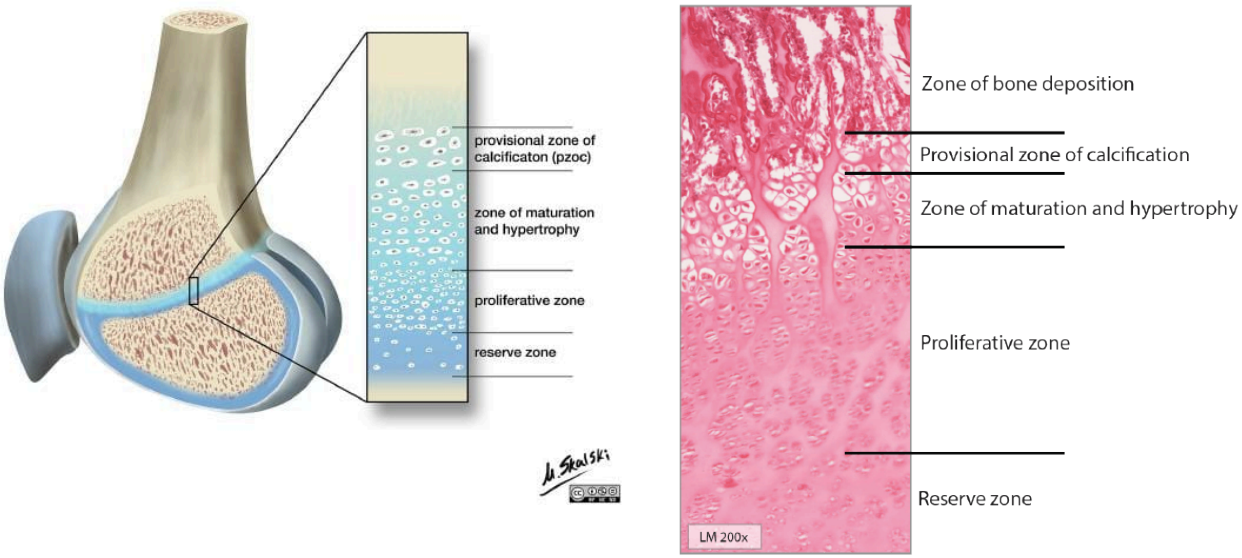

Figure 5.4.3: Longitudinal Bone Growth. The epiphyseal plate is responsible for longitudinal bone growth, displaying five distinct zones of cartilage growth and ossification. *(Image credit - illustration: "Physeal Anatomy" courtesy of Dr. Matt Skalski, Radiopaedia.org, from the case rID: 27354, is licensed under CC BY-NC-ND 4.0). Micrograph: "Longitudinal Bone Growth" by Jennifer Lange is licensed under CC BY-NC-SA 4.0, image provided by the Regents of the University of Michigan Medical School under CC-BY-NC-SA 4.0 © 2022)*

The **proliferative zone** is the next layer toward the diaphysis and contains stacks of slightly larger chondrocytes. It makes new chondrocytes (via mitosis) to replace those that die at the diaphyseal end of the plate. Chondrocytes in the next layer, the **zone of maturation and hypertrophy**, are older and larger than those in the proliferative zone. The more mature cells are situated closer to the diaphyseal end of the plate. The longitudinal growth of bone is a result of cellular division in the proliferative zone and the maturation of cells in the zone of maturation and hypertrophy.

Most of the chondrocytes in the **zone of calcified matrix**, the zone closest to the diaphysis, are dead because the matrix around them has calcified. Capillaries and osteoblasts from the diaphysis penetrate this zone, and the osteoblasts secrete bone tissue on the remaining calcified cartilage. Thus, the zone of calcified matrix connects the epiphyseal plate to the diaphysis. A bone grows in length when osseous tissue is added to the diaphysis.

Bones continue to grow in length until early adulthood. The rate of growth is controlled by hormones, which will be discussed later. When the chondrocytes in the epiphyseal plate cease their proliferation and bone replaces the cartilage, longitudinal growth stops. All that remains of the epiphyseal plate is the **epiphyseal line** (Figure 5.4.4).

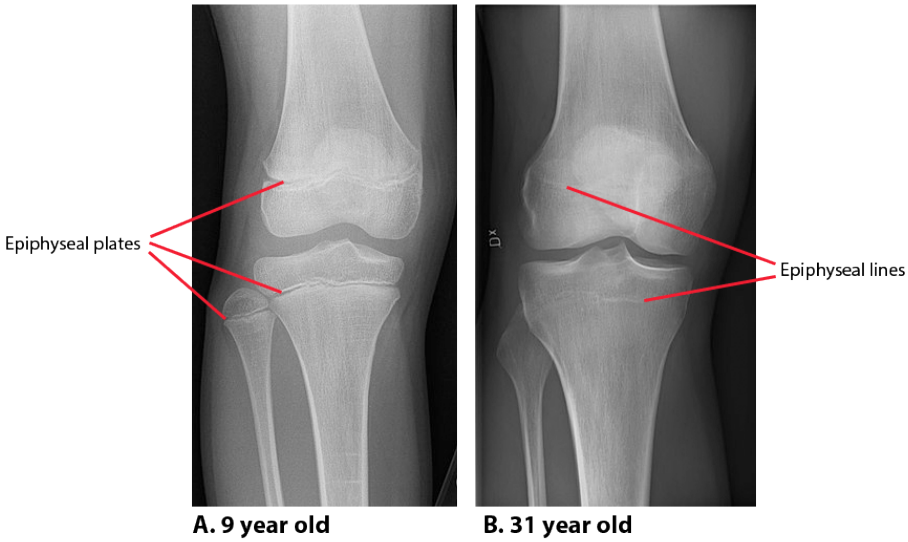

Figure 5.4.4: Epiphyseal Plate to Epiphyseal Line. As a bone matures the epiphyseal plate progresses to an epiphyseal line. (A) Epiphyseal plates are visible in the growing bones of a 9 year old. (B) Epiphyseal lines are the remnants of epiphyseal plates in a mature bone. (Image credit: "Epiphyseal Plate to Epiphyseal Line" by Jennifer Lange is licensed under CC BY-NC-SA 4.0; X-ray A: Staff at the Department of Radiology, UC San Diego Health., Public domain, via Wikimedia Commons; X-ray B: Mikael Häggström, M.D., Public Domain, via Wikimedia Commons)

How Bones Grow in Diameter

While bones are increasing in length, they are also increasing in diameter; growth in diameter can continue even after longitudinal growth ceases. This is called appositional growth (Figure 5.4.5). Osteoclasts resorb old bone that lines the medullary cavity, while osteoblasts produce new bone tissue beneath the periosteum. The erosion of old bone along the medullary cavity and the deposition of new bone beneath the periosteum not only increase the diameter of the diaphysis but also increase the diameter of the medullary cavity. This process is called **modeling**.

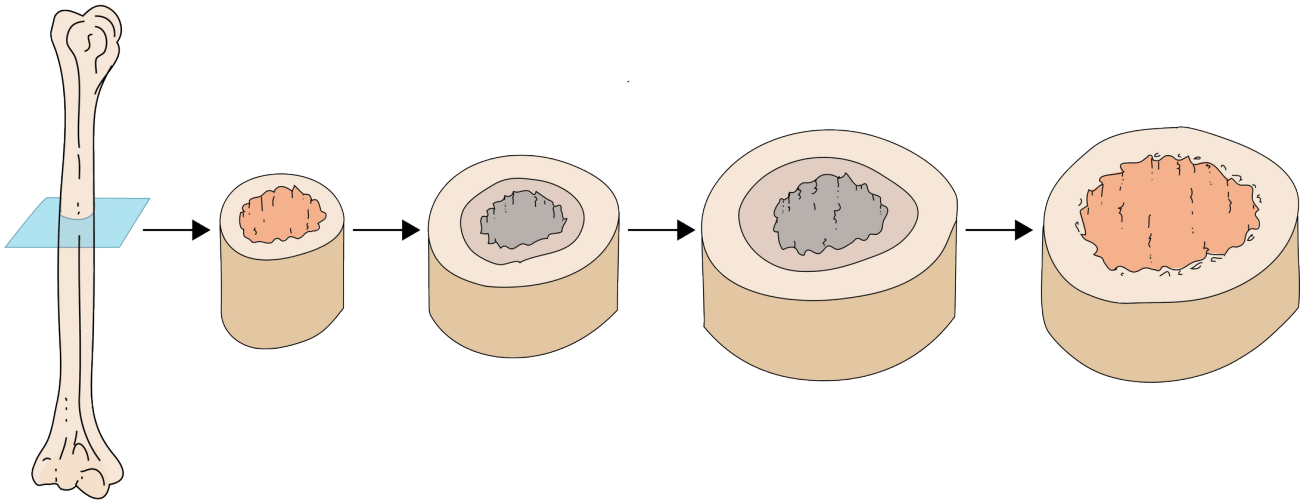

Figure 5.4.5: Appositional Growth. Growth in the diameter of a bone is known as appositional growth. Both osteoblasts and osteoclasts are active during the process of remodeling. ("Appositional Growth" by Daniel Donnelly is licensed under CC BY 4.0)

Bone Remodeling

The process in which matrix is resorbed on one surface of a bone and deposited on another is known as bone modeling. Modeling primarily takes place during a bone's growth. However, in adult life, bone undergoes **remodeling**, in which resorption of old or damaged bone takes place on the same surface where osteoblasts lay new bone to replace that which is resorbed. Injury, exercise,

and other activities lead to remodeling. Those influences are discussed later in the chapter, but even without injury or exercise, about 5 to 10 percent of the skeleton is remodeled annually by destroying old bone and renewing it with fresh bone.

DISEASES OF THE...

Skeletal System

Osteogenesis imperfecta (OI) is a genetic disease in which bones do not form properly and therefore are fragile and break easily. It is also called *brittle bone disease*. The disease is present from birth and affects a person throughout life.

The genetic mutation that causes OI affects the body's production of collagen, one of the critical components of bone matrix. The severity of the disease can range from mild to severe. Those with the most severe forms of the disease sustain many more fractures than those with a mild form. Frequent and multiple fractures (red arrows) typically lead to bone deformities and short stature. Bowing of the long bones and curvature of the spine are also common in people afflicted with OI. Curvature of the spine makes breathing difficult because the lungs are compressed.

Because collagen is such an important structural protein in many parts of the body, people with OI may also experience fragile skin, weak muscles, loose joints, easy bruising, frequent nosebleeds, brittle teeth, blue sclera, and hearing loss. There is no known cure for OI. Treatment focuses on helping the person retain as much independence as possible while minimizing fractures and maximizing mobility. Toward that end, safe exercises, like swimming, in which the body is less likely to experience collisions or compressive forces, are recommended. Braces to support legs, ankles, knees, and wrists are used as needed. Canes, walkers, or wheelchairs can also help compensate for weaknesses.

When bones do break, casts, splints, or wraps are used. In some cases, metal rods may be surgically implanted into the long bones of the arms and legs. Research is currently being conducted on using bisphosphonates to treat OI. Smoking and being overweight are especially risky in people with OI, since smoking is known to weaken bones, and extra body weight puts additional stress on the bones.

Concept Review

All bone formation is a replacement process. Embryos develop a cartilaginous skeleton and various membranes. During development, these are replaced by bone during the ossification process. In intramembranous ossification, bone develops directly from sheets of mesenchymal connective tissue. In endochondral ossification, bone develops by replacing hyaline cartilage. Activity in the epiphyseal plate enables bones to grow in length. Modeling allows bones to grow in diameter. Remodeling occurs

as bone is resorbed and replaced by new bone. Osteogenesis imperfecta is a genetic disease in which collagen production is altered, resulting in fragile, brittle bones.

Review Questions

Query 5.4.1

This interactive element is not available in this format. Visit the link or scan the QR code to access it online.

View this Interactive Content online

Critical Thinking Questions

Query 5.4.2

This interactive element is not available in this format. Visit the link or scan the QR code to access it online.

View this Interactive Content online

Query 5.4.3

This interactive element is not available in this format. Visit the link or scan the QR code to access it online.

View this Interactive Content online

Glossary

Query 5.4.4

This interactive element is not available in this format. Visit the link or scan the QR code to access it online.

View this Interactive Content online

Contributors and Attributions

- OpenStax Anatomy & Physiology (CC BY 4.0). Access for free at https://openstax.org/books/anatomy-and-physiology

This page titled 5.4: Bone Formation and Development is shared under a CC BY-NC-SA 4.0 license and was authored, remixed, and/or curated by Jennifer Lange et al..

- 5.4: Bone Formation and Development by Whitney Menefee, Julie Jenks, Chiara Mazzasette, and Kim-Leiloni Nguyen is licensed CC BY 4.0.

5.5: Fractures and Bone Repair

By the end of this section, you will be able to:

- Differentiate among the different types of fractures
- Describe the steps involved in bone repair

A **fracture** is a broken bone. It will heal whether or not a physician resets it in its anatomical position. If the bone is not reset correctly, the healing process will keep the bone in its deformed position. When a broken bone is manipulated and set into its natural position without surgery, the procedure is called a **closed reduction**. **Open reduction** requires surgery to expose the fracture and reset the bone. While some fractures can be minor, others are quite severe and result in grave complications. For example, a fractured diaphysis of the femur has the potential to release fat globules into the bloodstream. These can become lodged in the capillary beds of the lungs, leading to respiratory distress and if not treated quickly, death.

Types of Fractures

Fractures are classified by their complexity, location, and other features (Figure 5.5.1 and Figure 5.5.2). Table 5.5.1 outlines common types of fractures. Some fractures may be described using more than one term because it may have the features of more than one type (e.g., an open transverse fracture).

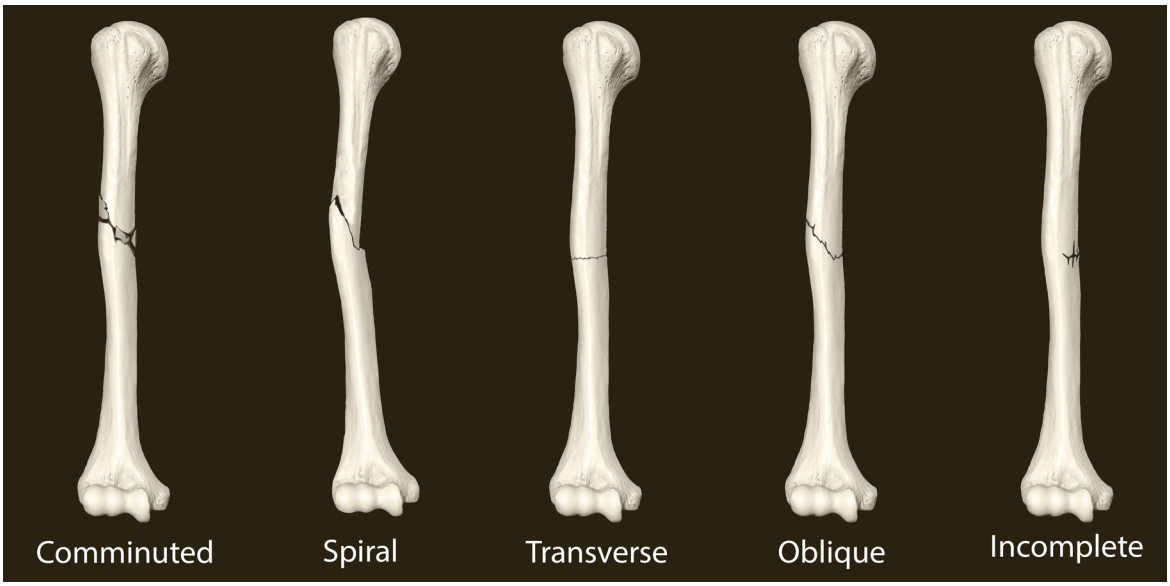

Figure 5.5.1: Types of Fractures. Compare the angle and number of pieces in different types of fractures: comminuted, spiral, transverse, oblique, and incomplete. *(Image credit: "Types of Fractures" by Jennifer Lange is licensed under CC BY-NC-SA 4.0, modification of image from Anatomy Standard under CC BY-NC 4.0.)*

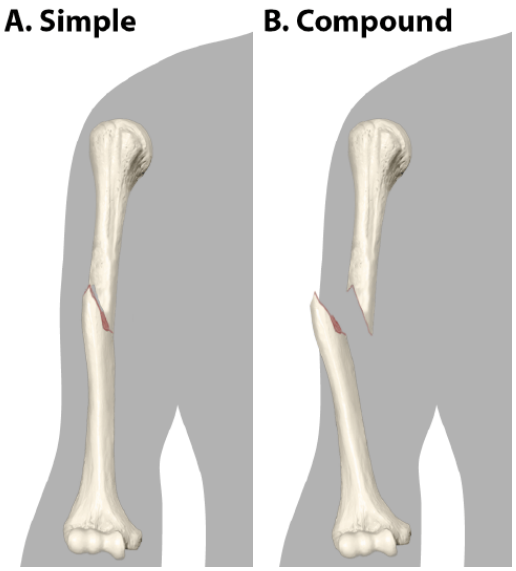

Figure 5.5.2: Simple and Compound Fractures. Simple fractures do not break through the skin surface, whereas compound fractures do. (Image credit: "Simple and Compound Fractures" by Jennifer Lange is licensed under CC BY-NC-SA 4.0, modification of image from Anatomy Standard under CC BY-NC 4.0.)

Table 5.5.1: Types of Fractures

Type of fracture	Description
Transverse	Occurs straight across the long axis of the bone
Oblique	Occurs at an angle that is not 90 degrees
Spiral	Bone segments are pulled apart as a result of a twisting motion
Comminuted	Several breaks result in many small pieces between two large segments
Impacted	One fragment is driven into the other, usually as a result of compression
Greenstick (children), Incomplete (adults)	A partial fracture in which only one side of the bone is broken
Compound (or Open)	A fracture in which at least one end of the broken bone tears through the skin; carries a high risk of infection
Simple (or Closed)	A fracture in which the skin remains intact

Bone Repair

When a bone breaks, blood flows from any vessel torn by the fracture. These vessels could be in the periosteum, osteons, and/or medullary cavity. The blood begins to clot, and about six to eight hours after the fracture, the clotting blood has formed a **fracture hematoma** (Figure 5.5.3.a). The disruption of blood flow to the bone results in the death of bone cells around the fracture.

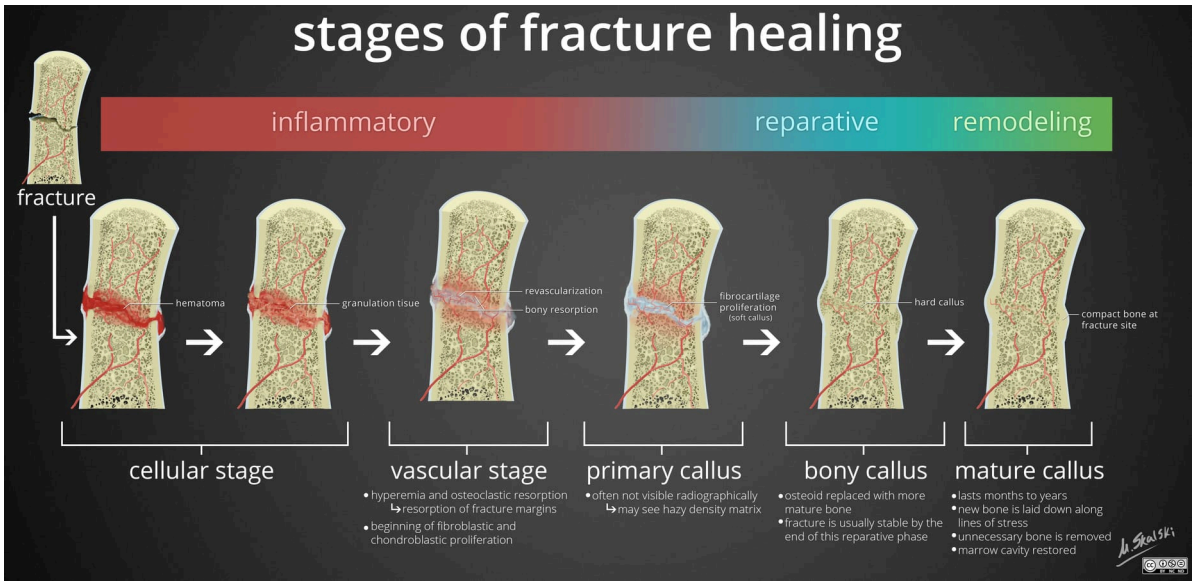

Figure 5.5.3: Stages in Fracture Repair. The healing of a bone fracture follows a series of progressive steps: a fracture hematoma forms, blood vessels grow into the area, a cartilaginous callus forms, the cartilage ossifies into a bony callus, the callus remodels. *(Image credit: "Stages of Fracture Repair" Case courtesy of Matt Skalski. From the case rID: 57418.)*

Within about 48 hours after the fracture, chondrocytes from the endosteum have created an **internal callus** (plural = calli) by secreting a fibrocartilaginous matrix between the two ends of the broken bone, while the periosteal chondrocytes and osteoblasts create an **external callus** of hyaline cartilage and bone, respectively, around the outside of the break (Figure 5.5.3.*b*). This stabilizes the fracture.

Over the next several weeks, osteoclasts resorb the dead bone; osteogenic cells become active, divide, and differentiate into osteoblasts. The cartilage in the calli is replaced by trabecular bone via endochondral ossification (Figure 5.5.3.*c*).

Eventually, the internal and external calli unite, compact bone replaces spongy bone at the outer margins of the fracture, and healing is complete. A slight swelling may remain on the outer surface of the bone, but quite often, that region undergoes remodeling (Figure 5.5.3.*d*), and no external evidence of the fracture remains.

Concept Review

Fractured bones may be repaired by closed reduction or open reduction. Fractures are classified by their complexity, location, and other features. Common types of fractures are transverse, oblique, spiral, comminuted, impacted, greenstick, open (or compound), and closed (or simple). Healing of fractures begins with the formation of a hematoma, followed by internal and external calli. Osteoclasts resorb dead bone, while osteoblasts create new bone that replaces the cartilage in the calli. The calli eventually unite, remodeling occurs, and healing is complete.

Review Questions

Query 5.5.1

This interactive element is not available in this format. Visit the link or scan the QR code to access it online.

View this Interactive Content online

Critical Thinking Questions

Query 5.5.2

This interactive element is not available in this format. Visit the link or scan the QR code to access it online.

View this Interactive Content online

Query 5.5.3

This interactive element is not available in this format. Visit the link or scan the QR code to access it online.

View this Interactive Content online

Glossary

Query 5.5.4

This interactive element is not available in this format. Visit the link or scan the QR code to access it online.

View this Interactive Content online

Contributors and Attributions

- OpenStax Anatomy & Physiology (CC BY 4.0). Access for free at https://openstax.org/books/anatomy-and-physiology

This page titled 5.5: Fractures and Bone Repair is shared under a CC BY-NC-SA 4.0 license and was authored, remixed, and/or curated by Jennifer Lange et al..

- 5.5: Fractures - Bone Repair by Whitney Menefee, Julie Jenks, Chiara Mazzasette, and Kim-Leiloni Nguyen is licensed CC BY 4.0.

5.6: Exercise, Nutrition, Hormones, and Bone Tissue Health

By the end of this section, you will be able to:

- Describe the effect exercise has on bone tissue
- Discuss the role nutrients play in bone health
- Describe the effects of hormones on bone tissue
- Explain how the structure of bone is affected by insufficiencies in exercise, nutrients, and hormones.

All of the organ systems of your body are interdependent, and the skeletal system is no exception. The food you take in via your digestive system and the hormones secreted by your endocrine system affect your bones. Even using your muscles to engage in exercise has an impact on your bones.

Exercise and Bone Tissue

Functions of bone are to provide support for the body by providing a framework that resists outside forces such as gravity and provides solid anchoring points for muscles to pull against to cause movement. Applying these stressors on the bone tissue cause our osteoblasts to build matrix in order to provide sufficient resistance. The two mays in which bone structure adapts to such forces are to alter the thickness of the cortical (surface) compact bone and to align the trabeculae in the cancellous bone. The trabecular pattern of growth follows the course of stress lines along the bone and the thickest trabeculae develop along the lines of maximum stress.

If the stressors on a particular bone increase, then the bone will remodel itself to become stronger and resist the new load. Increased stressors could be carrying more weight (either by increasing body mass or carrying external weight, such as a backpack), increases the amount of weight-bearing activities, and strengthening muscles. The opposite will also happen if such stressors decrease: the bone will remodel itself to removed un-needed matrix. The proximal femur in Figure 5.6.1 below shows these lines of tension and compression.

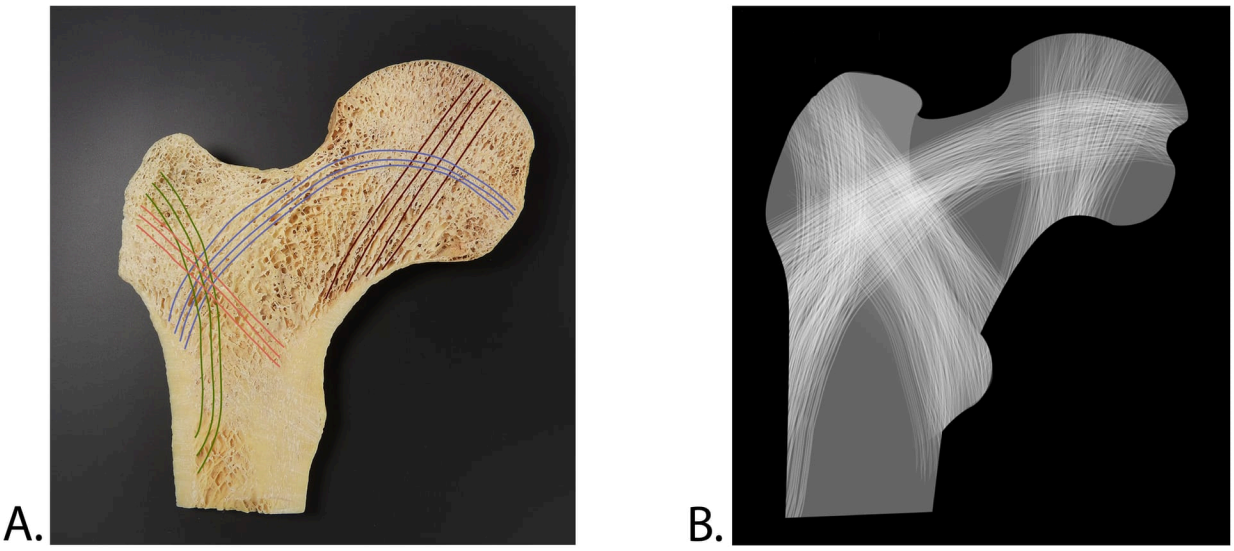

Figure 5.6.1: Lines of Force. The lines of tension and compression can be seen in the trabecular arrangement in the cut femur (A), showing alignment with a model of the lines of force (B). *(Image credit: "Lines of Force" by Jennifer Lange is licensed under CC BY-NC-SA 4.0. Original images from (A) MAKY.OREL, CC0, via Wikimedia Commons, and (B) Case courtesy of Matt Skalski, Radiopaedia.org, from the case rID: 19963.)*

DISEASES OF THE...

Skeletal System

During long space missions, astronauts can lose approximately 1 to 2 percent of their bone mass per month. This loss of bone mass is thought to be caused by the lack of mechanical stress on astronauts' bones due to the low gravitational forces in space. Lack of mechanical stress causes bones to lose mineral salts and collagen fibers, and thus strength. Similarly, mechanical stress stimulates the deposition of mineral salts and collagen fibers. The internal and external structure of a bone will change as stress increases or decreases so that the bone is an ideal size and weight for the amount of activity it endures. That is why people who exercise regularly have thicker bones than people who are more sedentary. It is also why a broken bone in a cast atrophies while its contralateral mate maintains its concentration of mineral salts and collagen fibers. Bones undergo remodeling as a result of forces (or lack of forces) placed on them.

Numerous, controlled studies have demonstrated that people who exercise regularly have greater bone density than those who are more sedentary. Any type of exercise will stimulate the deposition of more bone tissue, but resistance training has a greater effect than cardiovascular activities. Resistance training is especially important to slow down the eventual bone loss due to aging and for preventing osteoporosis.

NASA astronaut Steve Swanson, Expedition 40 commander, equipped with a bungee harness, exercises on the Combined Operational Load Bearing External Resistance Treadmill (COLBERT) in the International Space Station.

(Image credit: "iss040e086619" by NASA Johnson is licensed under CC BY-NC 2.0)

Nutrition and Bone Tissue: Calcium and Vitamin D

Calcium is a critical component of the bone extracellular matrix, especially in the form of calcium phosphate and calcium carbonate. Calcium must be obtained from the diet, but it cannot be absorbed by the small intestine without vitamin D. Therefore, intake of vitamin D is also critical to bone health. Milk and other dairy foods are key sources of dietary calcium as are green leafy vegetables, broccoli, and intact salmon and canned sardines with their soft bones. Nuts, beans, seeds, and shellfish provide calcium in smaller quantities.

Vitamin D is not found naturally in many foods, except for fatty fish like salmon and tuna or fortified milk or cereal, so the body must produce it from a cholesterol precursor. Sunlight on the skin triggers the body to produce vitamin D, but many people, especially those of darker complexion and those living in northern latitudes where the sun's rays are not as strong, are deficient in vitamin D. In cases of deficiency, a doctor can prescribe a vitamin D supplement.

Hormones and Bone Tissue

The endocrine system produces and secretes hormones, many of which interact with the skeletal system. These hormones are involved in controlling bone growth, maintaining bone once it is formed, and remodeling it.

Hormones That Influence Osteoblasts

Several hormones are necessary for controlling bone growth and maintaining the bone matrix. The pituitary gland secretes growth hormone (GH), which, as its name implies, controls bone growth in several ways: it triggers chondrocyte proliferation in epiphyseal plates, resulting in the increasing length of long bones, and it increases calcium retention and stimulates osteoblastic activity, which improves bone density.

GH is not alone in stimulating bone growth and maintaining osseous tissue. During puberty, the sex hormones (estrogen from the ovaries, testosterone from the testes) also promote osteoblastic activity and production of bone matrix, and they are responsible for the growth spurt that often occurs during adolescence. They also promote the conversion of the epiphyseal plate to the epiphyseal line (i.e., cartilage to its bony remnant), thus bringing an end to the longitudinal growth of bones.

AGING AND THE...

Skeletal System:

Osteoporosis is a disease characterized by a decrease in bone mass that occurs when the rate of bone resorption exceeds the rate of bone formation, a common occurrence as the body ages. Histologically, osteoporosis is characterized by a reduction in the thickness of compact bone (cortical thinning) and in the number and size of trabeculae in cancellous bone (trabecular thinning) (Figure 5.6.4). As a result of having fewer, thinner trabeculae the spaces within the cancellous bone become larger, which is where the "porous" appearance comes from.

While osteoporosis can involve any bone, it most commonly affects the proximal end of the femur and the vertebrae. As a result of the loss of bone density, the osseous tissue may not provide adequate support for everyday functions and something as simple as a sneeze can cause a vertebral fracture. When an elderly person falls and breaks a hip (really, the femur), it is very likely the femur that broke first, which resulted in the fall.

For many elderly individuals, a hip fracture can be life threatening. The fracture itself may not be serious, but the immobility that comes during the healing process can lead to the formation of blood clots that can lodge in the capillaries of the lungs resulting in respiratory failure, pneumonia due to the lack of poor air exchange that accompanies immobility, pressure sores (bed sores) that allow pathogens to enter the body and cause infections, and urinary tract infections from catheterization.

Current treatments for managing osteoporosis include bisphosphonates (the same medications often used in Paget's disease), calcitonin, and estrogen (for women only). Bisphophonates is a class of medications that inhibit osteoclast activity, acting in synergy with calcitonin. Estrogen promote osteoblast activity. Another important step in managing the potential outcomes from osteoporosis is minimizing the risk of falls, for example, by removing tripping hazards.

A.

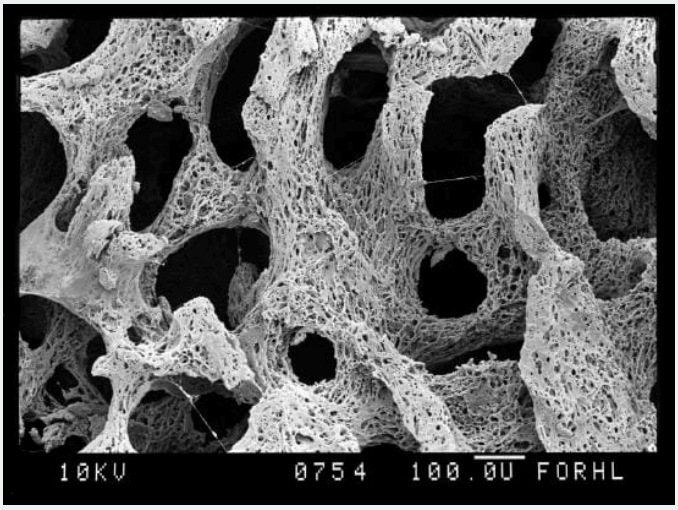

B.

Figure 5.6.4: Osteoporosis. In osteoporosis the bone becomes less dense and as bone mass is lost. As seen in the SEM image, the trabeculae of the spongy bone develop pores that weakens their structure and the bone's ability to withstand external forces. *(Image credits: A. "Osteoporosis Effect and Locations" by BruceBlaus is licensed under CC BY-SA 4.0 , via Wikimedia Commons; B. "SEM bone, rotten trabeculae, osteoporosis" by David Gregory and Debbie Marshall is licensed under CC BY 4.0.*

Bone mass (total mass of skeletal calcium in grams) peaks around 30 years of age for both males and females (Figure 5.6.4). Females lose bone mass more quickly than males starting at about 50 years of age. This occurs because 50 is the approximate age at which females go through menopause and the ovaries cease the production of estrogen, a hormone that promotes osteoblastic activity and production of bone matrix. Thus, osteoporosis is more common in females than in males, but males can develop it too. Anyone with a family history of osteoporosis has a greater risk of developing the disease, so the best treatment is prevention, which should start with a childhood diet that includes adequate intake of calcium and vitamin D and a lifestyle that includes weight-bearing exercise. Promoting proper nutrition and weight-bearing exercise early in life can maximize bone mass before the age of 30, thus reducing the risk of osteoporosis.

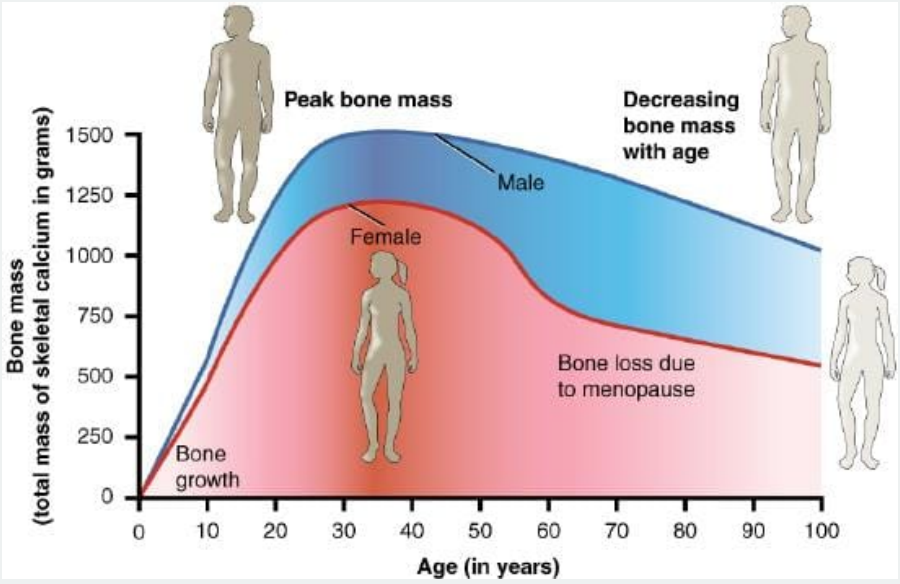

Figure 5.6.4: Graph Showing Relationship Between Age and Bone Mass. Bone density peaks at about 30 years of age. Females lose bone mass more rapidly than males. *(Image credit: "Age and Bone Mass" by OpenStax is licensed under CC BY 3.0.)*

Hormones That Influence Osteoclasts

Bone modeling and remodeling require osteoclasts to resorb unneeded, damaged, or old bone, and osteoblasts to lay down new bone. Two hormones that affect the osteoclasts are parathyroid hormone (PTH) and calcitonin. These two hormones are released in response to blood calcium levels that are too low or too high and their effects are targeted at maintaining homeostatic blood calcium. PTH stimulates osteoclast proliferation and activity. As a result, calcium is released from the bones into the circulation, thus increasing the calcium ion concentration in the blood. Calcitonin, a hormone secreted by the thyroid gland, has some effects that counteract those of PTH. Calcitonin inhibits osteoclast activity and stimulates calcium uptake by the bones, thus reducing the concentration of calcium ions in the blood. As evidenced by their opposing functions in maintaining calcium homeostasis, PTH and calcitonin are generally *not* secreted at the same time.

Concept Review

Mechanical stress stimulates the deposition of mineral salts and collagen fibers within bones. Calcium, the predominant mineral in bone, cannot be absorbed from the small intestine if vitamin D is lacking. Vitamin K supports bone mineralization and may have a synergistic role with vitamin D. Magnesium and fluoride, as structural elements, play a supporting role in bone health. Omega-3 fatty acids reduce inflammation and may promote production of new osseous tissue. Growth hormone increases the length of long bones, enhances mineralization, and improves bone density. Thyroxine stimulates bone growth and promotes the synthesis of bone matrix. The sex hormones (estrogen from the ovaries, testosterone from the testes) promote osteoblastic activity and the production of bone matrix, are responsible for the adolescent growth spurt, and promote closure of the epiphyseal plates. Osteoporosis is a disease characterized by decreased bone mass that is common in aging adults. Calcitriol stimulates the digestive tract to absorb calcium and phosphate. Parathyroid hormone (PTH) stimulates osteoclast proliferation and resorption of bone by osteoclasts. Vitamin D plays a synergistic role with PTH in stimulating the osteoclasts. Additional functions of PTH include promoting reabsorption of calcium by kidney tubules and indirectly increasing calcium absorption from the small intestine. Calcitonin inhibits osteoclast activity and stimulates calcium uptake by bones.

Review Questions

Query 5.6.1

This interactive element is not available in this format. Visit the link or scan the QR code to access it online.

View this Interactive Content online

Critical Thinking Questions

Query 5.6.2

This interactive element is not available in this format. Visit the link or scan the QR code to access it online.

View this Interactive Content online

Query 5.6.3

This interactive element is not available in this format. Visit the link or scan the QR code to access it online.

View this Interactive Content online

Glossary

Query 5.6.4

This interactive element is not available in this format. Visit the link or scan the QR code to access it online.

View this Interactive Content online

Contributors and Attributions

- OpenStax Anatomy & Physiology (CC BY 4.0). Access for free at https://openstax.org/books/anatomy-and-physiology

This page titled 5.6: Exercise, Nutrition, Hormones, and Bone Tissue Health is shared under a CC BY-NC-SA 4.0 license and was authored, remixed, and/or curated by Jennifer Lange et al..

- 5.6: Exercise, Nutrition, Hormones, and Bone Tissue by Whitney Menefee, Julie Jenks, Chiara Mazzasette, and Kim-Leiloni Nguyen is licensed CC BY 4.0.
- 5.4: Bone Formation and Development by Whitney Menefee, Julie Jenks, Chiara Mazzasette, and Kim-Leiloni Nguyen is licensed CC BY 4.0.

5.7: Bone Classification

By the end of this section, you will be able to:

- Classify bones according to their shapes
- Describe the function of each category of bones

The 206 bones that compose the adult skeleton are divided into five categories based on their shapes (Figure 5.7.1). Their shapes and their functions are related such that each categorical shape of bone has a distinct function.

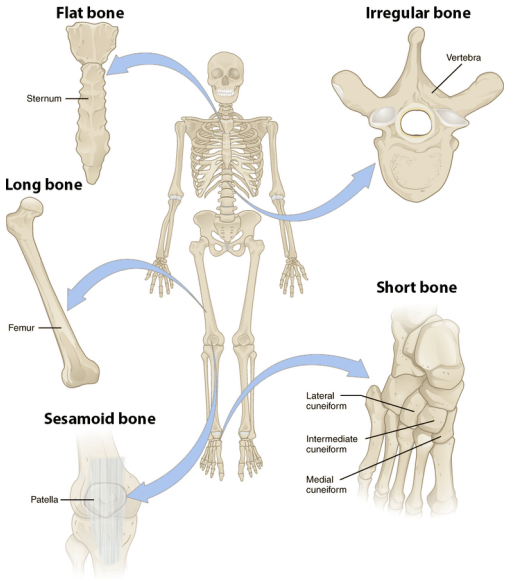

Figure 5.7.1: Classifications of Bones. Bones are classified according to their shape. *(Image credit: "Bone Classifications" by Jennifer Lange is licensed under CC BY-NC-SA 4.0 , modification of original by OpenStax .)*

Long Bones

A **long bone** is one that is cylindrical in shape, being longer than it is wide. Keep in mind, however, that the term describes the shape of a bone, not its size. Long bones are found in the arms (humerus, ulna, radius) and legs (femur, tibia, fibula), as well as in the hands (metacarpals, phalanges) and feet (metatarsals, phalanges). Long bones function as levers; they move when muscles contract.

Short Bones

A **short bone** is one that is cube-like in shape, being approximately equal in length, width, and thickness. The only short bones in the human skeleton are in the carpals of the wrists and the tarsals, such as the lateral cuneiform, intermediate cuneiform, and medial cuneiform, of the ankles. Short bones provide stability and support as well as some limited motion.

Flat Bones

The term "**flat bone**" is somewhat of a misnomer because, although a flat bone is typically thin, it is also often curved. Examples include the cranial (skull) bones, the scapulae (shoulder blades), the sternum (breastbone), and the ribs. Flat bones serve as points of attachment for muscles and often protect internal organs.

Irregular Bones

An **irregular bone** is one that does not have any easily characterized shape and therefore does not fit any other classification. These bones tend to have more complex shapes, like the vertebrae that support the spinal cord and protect it from compressive forces. Many facial bones, particularly the ones containing sinuses, are classified as irregular bones. While most irregular bones function to protect internal organs, because each is irregular in its own way, there is no one general function that fits this class of bones.

Sesamoid Bones

A **sesamoid bone** is a small, round bone that, as the name suggests, is shaped like a sesame seed. These bones form in tendons (the sheaths of tissue that connect bones to muscles) where a great deal of pressure is generated in a joint. The sesamoid bones protect tendons by helping them overcome compressive forces. Sesamoid bones vary in number and placement from person to person but are typically found in tendons associated with the feet, hands, and knees. The patellae (singular = patella) are the only sesamoid bones found in common with every person. Table 5.7.1 reviews bone classifications with their associated features, functions, and examples.

Table 5.7.1: Bone Classifications

Bone classification	Features	Function(s)	Examples
Long	Cylinder-like shape, longer than it is wide	Leverage	Femur, tibia, fibula, metatarsals, humerus, ulna, radius, metacarpals, phalanges
Short	Cube-like shape, approximately equal in length, width, and thickness	Provide stability, support, while allowing for some motion	Carpals, tarsals
Flat	Thin and curved	Points of attachment for muscles; protectors of internal organs	Sternum, ribs, scapulae, cranial bones
Irregular	Complex shape	Protect internal organs	Vertebrae, facial bones
Sesamoid	Small and round; embedded in tendons	Protect tendons from compressive forces	Patellae

Concept Review

Bones can be classified according to their shapes. Long bones, such as the femur, are longer than they are wide. Short bones, such as the carpals, are approximately equal in length, width, and thickness. Flat bones are thin, but are often curved, such as the ribs. Irregular bones such as those of the face have no characteristic shape. Sesamoid bones, such as the patellae, are small and round, and are located in tendons.

Review Questions

Query 5.7.1

This interactive element is not available in this format. Visit the link or scan the QR code to access it online.

View this Interactive Content online

Critical Thinking Questions

Query 5.7.2

This interactive element is not available in this format. Visit the link or scan the QR code to access it online.

View this Interactive Content online

Query 5.7.3

This interactive element is not available in this format. Visit the link or scan the QR code to access it online.

View this Interactive Content online

Glossary

Query 5.7.4

This interactive element is not available in this format. Visit the link or scan the QR code to access it online.

View this Interactive Content online

Contributors and Attributions

- OpenStax Anatomy & Physiology (CC BY 4.0). Access for free at https://openstax.org/books/anatomy-and-physiology

This page titled 5.7: Bone Classification is shared under a CC BY-NC-SA 4.0 license and was authored, remixed, and/or curated by Jennifer Lange et al..

- 5.7: Bone Classification by Whitney Menefee, Julie Jenks, Chiara Mazzasette, and Kim-Leiloni Nguyen is licensed CC BY 4.0.

5.8: Anatomical Atlas - Bone Tissue and Bone Structure

A compendium of anatomical images: slides, models, and/or cadavers.

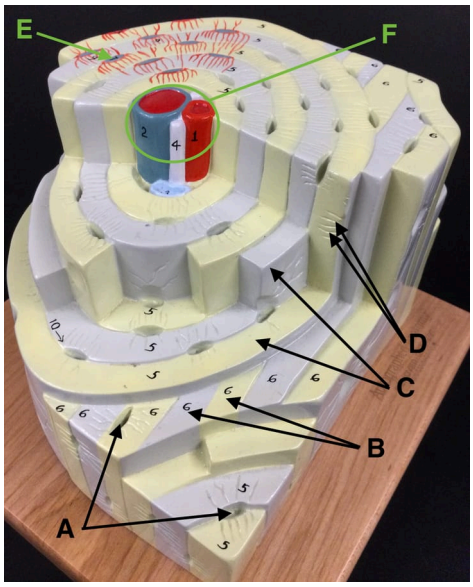

Image Credit

"Osteon Model - Atlas" by Jennifer Lange is licensed under CC BY-NC-SA 4.0.

Answer Key (click to show/hide answers)

A - lacunae

B - interstitial lamellae

C - concentric lamellae

D - canaliculi

E - osteocyte

F - central canal with blood vessels and nerve

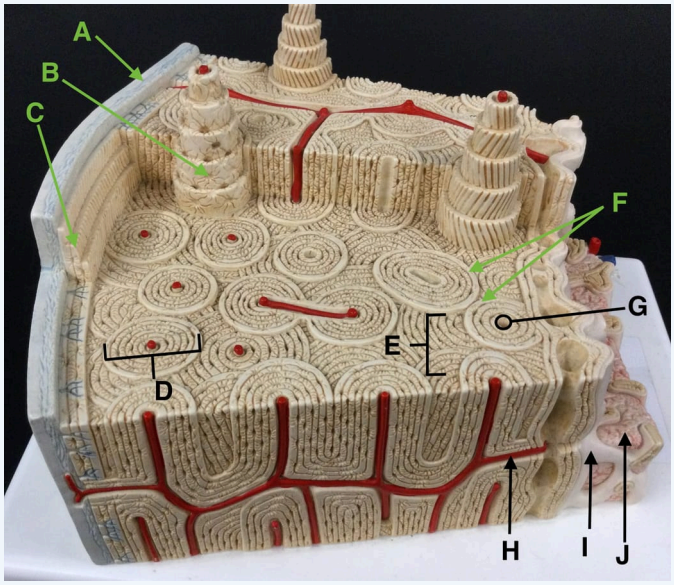

Image Credit

"Compact Bone Model - Atlas" by Jennifer Lange is licensed under CC BY-NC-SA 4.0.

Answer Key (click to show/hide answers)

A - periosteum

B - lacuna

C - circumferential lamellae

D - osteon

E - interstitial lamellae

F - concentric lamellae

G - central canal

H - perforating canal with blood vessel

I - endosteum

J - bone marrow

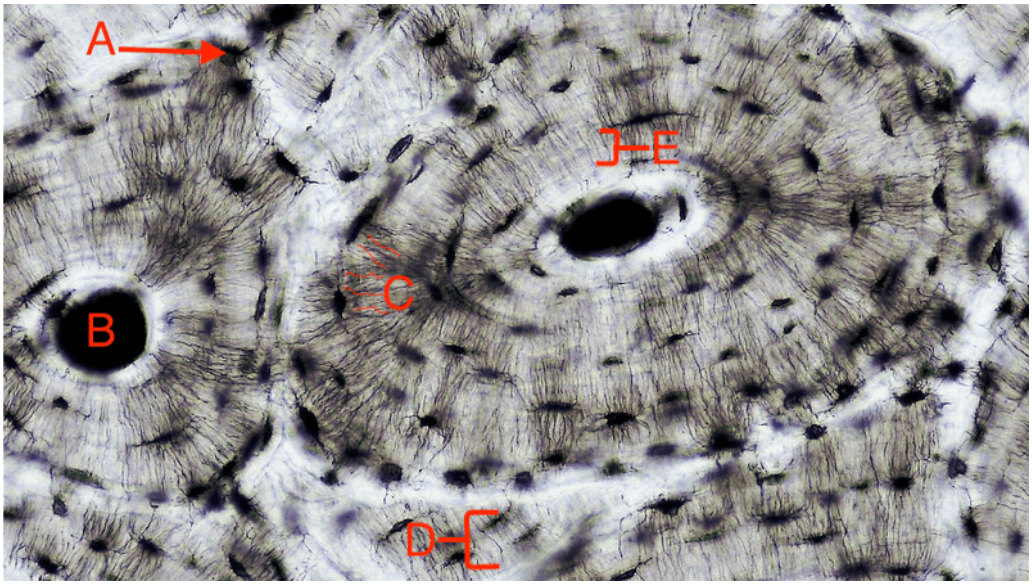

Image Credit

"Compact Bone Histology - Atlas" by Jennifer Lange is licensed under CC BY-NC-SA 4.0, micrograph provided by Berkshire Community College Bioscience Image Library is in the Public Domain.)

Answer Key (click to show/hide answers)

A - lacuna (space for osteocyte)

B - central canal

C - canaliculi

D - interstitial lamellae

E - concentric lamellae

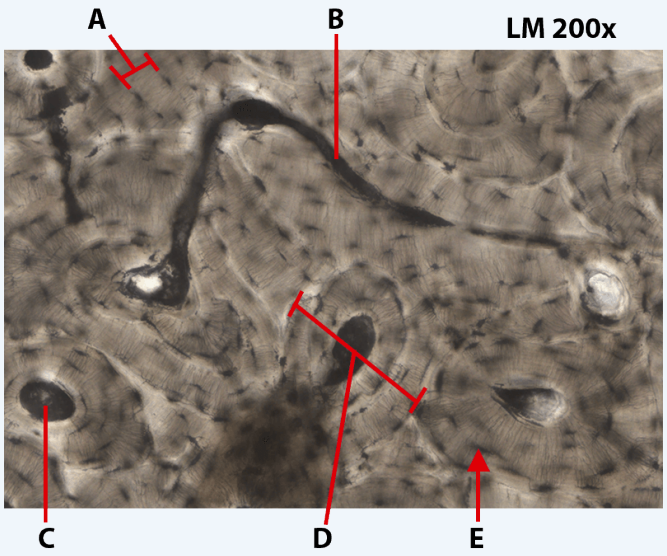

Image credit:

"Histology of Compact Bone" by Jennifer Lange, slide provided by the Regents of the University of Michigan Medical School under CC BY-NC-SA 4.0 © 2022.

Answer Key (click to show/hide answers)

Compact Bone Tissue

A - concentric lamella

B - perpendicular (Volkmann) canal

C - central canal

D - osteon

E - lacuna (with osteocyte)

Image Credit

"Spongy Bone Histology - Atlas" by Jennifer Lange is licensed under under CC BY-NC-SA 4.0, micrographs provided by Virginia Commonwealth University.)

Answer Key (click to show/hide answers)

A - ostocyte

B - osteoblast

C - trabecula

D - lacuna

E - ostoclast

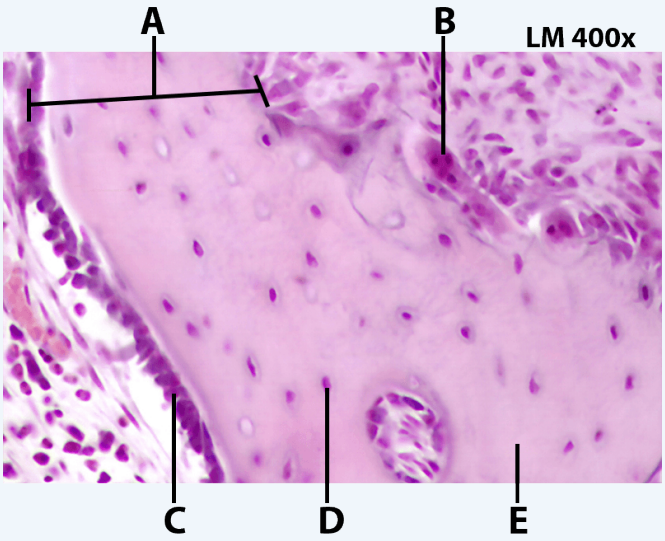

Image credit:

"Histology of Cancellous Bone" by Jennifer Lange, slide provided by the Regents of the University of Michigan Medical School under CC BY-NC-SA 4.0 © 2022.

Answer Key (click to show/hide answers)

Cancellous (Spongy) Bone Tissue

A - trabecula

B - osteoclast

C - osteoblast

D - osteocyte

E - extracellular matrix (osteoid)

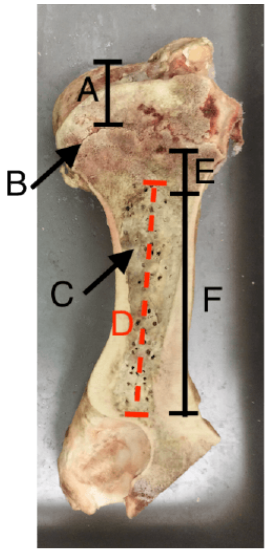

Image Credit

"Long Bone - Atlas" by Jennifer Lange is licensed under CC BY-NC-SA 4.0.

Answer Key (click to show/hide answers)

A - epiphysis (distal)

B - epiphyseal plate (line)

C - yellow bone marrow

D - marrow cavity

E - metaphysis (distal)

F - diaphysis

This page titled 5.8: Anatomical Atlas - Bone Tissue and Bone Structure is shared under a CC BY-NC-SA 4.0 license and was authored, remixed, and/or curated by Jennifer Lange et al..

5.9: Practice Practical - Bone Tissue and Bone Structure

Answer each of the following questions by typing your answer into the box(es).

Query 5.9.1

This interactive element is not available in this format. Visit the link or scan the QR code to access it online.

View this Interactive Content online

Query 5.9.1

This interactive element is not available in this format. Visit the link or scan the QR code to access it online.

View this Interactive Content online

Query 5.9.1

This interactive element is not available in this format. Visit the link or scan the QR code to access it online.

View this Interactive Content online

Query 5.9.1

This interactive element is not available in this format. Visit the link or scan the QR code to access it online.

View this Interactive Content online

Query 5.9.1

This interactive element is not available in this format. Visit the link or scan the QR code to access it online.

View this Interactive Content online

Query 5.9.1

This interactive element is not available in this format. Visit the link or scan the QR code to access it online.

View this Interactive Content online

This page titled 5.9: Practice Practical - Bone Tissue and Bone Structure is shared under a CC BY-NC-SA 4.0 license and was authored, remixed, and/or curated by Jennifer Lange et al..

6: AXIAL AND APPENDICULAR SKELETON

6.1: Introduction to the Skeleton System

6.2: Divisions of the Skeletal System

6.3: The Skull

6.4: The Vertebral Column

6.5: The Thoracic Cage

6.6: The Pectoral Girdle

6.7: Bones of the Upper Limb

6.8: The Pelvic Girdle and Pelvis

6.9: Bones of the Lower Limb

6.10: Embryonic Development of the Skeleton

6.11: Anatomical Atlas - Skeleton

6.12: Practice Practical - Skeleton

This page titled 6: Axial and Appendicular Skeleton is shared under a CC BY-NC-SA 4.0 license and was authored, remixed, and/or curated by Jennifer Lange et al..

- 6: Axial Skeleton by Whitney Menefee, Julie Jenks, Chiara Mazzasette, and Kim-Leiloni Nguyen is licensed CC BY 4.0.

6.1: Introduction to the Skeleton System

Chapter Learning Objectives

After studying this chapter, you will be able to:

- Describe the functions of the skeletal system and define its two major subdivisions
- Identify the bones and bony structures of the skull, the cranial suture lines, the cranial fossae, and the openings in the skull
- Discuss the vertebral column and regional variations in its bony components and curvatures
- Describe the components of the thoracic cage
- Discuss the embryonic development of the axial skeleton

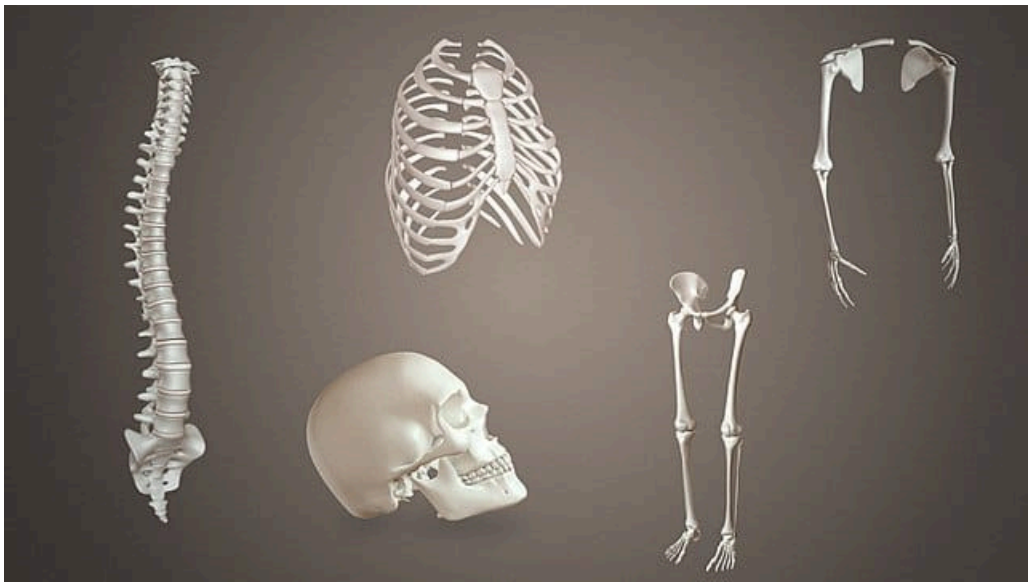

Figure 6.1.1: Bones of the Human Skeleton. (Image credit: "Bones of skeleton" by Scientific Animations is licensed under CC BY-SA 4.0, via Wikimedia Commons)

The skeletal system forms the rigid internal framework of the body. It consists of the bones, cartilages, and ligaments. Bones support the weight of the body, allow for body movements, and protect internal organs. Cartilage provides flexible strength and support for body structures such as the thoracic cage, the external ear, and the trachea and larynx. At joints of the body, cartilage can also unite adjacent bones or provide cushioning between them. Ligaments are the strong connective tissue bands that hold the bones at a moveable joint together and serve to prevent excessive movements of the joint that would result in injury. The skeleton is moved by the muscles of the body, which are firmly attached to bones, often via connective tissue structures called tendons. As muscles contract, they pull on the bones to produce movements of the body. Thus, without a skeleton, you would not be able to stand, run, or even feed yourself!

Each bone of the body serves a particular function, and therefore bones vary in size, shape, and strength based on these functions. For example, the bones of the lower back and lower limb are thick and strong to support your body weight. Similarly, the size of a bony landmark that serves as a muscle attachment site on an individual bone is related to the strength of this muscle. Muscles can apply very strong pulling forces to the bones of the skeleton. To resist these forces, bones have enlarged bony landmarks at sites where powerful muscles attach. This means that not only the size of a bone, but also its shape, is related to its function. For this reason, the identification of bony landmarks is important during your study of the skeletal system.

Bones are also dynamic organs that can modify their strength and thickness in response to changes in muscle strength or body weight. Thus, muscle attachment sites on bones will thicken if you begin a workout program that increases muscle strength. Similarly, the walls of weight-bearing bones will thicken if you gain body weight or begin pounding the pavement as part of a new running regimen. In contrast, a reduction in muscle strength or body weight will cause bones to become thinner. This may happen

during a prolonged hospital stay, following limb immobilization in a cast, or going into the weightlessness of outer space. Even a change in diet, such as eating only soft food due to the loss of teeth, will result in a noticeable decrease in the size and thickness of the jaw bones.

Contributors and Attributions

- OpenStax Anatomy & Physiology (CC BY 4.0). Access for free at https://openstax.org/books/anatomy-and-physiology

This page titled 6.1: Introduction to the Skeleton System is shared under a CC BY-NC-SA 4.0 license and was authored, remixed, and/or curated by Jennifer Lange et al..

- 6.1: Introduction to the Skeleton System by Whitney Menefee, Julie Jenks, Chiara Mazzasette, and Kim-Leiloni Nguyen is licensed CC BY 4.0.

6.2: Divisions of the Skeletal System

By the end of this section, you will be able to:

- Distinguish between the axial skeleton and appendicular skeleton
- Discuss the functions of the axial skeleton and appendicular skeleton
- Define the axial skeleton and its components
- Define the appendicular skeleton and its components

The skeletal system includes all of the bones, cartilages, and ligaments of the body that support and give shape to the body and body structures. The **skeleton** consists of the bones of the body. For adults, there are 206 bones in the skeleton. Younger individuals have higher numbers of bones because some bones fuse together during childhood and adolescence to form an adult bone. The primary functions of the skeleton are to provide a rigid, internal structure that can support the weight of the body against the force of gravity, and to provide a structure upon which muscles can act to produce movements of the body. The lower portion of the skeleton is specialized for stability during walking or running. In contrast, the upper skeleton has greater mobility and ranges of motion, features that allow you to lift and carry objects or turn your head and trunk.

In addition to providing for support and movements of the body, the skeleton has protective and storage functions. It protects the internal organs, including the brain, spinal cord, heart, lungs, and pelvic organs. The bones of the skeleton serve as the primary storage site for important minerals such as calcium and phosphate. The bone marrow found within bones stores fat and houses the blood-cell producing tissue of the body.

The skeleton is subdivided into two major divisions—the axial and appendicular. See Table 6.2.1 for a full list of the bones as well as how many of each are found in the body.

The Axial Skeleton

The **axial skeleton** forms the vertical, central axis of the body and includes all bones of the head, neck, chest, and back (Figure 6.2.1). It serves to protect the brain, spinal cord, heart, and lungs. It also serves as the attachment site for muscles that move the head, neck, and back, and for muscles that act across the shoulder and hip joints to move their corresponding limbs.

The axial skeleton of the adult consists of 80 bones, including the **skull**, the **vertebral column**, and the **thoracic cage**. The skull has two main divisions, the cranial portion and the facial portion, and is formed by 22 bones. Also associated with the head are an additional seven bones, including the **hyoid bone** and the **ear ossicles** (three small bones found in each middle ear). The vertebral column consists of 24 bones, each called a **vertebra**, plus the **sacrum** and **coccyx**. The thoracic cage includes the 12 pairs of **ribs**, and the **sternum**, the flattened bone of the anterior chest.

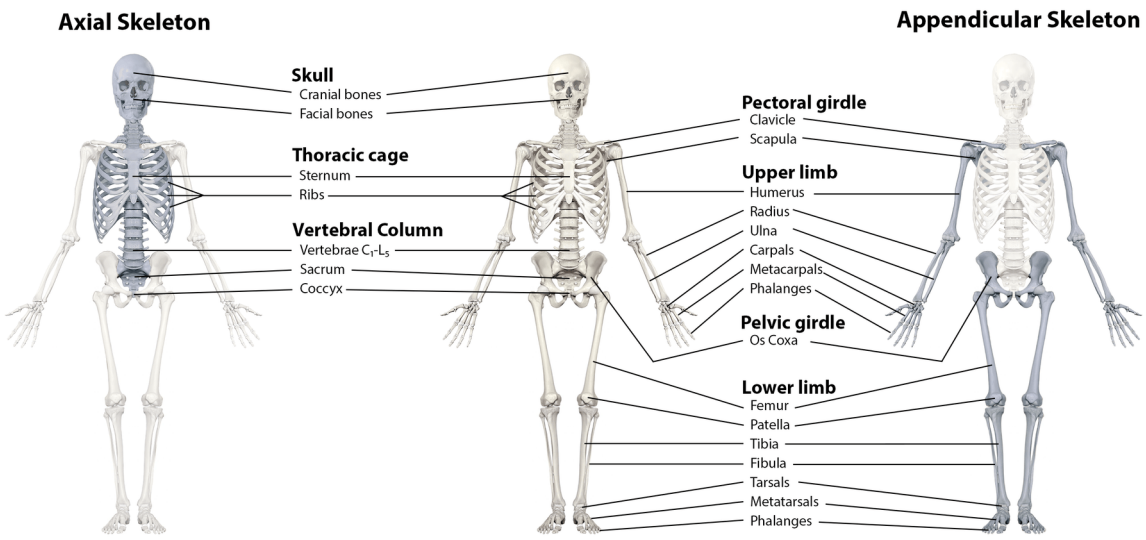

Figure 6.2.1: Axial and Appendicular Skeleton. The axial skeleton supports the head, neck, back, and chest and thus forms the vertical axis of the body. It consists of the skull, vertebral column (including the sacrum and coccyx), and the thoracic cage, formed by the ribs and sternum. The appendicular skeleton is made up of all bones of the upper and lower limbs. *(Image credit: "Axial and Appendicular Skeleton" by Jennifer Lange is licensed under CC BY-NC-SA 4.0, modification of images from Anatomy Standard under CC BY-NC 4.0.)*

The Appendicular Skeleton

The **appendicular skeleton** includes all bones of the upper and lower limbs, plus the bones that attach each limb to the axial skeleton. There are 126 bones in the appendicular skeleton of an adult. The bones that attach the upper limbs to the axial skeleton, include the clavicle and scapula, and are collectively known as the pectoral (shoulder) girdle. Bones of the upper limb include the humerus, ulna, radius, carpals, metacarpals and phalanges. The pelvic girdle, which attaches the lower limbs to the axial skeleton, is made up of the hip bones (coxae; singular coxa). Bones of the lower limb include the femur, patella, tibia, fibula, tarsals, metatarsals, and phalanges. The bones of the appendicular skeleton serve as attachment sites for muscles that move the appendages. The bones of the lower limb are structured to bear the weight of the body as well.

Table 6.2.1: Bones of the Skeleton. A table lists the bones in each region.

Axial Skeleton

Skull	**Cranial Bones (8)** • Ethmoid bone (1) • Frontal bone (1) • Occipital bone (1) • Parietal bones (2) • Sphenoid bone (1) • Temporal bones (2) **Facial Bones (14)** • Inferior nasal conchae (2) • Lacrimal bones (2) • Mandible (1) • Maxilla (1) • Nasal bones (2) • Palatine bone (1) • Vomer (1) • Zygomatic bones (2) **Associated Bones (7)** • Auditory ossicles [malleus (2), incus (2), stapes (2)] • Hyoid bone (1)
Vertebral Column	**Vertebrae (24)** • Cervical vertebrae (7) • Thoracic vertebrae (12) • Lumbar vertebrae (5) **Sacrum (1)** **Coccyx (1)**
Thoracic Cage	**Sternum (1)** **Ribs (24)**
Appendicular Skeleton	
Pectoral Girdle	**Clavicle (2)** **Scapula (2)**

Upper Limb	**Humerus (2)** **Radius (2)** **Ulna (2)** **Carpals (16)** • Scaphoid (2) • Lunate (2) • Triquetrum (2) • Pisiform (2) • Trapezius (2) • Trapezoid (2) • Capitate (2) • Hamate (2) **Metacarpals (10)** **Phalanges (28)** • Proximal (10) • Middle (8) • Distal (10)
Pelvic Girdle	**Os Coxa (2)**
Lower Limb	**Femur (2)** **Patella (2)** **Tibia (2)** **Fibula (2)** **Tarsals (16)** • Medial cuneiform (2) • Intermediate cuneiform (2) • Lateral cuneiform (2) • Cuboid (2) • Navicular (2) • Talus (2) • Calcaneus (2) **Metatarsals (10)** **Phalanges (28)** • Proximal (10) • Middle (8) • Distal (10)

Concept Review

The skeletal system includes all of the bones, cartilages, and ligaments of the body. It serves to support the body, protect the brain and other internal organs, and provides a rigid structure upon which muscles can pull to generate body movements. It also stores fat and the tissue responsible for the production of blood cells. The skeleton is subdivided into two parts. The axial skeleton forms a vertical axis that includes the head, neck, back, and chest. It has 80 bones and consists of the skull, vertebral column, and thoracic cage. The adult vertebral column consists of 24 vertebrae plus the sacrum and coccyx. The thoracic cage is formed by 12 pairs of ribs and the sternum. The appendicular skeleton consists of 126 bones in the adult and includes all of the bones of the upper and lower limbs plus the bones that anchor each limb to the axial skeleton.

Review Questions

Query 6.2.1

This interactive element is not available in this format. Visit the link or scan the QR code to access it online.

View this Interactive Content online

Critical Thinking Question

Query 6.2.2

This interactive element is not available in this format. Visit the link or scan the QR code to access it online.

View this Interactive Content online

Query 6.2.3

This interactive element is not available in this format. Visit the link or scan the QR code to access it online.

View this Interactive Content online

Glossary

Query 6.2.4

This interactive element is not available in this format. Visit the link or scan the QR code to access it online.

View this Interactive Content online

Contributors and Attributions

- OpenStax Anatomy & Physiology (CC BY 4.0). Access for free at https://openstax.org/books/anatomy-and-physiology

This page titled 6.2: Divisions of the Skeletal System is shared under a CC BY-NC-SA 4.0 license and was authored, remixed, and/or curated by Jennifer Lange et al..

- 6.2: Divisions of the Skeletal System by Whitney Menefee, Julie Jenks, Chiara Mazzasette, and Kim-Leiloni Nguyen is licensed CC BY 4.0.

6.3: The Skull

By the end of this section, you will be able to:

- List and identify the bones of the brain case and face
- Locate the major suture lines of the skull and name the bones associated with each
- Define the paranasal sinuses and identify the location of each
- Name the bones that make up the walls of the orbit and identify the openings associated with the orbit
- Identify the bones and structures that form the nasal septum and nasal conchae, and locate the hyoid bone
- Identify the bony openings of the skull

The **skull** is the skeletal structure of the head that supports the face and protects the brain. It is subdivided into the **facial bones** (also called **viscerocranium**) and the **cranium** (also called **neurocranium**) (Figure 6.3.1). The facial bones underlie the facial structures, form the nasal cavity, enclose the eyeballs, and support the teeth of the upper and lower jaws. The rounded brain case surrounds and protects the brain and houses the middle and inner ear structures.

Interactive Content

This interactive element is not available in this format. Visit the link or scan the QR code to access it online.

View this Interactive Content online

In the adult, the skull consists of 22 individual bones, 21 of which are immobile and united into a single unit. The 22nd bone is the **mandible** (lower jaw), which is the only moveable bone of the skull.

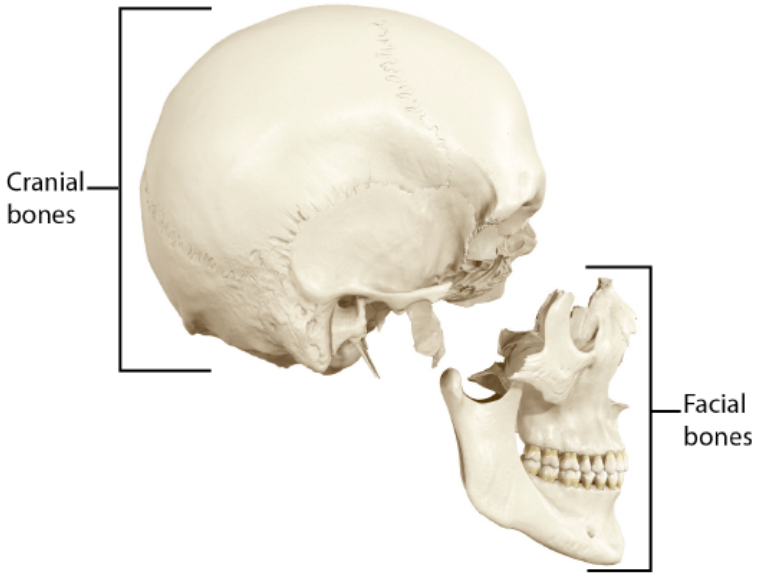

Figure 6.3.1: Parts of the Skull. The skull consists of the rounded cranial bones that protect the brain and the facial bones that form the upper and lower jaws, nose, orbits, and other facial structures. *(Image credit: "Bones of the Skull - Lateral View" by Jennifer Lange is licensed under CC BY-NC-SA 4.0, modification of image from Anatomy Standard under CC BY-NC 4.0.)*)

The bones that make up the adult skull can either be paired, one on the right side and one on the left side, or singular. Singular bones cross the midline and often are formed by the fusion of the right and left bones present in the fetus. (Figure 6.3.2)

The paired bones of the cranium (there is a right and a left) are:

- Parietal bones
- Temporal bones

The singular bones of the cranium are:

- Ethmoid bone
- Frontal bone
- Occipital bone
- Sphenoid bone

The paired bones of the face (there is a right and a left) are:

- Inferior nasal conchae
- Lacrimal bones
- Nasal bones
- Zygomatic bones

The singular bones of the face are:

- Mandible
- Maxilla
- Palatine bone
- Vomer

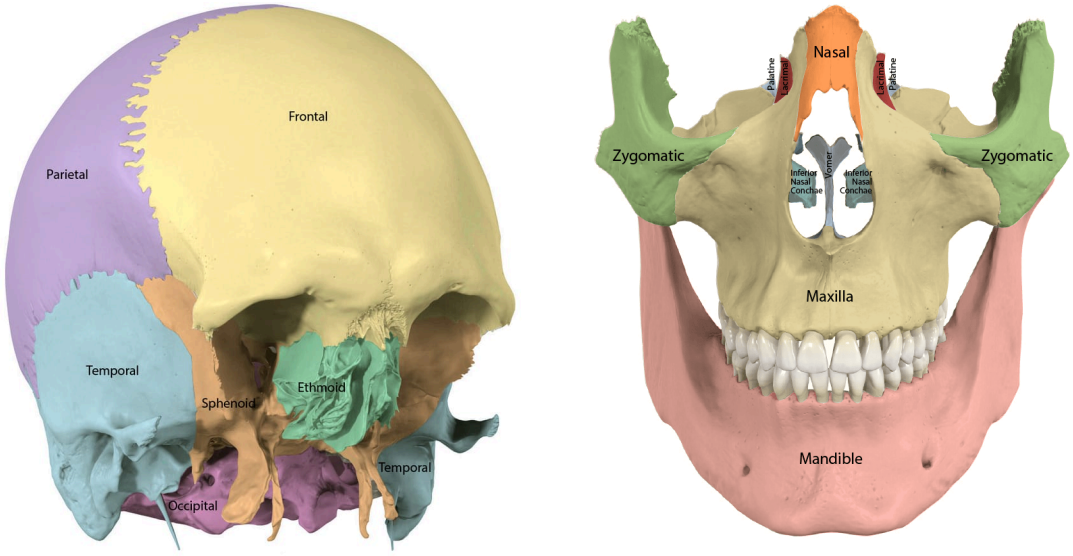

Figure 6.3.2: Skull Bones. The adult skull is comprised of 22 individual bones. *(Image credits: "Cranial Bones" and "Facial Bones" by Mark Schaeffer are licensed under CC BY-NC-SA 4.0, modification of images from Anatomy Standard under CC BY-NC 4.0.)*

Bones of the Skull

The bones of the skull have complex shapes and they fit together like the pieces of a very intricate jigsaw puzzle. We will first examine the skull as a whole, from multiple viewpoints, and then we will look at specific features of each bone or group of bones. These specific features, called landmarks, are the ridges where muscles attach, the concave and convex surfaces of a joint, or the holes that allow for the passage of blood vessels or nerves.

Anterior View

The anterior view of the skull (Figure 6.3.3 is dominated by the forehead, formed mainly by the **frontal bone**, and the openings of the orbits and the nasal cavity. Also seen are the upper and lower jaws, with their respective teeth.

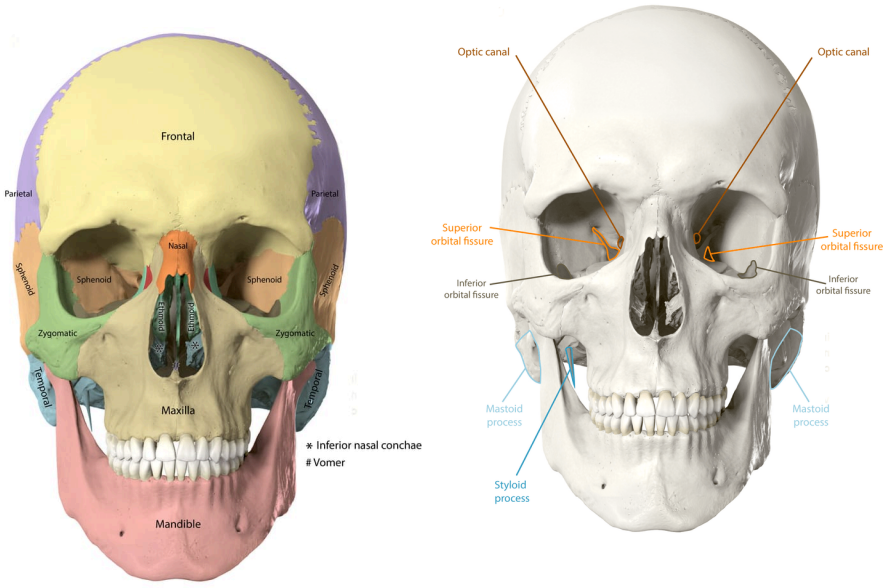

Figure 6.3.3: Anterior Views of the Skull. Anterior views of the skull shows the bones that form the forehead, orbits (eye sockets), nasal cavity, nasal septum, and upper and lower jaws. *(Image credits: "Skull Bones Anterior View" by Mark Schaeffer are licensed under CC BY-NC-SA 4.0, modification of images from Anatomy Standard under CC BY-NC 4.0.)*

The **orbit** is the bony socket that houses the eyeball and muscles that move the eyeball or open the upper eyelid. The walls of the orbit are formed by multiple bones. The majority of the socket consists of parts of the **frontal bone, maxilla, sphenoid bone,** and **zygomatic bone**. Small parts of the **ethmoid bone, lacrimal bone**, and **palatine bone** also contribute to the medial wall. (Figure 6.3.4) Within the orbit are three openings that allow for blood vessels and nerves to pass:

- **Inferior orbital fissure** - This opening is found on the floor of the orbit between the sphenoid, maxillary, and zygomatic bones. Traveling through this fissure are nerves that provide sensory information to the skin that covers the temporal and zygomatic bones and that regulate blood flow to the nasal mucosa, allowing for the warming/cooling of air in the nasal cavity. This fissure also allows for the passage of blood vessels.
- **Superior orbital fissure**—This large, irregular opening into the posterior orbit is located on the anterior wall of the middle cranial fossa, lateral to the optic canal and under the projecting margin of the lesser wing of the sphenoid bone. Nerves to the eyeball and associated muscles, and sensory nerves to the forehead pass through this opening.
- **Optic canal**—This opening is located at the anterior lateral corner of the sella turcica. It provides for passage of the optic nerve into the orbit.

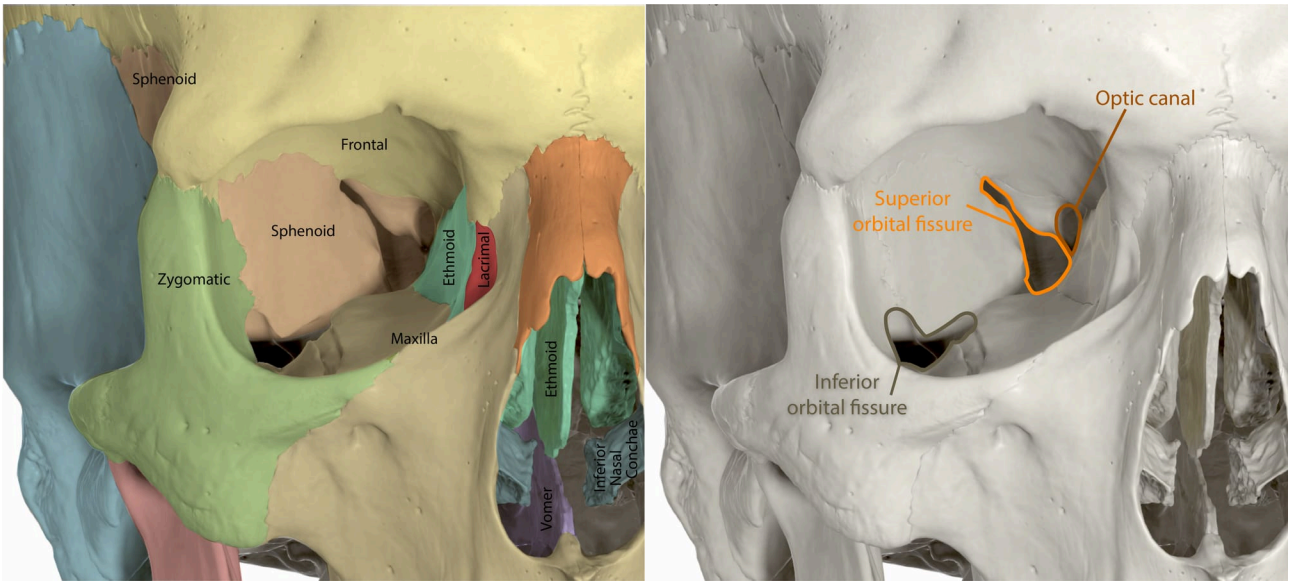

Figure 6.3.4: Bones of the Orbit. Several bones comprise the walls of the orbit. *(Image credit: "Bones of the Orbit Close-up" by Mark Schaeffer is licensed under CC BY-NC-SA 4.0, modification of images from Anatomy Standard under CC BY-NC 4.0.)*

Inside the nasal area of the skull (Figure 6.3.5), the **nasal cavity** is divided into halves by the **nasal septum**. The upper portion of the nasal septum is formed by the **perpendicular plate of the ethmoid bone** and the lower portion is formed by the **vomer bone**. Each side of the nasal cavity is triangular in shape, with a broad inferior space that narrows superiorly. When looking into the nasal cavity from the front of the skull, two bony plates are seen projecting from each lateral wall. The larger of these is the **inferior nasal concha**, an independent bone of the skull. Two additional ridges located just above the inferior concha in the upper nasal cavity, the **middle nasal concha** and **superior nasal concha**, are parts of the ethmoid bone and are not visible here.

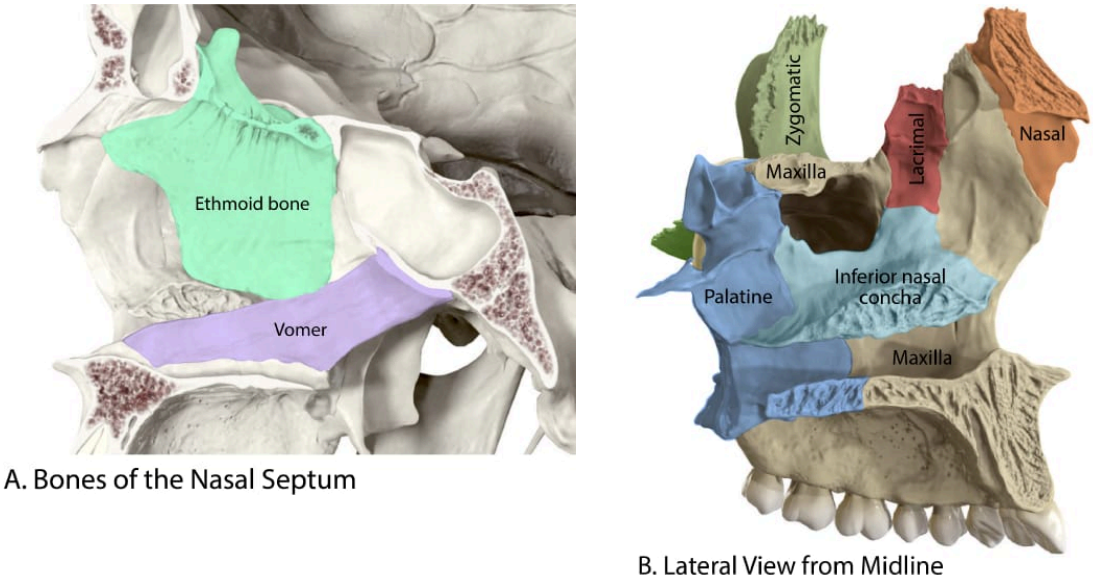

Figure 6.3.5: Bones of the Nasal Complex. The nasal septum has two major bones - the ethmoid bone and the vomer - that divide the nasal cavity into left and right components. The lateral walls of the nasal cavity contain the inferior nasal conchae, that serve to spin inhaled air. *(Image credit: "Bones of the Nasal Complex" by Jennifer Lange is licensed under CC BY-NC-SA 4.0, modification of images from Anatomy Standard.)*

Lateral View of Skull

A view of the lateral skull is dominated by the large, rounded brain case, zygomatic (cheek) bones, and the maxilla and mandible with their teeth (Figure 6.3.6). Connecting these areas is a bridge of bone called the **zygomatic arch**. All of the cranial bones can

be seen from the lateral view: frontal, parietal, occipital, sphenoid (starting with the forehead and tracing a "C" the order of the bones follow the pneumonic "FPOTS") and the ethmoid is in the "eye".

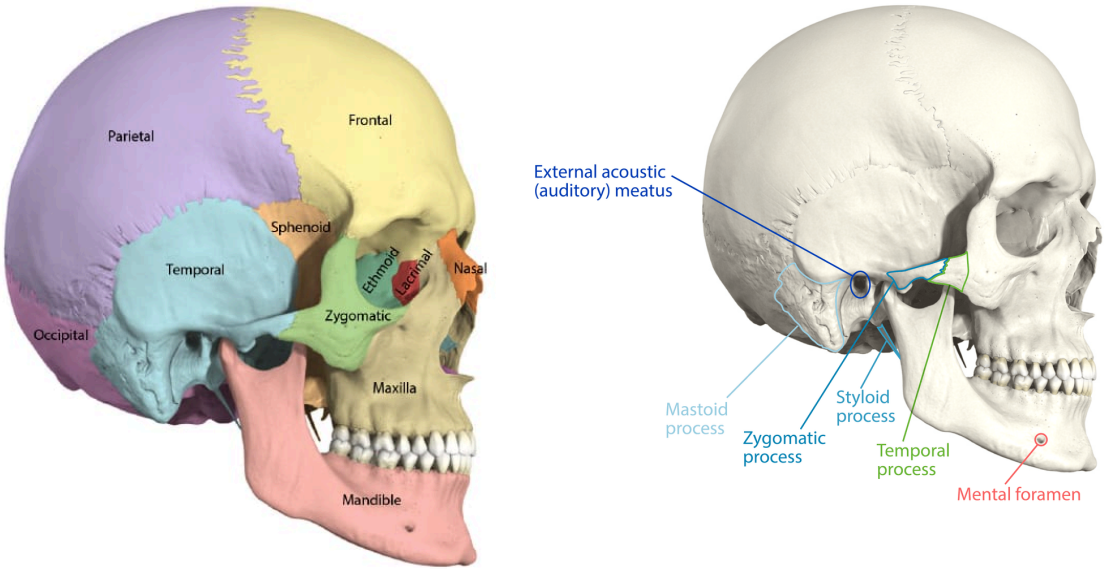

Figure 6.3.6: Lateral View of Skull. The lateral skull shows the large rounded brain case, zygomatic arch, and the upper and lower jaws. The zygomatic arch is formed jointly by the temporal bone and the zygomatic bone. *(Image credit: "Lateral View of the Skull" by Mark Schaeffer is licensed under CC BY-NC-SA 4.0, modification of images from Anatomy Standard under CC BY-NC 4.0.)*

The **zygomatic arch** is the bony arch on the side of skull that spans from the area of the cheek to just above the ear canal. It is formed by the junction of two bony processes: a short anterior component, the **temporal process of the zygomatic bone** (the cheekbone) and a longer posterior portion, the **zygomatic process of the temporal bone**, extending forward from the temporal bone. Thus the temporal process (anteriorly) and the zygomatic process (posteriorly) join together, like the two ends of a drawbridge, to form the zygomatic arch. One of the major muscles that pulls the mandible upward during biting and chewing arises from the zygomatic arch.

Superior View

Viewed from above, only four skull bones are visible: frontal, right parietal, left parietal, and occipital. These four bones make up the **calvaria**, or the skull roof. In your anatomy lab you will most likely be able to remove the calvaria from the skull models so you can view the interior structures. (Figure 6.3.7).

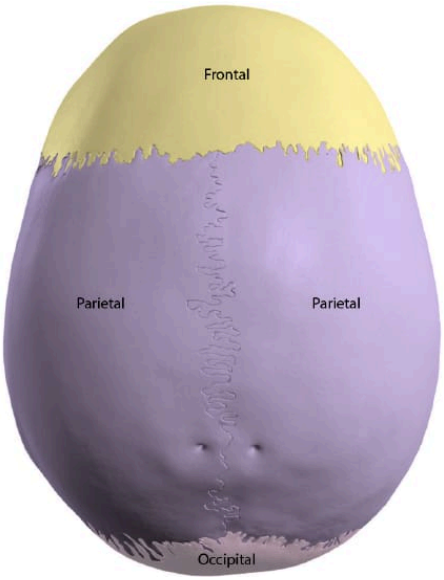

Figure \(\PageIndex{7}\): Superior View of Skull. The superior skull shows the large rounded brain case. In this view both the right and left parietal bones are visible, as well as the singular occipital and frontal bones. *(Image credit: "Superior View of the Skull" by Mark Schaeffer is licensed under CC BY-NC-SA 4.0, modification of images from Anatomy Standard under CC BY-NC 4.0.)*

Inferior View

The inferior aspect of the skull is complex in shape as it is the location of multiple foraminae for the passage of multiple blood vessels, nerves, and the spinal cord. Tracing the anterior border of the sphenoid bone gives you the junction between the bones of the face and cranium (Figure 6.3.8).

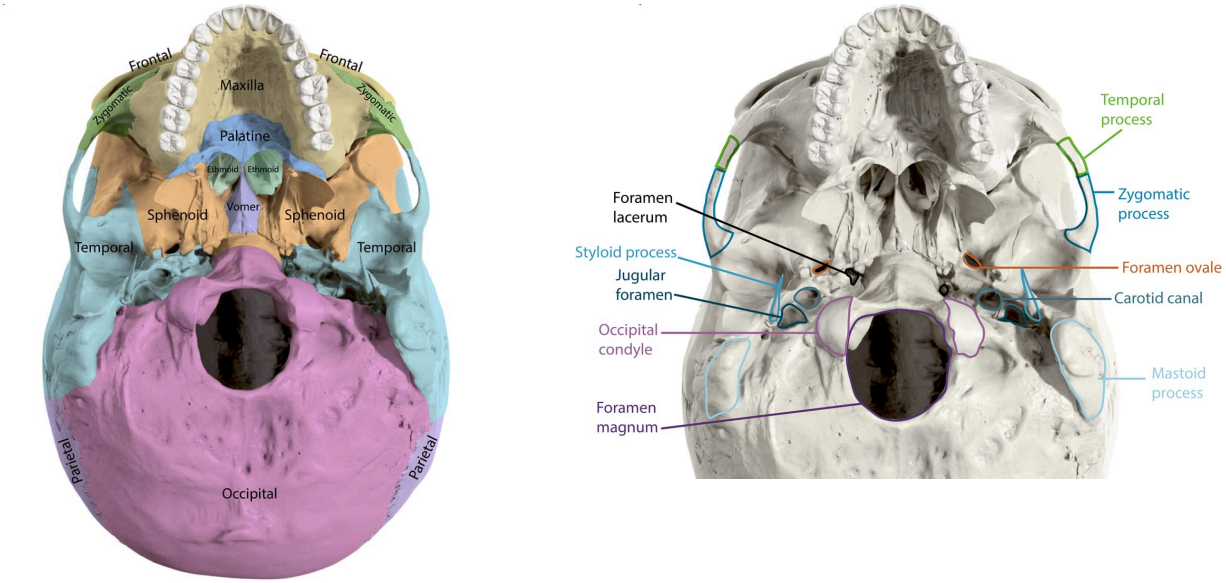

Figure 6.3.8: Inferior View of the Skull. Viewed from the inferior, the full width of the sphenoid bone can easily be seen. The landmarks allowing passage of nerves, blood vessels, and the spinal cord as well as several muscle attachment points are shown; each is outlined in a color of its respective bone. *(Image credit: "Inferior View of the Skull" by Mark Schaeffer is licensed under CC BY-NC-SA 4.0, modification of images from Anatomy Standard under CC BY-NC 4.0.)*

Foramina visible include:

- **Foramen lacerum** - This irregular opening is located in the base of the skull, immediately inferior to the exit of the carotid canal. This opening is an artifact of the dry skull, because in life it is completely filled with cartilage. All the openings of the skull that provide for passage of nerves or blood vessels have smooth margins; the word lacerum (“ragged” or “torn”) tells us

that this opening has ragged edges and thus nothing passes through it.

- **Foramen ovale** - is an oval shaped opening in the sphenoid bone that allows for passage of blood vessels and nerves, the largest of which is the mandibular branch of cranial nerve V.
- **Carotid canal** - The carotid canal is a zig-zag shaped tunnel that provides passage through the base of the skull for one of the major arteries that supplies the brain. Its entrance is located on the outside base of the skull, anteromedial to the styloid process. The canal then runs anteromedially within the bony base of the skull, and then turns upward to its exit in the floor of the middle cranial cavity, above the foramen lacerum.
- **Jugular foramen -** In this external view the jugular foramen is located slightly posterior and lateral to the carotid canal, as the internal jugular vein runs adjacent to the internal carotid artery. Because veins lack blood pressure, their walls tend to partially collapse instead of maintaining a round shape (as arteries do). Thus, the jugular foramen is not a uniformly round hole.
- **Foramen magnum** - Being "magnum" this is the largest foramen in the skull. The foramen magnum serves as the dividing line between the brain and the spinal cord, even though they are continuous with each other on a structural level.

Bones of the Neurocranium

The cranial bones (the neurocranium) contain and protect the brain. The interior space that is almost completely occupied by the brain is called the **cranial cavity**. The floor of the neurocranium is referred to as the base of the skull. The neurocranium consists of eight bones: the paired parietal and temporal bones, plus the unpaired frontal, occipital, sphenoid, and ethmoid bones.

Interactive Content

This interactive element is not available in this format. Visit the link or scan the QR code to access it online.

View this Interactive Content online

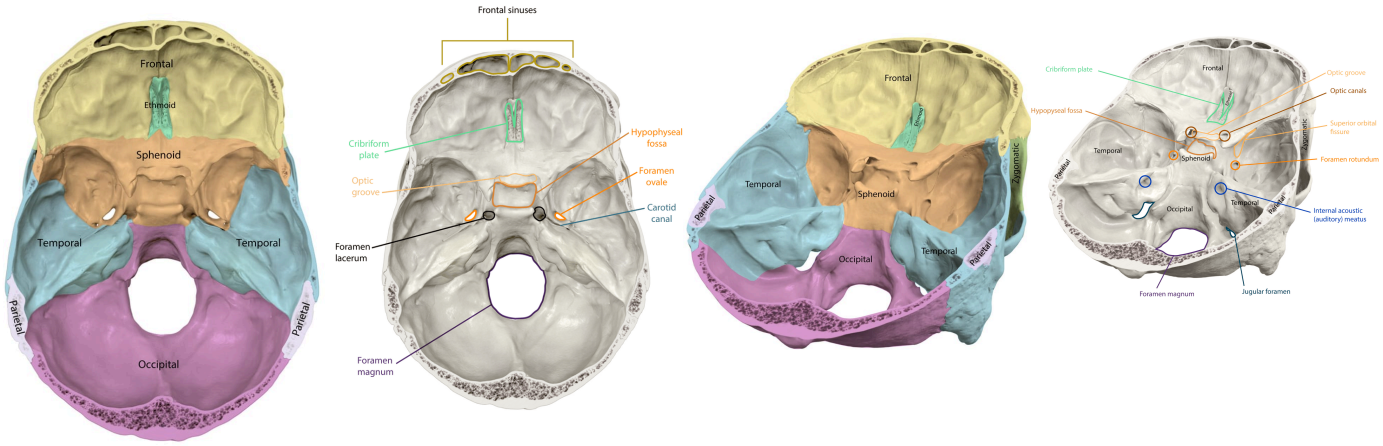

Figure 6.3.9: Interior Views of the Skull. Viewed from the inferior, the full width of the sphenoid bone can easily be seen. The landmarks allowing passage of nerves, blood vessels, and the spinal cord as well as several muscle attachment points are shown; each is outlined in a color of its respective bone. *(Image credit: "Inferior View of the Skull" by Mark Schaeffer is licensed under CC BY-NC-SA 4.0, modification of images from Anatomy Standard under CC BY-NC 4.0.)*

Parietal Bones

The **parietal bone** forms most of the upper lateral side wall of the skull (parietal = "wall") (Figure 6.3.10). These are paired bones, with the right and left parietal bones joining together at the top of the skull. Each parietal bone is also bordered anteriorly by the frontal bone, inferiorly by the temporal bone, and posteriorly by the occipital bone.

Parietal Bone Ex Situ

Parietal Bone In Situ

Figure 6.3.10: Parietal Bone. The right parietal bone in situ and ex situ. *(Image credits: "Parietal Bone In Situ" and "Parietal Bone Ex Situ" by Sofia Elizondo is licensed under CC BY-NC-SA 4.0, modification of images from Anatomy Standard under CC BY-NC 4.0.)*

Temporal Bones

The **temporal bone** forms the lower lateral side of the skull (Figure 6.3.6). Common wisdom has it that the temporal bone (temporal = “time”) is so named because this area of the head (the temple) is where hair typically first turns gray, indicating the passage of time.

The temporal bone has three processes for muscle attachment (Figure 6.3.11):

- the **zygomatic process** of the temporal bone projects anteriorly to meet the zygomatic bone and it forms the posterior portion of the zygomatic arch,
- the **mastoid process** projects inferiorly and can easily be felt on the side of the head just behind your earlobe,
- the s**tyloid process** is an elongated, downward bony projection posterior to the mandibular fossa on the external base of the skull; so named because of its resemblance to a stylus (a pen or writing tool).

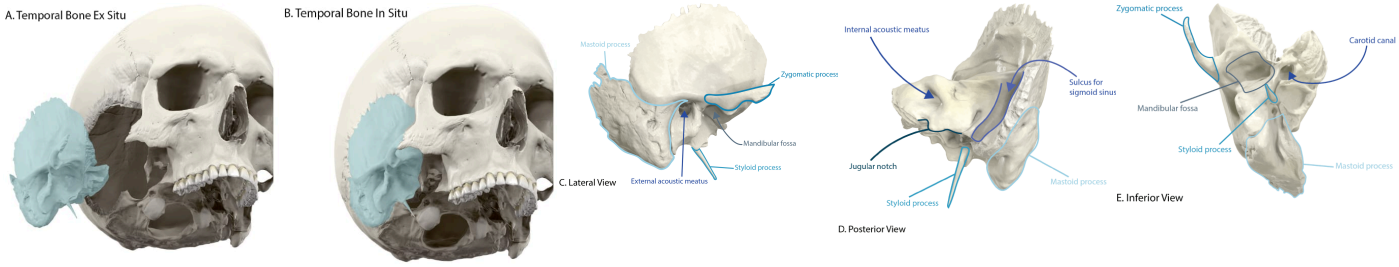

Figure 6.3.11: Temporal Bone and Landmarks. Shown in isolation in (C) lateral, (D) posterior, and (E) inferior views, the temporal bone surrounds the structures of the ear, your temple, and the posterior part of your cheek bone line. The temporal bone has an opening for the passage of the largest artery serving the brain - the carotid canal - and a notch that forms one wall of the jugular foramen. On the external surface, sound waves enter the external acoustic meatus and the nerve carrying auditory information exits through the internal acoustic meatus. *(Image credit: "Temporal Bone and Landmarks" by Sofia Elizondo is licensed under CC BY-NC-SA 4.0, modification of images from Anatomy Standard under CC BY-NC 4.0.)*

Important landmarks of the temporal bone, as seen in Figures 6.3.11 and 6.3.9, include the following:

- **External acoustic meatus** (ear canal) - This is the large opening on the lateral side of the skull that is associated with the

ear.

- **Internal acoustic meatus** - This opening is located inside the cranial cavity, on the medial side of the petrous ridge. It connects to the middle and inner ear cavities of the temporal bone.
- Immediately inferior to the internal acoustic meatus is the large, irregularly shaped **jugular foramen**. This foramen is formed by the jugular notch of the temporal bone and the border of the occipital bone. Several cranial nerves from the brain exit the skull via this opening. It is also the exit point through the base of the skull for all the venous return blood leaving the brain. The venous structures that carry blood inside the skull form large, curved grooves on the inner walls of the posterior cranial fossa, which terminate at each jugular foramen.
- **Carotid canal** - The carotid canal is a zig-zag shaped tunnel that provides passage through the base of the skull for one of the major arteries that supplies the brain. Its entrance is located on the outside base of the skull, anteromedial to the styloid process. The canal then runs anteromedially within the bony base of the skull, and then turns upward to its exit in the floor of the middle cranial cavity, above the foramen lacerum.

Frontal Bone

The **frontal bone** is the single bone that forms the forehead. It has two main parts, the squamous part, which forms the large, flat, superior portion of the bone, and the orbit part. The frontal bone is thickened just above each supraorbital margin, forming rounded brow ridges. These are located just behind your eyebrows and vary in size among individuals, although they are generally larger in males. Inside the cranial cavity, the frontal bone extends posteriorly. This flattened region forms both the roof of the orbit below and part of the floor of the cranial cavity above (Figure 6.3.12).

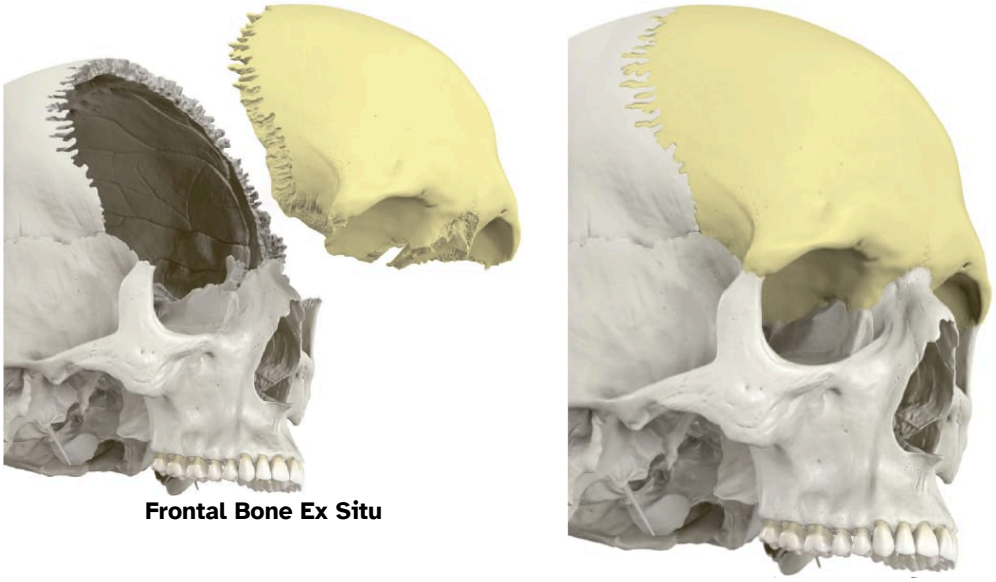

Frontal Bone Ex Situ

Frontal Bone In Situ

Figure 6.3.12: The Frontal Bone Ex Situ and In Situ. The frontal bone forms the anterior wall of the cranial cavity and the superior wall of the orbit. *(Image credit: "Frontal Bone Ex Situ and In Situ" by Sofia Elizondo are licensed under CC BY-NC-SA 4.0, modification of images from Anatomy Standard under CC BY-NC 4.0.)*

Occipital Bone

The **occipital bone** is the single bone that forms the posterior skull and posterior base of the cranial cavity (Figure 6.3.6; see also Figure 6.3.13). On the base of the skull, the occipital bone contains the large opening of the **foramen magnum**, which allows for passage of the spinal cord as it exits the skull. Superficially, on either side of the foramen magnum is an oval-shaped **occipital condyle**. These condyles form joints with the first cervical vertebra and thus support the skull on top of the vertebral column.

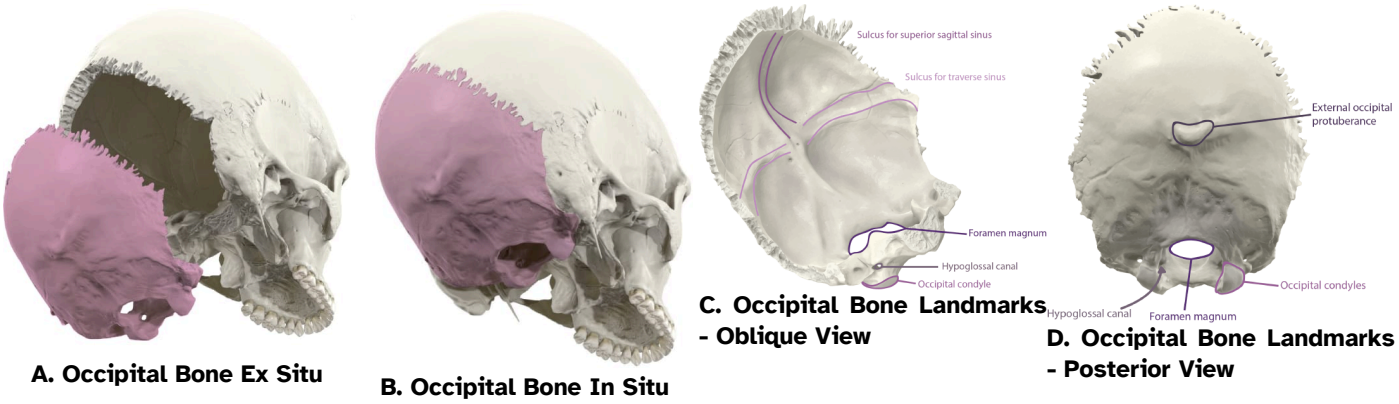

A. Occipital Bone Ex Situ

B. Occipital Bone In Situ

C. Occipital Bone Landmarks - Oblique View

D. Occipital Bone Landmarks - Posterior View

Figure 6.3.13: Occipital Bone and Landmarks. The occipital bone forms the posterior and inferior portion of the cranium. It serves as the connection point between the skull and the vertebral column, with the articular surfaces of the occipital condyles. The foramen magnum is the large hole the spinal cord passes through. *(Image credit: "Occipital Bone and Landmarks" by Sofia Elizondo are licensed under CC BY-NC-SA 4.0, modification of images from Anatomy Standard under CC BY-NC 4.0.)*

Sphenoid Bone

The **sphenoid bone** is a single, complex bone of the central skull (Figure 6.3.8). It serves as a "keystone" bone, because it joins with almost every other bone of the skull. The sphenoid forms much of the base of the central skull and also extends laterally to contribute to the sides of the skull. Inside the cranial cavity, the right and left lesser wings of the sphenoid bone resemble the wings of a flying bird or a moth (Figure 6.3.9). The **sella turcica** ("Turkish saddle") is located at the midline, on the body of the sphenoid bone (Figure 6.3.14). The rounded depression in the floor of the sella turcica is the **hypophyseal (pituitary) fossa**, which houses the pea-sized pituitary (hypophyseal) gland and the posterior wall is the **dorsum sellae.** The greater wings of the sphenoid bone extend laterally to either side away from the sella turcica, where they form the anterior floor of the middle cranial fossa. The greater wing is best seen on the outside of the lateral skull, where it forms a rectangular area immediately anterior to the temporal bone.

The sphenoid bone has several openings for the passage of blood vessels and cranial nerves, which include (Figure 6.3.14):

- **Optic canal**—This opening is located at the anterior lateral corner of the sella turcica. It provides for passage of the optic nerve into the orbit.
- **Superior orbital fissure**—This large, irregular opening into the posterior orbit is located on the anterior wall of the middle cranial fossa, lateral to the optic canal and under the projecting margin of the lesser wing of the sphenoid bone. Nerves to the eyeball and associated muscles, and sensory nerves to the forehead pass through this opening.
- **Foramen rotundum**—This rounded opening (rotundum = "round") is located in the floor of the middle cranial fossa, just inferior to the superior orbital fissure. It is the exit point for a major sensory nerve that supplies the cheek, nose, and upper teeth.
- **Foramen ovale** — This large, oval-shaped opening in the floor of the middle cranial fossa provides passage for a major sensory nerve to the lateral head, cheek, chin, and lower teeth.
- **Carotid canal**—This is the zig-zag passageway through which a major artery to the brain enters the skull. The entrance to the carotid canal is located on the inferior aspect of the skull, anteromedial to the styloid process (see Figure 6.3.6.a). From here, the canal runs anteromedially within the bony base of the skull. Just above the foramen lacerum, the carotid canal opens into the middle cranial cavity, near the posterior-lateral base of the sella turcica.

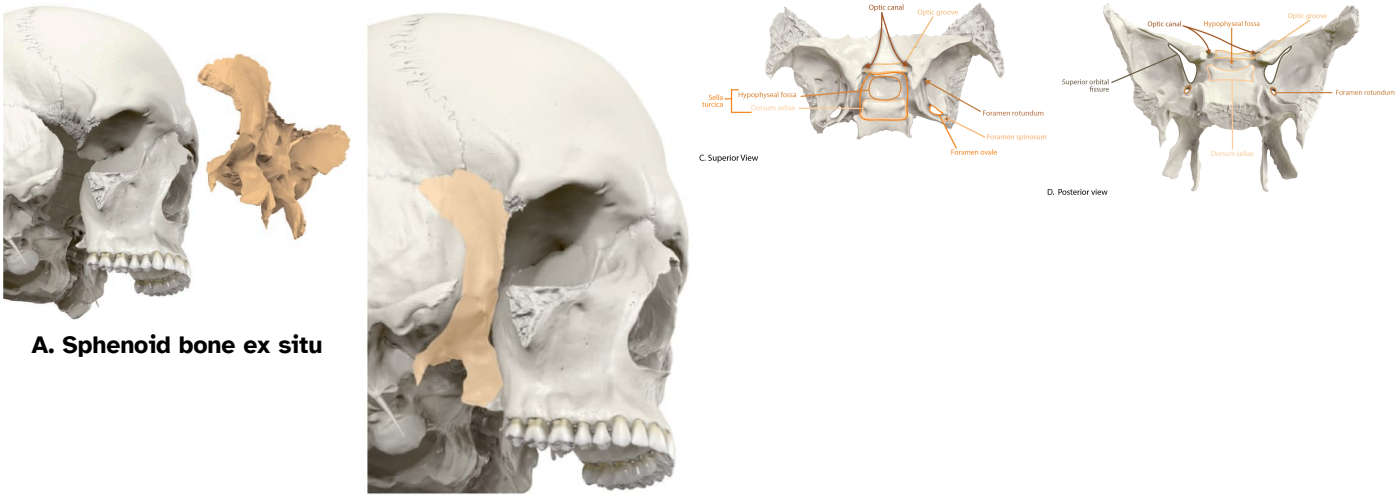

A. Sphenoid bone ex situ

B. Sphenoid bone in situ

Figure 6.3.14: Sphenoid Bone and Landmarks. Shown in isolation in (C) superior and (D) posterior views, the sphenoid bone is a single midline bone that forms the anterior walls and floor of the middle cranial fossa. The hypophyseal fossa and the dorsum sellae are within the sella turcica and serve as the surrounds for the pituitary gland. The sphenoid has multiple openings for the passage of nerves and blood vessels, including the optic canal, superior orbital fissure, foramen rotundum, foramen ovale, and foramen spinosum. *(Image credit: "Sphenoid Bone and Landmarks" by Sofia Elizondo is licensed under CC BY-NC-SA 4.0, modification of images from Anatomy Standard under CC BY-NC 4.0.)*

Ethmoid Bone

The **ethmoid bone** is a single, midline bone that forms the roof and lateral walls of the upper nasal cavity, the upper portion of the nasal septum, and contributes to the medial wall of the orbit (Figure 6.3.4. On the interior of the skull, the ethmoid also forms a portion of the floor of the anterior cranial cavity (see Figure 6.3.5).

Within the nasal cavity, the **perpendicular plate** of the ethmoid bone forms the upper portion of the nasal septum (Figure 6.3.5 . The ethmoid bone also forms the lateral walls of the upper nasal cavity. Extending from each lateral wall are the superior nasal concha and middle nasal concha, which are thin, curved projections that extend into the nasal cavity to increase the surface area of the nasal passages and to cause the incoming air to spin (see Respiratory System chapter).

In the cranial cavity, the ethmoid bone forms a small area at the midline in the floor of the anterior cranial fossa. This region also forms the narrow roof of the underlying nasal cavity. This portion of the ethmoid bone consists of two parts, the crista galli and cribriform plates (Figure 6.3.15). The **crista galli** (“rooster’s comb or crest”) is a small upward bony projection located at the midline. It functions as an anterior attachment point for one of the connective tissue covering layers of the brain. To either side of the crista galli is the **cribriform plate** (cribrum = “sieve”), a small, flattened area with numerous small openings termed olfactory foramina. Small nerve branches from the olfactory (smell) areas of the nasal cavity pass through these openings to enter the brain.

The lateral portions of the ethmoid bone are located between the orbit and upper nasal cavity, and thus form the lateral nasal cavity wall and a portion of the medial orbit wall. The **ethmoid air cells**, spaces creating a honeycomb-like structure in the lateral portions of the bone, form the ethmoidal sinuses (Figure 6.3.15), one of the four pairs of paranasal sinus. The paranasal sinuses also play a role in the respiratory system.

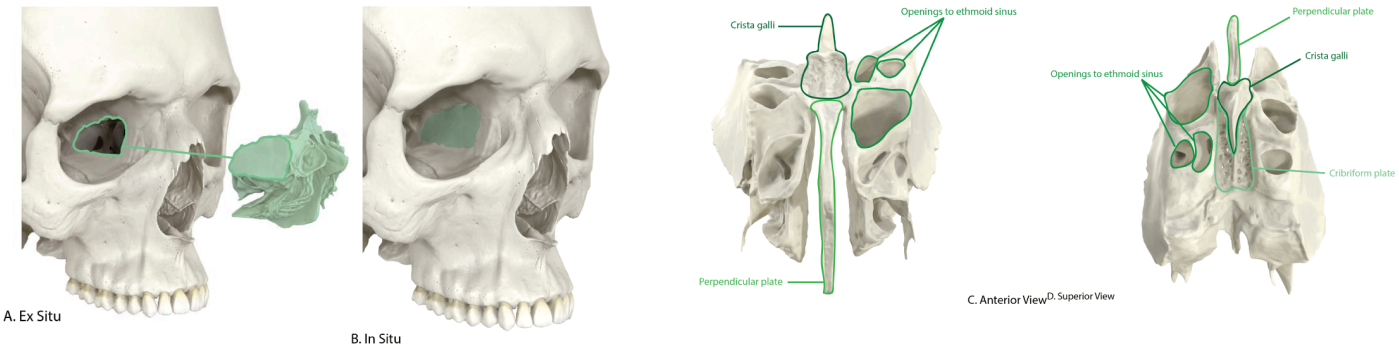

Figure 6.3.15: Ethmoid Bone. The unpaired ethmoid bone is located at the midline within the central skull. It has an upward projection, the crista galli, and a downward projection, the perpendicular plate, which forms the upper nasal septum. The cribriform plates form both the roof of the nasal cavity and a portion of the anterior cranial fossa floor. The lateral sides of the ethmoid bone form the lateral walls of the upper nasal cavity, part of the medial orbit wall, and give rise to the superior and middle nasal conchae. The ethmoid bone also contains the ethmoid air cells. *(Image credit: "Ethmoid Bone" by Sofia Elizondo is licensed under CC BY-NC-SA 4.0, modification of images from Anatomy Standard under CC BY-NC 4.0.)*

Sutures of the Skull

A **suture** is an immobile joint between adjacent bones of the skull. The narrow gap between the bones is filled with dense irregular connective tissue that unites the bones. The long sutures located between the bones of the brain case are not straight, but instead follow irregular, tightly twisting paths. These twisting lines serve to tightly interlock the adjacent bones, thus adding strength to the skull for brain protection.

Figure 6.3.16 shows the major sutures of the skull. The two suture lines seen on the top of the skull are the coronal and sagittal sutures. The **coronal suture** runs from side to side across the skull, within the coronal plane of section. It joins the frontal bone to the right and left parietal bones. The **sagittal suture** extends posteriorly from the coronal suture, running along the midline at the top of the skull in the sagittal plane of section. It unites the right and left parietal bones. On the posterior skull, the sagittal suture terminates by joining the lambdoid suture. The **lambdoid suture** extends downward and laterally to either side away from its junction with the sagittal suture. The lambdoid suture joins the occipital bone to the right and left parietal and temporal bones. This suture is named for its upside-down "V" shape, which resembles the capital letter version of the Greek letter lambda (Λ). The **squamous suture** is located on the lateral skull. It unites the squamous portion of the temporal bone with the parietal bone. At the intersection of four bones is the **pterion**, a small, capital-H-shaped suture line region that unites the frontal bone, parietal bone, squamous portion of the temporal bone, and greater wing of the sphenoid bone. It is the weakest part of the skull. The pterion is located approximately two finger widths above the zygomatic arch and a thumb's width posterior to the upward portion of the zygomatic bone.

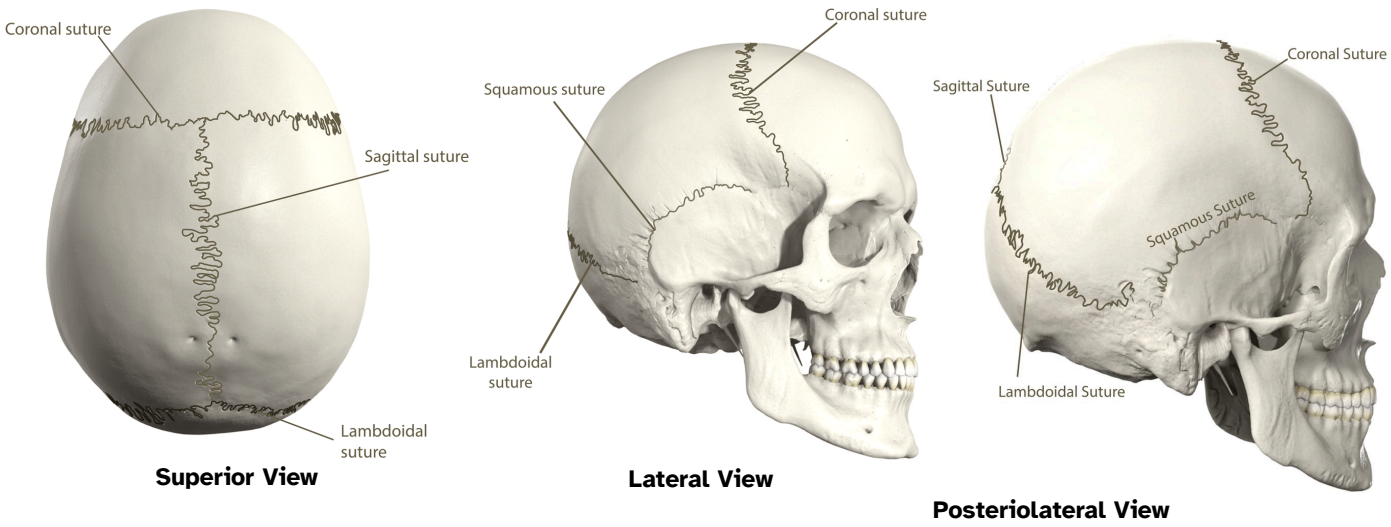

Figure 6.3.16: Sutures of the Skull. Sutures represent the immovable joints found between skull bones. In the superior view the coronal, sagittal and lambdoid sutures are visible. A lateral view of the skull shows the coronal, squamous, and lambdoid sutures. A posterior view shows the sagittal, lambdoid, and squamous sutures. *("Sutures of the Skull" by Mark Schaeffer is licensed under CC BY-NC-SA 4.0, modification of images from Anatomy Standard under CC BY-NC 4.0..)*

DISORDERS OF THE...

Skeletal System: Cranial Fractures

Head and traumatic brain injuries are major causes of immediate death and disability, with bleeding and infections as possible additional complications. According to the Centers for Disease Control and Prevention (2010), approximately 30 percent of all injury-related deaths in the United States are caused by head injuries. The majority of head injuries involve falls. They are most common among young children (ages 0–4 years), adolescents (15–19 years), and the elderly (over 65 years). Additional causes vary, but prominent among these are automobile and motorcycle accidents.

Strong blows to the brain-case portion of the skull can produce fractures (Figure 6.3.20). These may result in bleeding inside the skull with subsequent injury to the brain. The most common is a linear skull fracture, in which fracture lines radiate from the point of impact. Other fracture types include a comminuted fracture, in which the bone is broken into several pieces at the point of impact, or a depressed fracture, in which the fractured bone is pushed inward. In a contrecoup (counterblow) fracture, the bone at the point of impact is not broken, but instead a fracture occurs on the opposite side of the skull. Fractures of the occipital bone at the base of the skull can occur in this manner, producing a basilar fracture that can damage the artery that passes through the carotid canal.

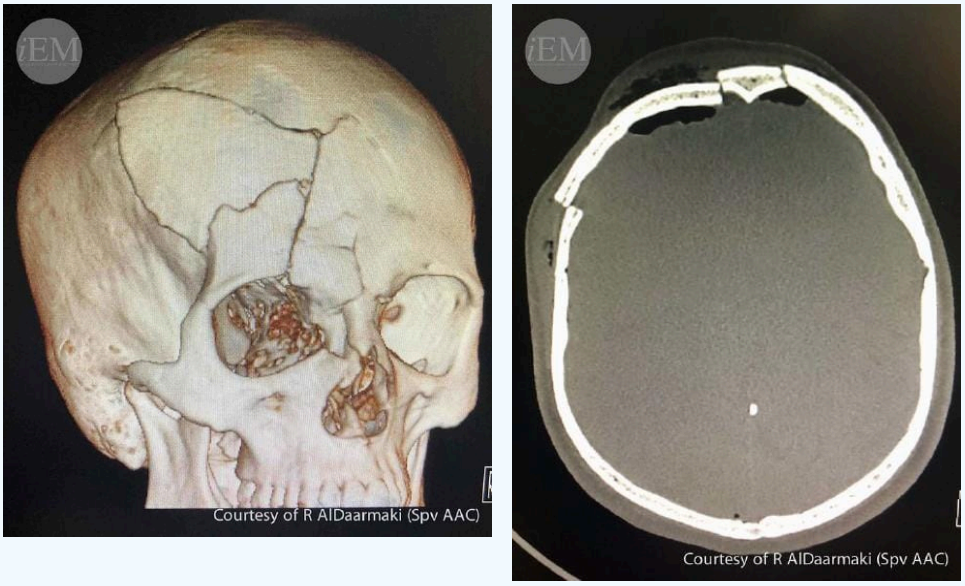

Figure 6.3.17: Skull Fracture. A 31-year-old male presented to the Emergency Room after falling from a 3-meter wall and landing on his face. (Skull Fracture and Skull Fracture Scan by iEM is licensed under CC BY-NC-S 2.0)

A blow to the lateral side of the head may fracture the bones of the pterion. The pterion is an important clinical landmark because located immediately deep to it on the inside of the skull is a major branch of an artery that supplies the skull and covering layers of the brain. If the underlying artery is damaged, bleeding can cause the formation of a hematoma (collection of blood) between the brain and interior of the skull. As blood accumulates, it will put pressure on the brain. Symptoms associated with a hematoma may not be apparent immediately following the injury, but if untreated, blood accumulation will exert increasing pressure on the brain and can result in death within a few hours.

Facial Bones of the Skull

The facial bones of the skull form the upper and lower jaws, the nose, nasal cavity and nasal septum, and the orbit. The facial bones include 14 bones, with six paired bones and two unpaired bones (Figure 6.3.18). The paired bones are the maxilla, palatine, zygomatic, nasal, lacrimal, and inferior nasal conchae bones. The unpaired bones are the vomer and mandible bones. Although classified with the brain-case bones, the ethmoid bone also contributes to the nasal septum and the walls of the nasal cavity and orbit.

Interactive Content

This interactive element is not available in this format. Visit the link or scan the QR code to access it online.

View this Interactive Content online

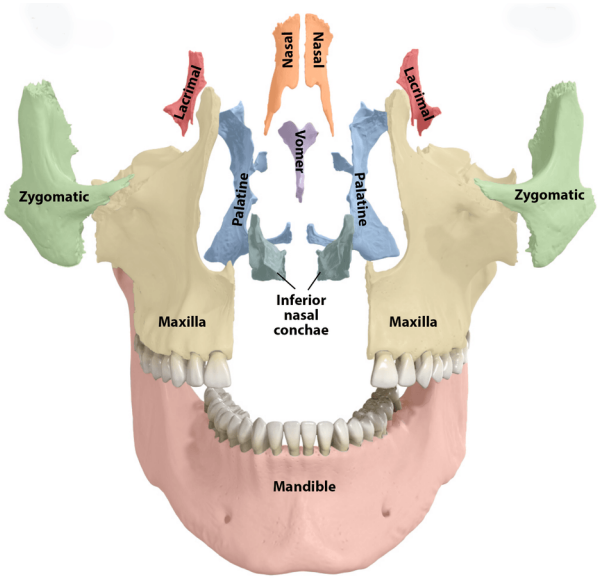

Figure 6.3.18: Facial Bones Separated. The facial bones contain six pairs and two singular bones. *(Image credit: "Facial Bones Separated" by Jennifer Lange is licensed under CC BY-NC-SA 4.0, modification of images from Anatomy Standard under CC BY-NC 4.0.)*

Maxillary Bone

The **maxillary bone**, often referred to simply as the maxilla (plural = maxillae), is one of a pair that together form the upper jaw, much of the hard palate, the medial floor of the orbit, and the lateral base of the nose (see Figure 6.3.2). The curved, inferior margin of the maxillary bone that forms the upper jaw and contains the upper teeth (Figure 6.3.19). Each tooth is anchored into a deep socket. On the anterior maxilla, just below the orbit, is the **infraorbital foramen**. This is the point of exit for a sensory nerve that supplies the nose, upper lip, and anterior cheek. On the inferior skull, the maxillary bone can be seen forming the anterior three-quarters of the hard palate (see Figure 6.3.8). The **hard palate** is the bony plate that forms the roof of the mouth and floor of the nasal cavity, separating the oral and nasal cavities. On the lateral side of each maxillary bone is where the maxilla articulates (connects) with the zygomatic bone.

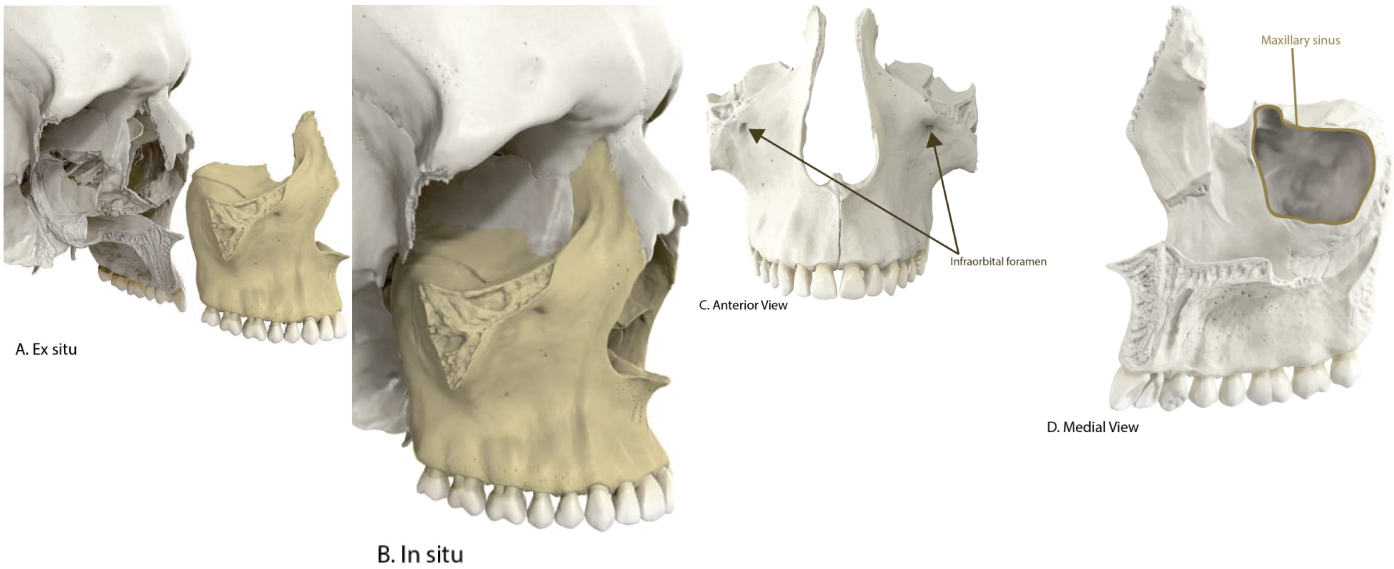

Figure 6.3.19: Maxillary Bone. The maxillary bone forms the upper jaw and supports the upper teeth. Each maxilla also forms the lateral floor of each orbit and the majority of the hard palate. *(Image credit: "Maxillary Bone" by Sofia Elizondo is licensed under CC BY-NC-SA 4.0, modification of images from Anatomy Standard under CC BY-NC 4.0.)*

Palatine Bone

The **palatine bone** is one of a pair of irregularly shaped bones that contribute small areas to the lateral walls of the nasal cavity and the medial wall of each orbit. The largest region of each of the palatine bone is the horizontal plate that forms the posterior aspect of the roof of your mouth. The plates from the right and left palatine bones join together at the midline to form the posterior quarter of the hard palate (see Figure 6.3.20 and Figure 6.3.8). Thus, the palatine bones are best seen in an inferior view of the skull and hard palate.

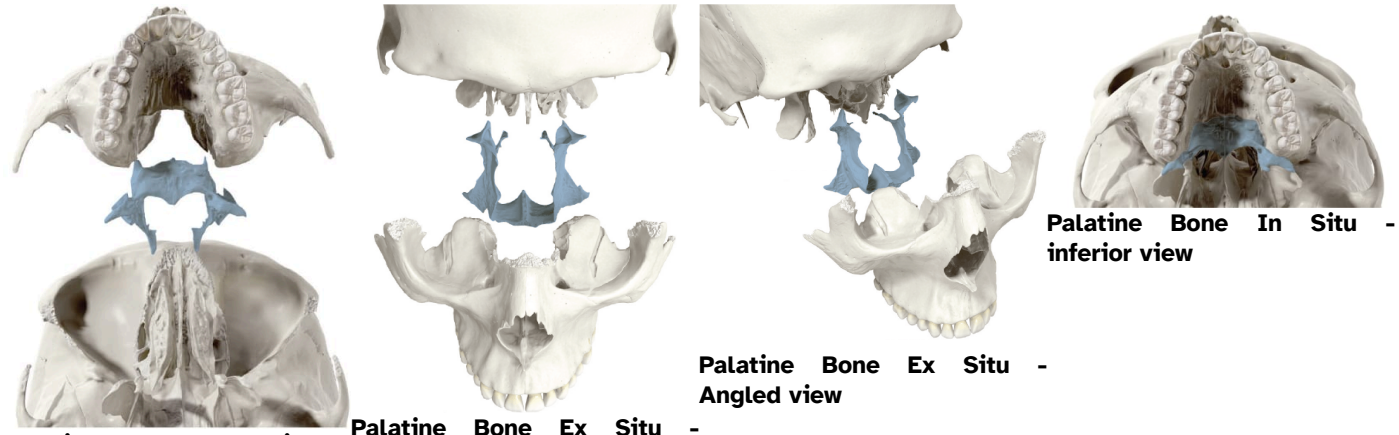

Palatine Bone Ex Situ - inferior view

Palatine Bone Ex Situ - anterior view

Palatine Bone Ex Situ - Angled view

Palatine Bone In Situ - inferior view

Figure 6.3.20: Palatine Bone - Ex Situ and In Situ. The palatine bone has a "U" shape and form the posterior aspect of the hard palate (posterior to the maxilla).

HOMEOSTATIC IMBALANCES

Cleft Lip and Cleft Palate

During embryonic development, the right and left maxilla bones come together at the midline to form the upper jaw. At the same time, the muscle and skin overlying these bones join together to form the upper lip. Inside the mouth, the palatine processes of the maxilla bones, along with the horizontal plates of the right and left palatine bones, join together to form the hard palate. If an error occurs in these developmental processes, a birth defect of cleft lip or cleft palate may result.

Cleft lip is a common development defect that affects approximately 1:1000 births, most of which are male. This defect involves a partial or complete failure of the right and left portions of the upper lip to fuse together, leaving a cleft (gap).

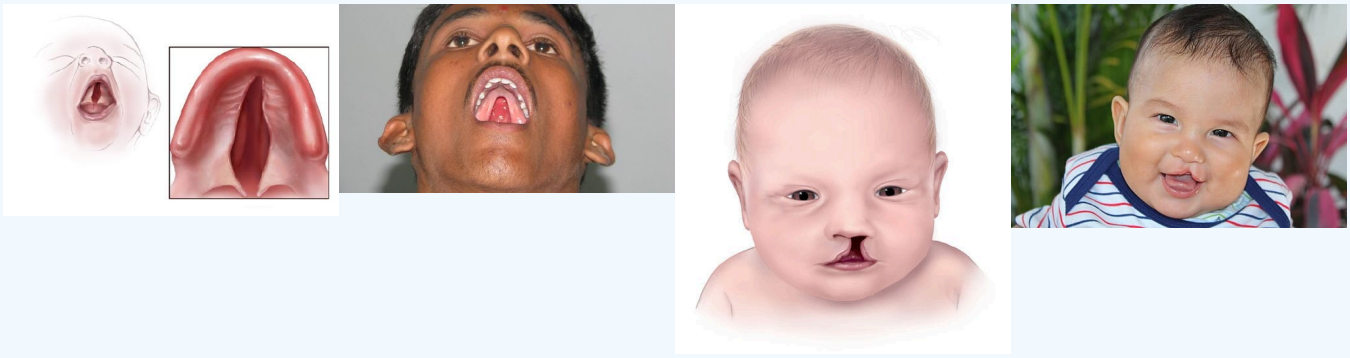

Figure 6.3.21: Illustrations and photographs of cleft palate and cleft lip. *(Image credits: "Infant with Cleft Palate Illustration" and "Infant with a Cleft Lip" by Centers for Disease Control and Prevention is in the public domain, via Wikimedia Commons; photograph of cleft palate by the Trinity Care Foundation is licensed under CC BY-NC-ND 2.0; "Infant with a Cleft Lip" by Perryrosen1 is licensed under CC BY-SA 4.0, via Wikimedia Commons.)*

A more severe developmental defect is cleft palate, which affects the hard palate. The hard palate is the bony structure that separates the nasal cavity from the oral cavity. It is formed during embryonic development by the midline fusion of the horizontal plates from the right and left palatine bones and the palatine processes of the maxilla bones. Cleft palate affects approximately 1:2500 births and is more common in females. It results from a failure of the two halves of the hard palate to completely come together and fuse at the midline, thus leaving a gap between them. This gap allows for communication between the nasal and oral cavities. In severe cases, the bony gap continues into the anterior upper jaw where the alveolar processes of the maxilla bones also do not properly join together above the front teeth. If this occurs, a cleft lip will also be seen. Because of the communication between the oral and nasal cavities, a cleft palate makes it very difficult for an infant to generate the suckling needed for nursing, thus leaving the infant at risk for malnutrition. Surgical repair is required to correct cleft palate defects.

Zygomatic Bone

The **zygomatic bone** is also known as the cheekbone. Each of the paired zygomatic bones forms much of the lateral wall of the orbit and the lateral-inferior margins of the anterior orbital opening (Figure 6.3.2). The short **temporal process of the zygomatic bone** projects posteriorly (Figure 6.3.22, where it forms the anterior portion of the **zygomatic arch** (Figure 6.3.3).

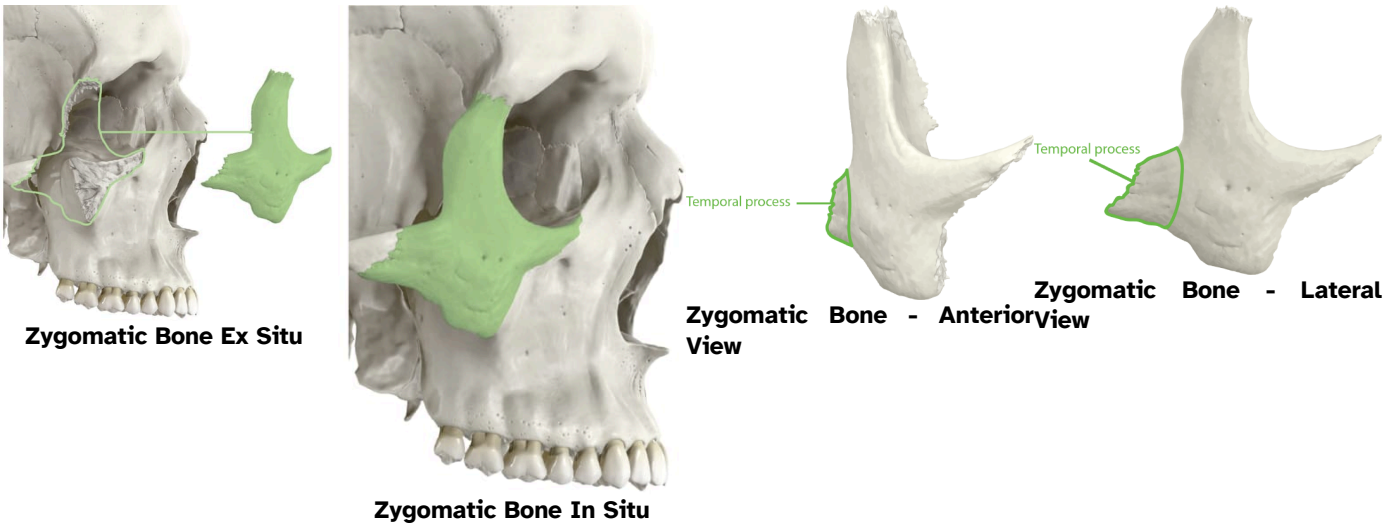

Figure 6.3.22: The zygomatic bone is the lateral facial bone. Its temporal process articulates with the temporal bone to form the zygomatic arch. *(Image credits: "Zygomatic Bone Ex Situ and In Situ" and "Zygomatic Bone Anterior and Lateral View" by Sofia Elizondo are licensed under CC BY-NC-SA 4.0, modification of images from Anatomy Standard under CC BY-NC 4.0.)*

Nasal Bone

The **nasal bone** is one of two small bones that articulate (join) with each other to form the bony base (bridge) of the nose. They also support the cartilages that form the lateral walls of the nose (Figure 6.3.23 and Figure 6.3.3). These are the bones that are damaged when the nose is broken.

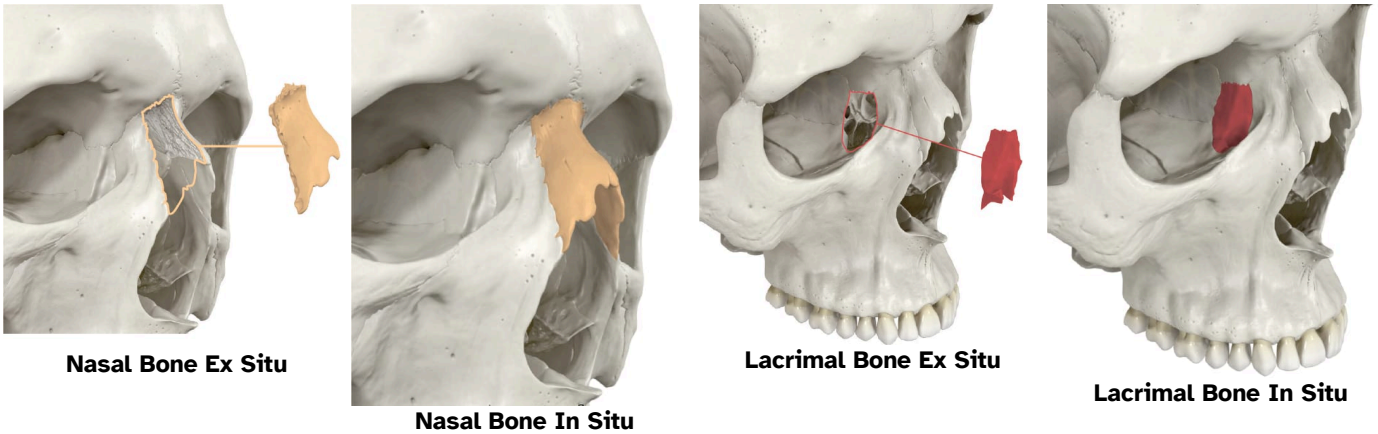

Figure 6.3.23: Nasal Bone and Lacrimal Bone Ex Situ and In Situ. The nasal bones form the superior, hard portion of the bridge of your nose. The lacrimal bones are within the orbit, forming part of the medial wall. *(Image credits: "Nasal Bone Ex Situ and In Situ" and "Lacrimal Bone Ex Situ and In Situ" by Sofia Elizondo are licensed under CC BY-NC-SA 4.0, modification of images from Anatomy Standard under CC BY-NC 4.0.)*

Lacrimal Bone

Each **lacrimal bone** is a small, rectangular bone that forms the anterior, medial wall of the orbit (Figure 6.3.23 and Figure 6.3.4). The anterior portion of the lacrimal bone forms a shallow depression and extending inferiorly from this is the **nasolacrimal canal**. The lacrimal fluid (tears of the eye), which serves to maintain the moist surface of the eye, drains at the medial corner of the eye into the nasolacrimal canal. This duct then extends downward to open into the nasal cavity, behind the inferior nasal concha. In the nasal cavity, the lacrimal fluid normally drains posteriorly, but with an increased flow of tears due to crying or eye irritation, some fluid will also drain anteriorly, thus causing a runny nose.

Inferior Nasal Conchae

The right and left **inferior nasal conchae** form a curved bony plate that projects into the nasal cavity space from the lower lateral wall (Figure 6.3.24 and Figure 6.3.5). The inferior concha is the largest of the nasal conchae and can easily be seen when looking into the anterior opening of the nasal cavity.

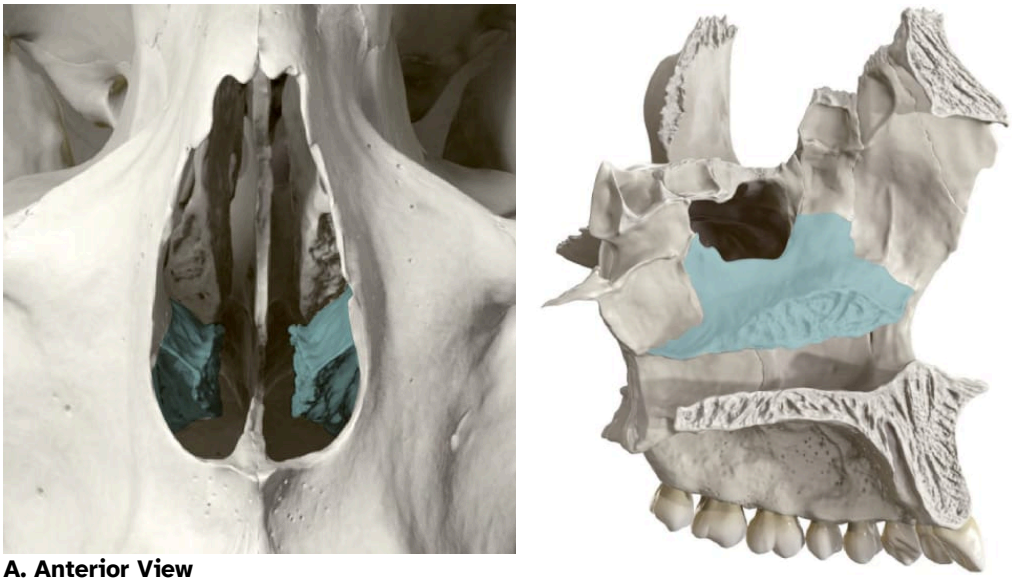

Figure 6.3.24: Inferior Nasal Conchae. These bones form ridges on the lateral walls of the nasal cavities. *(Image credits: "Inferior Nasal Conchae" by Jennifer Lange are licensed under CC BY-NC-SA 4.0, modification of images from Anatomy Standard.)*

Vomer Bone

The unpaired **vomer bone**, often referred to simply as the vomer, is triangular-shaped and forms the posterior-inferior part of the nasal septum (see Figure 6.3.25). The vomer is best seen when looking from behind into the posterior openings of the nasal cavity (see Figure 6.3.8). In this view, the vomer is seen to form the entire height of the nasal septum. A much smaller portion of the vomer can also be seen when looking into the anterior opening of the nasal cavity.

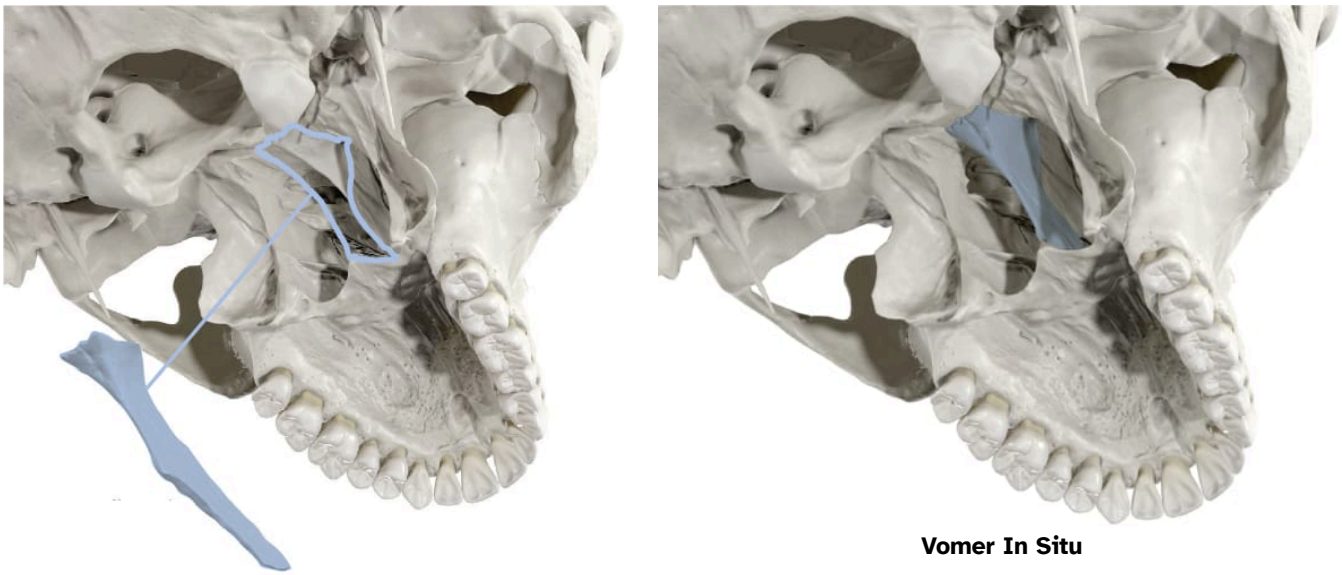

Vomer Ex Situ

Vomer In Situ

Figure 6.3.25: Vomer. The vomer is a small bone that makes up the inferior portion of the nasal septum. *(Image credits: "Vomer Ex Situ and In Situ" by Sofia Elizondo are licensed under CC BY-NC-SA 4.0, modification of images from Anatomy Standard under CC BY-NC 4.0.)*

Mandible

The **mandible** forms the lower jaw and is the only moveable bone of the skull. At the time of birth, the mandible consists of paired right and left bones, but these fuse together during the first year to form the single U-shaped mandible of the adult skull (Figure 6.3.26).

The each side of the mandible has two upward-going bony projections. The posterior projection is the **condylar process of the mandible**, which is topped by the oval-shaped **condyle**. The condyle of the mandible articulates (joins) with the mandibular fossa and articular tubercle of the temporal bone. Together these articulations form the temporomandibular joint, which allows for opening and closing of the mouth (see Figure 6.3.6).

Important landmarks of the mandible, as seen in Figure 6.3.26, include the mental foramen, the opening located on each side of the anterior-lateral mandible, which is the exit site for a sensory nerve that supplies the chin.

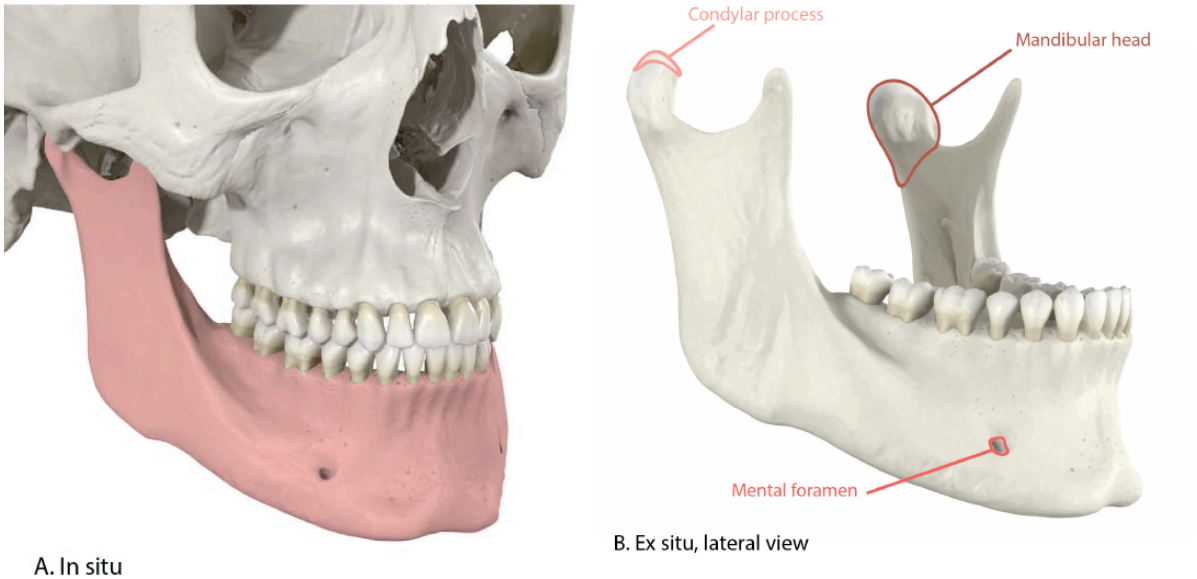

Figure 6.3.26: Mandible. The mandible is the only moveable bone of the skull. The condylar process on the mandibular head articulates with the mandibular fossa of the temporal bone. *(Image credits: "Mandible" by Sofia Elizondo are licensed under CC BY-NC-SA 4.0, modification of images from Anatomy Standard under CC BY-NC 4.0.)*

Interactive Element

Explore bones of the skull in these 3D interactive models:

This interactive element is not available in this format. Visit the link or scan the QR code to access it online.

View this Interactive Content online

Human Skull (calvarium & mandible removed) by **UBC Medicine - Educational Media** on **Sketchfab**

This interactive element is not available in this format. Visit the link or scan the QR code to access it online.

View this Interactive Content online

Human skull NC1K by **SusanElaineJones** on **Sketchfab**

This interactive element is not available in this format. Visit the link or scan the QR code to access it online.

View this Interactive Content online

Human Skull - Foramen by **The Center for BioMedical Visualization at SGU** on **Sketchfab**

Paranasal Sinuses

The **paranasal sinuses** are hollow, air-filled spaces located within certain bones of the skull (Figure 6.3.27). All of the sinuses communicate with the nasal cavity (paranasal = “next to nasal cavity”) and are lined with nasal mucosa. They serve to reduce bone mass and thus lighten the skull, and they also add resonance to the voice. This second feature is most obvious when you have a cold or sinus congestion. These produce swelling of the mucosa and excess mucus production, which can obstruct the narrow passageways between the sinuses and the nasal cavity, causing your voice to sound different to yourself and others. This blockage can also allow the sinuses to fill with fluid, with the resulting pressure producing pain and discomfort.

The paranasal sinuses are named for the skull bone that each occupies. The **frontal sinus** is located just above the eyebrows, within the frontal bone (Figure 6.3.9). This irregular space may be divided at the midline into bilateral spaces, or these may be fused into a single sinus space. The frontal sinus is the most anterior of the paranasal sinuses. The largest sinus is the **maxillary sinus** (Figure 6.3.19). These are paired and located within the right and left maxillary bones, where they occupy the area just below the orbits. The maxillary sinuses are most commonly involved during sinus infections. Because their connection to the nasal cavity is located high on their medial wall, they are difficult to drain. The **sphenoid sinus** is a single, midline sinus . It is located within the body of the sphenoid bone, just anterior and inferior to the sella turcica, thus making it the most posterior of the paranasal sinuses. The lateral aspects of the ethmoid bone contain multiple small spaces separated by very thin bony walls (Figure 6.3.15). Each of these spaces is called an **ethmoid air cell**. These are located on both sides of the ethmoid bone, between the upper nasal cavity and medial orbit, just behind the superior nasal conchae.

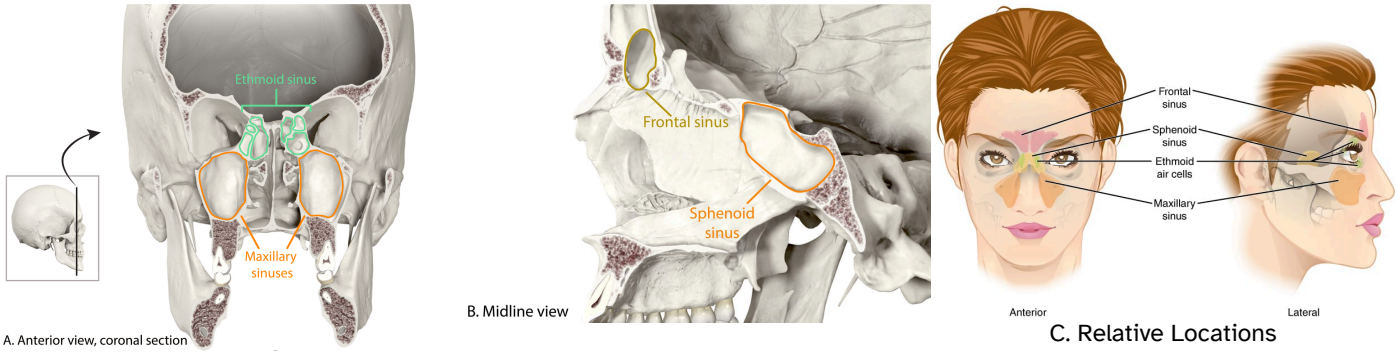

Figure 6.3.27: Paranasal Sinuses. The paranasal sinuses are hollow, air-filled spaces named for the skull bone that each occupies. The most anterior is the frontal sinus, located in the frontal bone above the eyebrows. The largest are the maxillary sinuses, located in the right and left maxillary bones below the orbits. The most posterior is the sphenoid sinus, located in the body of the sphenoid bone, under the sella turcica. The ethmoid air cells are multiple small spaces located in the right and left sides of the ethmoid bone, between the medial wall of the orbit and lateral wall of the upper nasal cavity. *(Images A and B credit: "Paranasal Sinuses" by Mark Schaeffer are licensed under CC BY-NC-SA 4.0, modification of image from Anatomy Standard under CC BY-NC 4.0. Image C credit: "Paranasal Sinuses" by OpenStax is licensed under CC BY 3.0)*

Hyoid Bone

The **hyoid bone** is an independent bone that does not articulate (form a joint) any other bone and thus is not part of the skull. In fact, it is the only bone in the human body that does not articulate with another bone, making it unique. It is a small U-shaped bone located in the upper neck near the level of the inferior mandible, with the tips of the “U” pointing posteriorly (Figure 6.3.28). The hyoid serves as the base for the tongue above, and is attached to the larynx below and the pharynx posteriorly. The hyoid is held in position by a series of small muscles that attach to it either from above or below. These muscles act to move the hyoid up/down or forward/back. Movements of the hyoid are coordinated with movements of the tongue, larynx, and pharynx during swallowing and speaking.

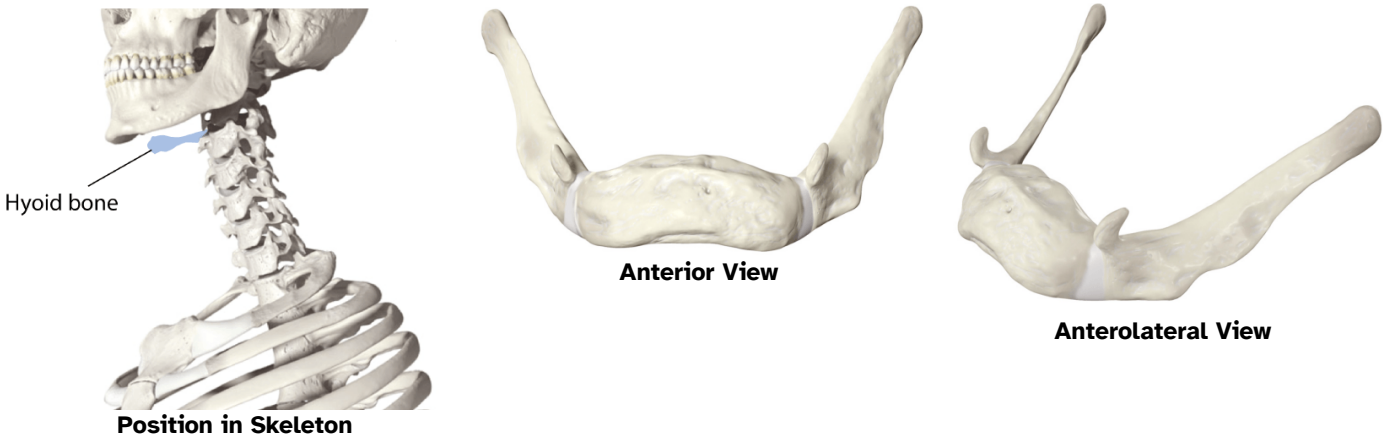

Figure 6.3.28: Hyoid Bone. The hyoid bone is located in the upper neck and does not join with any other bone. It provides attachments for muscles that act on the tongue, larynx, and pharynx. *(Image credits: "Hyoid Bone Position" by Sofia Elizondo is licensed under CC BY-NC-SA 4.0, modification of images from Anatomy Standard under CC BY-NC 4.0. "Hyoid Bone Anterior and Anterolateral Views" by Anatomy Standard are licensed under CC BY-NC 4.0.)*

Concept Review

The skull consists of the cranial bones and the facial bones. The cranial bones surround and protect the brain, which occupies the cranial cavity inside the skull. The brain case is formed by eight bones, the paired parietal and temporal bones plus the unpaired frontal, occipital, sphenoid, and ethmoid bones. The narrow gap between the bones is filled with dense, fibrous connective tissue that unites the bones to form sutures. The sagittal suture joins the right and left parietal bones. The coronal suture joins the parietal bones to the frontal bone, the lambdoid suture joins them to the occipital bone, and the squamous suture joins them to the temporal bone.

The facial bones support the facial structures and form the upper and lower jaws. These consist of 14 bones, with the paired maxillary, palatine, zygomatic, nasal, lacrimal, and inferior conchae bones and the unpaired vomer and mandible bones. The ethmoid bone also contributes to the formation of facial structures. The maxilla forms the upper jaw and the mandible forms the lower jaw. The maxilla also forms the larger anterior portion of the hard palate, which is completed by the smaller palatine bones that form the posterior portion of the hard palate.

Summary Table: Cranial Bones

Bone	Major Landmarks	Animation
Frontal	• frontal sinus	Interactive Content *This interactive element is not available in this format. Visit the link or scan the QR code to access it online.* View this Interactive Content online

Bone	Major Landmarks	Animation
Parietal (right and left)		Interactive Content *This interactive element is not available in this format. Visit the link or scan the QR code to access it online.* View this Interactive Content online
Occipital	• external occipital protuberance • foramen magnum • hypoglossal canal • occipital condyles • sulci for the transverse sinus and the superior sagittal sinus	YouTube Video *This interactive element is not available in this format. Visit the link or scan the QR code to access it online.* View this YouTube Video online
Temporal (right and left)	• carotid canal • external acoustic meatus • internal acoustic meatus • jugular foramen • mastoid process • styloid process • zygomatic process (part of zygomatic arch)	YouTube Video *This interactive element is not available in this format. Visit the link or scan the QR code to access it online.* View this YouTube Video online
Sphenoid	• foramen ovale • foramen rotundum • foramen spinosum • inferior orbital fissure • optic canal • optic groove • sella turcica with hypophyseal fossa and dorsum sellae • sphenoid sinus • superior orbital fissure	Interactive Content *This interactive element is not available in this format. Visit the link or scan the QR code to access it online.* View this Interactive Content online

Bone	Major Landmarks	Animation
Ethmoid	• cribriform plate • crista galli • ethmoid air cells • middle nasal conchae • perpendicular plate • superior nasal conchae	YouTube Video *This interactive element is not available in this format. Visit the link or scan the QR code to access it online.* View this YouTube Video online

Summary Table: Facial Bones

Bone	Major Landmarks	Animation
Inferior nasal conchae		
Lacrimal		
Mandible	• condylar process • mandibular head • mental foramen	
Maxilla	• infraorbital foramen • maxillary sinus	Interactive Content *This interactive element is not available in this format. Visit the link or scan the QR code to access it online.* View this Interactive Content online
Nasal		YouTube Video *This interactive element is not available in this format. Visit the link or scan the QR code to access it online.* View this YouTube Video online
Palatine		
Vomer		

Bone	Major Landmarks	Animation
Zygomatic	• temporal process (part of zygomatic arch)	YouTube Video *This interactive element is not available in this format. Visit the link or scan the QR code to access it online.* View this YouTube Video online

The hyoid bone is located in the upper neck and does not join with any other bone. It is held in position by muscles and serves to support the tongue above, the larynx below, and the pharynx posteriorly.

Review Questions

Query 6.3.1

This interactive element is not available in this format. Visit the link or scan the QR code to access it online.

View this Interactive Content online

Query 6.3.2

This interactive element is not available in this format. Visit the link or scan the QR code to access it online.

View this Interactive Content online

Critical Thinking Questions

Query 6.3.3

This interactive element is not available in this format. Visit the link or scan the QR code to access it online.

View this Interactive Content online

Query 6.3.4

This interactive element is not available in this format. Visit the link or scan the QR code to access it online.

View this Interactive Content online

Query 6.3.5

This interactive element is not available in this format. Visit the link or scan the QR code to access it online.

View this Interactive Content online

References

Centers for Disease Control and Prevention (US). Injury prevention and control: traumatic brain injury [Internet]. Atlanta, GA; [cited 2013 Mar 18]. Available from: http://www.cdc.gov/traumaticbraininjury/statistics.html.

Glossary

Query 6.3.6

This interactive element is not available in this format. Visit the link or scan the QR code to access it online.

View this Interactive Content online

Contributors and Attributions

- OpenStax Anatomy & Physiology (CC BY 4.0). Access for free at https://openstax.org/books/anatomy-and-physiology

This page titled 6.3: The Skull is shared under a CC BY-NC-SA 4.0 license and was authored, remixed, and/or curated by Jennifer Lange et al..

- 6.3: The Skull by Whitney Menefee, Julie Jenks, Chiara Mazzasette, and Kim-Leiloni Nguyen is licensed CC BY 4.0.

6.4: The Vertebral Column

By the end of this section, you will be able to:

- Describe each region of the vertebral column and the number of bones in each region
- Discuss the curves of the vertebral column and how these change after birth
- Describe a typical vertebra and determine the distinguishing characteristics for vertebrae in each vertebral region and features of the sacrum and the coccyx
- Define the structure of an intervertebral disc
- Determine the location of the ligaments that provide support for the vertebral column

The vertebral column is also known as the spinal column or spine (Figure 6.4.1). It consists of a sequence of vertebrae (singular = vertebra), each of which is separated and united by an **intervertebral disc,** composed of a pad of fibrocartilage. Together, the vertebrae and intervertebral discs form the vertebral column. It is a flexible column that supports the head, neck, and body and allows for their movements. It also protects the spinal cord, which passes down the back through openings in the vertebrae.

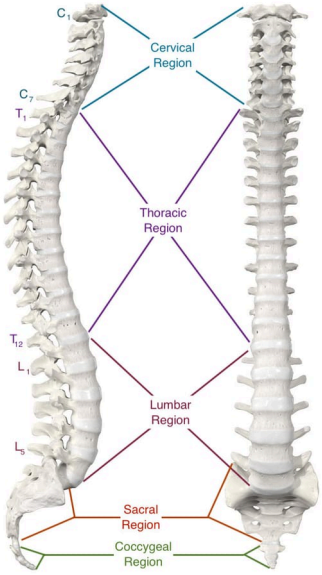

Figure 6.4.1: Vertebral Column. The adult vertebral column consists of 24 vertebrae, plus the sacrum and coccyx. The vertebrae are divided into three regions: cervical C1–C7 vertebrae, thoracic T1–T12 vertebrae, and lumbar L1–L5 vertebrae. *(Image credit: "Vertebral Column Regions" by Jennifer Lange is licensed under CC BY-NC-SA 4.0>, modification of image from Anatomy Standard under CC BY-NC 4.0.*

Regions of the Vertebral Column

The vertebral column originally develops as a series of 33 vertebrae, but this number is eventually reduced to 24 vertebrae, plus the sacrum and coccyx. The vertebral column is subdivided into five regions, with the vertebrae in each area named for that region and numbered in descending order. In the neck, there are seven cervical vertebrae, each designated with the letter “C” followed by its number. Superiorly, the C1 vertebra articulates (forms a joint) with the occipital condyles of the occipital bone of the skull. Inferiorly, C1 articulates with the superior portion of the C2 vertebra. The inferior portion of C2 then articulates with the superior portion of the C3 vertebra, and so on. Below the cervical vertebrae are the 12 thoracic vertebrae, designated T1–T12. The lower back contains the L1–L5 lumbar vertebrae. The single sacrum, which is also part of the pelvis, is formed by the fusion of five sacral vertebrae. Similarly, the coccyx, or tailbone, results from the fusion of four small coccygeal vertebrae. However, the sacral and coccygeal fusions do not start until age 20 and are usually completed around age 30.

An interesting anatomical fact is that almost all mammals have seven cervical vertebrae, regardless of body size. This means that there are large variations in the size of cervical vertebrae, ranging from the very small cervical vertebrae of a shrew to the greatly elongated vertebrae in the neck of a giraffe. In a full-grown giraffe, each cervical vertebra is 11 inches tall.

Curvatures of the Vertebral Column

The adult vertebral column does not form a straight line, but instead has four curvatures along its length (see Figure 6.4.2). These curves increase the vertebral column's strength, flexibility, and ability to absorb shock. When the load on the spine is increased, by carrying a heavy backpack for example, the curvatures increase in depth (become more curved) to accommodate the extra weight. They then spring back when the weight is removed. The four adult curvatures are classified as either primary or secondary curvatures. Primary curves are retained from the original fetal curvature, while secondary curvatures develop after birth.

During fetal development, the body is flexed anteriorly into the fetal position, giving the entire vertebral column a single curvature that is concave anteriorly. In the adult, this fetal curvature is retained in two regions of the vertebral column as the **thoracic curve**, which involves the thoracic vertebrae, and the **sacrococcygeal curve**, formed by the sacrum and coccyx. Each of these is thus called a **primary curve** because they are retained from the original fetal curvature of the vertebral column.

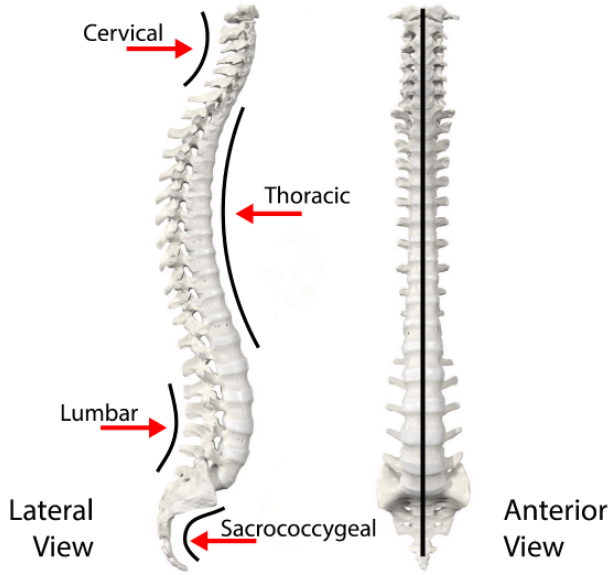

Figure 6.4.2: When viewed laterally, the vertebral column has four curves: the thoracic and sacrococcygeal regions are concave on the anterior side while the cervical and lumbar regions are concave on the posterior side. When viewed anteriorly (or posteriorly) the vertebral column is straight. *(Image credit: "Vertebral Column Curvatures" by Jennifer Lange is licensed under CC BY-NC-SA 4.0, modification of image from Anatomy Standard under CC BY-NC 4.0.)*

A **secondary curve** develops gradually after birth as the child learns to sit upright, stand, and walk. Secondary curves are concave posteriorly, opposite in direction to the original fetal curvature. The **cervical curve** of the neck region develops as the infant begins to hold their head upright when sitting. Later, as the child begins to stand and then to walk, the **lumbar curve** of the lower back develops. In adults, the lumbar curve is generally deeper in females, which helps to reduce back pressure during pregnancy.

DISORDERS OF THE...

Vertebral Column

Developmental anomalies, pathological changes, or obesity can enhance the normal vertebral column curves, resulting in the development of abnormal or excessive curvatures (Figure 6.4.3). **Kyphosis**, also referred to as humpback or hunchback, is an excessive posterior curvature of the thoracic region. This can develop when osteoporosis causes weakening and erosion of the anterior portions of the upper thoracic vertebrae, resulting in their gradual collapse. **Lordosis**, or swayback, is an excessive anterior curvature of the lumbar region and is most commonly associated with obesity or late pregnancy. The accumulation of body weight in the abdominal region results an anterior shift in the line of gravity that carries the weight of the body. This causes in an anterior tilt of the pelvis and a pronounced enhancement of the lumbar curve.

Scoliosis is an abnormal, lateral curvature, accompanied by twisting of the vertebral column. Compensatory curves may also develop in other areas of the vertebral column to help maintain the head positioned over the feet. Scoliosis is the most common vertebral abnormality among girls. The cause is usually unknown, but it may result from weakness of the

back muscles, defects such as differential growth rates in the right and left sides of the vertebral column, or differences in the length of the lower limbs. When present, scoliosis tends to get worse during adolescent growth spurts. Although most individuals do not require treatment, a back brace may be recommended for growing children. In extreme cases, surgery may be required.

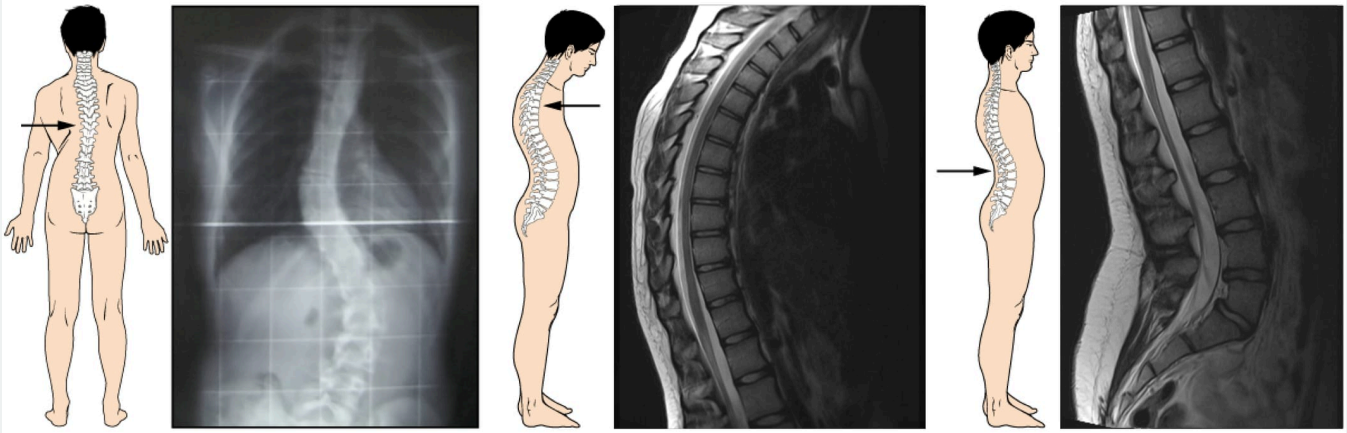

Excessive vertebral curves can be identified while an individual stands in the anatomical position. Observe the vertebral profile from the side and then from behind to check for kyphosis or lordosis. Then have the person bend forward. If scoliosis is present, an individual will have difficulty in bending directly forward, and the right and left sides of the back will not be level with each other in the bent position.

Figure 6.4.3: Abnormal Curvatures of the Vertebral Column. (a) Scoliosis is an abnormal lateral bending of the vertebral column. (b) An excessive curvature of the upper thoracic vertebral column is called kyphosis. (c) Lordosis is an excessive curvature in the lumbar region of the vertebral column. (*Image credit: "Abnormal Curves of Vertebral Column" by Jennifer Lange is licensed under CC BY-NC-SA 4.0. Modification of original by OpenStax. "Kyphosis" and "Lordosis" MRI images from Radiopedia. Case courtesy of Mostafa El-Feky.)*

General Structure of a Vertebra

Within the different regions of the vertebral column, vertebrae vary in size and shape, but they all follow a similar structural pattern. A typical vertebra will consist of a body, a vertebral arch, and seven processes (Figure 6.4.4). The **body** is the anterior portion of each vertebra and is the part that supports the body weight. Because of this, the vertebral bodies progressively increase in size and thickness going down the vertebral column. The bodies of adjacent vertebrae are separated and strongly united by an intervertebral disc.

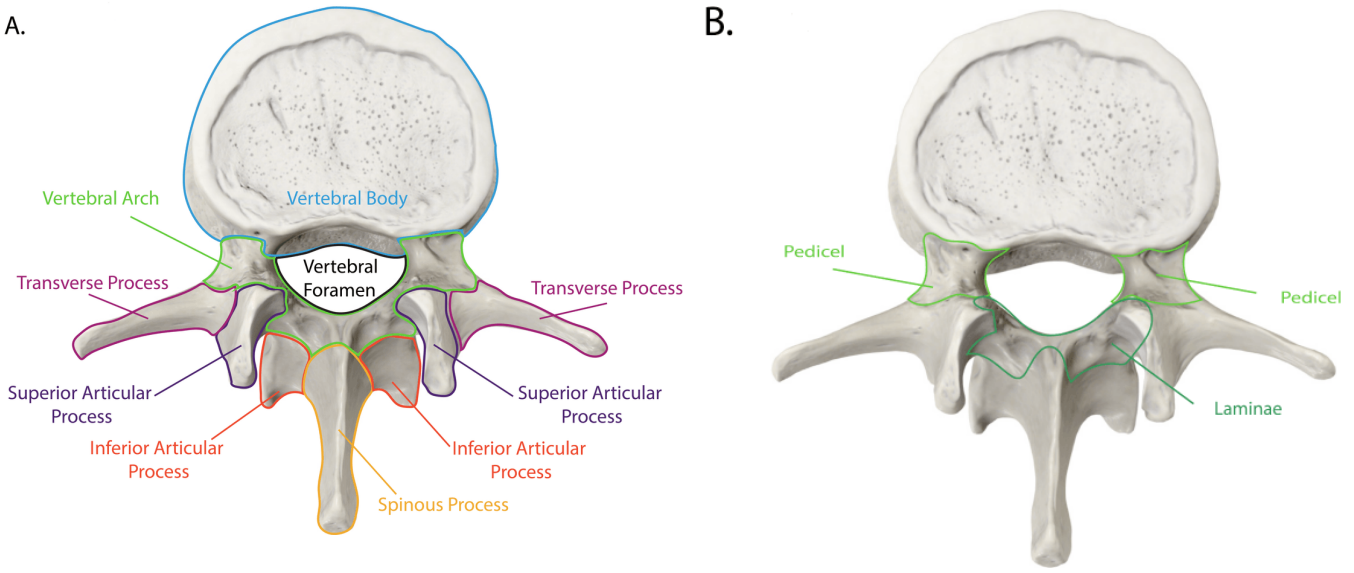

Figure 6.4.4: Parts of a Typical Vertebra. A typical vertebra consists of a body and a vertebral arch. The arch is formed by the paired pedicles and paired laminae (B). Arising from the vertebral arch are the transverse, spinous, superior articular, and inferior articular processes. *(Image credit: "Typical Vertebral Structure" by Gabrielle Spurlock is licensed under CC BY-NC-SA 4.0, modification of image from Anatomy Standard under CC BY-NC 4.0.)*

The **vertebral arch** forms the posterior portion of each vertebra. It consists of four parts, the right and left pedicles and the right and left laminae. Each **pedicle** forms one of the lateral sides of the vertebral arch. The pedicles are anchored to the posterior side of the vertebral body. Each **lamina** forms part of the posterior roof of the vertebral arch. The large opening between the vertebral arch and body is the **vertebral foramen**, which contains the spinal cord (Figure 6.4.5). In the intact vertebral column, the vertebral foramina of all of the vertebrae align to form the **vertebral (spinal) canal**, which serves as the bony protection and passageway for the spinal cord down the back. When the vertebrae are aligned together in the vertebral column, notches in the margins of the pedicles of adjacent vertebrae together form an **intervertebral foramen**, the opening through which a spinal nerve exits from the vertebral column.

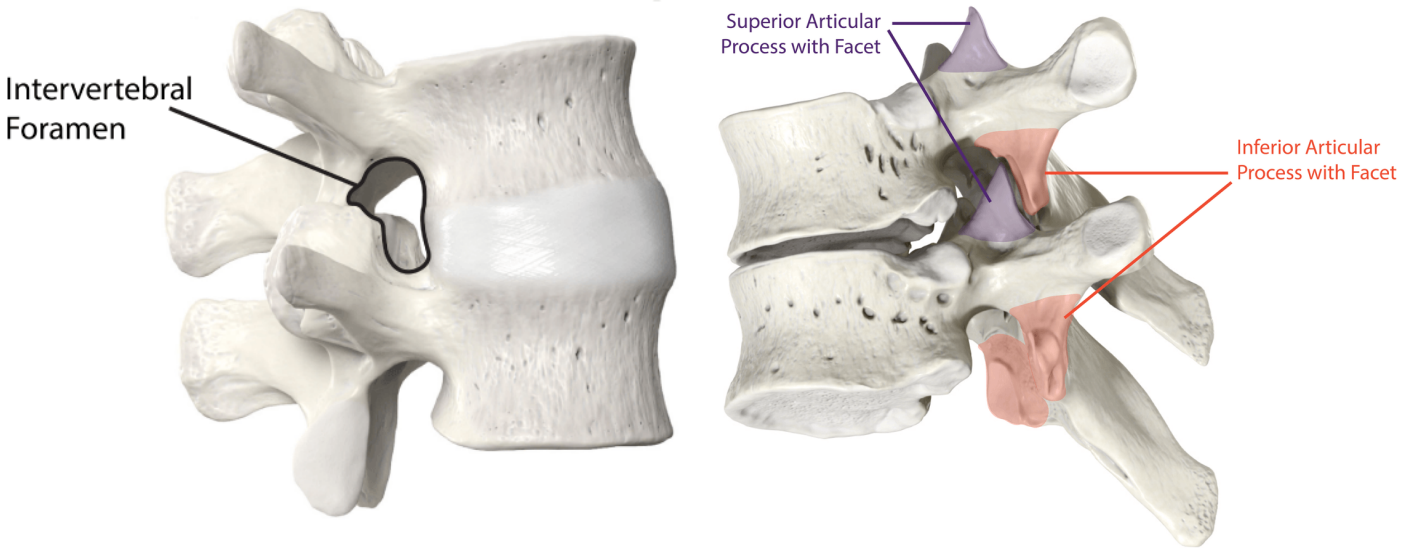

Figure 6.4.5: Intervertebral Features. The intervertebral foramen is the space through which spinal nerves pass that is located between the pedicels of adjacent vertebrae. The vertebral facet joints occur between adjacent superior and inferior articular processes, with the specific contact points being their facets. *(Image credit: "Intervertebral Foramen" by Jennifer Lange is licensed under CC BY-NC-SA 4.0, modification of image from Anatomy Standard under CC BY-NC 4.0.)*

Seven processes arise from the vertebral arch. Each paired **transverse process** projects laterally and arises from the junction point between the pedicle and lamina. The single **spinous process** (vertebral spine) projects posteriorly at the midline of the

back. The vertebral spines can easily be felt as a series of bumps just under the skin down the middle of the back. The transverse and spinous processes serve as important muscle attachment sites. A **superior articular process** extends or faces upward, and an **inferior articular process** faces or projects downward on each side of a vertebrae. The paired superior articular processes of one vertebra join with the corresponding paired inferior articular processes from the next higher vertebra. Each process has a **facet**, or flat surface, to accommodate this joining of the vertebrae. These junctions form slightly moveable joints between the adjacent vertebrae. The shape and orientation of the articular processes vary in different regions of the vertebral column and play a major role in determining the type and range of motion available in each region.

Regional Modifications of Vertebrae

In addition to the general characteristics of a typical vertebra described above, vertebrae also display characteristic size and structural features that vary between the different vertebral column regions. For example, cervical vertebrae are smaller than lumbar vertebrae due to differences in the proportion of body weight that each supports. Only thoracic vertebrae have sites for rib attachment, and the vertebrae that give rise to the sacrum and coccyx have fused together into single bones.

Cervical Vertebrae

Typical **cervical vertebrae**, such as C3 through C7, have several characteristic features that differentiate them from thoracic or lumbar vertebrae (Figure 6.4.6). Cervical vertebrae have a small body, reflecting the fact that they carry the least amount of body weight. Cervical vertebrae usually have a bifid (Y-shaped) spinous process. The spinous processes of the C3–C6 vertebrae are short, but the spine of C7 is much longer. You can find these vertebrae by running your finger down the midline of the posterior neck until you encounter the prominent C7 spine located at the base of the neck. Because of this feature, the C7 vertebra is also known as the **vertebra prominens**. The transverse processes of the cervical vertebrae are sharply curved (U-shaped) to allow for passage of the cervical spinal nerves. Each transverse process also has an opening called the **transverse foramen**. An important artery that supplies the brain ascends up the neck by passing through these openings. The superior and inferior articular processes of the cervical vertebrae are flattened and largely face upward or downward, respectively.

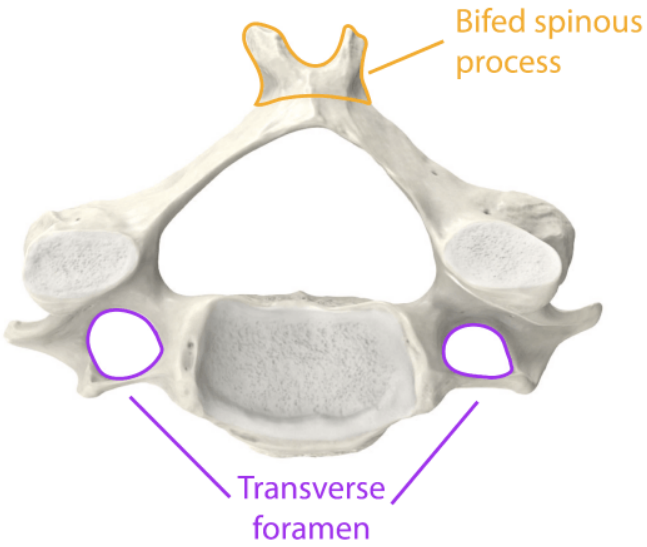

Figure 6.4.6: Cervical Vertebrae. A typical cervical vertebra has a small body, a bifid spinous process, transverse processes that have a transverse foramen that allow for passage of arteries to the brain. The atlas (C1 vertebra) does not have a body or spinous process. It consists of an anterior and a posterior arch and elongated transverse processes. The axis (C2 vertebra) has the upward projecting dens, which articulates with the anterior arch of the atlas. *(Image credit: "Typical Vertebra Structure" by Gabrielle Spurlock is licensed under CC BY-NC-SA 4.0, modification of image from Anatomy Standard under CC BY-NC 4.0.)*

The first and second cervical vertebrae are further modified, giving each a distinctive appearance (Figure 6.4.7). The first cervical (C1) vertebra is also called the **atlas**, because this is the vertebra that supports the skull on top of the vertebral column (in Greek mythology, Atlas was the god who supported the heavens on his shoulders). The C1 vertebra does not have a body or spinous process. Instead, it is ring-shaped, consisting of an **anterior arch** and a **posterior arch**. The transverse processes of the atlas are longer and extend more laterally than do the transverse processes of any other cervical vertebrae. The superior articular

processes face upward and are deeply curved for articulation with the occipital condyles on the base of the skull. The inferior articular processes are flat and face downward to join with the superior articular processes of the C2 vertebra.

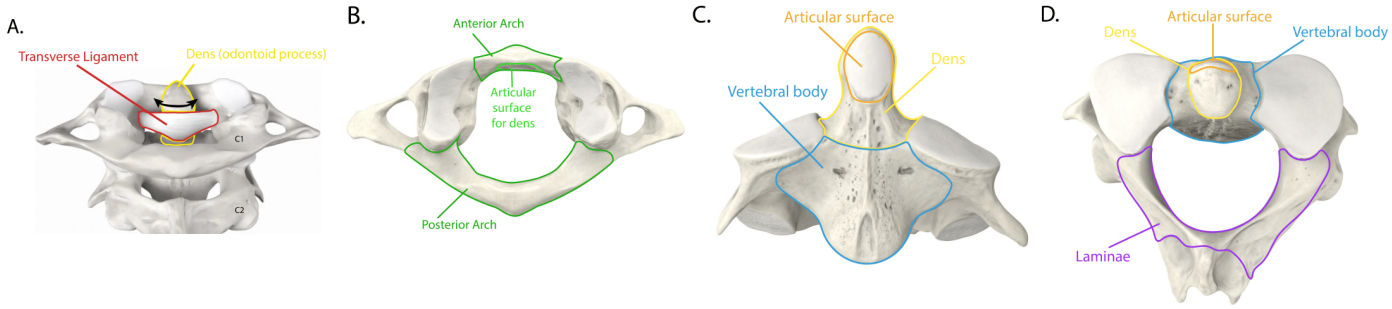

Figure 6.4.7: B. The atlas (C1 vertebra) does not have a body or spinous process. It consists of an anterior and a posterior arch and elongated transverse processes. C & D. The axis (C2 vertebra) has the upward projecting dens, which articulates with the anterior arch of the atlas. *(Image credit: "C1 and C2 Vertebrae Structure" by Gabrielle Spurlock is licensed under CC BY-NC-SA 4.0, modification of image from Anatomy Standard under CC BY-NC 4.0.)*

The second cervical (C2) vertebra is called the **axis**, because it serves as the axis for rotation when turning the head toward the right or left. The axis resembles typical cervical vertebrae in most respects, but is easily distinguished by the **dens** (odontoid process), a bony projection that extends upward from the vertebral body. The dens joins with the inner aspect of the anterior arch of the atlas, where it is held in place by the **transverse ligament**.

Thoracic Vertebrae

The bodies of the **thoracic vertebrae** are larger than those of cervical vertebrae (Figure 6.4.8). The characteristic feature for a typical midthoracic vertebra is the spinous process, which is long and has a pronounced downward angle that causes it to overlap the next inferior vertebra. The superior articular processes of thoracic vertebrae face anteriorly and the inferior processes face posteriorly. These orientations are important determinants for the type and range of movements available to the thoracic region of the vertebral column.

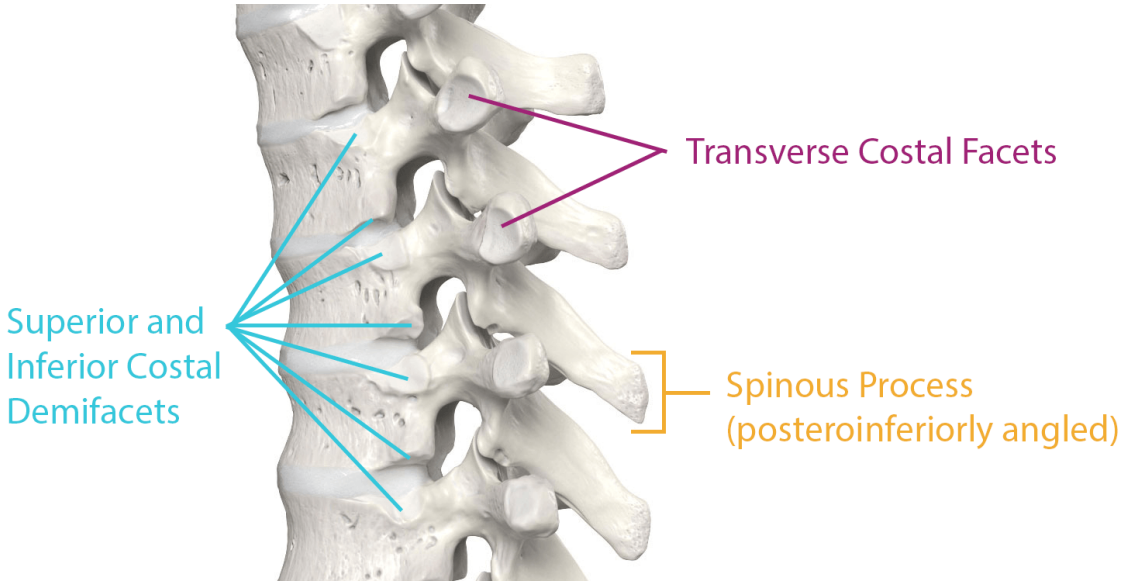

Figure 6.4.8: Thoracic Vertebrae. A typical thoracic vertebra is distinguished by the spinous process, which is long and projects downward to overlap the next inferior vertebra. It also has articulation sites (facets) on the vertebral body and the transverse process for rib attachment. *(Image credit: "Thoracic Vertebral Column Features" by Jennifer Lange is licensed under CC BY-NC-SA 4.0, modification of image from Anatomy Standard under CC BY-NC 4.0.)*

Thoracic vertebrae are the only ones with several additional articulation sites, each of which is called a **facet**, where a rib is attached (Figure 6.4.9). Most thoracic vertebrae have a superior and inferior facet located on the lateral sides of the body, each of which is called a **costal demifacet** (costal = “rib”). These are for articulation with the head (end) of a rib. An additional facet,

the **transverse costal facet**, is located on the transverse process for articulation with the tubercle of a rib.

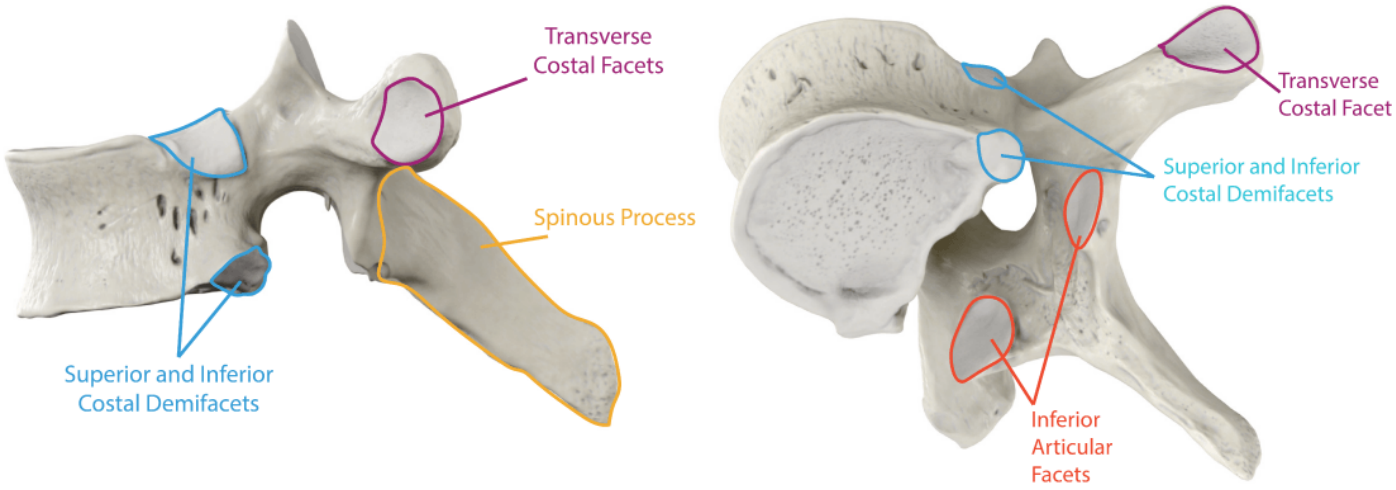

Figure 6.4.9: Unique features of a thoracic vertebra are the facets for articulating with the ribs and the spinous process that is long, slender, and angled in an inferior direction. *(Image credit: "Thoracic Vertebrae Features" by Gabrielle Spurlock is licensed under CC BY-NC-SA 4.0, modification of image from Anatomy Standard under CC BY-NC 4.0.)*

Lumbar Vertebrae

Lumbar vertebrae carry the greatest amount of body weight and are thus characterized by the large size and thickness of the vertebral body (Figure 6.4.10). They have short transverse processes and a short, blunt spinous process that projects posteriorly. The articular processes are large, with the superior process facing backward and the inferior facing forward.

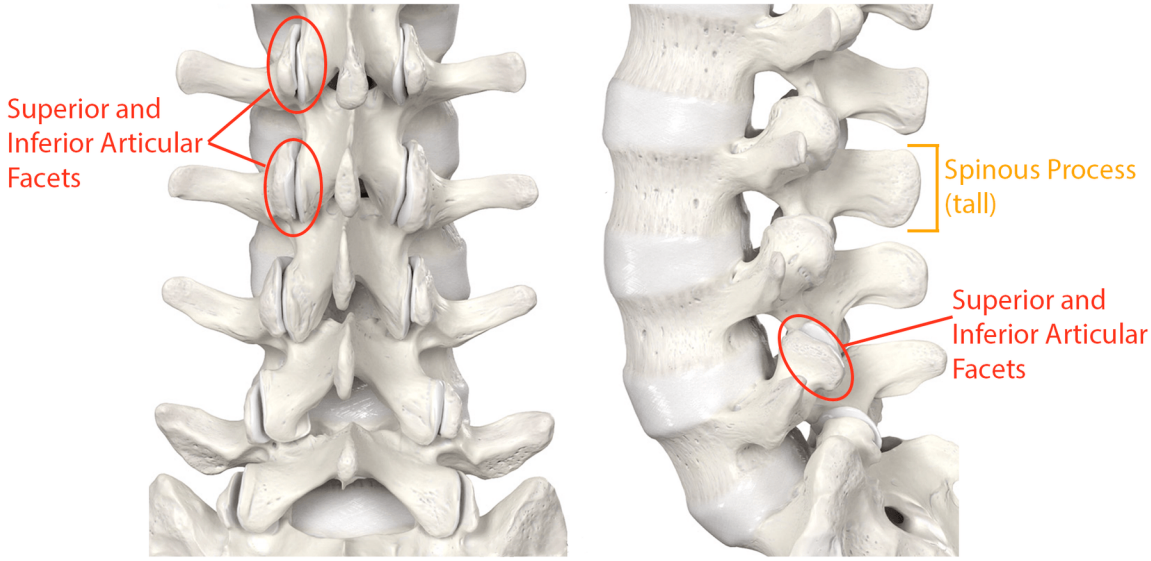

Figure 6.4.10: Lumbar vertebrae are characterized by having a large, thick body and a tall, robust spinous process. The articular processes are angled close to the sagittal plane, so the facets face medially and laterally. *(Image credit: "Lumbar Vertebral Column Features" by Jennifer Lange is licensed under CC BY-NC-SA 4.0, modification of image from Anatomy Standard under CC BY-NC 4.0.)*

Sacrum and Coccyx

The **sacrum** is a triangular-shaped bone that is thick and wide across its superior base where it is weight bearing and then tapers down to an inferior, non-weight bearing apex (Figure 6.4.11). It is formed by the fusion of five sacral vertebrae, a process that does not begin until after the age of 20 and continues until around age 30. On the anterior surface of the older adult sacrum, the lines of vertebral fusion can be seen as four transverse ridges. On the posterior surface, running down the midline, is the

median sacral crest, a bumpy ridge that is the remnant of the fused spinous processes (median = “midline”; while medial = “toward, but not necessarily at, the midline”). Similarly, the fused transverse processes of the sacral vertebrae form the lateral sacral crest. Lateral to this is the roughened **auricular surface**, which joins with the ilium portion of the hipbone to form the immobile sacroiliac joints of the pelvis. Passing inferiorly through the sacrum is a bony tunnel called the **sacral canal** through which the spinal nerves pass. The anterior and posterior surfaces of the sacrum have a series of paired openings, called foramina, that connect to the sacral canal. These openings allow for the anterior and posterior branches of the sacral spinal nerves to exit the sacrum. The **superior articular process of the sacrum**, one of which is found on either side of the superior opening of the sacral canal, articulates with the inferior articular processes from the L5 vertebra. The body of the sacrum articulates with the body of vertebra L5.

The **coccyx**, or tailbone, is derived from the fusion of four very small coccygeal vertebrae (see Figure 6.4.11). It articulates with the inferior tip of the sacrum. It is not weight bearing in the standing position, but may receive some body weight when sitting.

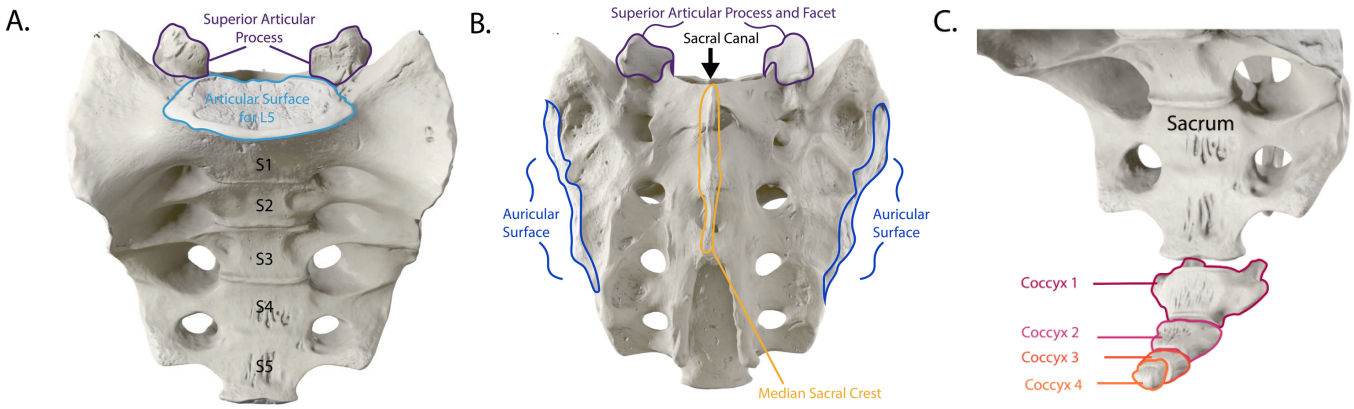

Figure 6.4.11: Sacrum and Coccyx. A) Anterior view: the sacrum is formed from the fusion of five sacral vertebrae. The superior aspect retains the articular surfaces for the lumbosacral joints. B) Posterior view: the fused spinous processes form the median sacral crest. Laterally, the auricular surface serves as the point of connection to the ileum. C) The coccyx is formed by the fusion of four small coccygeal vertebrae. *(Image credit: "Sacrum and Coccyx" by Gabrielle Spurlock is licensed under CC BY-NC-SA 4.0, modification of image from Anatomy Standard under CC BY-NC 4.0.)*

Intervertebral Discs and Ligaments of the Vertebral Column

The bodies of adjacent vertebrae are strongly anchored to each other by an intervertebral disc. This structure provides padding between the bones when they bear weight, and because it can change shape, also allows for movement between the vertebrae. Although the total amount of movement available between any two adjacent vertebrae is small, when these movements are summed together along the entire length of the vertebral column, large body movements can be produced. Ligaments that extend along the length of the vertebral column also contribute to its overall support and stability.

Intervertebral Disc

An **intervertebral disc** is a fibrocartilaginous pad that fills the gap between adjacent vertebral bodies (Figure 6.4.12). Each disc is anchored to the bodies of its adjacent vertebrae, thus strongly uniting the set. The discs also provide padding between vertebrae during weight bearing. Because of this, intervertebral discs are thin in the cervical region and thickest in the lumbar region, which carries the most body weight. In total, the intervertebral discs account for approximately 25 percent of your body height between the top of the pelvis and the base of the skull. Intervertebral discs are also flexible and can change shape to allow for movements of the vertebral column.

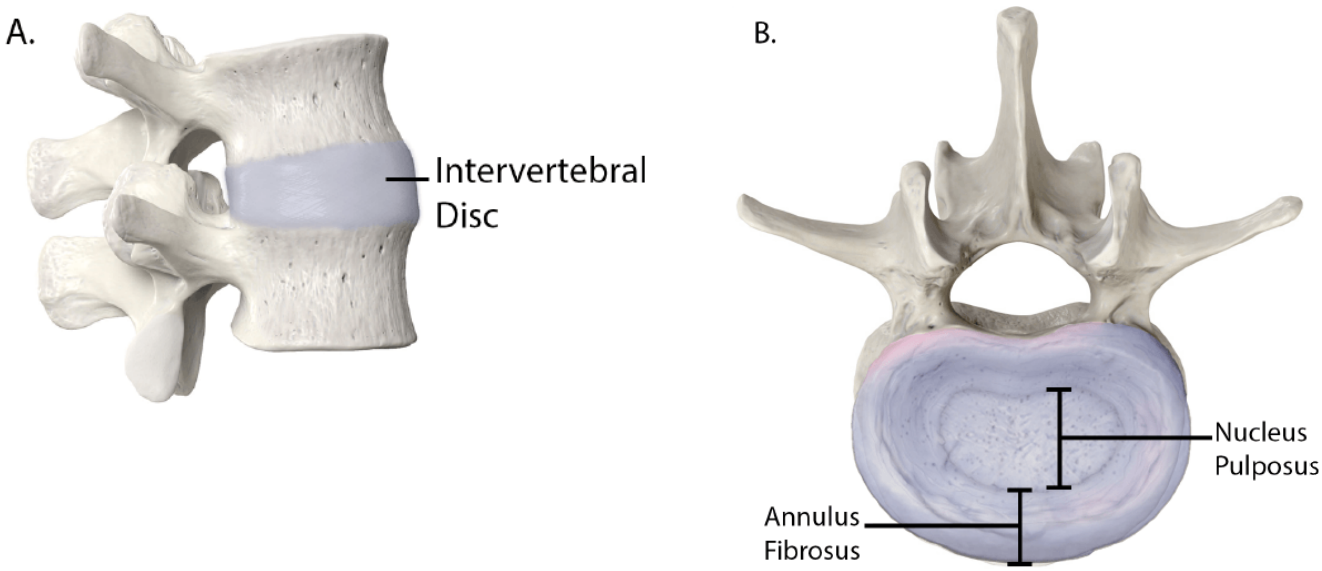

Figure 6.4.12: The bodies of adjacent vertebrae are separated and united by an intervertebral disc, which provides padding and allows for movements between adjacent vertebrae. The disc consists of a fibrous outer layer called the anulus fibrosus and a gel-like center called the nucleus pulposus. *(Image credit: "Intervertebral Discs" by Jennifer Lange is licensed under CC BY-NC-SA 4.0, modification of images from Anatomy Standard under CC BY-NC 4.0. and BruceBlaus, CC BY-SA 4.0, via Wikimedia Commons.)*

Each intervertebral disc consists of two parts. The **anulus fibrosus** is the tough, fibrous outer layer of the disc. It forms a circle (anulus = “ring” or “circle”) and is firmly anchored to the outer margins of the adjacent vertebral bodies. Inside is the **nucleus pulposus**, consisting of a softer, more gel-like material. It has a high water content that serves to resist compression and thus is important for weight bearing. With increasing age, the water content of the nucleus pulposus gradually declines. This causes the disc to become thinner, decreasing total body height somewhat, and reduces the flexibility and range of motion of the disc, making bending more difficult.The gel-like nature of the nucleus pulposus also allows the intervertebral disc to change shape as one vertebra rocks side to side or forward and back in relation to its neighbors during movements of the vertebral column. Thus, bending forward causes compression of the anterior portion of the disc but expansion of the posterior disc. If the posterior anulus fibrosus is weakened due to injury or increasing age, the pressure exerted on the disc when bending forward and lifting a heavy object can cause the nucleus pulposus to protrude posteriorly through the anulus fibrosus, resulting in a herniated disc (“ruptured” or “slipped” disc) (Figure 6.4.13). The posterior bulging of the nucleus pulposus can cause compression of a spinal nerve at the point where it exits through the intervertebral foramen, with resulting pain and/or muscle weakness in those body regions supplied by that nerve. The most common sites for disc herniation are the L4/L5 or L5/S1 intervertebral discs, which can cause sciatica, a widespread pain that radiates from the lower back down the thigh and into the leg. Similar injuries of the C5/C6 or C6/C7 intervertebral discs, following forcible hyperflexion of the neck from a collision accident or football injury, can produce pain in the neck, shoulder, and upper limb.

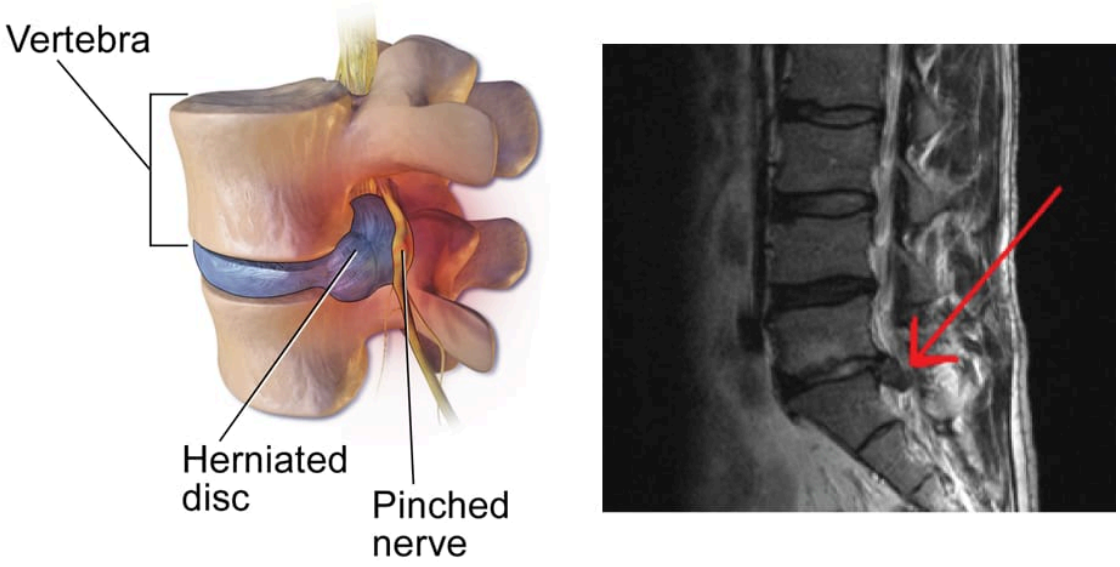

Figure 6.4.13: Herniated Intervertebral Disc. Weakening of the anulus fibrosus can result in herniation (protrusion) of the nucleus pulposus and compression of a spinal nerve, resulting in pain and/or muscle weakness in the body regions supplied by that nerve. *(Image credit: "Herniated Disc" by Jennifer Lange is licensed under CC BY-NC-SA 4.0, modification of images from BruceBlaus and from OpenStax via Wikimedia Commons.)*

Ligaments of the Vertebral Column

Adjacent vertebrae are united by ligaments that run the length of the vertebral column along both its posterior and anterior aspects (Figure 6.4.14). These serve to resist excess forward or backward bending movements of the vertebral column, respectively.

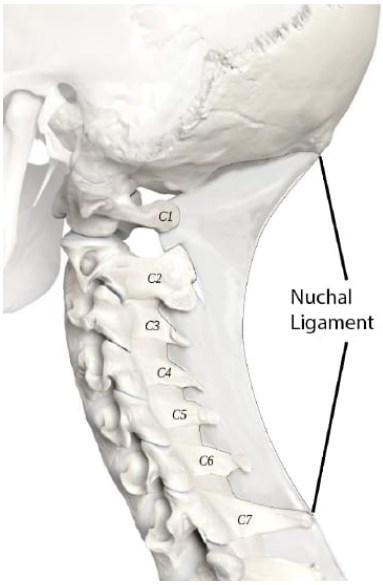

Figure 6.4.14: Nuchal Ligament. In the posterior neck, the nuchal ligament attaches to the cervical spinous processes and to the base of the skull. *(Image credit: "Nuchal Ligament" by Gabrielle Spurlock is licensed under CC BY-NC-SA 4.0, modification of image from Anatomy Standard under CC BY-NC 4.0.)*

The **anterior longitudinal ligament** runs down the anterior side of the entire vertebral column, uniting the vertebral bodies. It serves to resist excess backward bending of the vertebral column. Protection against this movement is particularly important in the neck, where extreme posterior bending of the head and neck can stretch or tear this ligament, resulting in a painful whiplash injury. Prior to the mandatory installation of seat headrests, whiplash injuries were common for passengers involved in a rear-end automobile collision.

The **supraspinous ligament** is located on the posterior side of the vertebral column, where it interconnects the spinous processes of the thoracic and lumbar vertebrae. This strong ligament supports the vertebral column during forward bending motions. In the posterior neck, where the cervical spinous processes are short, the supraspinous ligament expands to become the **nuchal ligament** (nuchae = “nape” or “back of the neck”). The nuchal ligament is attached to the cervical spinous processes and extends upward and posteriorly to attach to the midline base of the skull, out to the external occipital protuberance. It supports the skull and prevents it from falling forward. This ligament is much larger and stronger in four-legged animals such as cows, where the large skull hangs off the front end of the vertebral column. You can easily feel this ligament by first extending your head backward and pressing down on the posterior midline of your neck. Then tilt your head forward and you will fill the nuchal ligament popping out as it tightens to limit anterior bending of the head and neck.

Interactive Link

Use these 3D models to explore the structure of selected vertebrae:

This interactive element is not available in this format. Visit the link or scan the QR code to access it online.

View this Interactive Content online

Lumbar Vertebra 3 with Texture by **Wellesley College** on **Sketchfab**

This interactive element is not available in this format. Visit the link or scan the QR code to access it online.

View this Interactive Content online

Cervical Vertebra 2 with Texture by **Wellesley College** on **Sketchfab**

This interactive element is not available in this format. Visit the link or scan the QR code to access it online.

View this Interactive Content online

Sacrum with Texture by **Wellesley College** on **Sketchfab**

This interactive element is not available in this format. Visit the link or scan the QR code to access it online.

View this Interactive Content online

CAREER CONNECTIONS

Chiropractor

Chiropractors are health professionals who use nonsurgical techniques to help patients with musculoskeletal system problems that involve the bones, muscles, ligaments, tendons, or nervous system. They treat problems such as neck pain, back pain, joint pain, or headaches. Chiropractors focus on the patient's overall health and can also provide counseling related to lifestyle issues, such as diet, exercise, or sleep problems. If needed, they will refer the patient to other medical specialists.

Spring Aragon, a chiropractor at Branch Health Clinic Bangor, examines a patient's neck during a consultation. Chiropractic care emphasizes the recuperative power of the body to heal itself without the use of drugs or surgery. (U.S. Navy photo by Mass Communication Specialist 2nd Class Zulema Sotelo, public domain.)

Chiropractors use a drug-free, hands-on approach for patient diagnosis and treatment. They will perform a physical exam, assess the patient's posture and spine, and may perform additional diagnostic tests, including taking X-ray images. They primarily use manual techniques, such as spinal manipulation, to adjust the patient's spine or other joints. They can recommend therapeutic or rehabilitative exercises, and some also include acupuncture, massage therapy, or ultrasound as part of the treatment program. In addition to those in general practice, some chiropractors specialize in sport injuries, neurology, orthopaedics, pediatrics, nutrition, internal disorders, or diagnostic imaging.

Concept Review

The vertebral column forms the neck and back. The vertebral column originally develops as 33 vertebrae, but is eventually reduced to 24 vertebrae, plus the sacrum and coccyx. The vertebrae are divided into the cervical region (C1–C7 vertebrae), the thoracic region (T1–T12 vertebrae), and the lumbar region (L1–L5 vertebrae). The sacrum arises from the fusion of five sacral vertebrae and the coccyx from the fusion of four small coccygeal vertebrae. The vertebral column has four curvatures, the cervical, thoracic, lumbar, and sacrococcygeal curves. The thoracic and sacrococcygeal curves are primary curves retained from the original fetal curvature. The cervical and lumbar curves develop after birth and thus are secondary curves. The cervical curve develops as the infant begins to hold up the head, and the lumbar curve appears with standing and walking.

A typical vertebra consists of an enlarged anterior portion called the body, which provides weight-bearing support. Attached posteriorly to the body is a vertebral arch, which surrounds and defines the vertebral foramen for passage of the spinal cord. The vertebral arch consists of the pedicles, which attach to the vertebral body, and the laminae, which come together to form the roof of the arch. Arising from the vertebral arch are the laterally projecting transverse processes and the posteriorly oriented spinous process. The superior articular processes project upward, where they articulate with the downward projecting inferior articular processes of the next higher vertebrae.

A typical cervical vertebra has a small body, a bifid (Y-shaped) spinous process, and U-shaped transverse processes with a transverse foramen. In addition to these characteristics, the axis (C2 vertebra) also has the dens projecting upward from the vertebral body. The atlas (C1 vertebra) differs from the other cervical vertebrae in that it does not have a body, but instead consists of bony ring formed by the anterior and posterior arches. The atlas articulates with the dens from the axis. A typical thoracic vertebra is distinguished by its long, downward projecting spinous process. Thoracic vertebrae also have articulation facets on the body and transverse processes for attachment of the ribs. Lumbar vertebrae support the greatest amount of body weight and thus have a large, thick body. They also have a short, blunt spinous process. The sacrum is triangular in shape. The median sacral crest is formed by the fused vertebral spinous processes and the lateral sacral crest is derived from the fused transverse processes. Anterior (ventral) and posterior (dorsal) sacral foramina allow branches of the sacral spinal nerves to exit the sacrum. The auricular surfaces are articulation sites on the lateral sacrum that anchor the sacrum to the hipbones to form the pelvis. The coccyx is small and derived from the fusion of four small vertebrae.

The intervertebral discs fill in the gaps between the bodies of adjacent vertebrae. They provide strong attachments and padding between the vertebrae. The outer, fibrous layer of a disc is called the anulus fibrosus. The gel-like interior is called the nucleus pulposus. The disc can change shape to allow for movement between vertebrae. If the anulus fibrosus is weakened or damaged, the nucleus pulposus can protrude outward, resulting in a herniated disc.

The anterior longitudinal ligament runs along the full length of the anterior vertebral column, uniting the vertebral bodies. The supraspinous ligament is located posteriorly and interconnects the spinous processes of the thoracic and lumbar vertebrae. In the neck, this ligament expands to become the nuchal ligament. The nuchal ligament is attached to the cervical spinous processes and superiorly to the base of the skull, out to the external occipital protuberance. The posterior longitudinal ligament runs within the vertebral canal and unites the posterior sides of the vertebral bodies. The ligamentum flavum unites the lamina of adjacent vertebrae.

Review Questions

Query 6.4.1

This interactive element is not available in this format. Visit the link or scan the QR code to access it online.

View this Interactive Content online

Query 6.4.2

This interactive element is not available in this format. Visit the link or scan the QR code to access it online.

View this Interactive Content online

Query 6.4.3

This interactive element is not available in this format. Visit the link or scan the QR code to access it online.

View this Interactive Content online

Query 6.4.4

This interactive element is not available in this format. Visit the link or scan the QR code to access it online.

View this Interactive Content online

Critical Thinking Questions

Query 6.4.5

This interactive element is not available in this format. Visit the link or scan the QR code to access it online.

View this Interactive Content online

Query 6.4.6

This interactive element is not available in this format. Visit the link or scan the QR code to access it online.

View this Interactive Content online

Query 6.4.7

This interactive element is not available in this format. Visit the link or scan the QR code to access it online.

View this Interactive Content online

Query 6.4.8

This interactive element is not available in this format. Visit the link or scan the QR code to access it online.

View this Interactive Content online

Query 6.4.9

This interactive element is not available in this format. Visit the link or scan the QR code to access it online.

View this Interactive Content online

References

Schwartz, John. Spines, Made Extra Curvy for Women. New York Times [Internet]. 2013 Dec. 07 [cited 2021 Apr 5]; Available from: https://www.nytimes.com/2007/12/13/s...3pregnant.html

Glossary

Query 6.4.10

This interactive element is not available in this format. Visit the link or scan the QR code to access it online.

View this Interactive Content online

Contributors and Attributions

- OpenStax Anatomy & Physiology (CC BY 4.0). Access for free at https://openstax.org/books/anatomy-and-physiology

This page titled 6.4: The Vertebral Column is shared under a CC BY-NC-SA 4.0 license and was authored, remixed, and/or curated by Jennifer Lange et al..

- 6.4: The Vertebral Column by Whitney Menefee, Julie Jenks, Chiara Mazzasette, and Kim-Leiloni Nguyen is licensed CC BY 4.0.

6.5: The Thoracic Cage

By the end of this section, you will be able to:

- Discuss the components that make up the thoracic cage
- Identify the parts of the sternum and define the sternal angle
- Discuss the parts of a rib and rib classifications

The thoracic cage (rib cage) forms the thorax (chest) portion of the body. It consists of the 12 pairs of ribs with their costal cartilages and the sternum (Figure 6.5.1). The ribs are anchored posteriorly to the 12 thoracic vertebrae (T1–T12). The thoracic cage protects the heart and lungs.

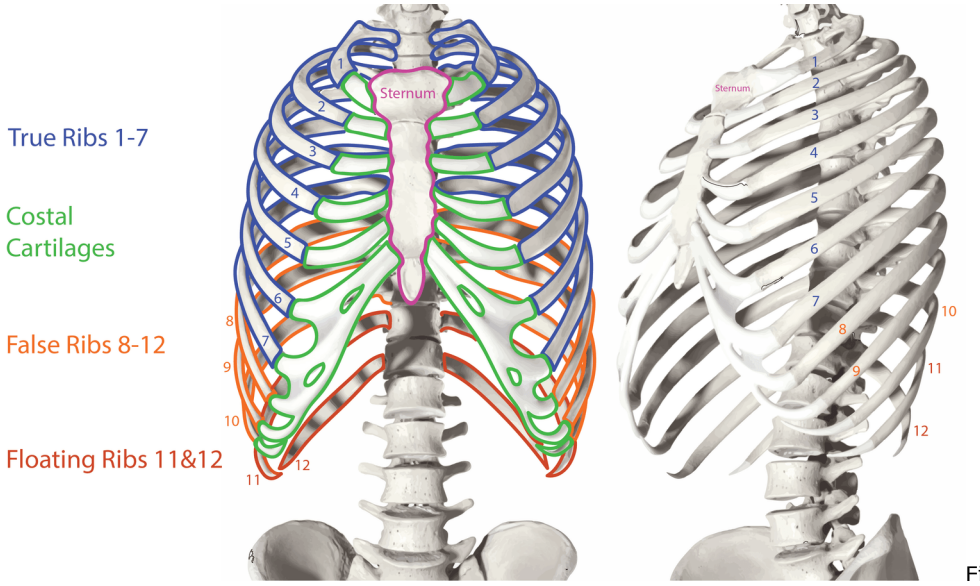

Figure 6.5.1: Thoracic Cage. The thoracic cage is formed by the sternum and 12 pairs of ribs with their costal cartilages. The ribs are anchored posteriorly to the 12 thoracic vertebrae. The ribs are classified as true ribs (1–7) and false ribs (8–12). The last two pairs of false ribs are also known as floating ribs (11–12). *(Image credit: "Thoracic Cage" by Gabrielle Spurlock is licensed under CC BY-NC-SA 4.0, modification of image from Anatomy Standard under CC BY-NC 4.0.)*

Sternum

The **sternum** is the elongated bony structure that anchors the anterior thoracic cage. It consists of three parts: the manubrium, body, and xiphoid process. The **manubrium** is the wider, superior portion of the sternum. The top of the manubrium has a shallow, U-shaped border called the **jugular (suprasternal) notch**. This can be easily felt at the anterior base of the neck, between the medial ends of the clavicles. The **clavicular notch** is the shallow depression located on either side at the superior-lateral margins of the manubrium. This is the site of the sternoclavicular joint, between the sternum and clavicle. The first ribs also attach to the manubrium.

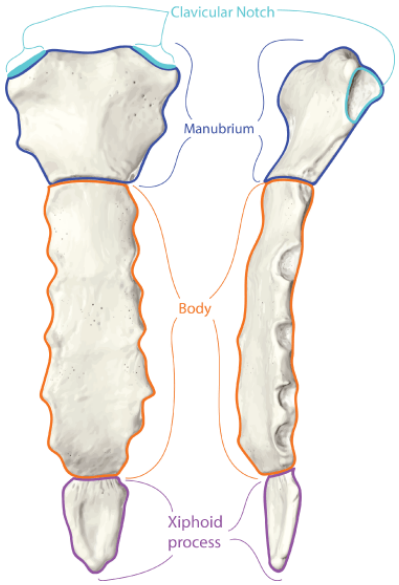

Figure 6.5.2: The sternum is located on the anterior midline of the thoracic cage. It is composed of three major regions: the manubrium, the body, and the xiphoid process. While the manubrium and the body begin fusing around age seven, the xiphoid process does not fuse with the body until later in life and may remain an independent bone. *(Image credit: "Sternum" by Gabrielle Spurlock is licensed under CC BY-NC-SA 4.0, modification of image from Anatomy Standard under CC BY-NC 4.0.)*

The elongated, central portion of the sternum is the body. The manubrium and body join together at the **sternal angle**, so called because the junction between these two components is not flat, but forms a slight bend. The second rib attaches to the sternum at the sternal angle. Since the first rib is hidden behind the clavicle, the second rib is the highest rib that can be identified by palpation, or felt with the fingers through the skin. Thus, the sternal angle and second rib are important landmarks for the identification and counting of the lower ribs. Ribs 3–7 attach to the sternal body.

The inferior tip of the sternum is the **xiphoid process**. This small structure is cartilaginous early in life, but gradually becomes ossified starting during middle age.

DISORDERS OF THE...

Thoracic Cage: Honeycomb sternum

The sternum develops from multiple ossification centers, typically one in the manubrium, four in the body, and one in the xiphoid process. The osteoid laid down starting at each center normally fuse together to form the singular bone region in childhood or early adulthood. A rare developmental variant of the sternum, resulting from unfused ossification centers gives a honeycomb configuration of the sternal body. This condition is usually asymptomatic and discovered incidentally during a routine exam of the chest.

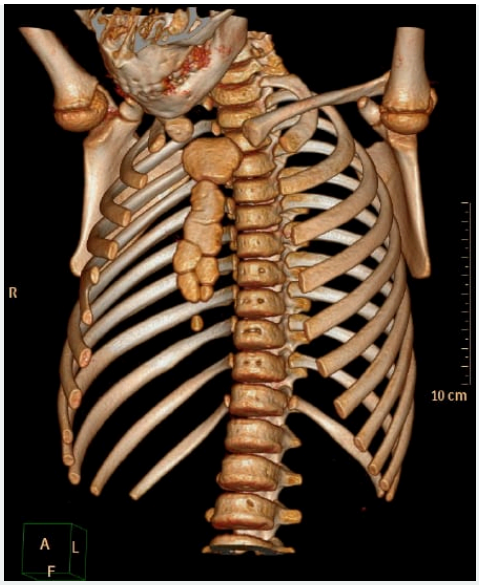

Figure 6.5.3: Honeycomb sternum. Case courtesy of Wesam Shamma, Radiopaedia.org. From the case rID: 174406.

Ribs

Each **rib** is a curved, flattened bone that contributes to the wall of the thorax. The ribs articulate posteriorly with the T1–T12 thoracic vertebrae, and most attach anteriorly via their costal cartilages to the sternum. There are 12 pairs of ribs. The ribs are numbered 1–12 in accordance with the thoracic vertebrae.

Parts of a Typical Rib

Figure 6.5.4 diagrams the bone markings of a typical rib. The posterior end of a typical rib is called the **head of the rib**. This region articulates primarily with the costal demifacet located on the body of the same numbered thoracic vertebra and to a lesser degree, with the costal demifacet located on the body of the next higher vertebra (Figure 6.5.5). A small bump on the posterior rib surface is the **tubercle of the rib**, which articulates with the facet located on the transverse process of the same numbered vertebra. The remainder of the rib is the **body of the rib** (shaft). The angles of the ribs form the most posterior extent of the thoracic cage. In the anatomical position, the angles align with the medial border of the scapula. A shallow **costal groove** for the passage of blood vessels and a nerve is found along the inferior margin of each rib. The anterior end of each rib articulates with the the costal cartilage for ribs 1-10, while the anterior end of ribs 11 and 12 are typically pointed.

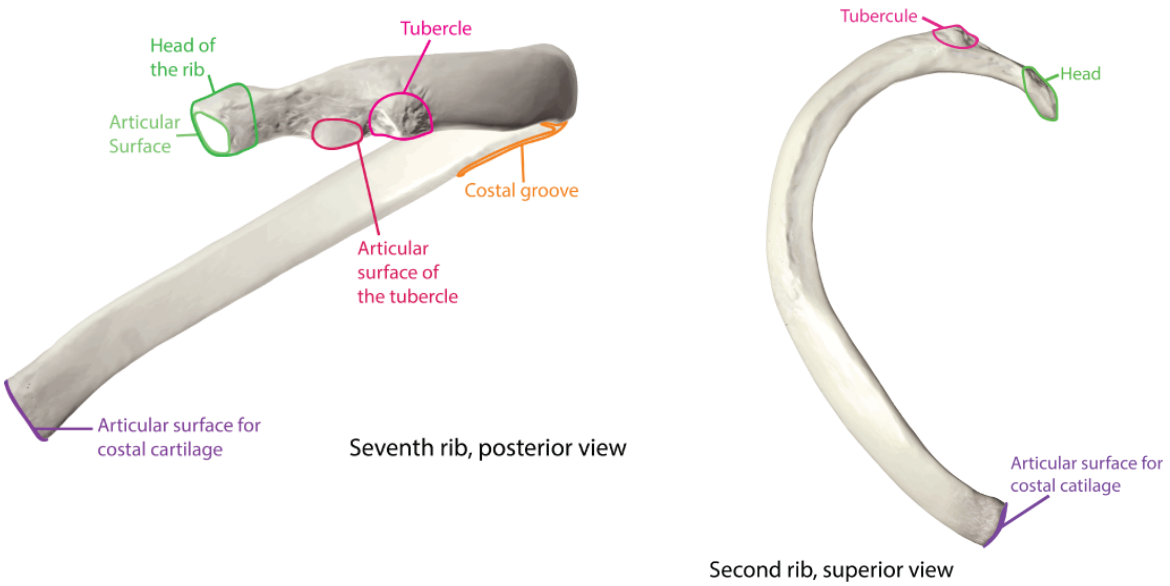

Figure 6.5.4: Typical ribs. Features of ribs 2-10. *(Image credit: "Typical Ribs" by Gabrielle Spurlock is licensed under CC BY-NC-SA 4.0, modification of image from Anatomy Standard under CC BY-NC 4.0.)*

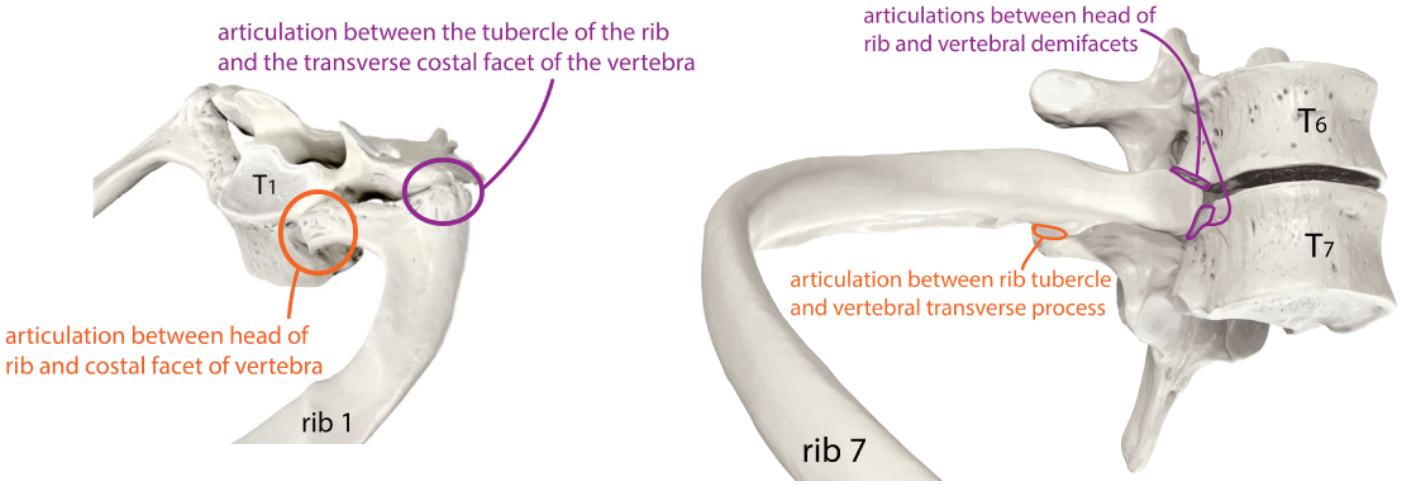

Figure 6.5.5: Vertebrocostal joints. The tubercle and head of the rib articulate posteriorly with the thoracic vertebrae while the anterior end articulates with the costal cartilages. *(Image credit: "Vertebrocostal Joints" by Gabrielle Spurlock is licensed under CC BY-NC-SA 4.0, modification of image from Anatomy Standard under CC BY-NC 4.0.)*

Rib Classifications

The bony ribs do not extend anteriorly completely around to the sternum. Instead, each rib ends in a **costal cartilage**. These cartilages are made of hyaline cartilage and can extend for several inches. Most ribs are then attached, either directly or indirectly, to the sternum via their costal cartilage (see Figure 6.5.1). The ribs are classified into three groups based on their relationship to the sternum.

Ribs 1–7 are classified as **true ribs** (vertebrosternal ribs). The costal cartilage from each of these ribs attaches directly to the sternum. Ribs 8–12 are called **false ribs** (vertebrochondral ribs). The costal cartilages from these ribs do not attach directly to the sternum. For ribs 8–10, the costal cartilages are attached to the cartilage of the next higher rib. Thus, the cartilage of rib 10 attaches to the cartilage of rib 9, rib 9 then attaches to rib 8, and rib 8 is attached to rib 7. The last two false ribs (11–12) are also called **floating ribs** (vertebral ribs). These are short ribs that do not attach to the sternum at all. Instead, their small costal cartilages terminate within the musculature of the lateral abdominal wall.

Concept Review

The thoracic cage protects the heart and lungs. It is composed of 12 pairs of ribs with their costal cartilages and the sternum. The ribs are anchored posteriorly to the 12 thoracic vertebrae. The sternum consists of the manubrium, body, and xiphoid process. The manubrium and body are joined at the sternal angle, which is also the site for attachment of the second ribs.

Ribs are flattened, curved bones and are numbered 1–12. Posteriorly, the head of the rib articulates with the costal facets located on the bodies of thoracic vertebrae and the rib tubercle articulates with the facet located on the vertebral transverse process. The angle of the ribs forms the most posterior portion of the thoracic cage. The costal groove in the inferior margin of each rib carries blood vessels and a nerve. Anteriorly, each rib ends in a costal cartilage. True ribs (1–7) attach directly to the sternum via their costal cartilage. The false ribs (8–12) either attach to the sternum indirectly or not at all. Ribs 8–10 have their costal cartilages attached to the cartilage of the next higher rib. The floating ribs (11–12) are short and do not attach to the sternum or to another rib.

Review Questions

Query 6.5.1

This interactive element is not available in this format. Visit the link or scan the QR code to access it online.

View this Interactive Content online

Critical Thinking Questions

Query 6.5.2

This interactive element is not available in this format. Visit the link or scan the QR code to access it online.

View this Interactive Content online

Query 6.5.3

This interactive element is not available in this format. Visit the link or scan the QR code to access it online.

View this Interactive Content online

Query 6.5.4

This interactive element is not available in this format. Visit the link or scan the QR code to access it online.

View this Interactive Content online

Query 6.5.5

This interactive element is not available in this format. Visit the link or scan the QR code to access it online.

View this Interactive Content online

Glossary

Query 6.5.6

This interactive element is not available in this format. Visit the link or scan the QR code to access it online.

View this Interactive Content online

Contributors and Attributions

OpenStax Anatomy & Physiology (CC BY 4.0). Access for free at https://openstax.org/books/anatomy-and-physiology

This page titled 6.5: The Thoracic Cage is shared under a CC BY-NC-SA 4.0 license and was authored, remixed, and/or curated by Jennifer Lange et al..

- 6.5: The Thoracic Cage by Whitney Menefee, Julie Jenks, Chiara Mazzasette, and Kim-Leiloni Nguyen is licensed CC BY 4.0.
- 17.2: Heart Anatomy by Whitney Menefee, Julie Jenks, Chiara Mazzasette, and Kim-Leiloni Nguyen is licensed CC BY 4.0.

6.6: The Pectoral Girdle

By the end of this section, you will be able to:

- Describe the bones that form the pectoral girdle
- List the functions of the pectoral girdle

The appendicular skeleton includes all of the limb bones, plus the bones that unite each limb with the axial skeleton. The bones that attach each upper limb to the axial skeleton form the pectoral girdle (shoulder girdle) that consists of two bones, the scapula and clavicle (Figure 6.6.1). The clavicle (collarbone) is an S-shaped bone located on the anterior side of the shoulder. It is attached on its medial end to the sternum of the thoracic cage, which is part of the axial skeleton. The lateral end of the clavicle articulates (joins) with the scapula just above the shoulder joint. You can easily palpate, or feel with your fingers, the entire length of your clavicle.

The **scapula** (shoulder blade) lies on the posterior aspect of the shoulder. It is supported by the **clavicle**, which also articulates with the humerus (arm bone) to form the shoulder joint. The scapula is a flat, triangular-shaped bone with a prominent ridge running across its posterior surface. This ridge extends out laterally, where it forms the bony tip of the shoulder and joins with the lateral end of the clavicle. By following along the clavicle, you can palpate out to the bony tip of the shoulder, and from there, you can move back across your posterior shoulder to follow the ridge of the scapula. Move your shoulder around and feel how the clavicle and scapula move together as a unit. Both of these bones serve as important attachment sites for muscles that aid with movements of the shoulder and arm.

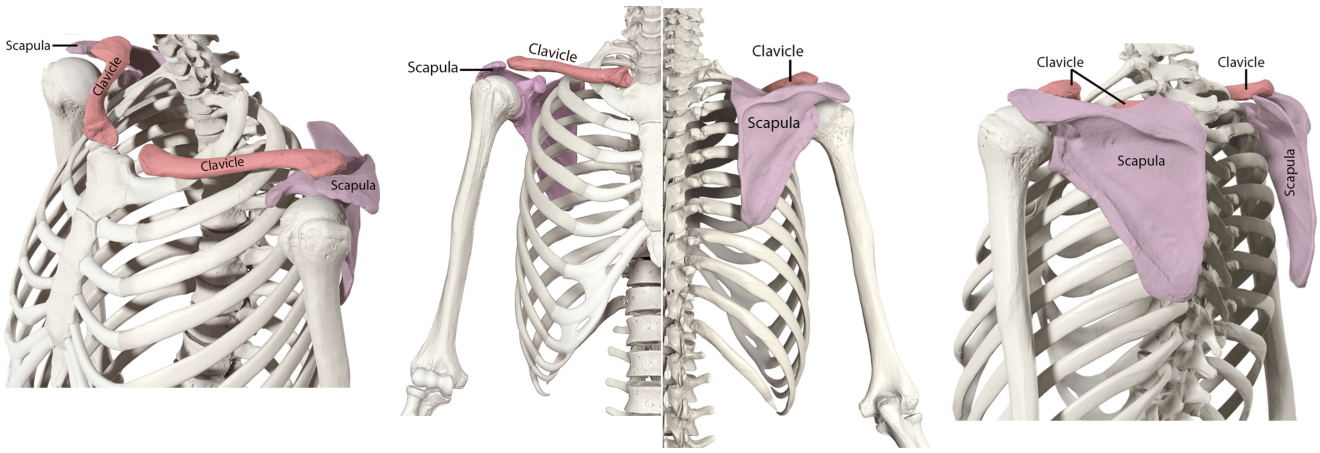

Figure 6.6.1: Pectoral Girdle. The pectoral girdle consists of the clavicle and the scapula, which serve to attach the upper limb to the sternum of the axial skeleton. *(Image credit: "Pectoral Girdle Bones Anterior and Posterior Views" by Jennifer Lange are licensed under CC BY-NC-SA 4.0, modification of image from Anatomy Standard under CC BY-NC 4.0.)*

The right and left pectoral girdles are not joined to each other, allowing each to operate independently. In addition, the clavicle of each **pectoral girdle** is anchored to the axial skeleton by a single, highly mobile joint. This allows for the extensive mobility of the entire pectoral girdle, which in turn enhances movements of the shoulder and upper limb.

Clavicle

The **clavicle** is the only long bone that lies in a horizontal position in the body (Figure 6.6.2). The clavicle has several important functions. First, anchored by muscles from above, it serves as a strut that extends laterally to support the scapula. This in turn holds the shoulder joint superiorly and laterally from the body trunk, allowing for maximal freedom of motion for the upper limb. The clavicle also transmits forces acting on the upper limb to the sternum and axial skeleton. Finally, it serves to protect the underlying nerves and blood vessels as they pass between the trunk of the body and the upper limb.

The clavicle has three regions: the medial end, the lateral end, and the shaft. The medial end, known as the **sternal end of the**

clavicle, has a triangular shape and articulates with the manubrium portion of the sternum. This forms the **sternoclavicular joint**, which is the only bony articulation between the pectoral girdle of the upper limb and the axial skeleton. This joint allows considerable mobility, enabling the clavicle and scapula to move in upward/downward and anterior/posterior directions during shoulder movements. The sternoclavicular joint is indirectly supported by the **costoclavicular ligament** (costo- = "rib"), which spans the sternal end of the clavicle and the underlying first rib. The lateral or **acromial end of the clavicle** articulates with the acromion of the scapula, the portion of the scapula that forms the bony tip of the shoulder. There are some sex differences in the morphology of the clavicle. In women, the clavicle tends to be shorter, thinner, and less curved. In men, the clavicle is heavier and longer, and has a greater curvature and rougher surfaces where muscles attach, features that are more pronounced in manual workers.

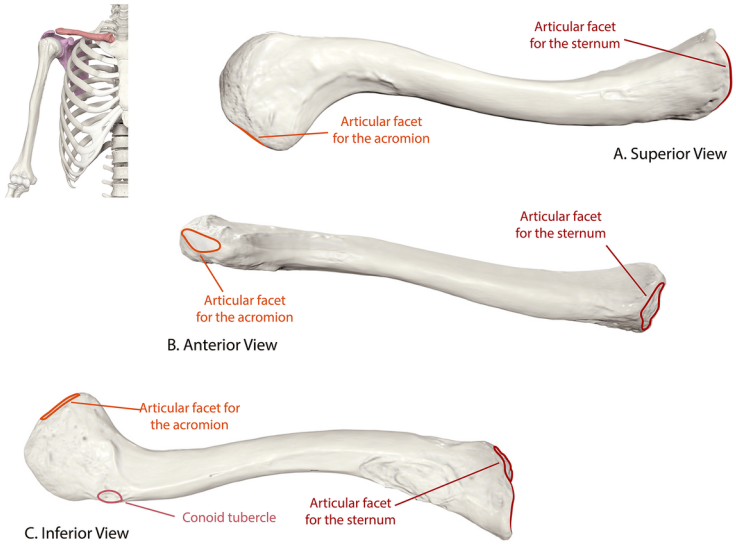

Figure 6.6.2: Clavicle. Each view of the clavicle shows the articular surfaces on the medial (sternal) and lateral (acromial) ends of the bone. On the inferior aspect is the conoid tubercle, which is an attachment site for the coracoclavicular ligaments of the shoulder joint. *(Image credit: "Clavicle - Superior, Anterior, Inferior" by Mark Schaeffer and Jennifer Lange is licensed under CC BY-NC-SA 4.0, modification of image from Anatomy Standard under CC BY-NC 4.0.)*

The clavicle is the most commonly fractured bone in the body. Such breaks often occur because of the force exerted on the clavicle when a person falls onto his or her outstretched arms, or when the lateral shoulder receives a strong blow. Because the sternoclavicular joint is strong and rarely dislocated, excessive force results in the breaking of the clavicle, usually between the middle and lateral portions of the bone. If the fracture is complete, the shoulder and lateral clavicle fragment will drop due to the weight of the upper limb, causing the person to support the sagging limb with their other hand. Muscles acting across the shoulder will also pull the shoulder and lateral clavicle anteriorly and medially, causing the clavicle fragments to override. The clavicle overlies many important blood vessels and nerves for the upper limb, but fortunately, due to the anterior displacement of a broken clavicle, these structures are rarely affected when the clavicle is fractured.

Scapula

The **scapula** is also part of the pectoral girdle and thus plays an important role in anchoring the upper limb to the body. The scapula is located on the posterior side of the shoulder. It is surrounded by muscles on both its anterior (deep) and posterior (superficial) sides, and thus does not articulate with the ribs of the thoracic cage.

The scapula has several important landmarks (Figure 6.6.3). The three margins or borders of the scapula, named for their positions within the body, are the **superior border of the scapula**, the **medial border of the scapula**, and the **lateral border of the scapula**. The **suprascapular notch** is located lateral to the midpoint of the superior border. The corners of the triangular scapula, at either end of the medial border, are the **superior angle of the scapula**, located between the medial and superior borders, and the **inferior angle of the scapula**, located between the medial and lateral borders. The inferior angle is the most inferior portion of the scapula, and is particularly important because it serves as the attachment point for several powerful muscles involved in shoulder and upper limb movements. The remaining corner of the scapula, between the superior and lateral borders, is the location of the **glenoid cavity** (glenoid fossa). This shallow depression articulates with the humerus bone of the arm to form the **glenohumeral joint** (shoulder joint). The small bony bumps located immediately above and below the glenoid cavity are the

supraglenoid tubercle and the **infraglenoid tubercle**, respectively. These provide attachments for muscles of the arm.

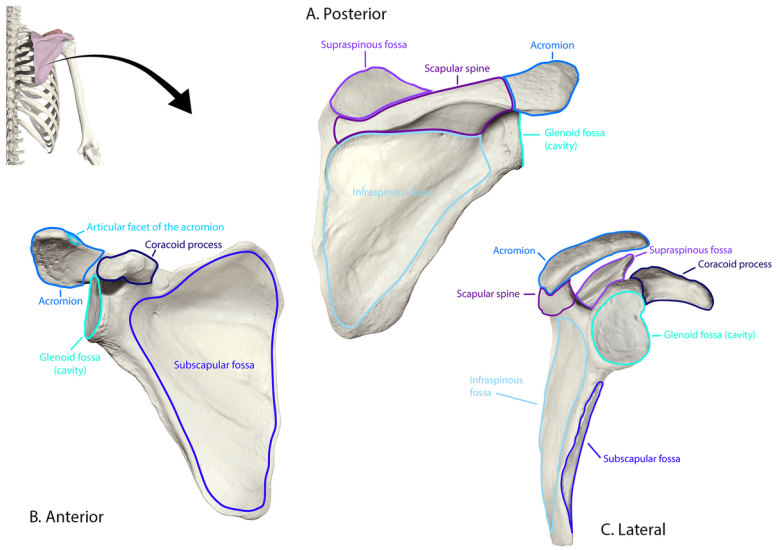

Figure 6.6.3: Scapula. The isolated scapula is shown here from anterior, posterior, and lateral views. *(Image credit: "Scapular Landmarks Multiple Views" by Claire McGuire and Jennifer Lange is licensed under CC BY-NC-SA 4.0, modification of images from Anatomy Standard under CC BY-NC 4.0.)*

The scapula also has two prominent projections. Toward the lateral end of the superior border, between the suprascapular notch and glenoid cavity, is the hook-like **coracoid process** (coracoid = "shaped like a crow's beak"). This process projects anteriorly and curves laterally. At the shoulder, the coracoid process is located inferior to the lateral end of the clavicle. It is anchored to the clavicle by a strong ligament, and serves as the attachment site for muscles of the anterior chest and arm. On the posterior aspect, the **spine of the scapula** is a long and prominent ridge that runs across its upper portion. Extending laterally from the spine is a flattened and expanded region called the **acromion**, or acromial process. The acromion forms the bony tip of the superior shoulder region and articulates with the lateral end of the clavicle, forming the **acromioclavicular joint** (see Figure 6.6.2). Together, the clavicle, acromion, and spine of the scapula form a V-shaped bony line that provides for the attachment of neck and back muscles that act on the shoulder, as well as muscles that pass across the shoulder joint to act on the arm.

The scapula has three depressions, each of which is called a **fossa** (plural = fossae). Two of these are found on the posterior scapula, above and below the scapular spine. Superior to the spine is the narrow **supraspinous fossa**, and inferior to the spine is the broad **infraspinous fossa**. The anterior (deep) surface of the scapula forms the broad **subscapular fossa**. All of these fossae provide large surface areas for the attachment of muscles that cross the shoulder joint to act on the humerus.

The acromioclavicular joint transmits forces from the upper limb to the clavicle. The ligaments around this joint are relatively weak. A hard fall onto the elbow or outstretched hand can stretch or tear the acromioclavicular ligaments, resulting in a moderate injury to the joint. However, the primary support for the acromioclavicular joint comes from a very strong ligament called the **coracoclavicular ligament** (see Figure 6.6.2). This connective tissue band anchors the coracoid process of the scapula to the inferior surface of the acromial end of the clavicle and thus provides important indirect support for the acromioclavicular joint. Following a strong blow to the lateral shoulder, such as when a hockey player is driven into the boards, a complete dislocation of the acromioclavicular joint can result. In this case, the acromion is thrust under the acromial end of the clavicle, resulting in ruptures of both the acromioclavicular and coracoclavicular ligaments. The scapula then separates from the clavicle, with the weight of the upper limb pulling the shoulder downward. This dislocation injury of the acromioclavicular joint is known as a "shoulder separation" and is common in contact sports such as hockey, football, or martial arts.

Interactive Element

Explore the structure of the scapula in these 3D models:

This interactive element is not available in this format. Visit the link or scan the QR code to access it online.

View this Interactive Content online

This interactive element is not available in this format. Visit the link or scan the QR code to access it online.

View this Interactive Content online

Concept Review

The pectoral girdle, consisting of the clavicle and the scapula, attaches each upper limb to the axial skeleton. The clavicle is an anterior bone whose sternal end articulates with the manubrium of the sternum at the sternoclavicular joint. The sternal end is also anchored to the first rib by the costoclavicular ligament. The acromial end of the clavicle articulates with the acromion of the scapula at the acromioclavicular joint. This end is also anchored to the coracoid process of the scapula by the coracoclavicular ligament, which provides indirect support for the acromioclavicular joint. The clavicle supports the scapula, transmits the weight and forces from the upper limb to the body trunk, and protects the underlying nerves and blood vessels.

The scapula lies on the posterior aspect of the pectoral girdle. It mediates the attachment of the upper limb to the clavicle, and contributes to the formation of the glenohumeral (shoulder) joint. This triangular bone has three sides called the medial, lateral, and superior borders. The suprascapular notch is located on the superior border. The scapula also has three corners, two of which are the superior and inferior angles. The third corner is occupied by the glenoid cavity. Posteriorly, the spine separates the supraspinous and infraspinous fossae, and then extends laterally as the acromion. The subscapular fossa is located on the anterior surface of the scapula. The coracoid process projects anteriorly, passing inferior to the lateral end of the clavicle.

Review Questions

Query 6.6.1

This interactive element is not available in this format. Visit the link or scan the QR code to access it online.

View this Interactive Content online

Critical Thinking Questions

Query 6.6.2

This interactive element is not available in this format. Visit the link or scan the QR code to access it online.

View this Interactive Content online

Query 6.6.3

This interactive element is not available in this format. Visit the link or scan the QR code to access it online.

View this Interactive Content online

Glossary

Query 6.6.4

This interactive element is not available in this format. Visit the link or scan the QR code to access it online.

View this Interactive Content online

Contributors and Attributions

- OpenStax Anatomy & Physiology (CC BY 4.0). Access for free at https://openstax.org/books/anatomy-and-physiology

This page titled 6.6: The Pectoral Girdle is shared under a CC BY-NC-SA 4.0 license and was authored, remixed, and/or curated by Jennifer Lange et al..

- 7.2: The Pectoral Girdle by Whitney Menefee, Julie Jenks, Chiara Mazzasette, and Kim-Leiloni Nguyen is licensed CC BY 4.0.

6.7: Bones of the Upper Limb

By the end of this section, you will be able to:

- Identify the divisions of the upper limb and describe the bones in each region
- List the bones and bony landmarks that articulate at each joint of the upper limb

The upper limb is divided into three regions. These consist of the upper **arm**, located between the shoulder and elbow joints; the **forearm**, which is between the elbow and wrist joints; and the **hand**, which is located distal to the wrist. There are 30 bones in each upper limb (Figure 6.7.1). The humerus is the single bone of the upper arm, and the **ulna** (medially) and the **radius** (laterally) are the paired bones of the forearm. The base of the hand contains eight bones, each called a **carpal bone**, and the palm of the hand is formed by five bones, each called a **metacarpal bone**. The fingers and thumb contain a total of 14 bones, each of which is a **phalanx** (plural = phalanges) bone of the hand.

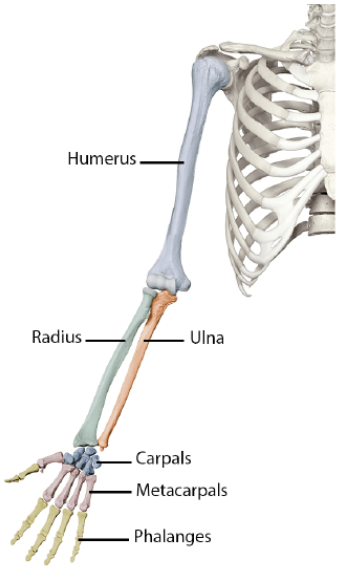

Figure 6.7.1: Bones of the Upper Limb. Bones of the brachial, antebrachial, and manual regions. *(Image credit: "Bones of the Upper Limb" by Jennifer Lange is licensed under CC BY-NC-SA 4.0, modification of image from Anatomy Standard.)*

Humerus

The **humerus** is the single bone of the upper arm region (Figure 6.7.2). At its proximal end is the **head of the humerus**. This is the large, round, smooth region that faces medially. The head articulates with the glenoid cavity of the scapula to form the glenohumeral (shoulder) joint. Located on the lateral side of the proximal humerus is an expanded bony area called the **greater tubercle**. The smaller **lesser tubercle** of the humerus is found on the anterior aspect of the humerus. Both the greater and lesser tubercles serve as attachment sites for muscles that act across the shoulder joint. The **deltoid tuberosity** is a roughened, V-shaped region located on the lateral side in the middle of the humerus shaft. As its name indicates, it is the site of attachment for the deltoid muscle.

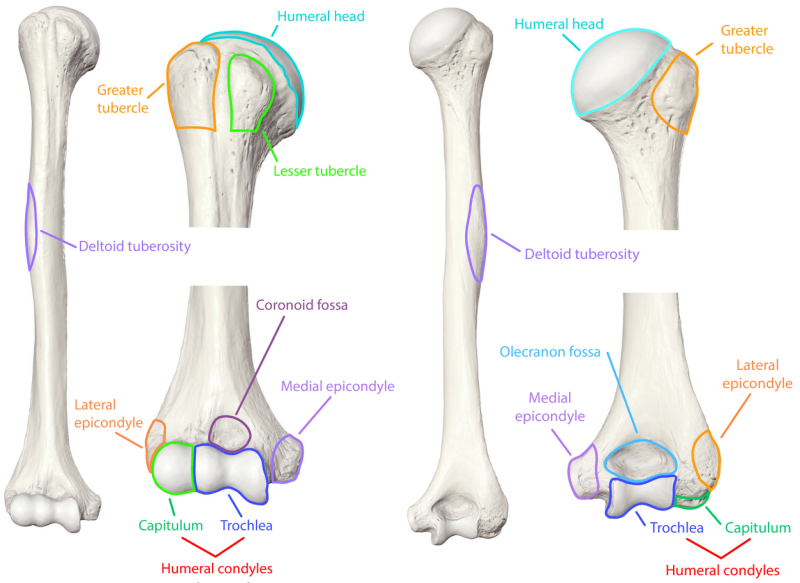

Figure 6.7.2: Humerus. The humerus is the single bone of the upper arm region. It articulates with the radius and ulna bones of the forearm to form the elbow joint and with the scapula to form the shoulder joint. *(Image credit: "Humerus - Anterior and Posterior" by Claire McGuire are licensed under CC BY-NC-SA 4.0, modification of image from Anatomy Standard.)*

Distally, the humerus becomes flattened. The prominent bony projection on the medial side is the **medial epicondyle of the humerus**. The much smaller **lateral epicondyle of the humerus** is found on the lateral side of the distal humerus. All of these areas are attachment points for muscles that act on the forearm, wrist, and hand. The powerful grasping muscles of the anterior forearm arise from the medial epicondyle, which is thus larger and more robust than the lateral epicondyle that gives rise to the weaker posterior forearm muscles.

The distal end of the humerus has two articulation areas, which join the ulna and radius bones of the forearm to form the **elbow joint**. The more medial of these areas is the **trochlea**, a hour glass- or pulley-shaped region (trochlea = “pulley”), which articulates with the ulna bone. Immediately lateral to the trochlea is the **capitulum** (“small head”), a knob-like structure located on the anterior surface of the distal humerus. The capitulum articulates with the radius bone of the forearm. Just proximal to these bony areas are spaces that accommodate the forearm bones when the elbow is fully bent (flexed) and fully straightened (extended). Superior to the trochlea on the anterior surface is the **coronoid fossa**, which receives the coronoid process of the ulna when the elbow is flexed. Similarly, the posterior humerus has the **olecranon fossa**, a larger depression that receives the olecranon process of the ulna when the forearm is fully extended.

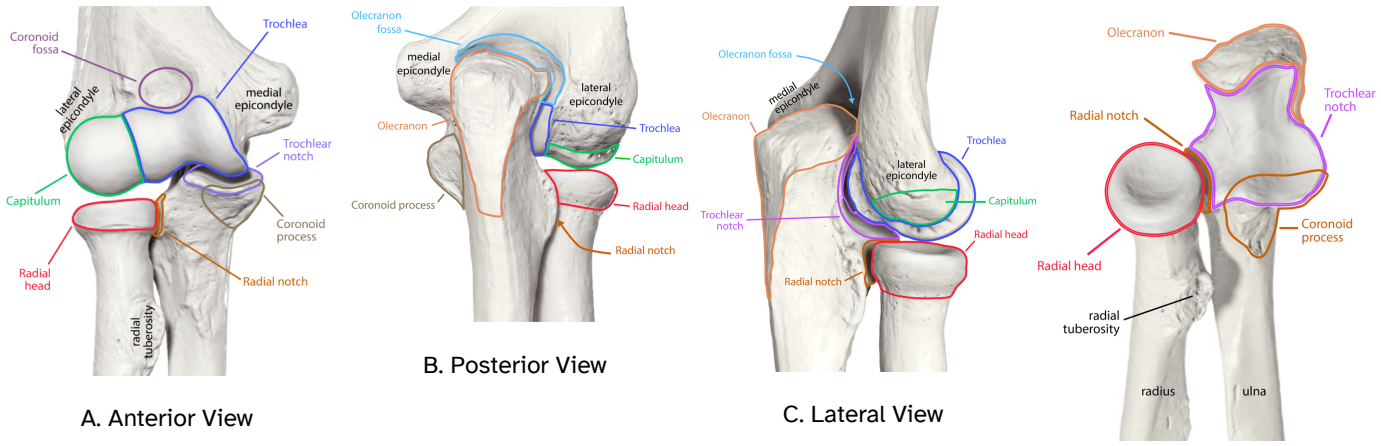

Figure 6.7.3: Bones of the Elbow Joint. At the elbow joint the "C" shaped trochlear notch pivots around the hourglass shaped trochlea. *(Image credits: "Elbow- Anterior, Posterior, and Lateral" and "Proximal Radius and Ulna" by Claire McGuire are licensed under CC BY-NC-SA 4.0, modification of image from Anatomy Standard.)*

Ulna

The **ulna** is the medial bone of the forearm. It runs parallel to the **radius**, which is the lateral bone of the forearm (Figure 6.7.4 and Figure 6.7.5). The proximal end of the ulna resembles a crescent wrench with its large, C-shaped indentation called the **trochlear notch**. This smooth region articulates with the trochlea of the humerus at the elbow joint. The posterior and proximal portion of the ulna, containing the proximal part of the trochlear notch, is the **olecranon process.** The olecranon process forms the bony tip of the elbow that contact the table. The inferior portion of the trochlear notch is on a prominent lip of bone called the **coronoid process of the ulna**. To the lateral side and slightly inferior to the trochlear notch is a small, smooth area called the **radial notch** (this looks like a bite mark in the coronoid process). This indented area is the site of articulation between the proximal radius and ulna, forming the **proximal radioulnar joint**.

More distal is the **shaft of the ulna**. The lateral side of the shaft forms a ridge called the **interosseous border of the ulna**. This is the line of attachment for the **interosseous membrane of the forearm**, also known as the antebrachial interosseous membrane, a sheet of dense connective tissue that unites the ulna and radius bones (Figure 6.7.6). The small, rounded area that forms the distal end is the **head of the ulna**. Projecting from the posterior side of the ulnar head is the **styloid process of the ulna**, a short bony projection. This serves as an attachment point for a connective tissue structure that unites the distal ends of the ulna and radius.

In the anatomical position, with the elbow fully extended and the palms facing forward, the arm and forearm do not form a straight line. Instead, the forearm deviates laterally by 5–15 degrees from the line of the arm. This deviation is called the carrying angle. It allows the forearm and hand to swing freely or to carry an object without hitting the hip. The carrying angle is larger in females to accommodate their wider pelvis.

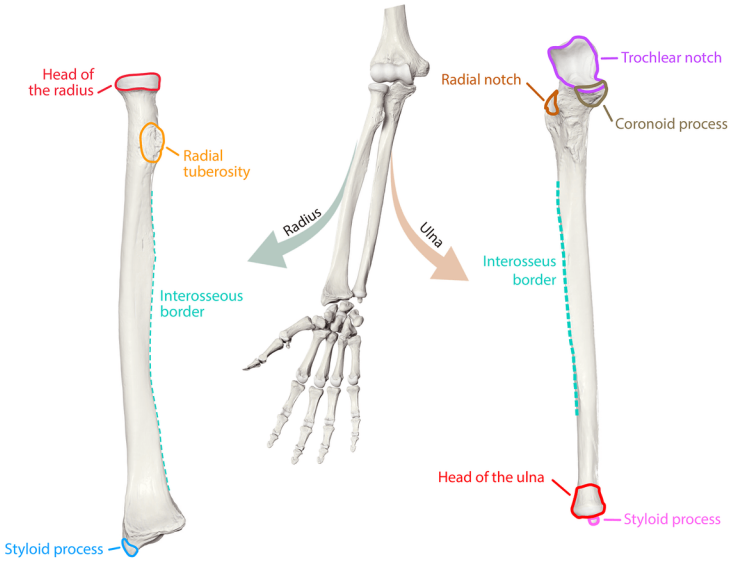

Figure 6.7.4: Bones of the Forearm - Anterior View. The radius and the ulna run parallel when in anatomical position. The radius is lateral (thumb side) and the ulna is medial (pinky side). *(Image credit: "Bones of the Forearm - Anterior View" by Jennifer Lange and Claire McGuire is licensed under CC BY-NC-SA 4.0, modification of image from Anatomy Standard.)*

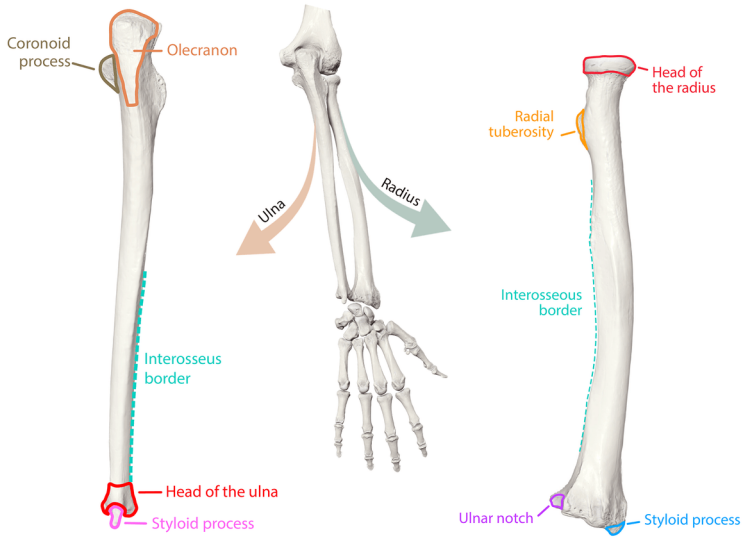

Figure 6.7.5: Bones of the Forearm - Posterior View. The radius articulates with the carpals at the wrist joint while the ulna articulates with the trochlea at the elbow joint. *(Image credit: "Bones of the Forearm" by Jennifer Lange and Claire McGuire is licensed under CC BY-NC-SA 4.0, modification of image from Anatomy Standard.)*

Radius

The **radius** runs parallel to the ulna, on the lateral (thumb) side of the forearm (see Figure 6.7.4 and Figure 6.7.5). The **head of the radius** is a disc-shaped structure that forms the proximal end. The small depression on the surface of the head articulates with the capitulum of the humerus as part of the elbow joint, whereas the smooth, outer margin of the head articulates with the radial notch of the ulna at the proximal radioulnar joint. Inferior to this point on the medial side is the **radial tuberosity**, an oval-shaped, bony protuberance that serves as a muscle attachment point.

The **shaft of the radius** is slightly curved and has a small ridge along its medial side. This ridge forms the **interosseous border of the radius**, which, like the similar border of the ulna, is the line of attachment for the interosseous membrane that unites the two forearm bones (Figure 6.7.6). The distal end of the radius has a smooth surface for articulation with two carpal bones to form the **radiocarpal joint** or wrist joint (Figure 6.7.7). On the medial side of the distal radius is the **ulnar notch of the radius**. This shallow depression articulates with the head of the ulna, which together form the **distal radioulnar joint**. The lateral end of the

radius has a pointed projection called the **styloid process of the radius**. This provides attachment for ligaments that support the lateral side of the wrist joint. Compared to the styloid process of the ulna, the styloid process of the radius projects more distally, thereby limiting the range of movement for lateral deviations of the hand at the wrist joint.

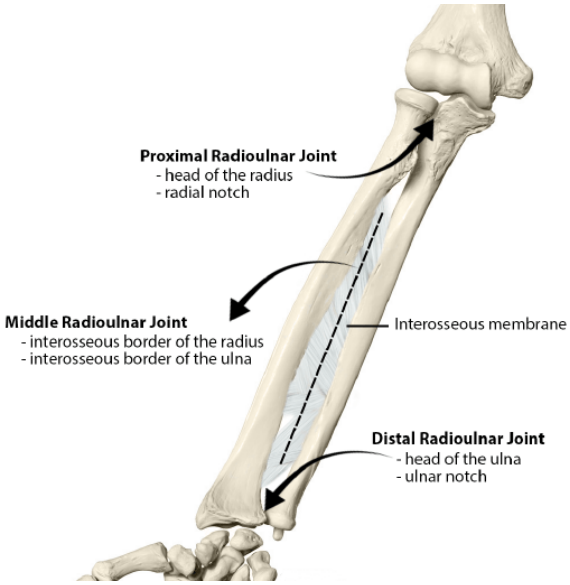

Figure 6.7.6: Radioulnar Joints Bone Landmarks. The radius and ulna articulate at three places - the proximal and the distal ends as well as the shafts. *(Image credit: "Radioulnar Joints Bone Landmarks" by Jennifer Lange is licensed under CC BY-NC-SA 4.0, modification of image from Anatomy Standard.)*

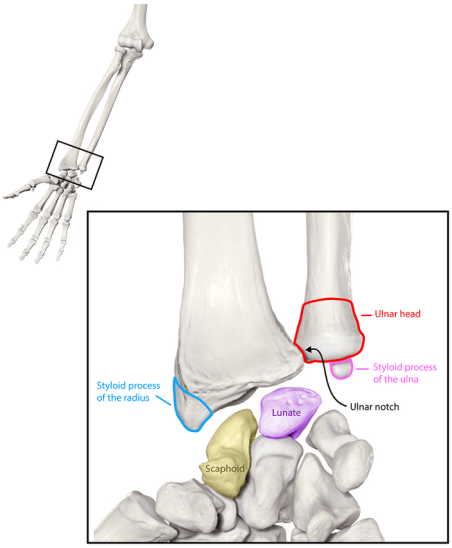

Figure 6.7.7: Bones of the Wrist Joint. The wrist is the radiocarpal joint, with the primary joint surfaces on the radius, scaphoid, and lunate. *(Image credit: "Wrist Joint - Anterior" by Claire McGuire is licensed under CC BY-NC-SA 4.0, modification of image from Anatomy Standard.)*

Carpal Bones

The wrist and base of the hand are formed by a series of eight small **carpal bones** (see Figure 6.7.8). The carpal bones are arranged in two rows, forming a proximal row of four carpal bones and a distal row of four carpal bones. The bones in the proximal row, running from the lateral (thumb) side to the medial side, are the **scaphoid** (“boat-shaped”), **lunate** (“moon-shaped”), **triquetrum** (“three-cornered”), and **pisiform** (“pea-shaped”) bones. The small, rounded pisiform bone articulates with

the anterior surface of the triquetrum bone. The pisiform thus projects anteriorly, where it forms the bony bump that can be felt at the medial base of your hand. The distal bones (lateral to medial) are the **trapezium** (“table”), **trapezoid** (“resembles a table”), **capitate** (“head-shaped”), and **hamate** (“hooked bone”) bones. The hamate bone is characterized by a prominent bony extension on its anterior side called the **hook of the hamate bone**.

A helpful mnemonic for remembering the arrangement of the carpal bones is “So Long To Pinky, Here Comes The Thumb.” This mnemonic starts on the lateral side and names the proximal bones from lateral to medial (scaphoid, lunate, triquetrum, pisiform), then makes a U-turn to name the distal bones from medial to lateral (hamate, capitate, trapezoid, trapezium). Thus, it starts and finishes on the lateral side.

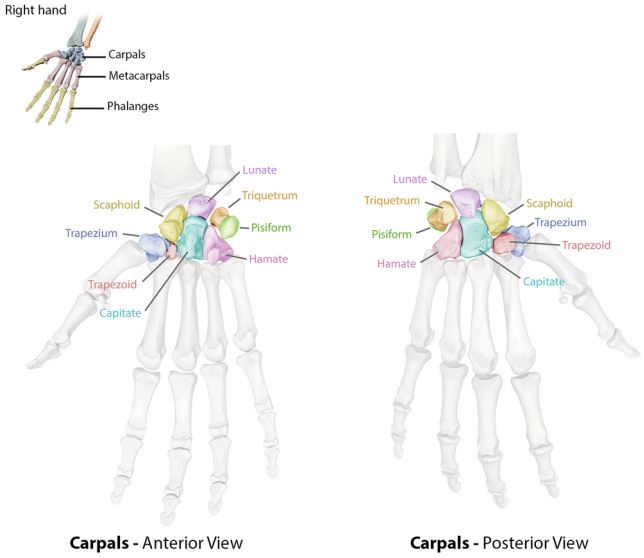

Figure 6.7.8: Bones of the Hand. The eight carpal bones form the base of the hand. These are arranged into proximal and distal rows of four bones each. *(Image credit: "Carpals" by Claire McGuire is licensed under CC BY-NC-SA 4.0, modification of image from Anatomy Standard.)*

The carpal bones form the base of the hand. This can be seen in the radiograph (X-ray image) of the hand that shows the relationships of the hand bones to the skin creases of the hand (see Figure 6.7.9). Within the carpal bones, the four proximal bones are united to each other by ligaments to form a unit. Only three of these bones, the scaphoid, lunate, and triquetrum, contribute to the radiocarpal joint. The scaphoid and lunate bones articulate directly with the distal end of the radius, whereas the triquetrum bone articulates with a fibrocartilaginous pad that spans the radius and styloid process of the ulna. The distal end of the ulna thus does not directly articulate with any of the carpal bones. The four distal carpal bones are also held together as a group by ligaments. The joints between each adjacent carpal is one of the intercarpal joints. Together, the radiocarpal and intercarpal joints are responsible for all movements of the hand at the wrist. The distal carpal bones also articulate with the metacarpal bones of the hand.

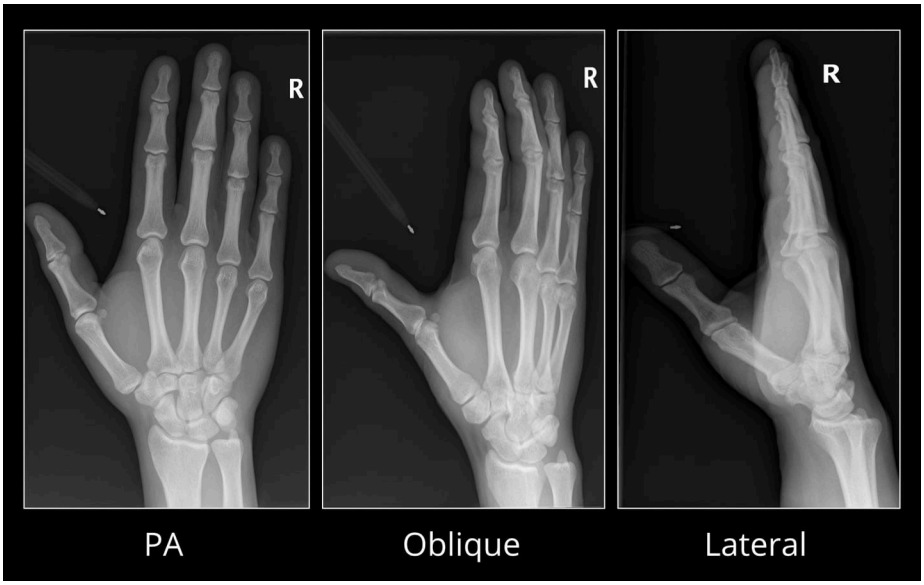

Figure 6.7.9: Bones of the Hand. This radiograph shows the position of the bones within the hand. Can you identify each of the carpals in each view? *(Image credit: Case courtesy of Jessica Hui Shi Ng, Radiopaedia.org. From the case rID: 70530.)*

In the articulated hand, the carpal bones form a U-shaped grouping. A strong ligament called the **flexor retinaculum** spans the top of this U-shaped area to maintain this grouping of the carpal bones (Figure 6.7.10). The flexor retinaculum is attached laterally to the trapezium and scaphoid bones, and medially to the hamate and pisiform bones. Together, the carpal bones and the flexor retinaculum form a passageway called the **carpal tunnel**, with the carpal bones forming the walls and floor, and the flexor retinaculum forming the roof of this space. The tendons of nine muscles of the anterior forearm and an important nerve pass through this narrow tunnel to enter the hand. Overuse of the muscle tendons or wrist injury can produce inflammation and swelling within this space. This produces compression of the nerve, resulting in carpal tunnel syndrome, which is characterized by pain or numbness, and muscle weakness in those areas of the hand supplied by this nerve.

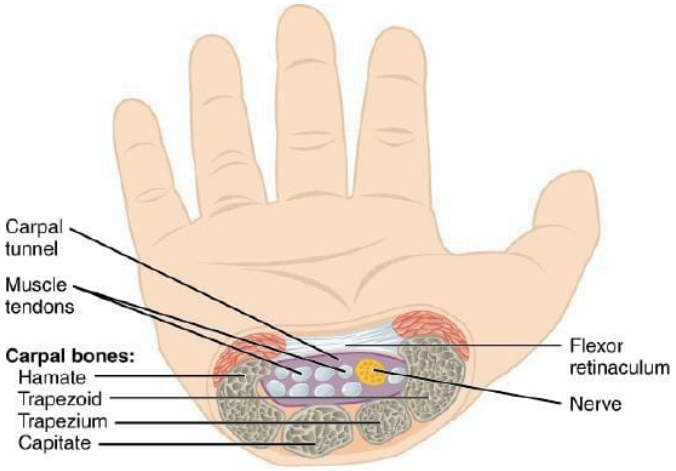

Figure 6.7.10: Carpal Tunnel. The carpal tunnel is the passageway by which nine muscle tendons and a major nerve enter the hand from the anterior forearm. The walls and floor of the carpal tunnel are formed by the U-shaped grouping of the carpal bones, and the roof is formed by the flexor retinaculum, a strong ligament that anteriorly unites the bones. (Image credit: "The Carpal Tunnel" by OpenStax is licensed under CC BY 3.0.)

Metacarpal Bones

The palm of the hand contains five elongated metacarpal bones. These bones lie between the carpal bones of the wrist and

the bones of the fingers and thumb (see Figure 6.7.11). The proximal end, also known as the base, of each metacarpal bone articulates with one of the distal carpal bones. Each of these articulations is a **carpometacarpal joint**. The elongated portion of the metacarpal bone is the body, or shaft. The expanded distal end, also known as the head, of each metacarpal bone articulates at the **metacarpophalangeal joint** with the proximal phalanx bone of the thumb or one of the fingers. The distal end also forms the knuckles of the hand, at the base of the fingers. The metacarpal bones are numbered 1–5, beginning at the thumb (or moving lateral to medial).

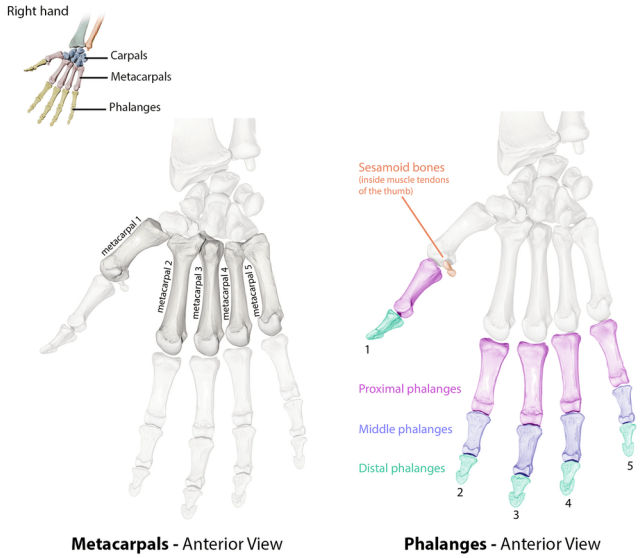

Figure 6.7.11: Metacarpals and Phalanges. The digits are numbered 1 to 5, with digit 1 being the thumb. Both the metacarpals and phalanges are named according to which digit they belong to. *(Image credit: "Metacarpals and Phalanges" by Claire McGuire is licensed under CC BY-NC-SA 4.0, modification of image from Anatomy Standard.)*

The first metacarpal bone, at the base of the thumb, is separated from the other metacarpal bones. This allows it a freedom of motion that is independent of the other metacarpal bones, which is very important for thumb mobility. The remaining metacarpal bones are united together to form the palm of the hand. The second and third metacarpal bones are firmly anchored in place and are immobile. However, the fourth and fifth metacarpal bones have limited anterior-posterior mobility, a motion that is greater for the fifth bone. This mobility is important during power gripping with the hand (Figure 6.7.12). The anterior movement of these bones, particularly the fifth metacarpal bone, increases the strength of contact for the medial hand during gripping actions.

Figure 6.7.12: Hand During Gripping. During tight gripping—compare (b) to (a)—the fourth and, particularly, the fifth metatarsal bones are pulled anteriorly. This increases the contact between the object and the medial side of the hand, thus improving the firmness of the grip. *(Image credit: "Hand Gripping" by OpenStax is licensed under CC BY 3.0.)*

Phalanx Bones

The fingers and thumb are composed of 14 bones, each of which is called a **phalanx** bone (plural = phalanges), named after the ancient Greek phalanx (a rectangular block of soldiers). The thumb (**pollex**) is digit number 1 and has two phalanges, a proximal phalanx, and a distal phalanx bone (see Figure 6.7.11). Digits 2 (index finger), 3 (middle finger), 4 (ring finger), and 5 (little finger) have three phalanges each, called the proximal, middle, and distal phalanx bones. An **interphalangeal joint** is one of the articulations between adjacent phalanges of the digits. Each phalanx bone has a base (proximal end), body (shaft), and a head (distal end).

DISORDERS OF THE...

Appendicular System: Fractures of Upper Limb Bones

Due to our constant use of the hands and the rest of our upper limbs, an injury to any of these areas will cause a significant loss of functional ability. Many fractures result from a hard fall onto an outstretched hand. The resulting transmission of force up the limb may result in a fracture of the humerus, radius, or scaphoid bones. These injuries are especially common in elderly people whose bones are weakened due to osteoporosis.

Another frequent injury following a fall onto an outstretched hand is a Colles fracture ("col-lees") of the distal radius (see Figure 6.7.13). This involves a complete transverse fracture across the distal radius that drives the separated distal fragment of the radius posteriorly and superiorly. This injury results in a characteristic "dinner fork" bend of the forearm just above the wrist due to the posterior displacement of the hand. This is the most frequent forearm fracture and is a common injury in persons over the age of 50, particularly in older women with osteoporosis. It also commonly occurs following a high-speed fall onto the hand during activities such as snowboarding or skating.

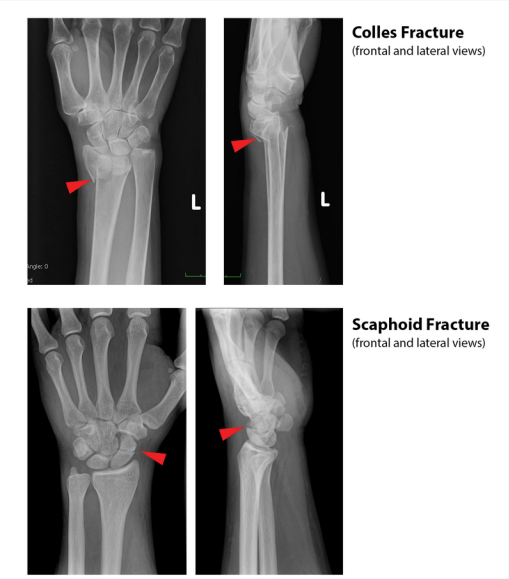

Figure 6.7.13: Fractures of the Upper Limb. A Colles fracture of the distal radius is the most common forearm fracture. The scaphoid is the most commonly fractured carpal. *(Image credits: Colles fracture case courtesy of Pir Abdul Ahad Aziz Qureshi, Radiopaedia.org. From the case rID: 47908. Scaphoid fracture case courtesy of David Cuete, Radiopaedia.org. From the case rID: 27557.)*

The most commonly fractured carpal bone is the scaphoid (see Figure 6.7.13), often resulting from a fall onto the hand. Deep pain at the lateral wrist may yield an initial diagnosis of a wrist sprain, but a radiograph taken several weeks after the injury, after tissue swelling has subsided, will reveal the fracture. Due to the poor blood supply to the scaphoid bone, healing will be slow and there is the danger of bone necrosis and subsequent degenerative joint disease of the wrist.

Interactive Element

Explore the structure of the bones of the upper limb in these 3D models:

This interactive element is not available in this format. Visit the link or scan the QR code to access it online. View this Interactive Content online	*This interactive element is not available in this format. Visit the link or scan the QR code to access it online.* View this Interactive Content online
This interactive element is not available in this format. Visit the link or scan the QR code to access it online. View this Interactive Content online	*This interactive element is not available in this format. Visit the link or scan the QR code to access it online.* View this Interactive Content online
This interactive element is not available in this format. Visit the link or scan the QR code to access it online. View this Interactive Content online	*This interactive element is not available in this format. Visit the link or scan the QR code to access it online.* View this Interactive Content online
This interactive element is not available in this format. Visit the link or scan the QR code to access it online. View this Interactive Content online	*This interactive element is not available in this format. Visit the link or scan the QR code to access it online.* View this Interactive Content online

Concept Review

Each upper limb is divided into three regions and contains a total of 30 bones. The upper arm is the region located between the shoulder and elbow joints. This area contains the humerus. The proximal humerus consists of the head, which articulates with the scapula at the glenohumeral joint, the greater and lesser tubercles separated by the intertubercular (bicipital) groove, and the anatomical and surgical necks. The humeral shaft has the roughened area of the deltoid tuberosity on its lateral side. The distal humerus is flattened, forming a lateral supracondylar ridge that terminates at the small lateral epicondyle. The medial side of the distal humerus has the large, medial epicondyle. The articulating surfaces of the distal humerus consist of the trochlea medially and the capitulum laterally. Depressions on the humerus that accommodate the forearm bones during bending (flexing) and straightening (extending) of the elbow include the coronoid fossa, the radial fossa, and the olecranon fossa.

The forearm is the region of the upper limb located between the elbow and wrist joints. This region contains two bones, the ulna medially and the radius on the lateral (thumb) side. The elbow joint is formed by the articulation between the trochlea of the humerus and the trochlear notch of the ulna, plus the articulation between the capitulum of the humerus and the head of the radius. The proximal radioulnar joint is the articulation between the head of the radius and the radial notch of the ulna. The proximal ulna also has the olecranon process, forming an expanded posterior region, and the coronoid process and ulnar tuberosity on its anterior aspect. On the proximal radius, the narrowed region below the head is the neck; distal to this is the radial tuberosity. The shaft portions of both the ulna and radius have an interosseous border, whereas the distal ends of each

bone have a pointed styloid process. The distal radioulnar joint is found between the head of the ulna and the ulnar notch of the radius. The distal end of the radius articulates with the proximal carpal bones, but the ulna does not.

The base of the hand is formed by eight carpal bones. The carpal bones are united into two rows of bones. The proximal row contains (from lateral to medial) the scaphoid, lunate, triquetrum, and pisiform bones. The scaphoid, lunate, and triquetrum bones contribute to the formation of the radiocarpal joint. The distal row of carpal bones contains (from medial to lateral) the hamate, capitate, trapezoid, and trapezium bones ("So Long To Pinky, Here Comes The Thumb"). The anterior hamate has a prominent bony hook. The proximal and distal carpal rows articulate with each other at the midcarpal joint. The carpal bones, together with the flexor retinaculum, also form the carpal tunnel of the wrist.

The five metacarpal bones form the palm of the hand. The metacarpal bones are numbered 1–5, starting with the thumb side. The first metacarpal bone is freely mobile, but the other bones are united as a group. The digits are also numbered 1–5, with the thumb being number 1. The fingers and thumb contain a total of 14 phalanges (phalanx bones). The thumb contains a proximal and a distal phalanx, whereas the remaining digits each contain proximal, middle, and distal phalanges.

Review Questions

Query 6.7.1

This interactive element is not available in this format. Visit the link or scan the QR code to access it online.

View this Interactive Content online

Query 6.7.2

This interactive element is not available in this format. Visit the link or scan the QR code to access it online.

View this Interactive Content online

Critical Thinking Questions

Query 6.7.3

This interactive element is not available in this format. Visit the link or scan the QR code to access it online.

View this Interactive Content online

Query 6.7.4

This interactive element is not available in this format. Visit the link or scan the QR code to access it online.

View this Interactive Content online

Glossary

Query 6.7.5

This interactive element is not available in this format. Visit the link or scan the QR code to access it online.

View this Interactive Content online

Contributors and Attributions

- OpenStax Anatomy & Physiology (CC BY 4.0). Access for free at https://openstax.org/books/anatomy-and-physiology

This page titled 6.7: Bones of the Upper Limb is shared under a CC BY-NC-SA 4.0 license and was authored, remixed, and/or curated by Jennifer Lange et al..

- 7.3: Bones of the Upper Limb by Whitney Menefee, Julie Jenks, Chiara Mazzasette, and Kim-Leiloni Nguyen is licensed CC BY 4.0.

6.8: The Pelvic Girdle and Pelvis

By the end of this section, you will be able to:

- Define the pelvic girdle and describe the bones of the pelvis
- Explain the three regions of the hip bone and identify their bony landmarks
- Describe the openings of the pelvis and the boundaries of the greater and lesser pelvis

The **pelvic girdle** (hip girdle) is formed by a two bones the right and left **os coxa** or **coxal bones** (coxal = “hip”), which serves as the attachment point for each lower limb. Each os coxa, in turn, is firmly joined to the axial skeleton via its attachment to the sacrum of the vertebral column. The right and left coxal bones also converge anteriorly to attach to each other. The bony **pelvis** is the entire structure formed by the two os coxae, the sacrum, and, attached inferiorly to the sacrum, the coccyx (Figure 6.8.1).

Unlike the bones of the pectoral girdle, which are highly mobile to enhance the range of upper limb movements, the bones of the pelvis are strongly united to each other to form a largely immobile, weight-bearing structure. This is important for stability because it enables the weight of the body to be easily transferred laterally from the vertebral column, through the pelvic girdle and hip joints, and into either lower limb whenever the other limb is not bearing weight. Thus, the immobility of the pelvis provides a strong foundation for the upper body as it rests on top of the mobile lower limbs.

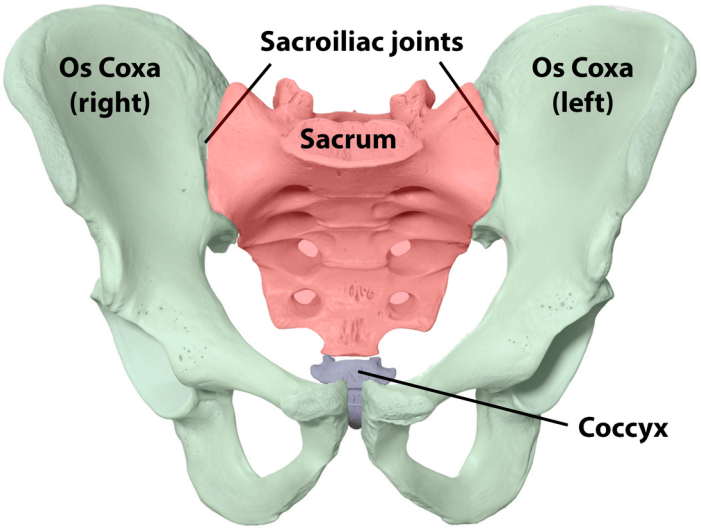

Figure 6.8.1: Pelvis. The pelvic girdle is formed by two coxal bones. The os coxa attaches the lower limb to the axial skeleton through its articulation with the sacrum. The right and left os coxae, plus the sacrum and the coccyx, together form the pelvis. *(Image credit: "Pelvic Girdle" by Jennifer Lange is licensed under CC BY-NC-SA 4.0, modification of image from Anatomy Standard under CC BY-NC 4.0.)*

Coxal Bone

The **os coxa** or **coxal bone**, forms the pelvic girdle portion of the pelvis. The paired coxal bones are the large, curved bones that form the lateral and anterior aspects of the pelvis. Each adult coxalp bone is formed by three separate bones that fuse together during the late teenage years. These bony components are the ilium, ischium, and pubis (Figure 6.8.2). These names are retained and used to define the three regions of the adult coxal bone.

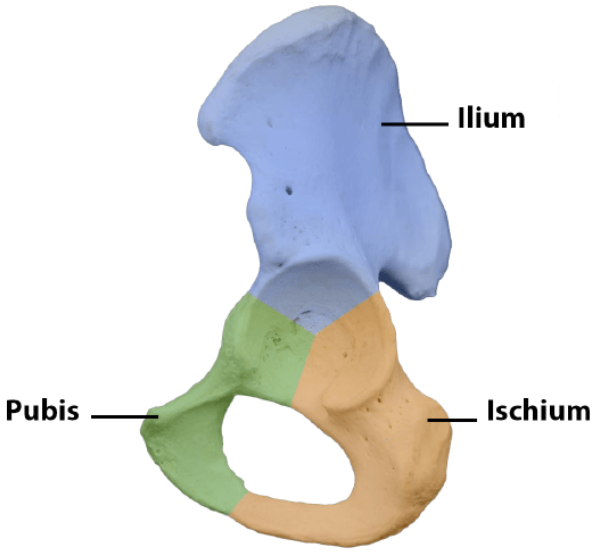

Figure 6.8.2: The Os Coxa. The adult coxal bone consists of three regions. The ilium forms the large, fan-shaped superior portion, the ischium forms the posteroinferior portion, and the pubis forms the anteromedial portion. *(Image credit: "Os Coxa Regions" by Jennifer Lange, modification of image from BlueLink that is licensed under CC BY-NC 4.0 with notification of the original authors.)*

The three regions of the adult os coxa can be seen in Figure 6.8.2. The **ilium** is the fan-like, superior region that forms the largest part of the hip bone. It is firmly united to the sacrum at the largely immobile **sacroiliac joint** (see Figure 6.8.1). The **ischium** forms the posteroinferior region of each hip bone. It supports the body when sitting. The **pubis** forms the anterior portion of the hip bone. The pubis curves medially, where it joins to the pubis of the opposite hip bone at a specialized joint called the pubic symphysis..

Ilium

When you place your hands on your waist, you can feel the arching, superior margin of the ilium along your waistline (see Figure 6.8.3). This curved, superior margin of the ilium is the **iliac crest**. The rounded, anterior termination of the iliac crest is the **anterior superior iliac spine**. This important bony landmark can be felt at your anterolateral hip. Inferior to the anterior superior iliac spine is a rounded protuberance called the **anterior inferior iliac spine**. Both of these iliac spines serve as attachment points for muscles of the thigh. Posteriorly, the iliac crest curves downward to terminate as the **posterior superior iliac spine**. Muscles and ligaments surround but do not cover this bony landmark, thus sometimes producing a depression seen as a “dimple” located on the lower back. More inferiorly is the **posterior inferior iliac spine**. This is located at the inferior end of a large, roughened area called the **auricular surface of the ilium**. The auricular surface articulates with the auricular surface of the sacrum to form the sacroiliac joint. Both the posterior superior and posterior inferior iliac spines serve as attachment points for the muscles and very strong ligaments that support the sacroiliac joint.

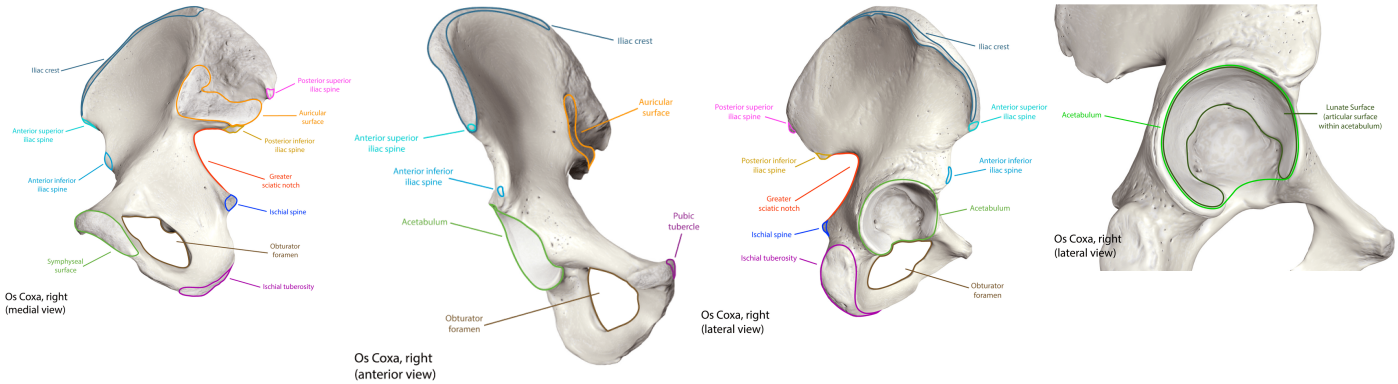

Figure 6.8.3: Landmarks of the os coxa as viewed medially, anteriorly, laterally. The close up of the lateral view shows the articular surface within the hip socket. *(Image credit: "Os Coxa, Multiple Views" by Mark Schaeffer is licensed under CC BY-NC-SA 4.0, modification of image from Anatomy Standard under CC BY-NC 4.0.)*

The shallow depression located on the anteromedial (internal) surface of the upper ilium is called the **iliac fossa**. The large, inverted U-shaped indentation located on the posterior margin of the lower ilium is called the **greater sciatic notch**.

Interactive Element

Explore the structure of the os coxa in these 3D models:

This interactive element is not available in this format. Visit the link or scan the QR code to access it online.

View this Interactive Content online

Right Coxal Bone with Texture by **Wellesley College** on **Sketchfab**

This interactive element is not available in this format. Visit the link or scan the QR code to access it online.

View this Interactive Content online

Ischium

The ischium forms the posterolateral portion of the hip bone (see Figure 6.8.2). The large, smooth area of the superior ischium is the **ischial body**.The large, roughened area of the inferior ischium is the **ischial tuberosity**. This serves as the attachment for the posterior thigh muscles and also carries the weight of the body when sitting. You can feel the ischial tuberosity if you wiggle your pelvis against the seat of a chair.

Pubis

The pubis forms the anterior portion of the hip bone (see Figure 6.8.2). The enlarged medial portion of the pubis is the **pubic body**. Located superiorly on the pubic body is a small bump called the **pubic tubercle**. The pubic body is joined to the pubic body of the opposite hip bone by the pubic symphysis (Figure 6.8.1). The flattened, medial surface of the bone is the **symphyseal surface**. The symphyseal surface of the right and left bones meet at the anterior midline of the pelvis to form the public symphysis joint.

Pelvis

The pelvis consists of four bones: the right and left os coxae, the sacrum, and the coccyx (see Figure 6.8.1). The pelvis has several important functions. Its primary role is to support the weight of the upper body when sitting and to transfer this weight to the lower limbs when standing. It serves as an attachment point for trunk and lower limb muscles, and also protects the internal pelvic organs. When standing in the anatomical position, the pelvis is tilted anteriorly. In this position, the anterior superior iliac spines and the pubic tubercles lie in the same vertical plane, and the anterior (internal) surface of the sacrum faces forward and downward.

The three areas of each coxal bone, the ilium, pubis, and ischium, converge centrally to form a deep, cup-shaped cavity called the **acetabulum** (Figure 6.8.2 and Figure 6.8.3). This is located on the lateral side of the os coxa and is the socket of the hip joint. The large opening in the anteroinferior coxal bone between the ischium and pubis is the **obturator foramen** (Figure 6.8.3). This space is largely filled in by a layer of connective tissue and serves for the attachment of muscles on both its internal and external surfaces.

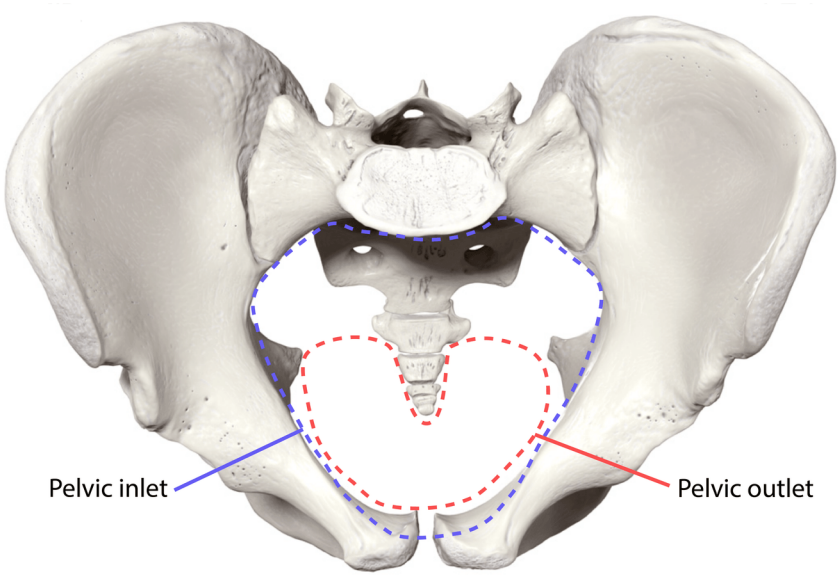

Figure 6.8.4: Pelvis. The pelvic follows the line of the pelvic brim and is the superior line tracing the area in which the pelvis forms a complete circle. The pelvic outlet is smaller and more inferior than the inlet. *(Image credit: "Pelvis" by Jennifer Lange is licensed under CC BY-NC-SA 4.0, modification of image from Anatomy Standard under CC BY-NC 4.0.)*

The space enclosed by the bony pelvis is divided into two regions (Figure 6.8.4). The broad, superior region, defined laterally by the large, fan-like portion of the upper hip bone, is called the **greater pelvis** (greater pelvic cavity; false pelvis). This broad area is occupied by portions of the small and large intestines, and because it is more closely associated with the abdominal cavity, it is sometimes referred to as the false pelvis. More inferiorly, the narrow, rounded space of the **lesser pelvis** (lesser pelvic cavity; true pelvis) contains the bladder and other pelvic organs, and thus is also known as the true pelvis. The **pelvic brim** (also known as the **pelvic inlet**) forms the superior margin of the lesser pelvis, separating it from the greater pelvis. The pelvic brim is defined by a line formed by the upper margin of the pubic symphysis anteriorly, and the pectineal line of the pubis, the arcuate line of the ilium, and the sacral promontory (the anterior margin of the superior sacrum) posteriorly. The inferior limit of the lesser pelvic cavity is called the **pelvic outlet**. This large opening is defined by the inferior margin of the pubic symphysis anteriorly, and the ischiopubic ramus, the ischial tuberosity, the sacrotuberous ligament, and the inferior tip of the coccyx posteriorly. Because of the anterior tilt of the pelvis, the lesser pelvis is also angled, giving it an anterosuperior (pelvic inlet) to posteroinferior (pelvic outlet) orientation.

Comparison of the Female and Male Pelvis

The differences between the adult female and male pelvis relate to function and body size. In general, the bones of the male pelvis are thicker and heavier, adapted for support of the male's heavier physical build and stronger muscles. The greater sciatic notch of the male hip bone is narrower and deeper than the broader notch of females. Because the female pelvis is adapted for childbirth, it is wider than the male pelvis, as evidenced by the distance between the anterior superior iliac spines (see Figure 6.8.5). The ischial tuberosities of females are also farther apart, which increases the size of the pelvic outlet. Because of this increased pelvic width, the subpubic angle is larger in females (greater than 80 degrees) than it is in males (less than 70 degrees). The female sacrum is wider, shorter, and less curved, and the sacral promontory projects less into the pelvic cavity, thus giving the female pelvic inlet (pelvic brim) a more rounded or oval shape compared to males. The lesser pelvic cavity of females is also wider and more shallow than the narrower, deeper, and tapering lesser pelvis of males. Because of the obvious differences between female and male hip bones, this is the one bone of the body that allows for the most accurate sex determination. Table 6.8.1 provides an overview of the general differences between the female and male pelvis.

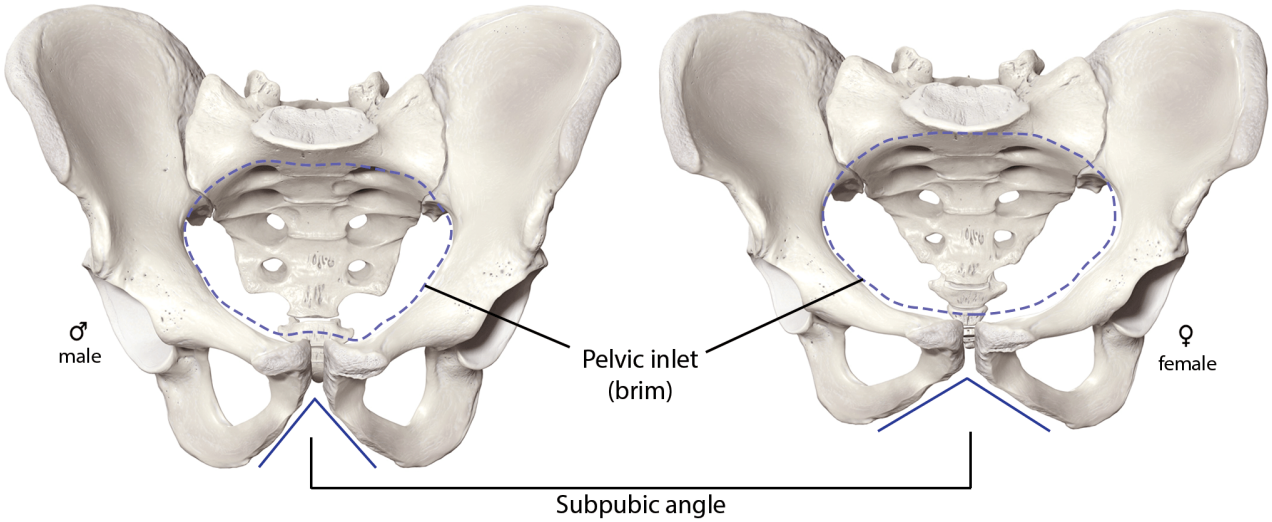

Figure 6.8.5: Male and Female Pelvis. The female pelvis is adapted for childbirth and is broader, with a larger subpubic angle and a wider pelvic brim than the male pelvis. *(Image credit: "Male and Female Pelvis Comparison" by Jennifer Lange is licensed under CC BY-NC-SA 4.0, modification of image from Anatomy Standard under CC BY-NC 4.0.)*

Table 6.8.1: Overview of Differences between the Female and Male Pelvis

Characteristic	Female pelvis	Male pelvis
Pelvic weight	Bones of the pelvis are lighter and thinner	Bones of the pelvis are thicker and heavier
Pelvic inlet shape	Pelvic inlet has a round or oval shape	Pelvic inlet is heart-shaped
Subpubic angle	Subpubic angle is greater than 80 degrees	Subpubic angle is less than 70 degrees
Pelvic outlet shape	Pelvic outlet is rounded and larger	Pelvic outlet is smaller

Career Connection

Forensic Pathology and Forensic Anthropology

A forensic pathologist (also known as a medical examiner) is a medically trained physician who has been specifically trained in pathology to examine the bodies of the deceased to determine the cause of death (Figure 6.8.6). A forensic pathologist applies his or her understanding of disease as well as toxins, blood and DNA analysis, firearms and ballistics, and other factors to assess the cause and manner of death. At times, a forensic pathologist will be called to testify under oath in situations that involve a possible crime. Forensic pathology is a field that has received much media attention on television shows or following a high-profile death.

Figure 6.8.6: Muhammad Nurul Islam, a UN forensic pathologist, examines human bones found on Dili beach, in the UN lab in Dili, Timor-Leste. *(Image credit: "Pathologist Examines Human Bones in Timor-Leste" by United Nations Photo is licensed under CC BY-NC-ND 2.0.)*

While forensic pathologists are responsible for determining whether the cause of someone's death was natural, a suicide, accidental, or a homicide, there are times when uncovering the cause of death is more complex, and other skills are needed. Forensic anthropology brings the tools and knowledge of physical anthropology and human osteology (the study of the skeleton) to the task of investigating a death. A forensic anthropologist assists medical and legal professionals in identifying human remains. The science behind forensic anthropology involves the study of archeological excavation; the examination of hair; an understanding of plants, insects, and footprints; the ability to determine how much time has elapsed since the person died; the analysis of past medical history and toxicology; the ability to determine whether there are any postmortem injuries or alterations of the skeleton; and the identification of the decedent (deceased person) using skeletal and dental evidence.

Due to the extensive knowledge and understanding of excavation techniques, a forensic anthropologist is an integral and invaluable team member to have on-site when investigating a crime scene, especially when the recovery of human skeletal remains is involved. When remains are bought to a forensic anthropologist for examination, he or she must first determine whether the remains are in fact human. Once the remains have been identified as belonging to a person and not to an animal, the next step is to approximate the individual's age, sex, race, and height. The forensic anthropologist does not determine the cause of death, but rather provides information to the forensic pathologist, who will use all of the data collected to make a final determination regarding the cause of death.

Concept Review

The pelvic girdle consists of the right and left ox coxae, which serve to attach each lower limb to the axial skeleton.

Joints

1. posterior with the sacrum at the sacroiliac joint,
2. anteriorly with each other at the pubic symphysis.

Regions

1. the ilium forms the large, fan-like superior region of the bone,
   - superior margin of this area is the iliac crest
   - at either end of the iliac crest are the anterior superior and posterior superior iliac spines
   - inferior to these are the anterior inferior and posterior inferior iliac spines

- the medial facing auricular surface of the ilium articulates with the sacrum
- the greater sciatic notch is the posterior margin of the ilium

2. the ischium is the posterolateral portion of the bone,
   - the ischial tuberosity supports body weight when sitting
   - the ischial spine is superior to the ischial tuberosity
3. the pubis forms the anterior portion of the bone
   - the symphyseal surface of each os coxa articulates with the other at the pubic symphysis joint
   - the pubic tubercle is on the superior margin, superior to the symphyseal surface

Multiregion Landmarks

1. The lateral side of the hip bone has the cup-like acetabulum, which is part of the hip joint.
2. The large anterior opening is the obturator foramen.

Pelvic Openings

1. These superior opening is the pelvic inlet (pelvic brim).
2. The inferior opening of the pelvis is the pelvic outlet.
3. Compared to the male, the female pelvis is wider to accommodate childbirth, has a larger subpubic angle, and a broader pelvic inlet and pelvic outlet.

Pelvis

The combination of the two os coxae, the sacrum, and the coccyx forms the pelvis. The pelvis has a pronounced anterior tilt. The primary function of the pelvis is to support the upper body and transfer body weight to the lower limbs. It also serves as the site of attachment for multiple muscles.

Review Questions

Query 6.8.1

This interactive element is not available in this format. Visit the link or scan the QR code to access it online.

View this Interactive Content online

Query 6.8.2

This interactive element is not available in this format. Visit the link or scan the QR code to access it online.

View this Interactive Content online

Critical Thinking Questions

Query 6.8.3

This interactive element is not available in this format. Visit the link or scan the QR code to access it online.

View this Interactive Content online

Query 6.8.4

This interactive element is not available in this format. Visit the link or scan the QR code to access it online.

View this Interactive Content online

Glossary

Query 6.8.5

This interactive element is not available in this format. Visit the link or scan the QR code to access it online.

View this Interactive Content online

Contributors and Attributions

- OpenStax Anatomy & Physiology (CC BY 4.0). Access for free at https://openstax.org/books/anatomy-and-physiology

This page titled 6.8: The Pelvic Girdle and Pelvis is shared under a CC BY-NC-SA 4.0 license and was authored, remixed, and/or curated by Jennifer Lange et al..

- 7.4: The Pelvic Girdle and Pelvis by Whitney Menefee, Julie Jenks, Chiara Mazzasette, and Kim-Leiloni Nguyen is licensed CC BY 4.0.

6.9: Bones of the Lower Limb

By the end of this section, you will be able to:

- Identify the divisions of the lower limb and describe the bones of each region
- Describe the bones and bony landmarks that articulate at each joint of the lower limb

Like the upper limb, the lower limb is divided into three regions. The **thigh** is that portion of the lower limb located between the hip joint and knee joint. The **leg** is specifically the region between the knee joint and the ankle joint. Distal to the ankle is the **foot**. The lower limb contains 30 bones. These are the femur, patella, tibia, fibula, tarsal bones, metatarsal bones, and phalanges (Figure 6.9.1). The **femur** is the single bone of the thigh. The **patella** is the kneecap and articulates with the distal femur. The **tibia** is the larger, weight-bearing bone located on the medial side of the leg, and the **fibula** is the thin bone of the lateral leg. The bones of the foot are divided into three groups. The posterior portion of the foot is formed by a group of seven bones, each of which is known as a **tarsal bone**, whereas the mid-foot contains five elongated bones, each of which is a **metatarsal bone**. The toes contain 14 small bones, each of which is a **phalanx bone of the foot**.

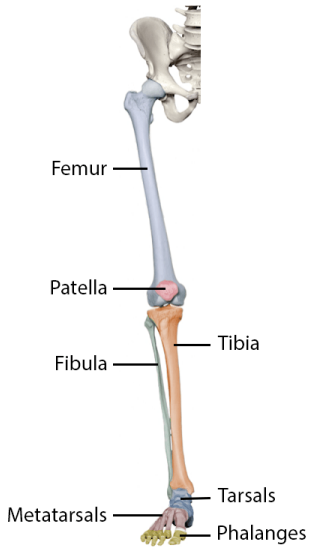

Figure 6.9.1: Bones of the Lower Limb. Bones of the femoral, crural, and pedal regions. *(Image credit: "Bones of the Lower Limb" by Jennifer Lange is licensed under CC BY-NC-SA 4.0, modification of image from Anatomy Standard under CC BY-NC 4.0.)*

Bones of the Thigh

The thigh is the common name for the femoral region, the area from where the lower limb meets the trunk to the midline of the knee joint. Two bones are within this region: the femur and the patella.

Femur

The **femur**, or thigh bone, is the single bone of the thigh region (Figure 6.9.2) . It is the longest and strongest bone of the body, and accounts for approximately one-quarter of a person's total height. The rounded, proximal end is the **head of the femur**, which articulates with the acetabulum of the hip bone to form the **hip joint**. The **fovea capitis** is a minor indentation on the medial side of the femoral head that serves as the site of attachment for the ligament of the head of the femur. This ligament spans the femur and acetabulum, but is weak and provides little support for the hip joint. It does, however, carry an important artery that supplies the head of the femur.

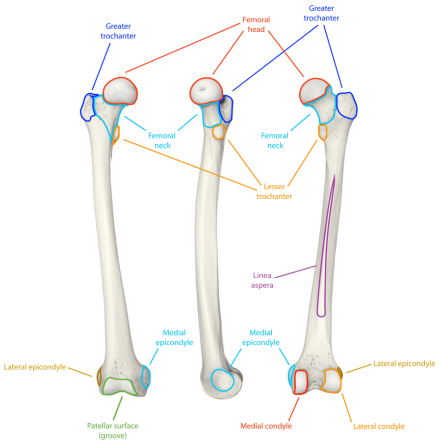

A. Anterior, Medial, and Posterior Views of the Femur

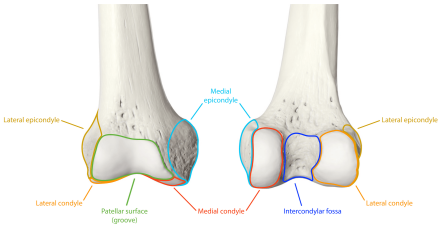

B. Anterior and Posterior Views of the Distal Femur

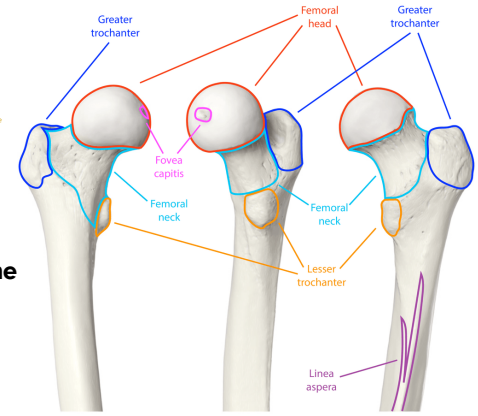

C. Anterior, Medial, and Posterior Views of the Proximal Femur

Figure 6.9.2: Femoral Landmarks. The femur is the single bone of the thigh region. It articulates superiorly with the hip bone at the hip joint, and inferiorly with the tibia at the knee joint. *(Image credit: "Femoral Landmarks" by Mark Schaeffer are licensed under CC BY-NC-SA 4.0, modification of images from Anatomy Standard under CC BY-NC 4.0.)*

The narrowed region below the head is the **neck of the femur**. This is a common area for fractures of the femur. The **greater trochanter** is the large, upward, bony projection located above the base of the neck. Multiple muscles that act across the hip joint attach to the greater trochanter, which, because of its projection from the femur, gives additional leverage to these muscles. The greater trochanter can be felt just under the skin on the lateral side of your upper thigh. The **lesser trochanter** is a small, bony prominence that lies on the medial aspect of the femur, just below the neck. A single, powerful muscle attaches to the lesser trochanter.

The elongated body, or **shaft of the femur** has a slight anterior bowing or curvature. At its proximal end, the posterior shaft has the **gluteal tuberosity**, a roughened area extending inferiorly from the greater trochanter. More inferiorly, the gluteal tuberosity becomes continuous with the **linea aspera** (“rough line”). This is the roughened ridge that passes distally along the posterior side of the mid-femur. Multiple muscles of the hip and thigh regions make long, thin attachments to the femur along the linea aspera.

The distal end of the femur has medial and lateral bony expansions. On the lateral side, the smooth portion that covers the distal and posterior aspects of the lateral expansion is the **lateral condyle of the femur**. The roughened area on the outer, lateral side of the condyle is the **lateral epicondyle of the femur**. Similarly, the smooth region of the distal and posterior medial femur is the **medial condyle of the femur**, and the irregular outer, medial side of this is the **medial epicondyle of the femur**. The lateral and medial condyles articulate with the tibia to form the knee joint. The epicondyles provide attachment for muscles of hip and knee joints and supporting ligaments of the knee. Posteriorly, the medial and lateral condyles are separated by a deep depression called the **intercondylar fossa**. Anteriorly, the smooth surfaces of the condyles join together to form a wide groove called the **patellar surface**, which provides for articulation with the patella bone. The combination of the medial and lateral condyles with the patellar surface gives the distal end of the femur a horseshoe (U) shape.

Patella

The triangular shaped patella (kneecap) has its pointy **apex** on the inferior side and its broader **base** on the superior side. It is largest sesamoid bone of the body (Figure 6.9.3) . A sesamoid bone is a bone that is incorporated into the tendon of a muscle where that tendon crosses a joint. The sesamoid bone articulates with the underlying bones to prevent damage to the muscle tendon due to rubbing against the bones during movements of the joint. The patella is found in the tendon of the quadriceps femoris muscle, the large muscle of the anterior thigh that passes across the anterior knee to attach to the tibia. The **articular surface of the patella** articulates with the patellar surface of the femur and thus prevents rubbing of the muscle tendon against the distal femur. The patella also lifts the tendon away from the knee joint, which increases the leverage power of the quadriceps femoris muscle as it acts across the knee. The patella does not articulate with the tibia.

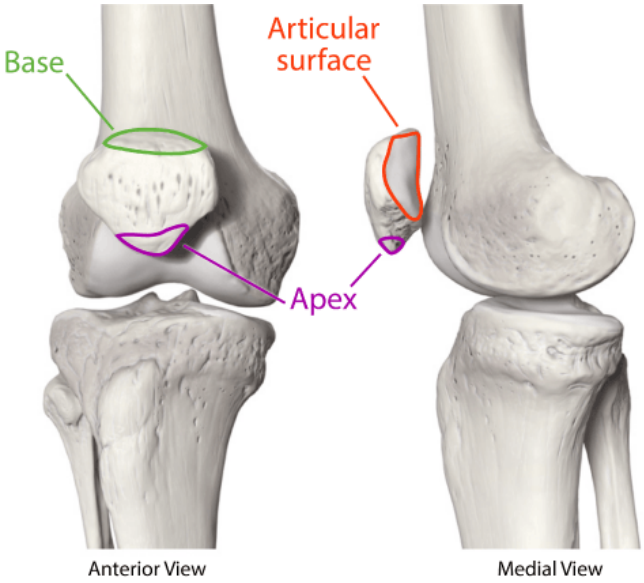

Figure 6.9.3: Patella. The patella sits in the patellar groove of the femur. This articulation forms the patellofemoral joint, which is a separate joint from the knee joint. *(Image credit: "Patella" by Mark Schaeffer is licensed under CC BY-NC-SA 4.0, modification of image from Anatomy Standard under CC BY-NC 4.0.)*

DISORDER OF THE .....

Skeletal System: Runner's Knee

Runner's knee, also known as patellofemoral syndrome, is the most common overuse injury among runners. It is most frequent in adolescents and young adults, and is more common n females. It often results from excessive running, particularly downhill, but may also occur in athletes who do a lot of knee bending, such as jumpers, skiers, cyclists, weight lifters, and soccer players. It is felt as a dull, aching pain around the front of the knee and deep to the patella. The pain may be felt when walking or running, going up or down stairs, kneeling or squatting, or after sitting with the knee bent for an extended period.

Patellofemoral syndrome may be initiated by a variety of causes, including individual variations in the shape and movement of the patella, a direct blow to the patella, or flat feet or improper shoes that cause excessive turning in or out of the feet or leg. These factors may cause in an imbalance in the muscle pull that acts on the patella, resulting in an abnormal tracking of the patella that allows it to deviate too far toward the lateral side of the patellar surface on the distal femur.

Because the hips are wider than the knee region, the femur has a diagonal orientation within the thigh, in contrast to the vertically oriented tibia of the leg (Figure 6.9.2) . The Q-angle is a measure of how far the femur is angled laterally away from vertical. The Q-angle is normally 10–15 degrees, with females typically having a larger Q-angle due to their wider pelvis. During extension of the knee, the quadriceps femoris muscle pulls the patella both superiorly and laterally, with the lateral pull greater in women due to their large Q-angle. This makes women more vulnerable to developing patellofemoral syndrome than men. Normally, the large lip on the lateral side of the patellar surface of the femur compensates for the lateral pull on the patella, and thus helps to maintain its proper tracking.

However, if the pull produced by the medial and lateral sides of the quadriceps femoris muscle is not properly balanced, abnormal tracking of the patella toward the lateral side may occur. With continued use, this produces pain and could result in damage to the articulating surfaces of the patella and femur, and the possible future development of arthritis. Treatment generally involves stopping the activity that produces knee pain for a period of time, followed by a gradual resumption of activity. Proper strengthening of the quadriceps femoris muscle to correct for imbalances is also important to help prevent reoccurrence.

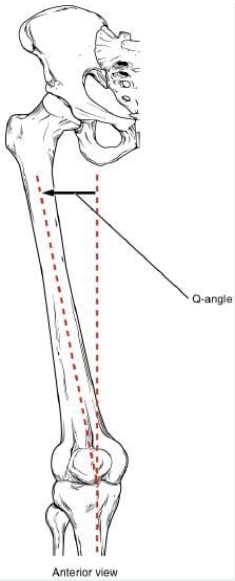

Figure 6.9.4: The Q-Angle. The Q-angle is a measure of the amount of lateral deviation of the femur from the vertical line of the tibia. Adult females have a larger Q-angle due to their wider pelvis than adult males. *(Image credit: "Femur Q Angle" by OpenStax is licensed under CC BY 3.0)*

Bones of the Leg

The leg is the crural region of the body, from the midline of the knee to the ankle joint. Two bones run parallel to each other in this region: the tibia is the larger, more medial bone and the fibula is the smaller, more lateral bone.

Tibia

The **tibia** (shin bone) is the larger of the two bones in the leg because all weight is transferred through it from the femur to the tarsals (Figure 6.9.5). It is usually the second longest bone of the body, after the femur, but occasionally its size is greater than the femur and it is the largest! The medial aspect of the tibia is located immediately under the skin, allowing it to be easily palpated down the entire length of the medial leg.

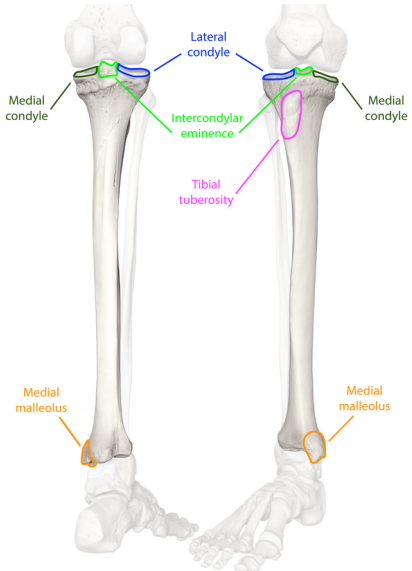

A. Anterior and Posterior Views

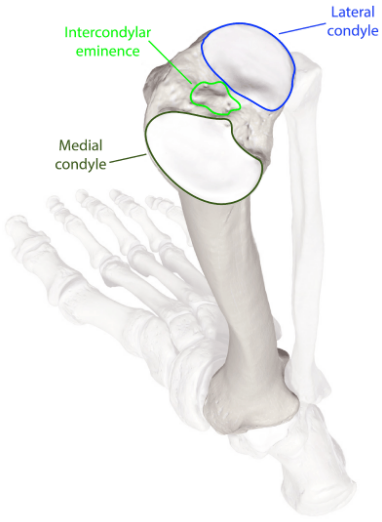

B. Superoposterior View

Figure 6.9.5: Tibia. The tibia is the larger, weight-bearing bone located on the medial side of the leg. *(Image credit: "Tibia Landmarks" by Mark Schaeffer is licensed under CC BY-NC-SA 4.0, modification of image from Anatomy Standard under CC BY-NC 4.0.)*

The proximal end of the tibia is greatly expanded. The two sides of this expansion form the **medial condyle of the tibia** and the **lateral condyle of the tibia**. The tibia does not have epicondyles. The top surface of each condyle is smooth and flattened, which forms an articular surface. These areas articulate with the medial and lateral condyles of the femur to form the **knee joint**. Between the articulating surfaces of the tibial condyles is the **intercondylar eminence**, an irregular, elevated area that serves as the inferior attachment point for the cruciate ligaments of the knee (see Figure 6.9.5 and Figure 6.9.6).

The **tibial tuberosity** is a knobby, elevated area on the anterior side of the tibia, near its proximal end. It is the attachment site for the quadriceps muscle tendon that surrounds the patella. More inferiorly, the body, or **shaft of the tibia**, becomes triangular in shape. The anterior apex of this triangle forms the **anterior border of the tibia**, which begins at the tibial tuberosity and runs inferiorly along the length of the tibia. Both the anterior border and the medial side of the triangular shaft are located immediately under the skin and can be easily palpated along the entire length of the tibia. A small ridge running down the lateral side of the tibial shaft is the **interosseous border of the tibia**. This is for the attachment of the **interosseous membrane of the leg**, the sheet of dense connective tissue that unites the tibia and fibula bones.

The large expansion found on the medial side of the distal tibia is the **medial malleolus** (“little hammer”). This forms the large bony bump found on the medial side of the ankle region. Both the smooth surface on the inside of the medial malleolus and the smooth area at the distal end of the tibia articulate with the talus bone of the foot as part of the ankle joint. On the lateral side of the distal tibia is a wide groove called the **fibular notch**. This area articulates with the distal end of the fibula, forming the **distal tibiofibular joint**.

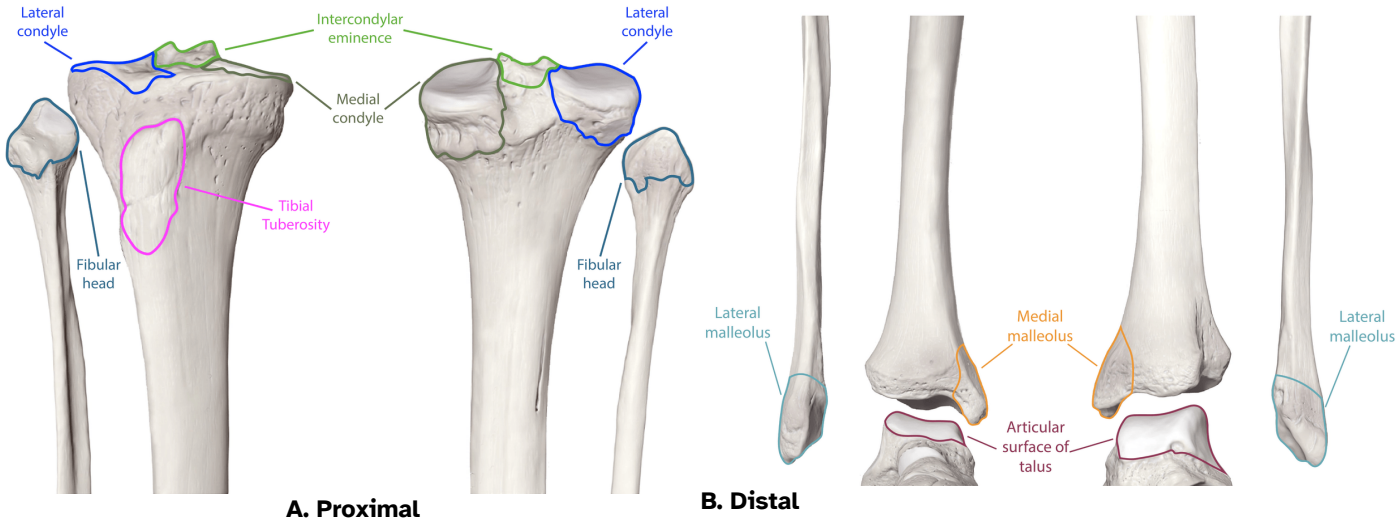

Figure 6.9.6: Landmarks of the Tibia and Fibula. Major landmarks of the tibia and fibula include their articular surfaces and attachment points for muscles and ligaments. *(Image credit: "Landmarks of the Tibia and Fibula - Multiple Views" by Mark Schaeffer is licensed under CC BY-NC-SA 4.0, modification of images from Anatomy Standard under CC BY-NC 4.0.)*

Fibula

The fibula is the slender bone located on the lateral side of the leg (Figure 6.9.6 and Figure 6.9.7) . The fibula does not bear weight. It serves primarily for muscle attachments and thus is largely surrounded by muscles. Only the proximal and distal ends of the fibula can be palpated.

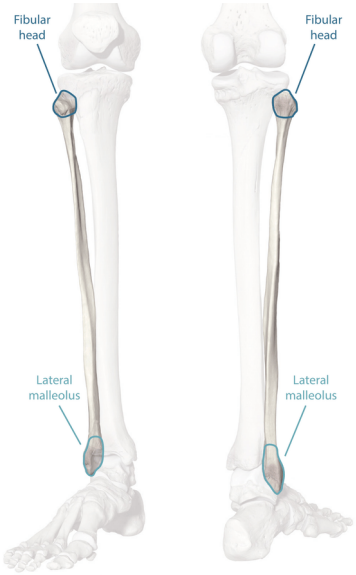

Figure 6.9.7: Fibula. The fibula is the lateral bone of the leg. It is slender because it is non-weightbearing. *(Image credit: "Fibula Landmarks" by Mark Schaeffer is licensed under CC BY-NC-SA 4.0, modification of image from Anatomy Standard under CC BY-NC 4.0.)*

The **head of the fibula** is the small, knob-like, proximal end of the fibula. It articulates with the inferior aspect of the lateral tibial condyle, forming the **proximal tibiofibular joint**. The thin **shaft of the fibula** has the **interosseous border of the fibula**, a narrow ridge running down its medial side for the attachment of the interosseous membrane that spans the fibula and tibia. The distal end of the fibula forms the **lateral malleolus**, which forms the easily palpated bony bump on the lateral side of the ankle. The deep (medial) side of the lateral malleolus articulates with the talus bone of the foot as part of the ankle joint. The distal fibula also articulates with the fibular notch of the tibia.

Bones of the Foot

The pes, or pedal region, contains three subregions corresponding to the three types of bones found here: the tarsals, the metatarsals, and the phalanges (digits) (Figure 6.9.8).

Tarsals

The posterior half of the foot is formed by seven tarsal bones (Figure 6.9.8). The most superior bone is the **talus**. This has a relatively square-shaped, upper surface that articulates with the tibia and fibula to form the **ankle joint**. Inferiorly, the talus articulates with the **calcaneus** (heel bone), the largest bone of the foot, which forms the heel. Body weight is transferred from the tibia to the talus to the calcaneus, which rests on the ground.

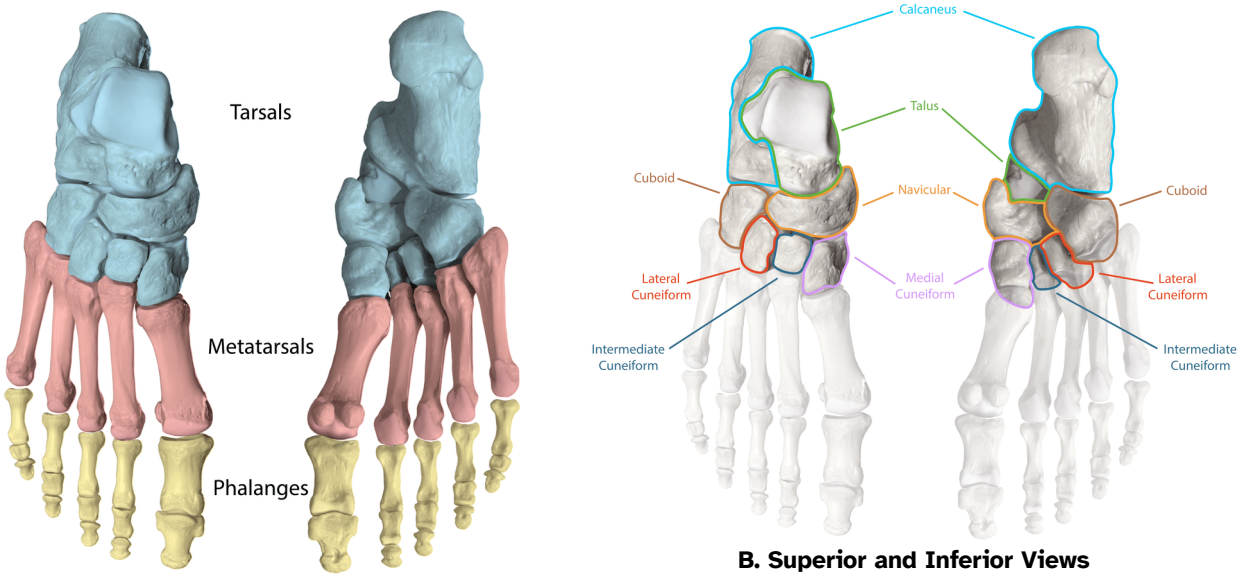

A. Superior and Inferior Views

B. Superior and Inferior Views

Figure 6.9.8: Bones of the Foot - Tarsals. The seven individual tarsal bones make up the heel and ankle region of the foot. *(Image credit: "Bones of the Foot" and "Bones of the Foot - Tarsals" by Mark Schaeffer are licensed under CC BY-NC-SA 4.0, modification of image from Anatomy Standard under CC BY-NC 4.0.)*

The **cuboid** bone articulates with the anterior end of the calcaneus bone. The talus bone articulates anteriorly with the **navicular** bone, which in turn articulates anteriorly with the three cuneiform ("wedge-shaped") bones. These bones are the **medial cuneiform**, the **intermediate cuneiform**, and the **lateral cuneiform**. Each of these bones has a broad superior surface and a narrow inferior surface, which together form the posterior aspect of the **transverse arch** (medial-lateral) of the foot (Figure 6.9.11). The navicular and lateral cuneiform bones also articulate with the medial side of the cuboid bone.

Metatarsals

The anterior half of the foot is formed by the five metatarsal bones, which are located between the tarsal bones of the posterior foot and the phalanges of the toes (Figure 6.9.8 and Figure 6.9.9) . These elongated bones are numbered 1–5, starting with the medial side of the foot. The numbering of the metatarsals matches with the corresponding digit (toe) number, and the digit with only two phalanges is always number 1. In this case, the big toe is digit number 1.

Figure 6.9.9: Bones of the Foot - Metatarsals. The five metatarsals make up the majority of the arch of the foot. They are numbered according to which digit they attach to, with digit number 1 being medial. *(Image credit: "Bones of the Foot - Metatarsals" by Mark Schaeffer is licensed under CC BY-NC-SA 4.0, modification of image from Anatomy Standard under CC BY-NC 4.0.)*

The first metatarsal bone is shorter and thicker than the others. The second metatarsal is the longest. The **base of the metatarsal bone** is the proximal end of each metatarsal bone. These articulate with the cuboid or cuneiform bones. The base of the fifth metatarsal has a large, lateral expansion that provides for muscle attachments. This expanded base of the fifth metatarsal can be felt as a bony bump at the midpoint along the lateral border of the foot. The expanded distal end of each metatarsal is the **head of the metatarsal bone**. Each metatarsal bone articulates with the proximal phalanx of a toe to form a **metatarsophalangeal joint**. The heads of the metatarsal bones also rest on the ground and form the ball (anterior end) of the foot.

Phalanges

The toes contain a total of 14 phalanx bones (phalanges), arranged in a similar manner as the phalanges of the fingers (Figure 6.9.10) . The toes are numbered 1–5, starting with the big toe, known as the **hallux**. The hallux has two phalanx bones, the proximal and distal phalanges. The remaining digits, numbers 2 through 5, all have proximal, middle, and distal phalanges. A joint between adjacent phalanx bones is called an interphalangeal joint.

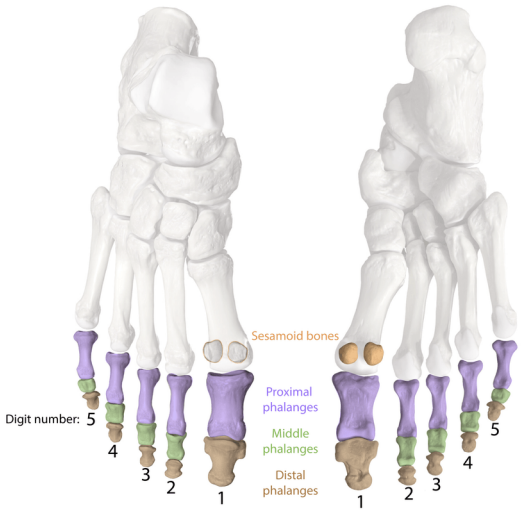

Figure 6.9.10: Bones of the Foot - Phalanges. The pattern and numbering system of the phalanges of the foot is the same as that of the phalanges of the hand. Digit 1 has only two phalanges (proximal and distal), while digits 2, 3, 4, and 5 have three phalanges (proximal, middle, and distal). *(Image credit: "Bones of the Foot - Phalanges" by Gabrielle Spurlock is licensed under CC BY-NC-SA 4.0, modification of image from Anatomy Standard under CC BY-NC 4.0.)*

Arches of the Foot

When the foot comes into contact with the ground during walking, running, or jumping activities, the impact of the body weight puts a tremendous amount of pressure and force on the foot. During running, the force applied to each foot as it contacts the ground can be up to 2.5 times your body weight. The bones, joints, ligaments, and muscles of the foot absorb this force, thus greatly reducing the amount of shock that is passed superiorly into the lower limb and body. The arches of the foot play an important role in this shock-absorbing ability. When weight is applied to the foot, these arches will flatten somewhat, thus absorbing energy. When the weight is removed, the arch rebounds, giving “spring” to the step. The arches also serve to distribute body weight side to side and to either end of the foot.

The foot has a transverse arch, a medial longitudinal arch, and a lateral longitudinal arch (Figure 6.9.11) . The transverse arch forms the medial-lateral curvature of the mid-foot. It is formed by the wedge shapes of the cuneiform bones and bases (proximal ends) of the first to fourth metatarsal bones. This arch helps to distribute body weight from side to side within the foot, thus allowing the foot to accommodate uneven terrain.

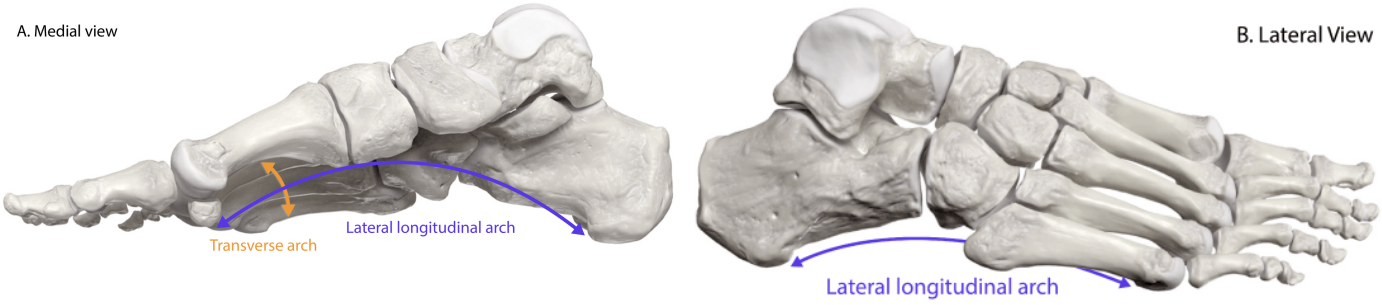

Figure 6.9.11: Arches of the Foot. The longitudinal arch runs anterior/posterior from the calcaneus to the heads of the metatarsals. The transverse arch runs medial/lateral underneath the metatarsals and cuneiforms. *(Image credit: "Arches of the Foot - Medial" and "Arches of the Foot - Lateral" by Mark Schaeffer are licensed under CC BY-NC-SA 4.0, modification of image from Anatomy Standard under CC BY-NC 4.0.)*

The longitudinal arches run down the length of the foot. The lateral longitudinal arch is relatively flat, whereas the medial longitudinal arch is larger (taller). The longitudinal arches are formed by the tarsal bones posteriorly and the metatarsal bones

anteriorly. These arches are supported at either end, where they contact the ground. Posteriorly, this support is provided by the calcaneus bone and anteriorly by the heads (distal ends) of the metatarsal bones. The talus bone, which receives the weight of the body, is located at the top of the longitudinal arches. Body weight is then conveyed from the talus to the ground by the anterior and posterior ends of these arches. Strong ligaments unite the adjacent foot bones to prevent disruption of the arches during weight bearing. On the bottom of the foot, additional ligaments tie together the anterior and posterior ends of the arches. These ligaments have elasticity, which allows them to stretch somewhat during weight bearing, thus allowing the longitudinal arches to spread. The stretching of these ligaments stores energy within the foot, rather than passing these forces into the leg. Contraction of the foot muscles also plays an important role in this energy absorption. When the weight is removed, the elastic ligaments recoil and pull the ends of the arches closer together. This recovery of the arches releases the stored energy and improves the energy efficiency of walking.

Figure 6.9.12: Pes Planus. Comparison of x-rays of a flat longitudinal arch (A) and a normal longitudinal arch (B). Notice the depression of the lateral bones compared to normal. *(Image credit: "Pes Planus" by Jennifer Lange is licensed under CC BY-NC-SA 4.0, modification of images from Radiopedia.org: pes planus case courtesy of Domenico Nicoletti, rID: 40527, and normal case courtesy of Andrew Dixon, rID: 36688.)*

Stretching of the ligaments that support the longitudinal arches can lead to pain. This can occur in overweight individuals, with people who have jobs that involve standing for long periods of time (such as a waitress), or walking or running long distances. If stretching of the ligaments is prolonged, excessive, or repeated, it can result in a gradual lengthening of the supporting ligaments, with subsequent depression or collapse of the longitudinal arches, particularly on the medial side of the foot (Figure 6.9.12). This condition is called pes planus (“flat foot” or “fallen arches”).

Interactive Element

Explore the structure of the bones of the lower limb in these 3D models:

This interactive element is not available in this format. Visit the link or scan the QR code to access it online.

View this Interactive Content online

Right Femur with Texture by **Wellesley College** on **Sketchfab**

This interactive element is not available in this format. Visit the link or scan the QR code to access it online.

View this Interactive Content online

This interactive element is not available in this format. Visit the link or scan the QR code to access it online.

View this Interactive Content online

Right Tibia with Texture by **Wellesley College** on **Sketchfab**

This interactive element is not available in this format. Visit the link or scan the QR code to access it online.

View this Interactive Content online

This interactive element is not available in this format. Visit the link or scan the QR code to access it online.

View this Interactive Content online

Human Foot Bones by **UBC Medicine - Educational Media** on **Sketchfab**

This interactive element is not available in this format. Visit the link or scan the QR code to access it online.

View this Interactive Content online

Concept Review

The lower limb is divided into three regions. These are the thigh, located between the hip and knee joints; the leg, located between the knee and ankle joints; and distal to the ankle, the foot. There are 30 bones in each lower limb. These are the femur, patella, tibia, fibula, seven tarsal bones, five metatarsal bones, and 14 phalanges.

- The **femur** is the single bone of the thigh. Key landmarks include:
  - rounded **head** for articulation with the acetabulum of the os coxa to form the hip joint,
  - the **greater and lesser trochanters** on the proximal end are muscle attachment points,
  - the **linea aspera** in the posterior mid-shaft region is a muscle attachment point,
  - three articulating surfaces on the distal end: the **medial and lateral condyles**, and the **patellar surface**,
  - the **medial and lateral epicondyles** are the rough protrusions superior to the condyles that serve as muscle and ligament attachment points.
- The **patella** is a sesamoid bone located within a muscle tendon. It articulates with the patellar surface on the anterior side of the distal femur.
- The leg contains the large **tibia** on the medial side and the slender **fibula** on the lateral side. The tibia bears the weight of the body, whereas the fibula does not bear weight. Key landmarks include:
  - The **interosseous border** of each bone is the attachment site for the connective tissue sheet that unites the tibia and fibula,
  - the proximal tibia consists of the expanded **medial and lateral condyles**, which articulate with the medial and lateral condyles of the femur to form the knee joint,
  - the **intercondylar eminence** is between the tibial condyles,
  - the **tibial tuberosity** is on the anterior side of the proximal tibia,
  - on the medial side of the distal tibia is the **medial malleolus**,
  - on the lateral side of the distal tibia is the **fibular notch,**
  - the **head of the fibula** forms the proximal end
  - the expanded distal end of the fibula is the **lateral malleolus**.
- The posterior foot is formed by the seven **tarsal bones**:
  - the **talus** articulates superiorly with the distal tibia to form the ankle joint,
  - the calcaneus forms the heel,
  - the **navicular**, the **cuboid**, and the **medial, intermediate, and lateral cuneiforms** are in the arch of the foot.
- The five **metatarsals** form the anterior foot.
- The **phalanges** are the bones of the toes. The big toe (digit number 1) has proximal and distal phalanx bones. The remaining toes have proximal, middle, and distal phalanges.

Review Questions

Query 6.9.1

This interactive element is not available in this format. Visit the link or scan the QR code to access it online.

View this Interactive Content online

Query 6.9.2

This interactive element is not available in this format. Visit the link or scan the QR code to access it online.

View this Interactive Content online

Critical Thinking Questions

Query 6.9.3

This interactive element is not available in this format. Visit the link or scan the QR code to access it online.

View this Interactive Content online

Query 6.9.4

This interactive element is not available in this format. Visit the link or scan the QR code to access it online.

View this Interactive Content online

Glossary

Query 6.9.5

This interactive element is not available in this format. Visit the link or scan the QR code to access it online.

View this Interactive Content online

Contributors and Attributions

OpenStax Anatomy & Physiology (CC BY 4.0). Access for free at https://openstax.org/books/anatomy-and-physiology

This page titled 6.9: Bones of the Lower Limb is shared under a CC BY-NC-SA 4.0 license and was authored, remixed, and/or curated by Jennifer Lange et al..

- 7.5: Bones of the Lower Limb by Whitney Menefee, Julie Jenks, Chiara Mazzasette, and Kim-Leiloni Nguyen is licensed CC BY 4.0.

6.10: Embryonic Development of the Skeleton

By the end of this section,

- Discuss the two types of embryonic bone development within the skull
- Describe the development of the vertebral column and thoracic cage
- Describe the growth and development of the embryonic limb buds
- Discuss the appearance of primary and secondary ossification centers

The axial skeleton begins to form during early embryonic development. However, growth, remodeling, and ossification (bone formation) continue for several decades after birth before the adult skeleton is fully formed. Knowledge of the developmental processes that give rise to the skeleton is important for understanding the abnormalities that may arise in skeletal structures.

Embryologically, the appendicular skeleton arises from mesenchyme, a type of embryonic tissue that can differentiate into many types of tissues, including bone or muscle tissue. Mesenchyme gives rise to the bones of the upper and lower limbs, as well as to the pectoral and pelvic girdles. Development of the limbs begins near the end of the fourth embryonic week, with the upper limbs appearing first. Thereafter, the development of the upper and lower limbs follows similar patterns, with the lower limbs lagging behind the upper limbs by a few days.

Development of the Skull

During the third week of embryonic development, a rod-like structure called the **notochord** develops dorsally along the length of the embryo. The tissue overlying the notochord enlarges and forms the neural tube, which will give rise to the brain and spinal cord. By the fourth week, mesoderm tissue located on either side of the notochord thickens and separates into a repeating series of block-like tissue structures, each of which is called a **somite**. As the somites enlarge, each one will split into several parts. The most medial of these parts is called a **sclerotome**. The sclerotomes consist of an embryonic tissue called mesenchyme, which will give rise to the fibrous connective tissues, cartilages, and bones of the body.

The bones of the skull arise from mesenchyme during embryonic development in two different ways. The first mechanism produces the bones that form the top and sides of the brain case. This involves the local accumulation of mesenchymal cells at the site of the future bone. These cells then differentiate directly into bone producing cells, which form the skull bones through the process of intramembranous ossification. As the brain case bones grow in the fetal skull, they remain separated from each other by large areas of dense connective tissue, each of which is called a **fontanelle** (Figure 6.10.1). The fontanelles are the soft spots on an infant's head. They are important during birth because these areas allow the skull to change shape as it squeezes through the birth canal. After birth, the fontanelles allow for continued growth and expansion of the skull as the brain enlarges. The largest fontanelle is located on the anterior head, at the junction of the frontal and parietal bones. The fontanelles decrease in size and disappear by age 2. However, the skull bones remain separated from each other at the sutures, which contain dense fibrous connective tissue that unites the adjacent bones. The connective tissue of the sutures allows for continued growth of the skull bones as the brain enlarges during childhood growth.

The second mechanism for bone development in the skull produces the facial bones and floor of the brain case. This also begins with the localized accumulation of mesenchymal cells. However, these cells differentiate into cartilage cells, which produce a hyaline cartilage model of the future bone. As this cartilage model grows, it is gradually converted into bone through the process of endochondral ossification. This is a slow process and the cartilage is not completely converted to bone until the skull achieves its full adult size.

At birth, the brain case and orbits of the skull are disproportionally large compared to the bones of the jaws and lower face. This reflects the relative underdevelopment of the maxilla and mandible, which lack teeth, and the small sizes of the paranasal sinuses and nasal cavity. During early childhood, the mastoid process enlarges, the two halves of the mandible and frontal bone fuse together to form single bones, and the paranasal sinuses enlarge. The jaws also expand as the teeth begin to appear. These changes all contribute to the rapid growth and enlargement of the face during childhood.

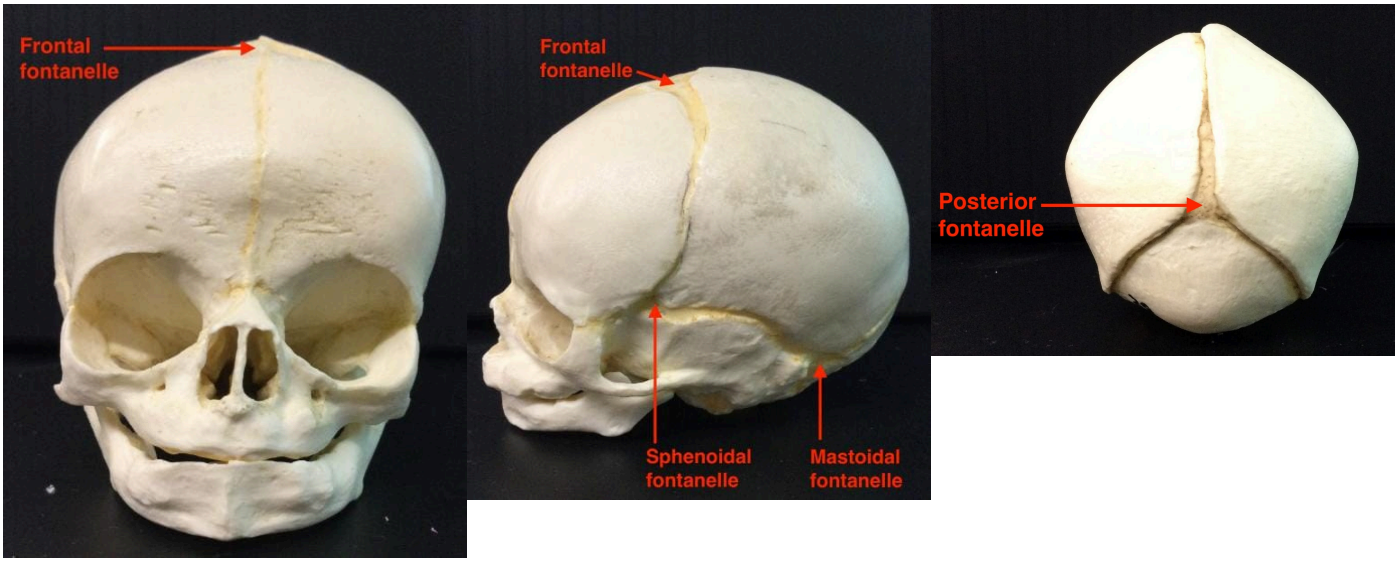

Figure 6.10.1: Fetal Skulls. The bones of the fetal skull are not fully ossified and are separated by large areas called fontanelles, which are filled with fibrous connective tissue. Fontanelles are located at points where three or more bones meet. The fontanelles allow for continued growth of the skull after birth. At the time of birth, the facial bones are small and underdeveloped, and the mastoid process has not yet formed.
(Image credits: "Fetal Skull Anterior, Lateral, and Posterior Views" by Jennifer Lange is licensed under CC BY-NC-SA 4.0.

Interactive Element

Use this 3D model to explore further the structure of the fetal skull:

This interactive element is not available in this format. Visit the link or scan the QR code to access it online.

View this Interactive Content online

Development of the Vertebral Column and Thoracic Cage

Development of the vertebrae begins with the accumulation of mesenchyme cells from each sclerotome around the notochord. These cells differentiate into a hyaline cartilage model for each vertebra, which then grow and eventually ossify into bone through the process of endochondral ossification. As the developing vertebrae grow, the notochord largely disappears. However, small areas of notochord tissue persist between the adjacent vertebrae and this contributes to the formation of each intervertebral disc.

The ribs and sternum also develop from mesenchyme. The ribs initially develop as part of the cartilage model for each vertebra, but in the thorax region, the rib portion separates from the vertebra by the eighth week. The cartilage model of the rib then ossifies, except for the anterior portion, which remains as the costal cartilage. The sternum initially forms as paired hyaline cartilage models on either side of the anterior midline, beginning during the fifth week of development. The cartilage models of the ribs become attached to the lateral sides of the developing sternum. Eventually, the two halves of the cartilaginous sternum fuse together along the midline and then ossify into bone. The manubrium and body of the sternum are converted into bone first, with the xiphoid process remaining as cartilage until late in life.

HOMEOSTATIC IMBALANCES

Craniosynostosis

The premature closure (fusion) of a suture line is a condition called craniosynostosis. This error in the normal developmental process results in abnormal growth of the skull and deformity of the head. It is produced either by defects in the ossification process of the skull bones or failure of the brain to properly enlarge. Genetic factors are involved, but the underlying cause is unknown. It is a relatively common condition, occurring in approximately 1:2000 births, with males being more commonly affected. Primary craniosynostosis involves the early fusion of one cranial suture, whereas complex craniosynostosis results from the premature fusion of several sutures.

The early fusion of a suture in primary craniosynostosis prevents any additional enlargement of the cranial bones and skull along this line. Continued growth of the brain and skull is therefore diverted to other areas of the head, causing an abnormal enlargement of these regions. For example, the early disappearance of the anterior fontanelle and premature closure of the sagittal suture prevents growth across the top of the head. This is compensated by upward growth by the bones of the lateral skull, resulting in a long, narrow, wedge-shaped head. This condition, known as scaphocephaly, accounts for approximately 50 percent of craniosynostosis abnormalities. Although the skull is misshapen, the brain still has adequate room to grow and thus there is no accompanying abnormal neurological development.

In cases of complex craniosynostosis, several sutures close prematurely. The amount and degree of skull deformity is determined by the location and extent of the sutures involved. This results in more severe constraints on skull growth, which can alter or impede proper brain growth and development.

Cases of craniosynostosis are usually treated with surgery. A team of physicians will open the skull along the fused suture, which will then allow the skull bones to resume their growth in this area. In some cases, parts of the skull will be removed and replaced with an artificial plate. The earlier after birth that surgery is performed, the better the outcome. After treatment, most children continue to grow and develop normally and do not exhibit any neurological problems.

Limb Growth

Each upper and lower limb initially develops as a small bulge called a **limb bud**, which appears on the lateral side of the early embryo. The upper limb bud appears near the end of the fourth week of development, with the lower limb bud appearing shortly after (Figure 6.10.2) .

Figure 6.10.2: Embryo at Seven Weeks. Limb buds are visible in an embryo at the end of the seventh week of development (embryo derived from an ectopic pregnancy). (Image credit: "Human Embryo" by Ed Uthman is licensed under CC BY 2.0)

Initially, the limb buds consist of a core of mesenchyme covered by a layer of ectoderm. The ectoderm at the end of the limb bud thickens to form a narrow crest called the **apical ectodermal ridge**. This ridge stimulates the underlying mesenchyme to rapidly proliferate, producing the outgrowth of the developing limb. As the limb bud elongates, cells located farther from the apical ectodermal ridge slow their rates of cell division and begin to differentiate. In this way, the limb develops along a proximal-to-distal axis.

During the sixth week of development, the distal ends of the upper and lower limb buds expand and flatten into a paddle shape. This region will become the hand or foot. The wrist or ankle areas then appear as a constriction that develops at the base of the paddle. Shortly after this, a second constriction on the limb bud appears at the future site of the elbow or knee. Within the paddle, areas of tissue undergo cell death, producing separations between the growing fingers and toes. Also during the sixth week of development, mesenchyme within the limb buds begins to differentiate into hyaline cartilage that will form models of the future limb bones.

The early outgrowth of the upper and lower limb buds initially has the limbs positioned so that the regions that will become the palm of the hand or the bottom of the foot are facing medially toward the body, with the future thumb or big toe both oriented toward the head. During the seventh week of development, the upper limb rotates laterally by 90 degrees, so that the palm of the hand faces anteriorly and the thumb points laterally. In contrast, the lower limb undergoes a 90-degree medial rotation, thus bringing the big toe to the medial side of the foot.

Ossification of Appendicular Bones

All of the girdle and limb bones, except for the clavicle, develop by the process of endochondral ossification. This process begins as the mesenchyme within the limb bud differentiates into hyaline cartilage to form cartilage models for future bones. By the twelfth week, a primary ossification center will have appeared in the diaphysis (shaft) region of the long bones, initiating the process that converts the cartilage model into bone. A secondary ossification center will appear in each epiphysis (expanded end) of these bones at a later time, usually after birth. The primary and secondary ossification centers are separated by the epiphyseal plate, a layer of growing hyaline cartilage. This plate is located between the diaphysis and each epiphysis. It continues to grow and is responsible for the lengthening of the bone. The epiphyseal plate is retained for many years, until the bone reaches its final, adult size, at which time the epiphyseal plate disappears and the epiphysis fuses to the diaphysis. (Seek additional content on ossification in the chapter on bone tissue.)

Small bones, such as the phalanges, will develop only one secondary ossification center and will thus have only a single epiphyseal plate. Large bones, such as the femur, will develop several secondary ossification centers, with an epiphyseal plate associated with each secondary center. Thus, ossification of the femur begins at the end of the seventh week with the appearance of the primary ossification center in the diaphysis, which rapidly expands to ossify the shaft of the bone prior to birth. Secondary ossification centers develop at later times. Ossification of the distal end of the femur, to form the condyles and epicondyles, begins shortly before birth. Secondary ossification centers also appear in the femoral head late in the first year after birth, in the greater trochanter during the fourth year, and in the lesser trochanter between the ages of 9 and 10 years. Once these areas have ossified, their fusion to the diaphysis and the disappearance of each epiphyseal plate follow a reversed sequence. Thus, the lesser trochanter is the first to fuse, doing so at the onset of puberty (around 11 years of age), followed by the greater trochanter approximately 1 year later. The femoral head fuses between the ages of 14–17 years, whereas the distal condyles of the femur are the last to fuse, between the ages of 16–19 years. Knowledge of the age at which different epiphyseal plates disappear is important when interpreting radiographs taken of children. Since the cartilage of an epiphyseal plate is less dense than bone, the plate will appear dark in a radiograph image. Thus, a normal epiphyseal plate may be mistaken for a bone fracture.

The clavicle is the one appendicular skeleton bone that does not develop via endochondral ossification. Instead, the clavicle develops through the process of intramembranous ossification. During this process, mesenchymal cells differentiate directly into bone-producing cells, which produce the clavicle directly, without first making a cartilage model. Because of this early production of bone, the clavicle is the first bone of the body to begin ossification, with ossification centers appearing during the fifth week of development. However, ossification of the clavicle is not complete until age 25.

DISORDERS OF THE...

Appendicular System: Congenital Clubfoot

Clubfoot, also known as talipes, is a congenital (present at birth) disorder of unknown cause and is the most common deformity of the lower limb. It affects the foot and ankle, causing the foot to be twisted inward at a sharp angle, like the head of a golf club (Figure 6.10.2) . Clubfoot has a frequency of about 1 out of every 1,000 births, and is twice as likely to occur in a male child as in a female child. In 50 percent of cases, both feet are affected.

Figure 6.10.3: Clubfoot. Clubfoot is a common deformity of the ankle and foot that is present at birth. Most cases are corrected without surgery, and affected individuals will grow up to lead normal, active lives. (Image credit: "Clubfoot" by OpenStax is licensed under CC BY 3.0)

At birth, children with a clubfoot have the heel turned inward and the anterior foot twisted so that the lateral side of the foot is facing inferiorly, commonly due to ligaments or leg muscles attached to the foot that are shortened or abnormally tight. These pull the foot into an abnormal position, resulting in bone deformities. Other symptoms may include bending of the ankle that lifts the heel of the foot and an extremely high foot arch. Due to the limited range of motion in the affected foot, it is difficult to place the foot into the correct position. Additionally, the affected foot may be shorter than normal, and the calf muscles are usually underdeveloped on the affected side. Despite the appearance, this is not a painful condition for newborns. However, it must be treated early to avoid future pain and impaired walking ability.

Although the cause of clubfoot is idiopathic (unknown), evidence indicates that fetal position within the uterus is not a contributing factor. Genetic factors are involved, because clubfoot tends to run within families. Cigarette smoking during pregnancy has been linked to the development of clubfoot, particularly in families with a history of clubfoot.

Previously, clubfoot required extensive surgery. Today, 90 percent of cases are successfully treated without surgery using new corrective casting techniques. The best chance for a full recovery requires that clubfoot treatment begin during the first 2 weeks after birth. Corrective casting gently stretches the foot, which is followed by the application of a holding cast to keep the foot in the proper position. This stretching and casting is repeated weekly for several weeks. In severe cases, surgery may also be required, after which the foot typically remains in a cast for 6 to 8 weeks. After the cast is removed following either surgical or nonsurgical treatment, the child will be required to wear a brace part-time (at night) for up to 4 years. In addition, special exercises will be prescribed, and the child must also wear special shoes. Close monitoring by the parents and adherence to postoperative instructions are imperative in minimizing the risk of relapse.

Despite these difficulties, treatment for clubfoot is usually successful, and the child will grow up to lead a normal, active life. Numerous examples of individuals born with a clubfoot who went on to successful careers include Dudley Moore (comedian and actor), Damon Wayans (comedian and actor), Troy Aikman (three-time Super Bowl-winning quarterback), Kristi Yamaguchi (Olympic gold medalist in figure skating), Mia Hamm (two-time Olympic gold medalist in soccer), and Charles Woodson (Heisman trophy and Super Bowl winner).

Concept Review

Formation of the axial skeleton begins during early embryonic development with the appearance of the rod-like notochord along the dorsal length of the early embryo. Repeating, paired blocks of tissue called somites then appear along either side of notochord. As the somites grow, they split into parts, one of which is called a sclerotome. This consists of mesenchyme, the

embryonic tissue that will become the bones, cartilages, and connective tissues of the body.

Mesenchyme in the head region will produce the bones of the skull via two different mechanisms. The bones of the brain case arise via intramembranous ossification in which embryonic mesenchyme tissue converts directly into bone. At the time of birth, these bones are separated by fontanelles, wide areas of fibrous connective tissue. As the bones grow, the fontanelles are reduced to sutures, which allow for continued growth of the skull throughout childhood. In contrast, the cranial base and facial bones are produced by the process of endochondral ossification, in which mesenchyme tissue initially produces a hyaline cartilage model of the future bone. The cartilage model allows for growth of the bone and is gradually converted into bone over a period of many years.

The vertebrae, ribs, and sternum also develop via endochondral ossification. Mesenchyme accumulates around the notochord and produces hyaline cartilage models of the vertebrae. The notochord largely disappears, but remnants of the notochord contribute to formation of the intervertebral discs. In the thorax region, a portion of the vertebral cartilage model splits off to form the ribs. These then become attached anteriorly to the developing cartilage model of the sternum. Growth of the cartilage models for the vertebrae, ribs, and sternum allow for enlargement of the thoracic cage during childhood and adolescence. The cartilage models gradually undergo ossification and are converted into bone.

The bones of the appendicular skeleton arise from embryonic mesenchyme. Limb buds appear at the end of the fourth week. The apical ectodermal ridge, located at the end of the limb bud, stimulates growth and elongation of the limb. During the sixth week, the distal end of the limb bud becomes paddle-shaped, and selective cell death separates the developing fingers and toes. At the same time, mesenchyme within the limb bud begins to differentiate into hyaline cartilage, forming models for future bones. During the seventh week, the upper limbs rotate laterally and the lower limbs rotate medially, bringing the limbs into their final positions.

Endochondral ossification, the process that converts the hyaline cartilage model into bone, begins in most appendicular bones by the twelfth fetal week. This begins as a primary ossification center in the diaphysis, followed by the later appearance of one or more secondary ossifications centers in the regions of the epiphyses. Each secondary ossification center is separated from the primary ossification center by an epiphyseal plate. Continued growth of the epiphyseal plate cartilage provides for bone lengthening. Disappearance of the epiphyseal plate is followed by fusion of the bony components to form a single, adult bone.

The clavicle develops via intramembranous ossification, in which mesenchyme is converted directly into bone tissue. Ossification within the clavicle begins during the fifth week of development and continues until 25 years of age.

Review Questions

Query 6.10.1

This interactive element is not available in this format. Visit the link or scan the QR code to access it online.

View this Interactive Content online

Query 6.10.2

This interactive element is not available in this format. Visit the link or scan the QR code to access it online.

View this Interactive Content online

Critical Thinking Questions

Query 6.10.3

This interactive element is not available in this format. Visit the link or scan the QR code to access it online.

View this Interactive Content online

Query 6.10.4

This interactive element is not available in this format. Visit the link or scan the QR code to access it online.

View this Interactive Content online

Query 6.10.5

This interactive element is not available in this format. Visit the link or scan the QR code to access it online.

View this Interactive Content online

Query 6.10.6

This interactive element is not available in this format. Visit the link or scan the QR code to access it online.

View this Interactive Content online

Query 6.10.7

This interactive element is not available in this format. Visit the link or scan the QR code to access it online.

View this Interactive Content online

Glossary

Query 6.10.8

This interactive element is not available in this format. Visit the link or scan the QR code to access it online.

View this Interactive Content online

- OpenStax Anatomy & Physiology (CC BY 4.0). Access for free at https://openstax.org/books/anatomy-and-physiology

This page titled 6.10: Embryonic Development of the Skeleton is shared under a CC BY-NC-SA 4.0 license and was authored, remixed, and/or curated by Jennifer Lange et al..

- 6.6: Embryonic Development of the Axial Skeleton by Whitney Menefee, Julie Jenks, Chiara Mazzasette, and Kim-Leiloni Nguyen is licensed CC BY 4.0.
- 7.6: Embryonic Development of the Appendicular Skeleton by Whitney Menefee, Julie Jenks, Chiara Mazzasette, and Kim-Leiloni Nguyen is licensed CC BY 4.0.

6.11: Anatomical Atlas - Skeleton

A compendium of anatomical images: slides, models, and/or cadavers.

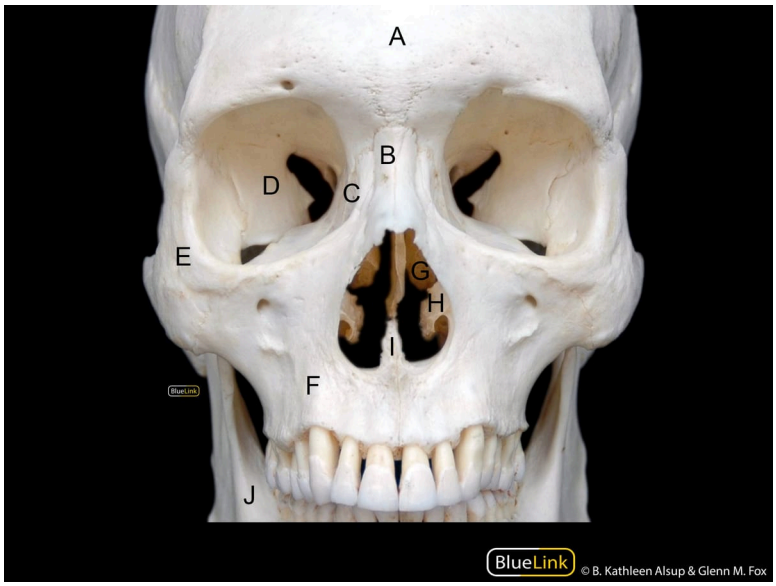

Image Credit

"Anterior Skull -Bones Atlas" by John Polos is licensed under CC BY-NC-SA 4.0, modification of original by BlueLink is licensed under CC BY-NC 4.0 with notification of the original authors.

Answer Key (click answers)

A - front

B - nasa

C - lacri

D - sphe

E - zygo

F - maxi bone)

G - ethn

H - infer concha

I - vome

J - mand

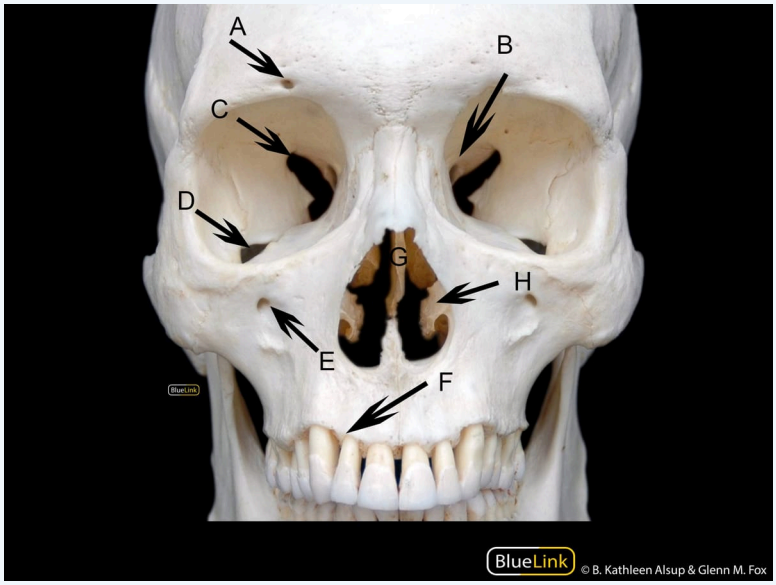

Image Credit

"Anterior Skull -Landmarks Atlas" by John Polos is licensed under CC BY-NC-SA 4.0, modification of original by BlueLink is licensed under CC BY-NC 4.0 with notification of the original authors.

Answer Key (click answers)

A - supra foramen

B - optic

C - supra

D - infra

E - infra

F - alveo

G - perp

H - infer concha

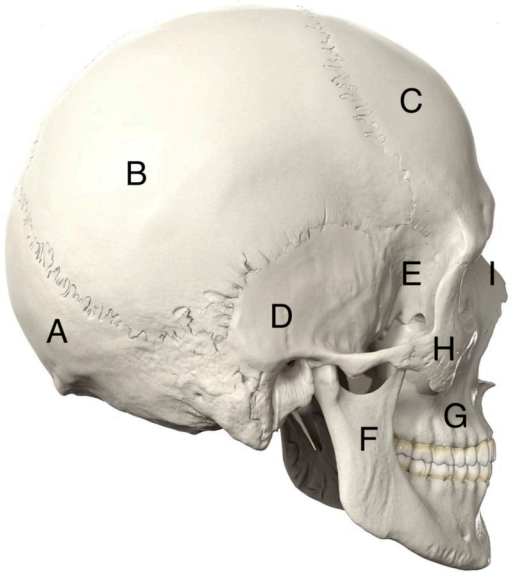

Image Credit

"Skull Bones Posterolateral View - Atlas" by Jennifer Lange is licensed under CC BY-NC-SA 4.0, modification of image from Anatomy Standard.

Answer Key (click answers)

A - occip

B - parie

C - front

D - temp

E - sphe

F - mand

G - maxi

H - zygo

I - nasal

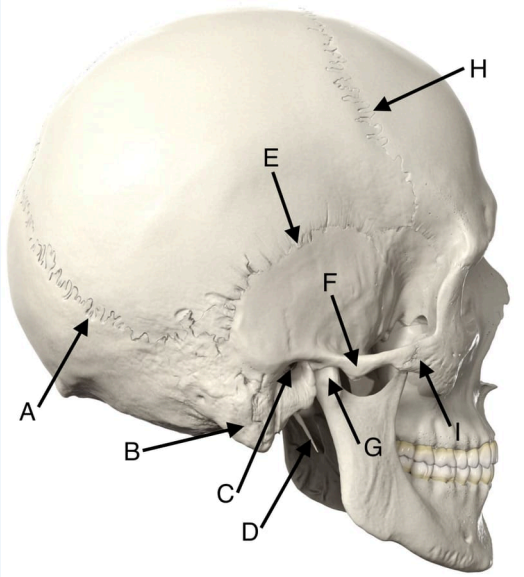

Image Credit

"Skull Landmarks Posterolateral View - Atlas" by Jennifer Lange is licensed under CC BY-NC-SA 4.0, modification of image from Anatomy Standard.

Answer Key (click answers)

A - lamb

B - mast

C - exte meatus

D - stylo

E - squa

F - zygo

G - man

H - coro

I - temp

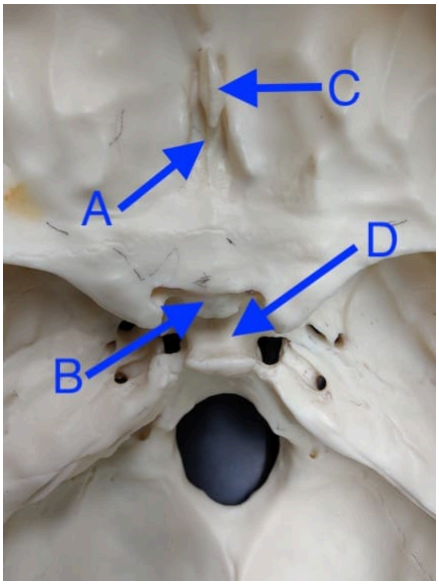

Image Credit

"Skull Interior Landmarks - Atlas" by Jennifer Lange is licensed under CC BY-NC-SA 4.0.

Answer Key (click answers)

A - cribr

B - optic

C - crist

D - hypo (part of

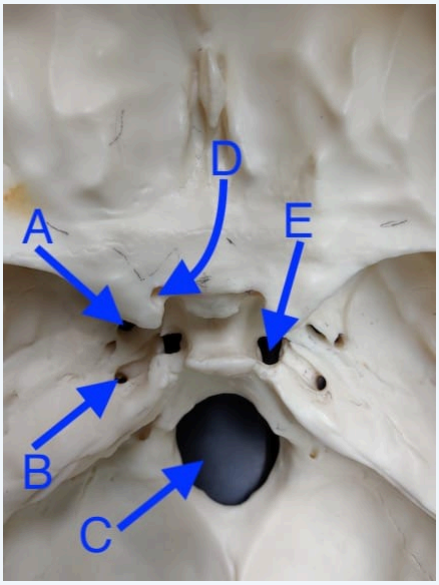

Image Credit

"Skull Foramina Interior View - Atlas" by Jennifer Lange is licensed under CC BY-NC-SA 4.0.

Answer Key (click answers)

A - forar

B - caro

C - forar

D - optic

E - forar

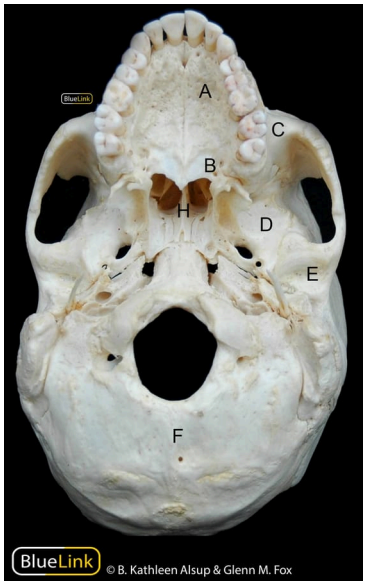

Image Credit

"Inferior Skull -Bones Atlas" by John Polos is licensed under CC BY-NC-SA 4.0, modification of original by BlueLink is licensed under CC BY-NC 4.0 with notification of the original authors.

Answer Key (click answers)

A - maxi bone)

B - palat

C - zygo

D - sphe

E - temp

F - occi

H - vom

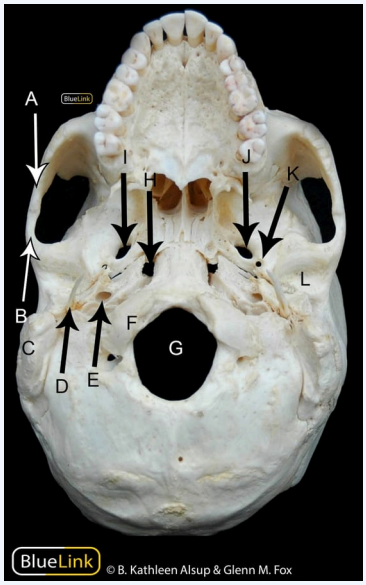

Image Credit

"Inferior Skull -Landmarks Atlas" by John Polos is licensed under CC BY-NC-SA 4.0, modification of original by BlueLink is licensed under CC BY-NC 4.0 with notification of the original authors.

Answer Key (click answers)

A - temp of zygon

B - zygo of temp

C - mast

D - stylo

E - caro

F - occi

G - fora

H - fora

I - foram

J - foram repeate

K - fora

L - mand

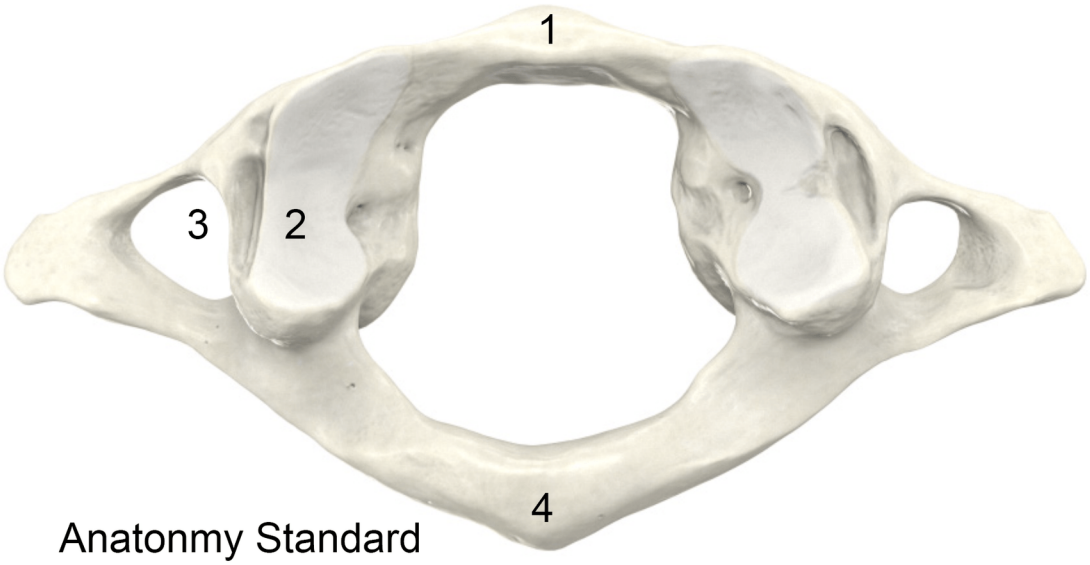

Image Credit

"Cervical Vertebra C1 - image for atlas" by John Polos is licensed under CC BY-NC-SA 4.0, modification of image from Anatomy Standard.

Answer Key (click answers)

1 - anter

2 - supe facet

3 - trans

4 - post

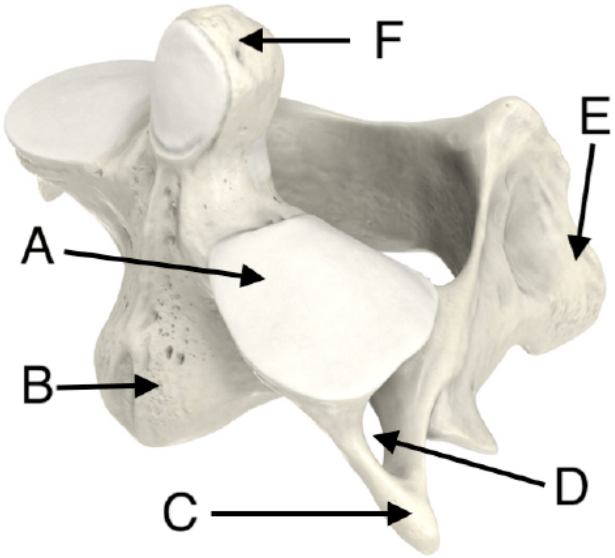

Image Credit

"Cervical Vertebra C2 - image for atlas" by Jennifer Lange is licensed under CC BY-NC-SA 4.0, modification of image from Anatomy Standard.

Answer Key (click answers)

A - supe facet

B - verte

C - trans

D - trans

E - spino

F - dens process

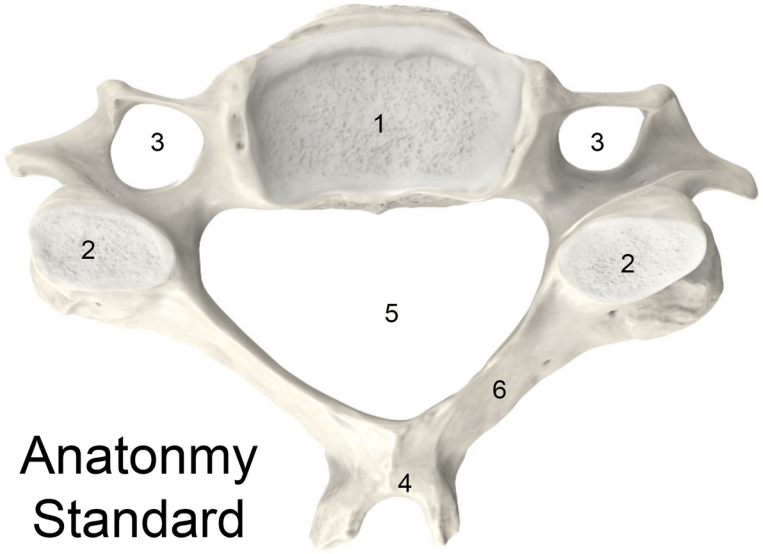

Image Credit

"Cervical Vertebra C5 - image for atlas" by John Polos is licensed under CC BY-NC-SA 4.0, modification of image from Anatomy Standard.

Answer Key (click answers)

1 - verte

2 - supe facet

3 - trans

4 - spino

5 - verte

6 - lamin arch

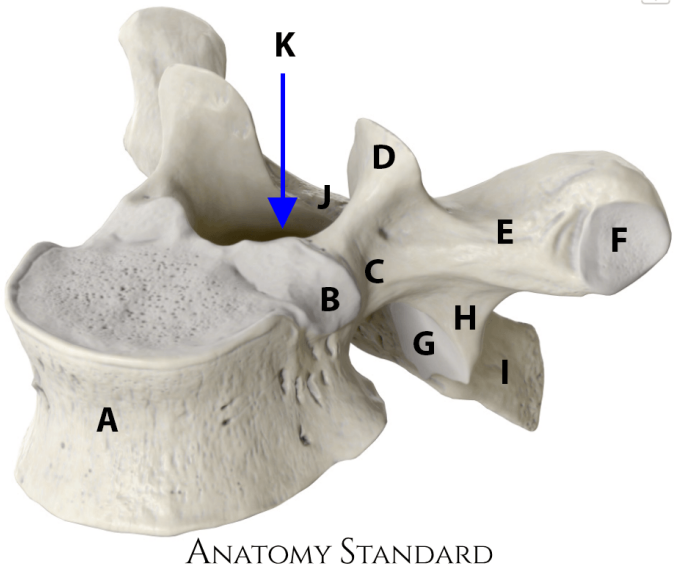

Image Credit

"Thoracic Vertebra - Atlas" by Jennifer Lange is licensed under CC BY-NC-SA 4.0, modification of image from Anatomy Standard.

Answer Key (click answers)

A - verte

B - supe demifac

C - pedi

D - supe process

E - trans

F - trans facet

G - infer facet

H - infer process

I - spinc

J - lamir

K - verte

Image Credit

"Lumbar Vertebra - image for atlas" by John Polos is licensed under CC BY-NC-SA 4.0, modification of image from Anatomy Standard.

Answer Key (click answers)

1 - verte

2 - supe process

3 - trans

4 - spin

5 - pedi arch

6 - infer process

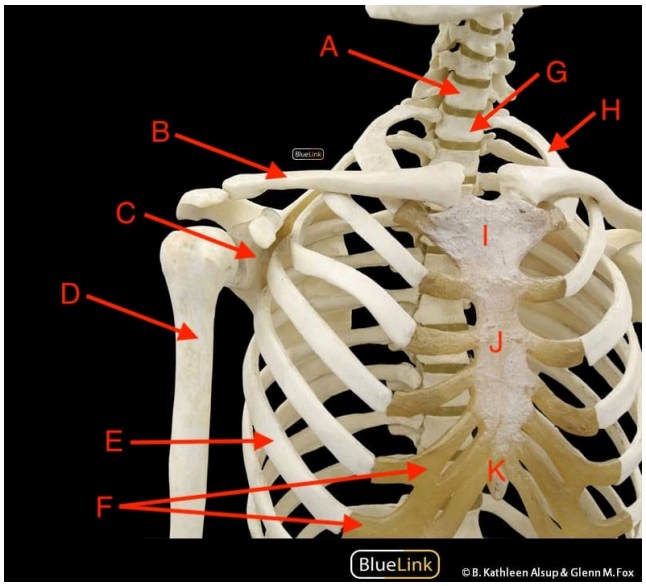

Image Credit

"Thoracic Cage, Pectoral Girdle, and Humerus Anterior View - Atlas" by Jennifer Lange is licensed under CC BY-NC-SA 4.0, modification of original by BlueLink is licensed under CC BY-NC 4.0 with notification of the original authors.

Answer Key (click answers)

A - cervi

B - clavi

C - scap

D - hum

E - rib #

F - costa

G - thora #1

H - rib #

I - manu sternum

J - body

K - xiph the ster

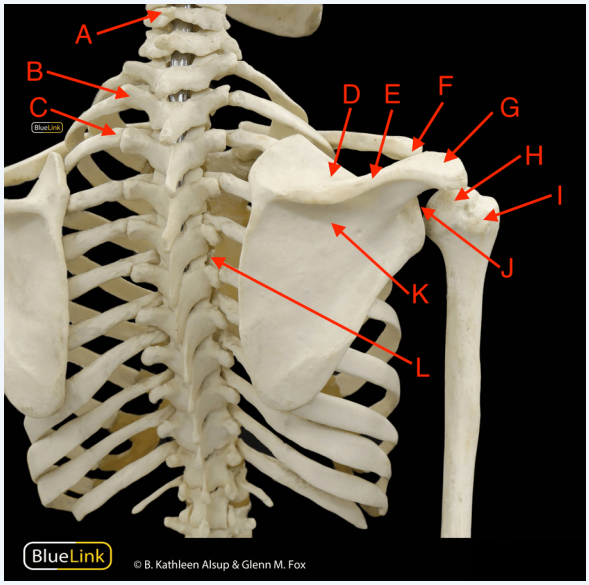

Image Credit

"Thoracic Cage, Pectoral Girdle, and Humerus Posterior View - Atlas" by Jennifer Lange is licensed under CC BY-NC-SA 4.0, modification of original by BlueLink is licensed under CC BY-NC 4.0 with notification of the original authors.

Answer Key (click answers)

A - bifec process

B - trans

C - tube

D - supr

E - spine scapula

F - acro clavicle

G - acro

H - heac humerus

I - great

J - glen (cavity)

K - infra

L - head

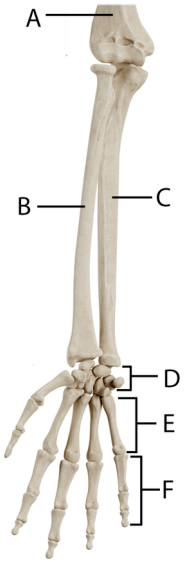

Image Credit

"Forearm and Hand Bones - Atlas" by Jennifer Lange is licensed under CC BY-NC-SA 4.0, modification of original by DrJanaOfficial.

Answer Key (click answers)

A - hum

B - radiu

C - ulna

D - carp

E - meta

F - phal

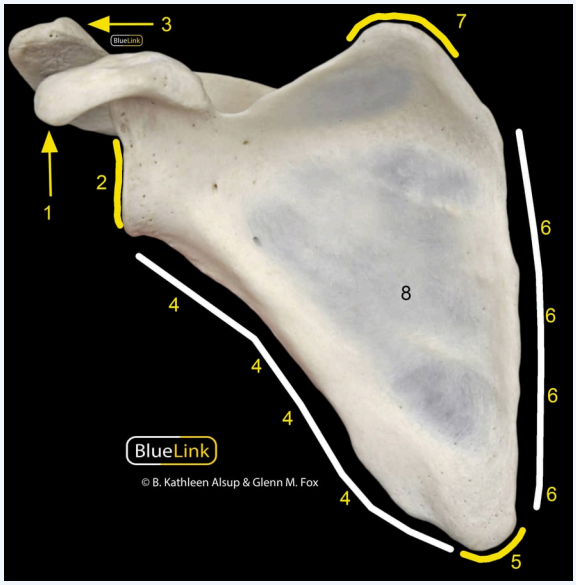

Image Credit

"Anterior Scapula - Atlas" by John Polos is licensed under CC BY-NC-SA 4.0, modification of original by BlueLink is licensed under CC BY-NC 4.0 with notification of the original authors.

Answer Key (click answers)

1 - corac

2 - glen (cavity)

3 - acro acromia

4 - later

5 - infer

6 - med

7 - supe

8 - subs

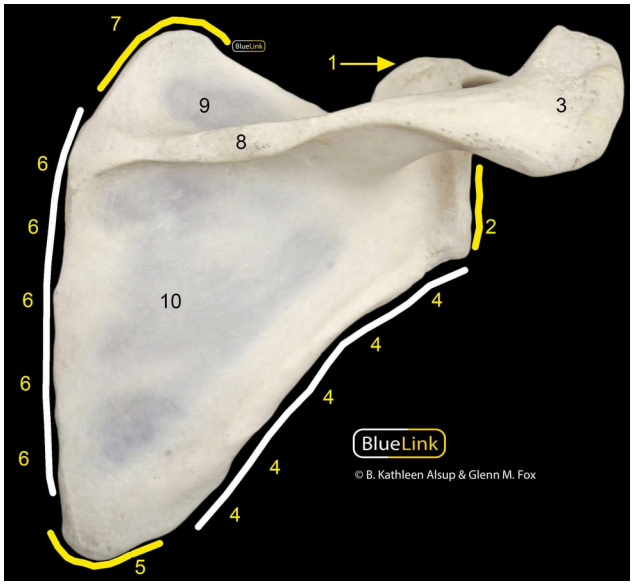

Image Credit

"Posterior Scapula - Atlas" by John Polos is licensed under CC BY-NC-SA 4.0, modification of original by BlueLink is licensed under CC BY-NC 4.0 with notification of the original authors.

Answer Key (click answers)

1 - corac

2 - glen (cavity)

3 - acro acromia

4 - later

5 - infer

6 - med

7 - supe

8 - Spin

9 - supr

10 - infr

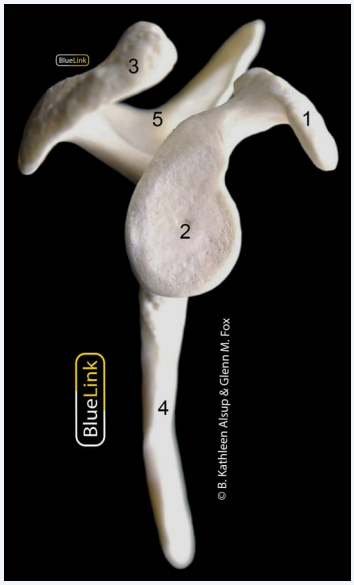

Image Credit

"Lateral Scapula - Atlas" by John Polos is licensed under CC BY-NC-SA 4.0, modification of original by BlueLink is licensed under CC BY-NC 4.0 with notification of the original authors.

Answer Key (click answers)

1 - corac

2 - glen (cavity)

3 - acro acromia

4 - later

5 - supr

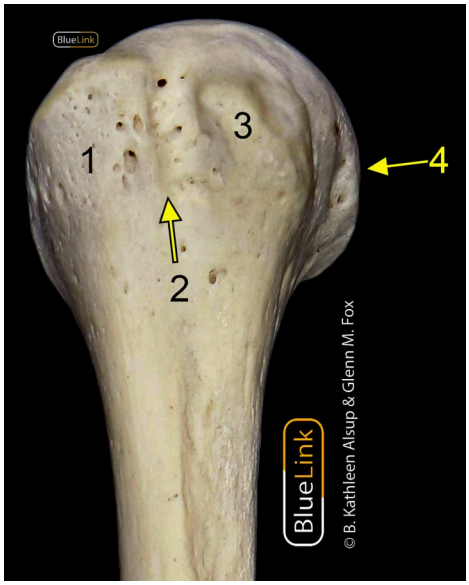

Image Credit

"Proximal Humerus- Atlas" by John Polos is licensed under CC BY-NC-SA 4.0, modification of original by BlueLink is licensed under CC BY-NC 4.0 with notification of the original authors.

Answer Key (click answers)

1 - great

2 - inter groove (

3 - lesse

4 - Head

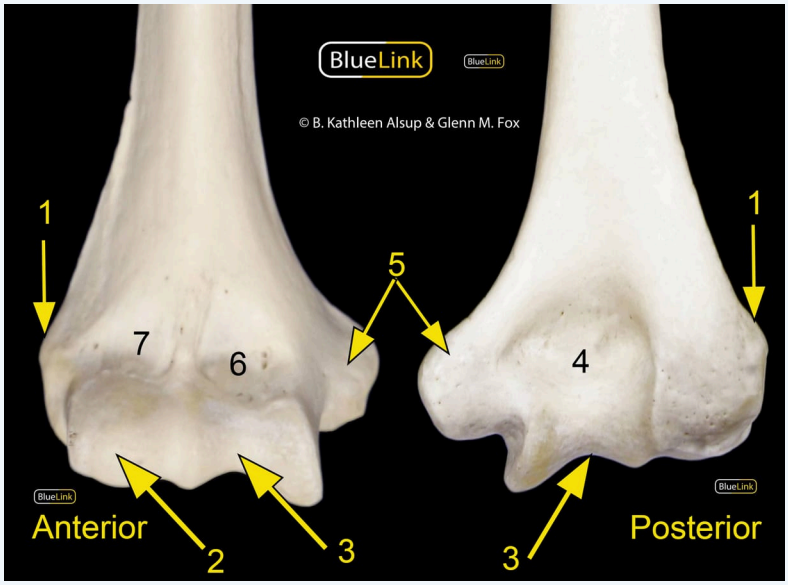

Image Credit

"Distal Humerus - Atlas" by John Polos is licensed under CC BY-NC-SA 4.0, modification of original by BlueLink is licensed under CC BY-NC 4.0 with notification of the original authors.

Answer Key (click answers)

1 - latera humerus

2 - capit

3 - troch view

4 - olecr

5 - medi epicond

6 - coro

7 - radia

8 - subs

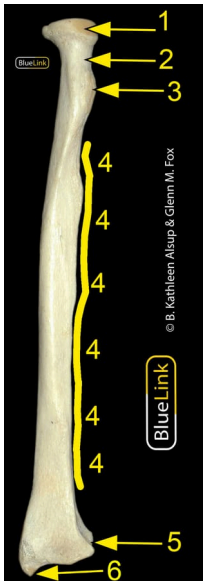

Image Credit

"Anterior Radius - Atlas" by John Polos is licensed under CC BY-NC-SA 4.0, modification of original by BlueLink is licensed under CC BY-NC 4.0 with notification of the original authors.

Answer Key (click answers)

1 - Head

2 - Neck

3 - radia

4 - inter border c

5 - ulnar

6 - stylo radius

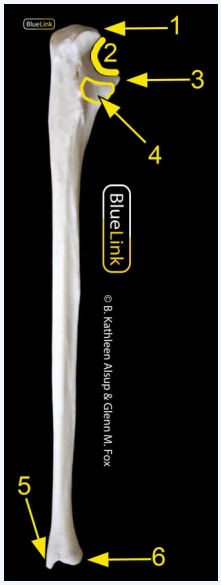

Image Credit

"Ulna - Atlas" by John Polos is licensed under CC BY-NC-SA 4.0, modification of original by BlueLink is licensed under CC BY-NC 4.0 with notification of the original authors.

Answer Key (click answers)

1 - olecr

2 - troch

3 - coro

4 - radia

5 - stylo ulna

6 - head

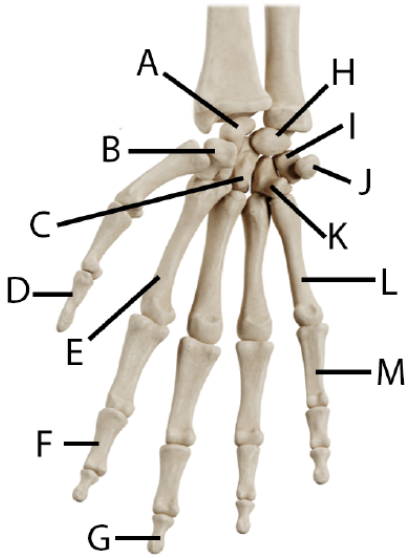

Image Credit

"Wrist and Hand Bones - Atlas" by Jennifer Lange is licensed under CC BY-NC-SA 4.0, modification of original by DrJanaOfficial.

Answer Key (click answers)

A - scap

B - trape

C - capi

D - first phalang

E - meta right ha

F - seco phalang

G - third phalang

H - luna

I - triqu

J - pisif

K - ham

L - meta right ha

M - fifth phalang

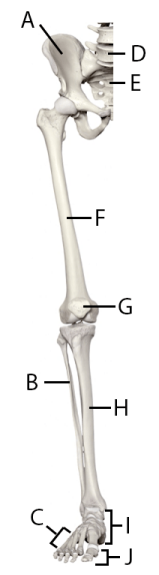

Image Credit

"Lower Limb Bones - Atlas" by Jennifer Lange is licensed under CC BY-NC-SA 4.0, modification of image from Anatomy Standard.

Answer Key (click answers)

A - os c

B - fibul

C - meta

D - lumb

E - sacru

F - femu

G - pate

H - tibia

I - tarsa

J - phala

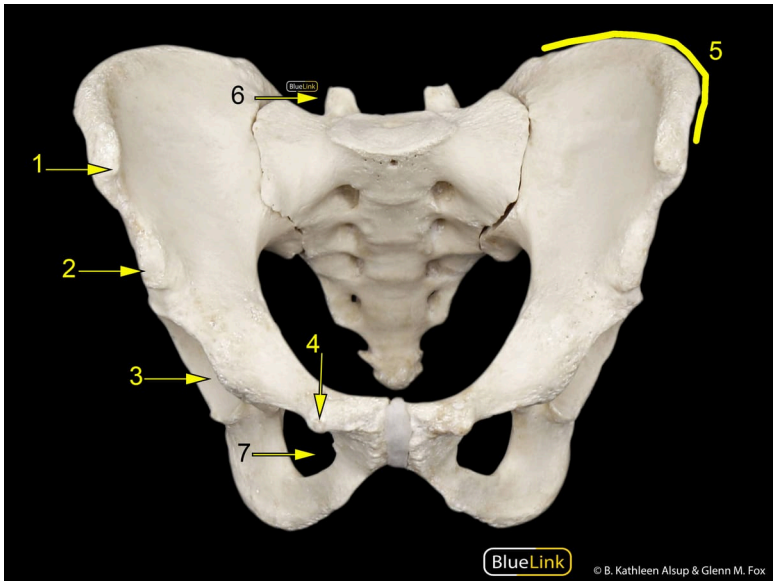

Image Credit

"Anterior hip - Atlas" by John Polos is licensed under CC BY-NC-SA 4.0, modification of original by BlueLink is licensed under CC BY-NC 4.0 with notification of the original authors.

Answer Key (click answers)

1 - anter iliac spi

2 - ante inferior

3 - aceta

4 - pubi

5 - illiac

6 - Supe articulat process

7 - obtu

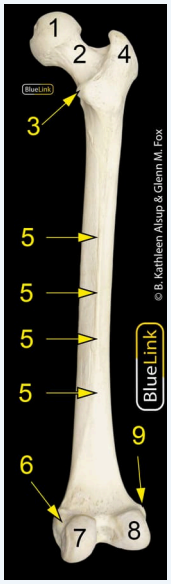

Image Credit

"Posterior Femur - Atlas" by John Polos is licensed under CC BY-NC-SA 4.0, modification of original by BlueLink is licensed under CC BY-NC 4.0 with notification of the original authors.

Answer Key (click answers)

1 - head

2 - neck

3 - lesse

4 - grea

5 - linea

6 - med

7 - medi

8 - later

9 - later

Image Credit

"Anterior Tibia - Atlas" by John Polos is licensed under CC BY-NC-SA 4.0, modification of original by BlueLink is licensed under CC BY-NC 4.0 with notification of the original authors.

Answer Key (click answers)

1 - latera

2 - tibial

3 - medi

4 - med

Image Credit

"Fibula- Atlas" by John Polos is licensed under CC BY-NC-SA 4.0, modification of original by BlueLink is licensed under CC BY-NC 4.0 with notification of the original authors.

Answer Key (click answers)

1 - head

2 - later

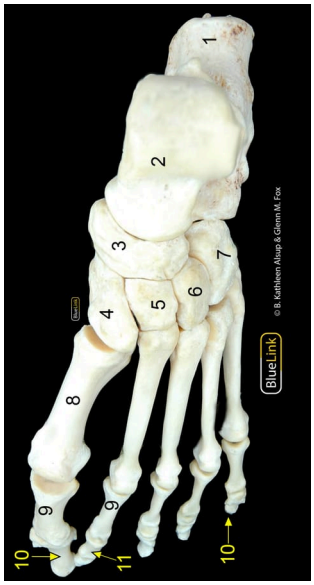

Image Credit

"Foot - Atlas" by John Polos is licensed under CC BY-NC-SA 4.0, modification of original by BlueLink is licensed under CC BY-NC 4.0 with notification of the original authors.

Answer Key (click answers)

1 - calca

2 - talus

3 - navic

4 - med

5 - interme

6 - later

7 - cubo

8 - meta

9 - prox

10 - dist

11 - inter phalang

This page titled 6.11: Anatomical Atlas - Skeleton is shared under a CC BY-NC-SA 4.0 license and was authored, remixed, and/or curated by Jennifer Lange et al..

6.12: Practice Practical - Skeleton

Please answer each of the following questions by typing your answer into the box(es).

Query 6.12.1

This interactive element is not available in this format. Visit the link or scan the QR code to access it online.

View this Interactive Content online

Query 6.12.1

This interactive element is not available in this format. Visit the link or scan the QR code to access it online.

View this Interactive Content online

Query 6.12.1

This interactive element is not available in this format. Visit the link or scan the QR code to access it online.

View this Interactive Content online

Query 6.12.1

This interactive element is not available in this format. Visit the link or scan the QR code to access it online.

View this Interactive Content online

Query 6.12.1

This interactive element is not available in this format. Visit the link or scan the QR code to access it online.

View this Interactive Content online

Query 6.12.1

This interactive element is not available in this format. Visit the link or scan the QR code to access it online.

View this Interactive Content online

Interactive Content

This interactive element is not available in this format. Visit the link or scan the QR code to access it online.

View this Interactive Content online

Query 6.12.1

This interactive element is not available in this format. Visit the link or scan the QR code to access it online.

View this Interactive Content online

This page titled 6.12: Practice Practical - Skeleton is shared under a CC BY-NC-SA 4.0 license and was authored, remixed, and/or curated by Jennifer Lange et al..

7: JOINTS

7.1: Introduction

7.2: Classification of Joints

7.3: Synovial Joints

7.4: Types of Body Movements

7.5: Anatomy of Selected Synovial Joints

7.6: Diseases and Injuries of Joints

7.7: Anatomical Atlas - Joints

7.8: Practice Practical - Joints

This page titled 7: Joints is shared under a CC BY-NC-SA 4.0 license and was authored, remixed, and/or curated by Jennifer Lange et al..

- 8: Joints by Whitney Menefee, Julie Jenks, Chiara Mazzasette, and Kim-Leiloni Nguyen is licensed CC BY 4.0.

7.1: Introduction

Chapter Learning Objectives

After studying this chapter, you will be able to:

- Discuss both functional and structural classifications for body joints
- Describe the characteristic features for fibrous, cartilaginous, and synovial joints and give examples of each
- Describe and identify the different body movements
- Discuss the structure of specific body joints and the movements allowed by each
- Explain the development of body joints

The adult human body has 206 bones, and with the exception of the hyoid bone in the neck, each bone is connected to at least one other bone. Joints, also known as articulations, are the location where bones come together. Many joints allow for movement between the bones. At these joints, the articulating surfaces of the adjacent bones can move smoothly against each other. However, the bones of other joints may be joined to each other by connective tissue or cartilage. These joints are designed for stability and provide for little or no movement. Importantly, joint stability and movement are inversely related to each other. This means that stable joints allow for little or no mobility between the adjacent bones. Conversely, joints that provide the most movement between bones are the least stable. Understanding the relationship between joint structure and function will help to explain why particular types of joints are found in certain areas of the body.

The articulating surfaces of bones at stable types of joints, with little or no mobility, are strongly united to each other. For example, most of the joints of the skull are held together by fibrous connective tissue and do not allow for movement between the adjacent bones. This lack of mobility is important, because the skull bones serve to protect the brain. Similarly, other joints united by fibrous connective tissue allow for very little movement, which provides stability and weight-bearing support for the body. For example, the tibia and fibula of the leg are tightly united to give stability to the body when standing. At other joints, the bones are held together by cartilage, which permits limited movements between the bones. Thus, the joints of the vertebral column only allow for small movements between adjacent vertebrae, but when added together, these movements provide the flexibility that allows your body to twist, or bend to the front, back, or side. In contrast, at joints that allow for wide ranges of motion, the articulating surfaces of the bones are not directly united to each other. Instead, these surfaces are enclosed within a space filled with lubricating fluid, which allows the bones to move smoothly against each other. These joints provide greater mobility, but since the bones are free to move in relation to each other, the joint is less stable. Most of the joints between the bones of the appendicular skeleton are this freely moveable type of joint. These joints allow the muscles of the body to pull on a bone and thereby produce movement of that body region. Your ability to kick a soccer ball, pick up a fork, and dance the tango depend on mobility at these types of joints.

Figure 7.1.1: Yoga. Without joints, body movements would be impossible. (Image credit: Mr. Yoga, CC BY-SA 4.0, via Wikimedia Commons)

Contributors and Attributions

- OpenStax Anatomy & Physiology (CC BY 4.0). Access for free at https://openstax.org/books/anatomy-and-physiology

This page titled 7.1: Introduction is shared under a CC BY-NC-SA 4.0 license and was authored, remixed, and/or curated by Jennifer Lange et al..

- 8.1: Introduction by Whitney Menefee, Julie Jenks, Chiara Mazzasette, and Kim-Leiloni Nguyen is licensed CC BY 4.0.

7.2: Classification of Joints

By the end of this section, you will be able to:

- Distinguish between the functional and structural classifications for joints
- Describe the three functional types of joints and give an example of each
- Describe the structural features of fibrous joints and of cartilaginous joints
- Distinguish between a suture, syndesmosis, and gomphosis
- Give an example of each type of fibrous joint and each type of cartilaginous joint
- Distinguish between a synchondrosis and symphysis

A **joint**, also called an **articulation**, is any place where adjacent bones or bone and cartilage come together (articulate with each other) to form a connection. Joints are classified both structurally and functionally. Structural classifications of joints take into account whether there is a space **(joint cavity)** between the bones or whether the gap is fully filled by either dense connective tissue or cartilage. Functional classifications describe the degree of movement available between the bones, ranging from immobile, to slightly mobile, to freely moveable joints.

Structural Classification of Joints

The structural classification of joints is based on whether the articulating surfaces of the adjacent bones are directly connected by fibrous connective tissue or cartilage, or whether the articulating surfaces contact each other within a fluid-filled joint cavity. These differences serve to divide the joints of the body into three structural classifications.

- A **fibrous joint** is where the adjacent bones are united by dense regular connective tissue.
- At a **cartilaginous joint**, the bones are joined by hyaline cartilage or fibrocartilage.
- At a **synovial joint**, the articulating surfaces of the bones are not directly connected, but instead come into contact with each other within a joint cavity that is filled with a lubricating fluid. Synovial joints allow for free movement between the bones and are the most common joints of the body. These three structural classifications will be discussed in further detail in the following sections of this chapter.

Fibrous Joints

At a fibrous joint, the adjacent bones are directly connected to each other by dense regular connective tissue, and thus the bones do not have a joint cavity between them (Figure 7.2.1. The gap between the bones may be narrow or wide. There are three types of fibrous joints. A **suture** is the narrow fibrous joint found between most bones of the skull. At a **syndesmosis** joint, the bones are more widely separated but are held together by either a narrow band of fibrous connective tissue called a **ligament** or a wide sheet of connective tissue called an **interosseous membrane**. This type of fibrous joint is found between the shaft regions of the long bones in the forearm and in the leg. Lastly, a **gomphosis** is the narrow fibrous joint between the roots of a tooth and the bony socket in the jaw into which the tooth fits.

Suture

All the bones of the skull, except for the mandible, are joined to each other by a fibrous joint called a **suture**. The dense regular connective tissue found at a suture (“to bind or sew”) strongly unites the adjacent skull bones and thus helps to protect the brain and form the face. In adults, the skull bones are closely opposed and fibrous connective tissue fills the narrow gap between the bones. The suture is frequently convoluted, forming a tight union that prevents most movement between the bones. (Figure 7.2.1) Thus, skull sutures are functionally classified as a synarthrosis, although some sutures may allow for slight movements between the cranial bones.

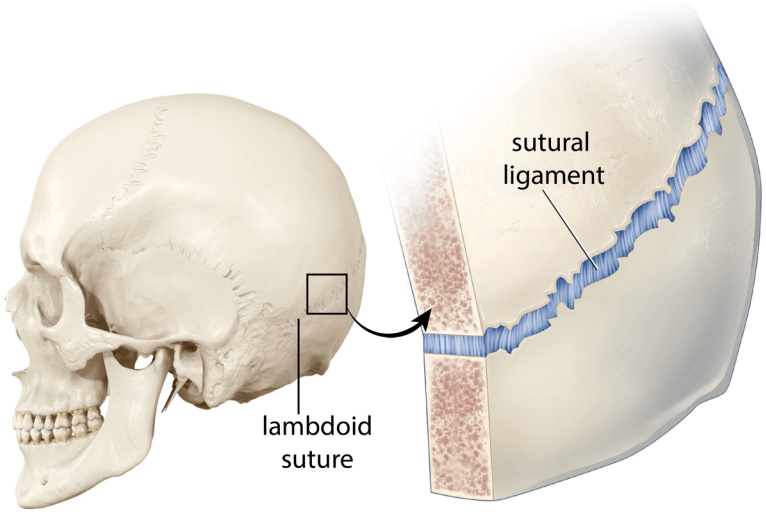

(Figure 7.2.1): Suture. The sutures of the skull are very narrow areas of dense regular connective tissue that are immovable. *(Image credit: "Fibrous Joint - Suture" by Jennifer Lange is licensed under CC BY-NC-SA 4.0, based on originals from Anatomy Standard (skull) and BlueLink (illustration).)*

In newborns and infants, the areas of connective tissue between the bones are much wider, especially in those areas on the top and sides of the skull that will become the sagittal, coronal, squamous, and lambdoid sutures. These broad areas of connective tissue are called **fontanelles** (Figure 7.2.2). The most prominent fontanelle is the **anterior fontanelle,** which can be found on top of the skull between the frontal bone and the parietal bones. For some newborns, the anterior fontanelle is visible on the top of the head, and is often called the infant's "soft spot". The **posterior fontanelle** can be found on the back side of the skull between the parietal bones and occipital bone. On the sides of the skull are two fontanelles, the **sphenoidal fontanelle** and the **mastoid fontanelle**. The sphenoidal fontanelle is located toward the anterior of the skull just superior to the sphenoid bone and connects the sphenoid bone, frontal bone, parietal bone, and temporal bone. The mastoid fontanelle, found toward the posterior of the skull, connects that occipital bone, parietal bone, and temporal bone.

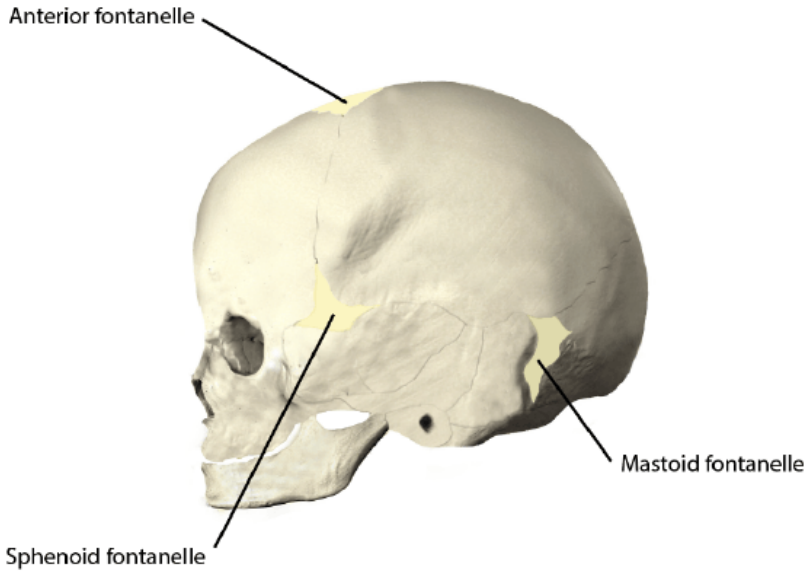

Figure 7.2.2: Fontanelles. The fontanelles are found in the fetal and infant skull at locations where three or more bones will later meet and form sutures between them. *(Image credit: "Fetal Skull Lateral View" by Mark Schaeffer is licensed under CC BY-NC-SA 4.0.)*

During birth, the fontanelles provide flexibility to the skull, allowing the bones to push closer together or to overlap slightly, thus aiding movement of the infant's head through the birth canal. After birth, these expanded regions of connective tissue allow for rapid growth of the skull and enlargement of the brain. The fontanelles greatly decrease in width during the first year after birth as the skull bones enlarge. When the connective tissue between the adjacent bones is reduced to a narrow layer, these fibrous

joints are now called sutures. At some sutures, the connective tissue will ossify and be converted into bone, causing the adjacent bones to fuse to each other. This fusion between bones is called a **synostosis** (“joined by bone”). Examples of synostosis fusions between cranial bones are found both early and late in life. At the time of birth, the frontal and maxillary bones consist of right and left halves joined together by sutures, which disappear by the eighth year of life as the halves fuse together to form a single bone. Late in life, the sagittal, coronal, and lambdoid sutures of the skull will begin to ossify and fuse, causing the suture line to gradually disappear.

Syndesmosis

A **syndesmosis** (“fastened with a band”) is a type of fibrous joint in which two parallel bones are united to each other by fibrous connective tissue. The gap between the bones may be narrow, with the bones joined by ligaments, or the gap may be wide and filled in by a broad sheet of connective tissue called an **interosseous membrane**.

In the forearm, the wide gap between the shaft portions of the radius and ulna bones are strongly united by the antebrachial interosseous membrane (Figure 7.2.3) . Similarly, in the leg, the shafts of the tibia and fibula are also united by the interosseous membrane. In addition, at the distal tibiofibular joint, the articulating surfaces of the bones lack cartilage and the narrow gap between the bones is anchored by fibrous connective tissue and ligaments on both the anterior and posterior aspects of the joint. Together, the interosseous membrane and these ligaments form the tibiofibular syndesmosis.

The syndesmoses found in the forearm and leg serve to unite parallel bones and prevent their separation. However, a syndesmosis does not prevent all movement between the bones, and thus this type of fibrous joint is functionally classified as an amphiarthrosis. In the leg, the syndesmosis between the tibia and fibula strongly unites the bones, allows for little movement, and firmly locks the talus bone in place between the tibia and fibula at the ankle joint. This provides strength and stability to the leg and ankle, which are important during weight bearing. In the forearm, the interosseous membrane is flexible enough to allow for rotation of the radius bone during forearm movements. Thus in contrast to the stability provided by the tibiofibular syndesmosis, the flexibility of the antebrachial interosseous membrane allows for the much greater mobility of the forearm.

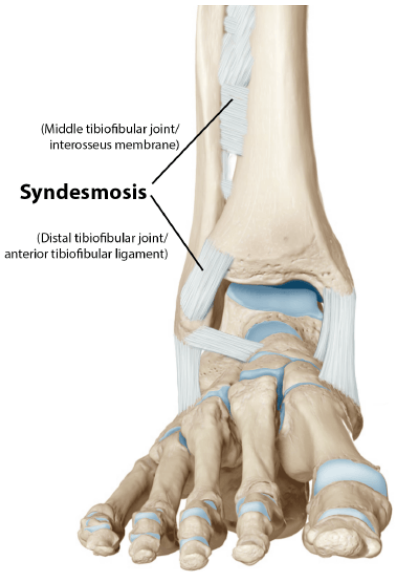

Figure 7.2.3: Syndesmosis. Two syndesmosis joints are found in the leg: the middle and distal tibiofibular joints. Both are thick bands of dense regular connective tissue that help to provide stability to the lower limb. *(Image credit: "Syndesmosis Joints of the Leg" by Justin Greene is licensed under CC BY-NC-SA 4.0, modification of image from Anatomy Standard.)*

The interosseous membranes of the leg and forearm also provide areas for muscle attachment. Damage to a syndesmotic joint, which usually results from a fracture of the bone with an accompanying tear of the interosseous membrane, will produce pain, loss of stability of the bones, and may damage the muscles attached to the interosseous membrane. If the fracture site is not properly immobilized with a cast or splint, contractile activity by these muscles can cause improper alignment of the broken bones during healing.

Gomphosis

A **gomphosis** (“fastened with bolts”) is the specialized fibrous joint that anchors the root of a tooth into its bony socket within the maxilla (upper jaw) or mandible (lower jaw) bones of the skull. A gomphosis is also known as a peg-and-socket joint. Spanning between the bony walls of the socket and the root of the tooth are numerous short bands of dense fibrous connective tissue, called the a **periodontal ligament** (Figure 7.2.4). Due to the immobility of a gomphosis, this type of joint is functionally classified as a synarthrosis.

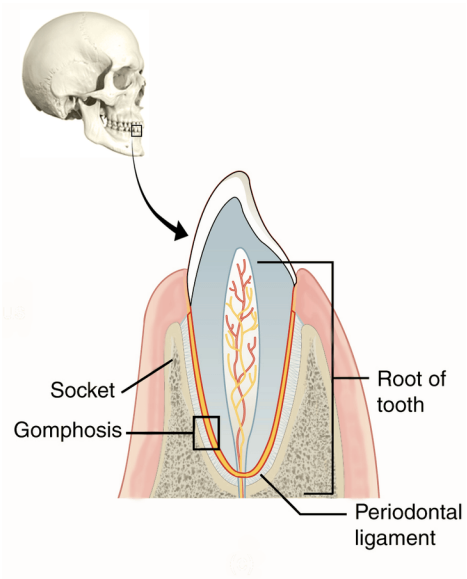

Figure 7.2.4: Gomphosis. A gomphosis is a specialized fibrous joint that anchors a tooth to its socket in the jaw. *(Image credit: "Gomphosis" by Jennifer Lange is licensed under CC BY-NC-SA 4.0, modification of original by OpenStax, skull inset by Anatomy Standard.)*

Cartilaginous Joints

As the name indicates, at a cartilaginous joint, the adjacent bones are united by cartilage, a tough but flexible type of connective tissue. These types of joints lack a joint cavity and involve bones that are joined together by either hyaline cartilage or fibrocartilage. There are two types of cartilaginous joints. A **synchondrosis** is a cartilaginous joint where the bones are joined by hyaline cartilage. Also classified as a synchondrosis are places where bone is united to a cartilage structure, such as between the anterior end of a rib and the costal cartilage of the thoracic cage. The second type of cartilaginous joint is a **symphysis**, where the bones are joined by fibrocartilage.

Synchondrosis

A **synchondrosis** (“joined by cartilage”) is a cartilaginous joint where bones are joined together by hyaline cartilage, or where bone is united to hyaline cartilage. A synchondrosis may be temporary or permanent. A temporary synchondrosis is the epiphyseal plate (growth plate) of a growing long bone (Figure 7.2.5). The epiphyseal plate is the region of growing hyaline cartilage that unites the diaphysis (shaft) of the bone to the epiphysis (end of the bone). Bone lengthening involves growth of the epiphyseal plate cartilage and its replacement by bone, which adds to the diaphysis. For many years during childhood growth, the rates of cartilage growth and bone formation are equal and thus the epiphyseal plate does not change in overall thickness as the bone lengthens. During the late teens and early 20s, growth of the cartilage slows and eventually stops. The epiphyseal plate is then completely replaced by bone, and the diaphysis and epiphysis portions of the bone fuse together to form a single adult bone. This fusion of the diaphysis and epiphysis is a synostosis. Once this occurs, bone lengthening ceases. For this reason, the epiphyseal plate is considered to be a temporary synchondrosis. Because cartilage is softer than bone tissue, injury to a growing long bone can damage the epiphyseal plate cartilage, thus stopping bone growth and preventing additional bone lengthening.

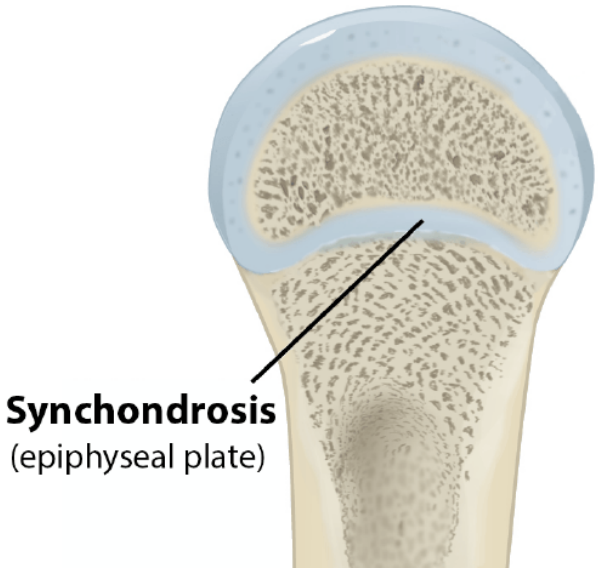

Figure 7.2.5: Synchondrosis - Epiphyseal Plate. The hyaline cartilage of the epiphyseal plate (growth plate) forms a synchondrosis that unites the shaft (diaphysis) and end (epiphysis) of a long bone and allows the bone to grow in length. *(Image credit: "Synchondrosis - Epiphyseal Plate" by Jennifer Lange and Justin Greene is licensed under CC BY-NC-SA 4.0, modification of original by OpenStax.)*

Growing layers of cartilage also form synchondroses that join together the ilium, ischium, and pubic portions of the hip bone during childhood and adolescence. When body growth stops, the cartilage disappears and is replaced by bone, forming synostoses and fusing the bony components together into the single hip (coxal) bone of the adult. Similarly, synostoses unite the sacral vertebrae that fuse together to form the adult sacrum.

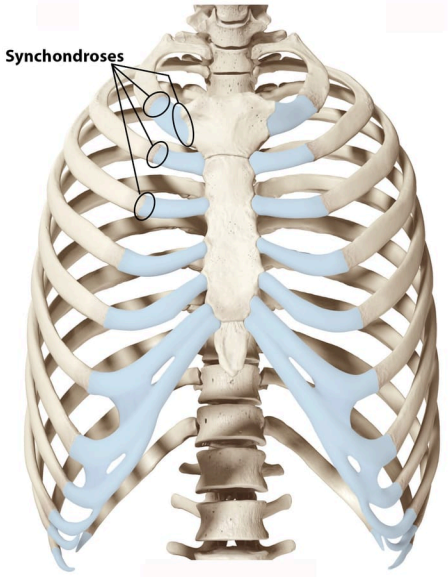

Figure 7.2.6: Synchondrosis - Costochondral Joints and Sternocostal Joint #1. The hyaline cartilage framework for the anteromedial portion of the ribs remains in an adult, so the junction between the bone of the rib and the cartilage of the costal cartilages is a snychondrosis joint. *(Image credit: "Synchondroses of Thoracic Cage" by Jennifer Lange is licensed under CC BY-NC-SA 4.0, modification of image from Anatomy Standard under CC BY-NC 4.0.)*

Examples of permanent synchondroses are found in the thoracic cage (Figure 7.2.6). One example is the first sternocostal joint, where the first rib is anchored to the manubrium by its costal cartilage. (The articulations of the remaining costal cartilages to the sternum are all synovial joints.) Additional synchondroses are formed where the anterior end of the other 11 ribs is joined to its costal cartilage. Unlike the temporary synchondroses of the epiphyseal plate, these permanent synchondroses retain their hyaline cartilage and thus do not ossify with age. Due to the lack of movement between the bone and cartilage, both temporary and permanent synchondroses are functionally classified as a synarthrosis.

Symphysis

A cartilaginous joint where the bones are joined by fibrocartilage is called a **symphysis** (“growing together”). Fibrocartilage is very strong because it contains numerous bundles of thick collagen fibers, thus giving it a much greater ability to resist pulling and bending forces when compared with hyaline cartilage. This gives symphyses the ability to strongly unite the adjacent bones, but can still allow for limited movement to occur. Thus, a symphysis is functionally classified as an amphiarthrosis.

The gap separating the bones at a symphysis may be narrow or wide. Examples in which the gap between the bones is narrow include the pubic symphysis and the manubriosternal joint. At the pubic symphysis, the pubic portions of the right and left hip bones of the pelvis are joined together by fibrocartilage across a narrow gap. Similarly, at the manubriosternal joint, fibrocartilage unites the manubrium and body portions of the sternum. The intervertebral discs have a wider gap between the bones, and the fibrocartilage here is thicker to absorb compression from our body's weight (Figure 7.2.7).

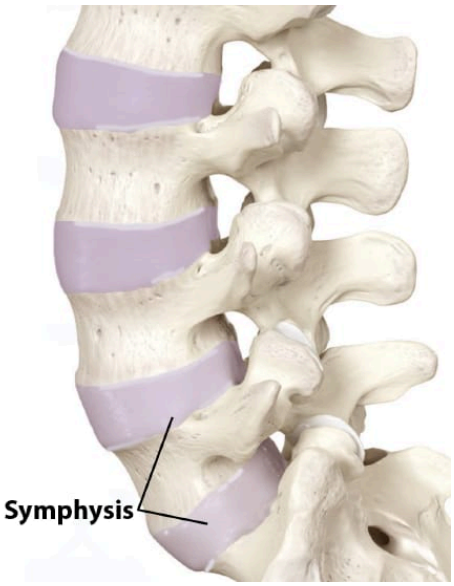

Figure 7.2.7: The bodies of adjacent vertebrae are joined together by fibrocartilage, forming symphysis joints. *(Image credit: "Symphysis Joints - Intervertebral Discs" by Jennifer Lange is licensed under CC BY-NC-SA 4.0, modification of image from Anatomy Standard under CC BY-NC 4.0.)*

The intervertebral symphysis is a wide symphysis located between the bodies of adjacent vertebrae of the vertebral column. Here, a thick pad of fibrocartilage called an intervertebral disc strongly unites the adjacent vertebrae by filling the gap between them. The width of the intervertebral symphysis is important because it allows for small movements between the adjacent vertebrae. In addition, the thick intervertebral disc provides cushioning between the vertebrae, which is important when carrying heavy objects or during high-impact activities such as running or jumping.

Functional Classification of Joints

The functional classification of joints is determined by the amount of mobility found between the adjacent bones. The amount of movement available at a particular joint of the body is related to the functional requirements for that joint. Thus immobile or slightly moveable joints serve to protect internal organs, give stability to the body, and allow for limited body movement. In contrast, freely moveable joints allow for much more extensive movements of the body and limbs. Joints are thus functionally classified as

- a **synarthrosis** or immobile joint,
- an **amphiarthrosis** or slightly moveable joint, or
- a **diarthrosis**, which is a freely moveable joint.

Depending on their location, fibrous joints may be functionally classified as a synarthrosis or an amphiarthrosis. Cartilaginous joints are also functionally classified as either a synarthrosis or an amphiarthrosis joint. All synovial joints are functionally classified as a diarthrosis joint.

Synarthrosis

An immobile or nearly immobile joint is called a **synarthrosis**. The immobile nature of these joints provides for a strong union between the articulating bones. This is important at locations where the bones provide protection for internal organs. Examples include sutures, such as the coronal, squamous, and lambdoid sutures, which are the fibrous joints between the bones of the skull, and the manubriosternal joint (Figure 7.2.8) that unites the manubrium and body of the sternum for protection of the heart.

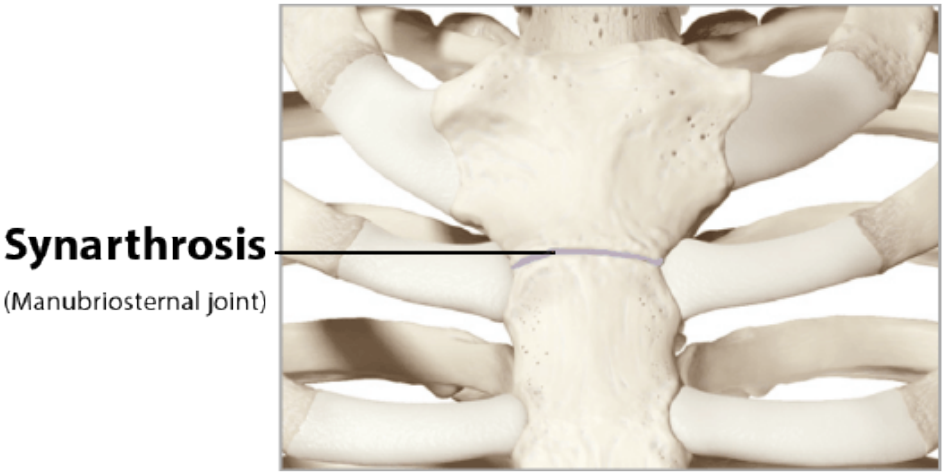

Figure 7.2.8: Synarthrosis - Manubriosternal Joint. The joint between the manubrium and the body of the sternum is an example of a synarthrosis, an immobile or essentially immobile joint. This joint is a synchondrosis that may ossify late in life. *(Image credit: "Synarthrosis - Manubriosternal Joint" by Jennifer Lange is licensed under CC BY-NC-SA 4.0, modification of image from Anatomy Standard under CC BY-NC 4.0.)*

Amphiarthrosis

An **amphiarthrosis** is a joint that has limited mobility but slight movement is available in many directions. An example of this type of joint is the cartilaginous joint that unites the bodies of adjacent vertebrae. Filling the gap between the vertebrae is a thick pad of fibrocartilage called an intervertebral disc. Each intervertebral disc strongly unites the vertebrae but still allows for a limited amount of movement between them. However, the small movements available between adjacent vertebrae can sum together along the length of the vertebral column to provide for large ranges of body movements.

Another example of an amphiarthrosis is the pubic symphysis of the pelvis (Figure 7.2.9). This is a cartilaginous joint in which the pubic regions of the right and left hip bones are strongly anchored to each other by fibrocartilage. This joint normally has very little mobility because the strength of the pubic symphysis is important in conferring weight-bearing stability to the pelvis. During childbirth this joint loosens so the pelvis can shift to adjust to the fetus passing through the pelvic outlet. Following birth, the joint should tighten again.

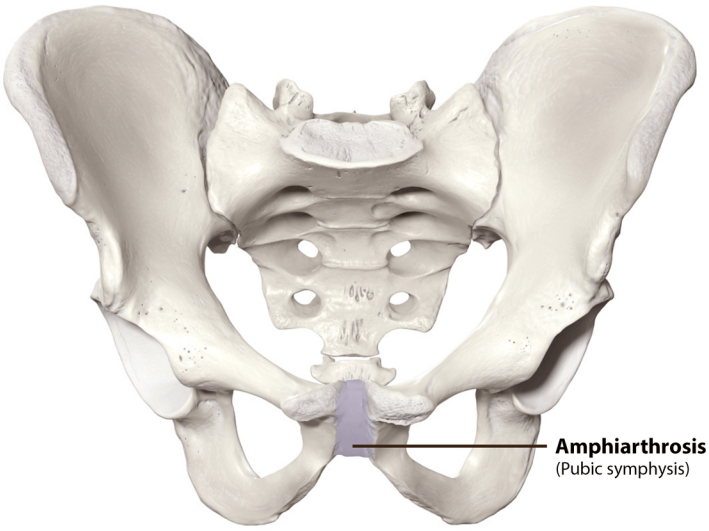

Figure 7.2.9: Amphiarthrosis - Pubic Symphysis. The fibrocartilage joining the right and left symphyseal surfaces allows for limited movement between the right and left os coxae and thus functionally forms an amphiarthrosis type of joint. *(Image credit: "Amphiarthrosis - Pubic Symphysis" by Jennifer Lange is licensed under CC BY-NC-SA 4.0, modification of image from Anatomy Standard.)*

Diarthrosis

A freely mobile joint is classified as a **diarthrosis**. These types of joints include all synovial joints (structural classification) of the body, which provide the majority of body movements. Most diarthrotic joints are found in the appendicular skeleton and thus give the limbs a wide range of motion. These joints are divided into three categories, based on the number of axes of motion provided by each. An axis in anatomy is described as the movements in reference to the three anatomical planes: transverse, frontal, and sagittal. Thus, diarthroses are classified as uniaxial (for movement in one plane), biaxial (for movement in two planes), or multiaxial joints (for movement in all three anatomical planes).

- A **uniaxial joint** only allows for a motion in a single plane (around a single axis). The elbow joint, which only allows for bending or straightening, is an example of a uniaxial joint.
- A **biaxial joint** allows for motions within two planes. An example of a biaxial joint is a metacarpophalangeal joint (knuckle joint) of the hand. The joint allows for movement along one axis to produce bending or straightening of the finger, and movement along a second axis, which allows for spreading of the fingers away from each other and bringing them together.
- A joint that allows for the several directions of movement is called a **multiaxial joint** (polyaxial or triaxial joint). This type of diarthrotic joint allows for movement along three axes (Figure 7.2.10). The hip joint, where the head of the femur articulates with the acetabulum of the hip bone, is a multiaxial joint. This allows the lower limb to move in an anterior-posterior direction and a medial-lateral direction. In addition, the limb can also be rotated around its long axis.

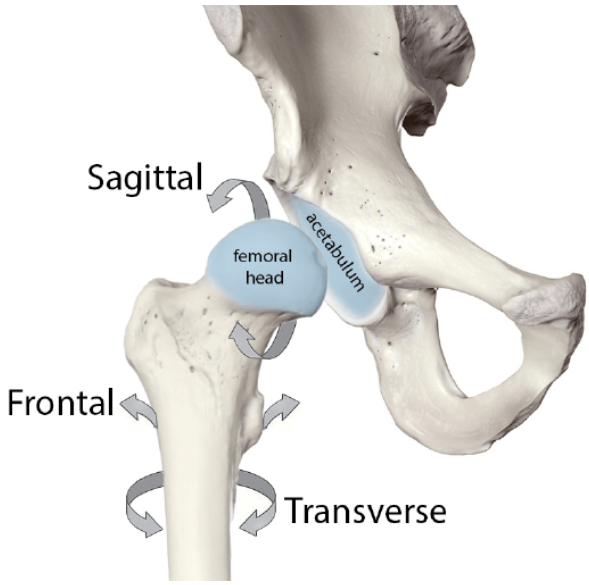

Figure 7.2.10: Diarthrosis - Multiaxial Joint. A multiaxial joint, such as the hip joint, allows for movements in each of the three planes, moving: anterior-posterior, medial-lateral, and rotational. *(Image credit: "Diarthrosis - Multiaxial Joint" by Jennifer Lange is licensed under CC BY-NC-SA 4.0, modification of image from Anatomy Standard.)*

Concept Review

Structural classifications of the body joints are based on how the bones are held together and articulate with each other. At fibrous joints, the adjacent bones are directly united to each other by dense regular connective tissue. Similarly, at a cartilaginous joint, the adjacent bones are united by cartilage. In contrast, at a synovial joint, the articulating bone surfaces are not directly united to each other, but come together within a fluid-filled joint cavity.

There are two types of cartilaginous joints.

- A synchondrosis is formed when the adjacent bones are united by hyaline cartilage.
  - Examples of synchondroses are: the epiphyseal plate of a growing long bone, the first sternocostal joint, and between the anterior ends of the bony ribs and the junction with their costal cartilage.
- A symphysis is where the bones are joined by fibrocartilage.
  - A narrow symphysis is found at the manubriosternal joint and at the pubic symphysis.
  - A wide symphysis is the intervertebral symphysis in which the bodies of adjacent vertebrae are united by an intervertebral disc.

The three types of fibrous joints are sutures, gomphoses, and syndesmoses.

- A suture is the narrow fibrous joint that unites most bones of the skull.
- At a gomphosis, the root of a tooth is anchored across a narrow gap by periodontal ligament to the walls of its socket in the bony jaw.
- A syndesmosis is the type of fibrous joint found between parallel bones. The gap between the bones may be wide and filled with a fibrous interosseous membrane, or it may narrow with ligaments spanning between the bones.
  - Syndesmoses are found between the bones of the forearm (radius and ulna) and the leg (tibia and fibula).

The most common type of joint is the diarthrosis, which is a freely moveable joint. All synovial joints are functionally classified as diarthroses.

- A uniaxial diarthrosis, such as the elbow, is a joint that only allows for movement within a single anatomical plane.
- Joints that allow for movements in two planes are biaxial joints, such as the metacarpophalangeal joints of the fingers.
- A multiaxial joint, such as the shoulder or hip joint, allows for three planes of motions.

The **functional classification** of body joints is based on the degree of movement found at each joint.

- A synarthrosis is a joint that is essentially immobile.
  - Examples include the fibrous joints of the skull sutures and the cartilaginous manubriosternal joint.
- A joint that allows for limited movement is an amphiarthrosis.
  - An example is the pubic symphysis of the pelvis, the cartilaginous joint that strongly unites the right and left hip bones of the pelvis.
  - The cartilaginous joints in which vertebrae are united by intervertebral discs provide for small movements between the adjacent vertebrae and are also an amphiarthrosis type of joint.

Review Questions

Query 7.2.1

This interactive element is not available in this format. Visit the link or scan the QR code to access it online.

View this Interactive Content online

Critical Thinking Questions

Query 7.2.2

This interactive element is not available in this format. Visit the link or scan the QR code to access it online.

View this Interactive Content online

Query 7.2.3

This interactive element is not available in this format. Visit the link or scan the QR code to access it online.

View this Interactive Content online

Query 7.2.4

This interactive element is not available in this format. Visit the link or scan the QR code to access it online.

View this Interactive Content online

Query 7.2.5

This interactive element is not available in this format. Visit the link or scan the QR code to access it online.

View this Interactive Content online

Query 7.2.6

This interactive element is not available in this format. Visit the link or scan the QR code to access it online.

View this Interactive Content online

Glossary

Query 7.2.7

This interactive element is not available in this format. Visit the link or scan the QR code to access it online.

View this Interactive Content online

Contributors and Attributions

- OpenStax Anatomy & Physiology (CC BY 4.0). Access for free at https://openstax.org/books/anatomy-and-physiology

This page titled 7.2: Classification of Joints is shared under a CC BY-NC-SA 4.0 license and was authored, remixed, and/or curated by Jennifer Lange et al..

- 8.2: Classification of Joints by Whitney Menefee, Julie Jenks, Chiara Mazzasette, and Kim-Leiloni Nguyen is licensed CC BY 4.0.
- 8.3: Fibrous Joints by Whitney Menefee, Julie Jenks, Chiara Mazzasette, and Kim-Leiloni Nguyen is licensed CC BY 4.0.
- 8.4: Cartilaginous Joints by Whitney Menefee, Julie Jenks, Chiara Mazzasette, and Kim-Leiloni Nguyen is licensed CC BY 4.0.

7.3: Synovial Joints

By the end of this section, you will be able to

- Describe the structural features of a synovial joint
- Discuss the function of additional structures associated with synovial joints
- List the six types of synovial joints and give an example of each

Synovial joints are the most common type of joint in the body. A key structural characteristic for a synovial joint that is not seen at fibrous or cartilaginous joints is the presence of a joint cavity. This fluid-filled space is the site at which the articulating surfaces of the bones contact each other. Also unlike fibrous or cartilaginous joints, the articulating bone surfaces at a synovial joint are not directly connected to each other with fibrous connective tissue or cartilage. This gives the bones of a synovial joint the ability to move smoothly against each other, allowing for increased joint mobility.

Structural Features of Synovial Joints

Synovial joints are characterized by the presence of a joint cavity. The walls of this space are formed by the **articular capsule** (Figure 7.3.1). The outer layers of the capsule is the **fibrous layer** comprised of dense irregular connective tissue structure that is attached to each bone just outside the area of the bone's articulating surface. This layer of the capsule restricts bone movements and protects the more delicate underlying structures. Lining the inner surface of the articular capsule is a thin **synovial membrane**. The cells of this membrane secrete **synovial fluid** (synovia = "a thick fluid"), a thick, slimy fluid that provides lubrication to further reduce friction between the bones of the joint. This fluid also provides nourishment to the articular cartilage, which does not contain blood vessels. The ability of the bones to move smoothly against each other within the joint cavity, and the freedom of joint movement this provides, means that each synovial joint is functionally classified as a diarthrosis.

Friction between the bones at a synovial joint is prevented by the presence of the **articular cartilage**, a thin layer of hyaline cartilage that covers the entire articulating surface of each bone. However, unlike at a cartilaginous joint, the articular cartilages of each bone are not continuous with each other. Instead, the articular cartilage acts like a coating over the bone surface, allowing the articulating bones to move smoothly against each other without damaging the underlying bone tissue.

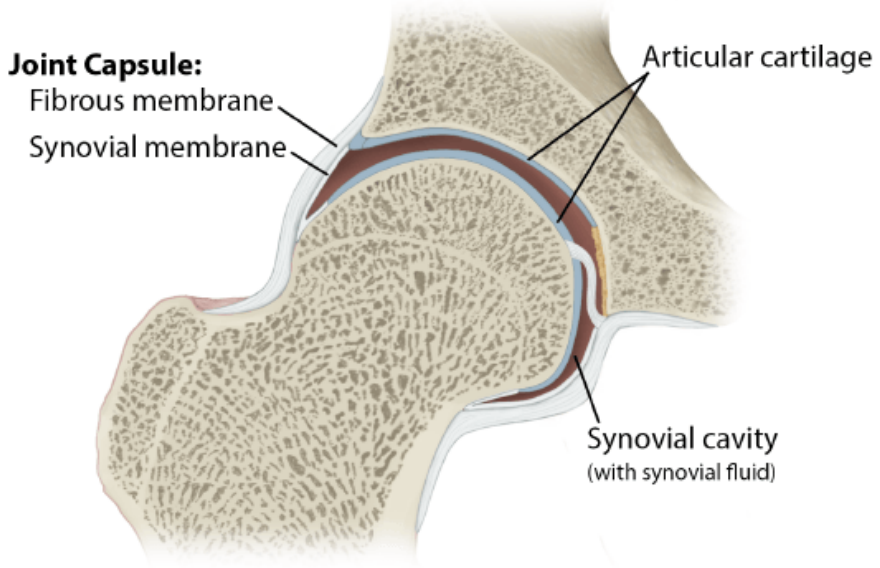

Figure 7.3.1: Synovial Joints. Synovial joints allow for smooth movements between the adjacent bones. The joint is surrounded by an articular capsule that defines a joint cavity filled with synovial fluid. The articulating surfaces of the bones are covered by a thin layer of articular cartilage. *(Image credit: "Synovial Joint Structure" by Justin Greene is licensed under CC BY-NC-SA 4.0.)*

Stabilizing Structures for Synovial Joints

To add more stability to the joint by preventing movements in specific directions, the bones are connected together by **ligaments**. These thick bands of dense regular connective tissue allow for normal movements at a joint, but limit the range of these motions, thus preventing excessive or abnormal joint movements (Figure $7.3.2a$). Ligaments are classified based on their relationship to the fibrous layer of the articular capsule:

- an **extracapsular ligament** is located outside of the articular capsule,
- a **capsular ligament** attaches to one bone and then fuses with the fibrous layer of the articular capsule, and
- an **intracapsular ligament** is located inside of the articular capsule.

At many synovial joints, additional support is provided by the muscles and their tendons that act across the joint. A **tendon** is the dense regular connective tissue structure that attaches a muscle to bone. As forces acting on a joint increase, the body will automatically increase the overall strength of contraction of the muscles crossing that joint, thus allowing the muscle and its tendon to serve as a "dynamic ligament" to resist forces and support the joint. This type of indirect support by muscles is very important at the shoulder joint, for example, where the ligaments are relatively weak.

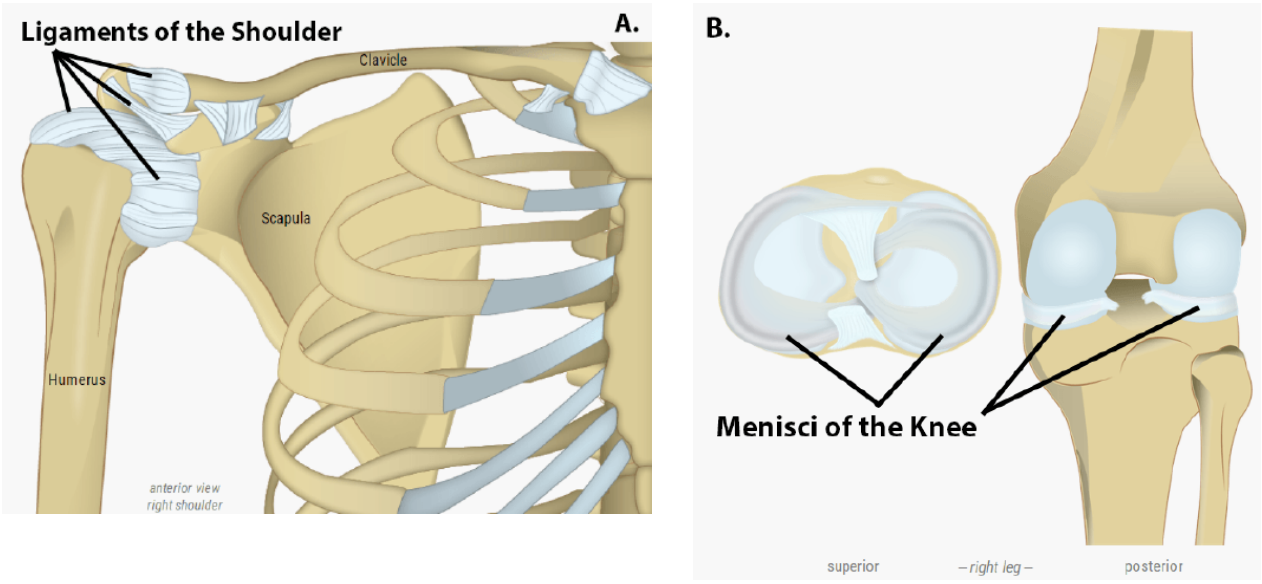

Figure $7.3.2$: Ligaments restrict the movements of joints such as the shoulder by tightening and preventing further rotation along their fiber axis. Menisci in the knee joint provide a cup-shaped cushion for the round femoral condyles to better fit the flat tibial condyles. *(Image credit: "Ligaments of the Shoulder" and "Menisci of the Knee" by Jennifer Lange are licensed under CC BY-NC-SA 4.0, based on images by University of British Columbia Clinical Anatomy.)*

A few synovial joints of the body have a fibrocartilage structure located between the articulating bones that improves the complementary fits of the two bone ends. This is called an **articular disc**, which is generally small and oval-shaped, or a **meniscus**, which is larger and C-shaped (Figure $7.3.2b$). These structures can serve several functions, depending on the specific joint. In some places, an articular disc may act to create a deeper socket, thus enlarging the articular surface. Examples of this include the labrum of the shoulder and the hip. At other synovial joints, the disc can provide shock absorption and cushioning between the bones, which is the function of each meniscus within the knee joint. Finally, an articular disc can serve to smooth the movements between the articulating bones, as seen at the temporomandibular joint. Some synovial joints also have a fat pad, which can serve as a cushion between the bones.

Additional Structures Associated with Synovial Joints

Additional structures located outside of a synovial joint serve to prevent friction between the bones of the joint and the overlying muscle tendons or skin. A **bursa** (plural = bursae) is a thin connective tissue sac filled with lubricating liquid. They are located in regions where skin, ligaments, muscles, or muscle tendons can rub against each other, usually near a synovial articulation. Bursae reduce friction by separating the adjacent structures, preventing them from rubbing directly against each other. Bursae are classified by their location. A **subcutaneous bursa** is located between the skin and an underlying bone. It allows skin to

move smoothly over the bone. Examples include the prepatellar bursa located over the kneecap (Figure 7.3.3) and the olecranon bursa at the tip of the elbow. A **submuscular bursa** is found between a muscle and an underlying bone, or between adjacent muscles. These prevent rubbing of the muscle during movements. A large submuscular bursa, the trochanteric bursa, is found at the lateral hip, between the greater trochanter of the femur and the overlying gluteus maximus muscle. A **subtendinous bursa** is found between a tendon and a bone. Examples include the subacromial bursa that protects the tendon of shoulder muscle as it passes under the acromion of the scapula, and the suprapatellar bursa that separates the tendon of the quadriceps femoris (thigh) muscle from the distal femur just above the knee (Figure 7.3.2).

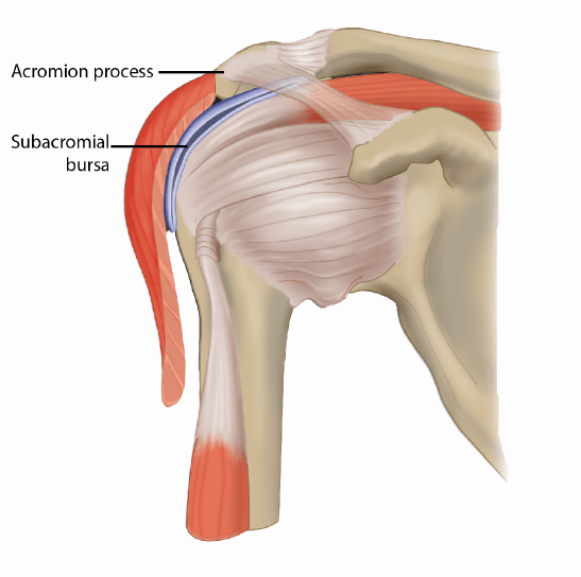

Figure 7.3.3: Subacromial Bursa. Bursae are fluid-filled sacs that serve to prevent friction between skin, muscle, or tendon and an overlying bone. The subacromial bursa of the shoulder joint protects the underlying muscle from wear and tear due to contact with the acromion process. *(Image Credit: "Subacromial Bursa" by Jennifer Lange is licensed under CC BY-NC-SA 4.0, modification of original "Slagter - Drawing Impingement of shoulder - no labels" by Ron Slagter.*

A **tendon sheath** is similar in structure to a bursa, but smaller. It is a connective tissue sac that surrounds a muscle tendon at places where the tendon crosses a joint. It contains a lubricating fluid that allows for smooth motions of the tendon during muscle contraction and joint movements.

DISORDERS OF THE ...

Joints: Bursitis

Bursitis is the inflammation of a bursa near a joint. This will cause pain, swelling, or tenderness of the bursa and surrounding area, and may also result in joint stiffness. Bursitis is most commonly associated with the bursae found at or near the shoulder, hip, knee, or elbow joints. At the shoulder, subacromial bursitis may occur in the bursa that separates the acromion of the scapula from the tendon of a shoulder muscle as it passes deep to the acromion. In the hip region, trochanteric bursitis can occur in the bursa that overlies the greater trochanter of the femur, just below the lateral side of the hip. Ischial bursitis occurs in the bursa that separates the skin from the ischial tuberosity of the pelvis, the bony structure that is weight bearing when sitting. At the knee, inflammation and swelling of the bursa located between the skin and patella bone is prepatellar bursitis (“housemaid’s knee”), a condition more commonly seen today in roofers or floor and carpet installers who do not use knee pads. At the elbow, olecranon bursitis is inflammation of the bursa between the skin and olecranon process of the ulna. The olecranon forms the bony tip of the elbow, and bursitis here is also known as “student’s elbow” (Figure 7.3.4).



Figure 7.3.4: Olecranon Bursitis. Normally this bursa provides a small fluid cushion for the tip of your elbow, but either hitting it hard or repeatedly resting on the elbow for long periods can cause inflammation. *(Image source: "Olecranon Bursitis" by Harrygouvas, is in the public domain.)*

Bursitis can be either acute (lasting only a few days) or chronic. It can arise from muscle overuse, trauma, excessive or prolonged pressure on the skin, rheumatoid arthritis, gout, or infection of the joint. Repeated acute episodes of bursitis can result in a chronic condition. Treatments for the disorder include antibiotics if the bursitis is caused by an infection, or anti-inflammatory agents, such as nonsteroidal anti-inflammatory drugs (NSAIDs) or corticosteroids if the bursitis is due to trauma or overuse. Chronic bursitis may require that fluid be drained, but additional surgery is usually not required.

Types of Synovial Joints

Synovial joints are subdivided based on the shapes of the articulating surfaces of the bones that form each joint. These shapes give rise to the type of movements they permit - if the bones run into each other, movement in that plane cannot occur. The six types of synovial joints are pivot, hinge, saddle, plane, condyloid, and ball-and-socket-joints (Figure 7.3.5) .

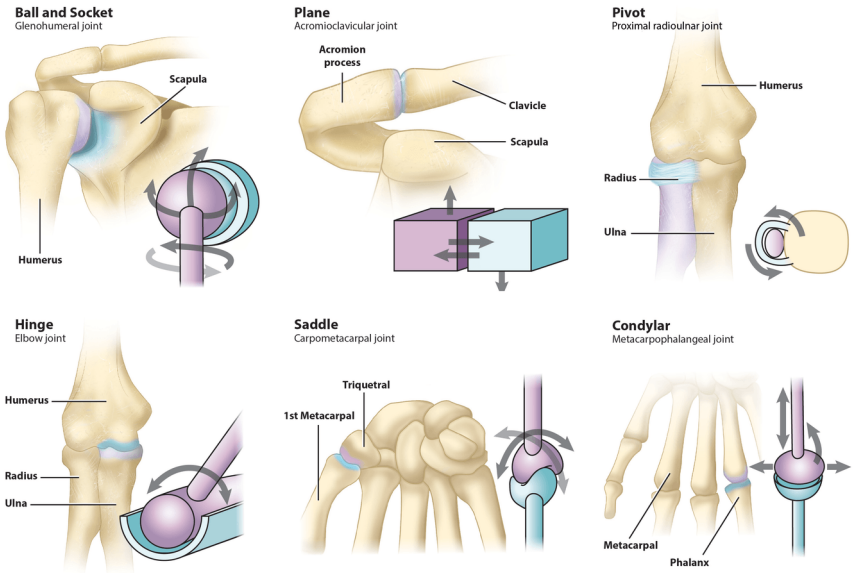

Figure 7.3.5: Types of Synovial Joints. The six types of synovial joints allow the body to move in a variety of ways that are determined by the fit (shape) of the two bones. *(Image credit: "Synovial Joints" by BlueLink is licensed under CC BY-NC 4.0 with notification of the original authors; modifications by Jennifer Lange.)*

When describing anatomical motion, an action is performed within (parallel to) one of the three anatomical planes: sagittal, frontal, transverse. Each joint has an axis of rotation that is a straight line running parallel to the plane of movement around which an object rotates. Movement at the joint takes place in a plane about an axis. There are three axes of rotation:

- **Anterior-Posterior Axis:** Imagine a pin that runs through the shoulder joint from front to back (anteriorly and posteriorly). The pin becomes the axis of rotation. Because of the pin's position, the only movement the shoulder could do about this axis is lateral/medial movement in the frontal plane.
- **Medial-Lateral Axis:** Mediolateral means the imaginary pin is inserted into the shoulder from a sideways (lateral) approach. The axis runs from the medial side of the joint to the lateral side. The position of the pin allows only movements toward the front or back (anterior and posterior) in the sagittal plane.
- **Longitudinal Axis** - In this case the pin passes vertically through the shoulder joint and into the length of the humerus. Because the pin runs through the joint from top to bottom, it would effectively prevent the arm from moving forward, backward, or side-to-side. The only movement it will allow is twisting in the transverse plane (i.e., rotation).

Ball-and-Socket Joint

The joint with the greatest range of motion is the **ball-and-socket joint**. At these joints, the rounded head of one bone (the ball) fits into the concave articulation (the socket) of the adjacent bone (Figure $7.3.5$) . The coxafemoral joint (hip) and the glenohumeral (shoulder) joint are the only ball-and-socket joints of the body. At the hip joint, the head of the femur articulates with the acetabulum of the hip bone, and at the shoulder joint, the head of the humerus articulates with the glenoid cavity of the scapula.Ball-and-socket joints are classified functionally as multiaxial joints. The femur and the humerus are able to move in both anterior-posterior and medial-lateral directions and they can also rotate around their long axis. The shallow socket formed by the glenoid cavity allows the shoulder joint an extensive range of motion. In contrast, the deep socket of the acetabulum and the strong supporting ligaments of the hip joint serve to constrain movements of the femur, reflecting the need for stability and weight-bearing ability at the hip.

Plane Joint

At a **plane joint**, also known as a gliding joint, the articulating surfaces of the bones are flat or slightly curved and of approximately the same size, which allows the bones to slide against each other (Figure $7.3.5$) . The motion at this type of joint is usually small and tightly constrained by surrounding ligaments. Based only on their shape, plane joints can allow multiple movements, including rotation. Thus plane joints can be functionally classified as a multiaxial joint. However, not all of these movements are available to every plane joint due to limitations placed on it by ligaments or neighboring bones. Thus, depending upon the specific joint of the body, a plane joint may exhibit only a single type of movement or several movements. Plane joints are found between the carpal bones (intercarpal joints) of the wrist or tarsal bones (intertarsal joints) of the foot, between the clavicle and acromion of the scapula (acromioclavicular joint), and between the superior and inferior articular processes of adjacent vertebrae (zygapophysial joints).

Pivot Joint

At a **pivot joint**, a rounded portion of a bone is enclosed within a ring formed partially by the articulation with another bone and partially by a ligament (Figure $7.3.5$) . The bone rotates within this ring. Since the rotation is around a single axis, pivot joints are functionally classified as a uniaxial type of joint. An example of a pivot joint is the atlantoaxial joint, found between the C1 (atlas) and C2 (axis) vertebrae. Here, the upward projecting dens of the axis articulates with the inner aspect of the atlas, where it is held in place by the transverse ligament. Rotation at this joint allows you to turn your head from side to side. A second pivot joint is found at the **proximal radioulnar joint**. Here, the head of the radius is largely encircled by a ligament that holds it in place as it articulates with the radial notch of the ulna. Rotation of the radius allows for forearm movements.

Hinge Joint

In a **hinge joint**, the bar-shaped convex end of one bone articulates with the concave end of the adjoining bone (Figure $7.3.5$) . This type of joint allows only for bending and straightening motions along a single axis, and thus hinge joints are functionally classified as uniaxial joints. the slightly-rounded end of one bone fits into the slightly-hollow end of the other bone. In this way, one bone moves while the other remains stationary, similar to the hinge of a door. A good example is the elbow joint, with the articulation between the trochlea of the humerus and the trochlear notch of the ulna. Other hinge joints of the body include the knee, ankle, and interphalangeal joints between the phalanx bones of the fingers and toes.

Saddle Joint

Saddle joints are so named because both of the articulating surfaces for the bones have a saddle shape (U-shaped), which is concave in one direction and convex in the other (Figure 7.3.5). Saddle joints are functionally classified as biaxial joints. The primary example is the first carpometacarpal joint, between the trapezium (a carpal bone) and the first metacarpal bone at the base of the thumb. This joint provides the thumb the ability to move away from the palm of the hand along two planes. Thus, the thumb can move within the same plane as the palm of the hand, or it can jut out anteriorly, perpendicular to the palm. This movement of the first carpometacarpal joint is what gives humans their distinctive “opposable” thumbs. The sternoclavicular joint is also classified as a saddle joint.

Condylar Joint

At a **condylar joint**, also known as an condyloid joint, the shallow depression at the end of one bone articulates with a rounded structure from an adjacent bone or bones (Figure 7.3.5), similar to a ball and socket joint. However, the condylar joint surfaces are oval as opposed to round. The knuckle (metacarpophalangeal) joints of the hand between the distal end of a metacarpal bone and the proximal phalanx bone are condyloid joints. Another example is the radiocarpal joint of the wrist, between the shallow depression at the distal end of the radius bone and the rounded scaphoid, lunate, and triquetrum carpal bones. Functionally, condyloid joints are biaxial joints that allow for two planes of movement - sagittal and frontal. One movement involves the bending and straightening of the fingers or the anterior-posterior movements of the hand. The second movement is a side-to-side movement, which allows you to spread your fingers apart and bring them together, or to move your hand in a medial-going or lateral-going direction. Transverse plane movement, twisting, is prevented by oval shape of the articular surfaces. An oval has two axes - a long axis and a short axis - on both the convex and concave surfaces. When attempting to twist the long axis will run into the opposing bone's short axis, which stops the movement.

Concept Review

Synovial joints are the most common type of joints in the body. They are characterized by the presence of a joint cavity, inside of which the bones of the joint articulate with each other. The articulating surfaces of the bones at a synovial joint are not directly connected to each other by connective tissue or cartilage, which allows the bones to move freely against each other. The walls of the joint cavity are formed by the articular capsule. Friction between the bones is reduced by a thin layer of articular cartilage covering the surfaces of the bones, and by a lubricating synovial fluid, which is secreted by the synovial membrane.

Synovial joints are strengthened by the presence of ligaments, which hold the bones together and resist excessive or abnormal movements of the joint. Ligaments are classified as extrinsic ligaments if they are located outside of the articular capsule, intrinsic ligaments if they are fused to the wall of the articular capsule, or intracapsular ligaments if they are located inside the articular capsule. Some synovial joints also have an articular disc (meniscus), which can provide padding between the bones, smooth their movements, or strongly join the bones together to strengthen the joint. Muscles and their tendons acting across a joint can also increase their contractile tension when needed, thus providing indirect support for the joint.

Bursae contain a lubricating fluid that serves to reduce friction between structures. Subcutaneous bursae prevent friction between the skin and an underlying bone, submuscular bursae protect muscles from rubbing against a bone or another muscle, and a subtendinous bursa prevents friction between bone and a muscle tendon. Tendon sheaths contain a lubricating fluid and surround tendons to allow for smooth movement of the tendon as it crosses a joint.

Based on the shape of the articulating bone surfaces and the types of movement allowed, synovial joints are classified into six types.

Synovial Joint Type	Number of Axes of Rotation	Planes of Movement	Examples
Plane	none - gliding only	varies	intercarpal, intertarsal, patellofemoral, acromioclavicular, intervertebral facets
Hinge	1	sagittal	elbow, knee, ankle, interphalangeal
Pivot	1	transverse	proximal radioulnar, atlantoaxial

Saddle	2	sagittal, frontal	carpometacarpal #1, sternoclavicular
Condylar	2	sagittal, frontal	wrist, metacarpophalangeal #2-5, atlanto-occipital
Ball & Socket	3	sagittal, frontal, transverse	shoulder (glenohumeral), hip

Review Questions

Query 7.3.1

This interactive element is not available in this format. Visit the link or scan the QR code to access it online.

View this Interactive Content online

Query 7.3.2

This interactive element is not available in this format. Visit the link or scan the QR code to access it online.

View this Interactive Content online

Critical Thinking Questions

Query 7.3.3

This interactive element is not available in this format. Visit the link or scan the QR code to access it online.

View this Interactive Content online

Query 7.3.4

This interactive element is not available in this format. Visit the link or scan the QR code to access it online.

View this Interactive Content online

Glossary

Query 7.3.5

This interactive element is not available in this format. Visit the link or scan the QR code to access it online.

View this Interactive Content online

Contributors and Attributions

- OpenStax Anatomy & Physiology (CC BY 4.0). Access for free at https://openstax.org/books/anatomy-and-physiology

This page titled 7.3: Synovial Joints is shared under a CC BY-NC-SA 4.0 license and was authored, remixed, and/or curated by Jennifer Lange et al..

- 8.5: Synovial Joints by Whitney Menefee, Julie Jenks, Chiara Mazzasette, and Kim-Leiloni Nguyen is licensed CC BY 4.0.

7.4: Types of Body Movements

By the end of this section, you will be able to

- Define the different types of body movements
- Identify the joints that allow for these motions

Synovial joints allow the body a tremendous range of movements. Each movement at a synovial joint results from the contraction or relaxation of the muscles that are attached to the bones on either side of the articulation. The type of movement that can be produced at a synovial joint is determined by its structural type. While the ball-and-socket joint gives the greatest range of movement at an individual joint, in other regions of the body, several joints may work together to produce a particular movement. Overall, each type of synovial joint is necessary to provide the body with its great flexibility and mobility. There are many types of movement that can occur at synovial joints (Table 7.4.1). Movement types are generally paired, with one being the opposite of the other. Body movements are always described in relation to the anatomical position of the body: upright stance, with upper limbs to the side of body and palms facing forward.

Planar Movements

The most common movements that our joints can do see that part of the body move in a motion parallel to one of the three body planes:

- sagittal plane movements - part moves in an anterior or posterior direction
- frontal plane movements - part moves in a medial or lateral direction
- transverse plane movements - a twisting movement

Sagittal Plane - Flexion and Extension

Flexion and **extension** are movements that take place within the sagittal plane and involve anterior or posterior movements of the trunk or limbs.

In the limbs, flexion decreases the angle between the bones (bending of the joint), while extension increases the angle and straightens the joint. For the upper limb, all anterior-going motions are flexion and all posterior-going motions are extension. These include anterior-posterior movements of the arm at the shoulder, the forearm at the elbow, the hand at the wrist, and the fingers at the metacarpophalangeal and interphalangeal joints. For the thumb, extension moves the thumb away from the palm of the hand, within the same plane as the palm, while flexion brings the thumb back against the index finger or into the palm. These motions take place at the first carpometacarpal joint. In the lower limb, bringing the thigh forward and upward is flexion at the hip joint, while any posterior-going motion of the thigh is extension. Note that extension of the thigh beyond the anatomical (standing) position is greatly limited by the ligaments that support the hip joint. Knee flexion is the bending of the knee to bring the foot toward the posterior thigh, and extension is the straightening of the knee. Flexion and extension movements are seen at the hinge, condyloid, saddle, and ball-and-socket joints of the limbs (Figure 7.4.1).

For the vertebral column, sagittal plane movements keep the inferior portion of the body stable and the superior portion moves in an anterior or posterior direction. Again, flexion is an anterior bending while extension involves a posterior-directed motion, such as straightening from a flexed position or bending backward (Figure 7.4.1). These movements occur in both the cervical and lumbar regions of the vertebral column and involve both the symphysis joint formed by each intervertebral disc, as well as the plane type of synovial joint formed between the inferior articular processes of one vertebra and the superior articular processes of the next lower vertebra.

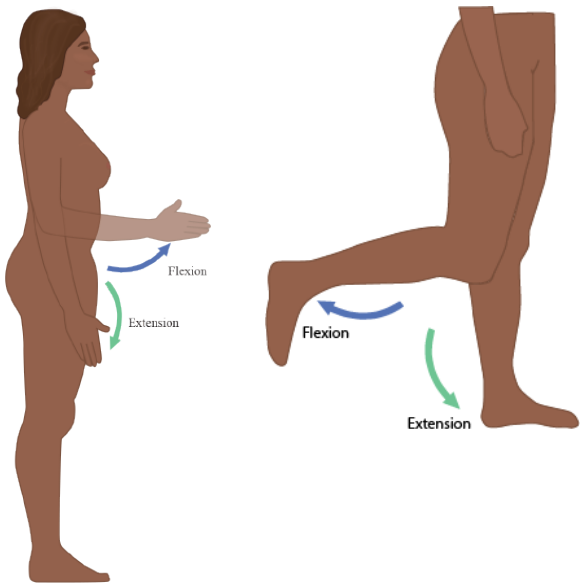

Figure 7.4.1: Movements of the Body - Flexion and Extension. Flexion and extension are opposing movements that are in the sagittal (anterior–posterior) plane of motion. These movements take place at the intervertebral, shoulder, hip, elbow, knee, wrist, metacarpophalangeal, metatarsophalangeal, and interphalangeal joints. *(Image credit: "Flexion and Extension" by Sophia Elizondo is licensed under CC BY-NC-SA 4.0.)*

Hyperextension is the abnormal or excessive extension of a joint beyond its normal range of motion, thus resulting in injury. Similarly, **hyperflexion** is excessive flexion at a joint. Hyperextension injuries are common at hinge joints such as the knee or elbow. In cases of "whiplash" in which the head is suddenly moved backward and then forward, a patient may experience both hyperextension and hyperflexion of the cervical region.

Frontal Plane - Lateral Flexion, Abduction and Adduction

Abduction and **adduction** motions occur within the frontal (coronal) plane and involve medial-lateral motions of the limbs. Abduction moves the limb laterally away from the midline of the body, while adduction is the opposing movement that brings the limb toward the body midline or across the midline. For example, abduction is raising the arm at the shoulder joint, moving it laterally away from the body, while adduction brings the arm down to the side of the body. Similarly, abduction and adduction at the wrist moves the hand away from or toward the midline of the body. Spreading the fingers or toes apart is also abduction, while bringing the fingers or toes together is adduction. For the thumb, abduction is the anterior movement that brings the thumb to a 90° perpendicular position, pointing straight out from the palm. Adduction moves the thumb back to the anatomical position, next to the index finger. Abduction and adduction movements are seen at joints with more than a single axis of rotation - condyloid, saddle, and ball-and-socket joints (Figure 7.4.2) .

Lateral flexion is the bending of the neck or trunk toward the right or left, moving either away from or closer to the midline. Just like with other movements, lateral flexion right and lateral flexion left are opposing movements. If you tilt your head toward your left shoulder this is lateral flexion left; moving your head back to center is lateral flexion right.

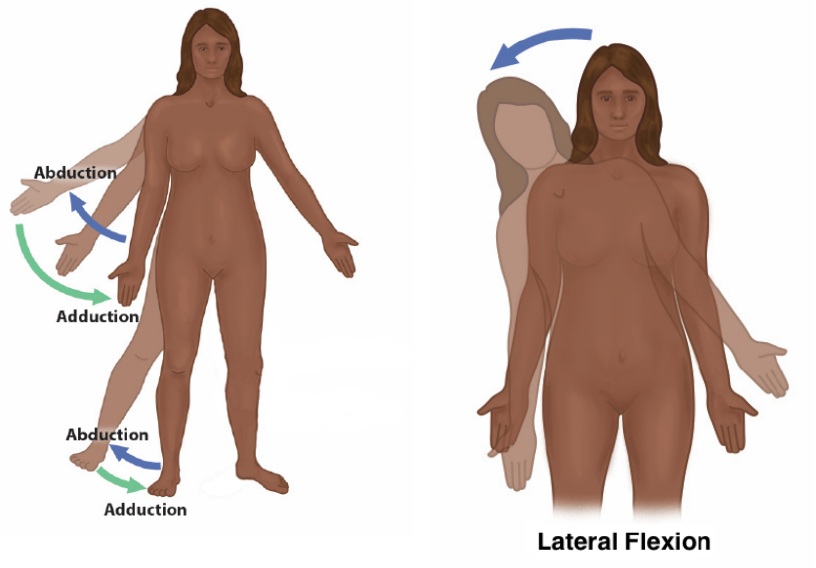

Figure 7.4.2: Movements of the Body - Adduction, Abduction and Lateral Flexion. Adduction and Abduction are opposing movements that are in the frontal (medial-lateral) plane of motion. These movements take place at the shoulder, hip, wrist, and metacarpophalangeal joints. When the motion is occurring at the intervertebral joints this movement is called lateral flexion to the right or to the left. *(Image credit: "Movements" by BlueLink is licensed under CC BY-NC 4.0 with notification of the original authors, modifications by Jennifer Lange.)*

Rotation

Rotation can occur within the vertebral column, at a pivot joint, or at a ball-and-socket joint. Rotation of the neck or body is the twisting movement produced by the summation of the small rotational movements available between adjacent vertebrae. At a pivot joint, one bone rotates in relation to another bone. This is a uniaxial joint, and thus rotation is the only motion allowed at a pivot joint. For example, at the atlantoaxial joint, the first cervical (C1) vertebra (atlas) rotates around the dens, the upward projection from the second cervical (C2) vertebra (axis). This allows the head to rotate from side to side as when shaking the head "no." The proximal radioulnar joint is a pivot joint formed by the head of the radius and its articulation with the ulna. This joint allows for the radius to rotate along its length during pronation and supination movements of the forearm (Figure 7.4.3).

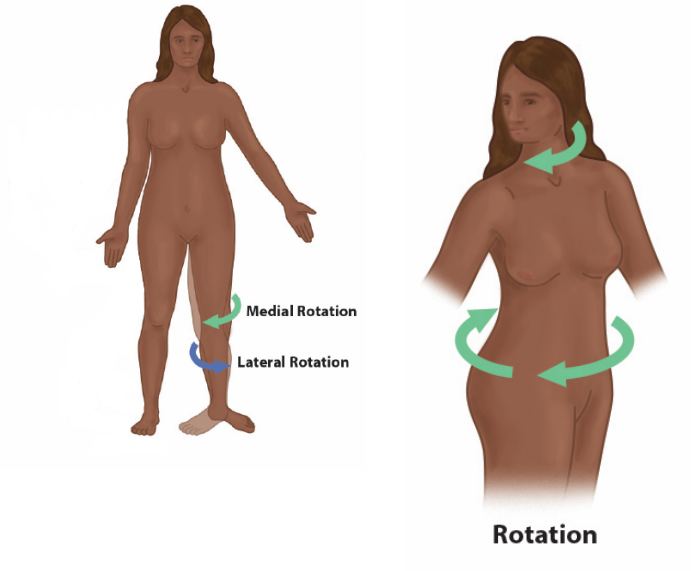

Figure 7.4.3: Movements of the Body - Rotations. Medial rotation and lateral rotation are opposing movements that are in the transverse plane of motion. These movements are twisting motions that take place at the shoulder and hip joints. When the motion is occurring at the intervertebral joints this movement is called lateral rotation to the right or to the left. *(Image credit: "Movements" by BlueLink is licensed under CC BY-NC 4.0 with notification of the original authors, modifications by Jennifer Lange.)*

Rotation can also occur at the ball-and-socket joints of the shoulder and hip. Here, the humerus and femur rotate around their long axis, which moves the anterior surface of the arm or thigh either toward or away from the midline of the body. Movement that brings the anterior surface of the limb toward the midline of the body is called **medial (internal) rotation**. Conversely, rotation of the limb so that the anterior surface moves away from the midline is **lateral (external) rotation** (Figure 7.4.3). Be sure to distinguish medial and lateral rotation, which can only occur at the multiaxial shoulder and hip joints, from circumduction, which can occur at either biaxial or multiaxial joints.

Non-planar or Special Movements

Circumduction

Circumduction is the movement of a body region in a circular manner, in which one end of the body region being moved stays relatively stationary while the other end describes a circle. It involves the sequential combination of flexion, adduction, extension, and abduction at a joint. This type of motion is found at biaxial condyloid and saddle joints, and at multiaxial ball-and-sockets joints (Figure 7.4.4).

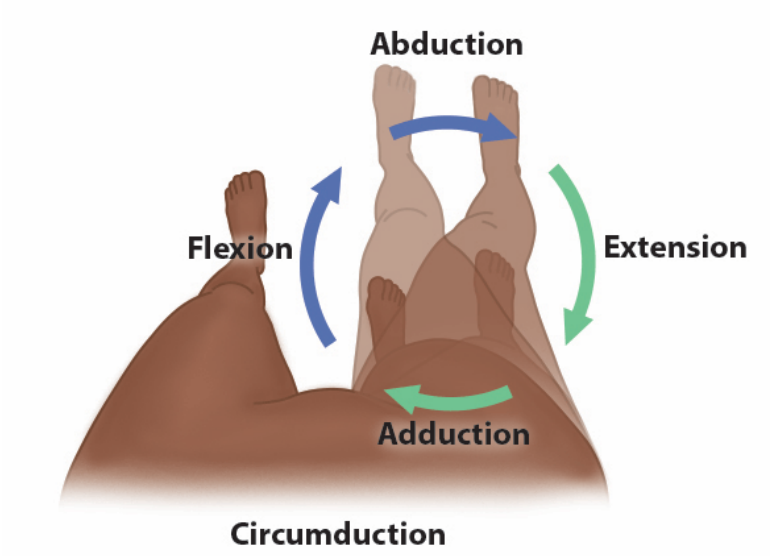

Figure 7.4.4: Movements of the Body - Circumduction. Circumduction is actually a combination of movements that cross multiple planes. This motion can only take place at multiaxial joints - the shoulder, wrist, metacarpophalangeal, and hip joints. *(Image credit: "Movements" by BlueLink is licensed under CC BY-NC 4.0 with notification of the original authors.)*

Supination and Pronation

Supination and pronation are movements of the forearm. In the anatomical position, the upper limb is held next to the body with the palm facing forward. This is the **supinated position** of the forearm. In this position, the radius and ulna are parallel to each other. When the palm of the hand faces backward, the forearm is in the **pronated position**, and the radius and ulna form an X-shape.

Supination and pronation are the movements of the forearm that go between these two positions. **Pronation** is the motion that moves the forearm from the supinated (anatomical) position to the pronated (palm backward) position. This motion is produced by rotation of the radius at the proximal radioulnar joint, accompanied by movement of the radius at the distal radioulnar joint. The proximal radioulnar joint is a pivot joint that allows for rotation of the head of the radius. Because of the slight curvature of the shaft of the radius, this rotation causes the distal end of the radius to cross over the distal ulna at the distal radioulnar joint. This crossing over brings the radius and ulna into an X-shape position. **Supination** is the opposite motion, in which rotation of the radius returns the bones to their parallel positions and moves the palm to the anterior facing (supinated) position (Figure 7.4.5).

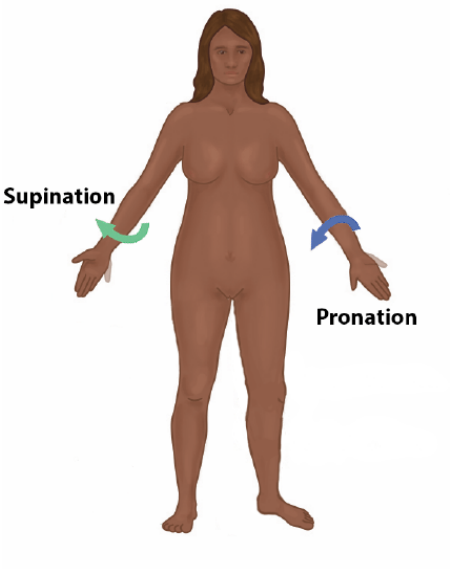

Figure 7.4.5: Movements of the Body - Pronation and Supination. In anatomical position your forearms are supinated (supine) and the palms are anterior. Pronation twists the forearm so the palm is facing posterior. *(Image credit: "Pronation-Supination" by Jennifer Lange is licensed under CC BY-NC-SA 4.0, modification of original by BlueLink .)*

Dorsiflexion and Plantar Flexion

Dorsiflexion and **plantar flexion** are movements at the ankle joint, which is a hinge joint. Lifting the front of the foot, so that the top of the foot moves toward the anterior leg is dorsiflexion, while lifting the heel of the foot from the ground or pointing the toes downward is plantar flexion. These are the only movements available at the ankle joint (Figure 7.4.6.A).

Inversion and Eversion

Inversion and eversion are complex movements that involve the multiple plane joints among the tarsal bones of the posterior foot (intertarsal joints) and thus are not motions that take place at the ankle joint. **Inversion** is the turning of the foot to angle the bottom of the foot toward the midline, while **eversion** turns the bottom of the foot away from the midline. The foot has a greater range of inversion than eversion motion. These are important motions that help to stabilize the foot when walking or running on an uneven surface and aid in the quick side-to-side changes in direction used during active sports such as basketball, racquetball, or soccer (Figure 7.4.6.B) .

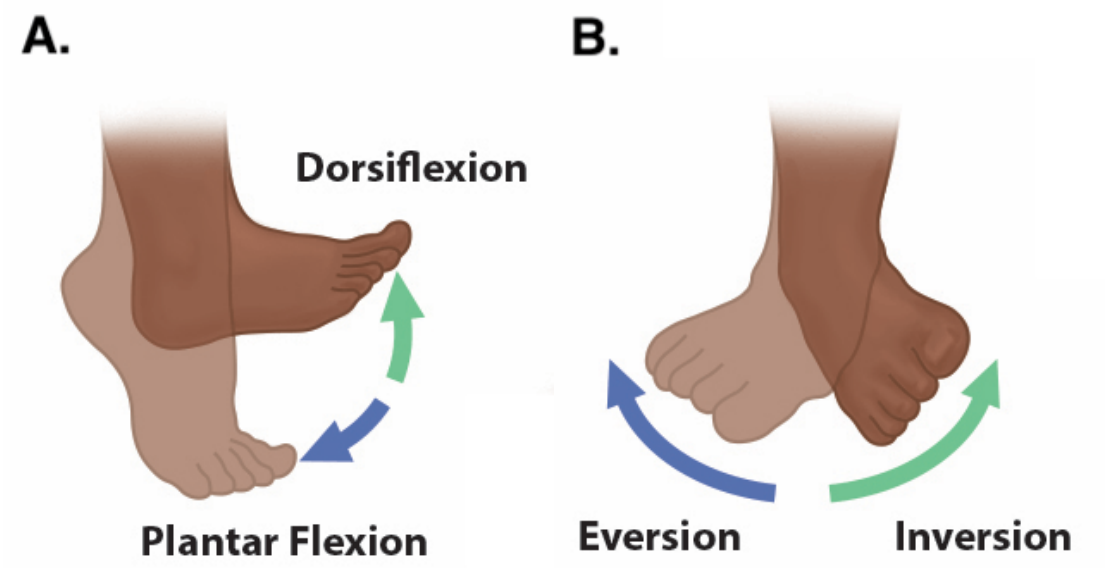

Figure 7.4.6: Movements of the Body - Ankle and Foot. A) When the foot is moving in the sagittal plane, dorsiflexion of the foot at the ankle joint moves the top of the foot toward the leg, while plantar flexion lifts the heel and points the toes. B) When the foot is moving in the frontal plane, eversion of the foot at the intertarsal joints moves the bottom (sole) of the foot away from the midline of the body, while foot inversion faces the sole toward the midline. *(Image credit: "Movements" by BlueLink is licensed under CC BY-NC 4.0 with notification of the original authors.)*

Protraction and Retraction

Protraction and **retraction** are anterior-posterior movements of the pectoral girdle or the mandible. Protraction of the pectoral girdle occurs when the shoulder is moved forward, as when pushing against something or throwing a ball. Retraction is the opposite motion, with the scapula being pulled posteriorly and medially, toward the vertebral column. For the mandible, protraction occurs when the lower jaw is pushed forward, to stick out the chin, while retraction pulls the lower jaw backward. (Figure 7.4.7).

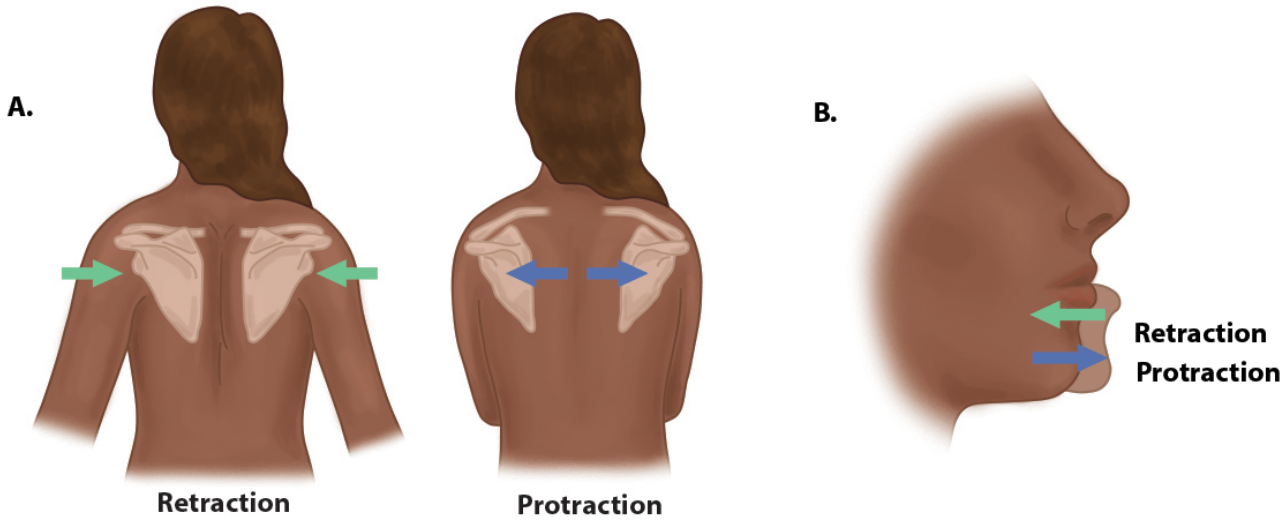

Figure 7.4.7: Protraction and Retraction. These moments occur at the sternoclavicular (A) and temporomandibular (B) joints. *(Image credit: "Movements" by BlueLink is licensed under CC BY-NC 4.0 with notification of the original authors.)*

Depression and Elevation

Depression and **elevation** are downward and upward movements of the pectoral girdle or the mandible. The upward movement of the pectoral girdle is elevation, while a downward movement is depression. These movements are used to shrug your shoulders. Similarly, elevation of the mandible is the upward movement of the lower jaw used to close the mouth or bite on something, and depression is the downward movement that produces opening of the mouth (Figure 7.4.8) .

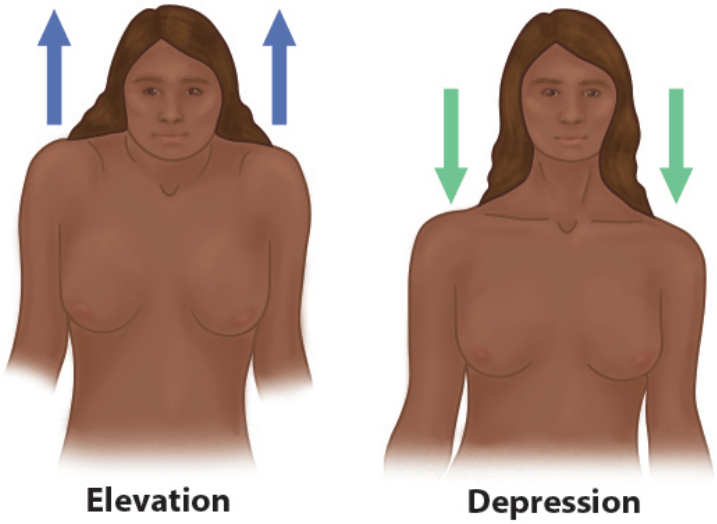

Figure 7.4.8: Elevation and Depression. The movements of elevation and depression also occur at the sternoclavicular joint and the temporomandibular joint (not shown). *(Image credit: "Movements" by BlueLink is licensed under CC BY-NC 4.0 with notification of the original authors.)*

Opposition and Reposition

Opposition is the thumb movement that brings the tip of the thumb in contact with the tip of a finger. This movement is produced at the first carpometacarpal joint, which is a saddle joint formed between the trapezium carpal bone and the first metacarpal bone. Thumb opposition is produced by a combination of flexion and abduction of the thumb at this joint. Returning the thumb to its anatomical position next to the index finger is called **reposition**. View these movements in the following video:

YouTube Video

This interactive element is not available in this format. Visit the link or scan the QR code to access it online.

View this YouTube Video online

Concept Review

The variety of movements provided by the different types of synovial joints allows for a large range of body motions and gives you tremendous mobility. These movements allow you to flex or extend your body or limbs, medially rotate and adduct your arms and flex your elbows to hold a heavy object against your chest, raise your arms above your head, rotate or shake your head, and bend to touch the toes (with or without bending your knees).

Each of the different structural types of synovial joints also allow for specific motions. The atlantoaxial pivot joint provides side-to-side rotation of the head, while the proximal radioulnar articulation allows for rotation of the radius during pronation and

supination of the forearm. Hinge joints, such as at the knee and elbow, allow only for flexion and extension. Similarly, the hinge joint of the ankle only allows for dorsiflexion and plantar flexion of the foot.

Condyloid and saddle joints are biaxial. These allow for flexion and extension, and abduction and adduction. The sequential combination of flexion, adduction, extension, and abduction produces circumduction. Multiaxial plane joints provide for only small motions, but these can add together over several adjacent joints to produce body movement, such as inversion and eversion of the foot. Similarly, plane joints allow for flexion, extension, and lateral flexion movements of the vertebral column. The multiaxial ball and socket joints allow for flexion-extension, abduction-adduction, and circumduction. In addition, these also allow for medial (internal) and lateral (external) rotation. Ball-and-socket joints have the greatest range of motion of all synovial joints.

Table 7.4.1: Synovial Joint Summary

Type of Joint	Movement	Example
Pivot	Uniaxial joint; allows rotational movement	Atlantoaxial joint (C1–C2 vertebrae articulation); proximal radioulnar joint
Hinge	Uniaxial joint; allows flexion/extension movements	Knee; elbow; ankle; interphalangeal joints of fingers and toes
Condyloid	Biaxial joint; allows flexion/extension, abduction/adduction, and circumduction movements	Metacarpophalangeal (knuckle) joints of fingers; radiocarpal joint of wrist; metatarsophalangeal joints for toes
Saddle	Biaxial joint; allows flexion/extension, abduction/adduction, and circumduction movements	First carpometacarpal joint of the thumb; sternoclavicular joint
Plane	Multiaxial joint; allows inversion and eversion of foot, or flexion, extension, and lateral flexion of the vertebral column	Intertarsal joints of foot; superior-inferior articular process articulations between vertebrae
Ball-and-socket	Multiaxial joint; allows flexion/extension, abduction/adduction, circumduction, and medial/lateral rotation movements	Shoulder and hip joints

Table 7.4.2: Synovial Joint Movements Summary

Flexion: Movement that ***decreases*** the angle between two bones or two parts of the body

Extension: Movement that ***increases*** the angle between two bones or two parts of the body

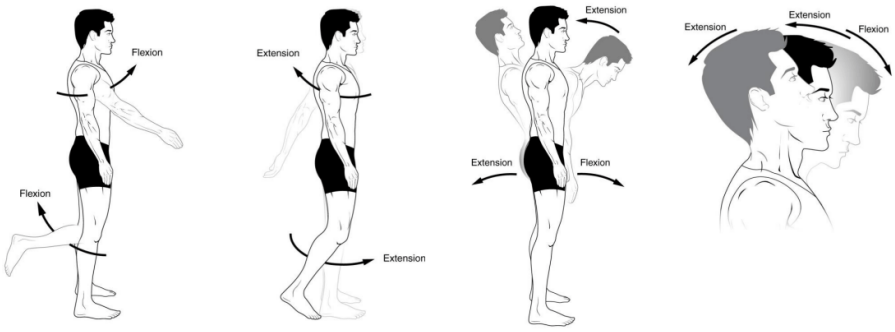

Plane of movement: ***Sagittal plane***

Where it happens: Neck, arm at the shoulder, forearm at the elbow, hand at the wrist, digits, spine, thigh at the hip, leg at the knee

Abduction: Movement of the limb/digit ***away*** from the midline ***(laterally)***

Adduction: Movement of the limb/digit ***towards*** the midline ***(medially)***

Plane of movement: ***Frontal plane***

Where it happens: Arm at the shoulder, digits, thigh at the hip

Lateral Flexion: Movement of the trunk in a lateral/medial direction

Plane of movement: ***Frontal plane***

Where it happens: Trunk at the lumbar intervertebral joints, cervical intervertebral joints, and atlanto-occipital joints.

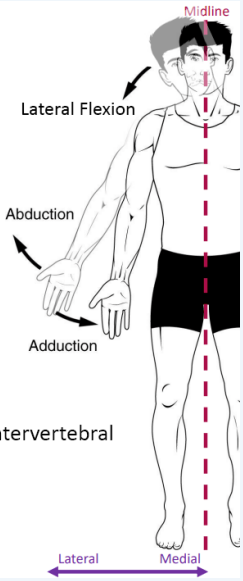

Rotation: ***Turning*** around a central longitudinal axis

The head can be rotated to the ***left*** and the ***right*** (i.e., shaking the head “no”)

Rotation of the limbs occurs when the forward-facing (anterior) surface is turned ***internally (medially)*** towards the midline, or ***externally (laterally)***, away from the midline

Where it happens: Head, arm at the shoulder, thigh at the hip

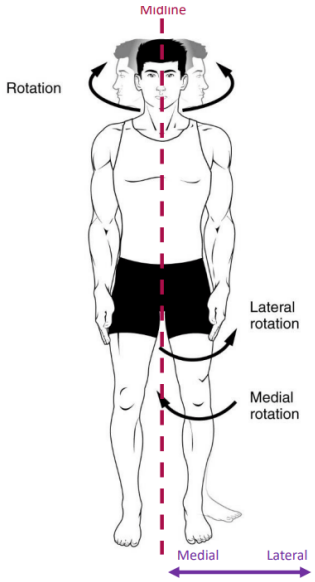

Plantar Flexion: Pushing or pointing the toes and the ball of the foot ***down*** towards the ground (i.e., standing on "tip toes")

Dorsiflexion: Standing on the heel of the foot, with the toes ***pointing up*** towards the sky

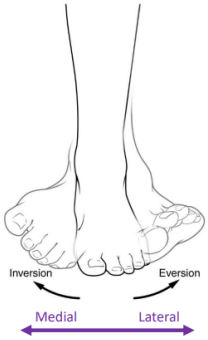

Inversion: Moving the foot to turn the sole ***inwards (medially)***

Eversion: Moving the foot to turn the sole ***outwards (laterally)***

Pronation: ***Rotation*** of the forearm (radius bone) ***inwards (medially)***, causing the palm to face ***downwards***

Supination: ***Rotation*** of the forearm (radius bone) ***outwards (laterally)***, causing the palm to face ***upwards***

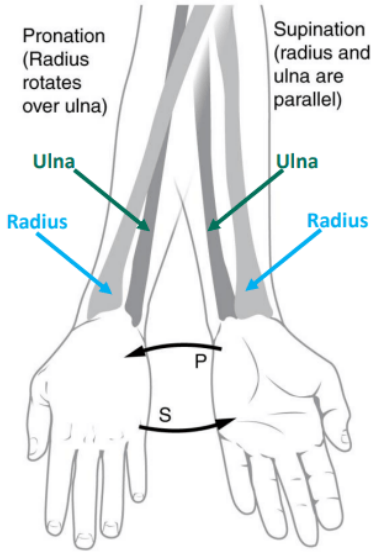

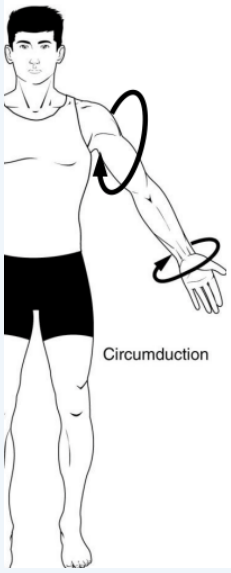

Circumduction: Movement ***at the joint*** that causes the limb to ***move in a circle***

Note: Circumduction is a compound movement that involves abduction, adduction, extension, and flexion

Where it happens: Ball-and-socket joints (e.g., shoulder, hip)

Elevation: Moving a body part ***upwards (superiorly)***

Depression: Moving a body part ***downwards (inferiorly)***

Where it happens: Eyelid, jaw (mandible), shoulder

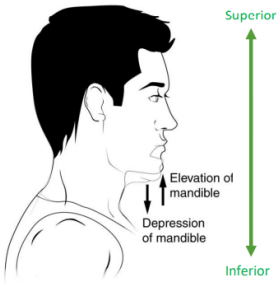

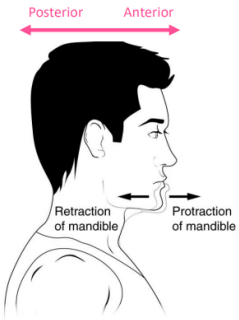

Protraction: Moving a body part ***forwards (anteriorly)***

Retraction: Moving a body part ***backwards (posteriorly)***

Where it happens: Jaw (mandible), scapula

(Image Credits: "Movements at Synovial Joints" by BlueLink is licensed under CC BY-NC 4.0 with notification of the original autho made by Jennifer Lange.)

Review Questions

Query 7.4.1

This interactive element is not available in this format. Visit the link or scan the QR code to access it online.

View this Interactive Content online

Query 7.4.2

This interactive element is not available in this format. Visit the link or scan the QR code to access it online.

View this Interactive Content online

Critical Thinking Questions

Query 7.4.3

This interactive element is not available in this format. Visit the link or scan the QR code to access it online.

View this Interactive Content online

Query 7.4.4

This interactive element is not available in this format. Visit the link or scan the QR code to access it online.

View this Interactive Content online

Glossary

Query 7.4.5

This interactive element is not available in this format. Visit the link or scan the QR code to access it online.

View this Interactive Content online

Contributors and Attributions

- OpenStax Anatomy & Physiology (CC BY 4.0). Access for free at https://openstax.org/books/anatomy-and-physiology

This page titled 7.4: Types of Body Movements is shared under a CC BY-NC-SA 4.0 license and was authored, remixed, and/or curated by Jennifer Lange et al..

- 8.6: Types of Body Movements by Whitney Menefee, Julie Jenks, Chiara Mazzasette, and Kim-Leiloni Nguyen is licensed CC BY 4.0.

7.5: Anatomy of Selected Synovial Joints

By the end of this section, you will be able to:

- Describe the bones that articulate together to form selected synovial joints
- Discuss the movements available at each joint
- Describe the structures that support and prevent excess movements at each joint

Each synovial joint of the body is specialized to perform certain movements. The movements that are allowed are determined by the structural classification for each joint. For example, a multiaxial ball-and-socket joint has much more mobility than a uniaxial hinge joint. However, the ligaments and muscles that support a joint may place restrictions on the total range of motion available. Thus, the ball-and-socket joint of the shoulder has little in the way of ligament support, which gives the shoulder a very large range of motion. In contrast, movements at the hip joint are restricted by strong ligaments, which reduce its range of motion but confer stability during standing and weight bearing.

This section will examine the anatomy of selected synovial joints of the body. Anatomical names for most joints are derived from the names of the bones that articulate at that joint, although some joints, such as the elbow, hip, and knee joints are exceptions to this general naming scheme.

Articulations of the Vertebral Column

In addition to being held together by the intervertebral discs, adjacent vertebrae also articulate with each other at synovial joints formed between the superior and inferior articular processes called **facet joints** (zygapophysial joints). These are plane joints that provide for only limited motions between the vertebrae. The orientation of the articular processes at these joints varies in different regions of the vertebral column and serves to determine the types of motions available in each vertebral region. The cervical and lumbar regions have the greatest ranges of motions.

In the neck, the articular processes of cervical vertebrae are flattened and generally face upward or downward. This orientation provides the cervical vertebral column with extensive ranges of motion for flexion, extension, lateral flexion, and rotation. In the thoracic region, the downward projecting and overlapping spinous processes, along with the attached thoracic cage, greatly limit flexion, extension, and lateral flexion. However, the flattened and vertically positioned thoracic articular processes allow for the greatest range of rotation within the vertebral column. The lumbar region allows for considerable extension, flexion, and lateral flexion, but the orientation of the articular processes largely prohibits rotation.

The articulations formed between the skull, the atlas (C1 vertebra), and the axis (C2 vertebra) differ from the articulations in other vertebral areas and play important roles in movement of the head. The **atlanto-occipital joint** is formed by the articulations between the superior articular processes of the atlas and the occipital condyles on the base of the skull. This articulation has a pronounced U-shaped curvature, oriented along the anterior-posterior axis. This allows the skull to rock forward and backward, producing flexion and extension of the head. This moves the head up and down, as when shaking your head “yes.”

The **atlantoaxial joint**, between the atlas and axis, consists of three articulations. The paired superior articular processes of the axis articulate with the inferior articular processes of the atlas. These articulating surfaces are relatively flat and oriented horizontally. The third articulation is the pivot joint formed between the dens, which projects upward from the body of the axis, and the inner aspect of the anterior arch of the atlas (Figure 7.5.1). The strong transverse ligament passes posterior to the dens to hold it in position against the anterior arch. These articulations allow the atlas to rotate on top of the axis, moving the head toward the right or left, as when shaking your head “no.”

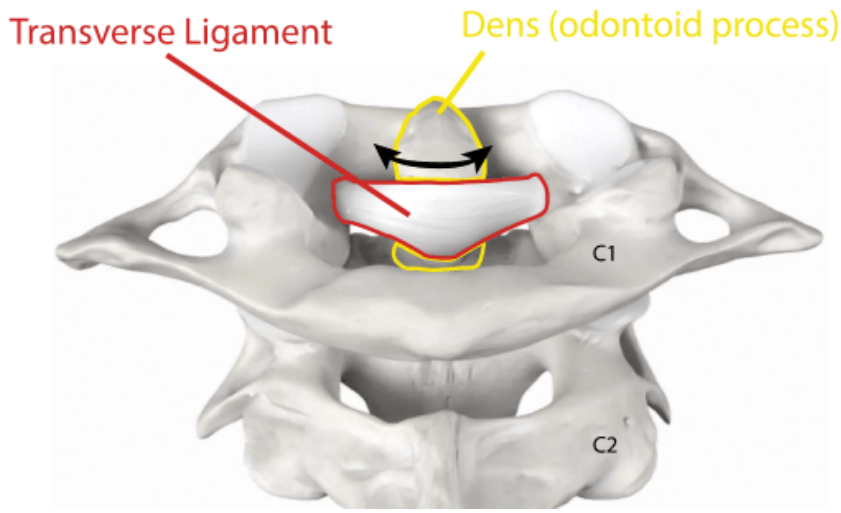

Figure 7.5.1: Atlantoaxial Joint. The atlantoaxial joint is a pivot type of joint between the dens portion of the axis (C2 vertebra) and the anterior arch of the atlas (C1 vertebra), with the dens held in place by a ligament. *(Image Credit: "Atlantoaxial Joint" by Jennifer Lange is licensed under CC BY-NC-SA 4.0, modification of image from Anatomy Standard.*

Pivot Joint Biomechanics

This interactive element is not available in this format. Visit the link or scan the QR code to access it online.

View this YouTube Video online

The modified structure of the atlas and axis, as well as the position of the transverse ligament, allow for a higher degree of rotation at the atlantoaxial joint than at other intervertebral joints. The pivot joint allows for the neck/head to rotate almost 90° to both the right and left sides.

Temporomandibular Joint

The **temporomandibular joint (TMJ)** is the joint that allows for opening (mandibular depression) and closing (mandibular elevation) of the mouth, as well as lateral/medial excursion and protraction/retraction motions of the lower jaw. This joint involves the articulation between the mandibular fossa and articular tubercle of the temporal bone, with the condyle (head) of the mandible. Located between these bony structures within the joint cavity, filling the gap between the skull and mandible, is a flexible articular disc (Figure 7.5.2) . This disc serves to smooth the movements between the temporal bone and mandibular condyle.

Movement at the TMJ during opening and closing of the mouth involves both gliding and hinge motions of the mandible. With the mouth closed, the mandibular condyle and articular disc are located within the mandibular fossa of the temporal bone. During opening of the mouth, the mandible hinges downward and at the same time is pulled anteriorly, causing both the condyle and the articular disc to glide forward from the mandibular fossa onto the downward projecting articular tubercle. The net result is a forward and downward motion of the condyle and mandibular depression. The temporomandibular joint is supported by an extrinsic ligament that anchors the mandible to the skull. This ligament spans the distance between the base of the skull and the lingula on the medial side of the mandibular ramus.

Dislocation of the TMJ may occur when opening the mouth too wide (such as when taking a large bite) or following a blow to the jaw, resulting in the mandibular condyle moving beyond (anterior to) the articular tubercle. In this case, the individual would not

be able to close their mouth. Temporomandibular joint disorder is a painful condition that may arise due to arthritis, wearing of the articular cartilage covering the bony surfaces of the joint, muscle fatigue from overuse or grinding of the teeth, damage to the articular disc within the joint, or jaw injury. Temporomandibular joint disorders can also cause headache, difficulty chewing, or even the inability to move the jaw (lock jaw). Pharmacologic agents for pain or other therapies, including bite guards, are used as treatments.

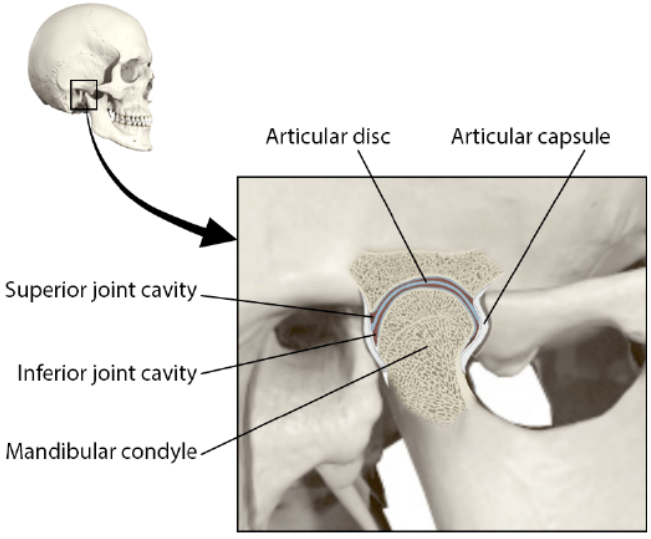

Figure 7.5.2: Temporomandibular Joint. The temporomandibular joint is the articulation between the temporal bone of the skull and the condyle of the mandible, with an articular disc located between these bones. *(Image credit: "Temporomandibular Joint" by Jennifer Lange and Justin Greene is licensed under CC BY-NC-SA 4.0, modification of image from Anatomy Standard.)*

Shoulder Joint

The shoulder joint is called the **glenohumeral joint**. This is a ball-and-socket joint formed by the articulation between the head of the humerus and the glenoid cavity of the scapula (Figure 7.5.3) . This joint has the largest range of motion of any joint in the body. However, this freedom of movement is due to the lack of structural support and thus the enhanced mobility is offset by a loss of stability.

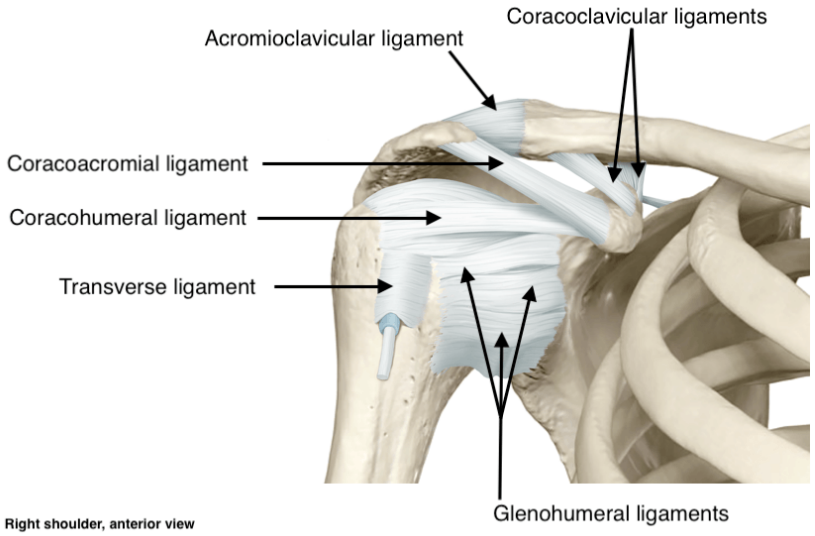

Figure 7.5.3: Glenohumeral Joint. The glenohumeral (shoulder) joint is a ball-and-socket joint that provides the widest range of motions. It has a loose articular capsule and is supported by ligaments and the rotator cuff muscles. *(Image credit: "Shoulder Joint Ligaments" by Justin Greene is licensed under CC BY-NC-SA 4.0, modification of image from Anatomy Standard.)*

The large range of motions at the shoulder joint is provided by the articulation of the large, rounded humeral head with the small and shallow glenoid cavity, which is only about one third of the size of the humeral head. Both of these structures are lined with articular cartilage. The socket formed by the glenoid cavity is deepened slightly by a small lip of fibrocartilage called the **glenoid labrum**, which extends around the outer margin of the cavity. The articular capsule that surrounds the glenohumeral joint is composed of a synovial membrane lined by a fibrous membrane and is relatively thin and loose to allow for large motions of the upper limb. Some structural support for the joint is provided by thickenings of the articular capsule wall that form weak intrinsic ligaments. These include the **coracohumeral ligament**, running from the coracoid process of the scapula to the anterior humerus, and three ligaments, each called a **glenohumeral ligament**, located on the anterior side of the articular capsule. These ligaments help to strengthen the superior and anterior capsule walls. An accessory ligament to the joint is the **coracoacromial ligament**, which attaches the coracoid process of the scapula to the acromion, and serves to prevent the head of the humerus from being displaced superiorly.

However, the primary support for the shoulder joint is provided by muscles crossing the joint, particularly the four rotator cuff muscles. These muscles (supraspinatus, infraspinatus, teres minor, and subscapularis) arise from the scapula and attach to the greater or lesser tubercles of the humerus. As these muscles cross the shoulder joint, their tendons encircle the head of the humerus and become fused to the anterior, superior, and posterior walls of the articular capsule. The thickening of the capsule formed by the fusion of these four muscle tendons is called the **rotator cuff**. Another muscle associated with the shoulder joint is the biceps brachii muscle. While it is not part of the rotator cuff, the tendon of the long head of the biceps brachii muscle, which is surrounded by a tendon sheath for protection within the joint, attaches to the glenoid labrum. Because of this association, any damage to the glenoid labrum typically results in damage or tearing of the biceps brachii tendon.

Two bursae, the **subacromial bursa** and the **subscapular bursa**, help to prevent friction between the rotator cuff muscle tendons and the scapula as these tendons cross the glenohumeral joint. In addition to their individual actions of moving the upper limb, the rotator cuff muscles also serve to hold the head of the humerus in position within the glenoid cavity. By constantly adjusting their strength of contraction to resist forces acting on the shoulder, these muscles serve as “dynamic ligaments” and thus provide the primary structural support for the glenohumeral joint.

Injuries to the shoulder joint are common. Repetitive use of the upper limb, particularly in abduction such as during throwing, swimming, or racquet sports, may lead to acute or chronic inflammation of the bursa or muscle tendons, a tear of the glenoid labrum, or degeneration or tears of the rotator cuff. Because the humeral head is strongly supported by muscles and ligaments around its anterior, superior, and posterior aspects, most dislocations of the humerus occur in an inferior direction. This can occur when force is applied to the humerus when the upper limb is fully abducted, as when diving to catch a baseball and landing on your hand or elbow. Inflammatory responses to any shoulder injury can lead to the formation of scar tissue between the articular capsule and surrounding structures, thus reducing shoulder mobility, a condition called adhesive capsulitis (“frozen shoulder”).

Interactive Link

Shoulder Joint Movements

This interactive element is not available in this format. Visit the link or scan the QR code to access it online.

View this YouTube Video online

Elbow Joint

The **elbow joint** is a uniaxial hinge joint formed by the **humeroulnar joint**, the articulation between the trochlea of the humerus and the trochlear notch of the ulna. Also associated with the elbow are the **humeroradial joint** and the **proximal radioulnar joint**. All three of these joints are enclosed within a single articular capsule (Figure 7.5.4) .

The articular capsule of the elbow is thin on its anterior and posterior aspects, but is thickened along its outside margins by strong intrinsic ligaments. These ligaments prevent side-to-side movements and hyperextension. On the medial side is the triangular **ulnar collateral ligament**. This arises from the medial epicondyle of the humerus and attaches to the coronoid process on the medial side of the proximal ulna. The strongest part of this ligament is the anterior portion, which resists hyperextension of the

elbow. The ulnar collateral ligament may be injured by frequent, forceful extensions of the forearm, as is seen in baseball pitchers. Reconstructive surgical repair of this ligament is referred to as Tommy John surgery, named for the former major league pitcher who was the first person to have this treatment.

The lateral side of the elbow is supported by the **radial collateral ligament**. This arises from the lateral epicondyle of the humerus and then blends into the lateral side of the annular ligament. The **annular ligament** encircles the head of the radius. This ligament supports the head of the radius as it articulates with the radial notch of the ulna at the proximal radioulnar joint. This is a pivot joint that allows for rotation of the radius during supination and pronation of the forearm.

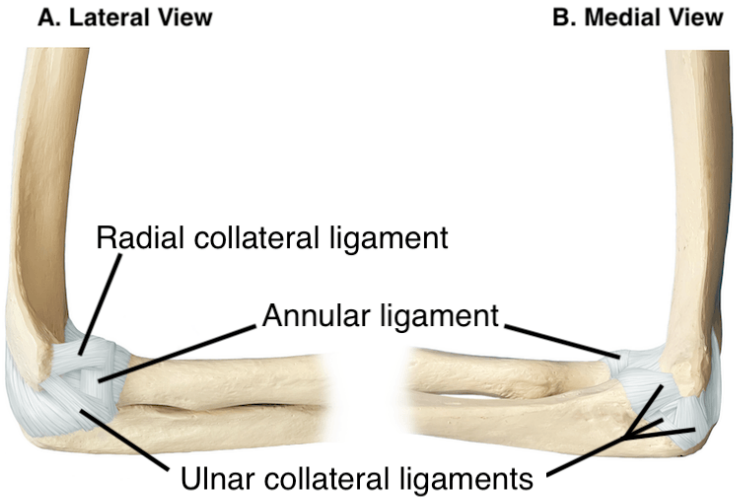

Figure 7.5.4: Elbow Joint. The elbow is a hinge joint that allows only for flexion and extension of the forearm, it is supported by the ulnar and radial collateral ligaments. The annular ligament supports the head of the radius at the proximal radioulnar joint, the pivot joint that allows for rotation of the radius. *(Image credit: "Elbow Joint Ligaments" by Justin Greene is licensed under CC BY-NC-SA 4.0.)*

Hip Joint

The **hip joint**, or the coxofemoral joint, is a multiaxial ball-and-socket joint between the head of the femur and the acetabulum of the hip bone (Figure 7.5.5). The hip carries the weight of the body and thus requires strength and stability during standing and walking. For these reasons, its range of motion is more limited than that of the shoulder joint.

The acetabulum is the socket portion of the hip joint. This space is deep and has a large articulation area for the femoral head, thus giving stability and weight bearing ability to the joint. The acetabulum is further deepened by the **acetabular labrum**, a fibrocartilage lip attached to the outer margin of the acetabulum. The surrounding articular capsule is strong, with several thickened areas forming intrinsic ligaments. These ligaments arise from the hip bone, at the margins of the acetabulum, and attach to the femur at the base of the neck. The ligaments are the **iliofemoral ligament**, **pubofemoral ligament**, and **ischiofemoral ligament**, all of which spiral around the head and neck of the femur. The ligaments are tightened by extension at the hip, thus pulling the head of the femur tightly into the acetabulum when in the upright, standing position. Very little additional extension of the thigh is permitted beyond this vertical position. These ligaments thus stabilize the hip joint and allow you to maintain an upright standing position with only minimal muscle contraction. Inside of the articular capsule, the **ligament of the head of the femur** (ligamentum teres) spans between the acetabulum and femoral head. This intracapsular ligament is normally slack and does not provide any significant joint support, but it does provide a pathway for an important artery that supplies the head of the femur.

The hip is prone to osteoarthritis, and thus was the first joint for which a replacement prosthesis was developed. A common injury in elderly individuals, particularly those with weakened bones due to osteoporosis, is a “broken hip,” which is actually a fracture of the femoral neck. This may result from a fall, or it may cause the fall. This can happen as one lower limb is taking a step and all of the body weight is placed on the other limb, causing the femoral neck to break and producing a fall. Any accompanying disruption of the blood supply to the femoral neck or head can lead to necrosis of these areas, resulting in bone and cartilage death. Femoral fractures usually require surgical treatment, after which the patient will need mobility assistance for a prolonged period, either from family members or in a long-term care facility. Consequentially, the associated health care costs of “broken

hips" are substantial. In addition, hip fractures are associated with increased rates of morbidity (incidences of disease) and mortality (death). Surgery for a hip fracture followed by prolonged bed rest may lead to life-threatening complications, including pneumonia, infection of pressure ulcers (bedsores), and thrombophlebitis (deep vein thrombosis; blood clot formation) that can result in a pulmonary embolism (blood clot within the lung).

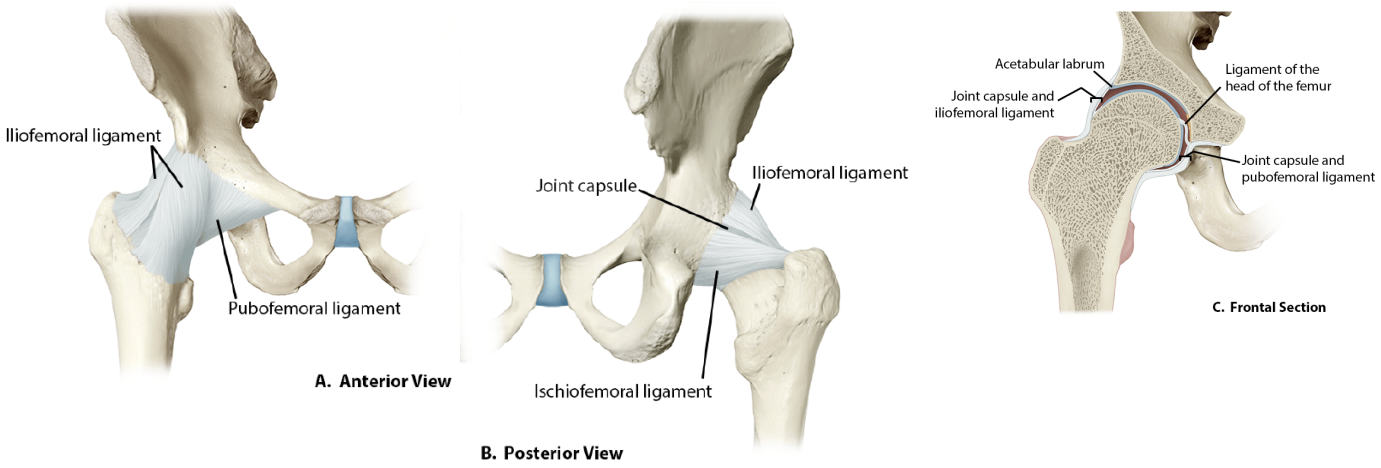

Figure 7.5.5: Hip Joint. Stability is added to the hip joint by three strong ligaments: the iliofemoral ligament, the ischiofemoral ligament, and the pubofemoral ligament. Additional stability comes from the acetabular labrum, a fibrocartilage pad that deepens the socket. (Image credit: "Hip Joint" by Justin Greene is licensed under *CC BY-NC-SA 4.0*, *modification of image from Anatomy Standard*.)

Interactive Link

Hip Joint Motion

This interactive element is not available in this format. Visit the link or scan the QR code to access it online.

View this YouTube Video online

Query 7.5.2

This interactive element is not available in this format. Visit the link or scan the QR code to access it online.

View this Interactive Content online

Knee Joint

The knee joint is the largest joint of the body (Figure 7.5.6) . It actually consists of two articulations: the **patellofemoral joint** is found between the patella and the distal femur and the **tibiofemoral joint** is located between the medial and lateral condyles of the femur and the medial and lateral condyles of the tibia. All of these articulations are enclosed within a single articular capsule. The knee functions as a hinge joint, allowing flexion and extension of the leg. This action is generated by both rolling and gliding motions of the femur on the tibia. The knee is well constructed for weight bearing in its extended position, but is vulnerable to injuries associated with hyperextension, twisting, or blows to the medial or lateral side of the joint, particularly while weight bearing.

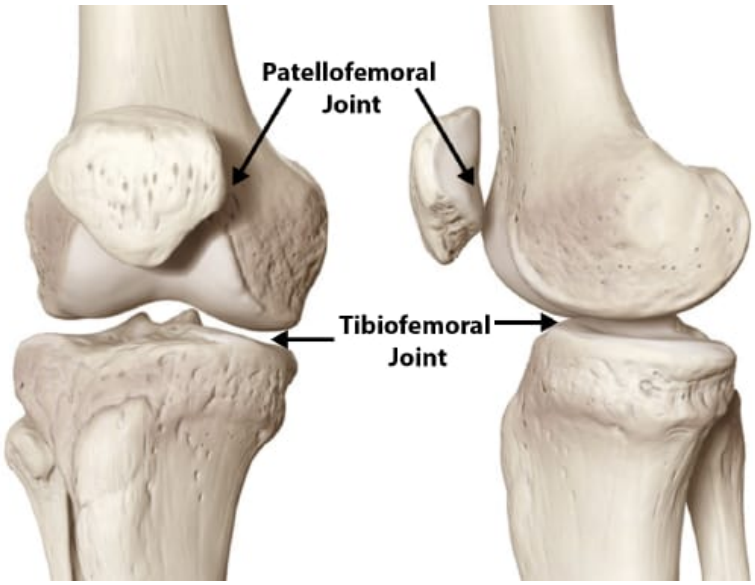

Figure 7.5.6: The Knee Joint. The knee joint has two articulations within a single capsule: the patellofemoral (gliding) and the tibiofemoral (hinge) joints. *(Image credit: "The Knee Joint" by Jennifer Lange is licensed under CC BY-NC-SA 4.0, modification of image from Anatomy Standard under CC BY-NC 4.0.)*

At the patellofemoral joint, the patella slides vertically within a groove on the distal femur. The patella is a sesamoid bone incorporated into the tendon of the quadriceps femoris muscle, the large muscle group of the anterior thigh. Continuing from the patella to the tibial tuberosity is the **patellar ligament**. The patella serves to protect the knee joint from anterior damage and to increase the force generated by the quads during knee extension.

The tibiofemoral joint is the articulation between the rounded condyles of the femur and the relatively flat condyles of the tibia. During flexion and extension motions, the condyles of the femur both roll and glide over the surfaces of the tibia. The rolling action produces flexion or extension, while the gliding action serves to maintain the femoral condyles centered over the tibial condyles, thus ensuring maximal bony, weight-bearing support for the femur in all knee positions. As the knee comes into full extension, the femur undergoes a slight medial rotation in relation to tibia. The rotation results because the lateral condyle of the femur is slightly smaller than the medial condyle. Thus, the lateral condyle finishes its rolling motion first, followed by the medial condyle. The resulting small medial rotation of the femur serves to “lock” the knee into its fully extended and most stable position. This is also called the "screw-home mechanism". Flexion of the knee is initiated by a slight lateral rotation of the femur on the tibia, which “unlocks” the knee. This lateral rotation motion is produced by the popliteus muscle of the posterior leg.

Located between the articulating surfaces of the femur and tibia are two articular discs, the **medial meniscus** and **lateral meniscus** (Figure 7.5.7) . Each is a C-shaped fibrocartilage structure that is thin along its inside margin and thick along the outer margin. They are attached to their tibial condyles, but do not attach to the femur. While both menisci are free to move during knee motions, the medial meniscus shows less movement because it is anchored at its outer margin to the articular capsule and tibial collateral ligament. The menisci provide padding between the bones and help to fill the gap between the round femoral condyles and flattened tibial condyles. Some areas of each meniscus lack an arterial blood supply and thus these areas heal poorly if damaged.

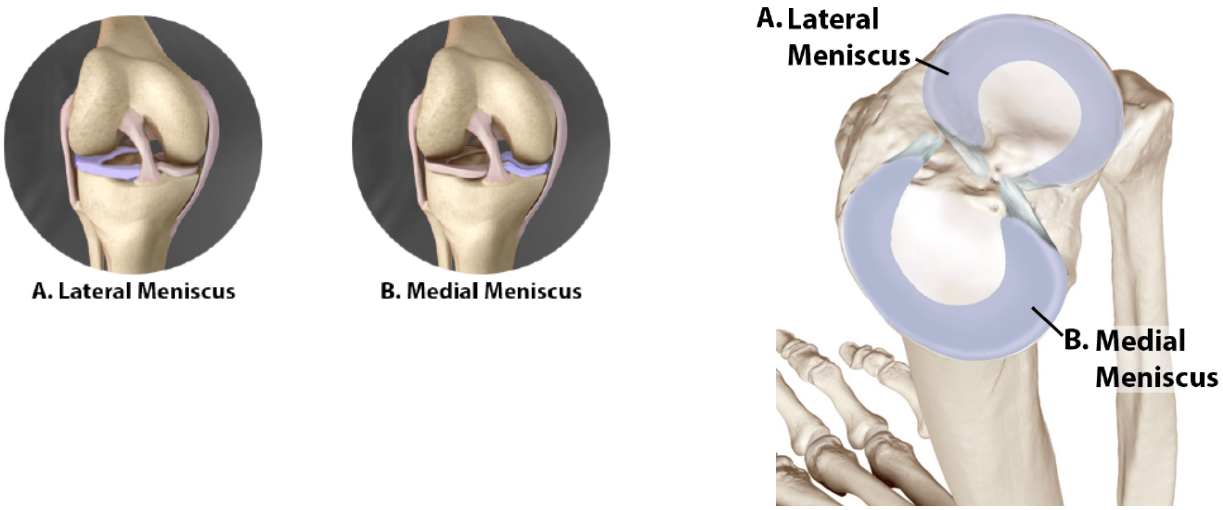

Figure 7.5.7: Knee Joint Menisci. The superior surface of the tibia has two fibrocartilage pads - the (A) lateral meniscus and the (B) medial meniscus - that are thicker along their outer edges than on their inner edges. This creates a slight indentation to help keep the femoral condyles from slipping out of place. *(Image credit: "Knee Joint Menisci" by Jennifer Lange is licensed under CC BY-NC-SA 4.0, modification of images from Scientific Animations and from Anatomy Standard.)*

The knee joint has multiple ligaments that provide support, particularly in the extended position (Figure 7.5.8) . Outside of the articular capsule, located at the sides of the knee, are two extrinsic ligaments. The **fibular collateral ligament** (lateral collateral ligament) is on the lateral side and spans from the lateral epicondyle of the femur to the head of the fibula. The **tibial collateral ligament** (medial collateral ligament) of the medial knee runs from the medial epicondyle of the femur to the medial tibia. As it crosses the knee, the tibial collateral ligament is firmly attached on its deep side to the articular capsule and to the medial meniscus, an important factor when considering knee injuries. In the fully extended knee position, both collateral ligaments are taut (tight), thus serving to stabilize and support the extended knee and preventing side-to-side or rotational motions between the femur and tibia.

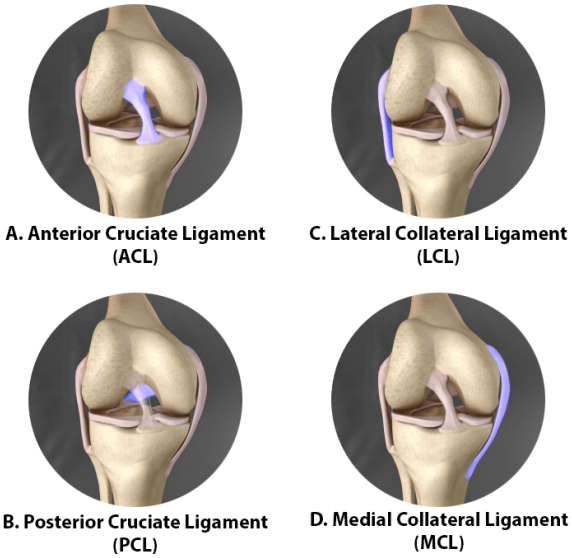

Figure 7.5.8: Knee Joint Ligaments. The knee joint is supported by four strong ligaments: A. the anterior cruciate ligament, B. the posterior cruciate ligament, C. the lateral (fibular) collateral ligament, and D. the medial (tibial) collateral ligament. *(Image credit: "Knee Joint Ligaments" by Jennifer Lange is licensed under CC BY-NC-SA 4.0, modification of original by Scientific Animations.)*

The articular capsule of the posterior knee is thickened by intrinsic ligaments that help to resist knee hyperextension. Inside the knee are two intracapsular ligaments, the **anterior cruciate ligament** and **posterior cruciate ligament**. These ligaments are anchored distally to the tibia at the intercondylar eminence, the roughened area between the tibial condyles, and proximally to the distal femur. The cruciate ligaments are named for whether they are attached anteriorly or posteriorly to this tibial region. Each ligament runs diagonally upward to attach to the inner aspect of a femoral condyle. The cruciate ligaments are named for

the X-shape formed as they pass each other (cruciate means “cross”). The posterior cruciate ligament is the stronger ligament. It serves to support the knee when it is flexed and weight bearing, as when walking downhill. In this position, the posterior cruciate ligament prevents the femur from sliding anteriorly off the top of the tibia. The anterior cruciate ligament becomes tight when the knee is extended, and thus resists hyperextension.

Knee Biomechanics

This interactive element is not available in this format. Visit the link or scan the QR code to access it online.

View this YouTube Video online

This interactive element is not available in this format. Visit the link or scan the QR code to access it online.

View this YouTube Video online

Query 7.5.3

This interactive element is not available in this format. Visit the link or scan the QR code to access it online.

View this Interactive Content online

Ankle and Foot Joints

The ankle is formed by the **talocrural joint** (Figure 7.5.9) . It consists of the articulations between the talus bone of the foot and the distal ends of the tibia and fibula of the leg (crural = “leg”). The superior aspect of the talus bone is square-shaped and has three areas of articulation. The top of the talus articulates with the inferior tibia. This is the portion of the ankle joint that carries the body weight between the leg and foot. The sides of the talus are firmly held in position by the articulations with the medial malleolus of the tibia and the lateral malleolus of the fibula, which prevent any side-to-side motion of the talus. The ankle is thus a uniaxial hinge joint that allows only for dorsiflexion and plantar flexion of the foot.

Additional joints between the tarsal bones of the posterior foot allow for the movements of foot inversion and eversion. Most important for these movements is the **subtalar joint**, located between the talus and calcaneus bones. The joints between the talus and navicular bones and the calcaneus and cuboid bones are also important contributors to these movements. All of the joints between tarsal bones are plane joints. Together, the small motions that take place at these joints all contribute to the production of inversion and eversion foot motions and are helpful for maintaining balance.

Like the hinge joints of the elbow and knee, the talocrural joint of the ankle is supported by several strong ligaments located on the sides of the joint. These ligaments extend from the medial malleolus of the tibia or lateral malleolus of the fibula and anchor to the talus and calcaneus bones. Since they are located on the sides of the ankle joint, they allow for dorsiflexion and plantar flexion of the foot. They also prevent abnormal side-to-side and twisting movements of the talus and calcaneus bones during eversion and inversion of the foot. On the medial side is the broad **deltoid ligament,** named for its triangular shape. The deltoid ligament supports the ankle joint and also resists excessive eversion of the foot. The lateral side of the ankle has several smaller ligaments. These include the **anterior talofibular ligament** and the **posterior talofibular ligament**, both of which span between the talus bone and the lateral malleolus of the fibula, and the **calcaneofibular ligament**, located between the calcaneus bone

and fibula. These ligaments support the ankle and also resist excess inversion of the foot.

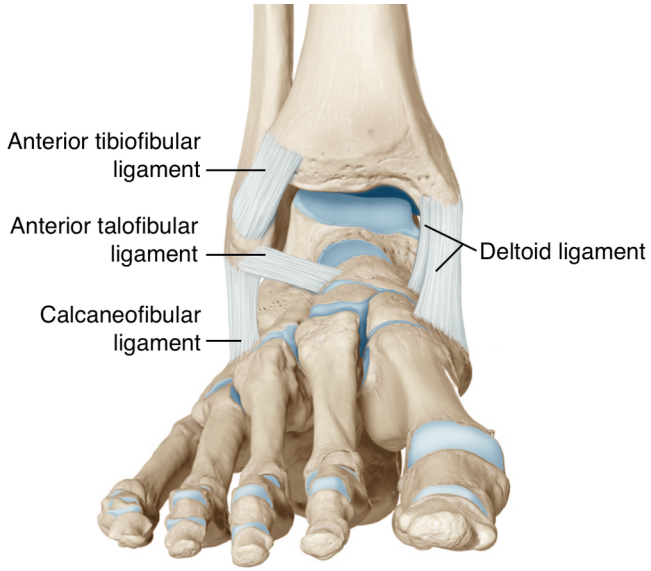

Figure 7.5.9: Ankle Joint. The talocrural (ankle) joint is a uniaxial hinge joint that only allows for dorsiflexion or plantar flexion of the foot. Ligaments that unite the medial or lateral malleolus with the talus and calcaneus bones serve to support the talocrural joint and to resist excess eversion or inversion of the foot. *(Image credit: "Ankle Joint Ligaments" by Justin Greene is licensed under CC BY-NC-SA 4.0.)*

Interactive Link

Ankle Joint Ligaments

This interactive element is not available in this format. Visit the link or scan the QR code to access it online.

View this YouTube Video online

DISORDERS OF THE...

Joints

The ankle is the most frequently injured joint in the body, with the most common injury being an inversion ankle sprain. A sprain is the stretching or tearing of the supporting ligaments. Excess inversion causes the talus bone to tilt laterally, thus damaging the ligaments on the lateral side of the ankle. The anterior talofibular ligament is most commonly injured, followed by the calcaneofibular ligament. In severe inversion injuries, the forceful lateral movement of the talus not only ruptures the lateral ankle ligaments, but also fractures the distal fibula.

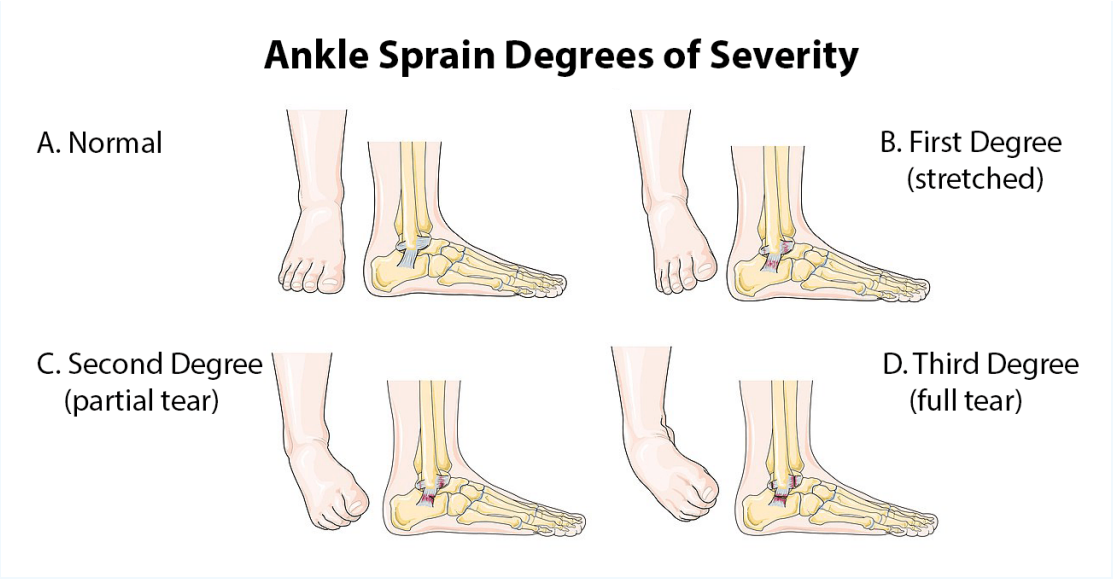

Figure 7.5.10: "*Ankle Sprains*" *by Jennifer Lange is licensed under CC BY-NC-SA 4.0, modification of original by Laboratoires Servier via Wikimedia Commons.*

Less common are eversion sprains of the ankle, which involve stretching of the deltoid ligament on the medial side of the ankle. Forcible eversion of the foot, for example, with an awkward landing from a jump or when a football player has a foot planted and is hit on the lateral ankle, can result in a Pott's fracture and dislocation of the ankle joint. In this injury, the very strong deltoid ligament does not tear, but instead shears off the medial malleolus of the tibia. This frees the talus, which moves laterally and fractures the distal fibula. In extreme cases, the posterior margin of the tibia may also be sheared off.

Above the ankle, the distal ends of the tibia and fibula are united by a strong syndesmosis formed by the interosseous membrane and ligaments at the distal tibiofibular joint. These connections prevent separation between the distal ends of the tibia and fibula and maintain the talus locked into position between the medial malleolus and lateral malleolus. Injuries that produce a lateral twisting of the leg on top of the planted foot can result in stretching or tearing of the tibiofibular ligaments, producing a syndesmotic ankle sprain or "high ankle sprain."

Most ankle sprains can be treated using the RICE technique: Rest, Ice, Compression, and Elevation. Reducing joint mobility using a brace or cast may be required for a period of time. More severe injuries involving ligament tears or bone fractures may require surgery.

Concept Review

Although synovial joints share many common features, each joint of the body is specialized for certain movements and activities. The joints of the upper limb provide for large ranges of motion, which give the upper limb great mobility, thus enabling actions such as the throwing of a ball or typing on a keyboard. The joints of the lower limb are more robust, giving them greater strength and the stability needed to support the body weight during running, jumping, or kicking activities. The joints described in this section are summarized in Table 7.5.1.

Table 7.5.1: Movements at Select Joints

Joint	Skeletal Structures	Classification	Movements	Key Supporting Structures
Intervertebral	Intervertebral discs between adjacent vertebra bodies	Symphysis; amphiarthrosis	• flexion, extension, hyperextension • lateral flexion (right/left) • rotation (right/left)	
Intervertebral	Superior and inferior articular processes of adjacent vertebrae	Planar; diarthrosis	• flexion, extension, hyperextension • lateral flexion (right/left) • rotation (right/left)	
Atlanto-occipital	Superior articular processes of C_1 and occipital condyles	Condyloid; diarthrosis	• flexion, extension, • lateral flexion (right/left) - slight	
Atlantoaxial	Dens of C_2 and anterior arch of C_1	Pivot; diarthrosis	• rotation (right/left)	• transverse ligament
Temporomandibular	Head of mandible and mandibular fossa of temporal bone; head of mandible and articular tubercle of temporal bone	Hinge and planar; diarthrosis	• elevation, depression • protraction, retraction • side-to-side (lateral displacement)	
Glenohumeral (shoulder)	Head of humerus and glenoid fossa of scapula	Ball and socket; diarthrosis	• flexion, extension, hyperextension • adduction, abduction • rotation (medial/lateral) • circumduction	• glenoid labrum • ligaments: coracohumeral, glenohumeral • tendons of rotator cuff and biceps brachii

Joint	Skeletal Structures	Classification	Movements	Key Supporting Structures
Humeroulnar (elbow)	Trochlea of humerus and trochlear notch of radius	Hinge; diarthrosis	• flexion, extension	• ligaments: ulnar collateral, radial collateral
Proximal radioulnar	Head of radius and radial notch	Pivot; diarthrosis	• supination, pronation	• annular ligament
Hip	Head of femur and acetabulum of os coxa	Ball and socket; diarthrosis	• flexion, extension, hyperextension • adduction, abduction • rotation (medial/lateral) • circumduction	• acetabular labrum • ligaments: iliofemoral, pubofemoral, ischiofemoral
Tibiofemoral (knee)	Femoral condyles and tibial condyles	Hinge; diarthrosis	• flexion, extension	• menisci: medial and lateral • ligaments: anterior cruciate, posterior cruciate, medial collateral, lateral collateral
Talocrural (ankle)	Distal tibia, medial malleolus, lateral malleolus and talus	Hinge; diarthrosis	• plantarflexion, dorsiflexion	• ligaments: deltoid, talofibular, calcaneofibular

Sprains are graded on a scale of 1 - 3, with grade 1 being the least severe (stretched) and grade 3 being the most severe (completely torn). The most commonly sprained joint is the ankle.

Review Questions

Query 7.5.5

This interactive element is not available in this format. Visit the link or scan the QR code to access it online.

View this Interactive Content online

Query 7.5.6

This interactive element is not available in this format. Visit the link or scan the QR code to access it online.

View this Interactive Content online

Critical Thinking Questions

Query 7.5.7

This interactive element is not available in this format. Visit the link or scan the QR code to access it online.

View this Interactive Content online

Query 7.5.8

This interactive element is not available in this format. Visit the link or scan the QR code to access it online.

View this Interactive Content online

Glossary

Query 7.5.9

This interactive element is not available in this format. Visit the link or scan the QR code to access it online.

View this Interactive Content online

Contributors and Attributions

- OpenStax Anatomy & Physiology (CC BY 4.0). Access for free at https://openstax.org/books/anatomy-and-physiology

This page titled 7.5: Anatomy of Selected Synovial Joints is shared under a CC BY-NC-SA 4.0 license and was authored, remixed, and/or curated by Jennifer Lange et al..

- 8.7: Anatomy of Selected Synovial Joints by Whitney Menefee, Julie Jenks, Chiara Mazzasette, and Kim-Leiloni Nguyen is licensed CC BY 4.0.

7.6: Diseases and Injuries of Joints

By the end of this section, you will be able to:

- Describe the similarities and differences between the three types of arthritis
- Classify sprains according to severity
- Describe what happens in a joint dislocation

Arthritis

Arthritis is a common disorder of synovial joints that involves inflammation of the joint. This often results in significant joint pain, along with swelling, stiffness, and reduced joint mobility. There are more than 100 different forms of arthritis. Arthritis may arise from aging, damage to the articular cartilage, autoimmune diseases, bacterial or viral infections, or unknown (probably genetic) causes.

Osteoarthritis

The most common type of arthritis is osteoarthritis, which is associated with aging and “wear and tear” of the articular cartilage (Figure 7.6.1) . Risk factors that may lead to osteoarthritis later in life include injury to a joint; jobs that involve physical labor; sports with running, twisting, or throwing actions; and being overweight. These factors put stress on the articular cartilage that covers the surfaces of bones at synovial joints, causing the cartilage to gradually become thinner. As the articular cartilage layer wears down, more pressure is placed on the bones. The joint responds by increasing production of the lubricating synovial fluid, but this can lead to swelling of the joint cavity, causing pain and joint stiffness as the articular capsule is stretched. The bone tissue underlying the damaged articular cartilage also responds by thickening, producing irregularities and causing the articulating surface of the bone to become rough or bumpy. Joint movement then results in pain and inflammation.

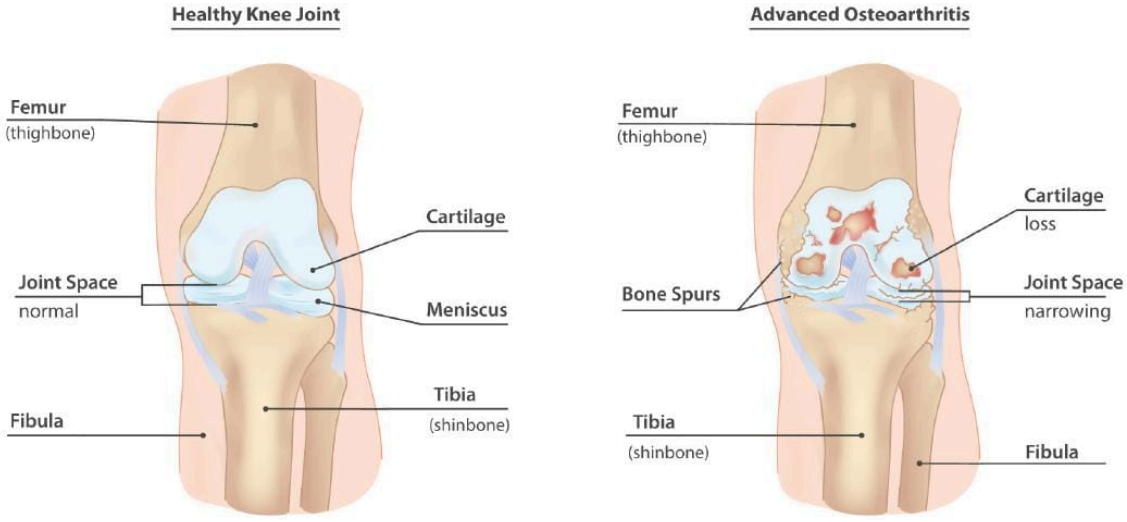

(Figure 7.6.1) : Osteoarthritis. Osteoarthritis of a synovial joint results from aging or prolonged joint wear and tear. These cause erosion and loss of the articular cartilage covering the surfaces of the bones, resulting in inflammation that causes joint stiffness and pain. In more advanced stages of osteoarthritis bone spurs (small sharp nodules) develop on the bones, which then acelerates further cartilage damage. *(Image credits: "Healthy Knee Joint" and "Advanced Osteoarthritis" by Injury Map are licensed under CC BY 4.0.)*

In its early stages, symptoms of osteoarthritis may be reduced by mild activity that “warms up” the joint, but the symptoms may worsen following exercise. In individuals with more advanced osteoarthritis, the affected joints can become more painful and therefore are difficult to use effectively, resulting in increased immobility. There is no cure for osteoarthritis, but several

treatments can help alleviate the pain. Treatments may include lifestyle changes, such as weight loss and low-impact exercise, and over-the-counter or prescription medications that help to alleviate the pain and inflammation. For severe cases, joint replacement surgery (arthroplasty) may be required (Figure 7.6.2).

Figure 7.6.2: Knee Replacement. In cases of severe osteoarthritis a knee arthroplasty, commonly called knee replacement, can be performed. Both the tibial and femoral articular surfaces are replaced - the cartilage and underlying bone is removed and replaced with metal components. X-rays three months post-surgery. (Image credits: "Right Knee Post-surgery" is in the public domain, via Wikimedia Commons.)

Joint replacement is a very invasive procedure, so other treatments are always tried before surgery. However arthroplasty can provide relief from chronic pain and can enhance mobility within a few months following the surgery. This type of surgery involves replacing the articular surfaces of the bones with prostheses (artificial components). For example, in hip arthroplasty, the worn or damaged parts of the hip joint, including the head and neck of the femur and the acetabulum of the pelvis, are removed and replaced with artificial joint components. The replacement head for the femur consists of a rounded ball attached to the end of a shaft that is inserted inside the diaphysis of the femur. The acetabulum of the pelvis is reshaped and a replacement socket is fitted into its place. The parts, which are always built in advance of the surgery, are sometimes custom made to produce the best possible fit for a patient.

Gout

Gout is a form of arthritis that results from the deposition of uric acid crystals within a body joint (Figure 7.6.3). Usually only one or a few joints are affected, such as the big toe, knee, or ankle. The attack may only last a few days, but may return to the same or another joint. Gout occurs when the body makes too much uric acid or the kidneys do not properly excrete it. A diet with excessive fructose has been implicated in raising the chances of a susceptible individual developing gout.

Figure 7.6.3: Gout. Gouty arthritis is characterized by recurrent attacks of a red, tender, hot and swollen joint. *(Image credit: "Gout Signs and Symptoms" by www.scientificanimations.com, CC BY-SA 4.0, via Wikimedia Commons.)*

Autoimmune Diseases

Autoimmune diseases, including rheumatoid arthritis, scleroderma, or systemic lupus erythematosus, produce arthritis because the immune system of the body attacks the body joints. In rheumatoid arthritis, the joint capsule and synovial membrane become inflamed. As the disease progresses, the articular cartilage is severely damaged or destroyed, resulting in joint deformation, loss of movement, and severe disability. The most commonly involved joints are the hands, feet, and cervical spine, with corresponding joints on both sides of the body usually affected, though not always to the same extent. Rheumatoid arthritis is also associated with lung fibrosis, vasculitis (inflammation of blood vessels), coronary heart disease, and premature mortality. With no known cure, treatments are aimed at alleviating symptoms. Exercise, anti-inflammatory and pain medications, various specific disease-modifying anti-rheumatic drugs, or surgery are used to treat rheumatoid arthritis.

Figure 7.6.4: Rheumatoid Arthritis. Rheumatoid arthritis causes swelling within the joint capsule that distorts the relative positions of the bones. *(Image credit: "Rheumatoid Arthritis" by BruceBlaus, CC BY-SA 4.0, via Wikimedia Commons*

Sprains

A **sprain** is an acute injury of a ligament that is often caused by a sudden or severe movement forcing the joint to exceed its

normal range of motion. The collagen fibers in a ligament have a small amount of elasticity - they can stretch by approximately 4% of their length. Tension applied by stretching or twisting that exceeds this elasticity limit will case the collagen fibers to tear. Sprains can occur at any joint, but they most commonly occur in the ankle, knee, or wrist. The majority of sprains are mild, causing minor swelling and bruising that can be resolved with conservative treatment, typically summarized as RICE: rest, ice, compression, and elevation. The most severe sprains involve complete tears, ruptures, or fractures, often leading to joint instability, severe pain, and decreased functional ability. These sprains require prolonged immobilization and sometimes surgery and/or physical therapy. Classification of sprains is based on the severity of damage to the ligament:

1. **First degree sprain (mild)** – There is minor stretching and structural damage to the ligament on the microscopic level, leading to mild swelling and bruising. Patients typically present without joint instability or decreased range of motion of the joint. Return to normal function can be expected from 4 days to 4 weeks.
2. **Second degree sprain (moderate)** – There is a partial tear of the affected ligament. Patients typically experience moderate swelling, tenderness, bruising and some instability of the joint. There may be some difficulty bearing weight on the affected joint resulting from the increased range of motion and the pain. Return to normal function depends on severity and can range from 4 weeks to 4 months.
3. **Third degree sprain (severe)** – There is a complete rupture or tear of the ligament, sometimes avulsing (tearing off) a piece of bone (Figure 7.6.5). Patients typically experience severe joint instability, pain, bruising, swelling, and inability to apply weight to the joint. However, in a minority of cases the patient may not experience any pain after the tear because the damage also severed the nerve endings that would normally send the pain signals to the brain. Return to normal function depends on severity and whether surgical repair is necessary, but the typical range is 3 to 6 months.

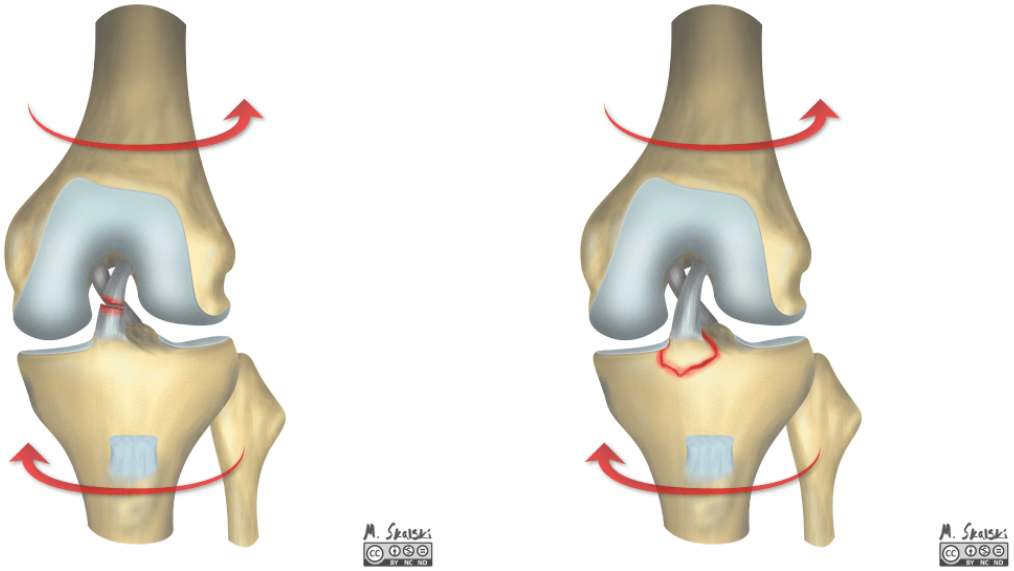

Figure 7.6.5: Third Degree Sprains. Excessive twisting of the knee joint can cause two different types of third degree sprains: the anterior cruciate ligament may tear completely or it may pull out of its attachment site on the tibia causing an avulsion. *(Image credit: "ACL Tear and ACL Avulsion Illustrations" are based on original case courtesy of Dr. Matt Skalski, Radiopaedia.org. From the case rID: 21443)*

DISORDERS OF THE...

Knee Joint

Injuries to the knee are common. Since this joint is primarily supported by muscles and ligaments, injuries to any of these structures will result in pain or knee instability. Injury to the posterior cruciate ligament occurs when the knee is flexed and the tibia is driven posteriorly, such as falling and landing on the tibial tuberosity or hitting the tibia on the dashboard when not wearing a seatbelt during an automobile accident. More commonly, injuries occur when forces are applied to the extended knee, particularly when the foot is planted and unable to move. Anterior cruciate ligament injuries can result with a forceful blow to the anterior knee, producing hyperextension, or when a runner makes a quick change of direction that produces both twisting and hyperextension of the knee (Figure 7.6.6).

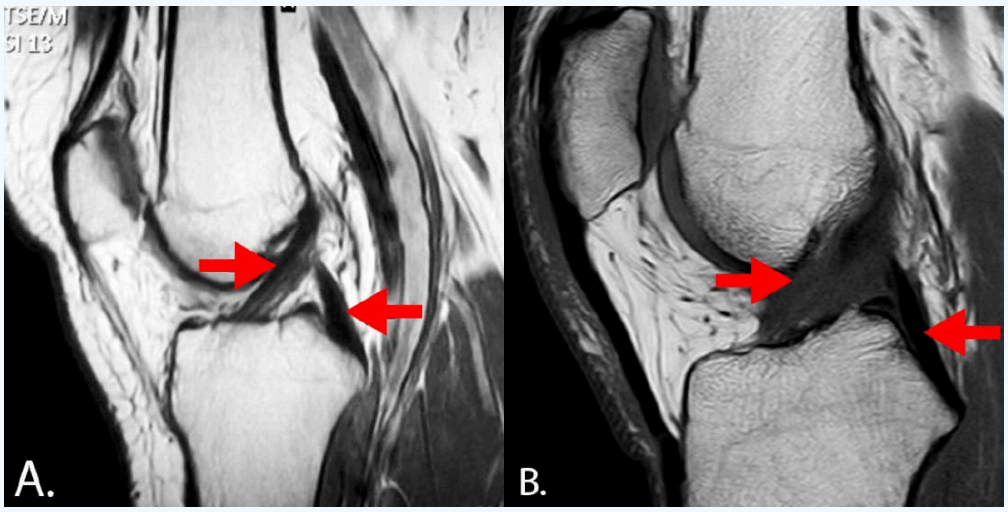

Figure 7.6.6: MRI of Knee Ligaments. Ligaments appear dark black on an MRI because of their lack of water. In image A both the ACL and PCL (arrows) are normal and appear as thick black bands; in image B the PCL is normal but the torn ACL appears as a fuzzy, variable grey area. *(Image Credits: "MRI of Knee Ligaments" by Jennifer Lange are licensed under CC BY-NC-SA 4.0, based on originals A: "MRI Normal ACL and PCL": Marios G Lykissas, George I Mataliotakis, Nikolaos Paschos, Christos Panovrakos, Alexandros E Beris and Christos D Papageorgiou, CC BY-SA 2.0, via Wikimedia Commons; B: MRI ACL tear: Case courtesy of Dr Ali Alsmair, Radiopaedia.org. From the case rID: 95927)*

A worse combination of injuries can occur with a hit to the lateral side of the extended knee (Figure 7.6.7). A moderate blow to the lateral knee will cause the medial side of the joint to open, resulting in stretching or damage to the tibial collateral ligament. Because the medial meniscus is attached to the tibial collateral ligament, a stronger blow can tear the ligament and also damage the medial meniscus (Figure 7.6.8). This is one reason that the medial meniscus is 20 times more likely to be injured than the lateral meniscus. A powerful blow to the lateral knee produces a “terrible triad” injury, in which there is a sequential injury to the tibial collateral ligament, medial meniscus, and anterior cruciate ligament.

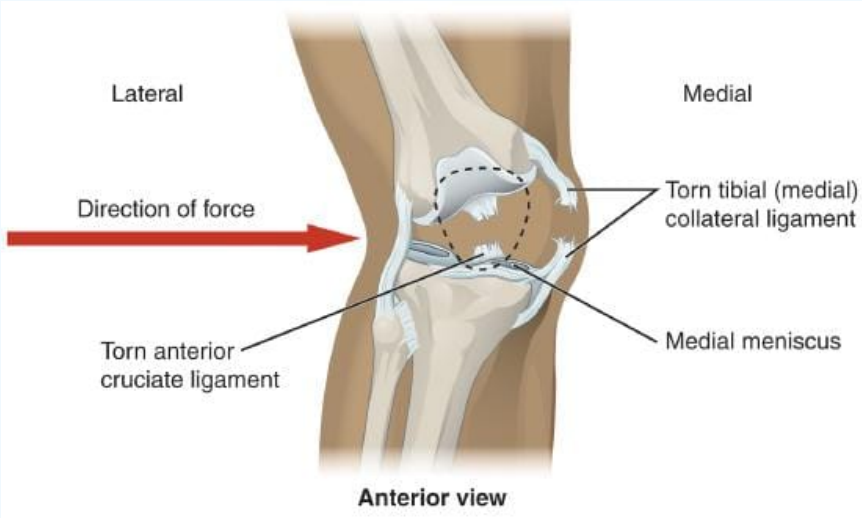

Figure 7.6.7: Knee Injury. A strong blow to the lateral side of the extended knee will cause three injuries, in sequence: tearing of the tibial collateral ligament, damage to the medial meniscus, and rupture of the anterior cruciate ligament. *(Image credit: "Knee Injury" by OpenStax is licensed under CC BY 3.0)*

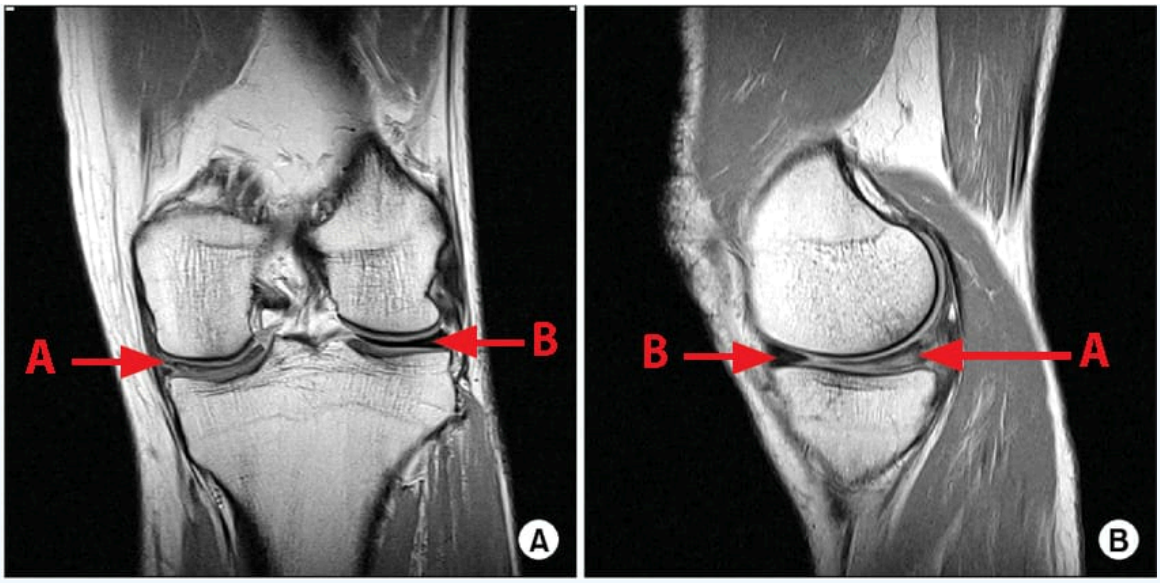

Figure 7.6.8: MRI of Knee Menisci. The menisci appear dark black on an MRI. Image A is a coronal view showing a normal meniscus (arrow B) as a solid black line that widens on the lateral edge and a torn meniscus (arrow A). Image B shows the same knee in a sagittal view. Here the healthy anterior aspect of the meniscus has a triangular shape while the torn posterior aspect of the meniscus shows a blurry grey area. *(Image Credit: "MRI of Knee Menisci" by Jennifer Lange is licensed under CC BY-NC-SA 4.0, based on original from Song, In & Kim, Jun & Lee, Jong & Park, Byeong-Seop. (2017). Discoid Medial Meniscus Tear, with a Literature Review of Treatments. Knee Surgery & Related Research. 29. 237-242. 10.5792/ksrr.15.054. Original licensed under CC BY-NC 4.0 International.)*

Arthroscopic surgery has greatly improved the surgical treatment of knee injuries and reduced subsequent recovery times. This procedure involves a small incision and the insertion into the joint of an arthroscope, a pencil-thin instrument that allows for visualization of the joint interior. Small surgical instruments are also inserted via additional incisions. These tools allow a surgeon to remove or repair a torn meniscus or to reconstruct a ruptured cruciate ligament. The current method for anterior cruciate ligament replacement involves using a portion of the patellar ligament. Holes are drilled into the cruciate ligament attachment points on the tibia and femur, and the patellar ligament graft, with small areas of attached bone still intact at each end, is inserted into these holes. The bone-to-bone sites at each end of the graft heal rapidly and strongly, thus enabling a rapid recovery.

Dislocation

A dislocation is the complete separation of the bones that form a joint, usually caused by trauma such as a car accident or a fall (Figure 7.6.9). In a partial dislocation, called a subluxation, the bones in the joint shift out of position but the articular surfaces remain in partial alignment. The shifting of the bones can also cause damage to the surrounding joint structures such as ligaments, the joint capsule, or the labrum as well as nearby muscles, blood vessels, or nerves. The most commonly dislocated joint is the shoulder, accounting for about 50% of injuries. Other commonly dislocated joints are the fingers, toes, patella, elbow, and hip, with the frequency of each varying by country. Joint dislocation results in pain, swelling, and, sometimes, bruising. Because moving the injured joint is so painful, some people are unwilling or unable to move it and will attempt to hold the bones to keep them immobile.

A. Anterior Shoulder Dislocation

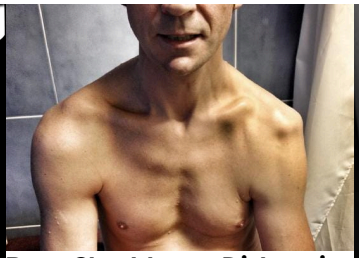

B. Shoulder Dislocation Clinical Appearance

C. Lateral Patella Dislocation

D. Finger Dislocation, 2nd Digit

Figure 7.6.9: Dislocation Images. A. In this x-ray of an anterior shoulder dislocation the head of the humerus is seen as anterior and medial to the glenoid fossa. B. A dislocated shoulder shows a sharp angle whereas the normal shoulder is rounded. C. In a patella dislocation the patella moves out of the patellar groove of the femur. D. The phalanges of the 2nd digit are curving medially because of a dislocation of the proximal interphalangeal joint. *(Image credits: A: "Shoulder Dislocation X-Ray" Case courtesy of Jeremy Jones, Radiopaedia.org. From the case rID: 6265. B: "Shoulder Dislocation" by Dave Haygarth is licensed under CC BY 2.0. C: "Patella Dislocation" by Hellerhoff is licensed under CC BY-SA 3.0, via Wikimedia Commons. D: "Finger Dislocation" by Rbmoore at en.wikipedia is licensed under CC BY-SA 3.0, via Wikimedia Commons.*

A dislocated joint usually can be successfully be manipulated (through pulling, twisting, etc.) into its normal position only by a trained medical professional. This procedure is called a reduction, as the displacement is reduced by bringing the bones back into normal alignment. Trying to reduce a joint without any training could substantially worsen the injury. Manipulating the bones back into position can be a very painful process, therefore people are given pain relievers, sedatives, and/or an anesthetic before the procedure, depending on the severity and location of the injury. Following reduction of the joint, a PRICE regimen is recommended: protection (immobilization), rest, ice, compression (pressure), and elevation.

Review Questions

Query 7.6.1

This interactive element is not available in this format. Visit the link or scan the QR code to access it online.

View this Interactive Content online

Critical Thinking Questions

Query 7.6.2

This interactive element is not available in this format. Visit the link or scan the QR code to access it online.

View this Interactive Content online

Glossary

Query 7.6.3

This interactive element is not available in this format. Visit the link or scan the QR code to access it online.

View this Interactive Content online

Contributors and Attributions

OpenStax Anatomy & Physiology (CC BY 4.0). Access for free at https://openstax.org/books/anatomy-and-physiology

This page titled 7.6: Diseases and Injuries of Joints is shared under a CC BY-NC-SA 4.0 license and was authored, remixed, and/or curated by Jennifer Lange et al..

- 8.8: Development of Joints by Whitney Menefee, Julie Jenks, Chiara Mazzasette, and Kim-Leiloni Nguyen is licensed CC BY 4.0.
- 8.5: Synovial Joints by Whitney Menefee, Julie Jenks, Chiara Mazzasette, and Kim-Leiloni Nguyen is licensed CC BY 4.0.
- 8.7: Anatomy of Selected Synovial Joints by Whitney Menefee, Julie Jenks, Chiara Mazzasette, and Kim-Leiloni Nguyen is licensed CC BY 4.0.

7.7: Anatomical Atlas - Joints

A compendium of anatomical images: slides, models, and/or cadavers.

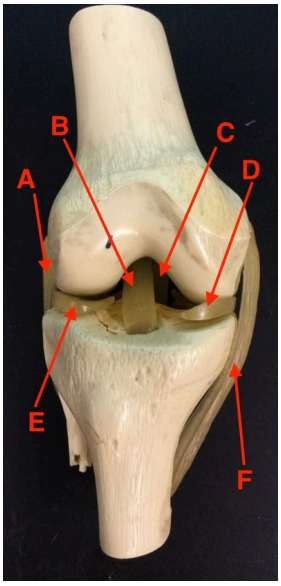

Image Credit

"Model of Knee Joint Anterior View - Atlas" by Jennifer Lange is licensed under CC BY-NC-SA 4.0.

Answer Key (click to show/hide answers)

A - lateral (fibular) collateral ligament

B - anterior cruciate ligament

C - posterior cruciate ligament

D - medial meniscus

E - lateral meniscus

F - medial (tibial) collateral ligament

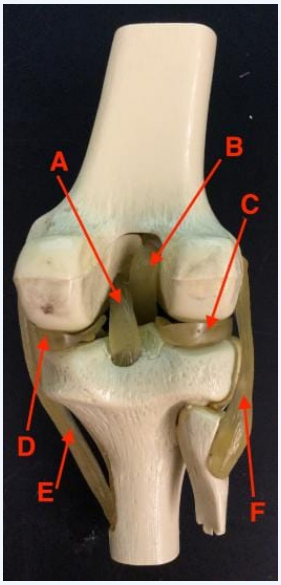

Image Credit

"Model of Knee Joint Posterior View - Atlas" by Jennifer Lange is licensed under CC BY-NC-SA 4.0.

Answer Key (click to show/hide answers)

A - posterior cruciate ligament

B - anterior cruciate ligament

C - lateral meniscus

D - medial meniscus

E - medial (tibial) collateral ligament

F - lateral (fibular) collateral ligament

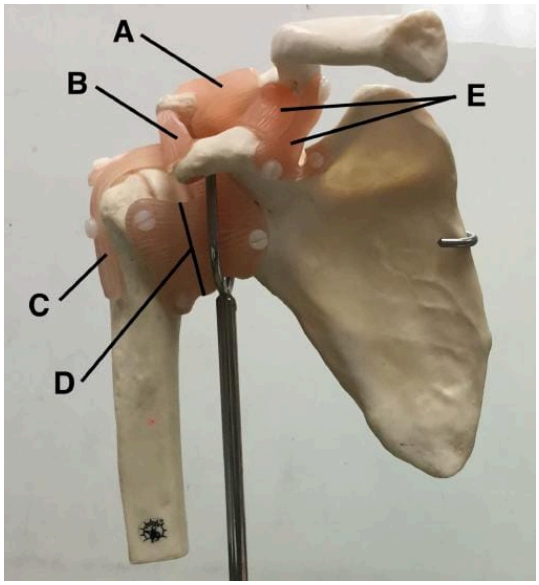

Image Credit

"Model of Shoulder Joint Anterior View - Atlas" by Jennifer Lange is licensed under CC BY-NC-SA 4.0.

Answer Key (click to show/hide answers)

A - acromioclavicular ligament

B - coracoacromial ligament

C - biceps brachii tendon

D - joint capsule and glenohumeral ligaments

E - coracoclavicular ligaments

For each joint give: 1) name, 2) structural classification, and 3) functional classification.

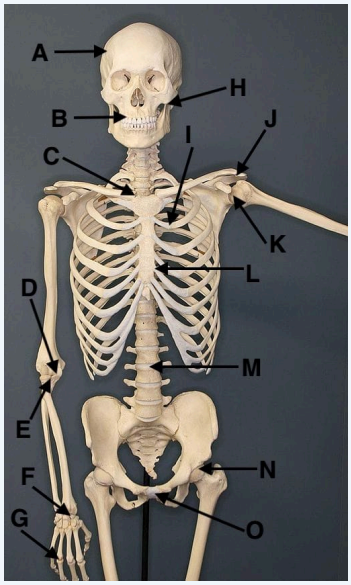

Image Credit

"Human Skeleton Joints - Atlas" by Jennifer Lange is licensed under CC BY-NC-SA 4.0., labeling of original image by Sklmsta, via Wikimedia Commons.)

Answer Key (click to show/hide answers)

A - squamous suture, fibrous - suture, synarthrosis

B - tooth (peg) and socket, fibrous - gomphosis, synarthrosis

C - sternoclavicular, synovial - saddle, diarthrosis

D - elbow (humeroulnar), synovial - hinge, diarthrosis

E - proximal radioulnar, synovial - pivot, diarthrosis

F - wrist (radiocarpal), synovial - condyloid, diarthrosis

G - knuckles (metacarpophalangeal), synovial, diarthrosis

H - temporomandibular, synovial - condyloid and hinge, diarthrosis

I - costochondral, cartilaginous - synchondrosis, synarthrosis

J - acromioclavicular, synovial - plane, diarthrosis

K - shoulder (glenohumeral), synovial - ball & socket, diarthrosis

L - sternocostal, synovial - plane, diarthrosis

M - intervertebral disc, cartilaginous - symphysis, amphiarthrosis

N - hip, synovial - ball & socket, diarthrosis

	O - pubic symphysis, cartilaginous - symphysis, amphiarthrosis

This page titled 7.7: Anatomical Atlas - Joints is shared under a CC BY-NC-SA 4.0 license and was authored, remixed, and/or curated by Jennifer Lange et al..

7.8: Practice Practical - Joints

To answer each of the following questions, type your answer into the box(es).

Query 7.8.1

This interactive element is not available in this format. Visit the link or scan the QR code to access it online.

View this Interactive Content online

Query 7.8.1

This interactive element is not available in this format. Visit the link or scan the QR code to access it online.

View this Interactive Content online



Query 7.8.1

This interactive element is not available in this format. Visit the link or scan the QR code to access it online.

View this Interactive Content online

Query 7.8.1

This interactive element is not available in this format. Visit the link or scan the QR code to access it online.

View this Interactive Content online

Query 7.8.1

This interactive element is not available in this format. Visit the link or scan the QR code to access it online.

View this Interactive Content online



Query 7.8.1

This interactive element is not available in this format. Visit the link or scan the QR code to access it online.

View this Interactive Content online

Query 7.8.1

This interactive element is not available in this format. Visit the link or scan the QR code to access it online.

View this Interactive Content online

Query 7.8.1

This interactive element is not available in this format. Visit the link or scan the QR code to access it online.

View this Interactive Content online

This page titled 7.8: Practice Practical - Joints is shared under a CC BY-NC-SA 4.0 license and was authored, remixed, and/or curated by Jennifer Lange et al..

8: MUSCLE TISSUES AND MUSCLE STRUCTURE

8.1: Introduction to Muscle Tissue
8.2: Muscle Tissues
8.3: Skeletal Muscle Organ Structure
8.4: Development and Regeneration of Muscle Tissue
8.5: Anatomical Atlas - Muscle Tissues
8.6: Practice Practical- Muscle Tissues

This page titled 8: Muscle Tissues and Muscle Structure is shared under a CC BY-NC-SA 4.0 license and was authored, remixed, and/or curated by Jennifer Lange et al..

- 9: Skeletal Muscle Tissue by Whitney Menefee, Julie Jenks, Chiara Mazzasette, and Kim-Leiloni Nguyen is licensed CC BY 4.0.

8.1: Introduction to Muscle Tissue

Chapter Learning Objectives

After studying this chapter, you will be able to:

- Explain the organization of muscle tissue
- Describe the function and structure of skeletal, cardiac muscle, and smooth muscle
- Explain how muscles work with tendons to move the body
- Describe how muscles contract and relax
- Explain the development and regeneration of muscle tissue

When most people think of muscles, they think of the muscles that are visible just under the skin, particularly of the limbs. These are skeletal muscles, so-named because most of them move the skeleton. But there are two other types of muscle in the body, with distinctly different jobs. Cardiac muscle, found in the heart, functions to pump blood through the circulatory system. Smooth muscle functions in various involuntary movements, such as having one's hair stand on end when cold or frightened, or moving food through the digestive system. This chapter will focus on the structure and function of skeletal muscles.

Figure 8.1.1: Tennis Player. Athletes rely on toned skeletal muscles to supply the force required for movement. (Image credit: "Tennis Player" by Emmanuel Huybrechts is licensed under CC BY 4.0)

Contributors and Attributions

- OpenStax Anatomy & Physiology (CC BY 4.0). Access for free at https://openstax.org/books/anatomy-and-physiology

This page titled 8.1: Introduction to Muscle Tissue is shared under a CC BY-NC-SA 4.0 license and was authored, remixed, and/or curated by Jennifer Lange et al..

- 9.1: Introduction to Muscle Tissue by Whitney Menefee, Julie Jenks, Chiara Mazzasette, and Kim-Leiloni Nguyen is licensed CC BY 4.0.

8.2: Muscle Tissues

By the end of this section, you will be able to:

- Compare and contrast the different types of muscle tissue
- Explain the four functional properties of muscle tissue

Muscle is one of the four primary tissue types of the body, and the body contains three types of muscle tissue: skeletal muscle, cardiac muscle, and smooth muscle (Figure 8.2.1). All muscle tissues have four functional properties in common which include **excitability**, **contractility**, **extensibility**, and **elasticity**.

- **Excitability** - the plasma membrane can change electrical states and send an electrical wave called an action potential along the entire surface of each cell.
- **Contractility** - allows muscle tissue to pull on its attachment points as the cells shorten.
- **Extensibility -** the cells of muscle tissue can stretch or elongate.
- **Elasticity -** following contraction or extension, a muscle can recoil to its original length when relaxed due to elastic proteins.

Muscle Tissue Types

Differences among the three muscle types include the microscopic organization of the intracellular contractile proteins—actin and myosin. The actin and myosin proteins are arranged very regularly in the cytoplasm of individual muscle cells (referred to as **myofibers**) in both skeletal muscle and cardiac muscle, which creates a striped pattern across the width of the cell called **striations**. The striations are visible with a light microscope under high magnification (see Figure $8.2.1.A, B$) as an alternating pattern of light - dark - light - dark - etc. along the entire length of the myofiber. These striations are more prominent in skeletal muscle fibers than in cardiac muscle fibers. Because the actin and myosin are not arranged in such regular fashion in smooth muscle, the cytoplasm of a smooth muscle fiber has a uniform, nonstriated appearance (resulting in the name smooth muscle).

Skeletal Muscle Tissue

Skeletal myofibers are long, striated rods that range from a few millimeters to multiple centimeters, extending beyond the sides of the images in Figure $8.2.1.A$ below (individual cell is outlined). The longest muscle in the body is the sartorius that has myofibers that are, on average, 42 centimeters/16.5 inches long! Skeletal muscle comprises approximately 40% of our body weight and contains 50 to 75% of all body proteins. Due to the need to conduct the functioning of such a large cell, each myofiber has many nuclei. The longer the fiber, the more nuclei it has. These nuclei are pushed to the edges of the cell to accommodate all of the intracellular proteins (as indicated by the arrows in Figure $8.2.1.A2$). Skeletal muscle is under voluntary control, so any muscular contraction that you can consciously decide to contract or relax has skeletal muscle in it. This includes all of the body's muscles that move the skeleton and the skin, including your muscles of respiration, as well as some of the body's tubular organs: anal sphincters, urinary sphincters, and your throat. Your tongue also contains skeletal muscle!

A. Skeletal Muscle @ 100x and @ 400x (longitudinal section)	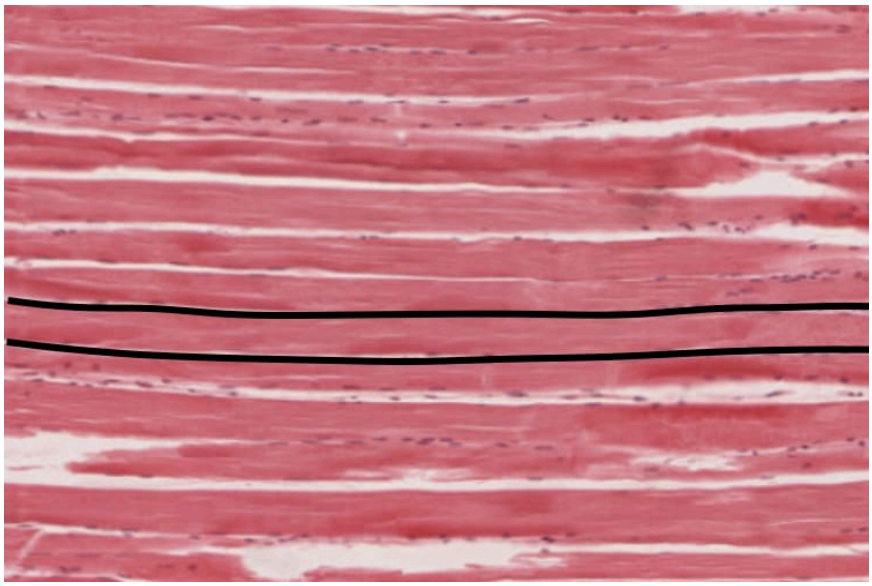	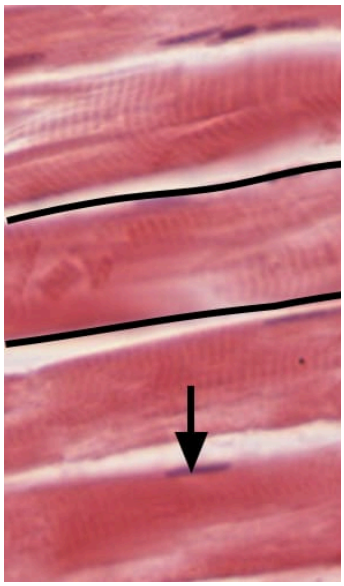
B. Cardiac Muscle @ 400x (longitudinal section)	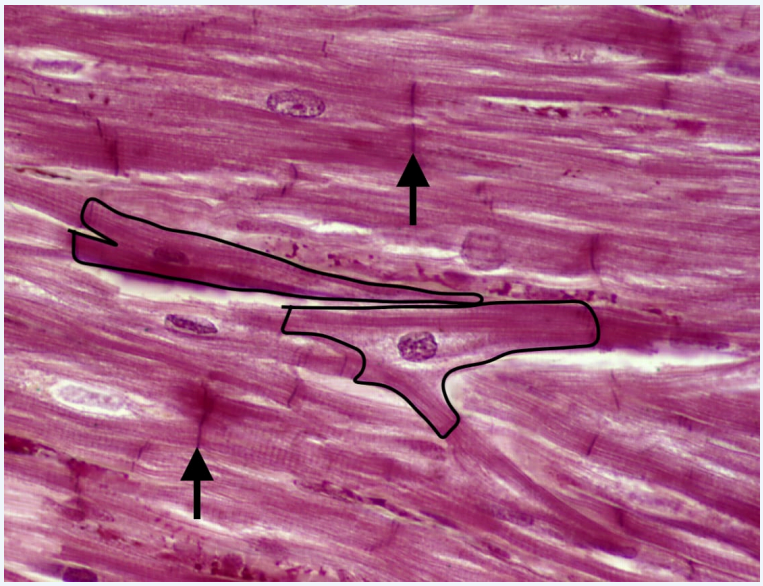	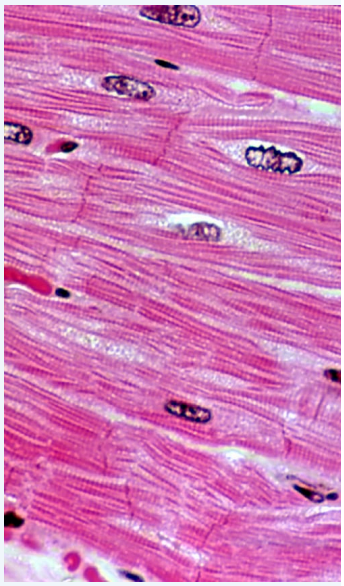

C. Smooth Muscle @ 400x (longitudinal and cross sections)	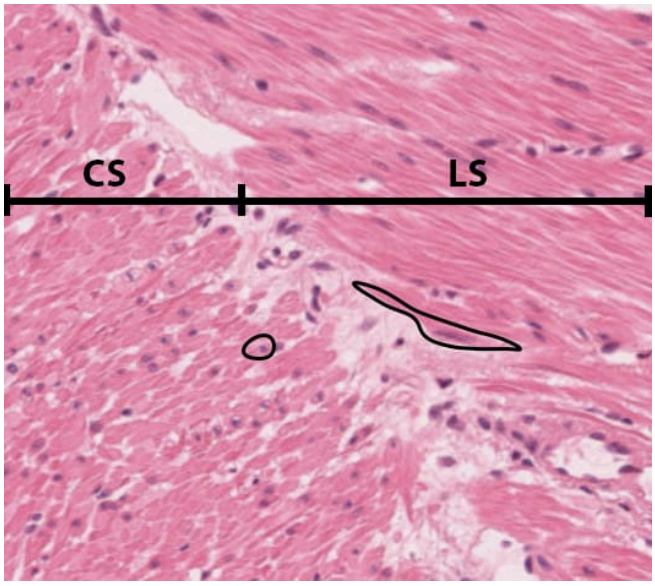	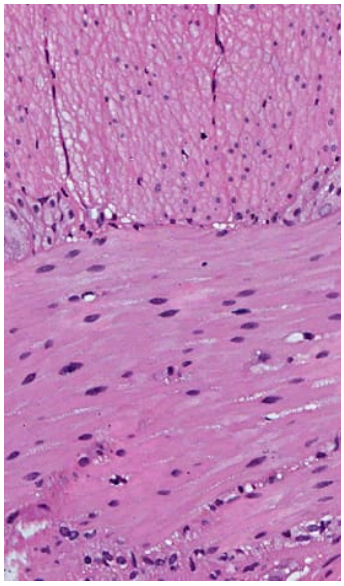

Figure 8.2.1. The Three Types of Muscle Tissue. The body contains three types of muscle tissue: A. skeletal muscle, B. cardiac muscle, C. smooth muscle. *(Image credits: Types of Muscle Tissue by Jennifer Lange are licensed under CC-BY-SA-NC 4.0. Micrographs A1, A2, and C1 provided by the Regents of University of Michigan Medical School, micrographs B1, B2, and C2 provided by Virginia Commonwealth University.)*

Cardiac Muscle Tissue

Cardiac muscle tissue is only found in the heart. Highly coordinated contractions of cardiac muscle pump blood into the vessels of the circulatory system. Cardiac muscle fibers are shorter than skeletal muscle fibers and usually contain only one nucleus, which is located in the central region of the cell. Cardiac muscle fibers also possess many mitochondria and myoglobin, as ATP is produced primarily through aerobic metabolism. Cardiac muscle fibers cells also are extensively branched and are physically and functionally connected to one another at their ends by specialized cell junctions call **intercalated disks** (indicated by arrows in Figure 8.2.1.*B*). Intercalated disks are part of the sarcolemma and contain two structures important in cardiac muscle contraction: **gap junctions** and **desmosomes** (Figure 8.2.2). A gap junction forms channels between adjacent cardiac muscle fibers that allows the electrical signal to flow quickly from one cardiac myofiber to the next. This joining of cells allows coordinated contraction of the entire heart. The remainder of the intercalated disk is composed of desmosomes. A desmosome is a cell structure that anchors the ends of cardiac muscle fibers together so the cells do not pull apart during the stress of individual fibers contracting.

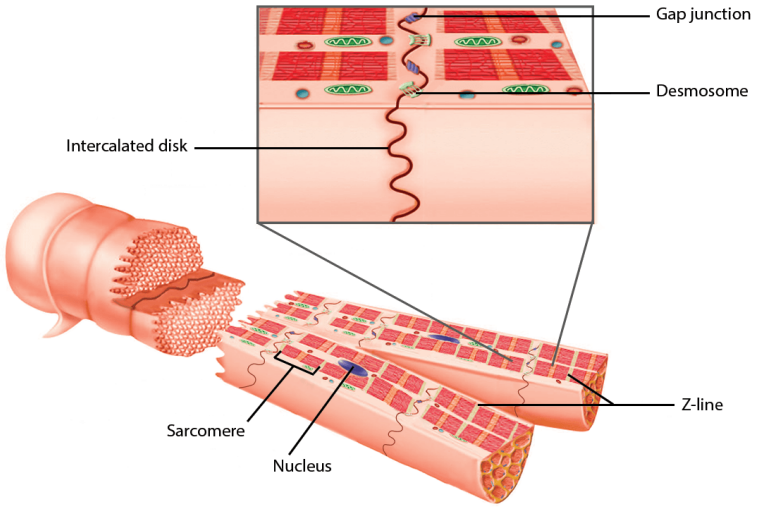

Figure 8.2.2: Cardiac Muscle. Cardiac myofibers are branched so they can connect to mutliple neighboring cells at intercalated disks. Intercalated disks are specialized cell junctions unique to cardiac muscle tissue that contain gap junctions and desmosomes. *(Image credit: "Cardiac Muscle" by Jennifer Lange is licensed under CC-BY-SA-NC 4.0, modification of original work by Cenveo.)*

Smooth Muscle Tissue

Smooth muscle (so-named because the cells do not have striations) is present in the walls of hollow organs like the urinary bladder, uterus, stomach, intestines, and in the walls of passageways, such as the arteries and veins of the circulatory system, and the tracts of the respiratory, urinary, and reproductive systems. Smooth muscle is also present in the eyes, where it functions to change the size of the iris and alter the shape of the lens; and in the skin where it causes hair to stand erect in response to cold temperature or fear. Smooth muscle fibers are spindle-shaped (wide in the middle and tapered at both ends, somewhat like a football) and have a single nucleus (see outlined cells in (Figure 8.2.1.C and in (Figure 8.2.3). They range from about 30 to 200 μm (thousands of times shorter than skeletal muscle fibers), and they produce their own connective tissue, endomysium.

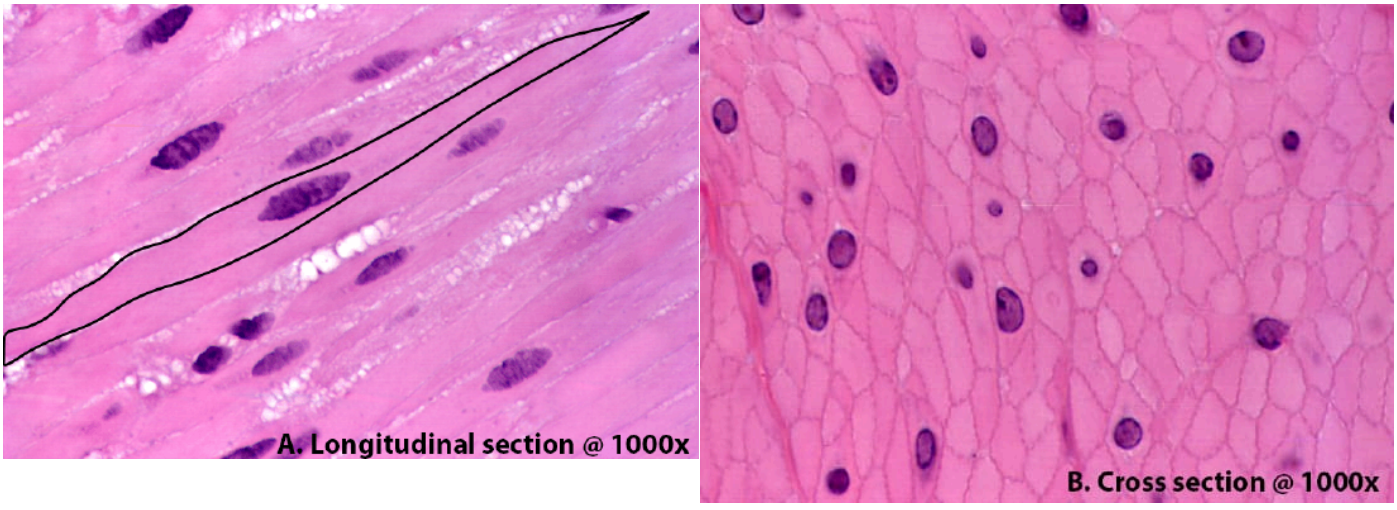

Figure 8.2.3: Smooth Muscle Fibers. Smooth muscle has spindle shaped cells that taper to points at the ends (A) and have a centrally located nucleus. Because of this shape, when viewed in cross section the myofibers will appear to have different diameters and only those cut through the center will show the nucleus (B). *(Image credit: "Smooth Muscle Fibers" by Jennifer Lange is licensed under CC-BY-SA-NC 4.0. Micrographs from Virginia Commonwealth University.)*

Although they do not have striations, smooth muscle fibers do have actin and myosin contractile proteins. These contractile proteins are connected to **dense bodies** that are fastened to the sarcolemma. Dense bodies also have cord-like **intermediate filaments** attached to them (Figure 8.2.4). When contraction occurs the contractile proteins pull on the dense bodies, which

then pull on the intermediate filaments networks throughout the sarcoplasm. This arrangement causes the entire muscle fiber to contract in a manner whereby the ends are pulled toward the center, causing the midsection to bulge in a corkscrew motion.

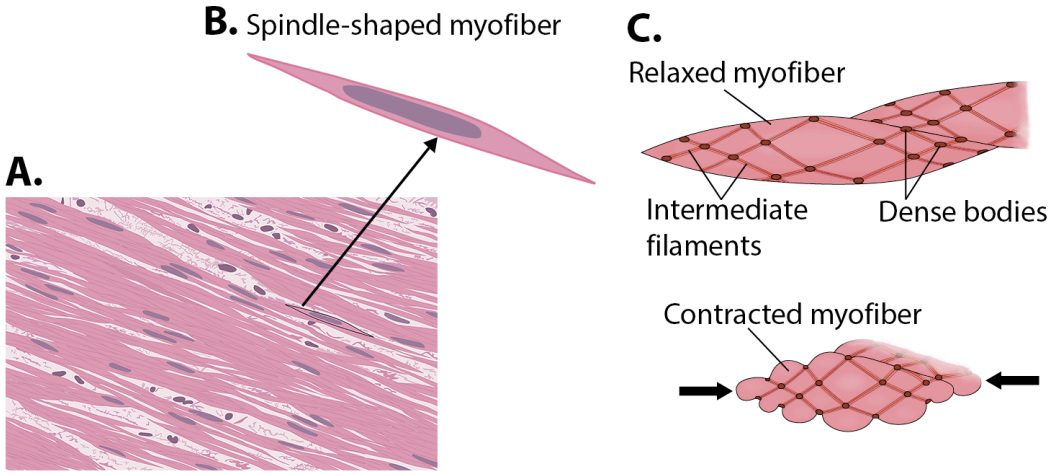

Figure 8.2.4: Smooth myofibers are spindle shaped cells that pinch inward from all directions when contracting. *(Image credit: "Smooth Myofiber Contraction" by Jennifer Lange and Justin Greene is licensed under CC-BY-SA-NC 4.0, image C is modification of original by OpenStax.)*

Concept Review

Muscle is the tissue in animals that allows for active movement of the body or materials within the body. There are three types of muscle tissue: skeletal muscle, cardiac muscle, and smooth muscle.

- Most of the body's skeletal muscle produces voluntary movement by acting on the skeleton. It has:
  - striations
  - long, rod-shaped cells
  - multiple peripheral nuclei
- Cardiac muscle is found in the wall of the heart and involuntarily pumps blood through the circulatory system. It has:
  - striations
  - short, rectangular, branched cells
  - single, central nucleus
  - intercalated discs
- Smooth muscle is found in the skin and in the walls of internal tubular organs where it involuntarily assists in moving materials. It has:
  - no striations
  - spindle-shaped cells
  - single, central nucleus

Review Questions

Query 8.2.1

This interactive element is not available in this format. Visit the link or scan the QR code to access it online.

View this Interactive Content online

Critical Thinking Questions

Query 8.2.2

This interactive element is not available in this format. Visit the link or scan the QR code to access it online.

View this Interactive Content online

Glossary

Query 8.2.3

This interactive element is not available in this format. Visit the link or scan the QR code to access it online.

View this Interactive Content online

Contributors and Attributions

- OpenStax Anatomy & Physiology (CC BY 4.0). Access for free at https://openstax.org/books/anatomy-and-physiology

This page titled 8.2: Muscle Tissues is shared under a CC BY-NC-SA 4.0 license and was authored, remixed, and/or curated by Jennifer Lange et al..

- 9.2: Overview of Muscle Tissues by Whitney Menefee, Julie Jenks, Chiara Mazzasette, and Kim-Leiloni Nguyen is licensed CC BY 4.0.

8.3: Skeletal Muscle Organ Structure

By the end of this section, you will be able to:

- Describe the layers of connective tissues and how they package skeletal muscle
- Explain how muscles work with tendons to move the body
- Identify and describe the microscopic anatomy of a muscle fiber and a sarcomere

The best-known feature of skeletal muscle is its ability to contract and cause movement. Skeletal muscles act not only to produce movement but also to stop movement, such as resisting gravity to maintain posture. Small, constant adjustments of skeletal muscles are needed to hold a body upright or balanced in any position. Muscles also prevent excess movement of the bones and joints, maintaining skeletal stability and preventing structural damage or deformation. Joints can become misaligned or dislocated by excessive or inappropriate forces applied to associated bones; muscles work to keep joints stable. Skeletal muscles are located throughout the body at the openings of internal tracts to control the movement of various substances. These muscles allow functions, such as swallowing, urination, and defecation, to be under voluntary control. Skeletal muscles also protect internal organs (particularly abdominal and pelvic organs) by acting as an external barrier or shield to external trauma and by supporting the weight of the organs.

Skeletal muscles contribute to the maintenance of homeostasis in the body by generating heat. Muscle contraction requires energy, and when ATP is broken down, heat is produced. This heat is very noticeable during exercise, when sustained muscle movement causes body temperature to rise, and in cases of extreme cold, when shivering produces random skeletal muscle contractions to generate heat.

Organ Structure

Each skeletal muscle is an organ consisting of multiple integrated tissues acting together to cause movement: skeletal muscle and three layers of proper connective tissue. The connective tissue layers (called “mysia”) provide structure to the muscle as a whole and also compartmentalize the muscle fibers within the muscle (Figure 8.3.1) and (Figure 8.3.2). Wrapping around the organ is a sheath of dense irregular connective tissue called the **epimysium** that allows a muscle to contract and move powerfully while maintaining its structural integrity. The epimysium also separates muscle from other tissues and organs in the area, allowing the muscle to move independently. Within the epimysium skeletal muscle fibers are organized into bundles, called **fascicles**, by a middle layer of dense irregular connective tissue making up the **perimysium**. This fascicular organization is common in muscles of the limbs; it allows the nervous system to trigger a specific movement of a muscle by activating a subset of muscle fibers within a bundle, or fascicle, of the muscle. Inside each fascicle, each muscle fiber is encased in a thin areolar connective tissue layer called the **endomysium**. The endomysium contains the extracellular fluid and nutrients to support the muscle fiber. These nutrients are supplied via blood capillaries located in the areolar tissue.

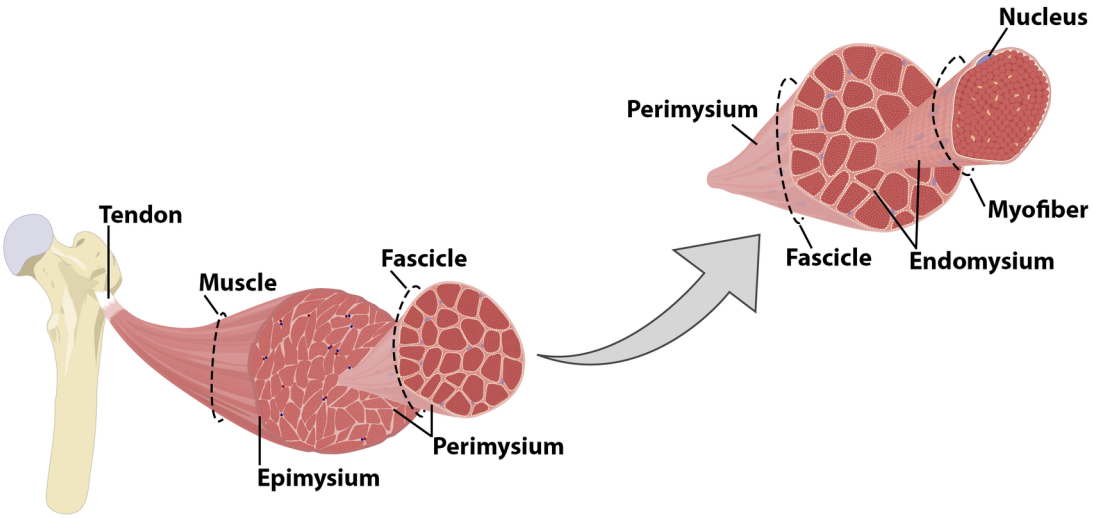

Figure 8.3.1: Skeletal Muscle Organ Structure. Each level of the organization of a skeletal muscle is wrapped in a connective tissue layer: the cell (myofiber) is surrounded by the endomysium, the bundle of cells (muscle fascicle) is surrounded by the perimysium, and the organ (muscle) is surrounded by the epimysium. *(Image credit: "Skeletal Muscle Organ Structure" by Justin Greene is licensed under CC BY-NC-SA 4.0).*

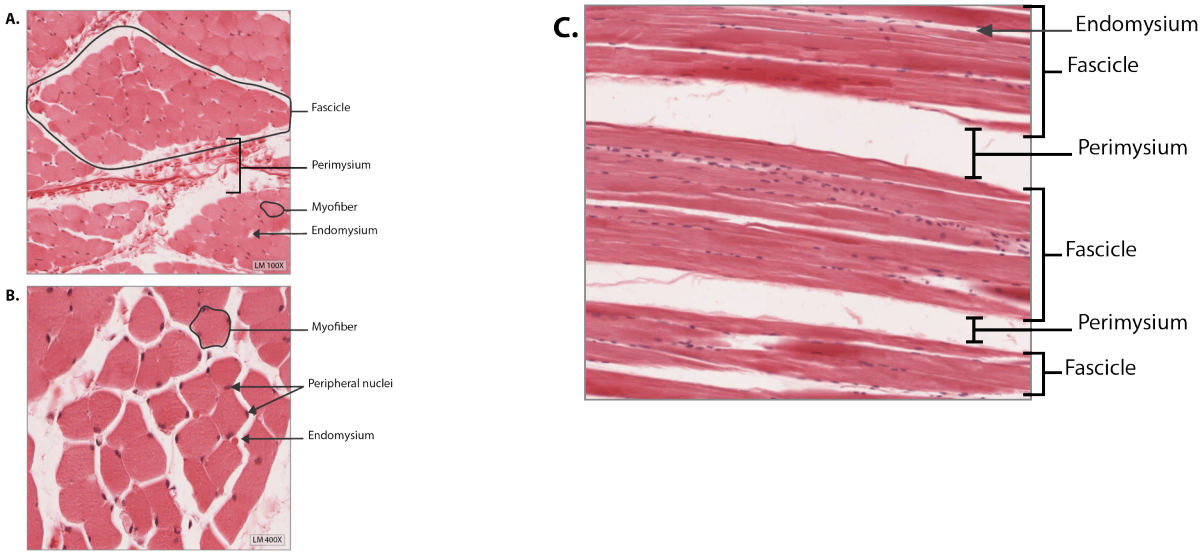

Figure 8.3.2: Histology of Skeletal Muscles in Cross and Long-Sections. Muscles are held together by and transfer force through their connective tissue layers. The perimysium surround the fascicles and can be seen between them. The endomysium surrounds the myofibers and appears thinner than the perimysium. A. Slide cross-section at 100x, B. Slide cross-section at 400x, C. Slide long-section at 100x. *(Image credit: "Histology of Skeletal Muscle" by Jennifer Lange, based on micrographs provided by the Regents of the University of Michigan under CC-BY-NC-SA 3.0)*

Skeletal muscles have **tendons** that attach to bones and transfer the force of contraction to the skeleton. The collagen in the three tissue layers intertwines and integrates with the collagen of a tendon, straightening to form a cord of dense regular connective tissue. At the other end of the tendon, the collagen incorporates into periosteum becoming dense irregular connective tissue once more. Tension created by contraction of the muscle fibers is transferred though the mysia, to the tendon, and then to the periosteum to pull on the bone to move the skeleton. In other places, the mysia may fuse with a broad, tendon-like sheet called an **aponeurosis**, or to fascia, the connective tissue between skin and bones. The broad sheet of connective tissue in the lower back that the latissimus dorsi muscles (the “lats”) fuse into is an example of an aponeurosis.

Every skeletal muscle is richly supplied by blood vessels for nourishment, oxygen delivery, and waste removal. In addition, every muscle fiber in a skeletal muscle is supplied by the axon branch of a somatic motor neuron, which signals the fiber to contract. Unlike cardiac and smooth muscle, the only way to functionally contract a skeletal muscle is through signaling from the nervous system.

Skeletal Muscle Fibers

Because skeletal muscle cells are long and cylindrical, they are commonly referred to as **skeletal muscle fibers** or **skeletal myofibers**. Specific terminology associated with myofibers is rooted in the Greek *sarco*, which means "flesh." The plasma membrane of muscle fibers is called the **sarcolemma** and the cytoplasm is referred to as **sarcoplasm.** Skeletal myofibers can be quite large for human cells, with diameters up to 100 μm and lengths up to 30 cm (11.8 in). During early development, embryonic myoblasts, each with its own nucleus, fuse with up to hundreds of other myoblasts to form the multinucleated myofibers. Multiple nuclei means multiple copies of genes, permitting the production of the large amounts of proteins and enzymes needed for muscle contraction along the length of the entire muscle fiber. Multiple nuclei also means mitosis would be extremely complicated, so skeletal myofibers do not divide.

Within the sarcoplasm of each muscle fiber are **myofibrils**, rods of protein that run the entire length of the muscle fiber and attach to the sarcolemma at its end (Figure 8.3.3). Each myofibril is composed of a bundle of contractile **thin and thick myofilaments**, along with other structural and elastic proteins. As myofibrils contract, the entire muscle cell contracts. Because myofibrils are only approximately 1.2 μm in diameter, hundreds to thousands can be found inside one muscle fiber.

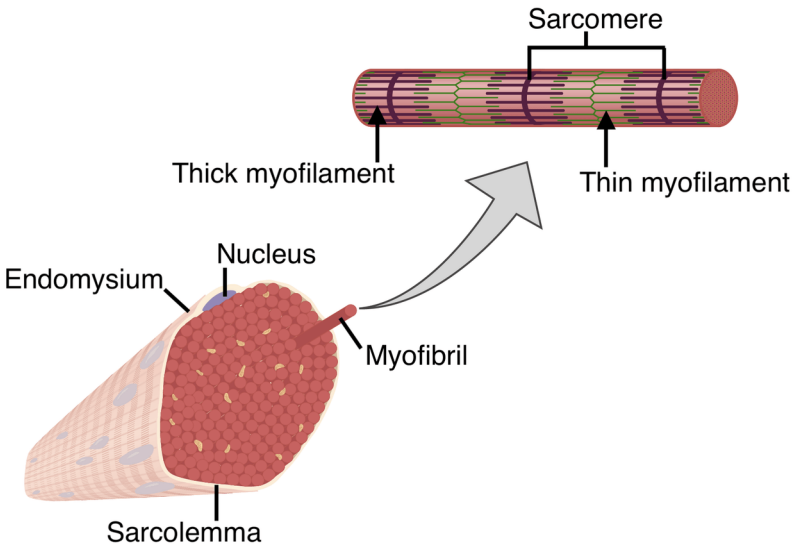

Figure 8.3.3: Myofibrils and Myofilaments. With each cell are multiple rods of proteins that contain two types of myofilaments - thin ones and thick ones. *(Image credit: "Myofibrils and Myofilaments" by Justin Greene is licensed under CC BY-NC-SA 4.0, myofibril enlargement based on original by OpenStax.)*

The Sarcomere, Myofilaments and Protein Organization

The striated appearance of skeletal muscle fibers is due to the arrangement of the thin and thick myofilaments in sequential order from one end of the muscle fiber to the other. Each segment of these myofilaments and their regulatory proteins, connected on each end to a protein network called the **Z-line** (or Z-disc), is called a **sarcomere**. The sarcomere is the functional unit of the muscle fiber and runs from one Z-line to the next Z-line. A chain of thousands of repeating sarcomeres forms the long tube-like myofibrils.

Each sarcomere is approximately 2 μm in length with a three-dimensional cylinder-like arrangement. The repeating pattern of the myofilaments, along with other proteins, within the sarcomere gives rise to very distinctive regions and structures (Figure 8.3.5). Each sarcomere is bordered by Z-lines to which the thin myofilaments are anchored. The central **M-line** anchors the thick filaments, which are composed of bundles of a single contractile protein called **myosin**. Each thick filaments contains approximately 300 myosin strands with their mobile **heads** protruding on the outer surface. Thin filaments contain two strands of

the contractile protein **actin** that are twisted around each other and two regulatory proteins, **troponin** and **tropomyosin**, whose position determines if myosin heads can bind to actin. The difference in protein mass between the two filaments is what causes the striated appearance of skeletal muscle fibers as their positions alternate along the myofibril (Figure 8.3.4).

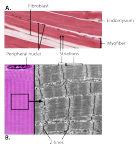

Figure 8.3.4: Skeletal Muscle Striations. The striated pattern of alternating light and dark staining bands results from the regular arrangement of the myofilaments: areas with myosin stain darkly and those without stain lightly. This banding pattern can be visible with a light microscope at 400x (image A) and becomes easier to see at higher magnifications. Image B shows a light microscope at 2,000x as well as a transmission electron microscope (TEM) at 15,000x. With the TEM you can also clearly see the Z-lines. *(Image credit: "Skeletal Muscle Striations" by Jennifer Lange is licensed under CC BY-NC-SA 4.0, slide A provided by the Regents of the University of Michigan Medical School under CC BY-NC-SA 4.0 © 2022; slide B micrographs provided by Virginia Commonwealth University under CC BY-NC-SA 4.0)*

The zone immediately surrounding the Z-lines is known as the **I band**, or light band, because only thin filaments are present (Figure 8.3.5). The thin composition of actin makes it difficult to see, hence the name the light band. The myosin is anchored to the central M line, from whence it projects toward, but not all to way to, the Z-lines. The area of the sarcomere where myosin is present is known as the **A band**, or dark band. There are some areas where thin and thick myofilaments are both present, known as the zone of overlap. The area in which no overlap occurs is the **H zone,** where only myosin is present. The alternation of I bands and A bands along the length of the myofibril, and thus the myofiber, is what gives the cell its striated appearance.

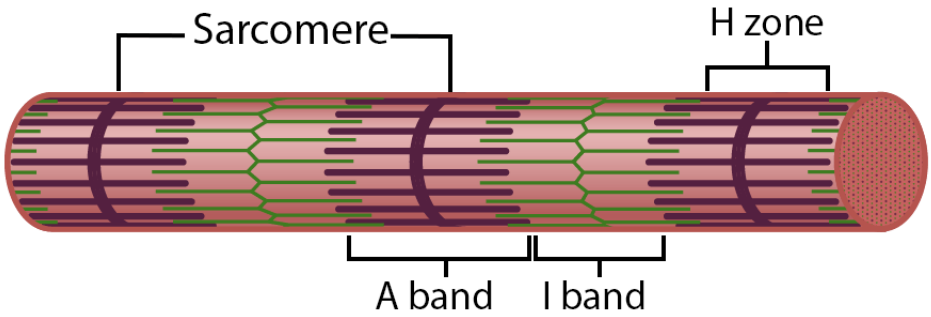

Figure 8.3.5: Myofibril and the Sarcomere. Myofibrils are composed of chains of thousands of repeating sarcomeres. The alternating I bands and A bands give the myofibril (and the myofiber) its striated appearance. *(Image credit: "Myofibril and the Sarcomere" by Justin Greene is licensed under CC BY-NC-SA 4.0, based on original by Openstax.)*

As mentioned above, actin and myosin are the proteins that are responsible for muscular contraction. The structural differences between these two myofilaments not only leads to the striated appearance of skeletal muscle tissue, but also to the ability of the two to work together to produce the overall function of muscle contraction.

Actin strands are formed by multiple spherical actin subunits, each of which contain a myosin binding site (Figure 8.3.6). In a relaxed muscle, the binding sites remain shielded by the troponin-tropomyosin regulatory complex. The tropomyosin filaments run the length of the actin, covering all of the binding sites. These filaments are held in place by troponin, which is also responsible for shifting the position of tropomyosin to uncover the binding sites in the presence of calcium ions.

Each myosin filament has two specific regions, the tail and the head (Figure 8.3.6). Connecting these two regions is a flexible hinge region. The tails are linked together into a bundle, while the heads take an active role in the muscle contraction process by binding to and pulling on actin. Each head contains an actin binding site as well as a binding site for the ATP molecules that will provide the energy needed for the contraction cycle to occur.

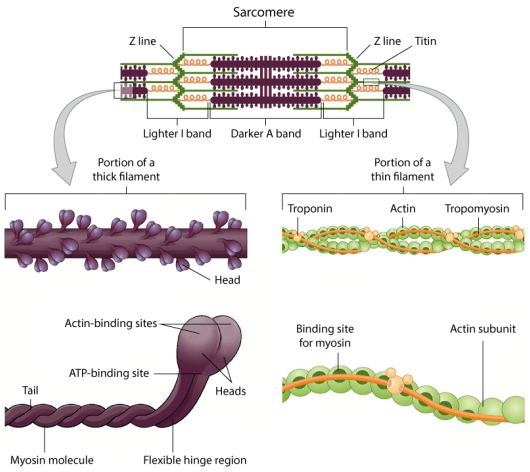

Figure 8.3.6: Myofilaments. The sarcomere, the region from one Z-line to the next Z-line, is the functional unit of a skeletal muscle fiber and is composed of a repeating arrangements of actin and myosin, along with other proteins. *(Image credit: "Sarcomere and Myofilaments" by Mark Schaeffer is licensed under CC BY-NC-SA 4.0, modification of original by Openstax.)*

Surrounding each myofibril is the **sarcoplasmic reticulum (SR),** the specialized smooth endoplasmic reticulum of myofibers, which stores, releases, and retrieves the calcium ions (Ca^{++}) needed for contraction to occur (Figure 8.3.7). The signal from a motor neuron stimulates the release of calcium ions (Ca^{++}) from its storage in the cell's sarcoplasmic reticulum. For the neuron's signal to reach the membrane of the SR there are periodic invaginations in the sarcolemma, called **T-tubules** ("T" stands for "transverse"). You will recall that the diameter of a muscle fiber can be up to 100 μm, so these T-tubules ensure that the cell membrane can get close to the SR in the sarcoplasm. On each side of the T-tubule is a **terminal cisterna** (plural - cisternae), an enlarged region of the SR that contains high concentrations of calcium ions. The arrangement of a T-tubule with the terminal cisternae of the SR on either side is called a **triad** (Figure 8.3.7). The triad encircles the cylindrical structure of the myofibril.

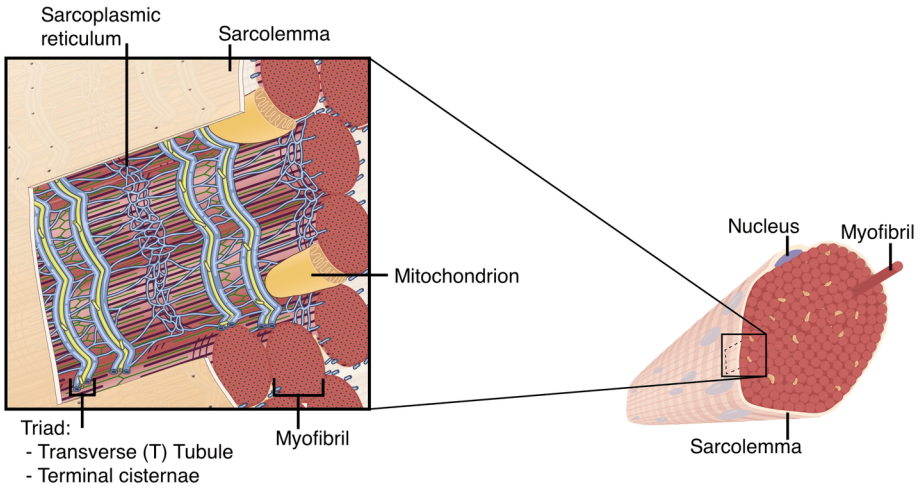

Figure 8.3.7: The Triad. Two terminal cisternae (part of sarcoplasmic reticulum) and one T-tubule comprise a triad—a "threesome" of membranes, with those of sarcoplasmic reticulum on both sides of the T-tubule sandwiched between them. *(Image credit: "Skeletal Myofiber Structure" by Justin Greene is licensed under CC BY-NC-SA 4.0.)*

The Neuromuscular Junction

The specialized site of the skeletal muscle where a motor neuron's axon terminal meets the muscle fiber is the **neuromuscular junction (NMJ)** (Figure 8.3.8). The axon terminal releases a chemical messenger, **acetylcholine (ACh),** that diffuses across the minute space between the two cells and bind to receptors embedded in the sarcolemma of the myofiber. These ACh receptors are only located within the NMJ region called the **motor end-plate**. Every myofiber in every skeletal muscle is innervated by a motor neuron at a NMJ. Excitation signals from the neuron are the only way to functionally activate the fiber to contract by allowing the myosin heads to bind to actin. (Although you could contract the muscles using electrical current or molecules, such as nicotine, that mimic the molecular structure of Ach.)

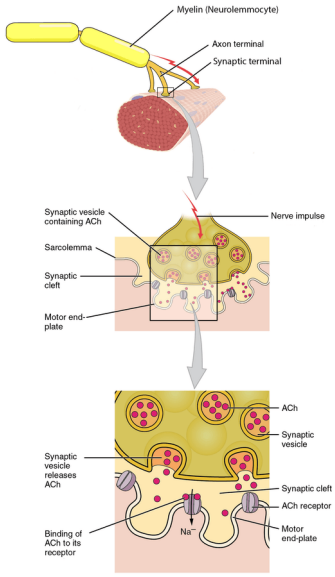

Figure 8.3.8: Motor End-Plate and Innervation. At the NMJ, the axon terminal releases ACh. The motor end-plate is the location of the ACh-receptors in the muscle fiber sarcolemma. When ACh molecules are released, they diffuse across a tiny space called the synaptic cleft and bind to the receptors. *(Image credit: "Motor Endplate and Innervation" by Jennifer Lange and Justin Greene is licensed under CC BY-NC-SA 4.0, modification of original by Openstax.)*

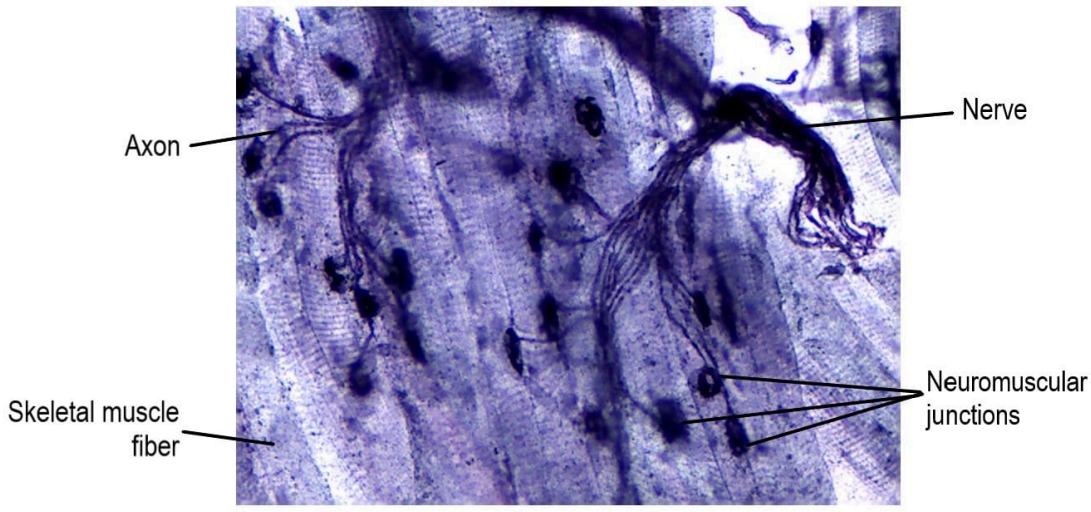

Figure 8.3.9: Neuromuscular Junctions. Every skeletal muscle fiber is innervated by a motor neuron at the neuromuscular junction. Signals from motor neurons initiate the process of muscle contraction. *(Image credit: "Motor End Plate - Labeled" by Whitney Menefee is licensed under CC BY-SA 4.0 / A derivative from the original work.)*

Muscle Shortening and Lengthening

When you contract your muscles you will feel them tightening up and they will bulge a bit in the middle, this is because the muscle is getting shorter and, therefore, fatter. (In physiology you will learn about lengthening contractions, which is an oxymoron since the definition of "to contract" means to shorten.) When you stretch out your muscles before you exercise or to try to ease muscle tension, you are physically lengthening the muscle. These alterations in the size and dimensions of the entire muscle are reflected in each of its structural levels: when the muscle shortens the fascicles, myofibers, and myofibrils also become shorter. The structure that stays the same size is the myofilaments. Recall from above that the functional unit of a muscle is the sarcomere and that the function of a muscle is to contract/relax/stretch, this means the sarcomere is the contractile unit that is physically becoming shorter.

During shortening contractions the Z-lines of the sarcomere are drawn closer together by the interaction of myosin and actin while the protein filaments stay the same length but shift relative positions, with the the area of overlap of the two filaments increasing. When stretching the muscle, the Z-lines are drawn farther apart and have a smaller area of overlapping filaments. The I band, the distance from the end of one thick filament to the next, shortens during a contraction and lengthens when stretched.

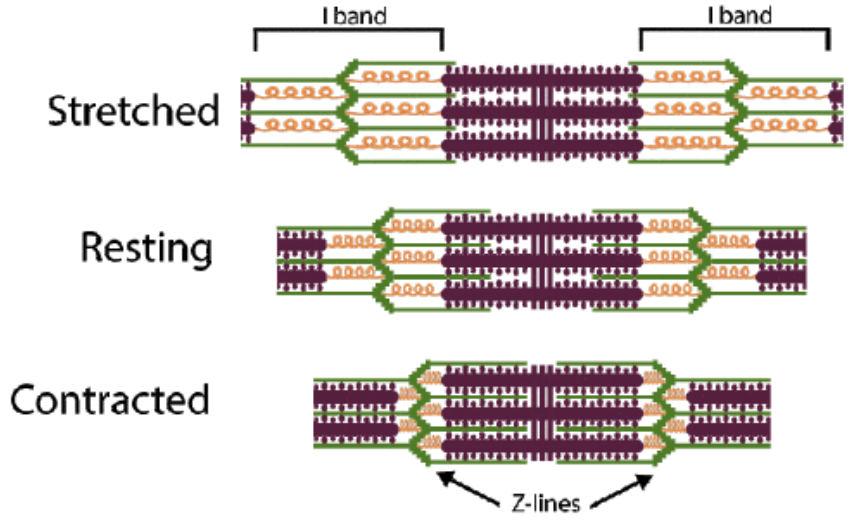

Figure 8.3.10: Sarcomere Length. The change in muscle length results from the cumulative change in the length of the sarcomeres. *(Image credit: "Sarcomere Length" by Mark Schaeffer is licensed under CC BY-NC-SA 4.0, based on original by OpenStax.)*

Concept Review

Skeletal muscles contain connective tissue, blood vessels, and nerves. There are three layers of connective tissue: epimysium, perimysium, and endomysium. Skeletal muscle fibers are organized into groups called fascicles. Blood vessels and nerves enter the connective tissue and branch. Muscles attach to bones directly or through tendons or aponeuroses. Skeletal muscles maintain posture, stabilize joints, support organs, control internal movement, and generate heat.

Skeletal muscle fibers are long, multinucleated cells. The membrane of the cell is the sarcolemma; the cytoplasm of the cell is the sarcoplasm. The sarcoplasmic reticulum (SR) is a form of endoplasmic reticulum that specializes in storing and releasing calcium. Muscle fibers are composed of myofibrils. The banding pattern along the myofibrils, called **striations**, are created by the organization of actin and myosin proteins in functional units called sarcomeres.

Review Questions

Query 8.3.1

This interactive element is not available in this format. Visit the link or scan the QR code to access it online.

View this Interactive Content online

Query 8.3.2

This interactive element is not available in this format. Visit the link or scan the QR code to access it online.

View this Interactive Content online

Critical Thinking Questions

Query 8.3.3

This interactive element is not available in this format. Visit the link or scan the QR code to access it online.

View this Interactive Content online

Query 8.3.4

This interactive element is not available in this format. Visit the link or scan the QR code to access it online.

View this Interactive Content online

Query 8.3.5

This interactive element is not available in this format. Visit the link or scan the QR code to access it online.

View this Interactive Content online

Query 8.3.6

This interactive element is not available in this format. Visit the link or scan the QR code to access it online.

View this Interactive Content online

Glossary

Query 8.3.7

This interactive element is not available in this format. Visit the link or scan the QR code to access it online.

View this Interactive Content online

Contributors and Attributions

- OpenStax Anatomy & Physiology (CC BY 4.0). Access for free at https://openstax.org/books/anatomy-and-physiology

This page titled 8.3: Skeletal Muscle Organ Structure is shared under a CC BY-NC-SA 4.0 license and was authored, remixed, and/or curated by Jennifer Lange et al..

- 9.3: Skeletal Muscle by Whitney Menefee, Julie Jenks, Chiara Mazzasette, and Kim-Leiloni Nguyen is licensed CC BY 4.0.

8.4: Development and Regeneration of Muscle Tissue

By the end of this section, you will be able to:

- Describe the function of satellite cells
- Define fibrosis
- Explain which muscle type has the greatest regeneration ability

Most muscle tissue of the body arises from embryonic mesoderm. Paraxial mesodermal cells adjacent to the neural tube form blocks of cells called **somites**. Skeletal muscles, excluding those of the head and limbs, develop from mesodermal somites, whereas skeletal muscle in the head and limbs develop from general mesoderm. Somites give rise to myoblasts. **Myoblasts** are muscle-forming stem cells that migrate to different regions in the body and then fuse(s) to form a **myotome** (Figure 8.4.1). As a myotome is formed from many different myoblast cells, it contains many nuclei, but has a continuous cytoplasm. This is why skeletal muscle cells are multinucleate, as the nucleus of each contributing myoblast remains intact in the mature skeletal muscle cell. At about 9 weeks, myofilaments are starting to form within the myotome, maturing the myotome into a myofiber. However, cardiac and smooth muscle cells are not multinucleate because the myoblasts that form their cells do not fuse.

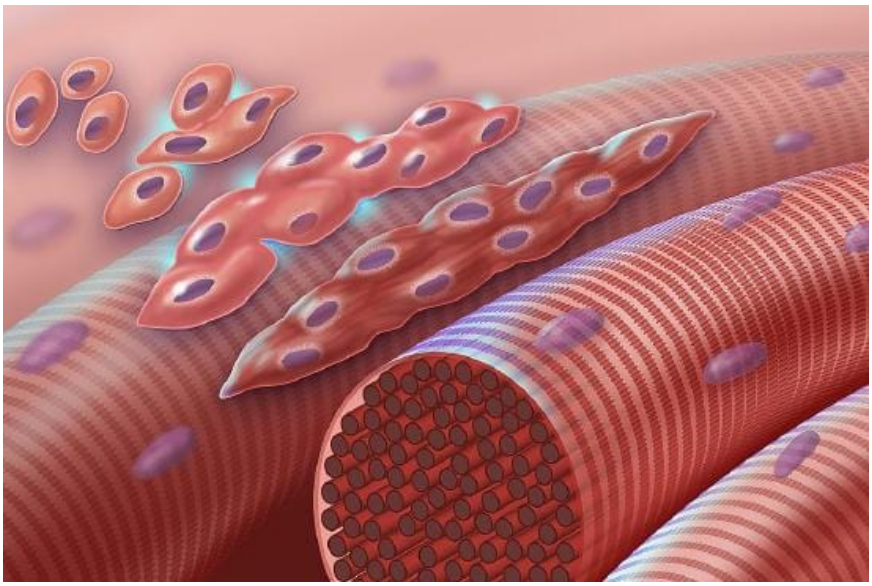

Figure 8.4.1: Myoblasts (early skeletal muscle cells with a single nucleus) fusing together to form myocytes (multinucleated muscle cells) during myogenesis. The myocytes will then mature and produce the internal protein structures of the myofilament. *(Image Credit: "Myoblast Fusion - Myogenesis" by Darryl Leja, National Human Genome Research Institute, National Institutes of Health, Public domain, via Wikimedia Commons).*

Although the number of skeletal muscle cells is set during development, satellite cells help to repair skeletal muscle cells. A **satellite cell** is similar to a myoblast because it is a type of stem cell; however, satellite cells are incorporated into mature myofiber and facilitate the protein synthesis required for repair and growth. These cells are located outside the sarcolemma, in the endomysium, and are stimulated to grow and fuse with muscle cells by growth factors that are released by muscle fibers under certain forms of stress. Satellite cells primarily help to repair damage in living cells, but they can regenerate muscle fibers to a limited extent. If a cell is damaged to a greater extent than can be repaired by satellite cells, the muscle fibers are replaced by scar tissue in a process called **fibrosis**. Because scar tissue cannot contract, muscle that has sustained significant damage loses strength and cannot produce the same amount of power or endurance as it could before being damaged.

Smooth muscle tissue can regenerate from a type of stem cell called a **pericyte**, which is found in some small blood vessels. Pericytes allow smooth muscle cells to regenerate and repair much more readily than skeletal and cardiac muscle tissue. Similar

to skeletal muscle tissue, cardiac muscle does not regenerate to a great extent. Dead cardiac muscle tissue is replaced by scar tissue, which cannot contract. As scar tissue accumulates, the heart loses its ability to pump because of the loss of contractile power. Fibrosis within cardiac tissue can cause electrical signaling disturbances and arrhythmias as well as cardiac failure from the decrease in contractile force. However, some minor regeneration may occur due to stem cells found in the blood that occasionally enter cardiac tissue.

CAREER CONNECTION

Physical Therapist

As muscle cells die, they are not regenerated but instead are replaced by connective tissue and adipose tissue, which do not possess the contractile abilities of muscle tissue. Muscles atrophy when they are not used, and over time if atrophy is prolonged, muscle cells die. It is therefore important that those who are susceptible to muscle atrophy exercise to maintain muscle function and prevent the complete loss of muscle tissue. In extreme cases, when movement is not possible, electrical stimulation can be introduced to a muscle from an external source. This acts as a substitute for endogenous (naturally originating from within) neural stimulation, stimulating the muscle to contract and preventing the loss of proteins that occurs with a lack of use.

Physical therapists work with patients to maintain muscle health. They are trained to target muscles susceptible to atrophy, and to prescribe and monitor exercises designed to stimulate those muscles. There are various causes of atrophy, including mechanical injury, disease, and age. After breaking a limb or undergoing surgery, inflammation and impaired muscle use can lead to atrophy. If the muscles are not exercised, this atrophy can lead to long-term muscle weakness. A stroke can also cause muscle impairment by interrupting neural stimulation to certain muscles. Without neural inputs, these muscles do not contract and thus begin to lose structural proteins. Exercising these muscles can help to restore muscle function and minimize functional impairments. Age-related muscle loss (sarcopenia) is also a target of physical therapy, as exercise can reduce the effects of age-related atrophy and improve muscle function.

The goal of a physical therapist is to improve physical functioning and reduce functional impairments; this is achieved by understanding the cause of muscle impairment and assessing the capabilities of a patient, after which a program to enhance these capabilities is designed. Some factors that are assessed include strength, balance, and endurance, which are continually monitored as exercises are introduced to track improvements in muscle function. Physical therapists can also instruct patients on the proper use of equipment, such as crutches, and assess whether someone has sufficient strength to use them.

Review Questions

Query 8.4.1

This interactive element is not available in this format. Visit the link or scan the QR code to access it online.

View this Interactive Content online

Critical Thinking Questions

Query 8.4.2

This interactive element is not available in this format. Visit the link or scan the QR code to access it online.

View this Interactive Content online

Query 8.4.3

This interactive element is not available in this format. Visit the link or scan the QR code to access it online.

View this Interactive Content online

Glossary

Query 8.4.4

This interactive element is not available in this format. Visit the link or scan the QR code to access it online.

View this Interactive Content online

Contributors and Attributions

- OpenStax Anatomy & Physiology (CC BY 4.0). Access for free at https://openstax.org/books/anatomy-and-physiology

This page titled 8.4: Development and Regeneration of Muscle Tissue is shared under a CC BY-NC-SA 4.0 license and was authored, remixed, and/or curated by Jennifer Lange et al..

- 9.6: Development and Regeneration of Muscle Tissue by Whitney Menefee, Julie Jenks, Chiara Mazzasette, and Kim-Leiloni Nguyen is licensed CC BY 4.0.

8.5: Anatomical Atlas - Muscle Tissues

A compendium of anatomical images: slides, models, and/or cadavers.



Image Credit

"Skeletal Muscle Model" by Jennifer Lange is licensed under CC BY-NC-SA 4.0.

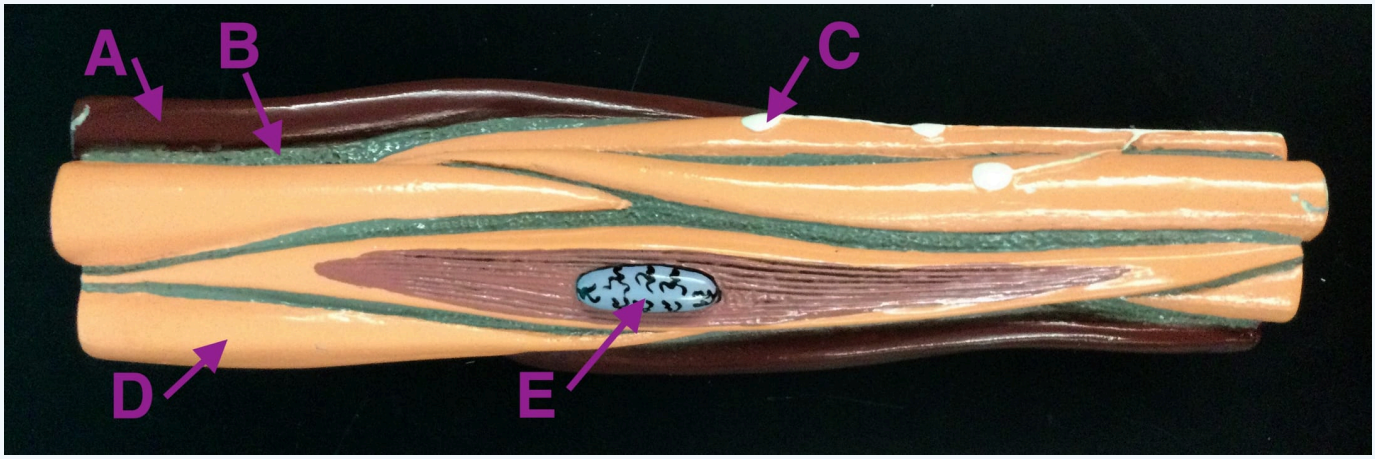

Image Credit

"Smooth Muscle Model" by Jennifer Lange is licensed under CC BY-NC-SA 4.0.

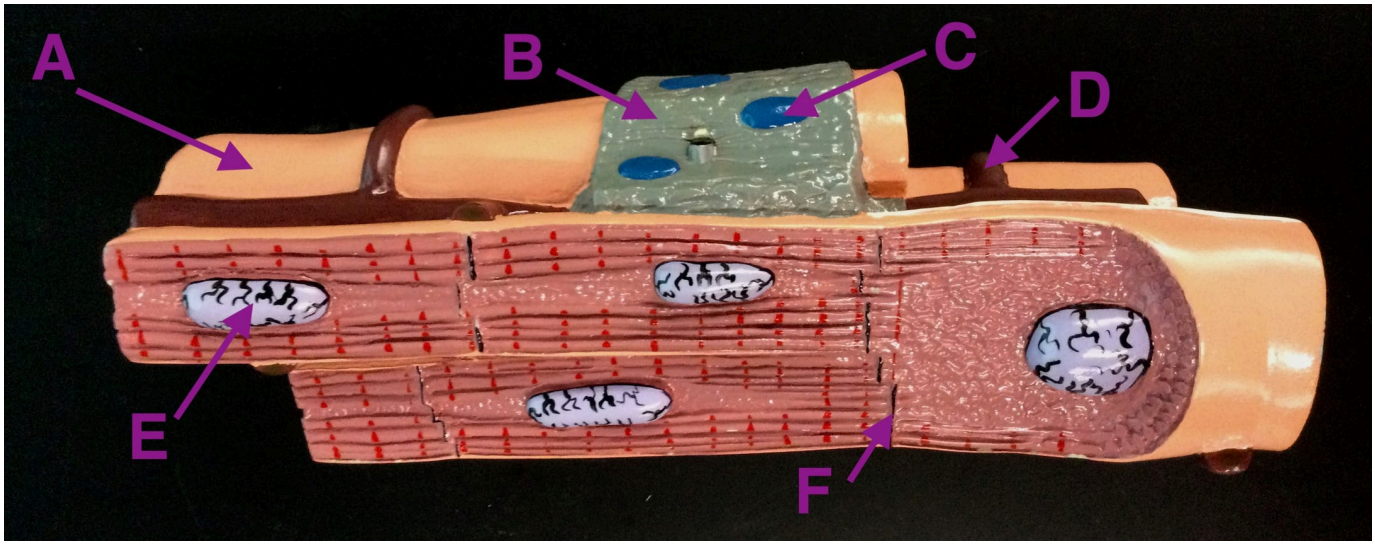

Image Credit

"Cardiac Muscle Model" by Jennifer Lange is licensed under CC BY-NC-SA 4.0.



Image Credit

"Sarcomere Model" by Jennifer Lange is licensed under CC BY-NC-SA 4.0.

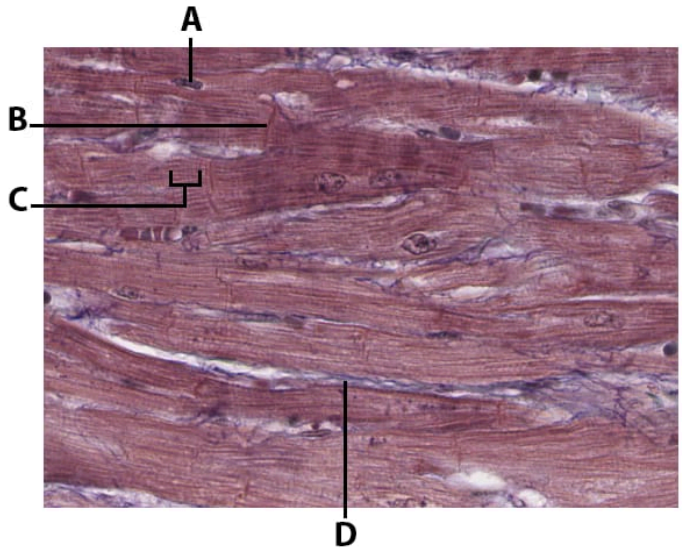

Image Credit

"Cardiac Muscle Histology" by Jennifer Lange is licensed under CC BY-NC-SA 4.0, micrographs provided by Virginia Commonwealth University under CC BY-NC-SA 4.0)

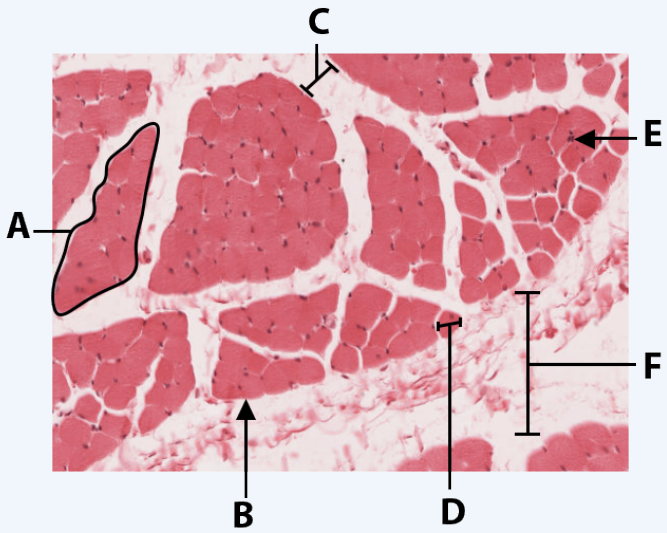

Image Credit

"Skeletal Muscle Histology - Cross Section" by Jennifer Lange is licensed under CC BY-NC-SA 4.0, slide provided by the Regents of the University of Michigan Medical School © 2022)

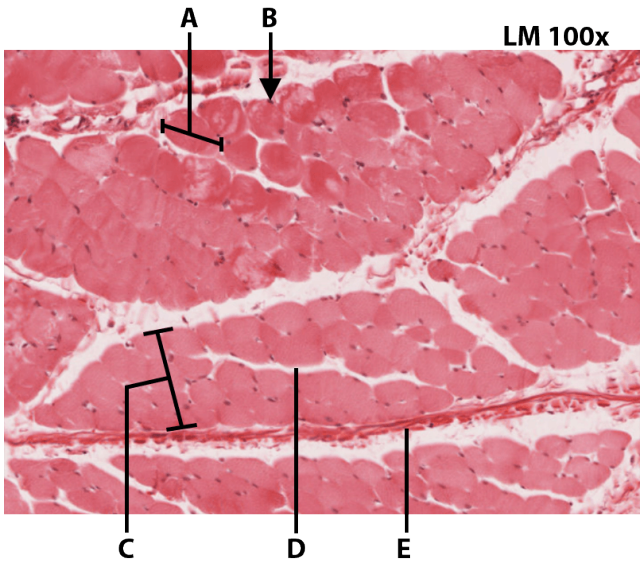

Image credit:

"Histology of Skeletal Muscle - Cross Section" by Jennifer Lange, slide provided by the Regents of the University of Michigan Medical School under CC BY-NC-SA 4.0 © 2022.

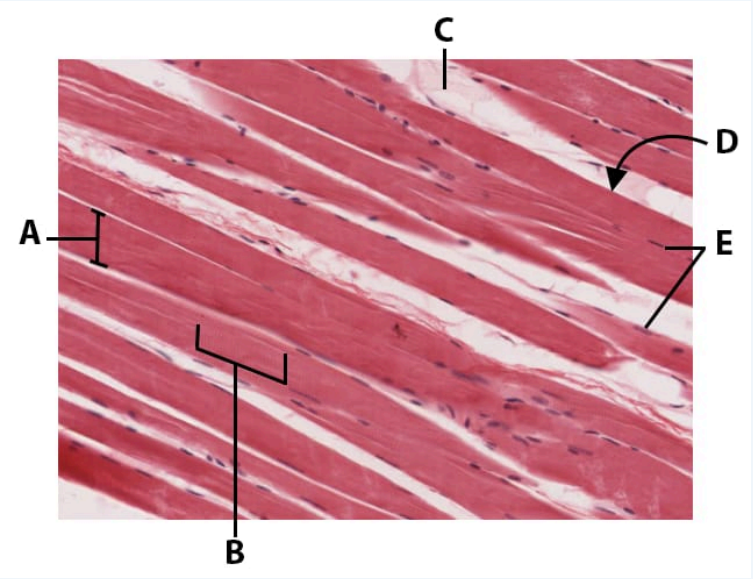

Image Credit

"Skeletal Muscle Histology - Long Section" by Jennifer Lange is licensed under CC BY-NC-SA 4.0, slide provided by the Regents of the University of Michigan Medical School © 2022)

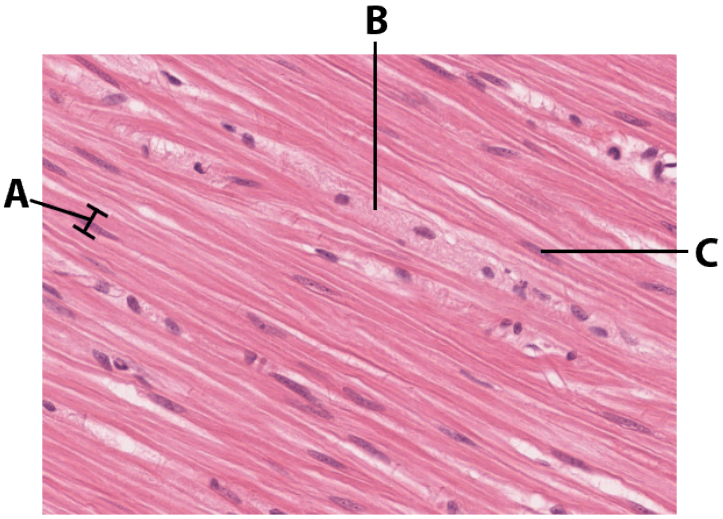

Image Credit

"Smooth Muscle Histology - Long Section" by Jennifer Lange is licensed under CC BY-NC-SA 4.0, slide provided by the Regents of the University of Michigan Medical School © 2022)

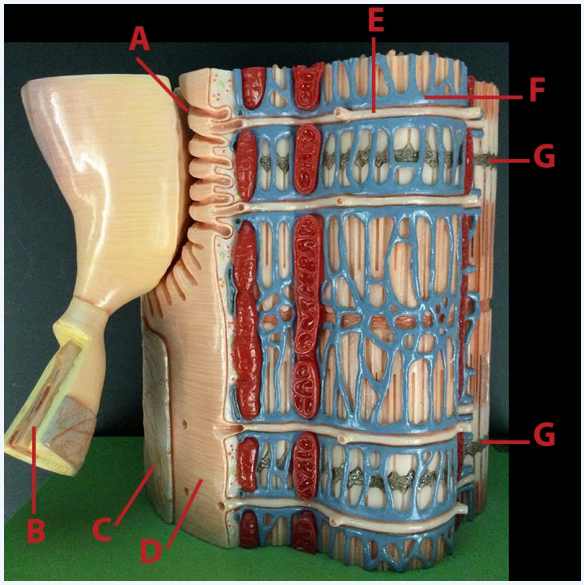

Image Credit

"Myofibril and NMJ Model" by Jennifer Lange is licensed under CC BY-NC-SA 4.0.

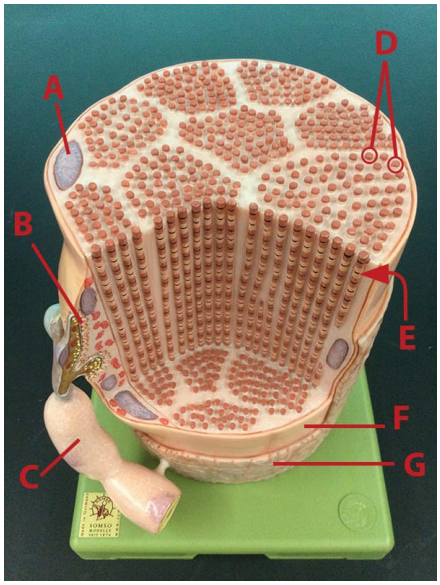

Image Credit

"Myofiber and NMJ Model" by Jennifer Lange is licensed under CC BY-NC-SA 4.0.

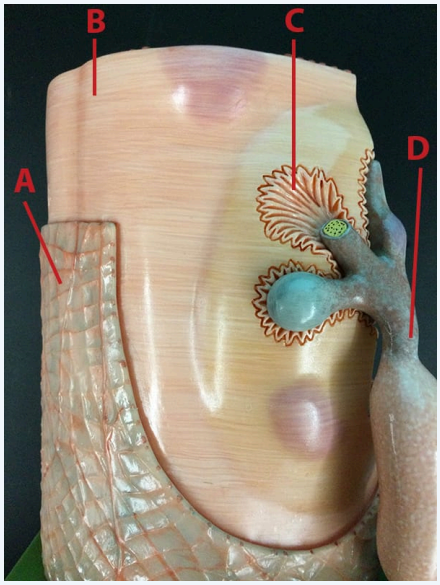

Image Credit

"NMJ and Myofiber Model" by Jennifer Lange is licensed under CC BY-NC-SA 4.0.



Image Credit

"Sarcomere of Myofibril Model" by Jennifer Lange is licensed under CC BY-NC-SA 4.0.

This page titled 8.5: Anatomical Atlas - Muscle Tissues is shared under a CC BY-NC-SA 4.0 license and was authored, remixed, and/or curated by Jennifer Lange et al..

8.6: Practice Practical- Muscle Tissues

Answer the following questions by typing your answer into the box(es).

Query 8.6.1

This interactive element is not available in this format. Visit the link or scan the QR code to access it online.

View this Interactive Content online

Query 8.6.1

This interactive element is not available in this format. Visit the link or scan the QR code to access it online.

View this Interactive Content online

Query 8.6.1

This interactive element is not available in this format. Visit the link or scan the QR code to access it online.

View this Interactive Content online

Query 8.6.1

This interactive element is not available in this format. Visit the link or scan the QR code to access it online.

View this Interactive Content online

Query 8.6.1

This interactive element is not available in this format. Visit the link or scan the QR code to access it online.

View this Interactive Content online

This page titled 8.6: Practice Practical- Muscle Tissues is shared under a CC BY-NC-SA 4.0 license and was authored, remixed, and/or curated by Jennifer Lange et al..

9: MUSCULAR SYSTEM

9.1: Introduction to the Muscular System

9.2: Interactions of Skeletal Muscles, Their Fascicle Arrangement, and Their Lever Systems

9.3: Naming Skeletal Muscles

9.4: Axial Muscles of the Head, Neck, and Back

9.5: Axial Muscles of the Abdominal Wall and Thorax

9.6: Appendicular Muscles of the Pectoral Girdle and Upper Limbs

9.7: Appendicular Muscles of the Pelvic Girdle and Lower Limbs

9.8: Anatomical Atlas - Muscular System

9.9: Practice Practical- Muscles

This page titled 9: Muscular System is shared under a CC BY-NC-SA 4.0 license and was authored, remixed, and/or curated by Jennifer Lange et al..

- 10: Muscular System by Whitney Menefee, Julie Jenks, Chiara Mazzasette, and Kim-Leiloni Nguyen is licensed CC BY 4.0.

9.1: Introduction to the Muscular System

Chapter Learning Objectives

After studying this chapter, you will be able to:

- Describe the actions and roles of agonists and antagonists
- Explain the structure and organization of muscle fascicles and their role in generating force
- Explain the criteria used to name skeletal muscles
- Identify the skeletal muscles and their actions on the skeleton and soft tissues of the body
- Identify the origins and insertions of skeletal muscles and the movements they cause

Think about the things that you do each day—talking, walking, sitting, standing, and running—all of these activities require movement of particular skeletal muscles. Skeletal muscles are even used during sleep. The diaphragm is a sheet of skeletal muscle that has to contract and relax for you to breathe day and night. If you recall from your study of the skeletal system and joints, body movement occurs around the joints in the body. The focus of this chapter is on skeletal muscle organization. The system to name skeletal muscles will be explained; in some cases, the muscle is named by its shape, and in other cases it is named by its location or attachments to the skeleton. If you understand the meaning of the name of the muscle, often it will help you remember its location and/or what it does. This chapter also will describe how skeletal muscles are arranged to accomplish movement, and how other muscles may assist, or be arranged on the skeleton to resist or carry out the opposite movement. The actions of the skeletal muscles will be covered in a regional manner, working from the head down to the toes.

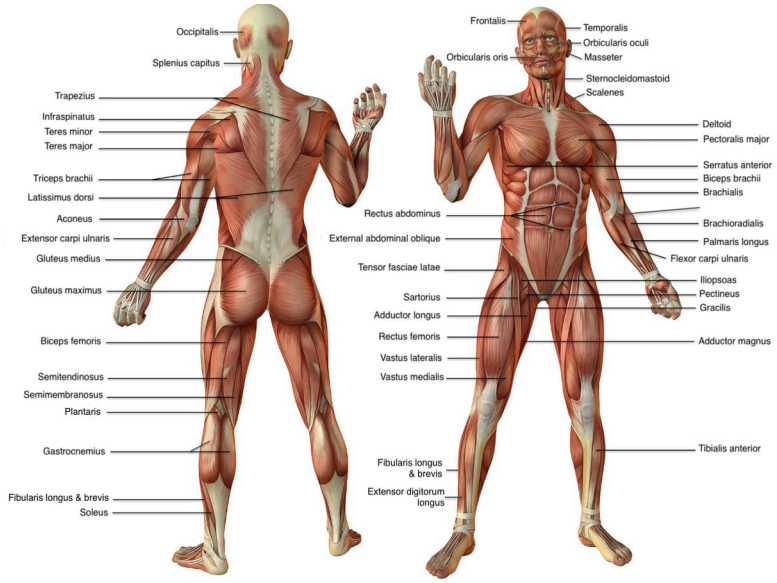

Figure 9.1.1: Muscles of the Body - Anterior and Posterior Views. *(Image credit: "Muscles of the Human Body" by Jennifer Lange, based on original by Homme en Noir is licensed by Creative Commons Attribution-Share Alike 4.0 International)*

Contributors and Attributions

- OpenStax Anatomy & Physiology (CC BY 4.0). Access for free at https://openstax.org/books/anatomy-and-physiology

This page titled 9.1: Introduction to the Muscular System is shared under a CC BY-NC-SA 4.0 license and was authored, remixed, and/or curated by Jennifer Lange et al..

- 10.1: Introduction to the Muscular System by Whitney Menefee, Julie Jenks, Chiara Mazzasette, and Kim-Leiloni Nguyen is licensed CC BY 4.0.

9.2: Interactions of Skeletal Muscles, Their Fascicle Arrangement, and Their Lever Systems

By the end of this section, you will be able to:

- Compare and contrast agonist and antagonist muscles
- Describe how fascicles are arranged within a skeletal muscle
- Explain the three types of muscle lever systems

To move the skeleton, the tension created by the contraction of the fibers in most skeletal muscles is transferred to the tendons. The tendons are strong bands of dense, regular connective tissue that connect muscles to bones. The bone connection is why this muscle tissue is called skeletal muscle.

Interactions of Skeletal Muscles in the Body

To pull on a bone, that is, to change the angle at its synovial joint by moving the skeleton, a skeletal muscle must also be attached to a fixed part of the skeleton. The end of the muscle attached to a fixed (stabilized) bone is called the **origin** and the moveable end of the muscle that attaches to the bone being pulled is called the muscle's **insertion**. The muscle's line of pull indicates the direction the body part will move when the insertion point is brought closer to the origin point (Figure 9.2.1).

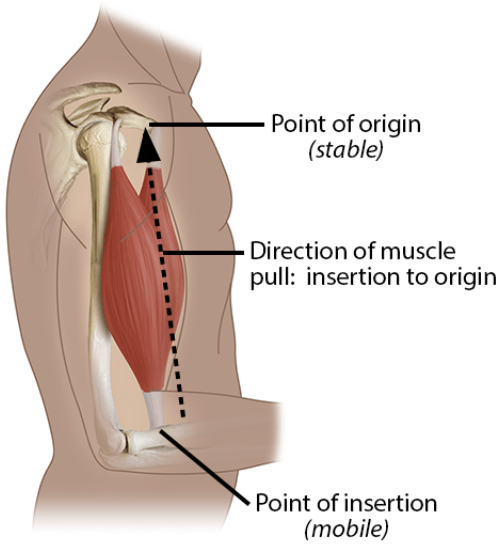

Figure 9.2.1: Origin and Insertion Points. When a muscle contracts and shortens, the bone at the point of insertion will move toward the bone at the point of origin. *(Image credit: "Origin and Insertion" by Justin Greene and Jennifer Lange is licensed under CC BY-NC-SA 4.0.)*

Although a number of muscles may be involved in an action, the principal muscle involved is called the **prime mover**, or **agonist**. During forearm **flexion** (bending the elbow), such as lifting a cup, a muscle called the biceps brachii is actually the prime mover; however, because it can be assisted by the brachialis, the brachialis is called a **synergist** in this action (Figure 9.2.2). Also involved is the brachioradialis which assists the brachialis, and is also considered a synergist. A synergist can also be a **fixator** that stabilizes the bone that is the attachment for the prime mover's origin.

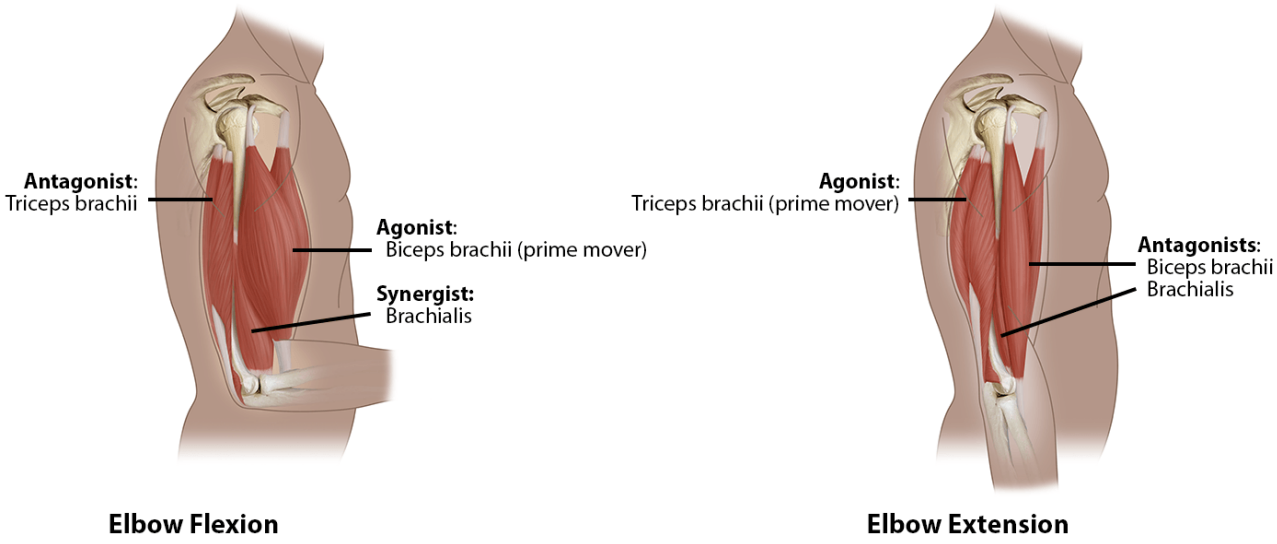

Figure 9.2.2: Functional Interactions. The biceps brachii flexes the forearm and the triceps brachii extends the arm, making them an agonist/antagonist pair. The brachialis is a synergist of biceps brachii that aids in its motions. *(Image credit: "Agonist and Antagonist" by Justin Greene and Jennifer Lange is licensed under CC BY-NC-SA 4.0.)*

A muscle with the opposite action of the prime mover is called an **antagonist**. Antagonists play two important roles in muscle function: (1) they maintain body or limb position, such as holding the arm out or standing erect; and (2) they control rapid movement, as in shadow boxing without landing a punch or the ability to check the motion of a limb.

For example, to extend the knee, a group of four muscles called the quadriceps femoris in the anterior compartment of the thigh are activated (and would be called the agonists of knee extension). However, to flex the knee joint, an opposite or antagonistic set of muscles called the hamstrings is activated.

As you can see, these terms would also be reversed for the opposing action. If you consider the first action as the knee bending, the hamstrings would be called the agonists and the quadriceps femoris would then be called the antagonists. See Table 9.2.1 for a list of some agonists and antagonists.

***Table* 9.2.1: Agonist and Antagonist Skeletal Muscle Pairs**

Agonist	Antagonist	Movement
Biceps brachii: in the anterior compartment of the arm	Triceps brachii: in the posterior compartment of the arm	The biceps brachii flexes the forearm, whereas the triceps brachii extends it.
Hamstrings: group of three muscles in the posterior compartment of the thigh	Quadriceps femoris: group of four muscles in the anterior compartment of the thigh	The hamstrings flex the leg, whereas the quadriceps femoris extend it.
Flexor digitorum superficialis and flexor digitorum profundus: in the anterior compartment of the forearm	Extensor digitorum: in the posterior compartment of the forearm	The flexor digitorum superficialis and flexor digitorum profundus flex the fingers and the hand at the wrist, whereas the extensor digitorum extends the fingers and the hand at the wrist.

There are also skeletal muscles that do not pull against the skeleton for movements. For example, there are the muscles that produce facial expressions. The insertions and origins of facial muscles are in the skin, so that certain individual muscles contract to form a smile or frown, form sounds or words, and raise the eyebrows. There also are skeletal muscles in the tongue, and the external urinary and anal sphincters that allow for voluntary regulation of urination and defecation, respectively. In addition, the diaphragm contracts and relaxes to change the volume of the pleural cavities but it does not move the skeleton to do this.

EVERYDAY CONNECTIONS

Exercise and Stretching

When exercising, it is important to first warm up the muscles. Stretching pulls on the muscle fibers and it also results in an increased blood flow to the muscles being worked. Without a proper warm-up, it is possible that you may either damage some of the muscle fibers or pull a tendon. A pulled tendon, regardless of location, results in pain, swelling, and diminished function; if it is moderate to severe, the injury could immobilize you for an extended period.

Recall the discussion about muscles crossing joints to create movement. Most of the joints you use during exercise are synovial joints, which have synovial fluid in the joint space between two bones. Exercise and stretching may also have a beneficial effect on synovial joints. Synovial fluid is a thin, but viscous film with the consistency of egg whites. When you first get up and start moving, your joints feel stiff for a number of reasons. After proper stretching and warm-up, the synovial fluid may become less viscous, allowing for better joint function.

Patterns of Fascicle Organization

Skeletal muscle is enclosed in connective tissue scaffolding at three levels. Each muscle fiber (cell) is covered by endomysium and the entire muscle is covered by epimysium. When a group of muscle fibers is "bundled" as a unit within the whole muscle by an additional covering of a connective tissue called perimysium, that bundled group of muscle fibers is called a **fascicle**. Fascicle arrangement by perimysia is correlated to the force generated by a muscle; it also affects the range of motion of the muscle. Based on the patterns of fascicle arrangement, skeletal muscles can be classified in several ways. Figure 9.2.3 shows some of the most common fascicle arrangements.

Parallel muscles have fascicles that are arranged in the same direction as the long axis of the muscle. The majority of skeletal muscles in the body have this type of organization. Some parallel muscles are flat sheets that expand at the ends to make broad attachments. Other parallel muscles are rotund with tendons at one or both ends. Muscles that seem to be plump have a large mass of tissue located in the middle of the muscle, between the insertion and the origin, which is known as the central body, or **belly**. When a muscle contracts, the contractile fibers shorten it to an even larger bulge. For example, extend and then flex your biceps brachii muscle; the large, middle section is the belly (Figure 9.2.2). When a parallel muscle has a central, large belly that is spindle-shaped, meaning it tapers as it extends to its origin and insertion, it sometimes is called **fusiform**. Parallel muscles that do not have have a spindle-shape, but instead have a more consistent diameter throughout the length of the muscle, such as sartorius of the upper leg, are non-fusiform.

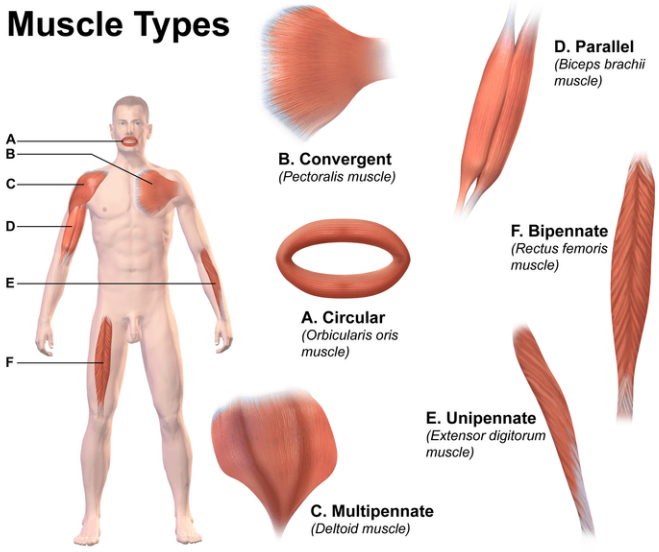

Figure 9.2.3: Muscle Shapes and Fascicle Arrangement. The skeletal muscles of the body typically come in six different general shapes. *(Image credit: "Muscle Types" by BruceBlaus is licensed under CC-BY-SA 4.0 International.*

Circular muscles are also called sphincters (Figure 9.2.3). When they relax, the sphincters' concentrically arranged bundles of muscle fibers increase the size of the opening, and when they contract, the size of the opening shrinks to the point of closure. The orbicularis oris muscle is a circular muscle that goes around the mouth. When it contracts, the oral opening becomes smaller, as when puckering the lips for whistling. Another example is the orbicularis oculi, one of which surrounds each eye. Consider, for example, the names of the two orbicularis muscles (orbicularis oris and orbicularis oculi), where part of the first name of both muscles is the same. The first part of orbicularis, orb (orb = "circular"), is a reference to a round or circular structure; it may also make one think of orbit, such as the moon's path around the earth. The word oris (oris = "oral") refers to the oral cavity, or the mouth. The word oculi (ocular = "eye") refers to the eye.

When a muscle has a widespread expansion over a sizable area, but then the fascicles come to a single, common attachment point, the muscle is called **convergent**. The attachment point for a convergent muscle could be a tendon, an aponeurosis (a flat, broad tendon), or a raphe (a very slender tendon). The large muscle on the chest, the pectoralis major, is an example of a convergent muscle because it converges on the greater tubercle of the humerus via a tendon. The temporalis muscle of the cranium is another.

Pennate muscles (penna = "feathers") blend into a tendon that runs through the central region of the muscle for its whole length, somewhat like the quill of a feather with the muscle arranged similar to the feathers. Due to this design, the muscle fibers in a pennate muscle can only pull at an angle, and as a result, contracting pennate muscles do not move their tendons very far. However, because a pennate muscle generally can hold more muscle fibers within it, it can produce relatively more tension for its size. There are three subtypes of pennate muscles.

In a **unipennate** muscle, the fascicles are located on one side of the tendon. The extensor digitorum of the forearm is an example of a unipennate muscle. A **bipennate** muscle has fascicles on both sides of the tendon, as seen in rectus femoris of the upper leg. In some pennate muscles, the muscle fibers wrap around the tendon, sometimes forming individual fascicles in the process. This arrangement is referred to as **multipennate**. A common example is the deltoid muscle of the shoulder, which covers the shoulder but has a single tendon that inserts on the deltoid tuberosity of the humerus.

Because of the fascicle arrangement, a portion of a multipennate muscle like the deltoid can be stimulated by the nervous system to change the direction of the pull. For example, when the deltoid muscle contracts, the arm **abducts** (moves away from midline in the sagittal plane), but when only the anterior fascicles are stimulated, the arm will abduct and flex (move anteriorly at the shoulder joint).

The Lever System of Muscle and Bone Interactions

Skeletal muscles do not work by themselves. Muscles are arranged in pairs based on their functions. For muscles attached to the bones of the skeleton, the connection determines the force, speed, and range of movement. These characteristics depend on each other and can explain the general organization of the muscular and skeletal systems.

The skeleton and muscles act together to move the body. Have you ever used the back of a hammer to remove a nail from wood? The handle acts as a lever and the head of the hammer acts as a fulcrum, the fixed point that the force is applied to when you pull back or push down on the handle. The effort applied to this system is the pulling or pushing on the handle to remove the nail, which is the load, or "resistance" to the movement of the handle in the system. Our musculoskeletal system works in a similar manner, with bones being stiff levers and the articular endings of the bones—encased in synovial joints—acting as fulcrums. The load would be an object being lifted or any resistance to a movement (your head is a load when you are lifting it), and the effort, or applied force, comes from contracting skeletal muscle.

Lever systems in the human body are classified based on the arrangement pattern of the fulcrum, resistance, and the applied force (Figure 9.2.4):

- **First Class Lever:** When the fulcrum lies between the resistance and the applied force, it is considered to be a first class lever (Figure 9.2.4.*a*). Tilting your head back uses a first class lever. In this motion the atlanto-occipital joint is the fulcrum, the head is the resistance, and the applied force is generated by the trapezius muscle of the neck.
- **Second Class Lever:** A second class lever is arranged with the resistance between the fulcrum and the applied force (Figure 9.2.4.*b*). When you stand on your tip toes, a second class lever is in use. The the body (resistance), lies between the metatarsophalangeal joints (fulcrum), and the applied forced from several lower leg muscles including gastrocnemius.
- **Third Class Lever:** The arrangement of a third class lever has the applied force between the fulcrum and the resistance (Figure 9.2.4.*c*). Flexion at the elbow, with the biceps brachii muscle (applied force) between the elbow joint (fulcrum) and the lower arm (resistance), is an example of motion using a third class lever.

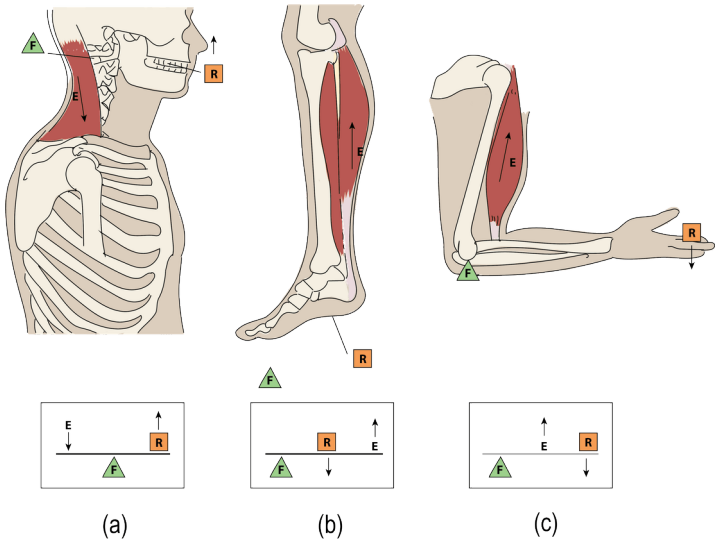

Figure 9.2.4: Lever Systems of the Human Body. (a) First class lever. (b) Second class lever. (c) Third class lever. The arrangement of the fulcrum (F), resistance (R), and effort, or applied force (E), determines the lever type found in the human body. *(Image credit: "Lever Systems of the Human Body" by Daniel Donnelly is licensed under CC BY 4.0, recolored by Jennifer Lange)*

Concept Review

Skeletal muscles each have an origin and an insertion. The end of the muscle that attaches to the bone being pulled is called the muscle's insertion and the end of the muscle attached to a fixed, or stabilized, bone is called the origin. The muscle primarily responsible for a movement is called the prime mover, and muscles that assist in this action are called synergists. A synergist that makes the insertion site more stable is called a fixator. Meanwhile, a muscle with the opposite action of the prime mover is called an antagonist. Several factors contribute to the force generated by a skeletal muscle. One is the arrangement of the fascicles in

the skeletal muscle. Fascicles can be parallel, circular, convergent, or pennate. Each arrangement has its own range of motion and ability to do work.

Review Questions

Query 9.2.1

This interactive element is not available in this format. Visit the link or scan the QR code to access it online.

View this Interactive Content online

Critical Thinking Questions

Query 9.2.2

This interactive element is not available in this format. Visit the link or scan the QR code to access it online.

View this Interactive Content online

Query 9.2.3

This interactive element is not available in this format. Visit the link or scan the QR code to access it online.

View this Interactive Content online

Query 9.2.4

This interactive element is not available in this format. Visit the link or scan the QR code to access it online.

View this Interactive Content online

Glossary

Query 9.2.5

This interactive element is not available in this format. Visit the link or scan the QR code to access it online.

View this Interactive Content online

Contributors and Attributions

- OpenStax Anatomy & Physiology (CC BY 4.0). Access for free at https://openstax.org/books/anatomy-and-physiology

This page titled 9.2: Interactions of Skeletal Muscles, Their Fascicle Arrangement, and Their Lever Systems is shared under a CC BY-NC-SA 4.0 license and was authored, remixed, and/or curated by Jennifer Lange et al..

- 10.2: Interactions of Skeletal Muscles, Their Fascicle Arrangement, and Their Lever Systems by Whitney Menefee, Julie Jenks, Chiara Mazzasette, and Kim-Leiloni Nguyen is licensed CC BY 4.0.

9.3: Naming Skeletal Muscles

By the end of this section, you will be able to:

- Describe the criteria used to name skeletal muscles
- Explain how understanding the muscle names helps describe shapes, location, and actions of various muscles

The Greeks and Romans conducted the first studies done on the human body in Western culture. The educated class of subsequent societies studied Latin and Greek, and therefore the early pioneers of anatomy continued to apply Latin and Greek terminology or roots when they named the skeletal muscles. The large number of muscles in the body and unfamiliar words can make learning the names of the muscles in the body seem daunting, but understanding the etymology can help. Etymology is the study of how the root of a particular word entered a language and how the use of the word evolved over time. Taking the time to learn the root of the words is crucial to understanding the vocabulary of anatomy and physiology. When you understand the names of muscles it will help you remember where the muscles are located and what they do (Figure 9.3.1, Table 9.3.1, and Table 9.3.2). Pronunciation of words and terms will take a bit of time to master, but after you have some basic information the correct names and pronunciations will become easier.

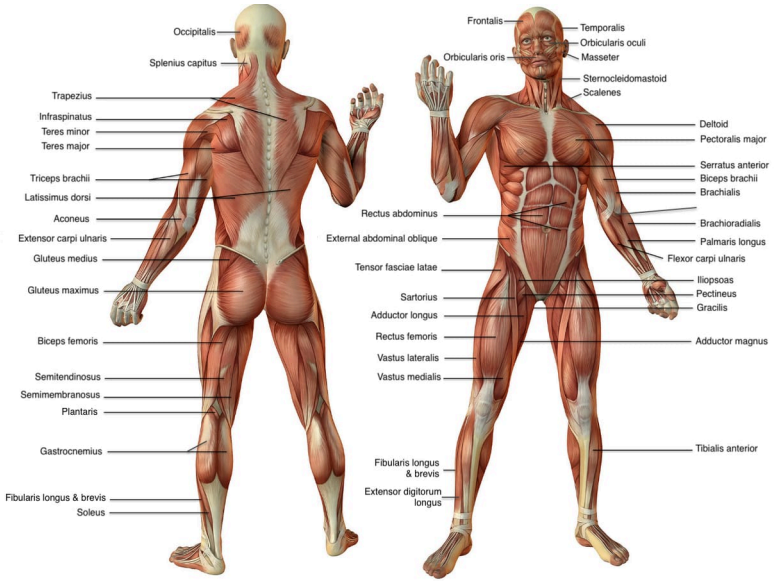

Figure 9.3.1: Muscles of the Body - Anterior and Posterior Views. (Image credit: "Muscles of the Human Body" by Jennifer Lange, based on original by Homme en Noir is licensed by Creative Commons Attribution-Share Alike 4.0 International)

Table 9.3.1: Understanding a Muscle Name from the Latin

Example	Word	Latin Root 1	Latin Root 2	Meaning	Translation
abductor digiti minimi	abductor	ab = away from	duct = to move	a muscle that moves away from	A muscle that moves the little finger or toe away from the midline
	digiti	digitus = digit		refers to a finger or toe	
	minimi	minimus = mini, tiny		little	
adductor digiti minimi	adductor	ad = to, toward	duct = to move	a muscle that moves toward	A muscle that moves the little finger or toe toward the midline
	digiti	digitus = digit		refers to finger or toe	

Example	Word	Latin Root 1	Latin Root 2	Meaning	Translation
	minimi	minimus = mini, tiny		little	

Table 9.3.2: Mnemonic Device for Latin Roots

Example	Latin or Greek Translation	Mnemonic Device
ad	to; toward	ADvance toward your goal
ab	away from	n/a
sub	under	SUBmarines move under water.
ductor	something that moves	A conDUCTOR makes a train move.
anti	against	If you are antisocial, you are against engaging in social activities.
epi	on top of	n/a
apo	to the side of	n/a
longissimus	longest	“Longissimus” is longer than the word “long.”
longus	long	long
brevis	short	brief
maximus	large	max
medius	medium	“Medius” and “medium” both begin with “med.”
minimus	tiny; little	mini
rectus	straight	To RECTify a situation is to straighten it out.
multi	many	If something is MULTIcolored, it has many colors.
uni	one	A UNIcorn has one horn.
bi/di	two	If a ring is DIcast, it is made of two metals.
tri	three	TRIple the amount of money is three times as much.
quad	four	QUADruplets are four children born at one birth.
externus	outside	EXternal
internus	inside	INternal

Anatomists name the skeletal muscles according to a number of criteria, each of which describes the muscle in some way. These include naming the muscle after its shape, its size compared to other muscles in the area, its location in the body or the location of its attachments to the skeleton, how many origins it has, or its action.

- The skeletal muscle’s anatomical location or its relationship to a particular bone often determines its name. For example: the frontalis muscle is located on top of the frontal bone of the skull; the brachialis is in the brachial region; the tibialis anterior runs along the tibia.
- The shapes of some muscles are very distinctive and the names, such as orbicularis, reflect the shape ('orb' = circular). The deltoid is a large, triangular-shaped muscle that covers the shoulder. It is so-named because the Greek letter delta looks like a triangle.
- The size of the muscles influences the names: gluteus **maximus** (largest), gluteus **medius** (medium), and the gluteus **minimus** (smallest).
- Names indicate length—**brevis** (short), **longus** (long)
- Names identify position relative to the midline: **lateralis** (to the outside away from the midline), and **medialis** (toward the midline). **Intermedius** is inbetween medial and lateral.
- The direction of the muscle fibers and fascicles are used to describe muscles relative to the midline, such as the **rectus** (straight) abdominis, or the **oblique** (at an angle) muscles of the abdomen, or the **transversus** (horizontal) abdominus

- Some muscle names indicate the number of muscles in a group. One example of this is the quadriceps, a group of four muscles located on the anterior (front) thigh. Other muscle names can provide information as to how many origins a particular muscle has, such as the biceps brachii. The prefix **bi** indicates that the muscle has two origins and **tri** indicates three origins.
- The location of a muscle's attachments can also appear in its name. When the name of a muscle is based on the attachments, the origin is always named first. For instance, the sternocleidomastoid muscle of the neck has a dual origin on the sternum (sterno) and clavicle (cleido), and it inserts on the mastoid process of the temporal bone.
- When muscles are named for the movement they produce, one can find action words in their name. Some examples are **flexor** (decreases the angle at the joint), **extensor** (increases the angle at the joint), **abductor** (moves the bone away from the midline), or **adductor** (moves the bone toward the midline).

Concept Review

Muscle names are based on many characteristics. The location of a muscle in the body is important. Some muscles are named based on their size and location, such as the gluteal muscles of the buttocks. Other muscle names can indicate the location in the body or bones with which the muscle is associated, such as the tibialis anterior. The shapes of some muscles are distinctive; for example, the direction of the muscle fibers is used to describe muscles of the body midline. The origin and/or insertion can also be features used to name a muscle; examples are the biceps brachii, triceps brachii, and the pectoralis major.

Review Questions

Query 9.3.1

This interactive element is not available in this format. Visit the link or scan the QR code to access it online.

View this Interactive Content online

Critical Thinking Questions

Query 9.3.2

This interactive element is not available in this format. Visit the link or scan the QR code to access it online.

View this Interactive Content online

Glossary

Query 9.3.3

This interactive element is not available in this format. Visit the link or scan the QR code to access it online.

View this Interactive Content online

Contributors and Attributions

- OpenStax Anatomy & Physiology (CC BY 4.0). Access for free at https://openstax.org/books/anatomy-and-physiology

This page titled 9.3: Naming Skeletal Muscles is shared under a CC BY-NC-SA 4.0 license and was authored, remixed, and/or curated by Jennifer Lange et al..

- 10.3: Naming Skeletal Muscle by Whitney Menefee, Julie Jenks, Chiara Mazzasette, and Kim-Leiloni Nguyen is licensed CC BY 4.0.

9.4: Axial Muscles of the Head, Neck, and Back

By the end of this section, you will be able to:

- Identify the major axial muscles of the face, head, neck, and vertebral column
- Identify the movement caused by these muscles

The skeletal muscles are divided into **axial** (muscles of the trunk and head) and **appendicular** (muscles of the arms and legs) categories. This system reflects the bones of the skeleton system, which are also arranged in this manner. The axial muscles are grouped based on location, function, or both. Some of the axial muscles may seem to blur the boundaries because they cross over to the appendicular skeleton. The first grouping of the axial muscles you will review includes the muscles of the head and neck, including those involving eye movements and swallowing, then you will review the muscles of the vertebral column.

Muscles That Create Facial Expression

The origins of the muscles of facial expression are on the surface of the skull (remember, the origin of a muscle does not move). The insertions of these muscles have fibers intertwined with connective tissue and the dermis of the skin. Because the muscles insert in the skin rather than on bone, when they contract, the skin moves to create facial expression (Figure 9.4.1).

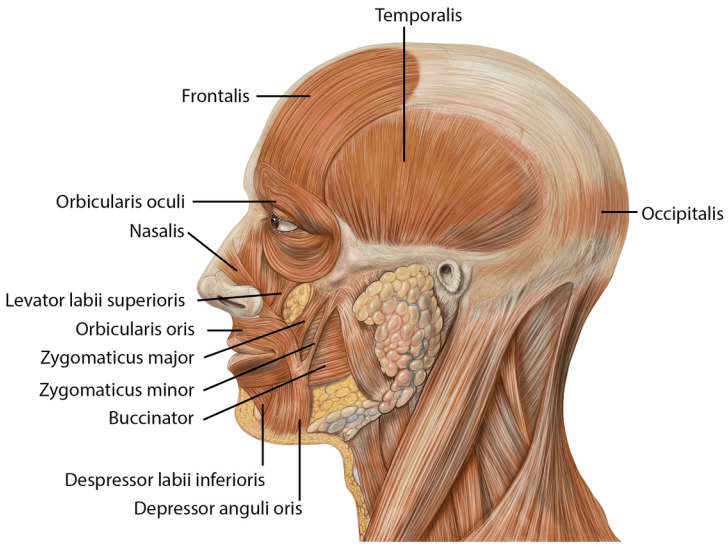

Figure 9.4.1: Muscles of Facial Expression. Many of the muscles of facial expression insert into the skin surrounding the eyelids, nose and mouth, producing facial expressions by moving the skin rather than bones. *(Image credit: "Muscles of Facial Expression" by Jennifer Lange, modified from original images by Patrick J. Lynch, http://patricklynch.net, licensed under CC-BY Attribution 2.5)*

Forehead and Orbit

The **occipitofrontalis** muscle moves the skin of the scalp and eyebrows in a superior direction. The muscle has a frontal belly and an occipital belly located near the respective bones. In other words, there is a muscle on the forehead (**frontalis**) and one on the back of the head (**occipitalis**), but there is no muscle across the top of the head. Instead, the two bellies are connected by a broad tendon called the **epicranial aponeurosis**, or galea aponeurosis (galea = “apple”). The physicians originally studying human anatomy thought the skull looked like an apple. This muscle is the prime mover of the eyebrows. Gently place your finger on your eyebrows then raise your eyebrows as if you were surprised and allow them to come back to rest. With these movements, you can feel the action of the occipitofrontalis. If you watch yourself in a mirror you will see that your forehead is wrinkling as the skin moves.

The **orbicularis oculi** is a circular muscle that surrounds the orbit. When this muscle contracts the eyelid closes. Pretend that a bug just flew into your eye - you will close the eyelid quickly and scrunch the skin around your eye socket using your orbicularis oculi. Want to close your eyelid gently, as if peacefully sleeping? This is caused by the relaxation of another muscle - the **levator palpebrae superioris**. When this muscle contracts is pulls your upper eyelid open, so relaxing it allows the eyelid to close.

Nose, Mouth and Cheeks

The mouth is used for both a variety of facial expressions as well as forming words while speaking and assisting in swallowing, so it has multiple muscles inserting into the surrounding skin. The largest of these muscles is the **orbicularis oris**, whose fibers encircle the lips and can keep them tightly closed. Contracting the orbicularis oris when pulling in more from the corners will produce a puckered, kissing, expression. Two primary muscles pull the skin and lips in an inferior direction - **depressor labii inferioris** pulls the lip down while **depressor anguli oris** pulls the corners of the mouth down and slightly laterally creating a frowning expression. Three primary muscles pull the skin and lips in a superior direction - the **levator labii superioris** pulls your lip upwards toward your nose while the **zygomaticus major and minor** pull the corners of the mouth up and lateral to cause you to smile. If you practice contracting the zygomaticus muscles you will get the perfect, on the spot smile for pictures!

Your nose itself does not move much, but you can flare your nostrils and compress the nasal cartilage using the **nasalis muscle**.

The largest muscle of the cheeks is the **buccinator** muscle, which compresses the cheek and allows you to whistle, blow, and suck. It also contributes to the actions of chewing and swallowing. Additional muscles of facial expression are presented in Table 9.4.1.

Table** 9.4.1**: Muscles of Facial Expression

Muscle	Origin	Insertion	Movement
Brow			
Occipitofrontalis (frontal belly/ frontalis)	Epicranial aponeurosis	Skin of eyebrow	Furrowing (wrinkling) brow
Occipitofrontalis (occipital belly/ occipitalis)	Occipital bone; mastoid process (temporal bone)	Epicranial aponeurosis	Retracts scalp
Orbit and Eyelid			
Orbicularis oculi	Medial wall of orbit	Skin surrounding eyelids	Closes eyelids (blinking, squinting, winking)
Levator palpebrae superioris	Sphenoid bone	Skin of superior eyelid	Elevates superior eyelid
Nose			
Nasalis	Maxilla	Skin of nostrils, nasal aponeurosis	Flaring nostrils
Mouth and Cheeks			
Buccinator	Maxilla, mandible	Orbicularis oris	Lateral movement of cheeks (e.g. sucking on a straw; also used to compress air in mouth while blowing)
Depressor anguli oris	Mandible	Skin at corners of mouth	Draws corners of mouth inferior and lateral (e.g. frowning)
Depressor labii inferioris	Mandible	Skin of lower lip	Lowering lower lip
Levator labii superioris	Maxilla	Skin of the of upper lip; orbicularis oris	Raising upper lip
Mentalis	Mandible	Skin of chin	Protrusion of lower lip (e.g. pouting expression)

Muscle	Origin	Insertion	Movement
Orbicularis oris	Maxilla, mandible; fibers of other facial muscles	Skin surrounding lips	Compresses and purses lips (e.g. kiss)
Zygomaticus major and minor	Zygomatic bone	Skin at superolateral corners of mouth and lip	Smiling

Muscles That Move the Eyes

The movement of the eyeball is under the control of the **extrinsic eye muscles** (extraocular muscles) that originate within the orbit and insert onto the superficial surface of the white of the eye. These muscles are located inside the eye socket and cannot be seen on any part of the visible eyeball (Figure 9.4.2 and Table 9.4.2). If you have ever been to a doctor who held up a finger and asked you to follow it up, down, and to both sides, he or she is checking to make sure your eye muscles are acting in a coordinated pattern.

Each of these six muscles are named for their position relative to the eyeball and the orientation of their myofibers:

- **Superior oblique muscle** - passes through fibrous trochlea, which is attached to the superiomedial aspect of the orbit
- **Inferior oblique muscle**
- **Superior rectus muscle**
- **Inferior rectus muscle**
- **Medial rectus muscle**
- **Lateral rectus muscle**

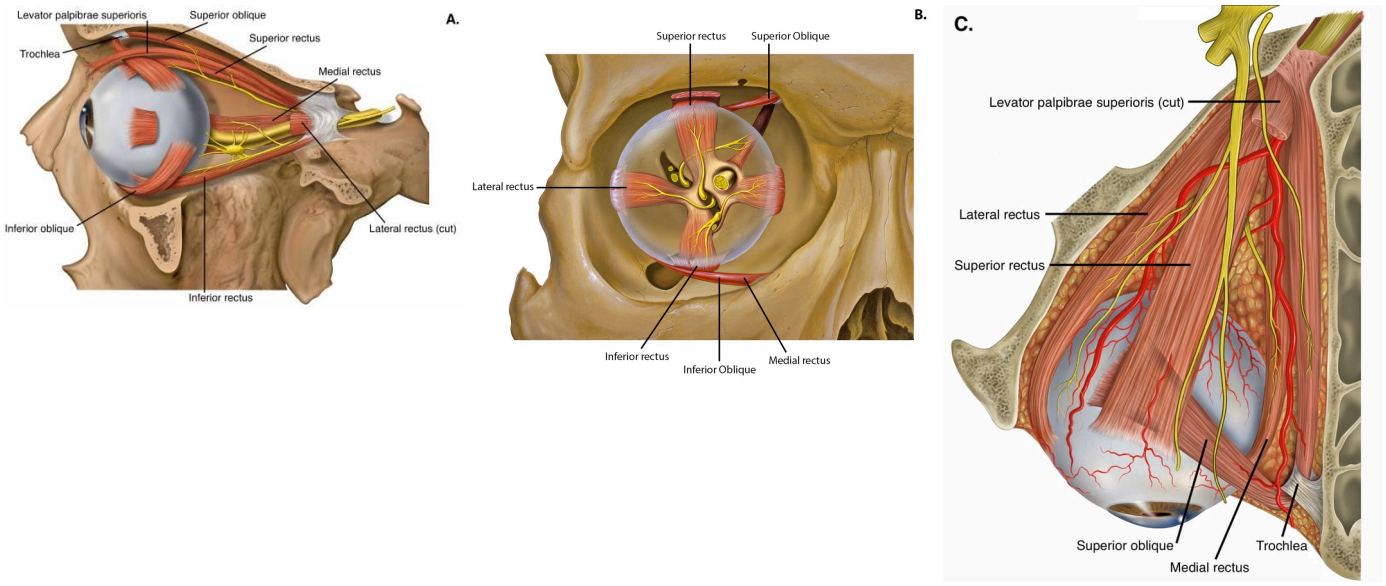

Figure 9.4.2: Extrinsic Eye Muscles. This six muscles control the movements of the eye within the socket. The four rectus muscles originate from a common tendon that surround the optic nerve while the two oblique muscles originate from the medial wall of the orbit. A. Left eye, lateral view. B. Right eye, superior view. C. Right eye, superior view. *(Image credit: "Extrinsic Eye Muscles" by Jennifer Lange, modified from original images by Patrick J. Lynch, http://patricklynch.net, licensed under CC-BY Attribution 2.5)*

Table** 9.4.2**: Muscles of the Eyes

Muscle	Origin	Insertion	Movement	Image(s)
Inferior oblique	Floor of orbit (maxilla)	Surface of eyeball between inferior rectus and lateral rectus	Moves eyes up and away from nose; rotates eyeball from 12 o'clock to 9 o'clock	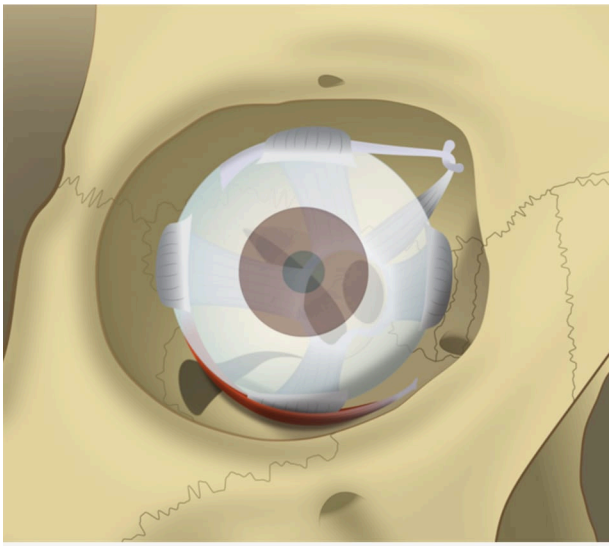 *right eye*
Inferior rectus	Common tendinous ring (ring attaches to optic foramen)	Inferior surface of eyeball	Moves eyes down and toward nose; rotates eyes from 6 o'clock to 3 o'clock	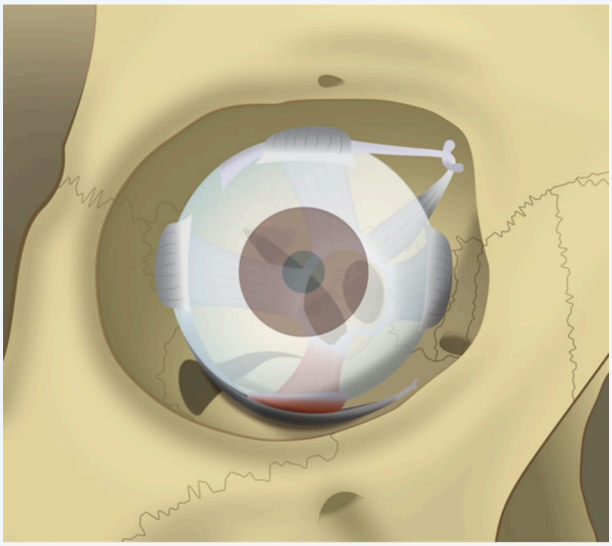 *right eye*

Muscle	Origin	Insertion	Movement	Image(s)
Lateral rectus	Common tendinous ring (ring attaches to optic foramen)	Lateral surface of eyeball	Moves eyes away from nose	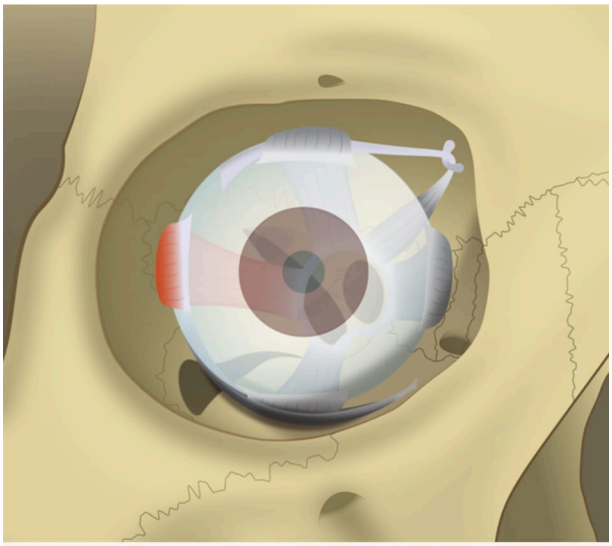 *right eye*
Medial rectus	Common tendinous ring (ring attaches to optic foramen)	Medial surface of eyeball	Moves eyes toward nose	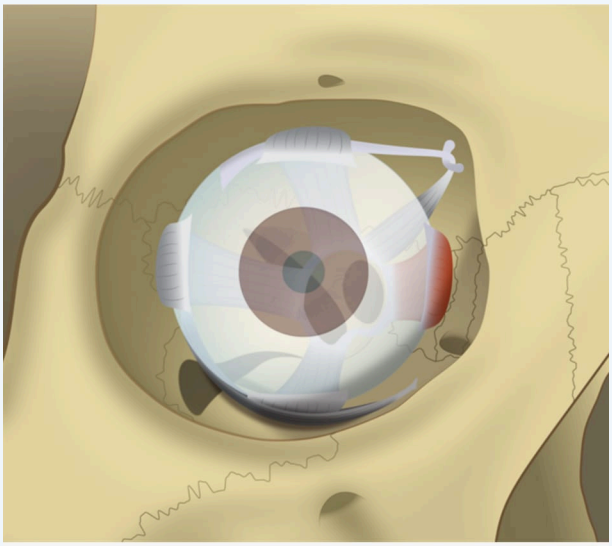 *right eye*

Muscle	Origin	Insertion	Movement	Image(s)
Superior oblique	Sphenoid bone	Surface of eyeball between superior rectus and lateral rectus	Moves eyes down and away from nose; rotates eyeball from 6 o'clock to 9 o'clock	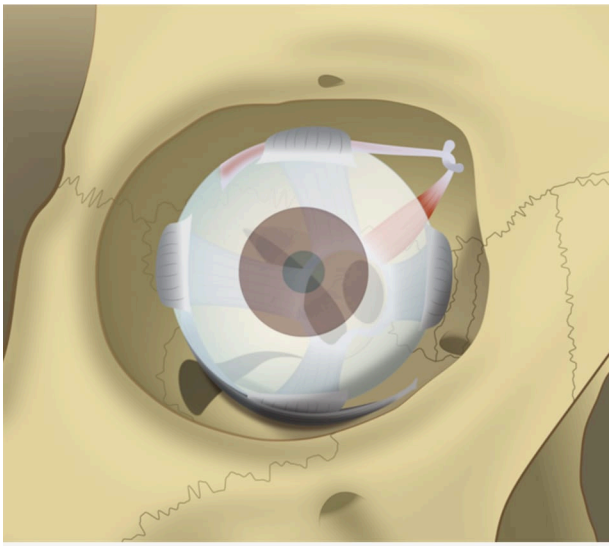 right eye
Superior rectus	Common tendinous ring (ring attaches to optic foramen)	Superior surface of eyeball	Moves eyes up and toward nose; rotates eyes from 1 o'clock to 3 o'clock	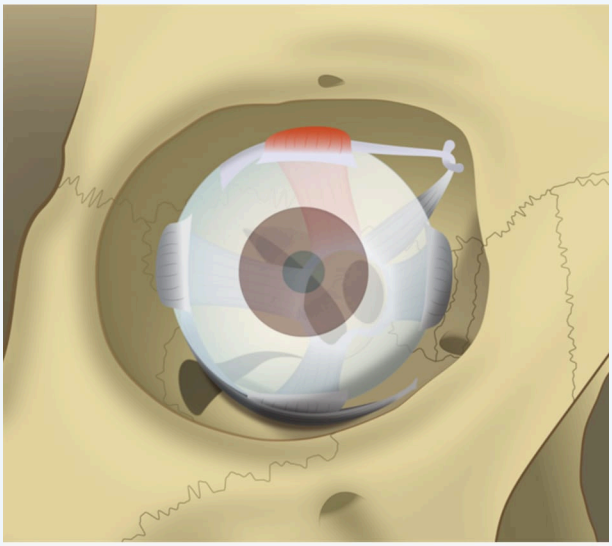 right eye

Muscles That Move the Lower Jaw at the Temporomandibular Joint

In anatomical terminology, chewing is called **mastication**. Muscles involved in chewing must be able to exert enough pressure to bite through and then chew food before it is swallowed (Figure 9.4.3 and Table 9.4.3). The **masseter** muscle is the main muscle used for chewing because it elevates the mandible (lower jaw) to close the mouth, and it is assisted by the **temporalis** muscle, which retracts the mandible. You can feel the temporalis move by putting your fingers to your temple as you chew.

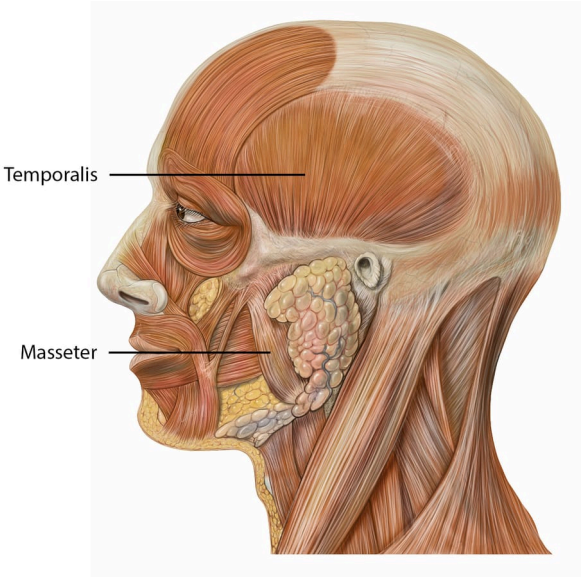

Figure 9.4.3: Muscles of Mastication. The muscles that move the mandible at the temporomandibular joint are typically located within the cheek and originate from processes in the skull. This provides the muscles with the large amount of leverage needed for chewing. *(Image credit: "Muscle of Mastication" by Jennifer Lange, modified from original images by Patrick J. Lynch, http://patricklynch.net, licensed under CC-BY Attribution 2.5)*

Table 9.4.3: Muscles of Mastication

Muscle	Origin	Insertion	Movement
Masseter	Zygomatic arch	Mandible, coronoid process and lateral surface	Closes mouth; elevation of mandible
Temporalis	Temporal bone	Mandible, coronoid process	Closes mouth; elevation and retraction of mandible

Muscles That Move the Tongue

Although the tongue is obviously important for tasting food, it is also necessary for mastication, **deglutition** (swallowing), and speech (Figure 9.4.4 and Table 9.4.4). Because it is so moveable, the tongue facilitates complex speech patterns and sounds.

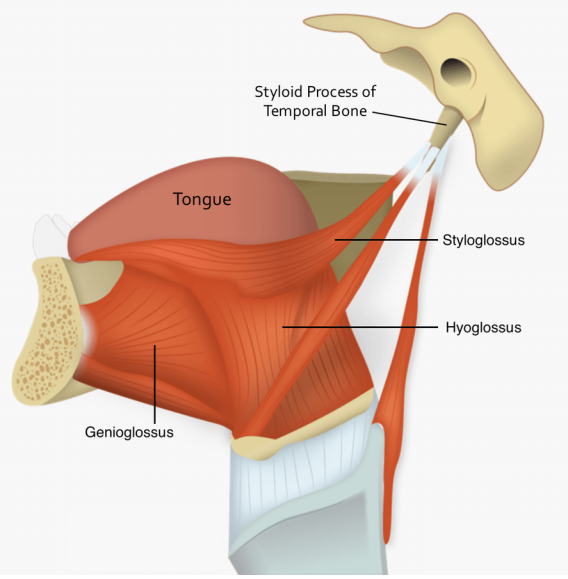

Figure 9.4.4: Muscles that Move the Tongue. The muscles that move the tongue allow for swallowing and speech. *(Image credit: "Extrinsic Tongue Muscles" by Jennifer Lange, modified from original by University of British Columbia Clinical Anatomy is licensed under CC BY-NC-SA 4.0)*

Table 9.4.4: Muscles for Tongue Movement, Swallowing, and Speech

Muscle	Origin	Insertion	Movement
Tongue			
Genioglossus	Mandible	Tongue undersurface; hyoid bone	Moves tongue down; sticks tongue out of mouth
Hyoglossus	Hyoid Bone	Sides of tongue	Flattens tongue
Styloglossus	Styloid process of temporal bone	Tongue undersurface and sides	Moves tongue up; retracts tongue back into mouth
Swallowing and Speaking			
Digastric	Mandible; temporal bone	Hyoid bone	Raises hyoid bone in a way that also raises the larynx, allowing the epiglottis to cover the glottis during deglutition; also assists in opening the mouth by depressing the mandible
Mylohyoid	Mandible	Hyoid bone; median raphe	Raises hyoid bone in a way that presses the tongue against the roof of the mouth, pushing food back into the pharynx during deglutition
Sternohyoid	Clavicle	Hyoid bone	Depresses the hyoid bone during swallowing and speaking

Tongue muscles can be extrinsic or intrinsic. Extrinsic tongue muscles insert into the tongue from outside origins, and the intrinsic tongue muscles insert into the tongue from origins within it. The extrinsic muscles move the whole tongue in different directions, whereas the intrinsic muscles allow the tongue to change its shape (such as, curling the tongue in a loop or flattening it).

The extrinsic muscles all include the word root glossus (glossus = “tongue”), and the muscle names are derived from where the muscle originates. The **genioglossus** (genio = “chin”) originates on the mandible and allows the tongue to move downward and forward. The **styloglossus** originates on the styloid bone, and allows upward and backward motion. The **hyoglossus** originates on the hyoid bone to move the tongue downward and flatten it.

EVERYDAY CONNECTIONS

Anesthesia and the Tongue Muscles

Before surgery, a patient must be made ready for general anesthesia. The normal homeostatic controls of the body are put “on hold” so that the patient can be prepped for surgery. Control of respiration must be switched from the patient’s homeostatic control to the control of the anesthesiologist. The drugs used for anesthesia relax a majority of the body’s muscles.

Among the muscles affected during general anesthesia are those that are necessary for breathing and moving the tongue. Under anesthesia, the tongue can relax and partially or fully block the airway, and the muscles of respiration may not move the diaphragm or chest wall. To avoid possible complications, the safest procedure to use on a patient is called endotracheal intubation. Placing a tube into the trachea allows the doctors to maintain a patient’s (open) airway to the lungs and seal the airway off from the oropharynx. Post-surgery, the anesthesiologist gradually changes the mixture of the gases that keep the patient unconscious, and when the muscles of respiration begin to function, the tube is removed. It still takes about 30 minutes for a patient to wake up, and for breathing muscles to regain control of respiration. After surgery, most people have a sore or scratchy throat for a few days.

Muscles of Swallowing and Speaking

The muscles of the anterior neck assist in deglutition (swallowing) and speech by controlling the positions of the larynx (voice box), and the hyoid bone, a horseshoe-shaped bone that functions as a solid foundation on which the tongue can move. The muscles of the neck are categorized according to their position relative to the hyoid bone (Figure 9.4.5). **Suprahyoid muscles** are superior to it, and the **infrahyoid muscles** are located inferiorly.

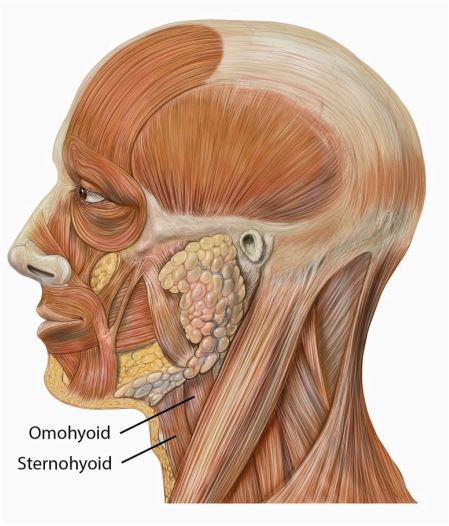

A. Lateral View

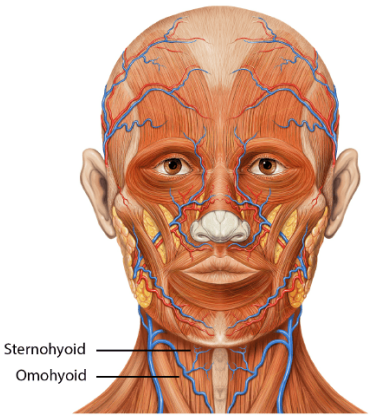

B. Anterior View

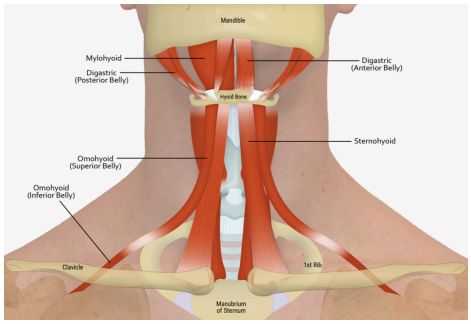

C. Anterior View of Inferior Chin

Figure 9.4.5: Infrahyoid and Suprahyoid Muscles. The anterior muscles of the neck facilitate swallowing and speech. Each of these muscles originate on or insert into the hyoid bone. From both anterior and lateral view points (A & B) only the superficial infrahyoid muscles can be seen. To see the suprahyoid muscles you need to view from a more inferior angle to see under the chin (C). *(Image credit: "Infrahyoid Muscles" by Jennifer Lange - A & B modified from original images by Patrick J. Lynch, http://patricklynch.net, licensed under CC-BY Attribution 2.5. Image C "Hyoid Muscles" by University of British Columbia Clinical Anatomy is licensed under CC BY-NC-SA 4.0 International.)*

The suprahyoid muscles raise the hyoid bone, the floor of the mouth, and the larynx during swallowing. Examples of these include the **digastric** muscle, which has anterior and posterior bellies that work to elevate the hyoid bone and larynx when one swallows; it also depresses the mandible. The **mylohyoid** muscle lifts the hyoid and helps press the tongue to the top of the mouth.

The strap-like infrahyoid muscles generally depress the hyoid bone and control the position of the larynx. For example, the **omohyoid** muscle, which has superior and inferior bellies, depresses the hyoid bone in conjunction with the **sternohyoid** muscles.

Muscles That Move the Head and Vertebral Column

The skull, attached to the top of the vertebral column, is balanced, moved, and rotated by muscles located in the neck. (Table 9.4.5). Muscles that insert into the skull move the head at the atlanto-occipital joint and they also move the neck at the cervical intervertebral joints. Additional muscles that insert into the cervical vertebrae also cause neck movements.

When these muscles act unilaterally (on one side), the joints of the head and cervical vertebrae rotate and laterally flex. When they contract bilaterally (both right and left sides), the joints of the head and cervical vertebrae flex or extend. The major muscle that, when contracting on only one side, causes lateral flexion and rotation is the **sternocleidomastoid**. When both sides contract together the joints flex. Place your fingers on both sides of the neck and tilt your head to the left and to the right. You will feel the movement originate there. (Figure 9.4.6).

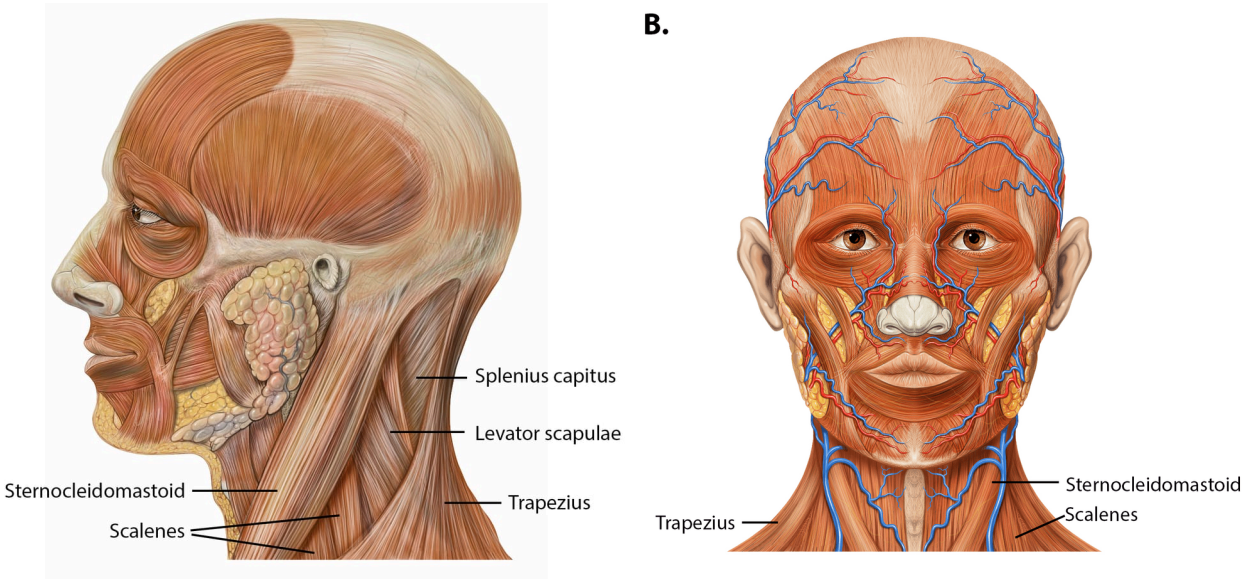

Figure 9.4.6: Lateral and Anterior Views of Neck Muscles. The superficial and deep muscles of the neck are responsible for moving the head, cervical vertebrae, and scapulae. (*Image credit: "Lateral and Anterior Neck Muscles" by Jennifer Lange, modified from original images by Patrick J. Lynch, http://patricklynch.net, licensed under CC-BY Attribution 2.5.*)

Table 9.4.5: Muscles That Move the Head

Muscle	Origin	Insertion	Movement	Image(s)
Longissimus capitis	Transverse and articular processes of cervical and thoracic vertebrae	Mastoid process of temporal bone	Rotates and tilts head to the side; tilts head backward	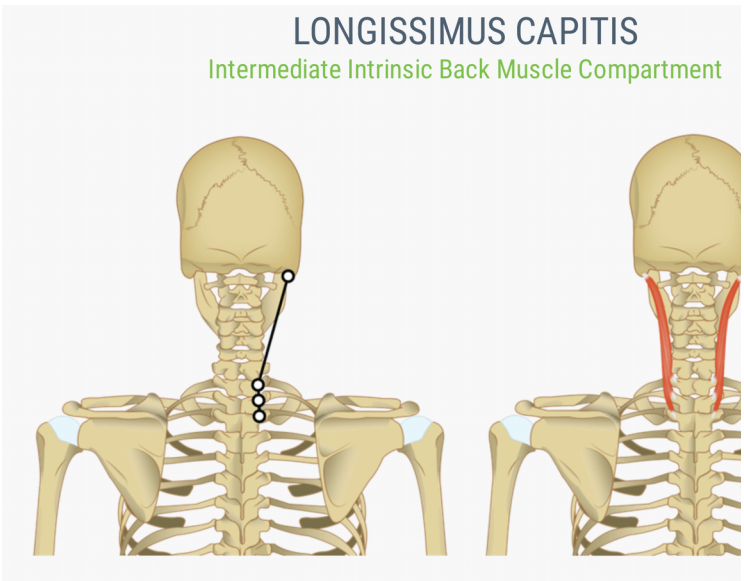
Semispinalis capitis	Transverse and articular processes of cervical and thoracic vertebrae	Occipital bone	Rotates and tilts head backward	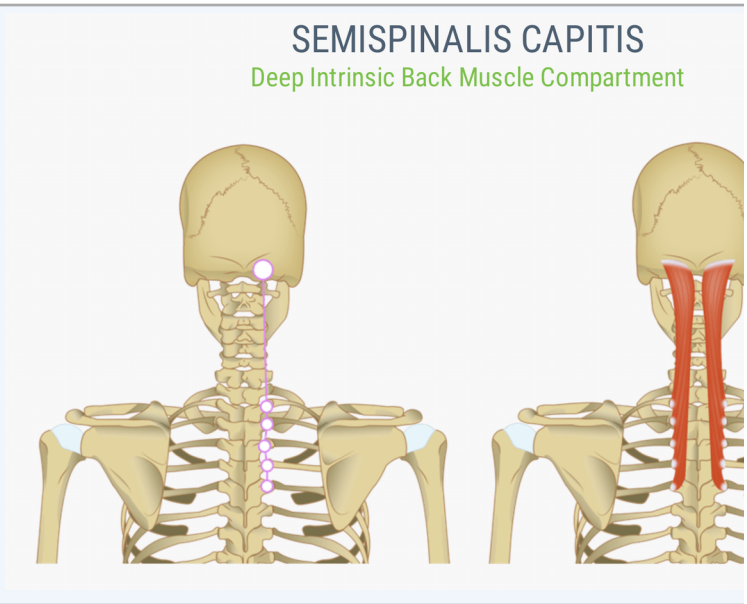

Muscle	Origin	Insertion	Movement	Image(s)
Splenius capitis	Spinous process of cervical and thoracic vertebrae	Mastoid process of temporal bone; occipital bone	Rotates and tilts head to the side; tilts head backward	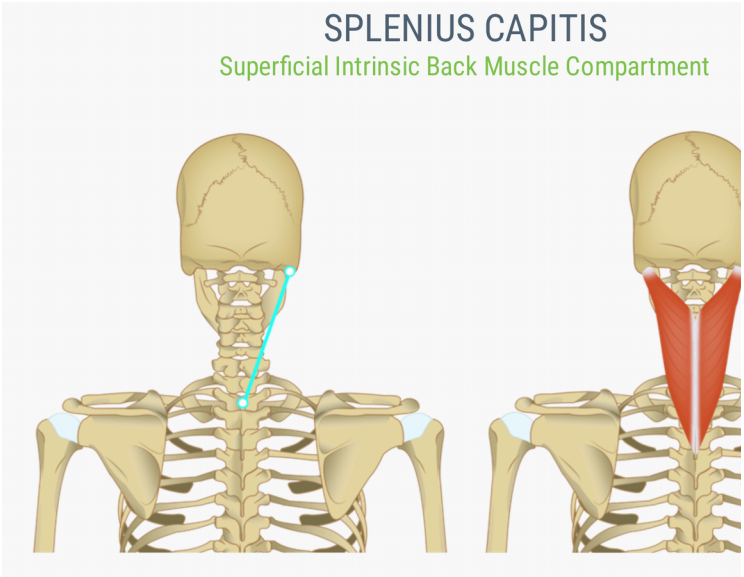
Sternocleidomastoid	Sternum; clavicle	Mastoid process of temporal bone; occipital bone	Rotates and tilts head to the side; tilts head forward	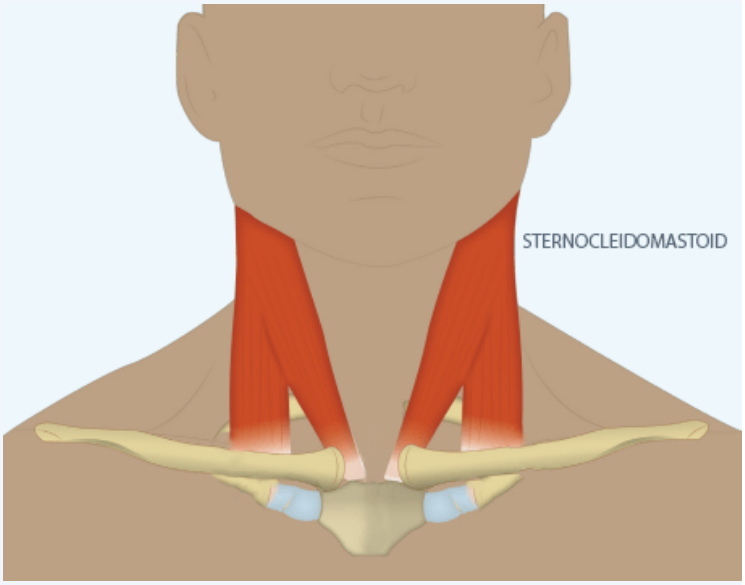

The muscles that insert into the skull are concerned with head movements and neck movements. The neck and back muscles that insert into vertebrae both stabilize and move the vertebral column. They are grouped according to the lengths and direction of the fascicles.

The **splenius** muscles originate at the midline and run laterally and superiorly to their insertions. From the sides and the back of the neck, the **splenius capitis** inserts onto the head region, and the **splenius cervicis** extends onto the cervical region. These muscles can extend the head, laterally flex it, and rotate it (Figure 9.4.7).

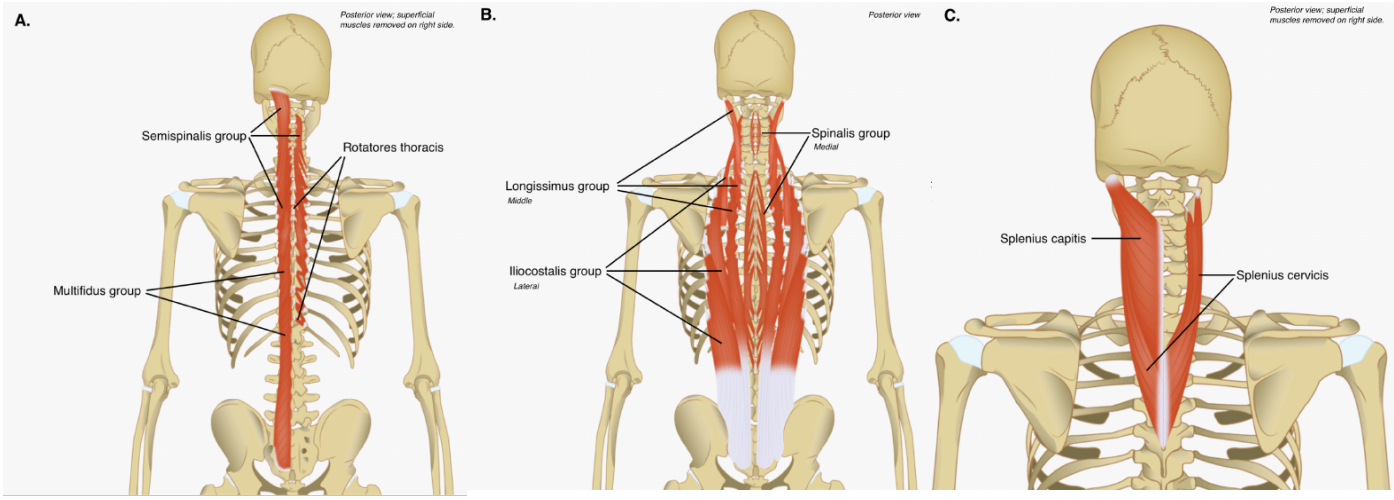

Figure 9.4.7: Muscles of the Posterior Neck and Back. The muscles of the along the posterior trunk work to both stabilize and move the vertebral column and some also move the head. They are arranged into two main groups based on their depth and function. A. Transversospinalis group, B. Erector spinae group, C. Splenius group. *(Image credit: "Muscles of the Posterior Neck and Back" by Jennifer Lange, modified from originals by University of British Columbia Clinical Anatomy is licensed under CC BY-NC-SA 4.0 International)*

The **erector spinae group** forms the majority of the muscle mass of the back and it is the primary extensor of the vertebral column. It controls flexion, lateral flexion, and rotation of the vertebral column, and maintains the lumbar curve. The erector spinae comprises the **iliocostalis** (laterally placed) **group**, the **longissimus** (intermediately placed) **group**, and the **spinalis** (medially placed) **group**.

The muscles in the **transversospinales group** run from the transverse processes to the spinous processes of the vertebrae and they function to stabilize and move the vertebral column. Similar to the erector spinae muscles, the **semispinalis muscles** and **multifidus muscles** in this group are named for the areas of the body with which they are associated. An additional muscle, rotatores thoracis, also rotates the vertebral column. All three muscle groups extend the vertebral column.

Finally, the **scalene muscles** work together to flex, laterally flex, and rotate the head. They also contribute to deep inhalation. The scalene muscles include the **anterior scalene** muscle (anterior to the middle scalene), the **middle scalene** muscle (the longest, intermediate between the anterior and posterior scalenes), and the **posterior scalene** muscle (the smallest, posterior to the middle scalene).

Interactive Element

3D rotation of the muscles of the head and neck.

The Anatomy of the Human by **HannahNewey** on **Sketchfab**

This interactive element is not available in this format. Visit the link or scan the QR code to access it online.

View this Interactive Content online

This interactive element is not available in this format. Visit the link or scan the QR code to access it online.

View this Interactive Content online

Concept Review

Muscles are either axial muscles or appendicular depending upon the location of the joints they move. The axial muscles move joints in the axial skeleton and are grouped based on location, function, or both. Groups include:

- **Facial expression:** The muscles in the face create expressions by inserting into the skin rather than onto bone.
- **Extraocular:** Muscles that move the eyeballs are extrinsic, meaning they originate outside of the eye and insert onto it.
- **Mastication:** The muscles that insert into the mandible are used for chewing, with the strongest ones elevating the mandible to close the jaw. They also play a role in speaking.
- **Tongue:** Tongue muscles are both extrinsic and intrinsic. They create complex movements that allow the tongue to move in all three planes as well as flatten and curl. These movements are used for directing food during chewing and swallowing.
- **Swallowing and speech:** The muscles of the anterior neck facilitate swallowing and speech, stabilize the hyoid bone and position the larynx.
- **Neck:** The muscles of the neck stabilize and move the head and move the joints between the cervical vertebrae.
- **Back and neck:** The muscles of the back and neck move the vertebral column can be divided into multiple groups including:
  - the splenius group in the posterior neck,
  - the erector spinae group run the length of the vertebral column to keep up upright; this group has three subgroups: the iliocostalis group, the longissimus group and the spinalis group,
  - the transversospinales group are shorter muscles that originate on the transverse processes in all regions,
  - the scalenes group in the lateral neck.

Review Questions

Query 9.4.1

This interactive element is not available in this format. Visit the link or scan the QR code to access it online.

View this Interactive Content online

Critical Thinking Questions

Query 9.4.2

This interactive element is not available in this format. Visit the link or scan the QR code to access it online.

View this Interactive Content online

Query 9.4.3

This interactive element is not available in this format. Visit the link or scan the QR code to access it online.

View this Interactive Content online

Query 9.4.4

This interactive element is not available in this format. Visit the link or scan the QR code to access it online.

View this Interactive Content online

Glossary

Query 9.4.5

This interactive element is not available in this format. Visit the link or scan the QR code to access it online.

View this Interactive Content online

Contributors and Attributions

- OpenStax Anatomy & Physiology (CC BY 4.0). Access for free at https://openstax.org/books/anatomy-and-physiology

This page titled 9.4: Axial Muscles of the Head, Neck, and Back is shared under a CC BY-NC-SA 4.0 license and was authored, remixed, and/or curated by Jennifer Lange et al..

- 10.4: Axial Muscles of the Head, Neck, and Back by Whitney Menefee, Julie Jenks, Chiara Mazzasette, and Kim-Leiloni Nguyen is licensed CC BY 4.0.

9.5: Axial Muscles of the Abdominal Wall and Thorax

By the end of this section, you will be able to:

- Identify the major skeletal muscles of the abdominal wall and thorax
- Identify the movements caused by these muscles

It is a complex job to balance the body on two feet and walk upright. The muscles of the vertebral column, thorax, and abdominal wall extend, flex, and stabilize different parts of the body's trunk. The deep muscles of the core of the body help maintain posture as well as carry out other functions. The brain sends out electrical impulses to these various muscle groups to control posture by alternate contraction and relaxation. This is necessary so that no single muscle group becomes fatigued too quickly. If any one group fails to function, body posture will be compromised.

Muscles of the Abdomen

There are four pairs of abdominal muscles that cover the anterior and lateral abdominal region and meet at the anterior midline: the external obliques, the internal obliques, the transversus abdominis, and the rectus abdominis (Figure 9.5.1, Figure 9.5.2 and Table 9.5.1).

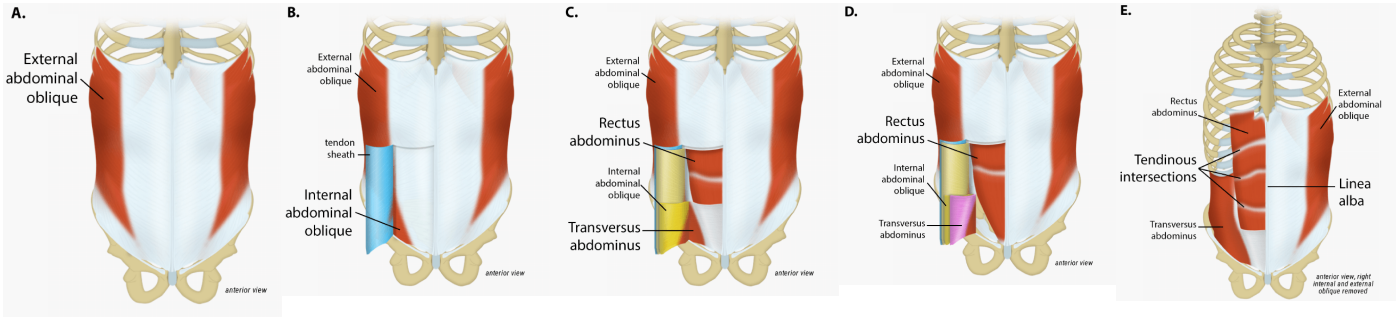

Figure 9.5.1: Muscles of the Abdomen. On the lateral and posterior walls the abdomen has three layers of muscles. From superficial to deep they are: A. external abdominal oblique, B. internal abdominal oblique, and C. transversus abdominus. In images C and D you can see the anteromedial muscle, the rectus abdominus. Tendon associated with these muscles are the tendinous intersections and the linea alba (image E). *(Image credits: "Abdominal Muscles" by Jennifer Lange are licensed under CC BY-NC-SA 4.0, based on images by University of British Columbia Clinical Anatomy)*

There are three flat skeletal muscles in the antero-lateral wall of the abdomen. The **external oblique**, closest to the surface, extend inferiorly and medially, in the direction of sliding one's four fingers into pants pockets. Perpendicular to it is the intermediate **internal oblique**, extending superiorly and medially, the direction the thumbs usually go when the other fingers are in the pants pocket. The deep muscle, the **transversus abdominis**, is arranged transversely around the abdomen, similar to the front of a belt on a pair of pants. This arrangement of three bands of muscles in different orientations allows various movements and rotations of the trunk. The three layers of muscle also help to protect the internal abdominal organs in an area where there is no bone.

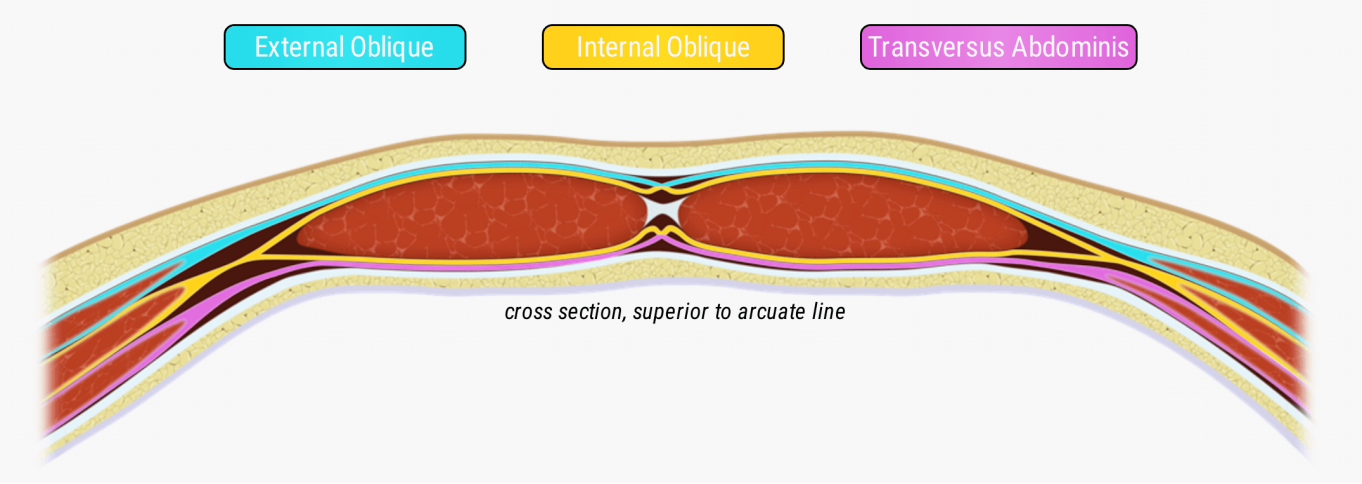

Figure 9.5.2: Muscles of the Abdomen - Cross Section. When viewed in cross section the relative positions of the lateral muscles can easily be seen. The tendon of the external oblique passes superficial to the rectus abdominus while the tendon of the transversus abdominus passes deep. The tendon of the internal oblique splits to pass around both sides.

*The **linea alba** is a white, fibrous band that is made of the bilateral **rectus sheaths** that join at the anterior midline of the body. These enclose the **rectus abdominis** muscles (a pair of long, linear muscles, commonly called the "sit-up" muscles) that originate at the pubic crest and symphysis, and extend the length of the body's trunk. Each muscle is segmented by three transverse bands of collagen fibers called the **tendinous intersections**. This results in the look of "six-pack abs," as each segment hypertrophies on individuals at the gym who do many sit-ups.*

Table 9.5.1: Muscles of the Abdomen

Muscle	Origin	Insertion	Movement	Image(s)
Internal oblique	Lumbar fascia, inguinal ligament and iliac crest	Linea alba, inferior rib surfaces 9-12, costal cartilages 8-10	Bilateral: Flexes vertebral column Unilateral: Lateral flexion and rotation of vertebral column	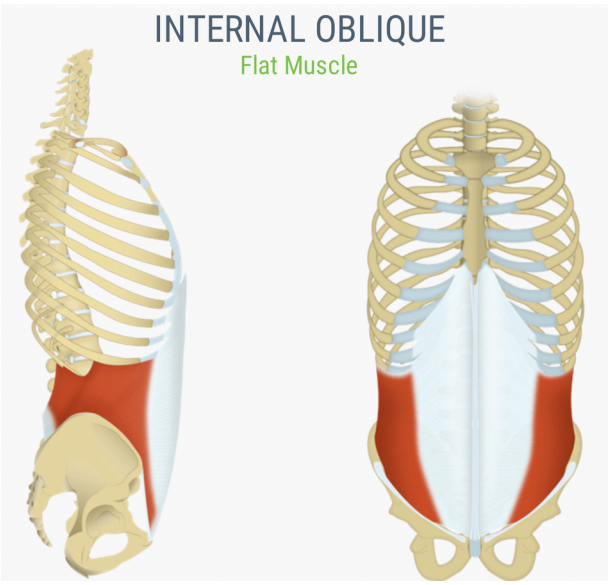

Muscle	Origin	Insertion	Movement	Image(s)
External oblique	Ilium; ribs 5 - 12	Ilium; linea alba; ribs 7 - 10	Bilateral: Flexes vertebral column Unilateral: Lateral flexion and rotation of vertebral column	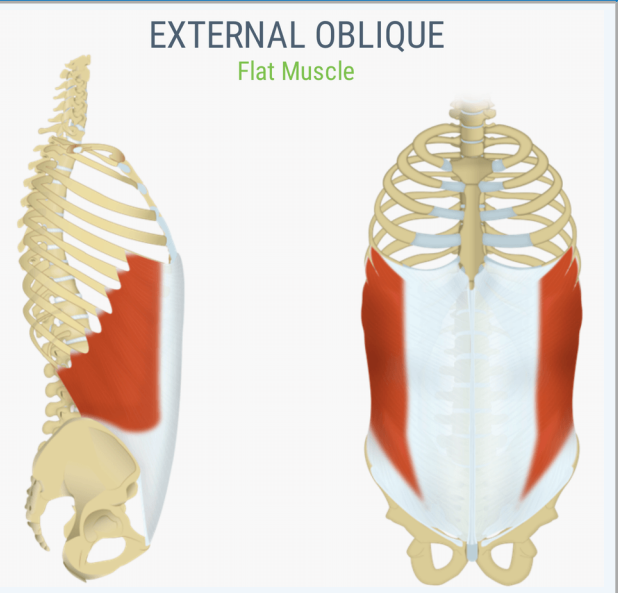
Rectus abdominis	Pubis	Ribs 5 and 7; sternum	Flexion of vertebral column	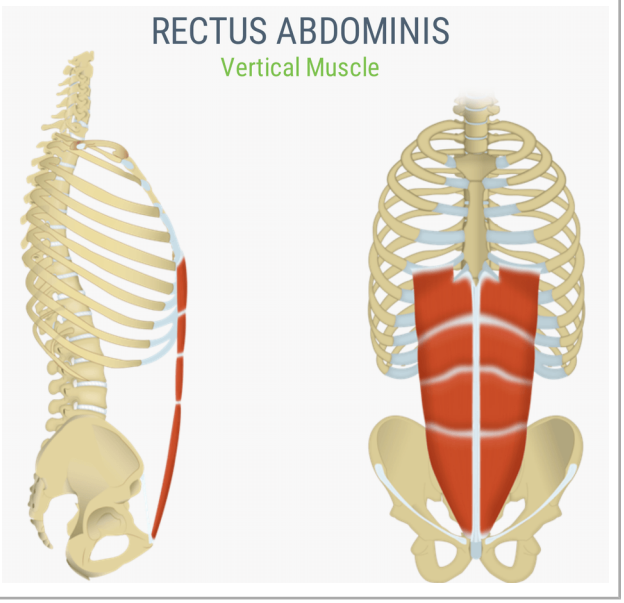

Muscle	Origin	Insertion	Movement	Image(s)
Transverse abdominus	Ilium; ribs 5 - 10	Linea alba; pubis; sternum	Squeezing abdomen during forceful exhalations, defecation, urination, and childbirth	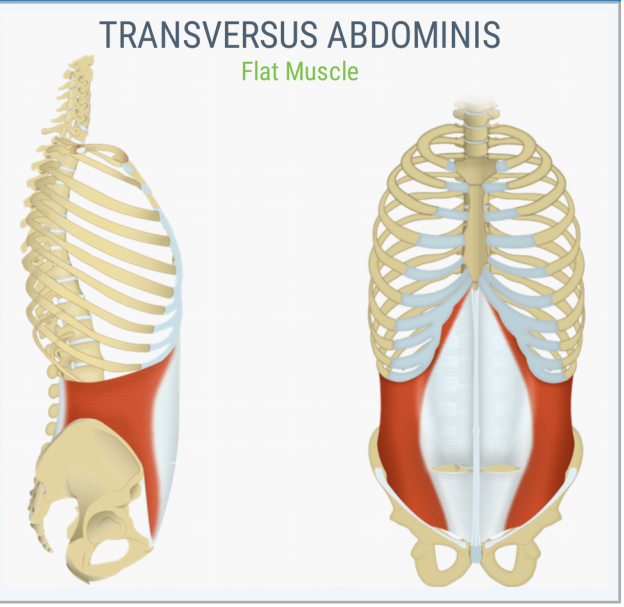

CAREER CONNECTIONS

Physical Therapist and Physical Therapy Assistant

Those who have a muscle or joint injury will most likely be sent to a physical therapist (PT) after seeing their regular doctor. PTs have a master's degree or doctorate, and are highly trained experts in the mechanics of body movements. Many PTs also specialize in sports injuries.

If you injured your shoulder the first thing a physical therapist would do during your first visit is to assess the functionality of the joint. The range of motion of a particular joint refers to the normal movements the joint performs. The PT will ask you to abduct and adduct, circumduct, and flex and extend the arm. The PT will note the shoulder's degree of function, and based on the assessment of the injury, will create an appropriate physical therapy plan. This plan can involve visits to the clinic to work with a Physical Therapy Assistant (PTA) who will help guide you through the appropriate exercises. Most likely, you also will be instructed to do a series of exercises to continue the therapy at home, followed by icing to decrease inflammation and swelling, which will continue for several weeks.

When physical therapy is complete, the PT will do an exit exam and send a detailed report on the improved range of motion and return of normal limb function to your doctor. Gradually, as the injury heals, the shoulder will begin to function correctly. Both Physical Therapists and Physical Therapy Assistants work closely with patients to help them get back to their normal level of physical activity.

Physical therapy technician Troy Hopkins assists retired Maj. Gen. William L. Moore Jr. at the Center for the Intrepid, Brooke Army Medical Center's outpatient rehabilitation facility on Joint Base San Antonio-Fort Sam Houston in San Antonio, Sept. 3, 2015. *(U.S. Army photo by Robert T. Shields/Released to Public Domain)*

Sierra Stout, a physical therapist with Global Outreach Doctors teaches a mobility exercise to a boy with scoliosis at a temporary medical treatment site in Point Fortin, Trinidad, Sept. 7, 2019. Comfort is working with health and government partners in Central America, South America, and the Caribbean to provide care on the ship and at land-based medical sites, helping to relieve pressure on national medical systems.

(U.S. Navy photo by Mass Communication Specialist Seaman Jordan R. Bair/Released to Public Domain)\

Muscles of Respiration

The muscles of the chest serve to facilitate breathing by changing the size of the thoracic cavity (Table 9.5.2). Movement of the ribs in a superior direction is called elevation of the ribs at both the sternocostal and vertebrocostal joints. Your chest expands drawing air into your lungs. Movement of the ribs in an inferior direction is called depression of the ribs, at the same joints. For your resting breathing no muscular contraction is necessary due to elasticity, but for deep exhalation muscles will pull the ribs downward and inward to decrease the size of the thoracic cavity.

Table 9.5.2: Muscles of the Thorax

Muscle	Origin	Insertion	Movement
Diaphragm	Lumbar vertebrae; ribs 6 - 12; sternum	Central tendon	Inhalation; compression of abdominopelvic cavity
Internal intercostals	Rib inferior to each intercostal muscle	Rib superior to each intercostal muscle	Forced exhalation
External intercostals	Rib superior to each intercostal muscle	Rib inferior to each intercostal muscle	Inhalation; elevation of ribs
Scalenes	Transverse processes of cervical vertebrae	Superior surface of 1st and 2nd rib	Elevate 1st and 2nd rib during forced inhalation

The change in volume of the thoracic cavity during breathing is due to the alternate contraction and relaxation of the **diaphragm**. It separates the thoracic and abdominal cavities, and is dome-shaped at rest (Figure 9.5.3). The superior surface of the diaphragm is convex, creating the elevated floor of the thoracic cavity. The inferior surface is concave, creating the curved roof of the abdominal cavity. Defecating, urination, and even childbirth involve cooperation between the diaphragm and abdominal muscles (this cooperation is referred to as the “Valsalva maneuver”). You hold your breath by a steady contraction of the diaphragm; this stabilizes the volume and pressure of the peritoneal cavity. When the abdominal muscles contract, the pressure cannot push the diaphragm up, so it increases pressure on the intestinal tract (defecation), urinary tract (urination), or reproductive tract (childbirth).

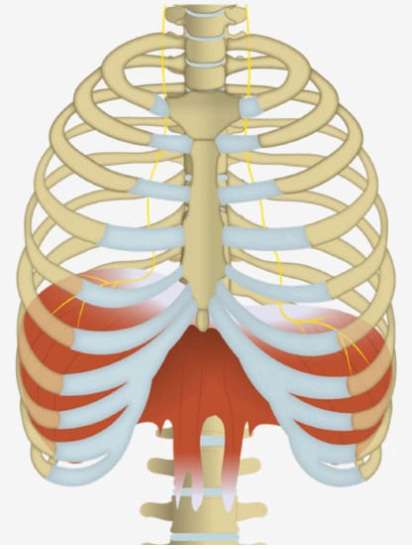

Figure 9.5.3: Diaphragm. The diaphragm is a dome-shaped muscle that serves as the divider between the thoracic cavity and the abdominal cavity. It is the primary muscle of breathing. *(Image credit: "The Diaphragm" by University of British Columbia Clinical Anatomy are licensed under CC BY-NC-SA 4.0 International)*

The central of the diaphragm is its tendon. To the sides of the tendon are the skeletal muscle portions of the diaphragm, which insert into the tendon while having a number of origins including the xiphoid process of the sternum anteriorly, the inferior six ribs and their cartilages laterally, and the lumbar vertebrae and 12th ribs posteriorly. The central tendon of the diaphragm also includes three openings for the passage of structures between the thorax and the abdomen such as the inferior vena cava, aorta, and the esophagus.

Assisting the diaphragm during deep breathing are two sets of muscles, called **intercostal muscles**, that span each of the intercostal spaces. The principal role of the intercostal muscles is to assist in breathing by changing the dimensions of the rib cage (Figure 9.5.4).

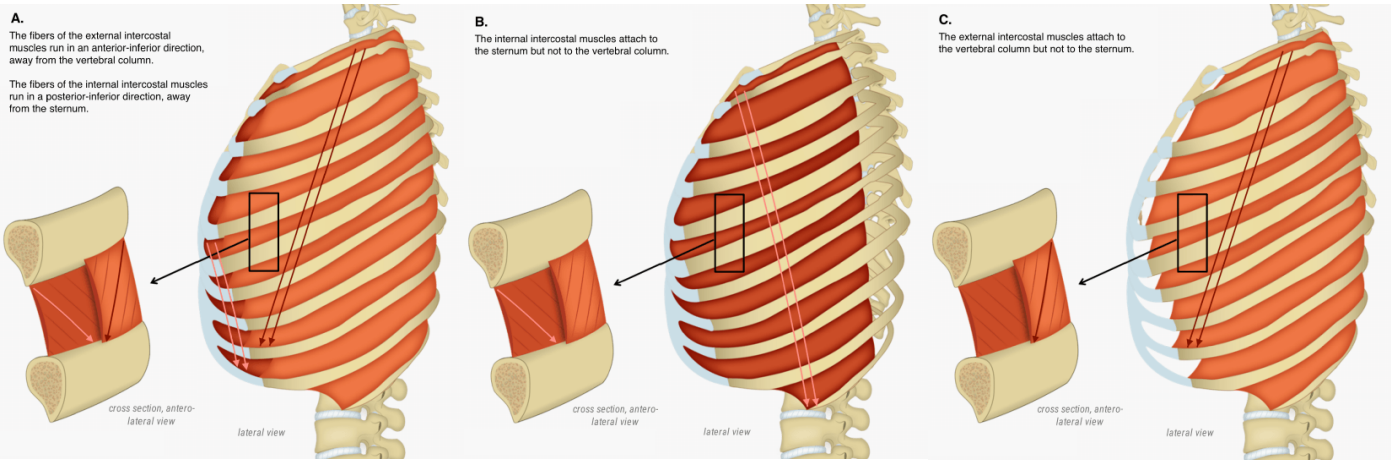

Figure 9.5.4: Intercostal Muscles. The internal and external intercostal muscles run between adjacent ribs. You can determine which is which by looking at their fiber angle and and their position relative to the sternum. *(Image credit: "External and Internal Intercostals" by Jennifer Lange, modified from originals by University of British Columbia Clinical Anatomy are licensed under CC BY-NC-SA 4.0 International)*

The 11 pairs of superficial **external intercostal** muscles aid in inspiration of air during breathing because when they contract, they raise the ribs, which expands the thoracic cavity. The 11 pairs of **internal intercostal** muscles, just deep to the externals, are used for forced (deep) expiration because they draw the ribs together to constrict the rib cage. The movement of the ribs caused by the intercostals is visualized using to analogies: a bucket handle and a pump handle.

Rib Movement During Breathing

To view animations of the movements of the thoracic cage during inhalation and exhalation visit UBC's Clinical Anatomy and select the pages "bucket handle effect" and "pump handle effect".

Muscles of the Pelvic Floor

The pelvic floor is a muscular sheet that defines the inferior portion of the pelvic cavity. The **pelvic diaphragm**, spanning anteriorly to posteriorly from the pubis to the coccyx, comprises the levator ani and the ischiococcygeus. Its openings include the anal canal and urethra, and the vagina in females.

The large **levator ani** consists of two skeletal muscles, the **pubococcygeus** and the **iliococcygeus** (Figure 9.5.5). The levator ani is considered the most important muscle of the pelvic floor because it supports the pelvic viscera. It resists the pressure produced by contraction of the abdominal muscles so that the pressure is applied to the colon to aid in defecation and to the uterus to aid in childbirth (assisted by the **ischiococcygeus**, which pulls the coccyx anteriorly). This muscle also creates skeletal

muscle sphincters at the urethra and anus. The posterior muscle of the of the pelvic floor is the **coccygeus**.

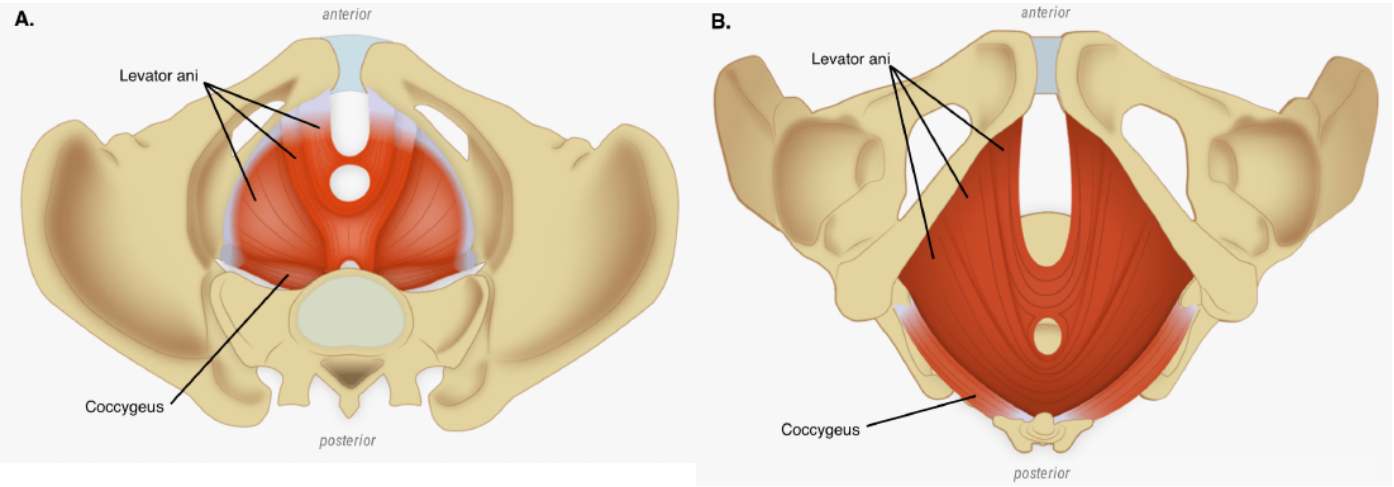

Figure 9.5.5: Muscles of the Pelvic Floor. The pelvic floor muscles support the pelvic organs, resist intra-abdominal pressure, and work as sphincters for the urethra, rectum, and vagina. *(Image credit: "Muscles of the Pelvic Floor" by Jennifer Lange, modified from originals by University of British Columbia Clinical Anatomy are licensed under CC BY-NC-SA 4.0 International)*

Concept Review

Made of skin, fascia, and four pairs of muscle, the anterior abdominal wall protects the organs located in the abdomen and moves the vertebral column. These muscles include the rectus abdominis, which extends through the entire length of the trunk, the external oblique, the internal oblique, and the transversus abdominus. The quadratus lumborum forms the posterior abdominal wall.

The muscles of the thorax play a large role in breathing, especially the dome-shaped diaphragm. When it contracts and flattens, the volume inside the pleural cavities increases, which decreases the pressure within them. As a result, air will flow into the lungs. The external and internal intercostal muscles span the space between the ribs and help change the shape of the rib cage and the volume-pressure ratio inside the pleural cavities during inspiration and expiration.

The perineum muscles play roles in urination in both sexes, ejaculation in men, and vaginal contraction in women. The pelvic floor muscles support the pelvic organs, resist intra-abdominal pressure, and work as sphincters for the urethra, rectum, and vagina.

Review Questions

Query 9.5.1

This interactive element is not available in this format. Visit the link or scan the QR code to access it online.

View this Interactive Content online

Critical Thinking Questions

Query 9.5.2

This interactive element is not available in this format. Visit the link or scan the QR code to access it online.

View this Interactive Content online

Query 9.5.3

This interactive element is not available in this format. Visit the link or scan the QR code to access it online.

View this Interactive Content online

Glossary

Query 9.5.4

This interactive element is not available in this format. Visit the link or scan the QR code to access it online.

View this Interactive Content online

Contributors and Attributions

- OpenStax Anatomy & Physiology (CC BY 4.0). Access for free at https://openstax.org/books/anatomy-and-physiology

This page titled 9.5: Axial Muscles of the Abdominal Wall and Thorax is shared under a CC BY-NC-SA 4.0 license and was authored, remixed, and/or curated by Jennifer Lange et al..

- 10.5: Axial Muscles of the Abdominal Wall and Thorax by Whitney Menefee, Julie Jenks, Chiara Mazzasette, and Kim-Leiloni Nguyen is licensed CC BY 4.0.

9.6: Appendicular Muscles of the Pectoral Girdle and Upper Limbs

By the end of this section, you will be able to:

- Identify the muscles of the pectoral girdle and upper limbs
- Identify the movement and function of the pectoral girdle and upper limbs

Muscles of the shoulder and upper limb can be divided into four groups: muscles that stabilize and position the pectoral girdle, muscles that move the arm, muscles that move the forearm, and muscles that move the wrists, hands, and fingers. The **pectoral girdle**, or shoulder girdle, consists of the lateral ends of the clavicle and scapula, along with the proximal end of the humerus, and the muscles covering these three bones to stabilize the shoulder joint. The girdle creates a base from which the head of the humerus, in its ball-and-socket joint with the glenoid fossa of the scapula, can move the arm in multiple directions.

Muscles That Move the Pectoral Girdle at the Sternoclavicular Joint

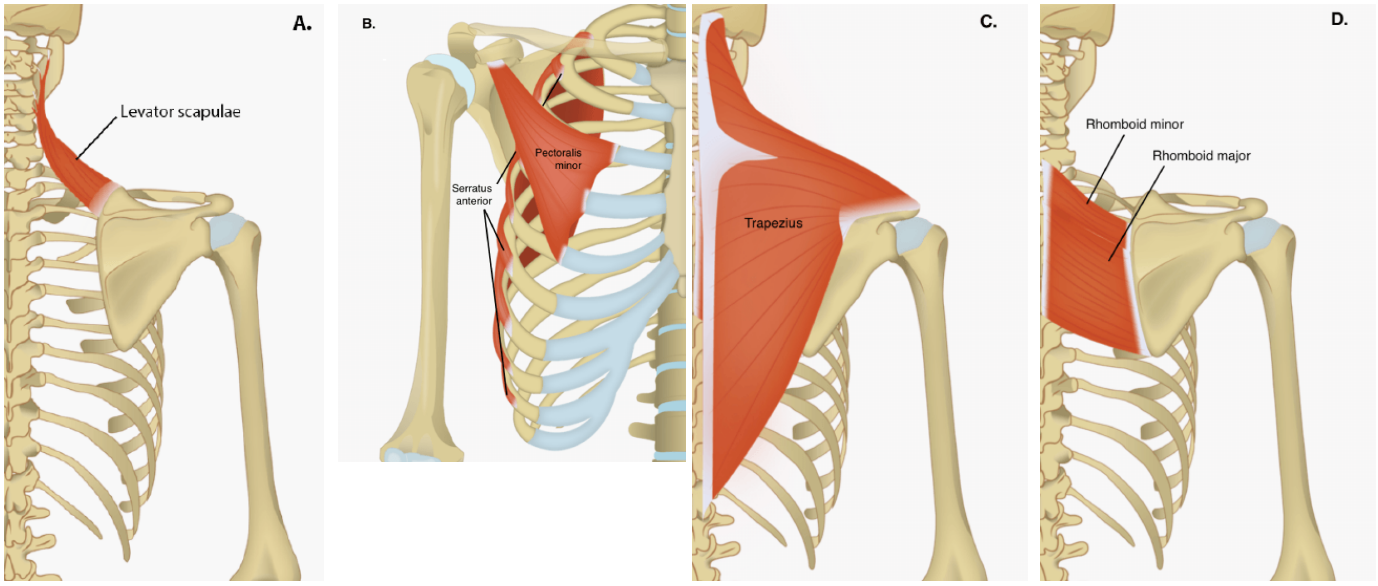

Figure 9.6.1: Muscles that Position the Pectoral Girdle. The muscles that stabilize the pectoral girdle make it a steady base on which other muscles can move the arm: A. Posterior muscle - deep, B. Anterior muscles - deep, C. Posterior muscles - superficial, D. Posterior muscles - deep. *(Image credit: "Muscles that Position the Pectoral Girdle" by Jennifer Lange are licensed under CC BY-NC-SA 4.0, based on images by University of British Columbia Clinical Anatomy.)*

Muscles that position the pectoral girdle are located either on the anterior thorax or on the posterior thorax (Figure 9.6.1 and Table 9.6.1). The anterior muscles include the **subclavius**, **pectoralis minor**, and **serratus anterior**. The posterior muscles include the **trapezius**, **levator scapulae, rhomboid major**, and **rhomboid minor**. When the rhomboids are contracted, your scapula moves medially, which can pull the shoulder and upper limb posteriorly.

Table 9.6.1: Muscles that Position the Pectoral Girdle

Muscle	Origin	Insertion	Movement	Image(s)
Levator scapulae	Transverse processes of C_1-C_4	Superior, medial border of scapula	Elevates and inferiorly rotates scapula (video)	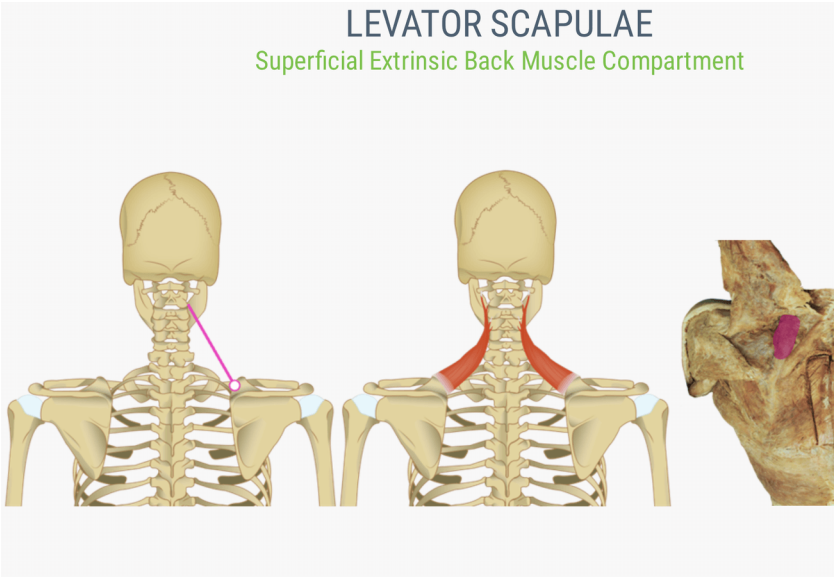
Pectoralis minor	Anterior surfaces of certain ribs (2 - 4 or 3 - 5)	Coracoid process of scapula	Rotates shoulder anteriorly (throwing motion); assists with inhalation	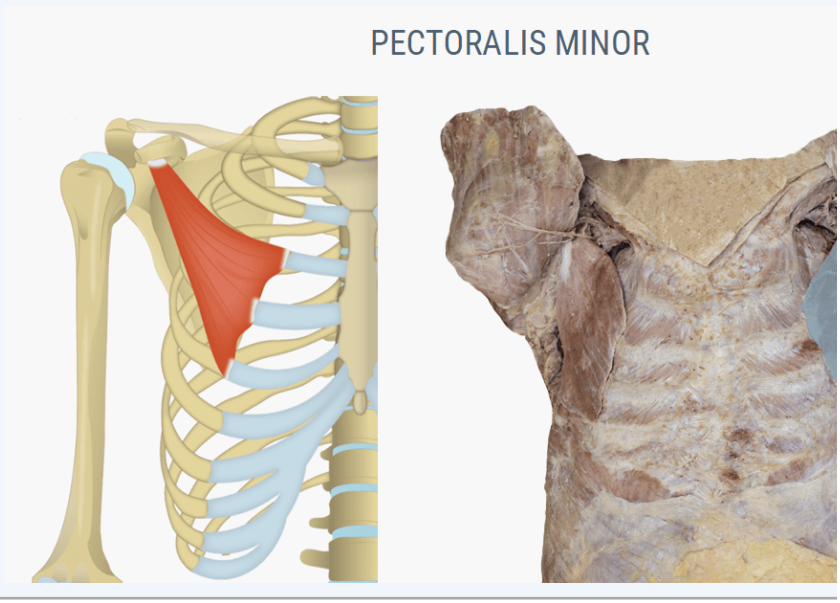

Muscle	Origin	Insertion	Movement	Image(s)
Rhomboid major	Thoracic vertebrae (T_2 - T_5)	Medial border of scapula	Retracts scapula (video)	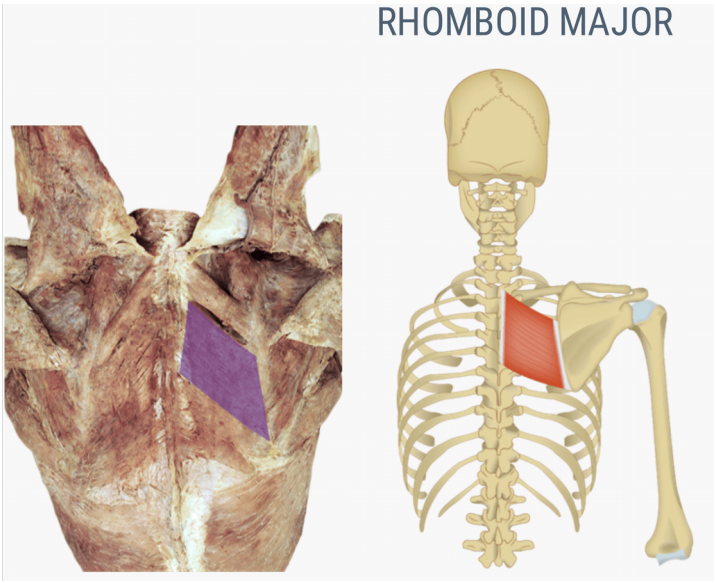
Rhomboid minor	Cervical and thoracic vertebrae (C7 and T1)	Medial border of scapula	Retracts scapula (video)	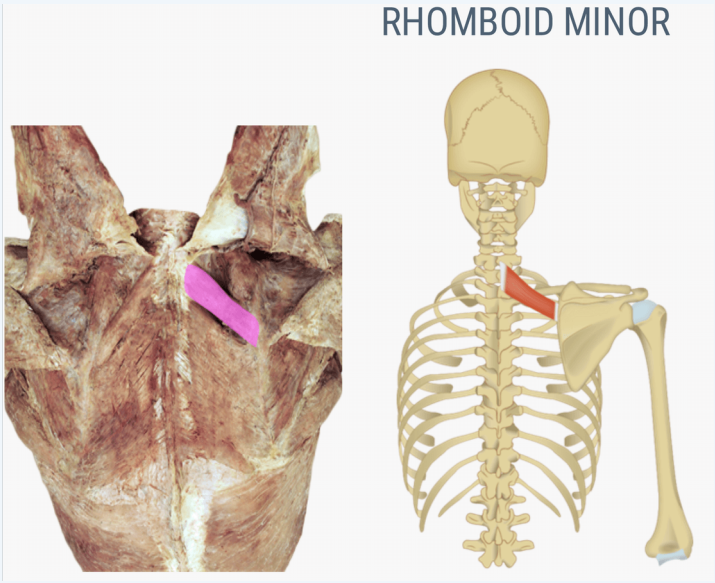

Muscle	Origin	Insertion	Movement	Image(s)
Serratus anterior	Muscle slips from certain ribs (1 - 8 or 1 - 9)	Anterior surface of vertebral border of scapula	Protracts scapula (video)	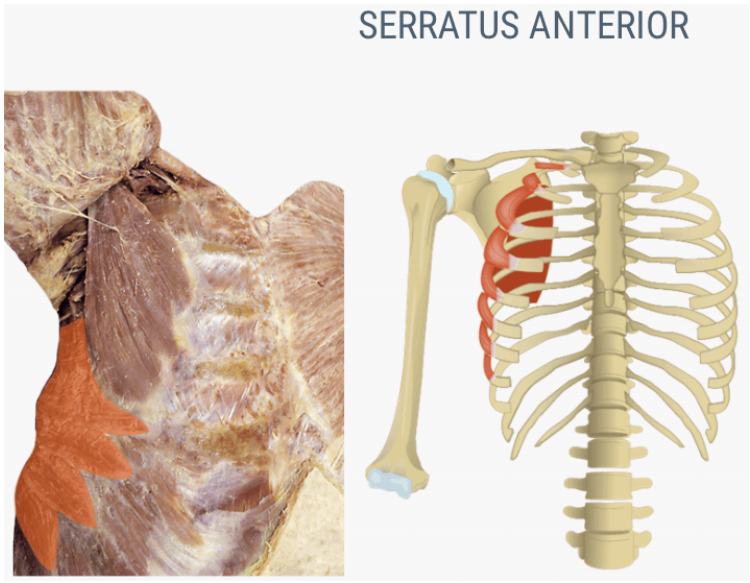
Trapezius	Skull; vertebral column	Acromion and spine of scapula; clavicle	Dependent upon which fibers are stimulated (video): 1. Elevate and rotate scapula, 2. Depress and rotate scapula, 3. Retract scapula	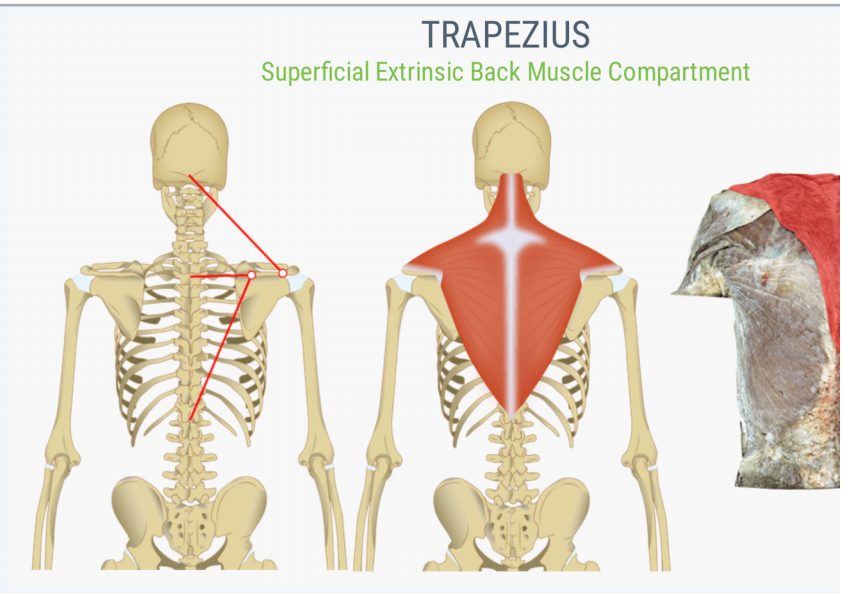

Image Credits

All images in this table are by *University of British Columbia Clinical Anatomy* and are licensed under *CC BY-NC-*

Muscles That Move the Humerus at the Shoulder Joint

Similar to the muscles that position the pectoral girdle, muscles that cross the shoulder joint and move the humerus bone of the arm include both axial and scapular muscles (Figure 9.6.2 and Table 9.6.2). The two muscles that originate on the axial skeleton are the **pectoralis major** and the latissimus dorsi. The pectoralis major is thick and fan-shaped, covering much of the superior portion of the anterior thorax. The broad, triangular **latissimus dorsi** is located on the inferior part of the back, where it inserts into a thick connective tissue sheath called an aponeurosis.

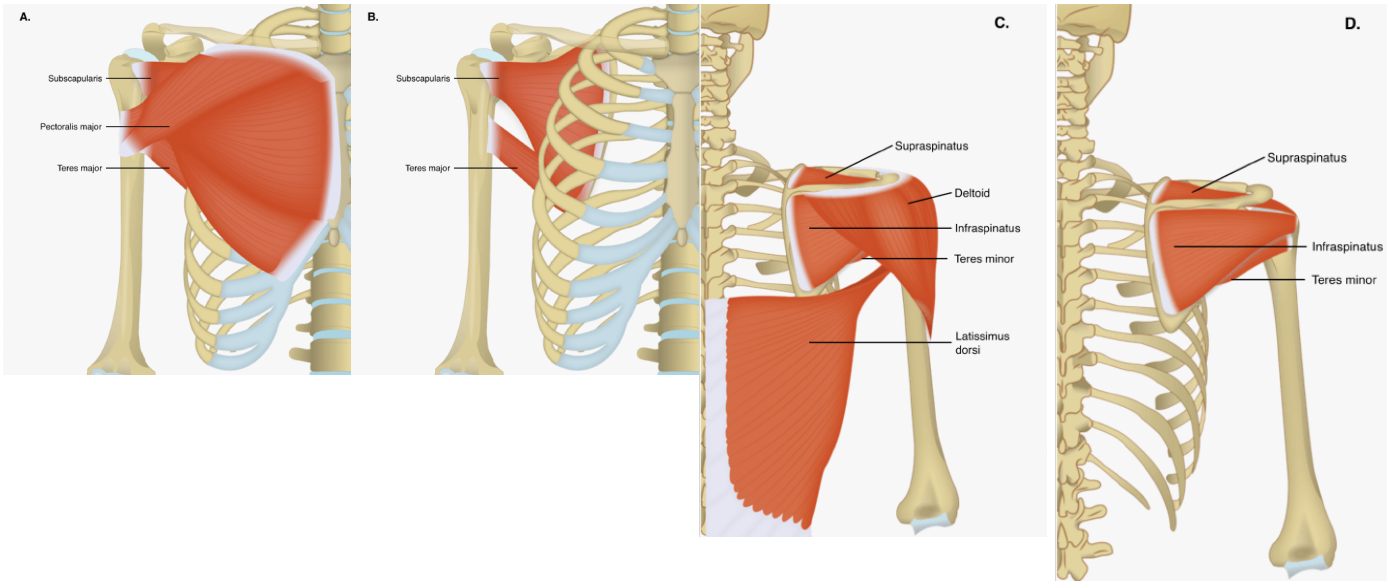

Figure 9.6.2: Muscles That Move the Humerus. A. Anterior view, superficial. B. Anterior view, deep. C. Posterior view, superficial. D. Posterior view, deep *(Image credit: "Muscles that Move the Humerus" by Jennifer Lange are licensed under CC BY-NC-SA 4.0, based on images by University of British Columbia Clinical Anatomy.)*

Table 9.6.2: Muscles that Move the Humerus at the Shoulder Joint

Muscle	Origin	Insertion	Movement	Image(s)
Latissimus dorsi	Thoracic vertebrae (T7-T12); lumbar vertebrae; lower ribs (9-12); iliac crest	Intertubercular sulcus of humerus	Extends, adducts, and internally rotates shoulder (video)	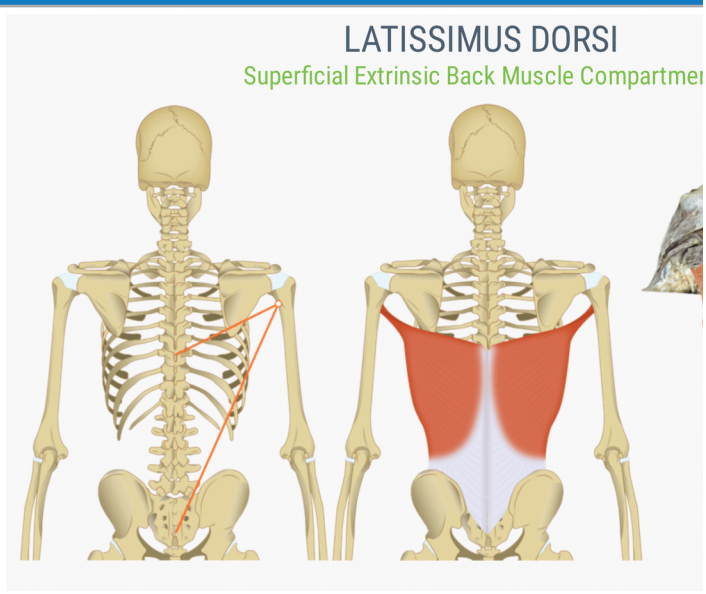

Muscle	Origin	Insertion	Movement	Image(s)
Pectoralis major	Clavicle; sternum; cartilage of certain ribs (1-6 or 1-7); aponeurosis of external oblique muscle	Greater tubercle of humerus	Flex, adduct, and internally rotate shoulder (video)	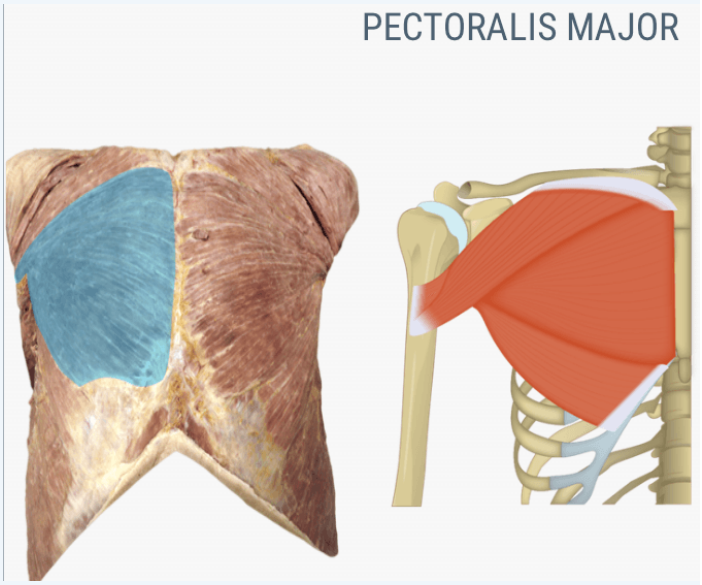
Coracobrachialis	Coracoid process of scapula	Medial surface of humerus shaft	Flex and adduct shoulder	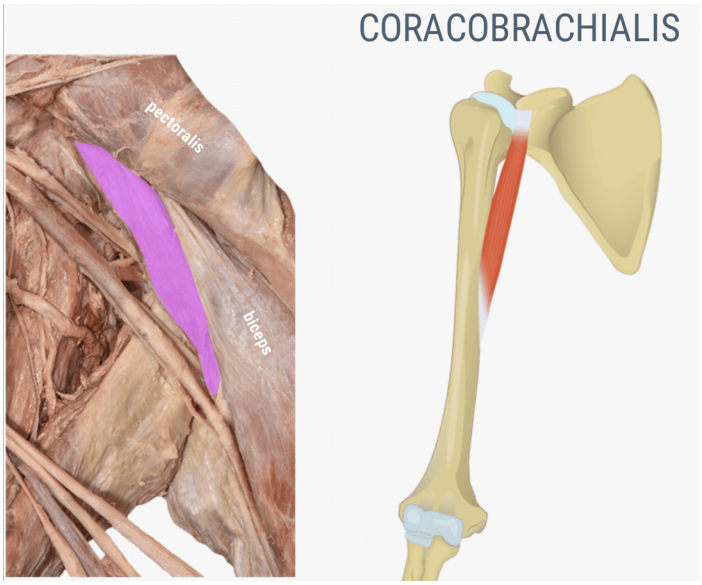

Muscle	Origin	Insertion	Movement	Image(s)
Deltoid	Trapezius; clavicle; acromion and spine of scapula	Deltoid tuberosity of humerus	Extends, abducts, and flexes shoulder (video) - motion is dependent upon which fibers are activated	
Subscapularis (part of rotator cuff)	Subscapular fossa of scapula	Lesser tubercle of humerus	Adduct and internally rotate shoulder; stabilizes shoulder joint during movement of the pectoral girdle (video)	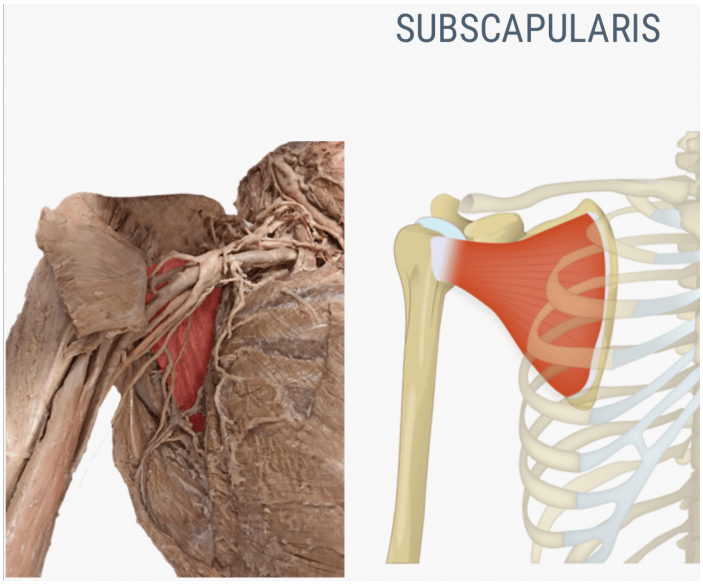

Muscle	Origin	Insertion	Movement	Image(s)
Infraspinatus (part of rotator cuff)	Infraspinous fossa of scapula	Greater tubercle of humerus	Externally rotate shoulder (video)	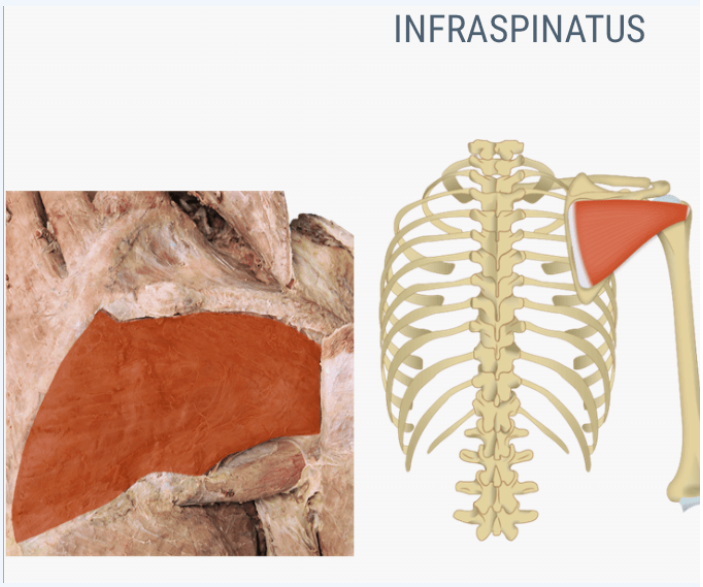
Supraspinatus (part of rotator cuff)	Supraspinous fossa of scapula	Greater tubercle of humerus	Abduct shoulder (video)	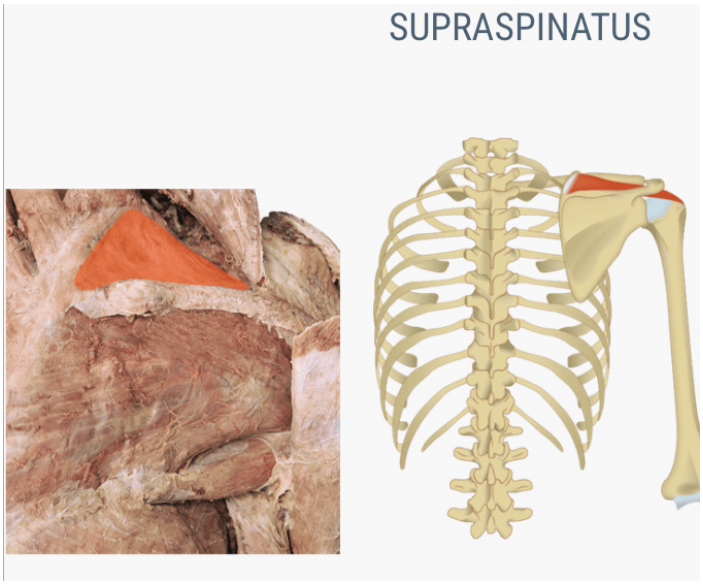

Muscle	Origin	Insertion	Movement	Image(s)
Teres major	Posterior surface of scapula	Intertubercular sulcus of humerus	Adduct and internally rotate shoulder	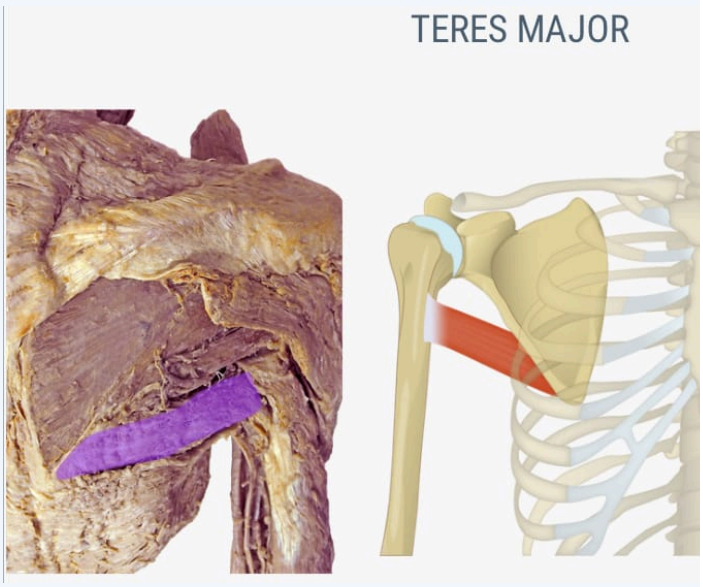
Teres minor (part of rotator cuff)	Lateral border of dorsal scapular surface	Greater tubercle of humerus	Externally rotate shoulder	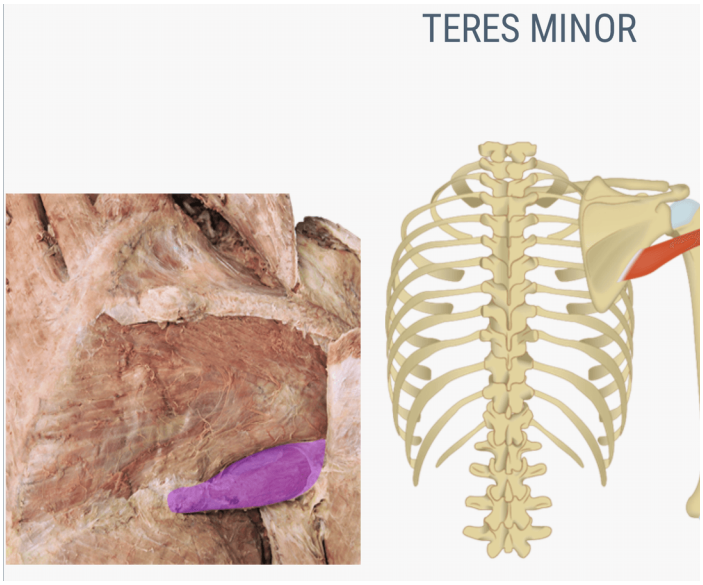

Image Credits

All images in this table are by *University of British Columbia Clinical Anatomy* and are licensed under *CC BY-NC-*

The rest of the shoulder muscles originate on the scapula. The anatomical and ligamental structure of the shoulder joint and the arrangements of the muscles covering it, allows the arm to carry out different types of movements. The **deltoid**, the thick muscle that creates the rounded lines of the shoulder is the major abductor of the arm, but it also facilitates flexing and medial rotation, as well as extension and lateral rotation. The **subscapularis** originates on the anterior scapula and medially rotates the arm. Named for their locations, the **supraspinatus** (superior to the spine of the scapula) and the **infraspinatus** (inferior to the spine of the scapula) abduct the arm, and laterally rotate the arm, respectively. The thick and flat **teres major** is inferior to the teres minor and extends the arm, and assists in adduction and medial rotation of it. The long **teres minor** laterally rotates and extends the arm. Finally, the **coracobrachialis** flexes and adducts the arm.

The tendons of the subscapularis, supraspinatus, infraspinatus, and teres minor connect the scapula to the humerus, forming the **rotator cuff** (musculotendinous cuff), the circle of tendons around the shoulder joint. When baseball pitchers undergo shoulder surgery it is usually on the rotator cuff, which becomes pinched and inflamed, and may tear away from the bone due to the

repetitive motion of bring the arm overhead to throw a fast pitch.

Muscles That Move the Forearm at the Elbow Joint

The forearm, containing the radius and ulna, has two actions at the hinge of the elbow joint: flexion, extension. The the muscles that cause flexion at the elbow joint include the **biceps brachii**, **brachialis**, and **brachioradialis**. The extensors are the **triceps brachii** and **anconeus**.

The biceps brachii, brachialis, and brachioradialis flex the forearm at the elbow. The two-headed **biceps brachii** crosses the shoulder and elbow joints to flex the forearm, also taking part in supinating the forearm at the radioulnar joints and flexing the arm at the shoulder joint. Deep to the biceps brachii, the **brachialis** provides additional power in flexing the forearm. Finally, the **brachioradialis** can flex the forearm quickly or help lift a load slowly. These muscles and their associated blood vessels and nerves form the **anterior compartment of the arm** (anterior flexor compartment of the arm) (Figure 9.6.3 and Table 9.6.3).

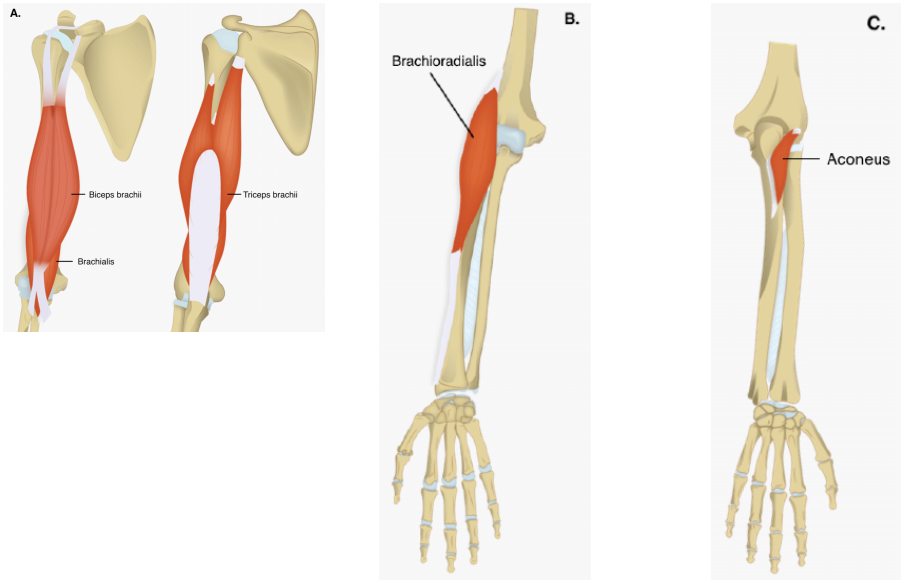

Figure 9.6.3: Muscles that Move the Forearm at the Elbow Joint. A. The prime movers of elbow flexion are in the anterior compartment - biceps brachii and brachialis. The prime mover of elbow extension is in the posterior compartment - triceps brachii. Muscles that assist in elbow movements are B. Brachioradialis and C. Aconeus. *(Image credit: "Muscles that Move the Forearm" by Jennifer Lange are licensed under CC BY-NC-SA 4.0, based on images by University of British Columbia Clinical Anatomy.)*

Table 9.6.3: Muscles that Move the Forearm at the Elbow Joint

Muscle	Origin	Insertion	Movement	Image(s)
Anterior Muscles (Flexion)				

Muscle	Origin	Insertion	Movement	Image(s)
Biceps brachii	Coracoid process; tubercle above glenoid cavity	Radial tuberosity	1. Flexion of elbow joint 2. Pronation of radioulnar joint 3. Flexion of shoulder joint	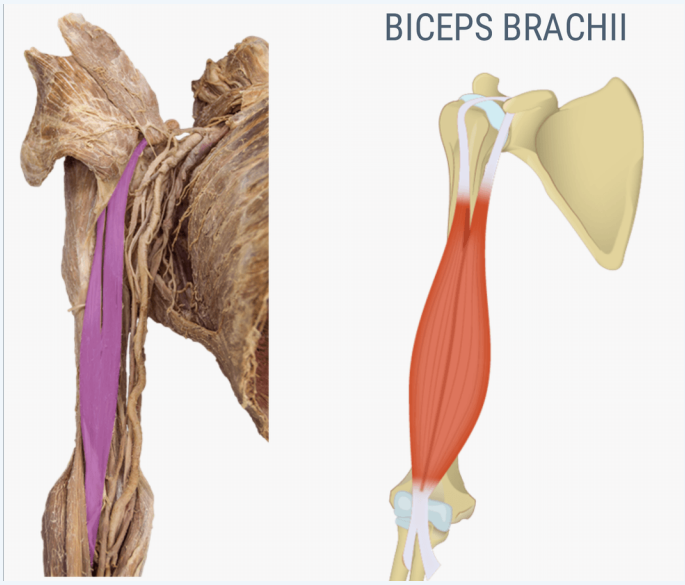
Brachialis	Front of distal humerus	Coronoid process of ulna	Elbow flexion	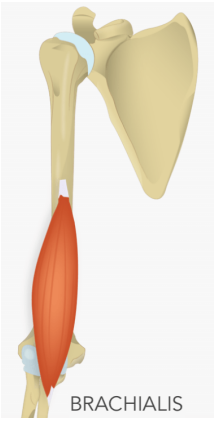
Brachioradialis	Lateral supracondylar ridge at distal end of humerus	Base of styloid process of radius	Assists in elbow flexion	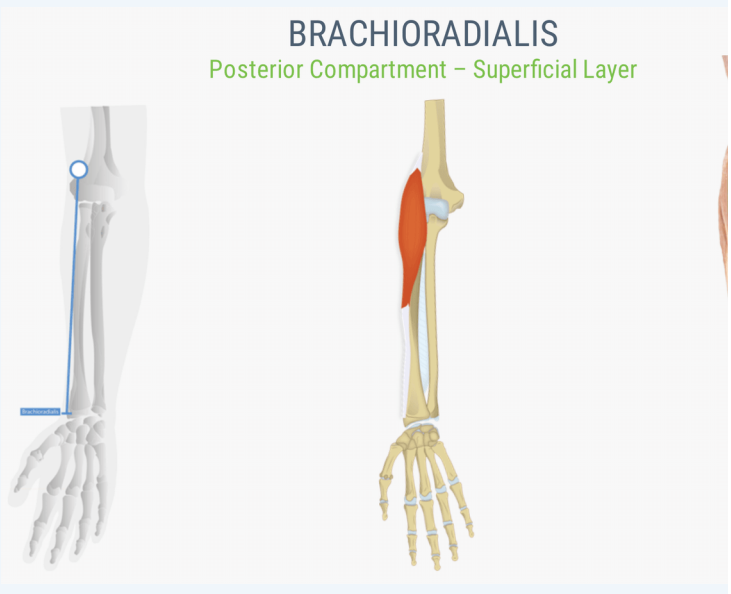
Posterior Muscles (Extension)				

Muscle	Origin	Insertion	Movement	Image(s)
Anconeus	Lateral epicondyle of humerus	Lateral aspect of olecranon process of ulna	Assists in extending elbow joint	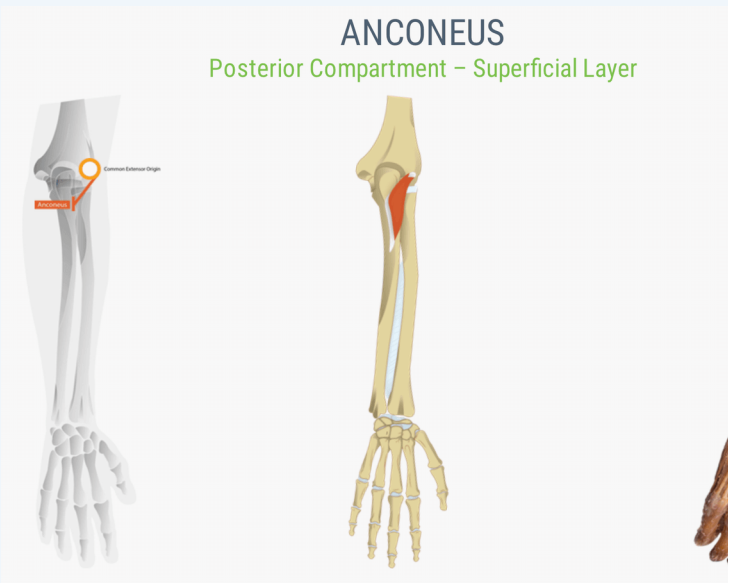
Triceps brachii	Infraglenoid tubercle of scapula; posterior shaft of humerus; posterior humeral shaft distal to the radial groove	Olecranon process of ulna	Extends elbow and shoulder	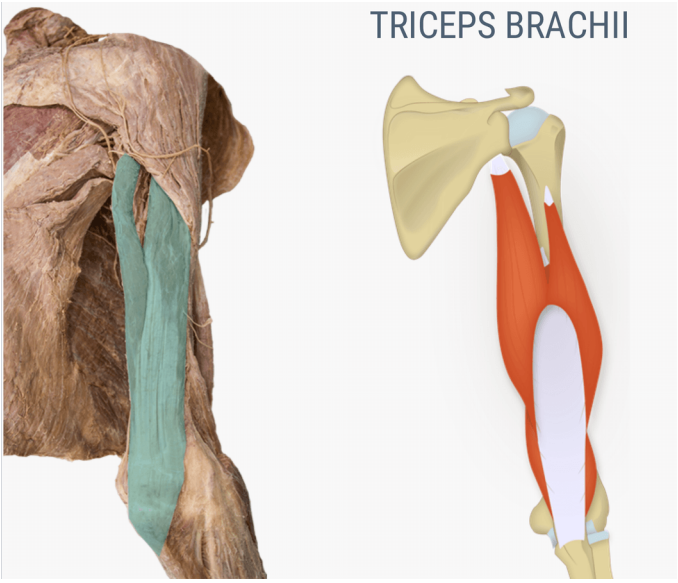

Image Credits

All images in this table are by *University of British Columbia Clinical Anatomy* and are licensed under *CC BY-NC-*

Muscles That Move the Forearm at the Radioulnar Joints

The pronators are the **pronator teres** and the **pronator quadratus**, and the **supinator** is the only one that turns the forearm anteriorly. When the forearm faces anteriorly, it is supinated. When the forearm faces posteriorly, it is pronated. (Table 9.6.4)

Table 9.6.4: Muscles that Move the Forearm at the Elbow Joint

Muscle	Origin	Insertion	Movement	Image(s)
Anterior Muscles (Pronation)				

Pronator quadratus	Distal portion of anterior ulnar shaft	Distal surface of anterior radius	Assists in turning hand palm posterior (pronation of radioulnar joint)	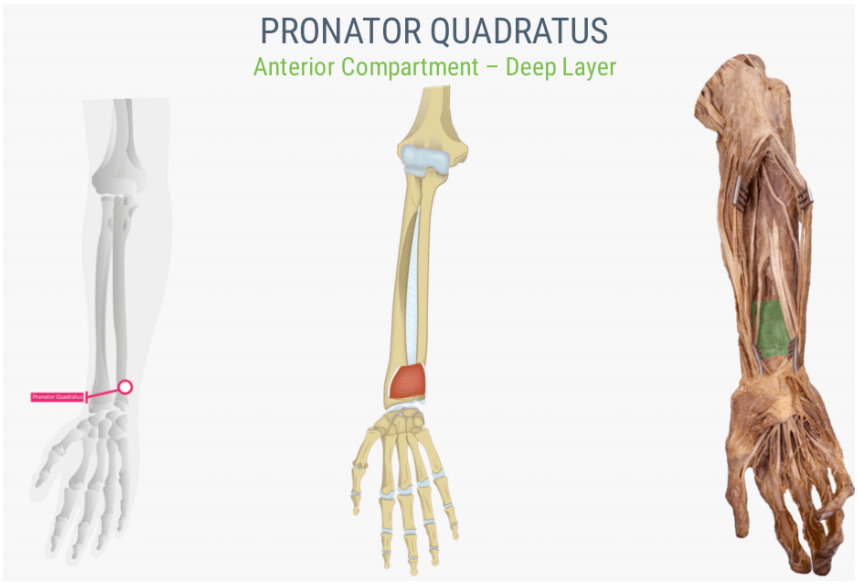
Pronator teres	Medial epicondyle of humerus; coronoid process of ulna	Lateral radius	Turns hand palm posterior (pronation of radioulnar joint)	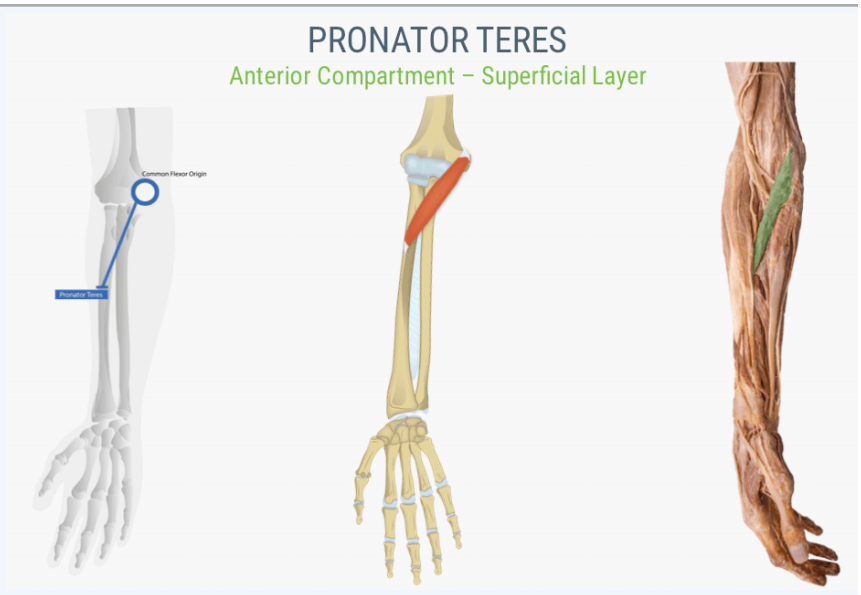
Posterior Muscles (Supination)				

Supinator	Lateral epicondyle of humerus; proximal ulna	Proximal end of radius	Turns hand palm anterior (supinator of radioulnar joint)	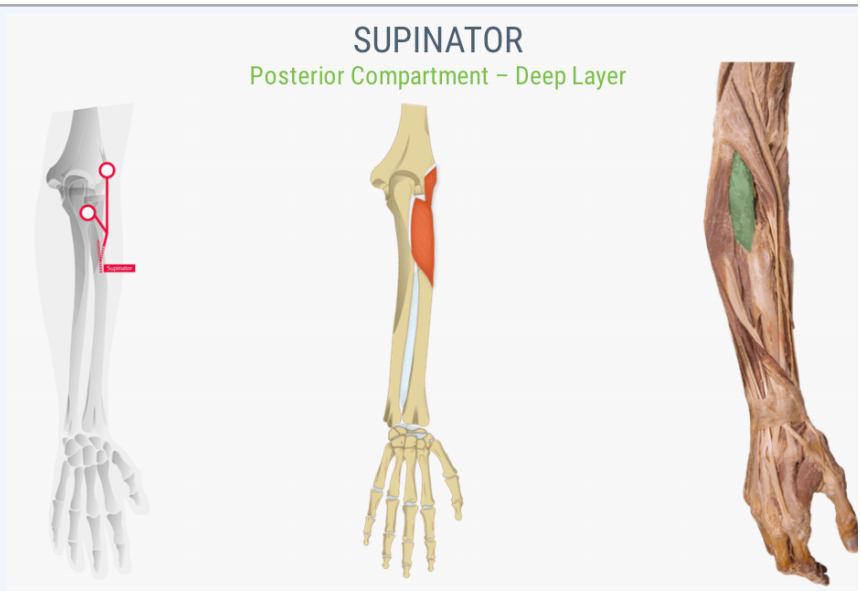

Image Credits

All images in this table are by *University of British Columbia Clinical Anatomy* and are licensed under *CC BY-NC-SA 4.0*.

Muscles That Move the Wrist, Hand, and Fingers

Wrist, hand, and finger movements are facilitated by two groups of muscles. The forearm is the origin of the **extrinsic muscles of the hand**. The palm is the origin of the intrinsic muscles of the hand.

Muscles of the Forearm That Move the Wrists, Hands, and Fingers

The muscles in the **anterior compartment of the forearm** (anterior flexor compartment of the forearm) originate on the humerus and insert onto different parts of the hand. These make up the bulk of the forearm. From lateral to medial, the **superficial anterior compartment of the forearm** includes the **flexor carpi radialis**, **palmaris longus**, **flexor carpi ulnaris**, and **flexor digitorum superficialis**. The flexor digitorum superficialis flexes the hand as well as the digits at the knuckles, which allows for rapid finger movements, as in typing or playing a musical instrument (Figure $9.6.4$ and Table $9.6.5$). However, poor ergonomics can irritate the tendons of these muscles as they slide back and forth with the carpal tunnel of the anterior wrist and pinch the median nerve, which also travels through the tunnel, causing Carpal Tunnel Syndrome. The **deep anterior compartment** produces flexion and bends fingers to make a fist. These are the **flexor pollicis longus** and the **flexor digitorum profundus**.

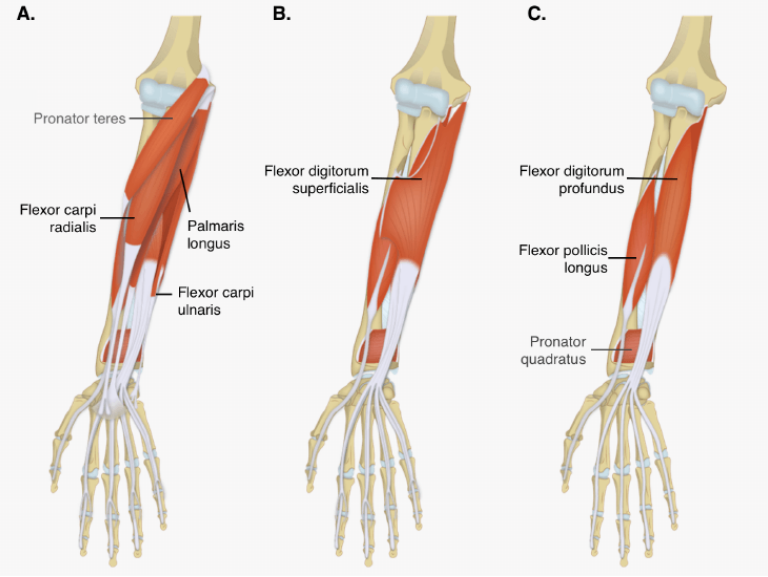

Figure 9.6.4: Anterior Muscles that Move the Joints of the Wrist, Hand, and Fingers. Muscles in the anterior compartment of the forearm all cause flexion. Some have additional actions depending upon their insertion point. A. Superficial layer (grey indicates muscle belongs in another group), B. Intermediate layer, C. Deep layer. (Image credit: "Muscles that Move the Joints of the Wrist, Hand, and Fingers" by Jennifer Lange *are licensed under CC BY-NC-SA 4.0, based on images by University of British Columbia Clinical Anatomy.*)

The muscles in the **superficial posterior compartment of the forearm** (superficial posterior extensor compartment of the forearm) originate on the humerus. These are the **extensor radialis longus**, **extensor carpi radialis brevis**, **extensor digitorum**, **extensor digiti minimi**, and the **extensor carpi ulnaris**.

The muscles of the **deep posterior compartment of the forearm** (deep posterior extensor compartment of the forearm) originate on the radius and ulna. These include the **abductor pollicis longus**, **extensor pollicis brevis**, **extensor pollicis longus**, and **extensor indicis** (Figure 9.6.5, Table 9.6.5).

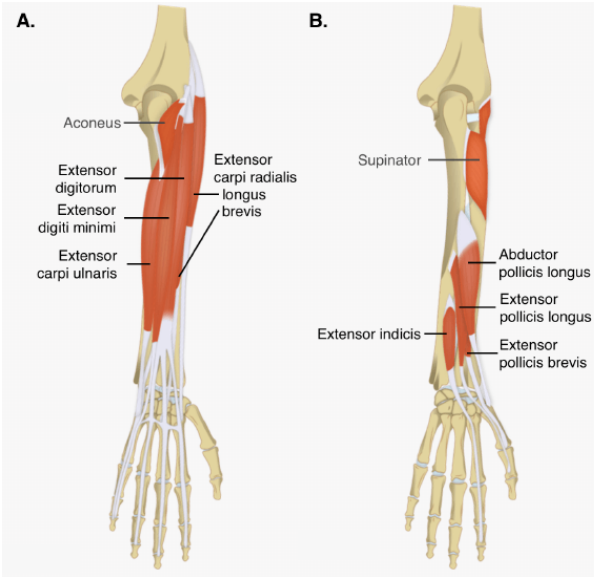

Figure 9.6.5: Posterior Muscles that Move the Joints of the Wrist, Hand, and Fingers. Most muscles in the posterior compartment of the forearm cause extension. Some have additional or other actions depending upon their insertion point. (Grey indicates muscle belongs in another group) A. Superficial layer, B. Deep layer. *(Image credit: "Posterior Muscles that Move the Joints of the Wrist, Hand, and Fingers" by Jennifer Lange are licensed under CC BY-NC-SA 4.0, based on images by University of British Columbia Clinical Anatomy.)*

Table 9.6.5: Muscles that Move the Wrist, Hands, and Forearm

Prime Mover	Origin	Insertion	Movement	Image(s)
Superficial/Intermediate Anterior Compartment of Forearm				
Flexor carpi ulnaris	Medial epicondyle of humerus; olecranon process; posterior surface of ulna	Pisiform bone; hamate bone; base of fifth metacarpal	Assists in bending hand up toward shoulder; tilts hand to side away from body; stabilizes wrist	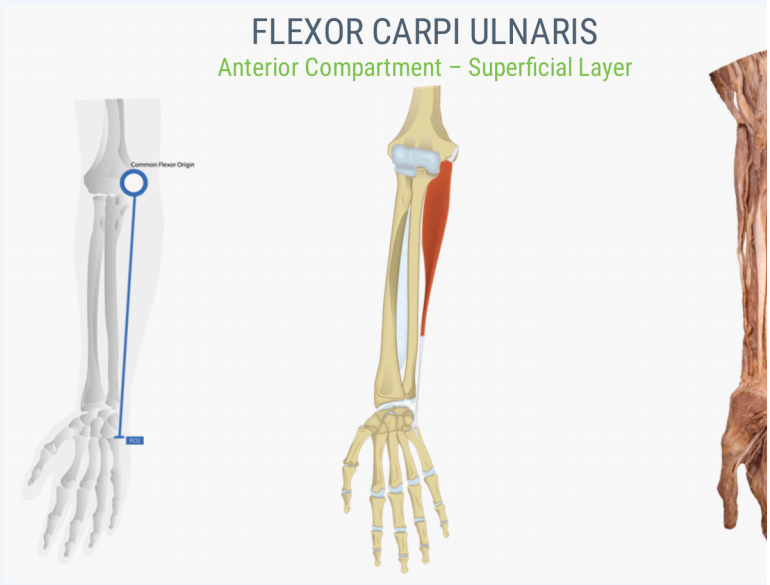
Flexor carpi radialis	Medial epicondyle of humerus	Base of second and third metacarpals	Bends wrist toward body; tilts hand to side away from body	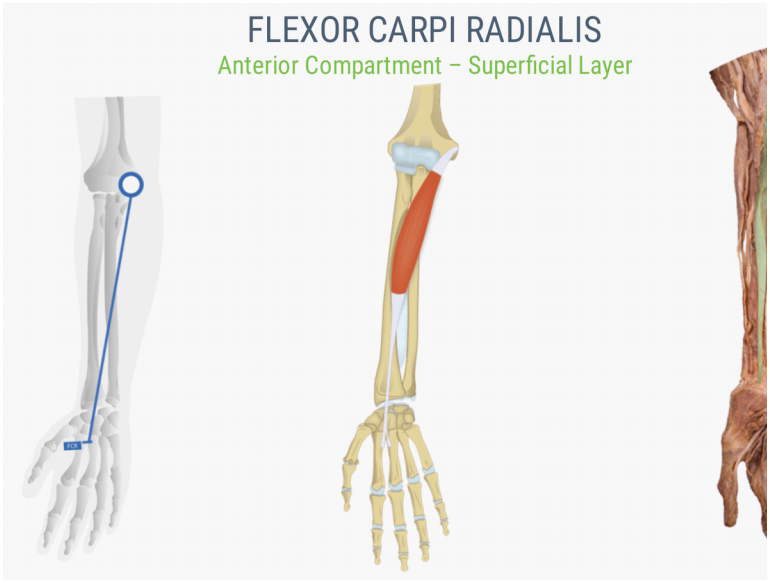

Prime Mover	Origin	Insertion	Movement	Image(s)
Flexor digitorum superficialis	Medial epicondyle of humerus; coronoid process of ulna; shaft of radius	Middle phalanges of fingers 2 - 5	Bends fingers to make fist	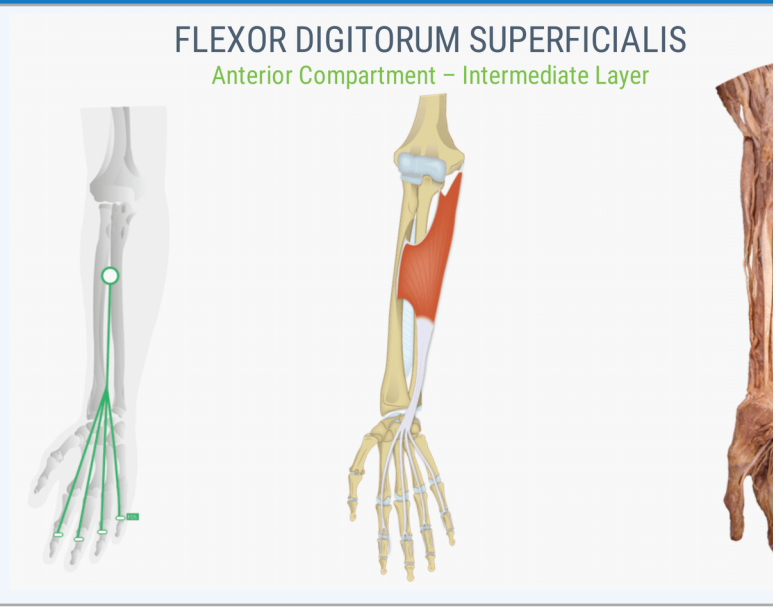
Palmaris longus	Medical epicondyle of humerus	Palmar aponeurosis; skin and fascia of palm	Assists in bending hand up toward shoulder	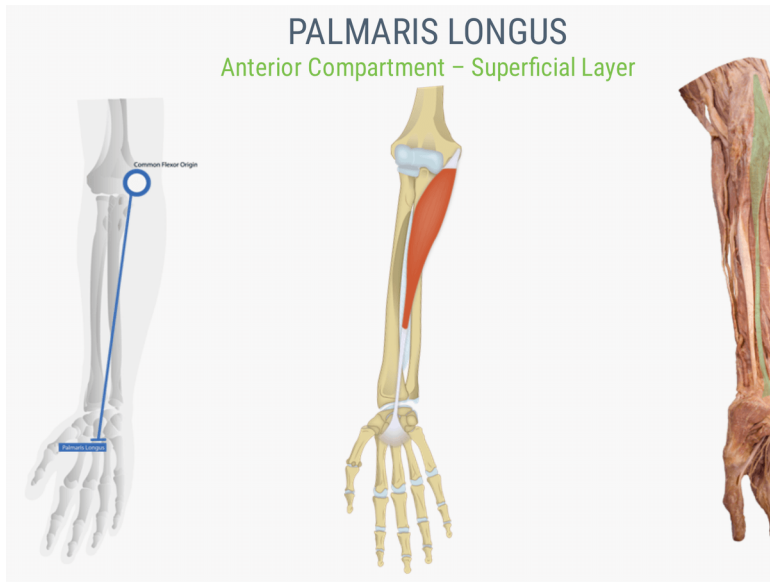
Deep Anterior Compartment of Forearm				

Prime Mover	Origin	Insertion	Movement	Image(s)
Flexor digitorum profundus	Coronoid process; anteromedial surface of ulna; interosseous membrane	Distal phalanges of fingers 2 - 5	Bends fingers to make a fist; also bends wrist toward body	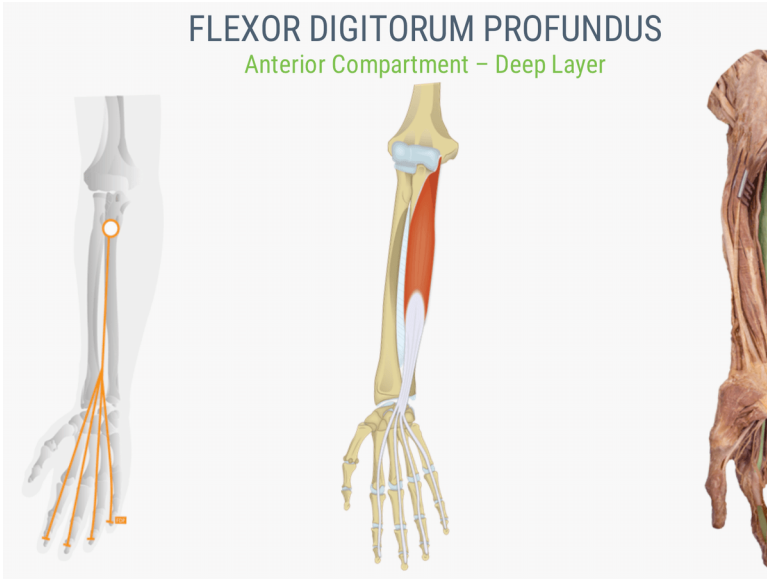
Flexor pollicus longus	Anterior surface of radius; interosseous membrane	Distal phalanx of thumb	Bends tip of thumb	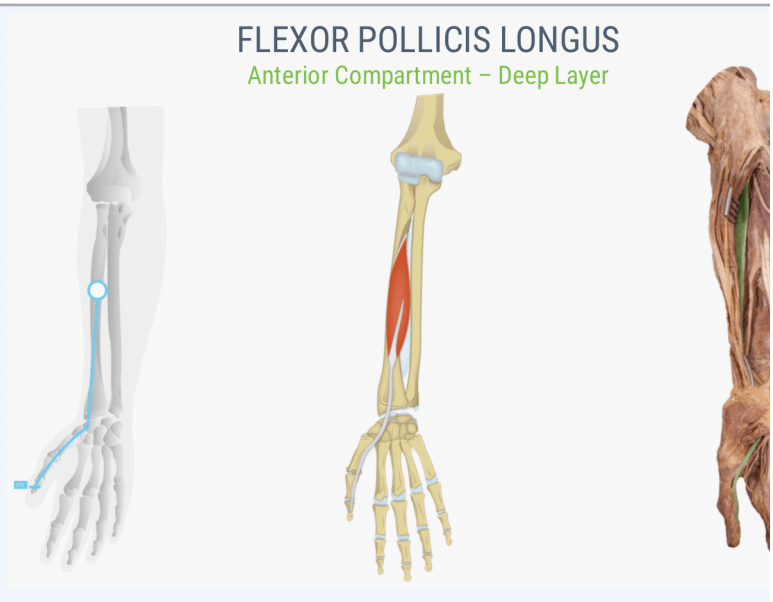
Superficial Posterior Compartment of Forearm				

Prime Mover	Origin	Insertion	Movement	Image(s)
Extensor carpi radialis brevis	Lateral epicondyle of humerus	Base of third metacarpal	Assists extensor radialis longus in extending and abducting wrist; also stabilizes hand during finger flexion	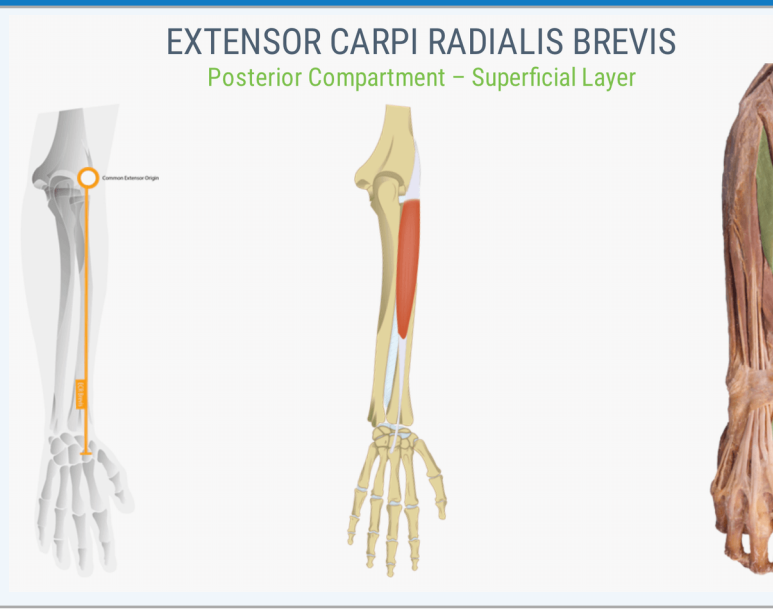
Extensor carpi ulnaris	Lateral epicondyle of humerus; posterior border of ulna	Base of fifth metacarpal	Straightens wrist away from body; tilts hand to side toward body	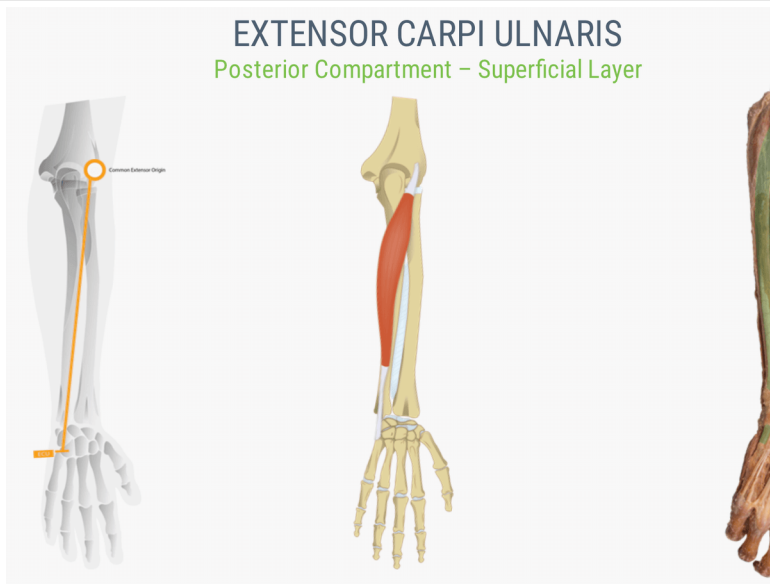

Prime Mover	Origin	Insertion	Movement	Image(s)
Extensor digiti minimi	Lateral epicondyle of humerus	Extensor expansion; distal phalanx of finger 5 (little finger)	Extends finger 5 (little finger)	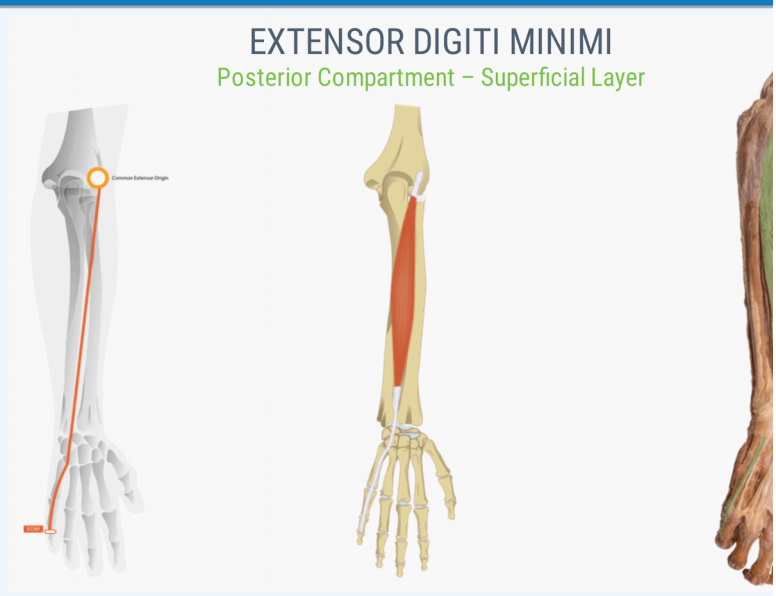
Extensor digitorum	Lateral epicondyle of humerus	Extensor expansions; distal phalanges of fingers	Opens fingers and moves them sideways away from the body	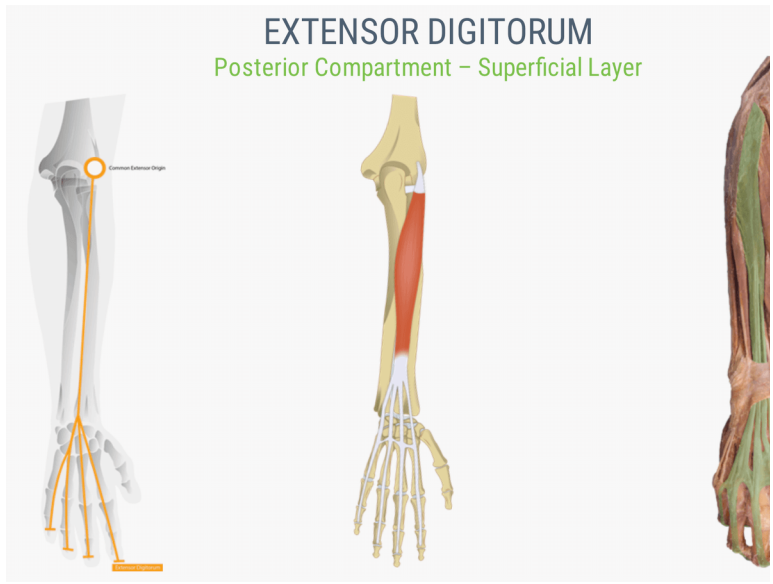

Prime Mover	Origin	Insertion	Movement	Image(s)
Extensor radialis longus	Lateral supracondylar ridge of humerus	Base of second metacarpal	Straightens wrist away from body	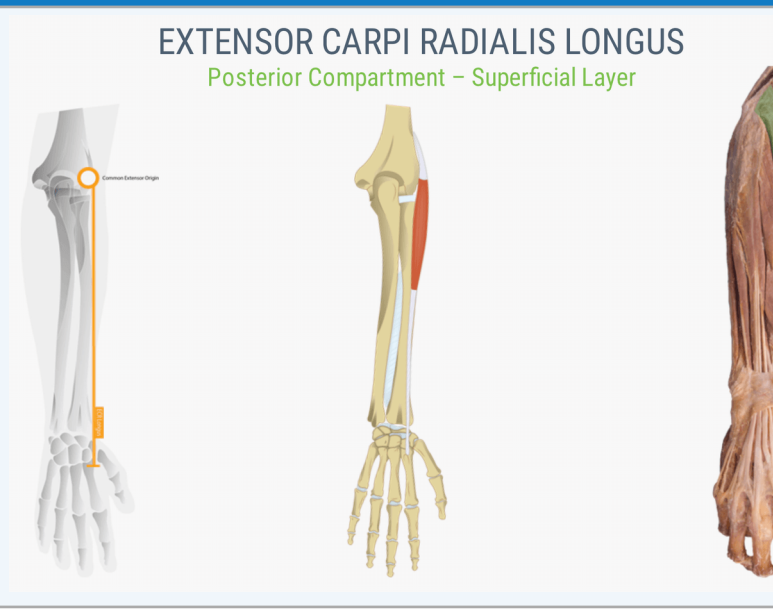
Deep Posterior Compartment of Forearm				
Abductor pollicis longus	Posterior surface of radius and ulna; interosseous membrane	Base of first metacarpal; trapezium	Moves thumb sideways toward body; extends thumb; moves hand sideways toward body	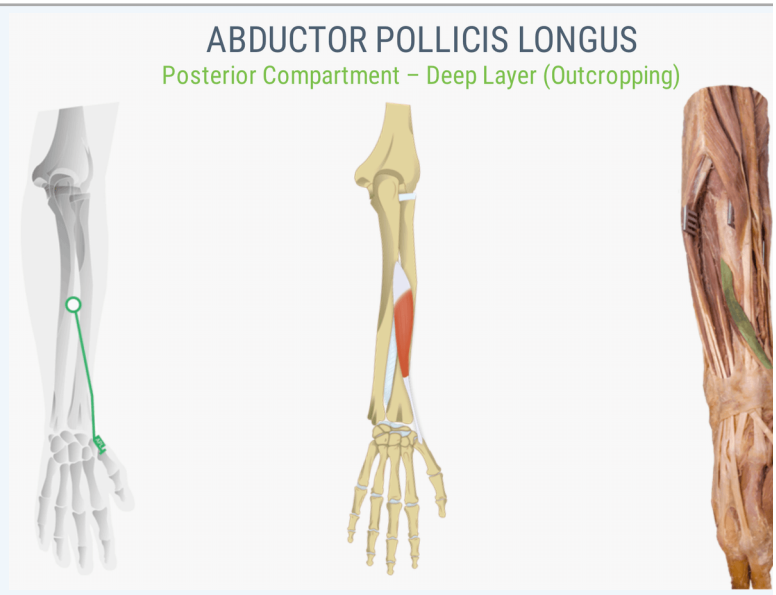

Prime Mover	Origin	Insertion	Movement	Image(s)
Extensor indicis	Posterior surface of distal ulna; interosseous membrane	Tendon of extensor digitorum of finger 2 (index finger)	Extends finger 2 (index finger); straightens wrist away from body	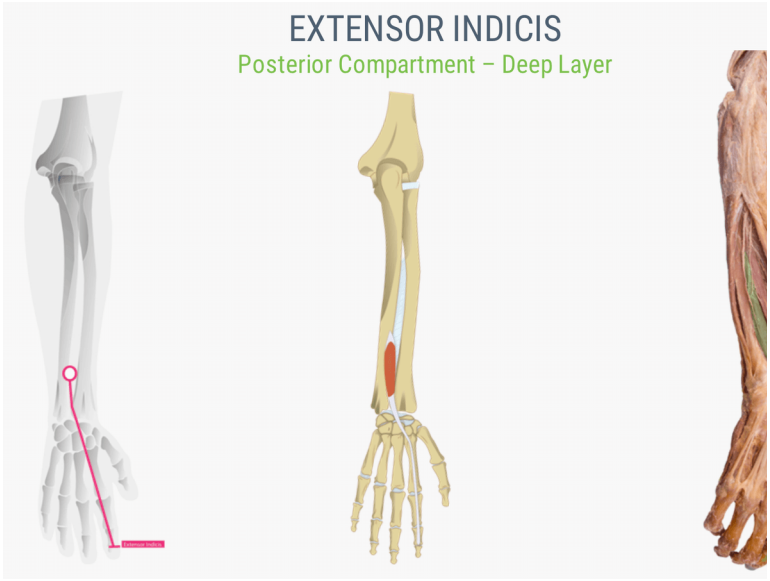
Extensor pollicis brevis	Dorsal shaft of radius and ulna; interosseous membrane	Base of proximal phalanx of thumb	Extends thumb	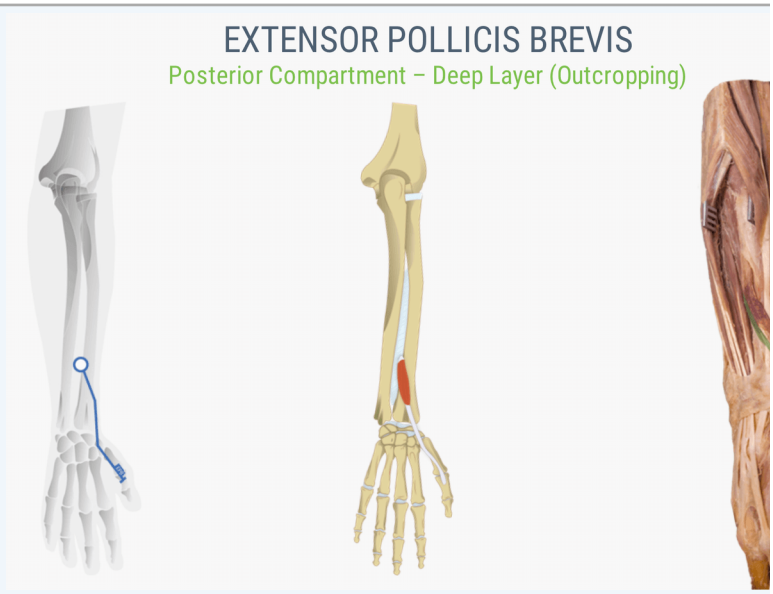

Prime Mover	Origin	Insertion	Movement	Image(s)
Extensor pollicis longus	Dorsal shaft of radius and ulna; interosseous membrane	Base of distal phalanx of thumb	Extends thumb	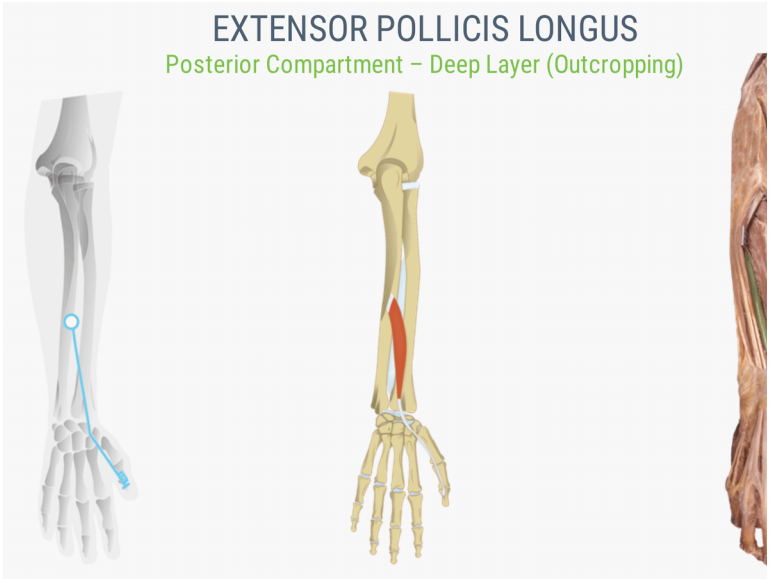

Image Credits

All images in this table are by *University of British Columbia Clinical Anatomy* and are licensed under *CC BY-NC-*

The tendons of the forearm muscles attach to the wrist and extend into the hand. Fibrous bands called **retinacula** sheath the tendons at the wrist. The **flexor retinaculum** extends over the palmar surface of the hand while the **extensor retinaculum** extends over the dorsal surface of the hand.

Intrinsic Muscles of the Hand

The **intrinsic muscles of the hand** both originate and insert within it (Figure 9.6.6, Table 9.6.6). These muscles allow your fingers to also make precise movements for actions, such as typing or writing. These muscles are divided into three groups. The **thenar** muscles are on the radial aspect of the palm. The **hypothenar** muscles are on the medial aspect of the palm, and the **intermediate** muscles are midpalmar.

The thenar muscles include the **abductor pollicis brevis**, **opponens pollicis**, **flexor pollicis brevis**, and the **adductor pollicis**. These muscles form the **thenar eminence**, the rounded contour of the base of the thumb, and all act on the thumb. The movements of the thumb play an integral role in most precise movements of the hand.

The hypothenar muscles include the **abductor digiti minimi**, **flexor digiti minimi brevis**, and the **opponens digiti minimi**. These muscles form the **hypothenar eminence**, the rounded contour of the little finger, and as such, they all act on the little finger. Finally, the intermediate muscles act on all the fingers and include the **lumbrical**, the **palmar interossei**, and the **dorsal interossei**.

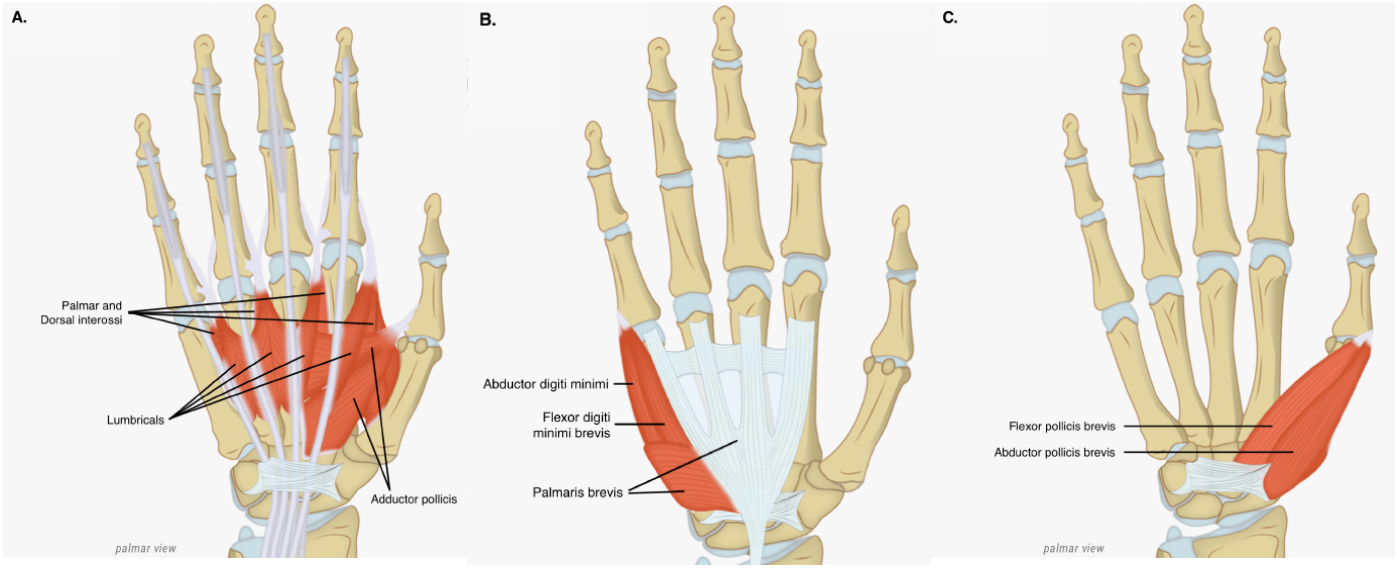

Figure 9.6.6: Intrinsic Muscles of the Hand. These muscles allow for fine motor control of the digits for activities such as writing and typing. A. Palmar view of the deep muscles. B. Palmar view of the hypothenar muscles. C. Palmar view of the thenar muscles. *(Image credit: "Intrinsic Muscles of the Hand" by Jennifer Lange are licensed under CC BY-NC-SA 4.0, based on images by University of British Columbia Clinical Anatomy.)*

Table 9.6.6: Intrinsic Muscles of the Hand

Muscle	Origin	Insertion	Movement	Image(s)
Thenar Muscles (movements video)				

Muscle	Origin	Insertion	Movement	Image(s)
Abductor pollicis brevis	Flexor retinaculum; and nearby carpals	Lateral base of proximal phalanx of thumb	Abducts and flexes thumb	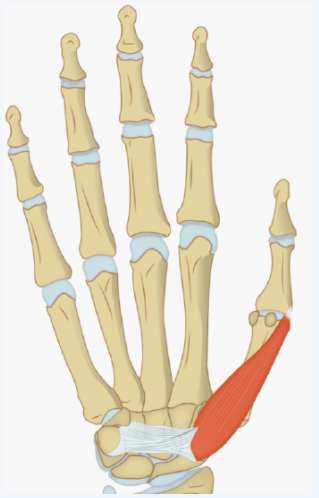
Adductor pollicis	Capitate bone; bases of metacarpals 2 - 4; front of metacarpal 3	Medial base of proximal phalanx of thumb	Adducts and flexes thumb	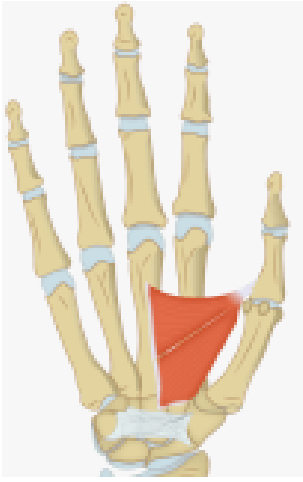

Muscle	Origin	Insertion	Movement	Image(s)
Flexor pollicis brevis	Flexor retinaculum; trapezium	Lateral base of proximal phalanx of thumb	Flexes thumb	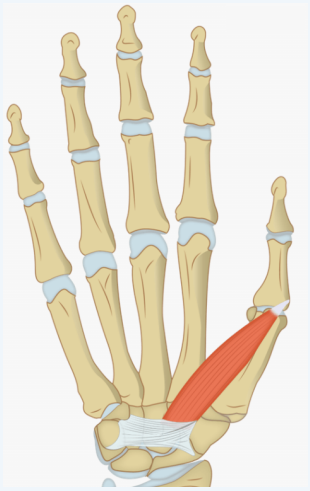
Opponens pollicis	Flexor retinaculum; trapezium	Anterior of first metacarpal	Opposes thumb (moves thumb across palm to touch other fingers)	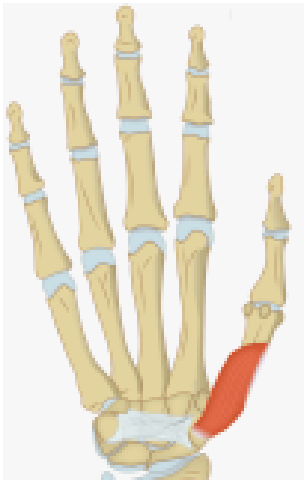
Hypothenar Muscles				

Muscle	Origin	Insertion	Movement	Image(s)
Abductor digiti minimi	Pisiform bone	Medial side of proximal phalanx of finger 5 (little finger)	Abducts and flexes MCP of 5th digit	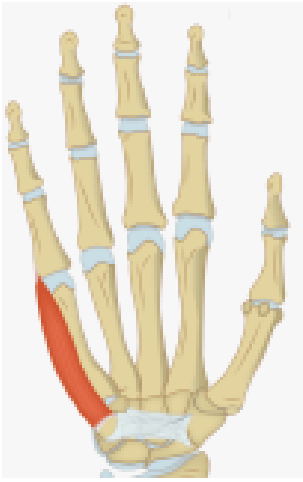
Flexor digiti minimi brevis	Hamate bone; flexor retinaculum	Medial side of proximal phalanx of finger 5 (little finger)	Flexes MCP of 5th digit	

Muscle	Origin	Insertion	Movement	Image(s)
Opponens digiti minimi	Hamate bone; flexor retinaculum	Medial side of fifth metacarpal	Opposes digit 5 (moves little finger across palm to touch thumb)	
Deep Muscles				
Dorsal interossei	Sides of metacarpals	Both sides of finger 3; for each other finger, extensor expansion over first phalanx on side opposite finger 3	Abducts and flexes the three middle fingers at metacarpo-phalangeal joints; extends the three middle fingers at interphalangeal joints	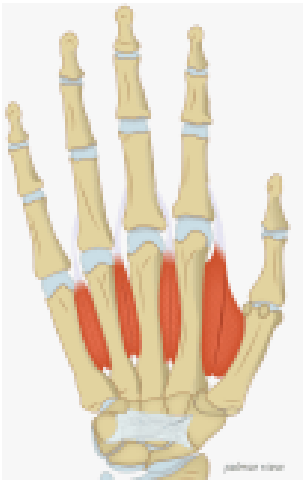
Lumbricals	Palm (lateral sides of tendons in flexor digitorum profundus)	Fingers 2–5 (lateral edges of extensional expansions on first phalanges)	Flexes each finger at metacarpo-phalangeal joints; extends each finger at interphalangeal joints	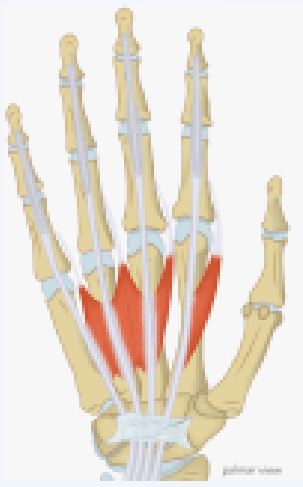

Muscle	Origin	Insertion	Movement	Image(s)
Palmar interossei	Side of each metacarpal that faces metacarpal 3 (absent from metacarpal 3)	Extensor expansion on first phalanx of each finger (except finger 3) on side facing finger 3	Adducts and flexes each finger at metacarpo-phalangeal joints; extends each finger at interphalangeal joints	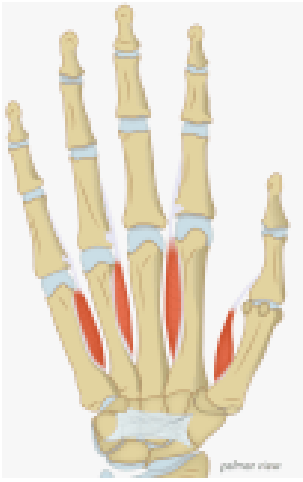

Image Credits

All images in this table are by *University of British Columbia Clinical Anatomy* *and are licensed under* *CC BY-NC-SA 4.0.*

Muscles of the upper limb

Explore the muscles of the upper limb in these 3D models.

Arm Inverse by **AnatomyPhysiologySCC** on **Sketchfab**

Body3D Interactive Model (opens in new window)

Concept Review

The clavicle and scapula make up the pectoral girdle, which provides a stable origin for the muscles that move the humerus. The muscles that position and stabilize the pectoral girdle are located on the thorax. The anterior thoracic muscles are the subclavius, pectoralis minor, and the serratus anterior. The posterior thoracic muscles are the trapezius, levator scapulae, rhomboid major,

and rhomboid minor. Nine muscles cross the shoulder joint to move the humerus. The ones that originate on the axial skeleton are the pectoralis major and the latissimus dorsi. The deltoid, subscapularis, supraspinatus, infraspinatus, teres major, teres minor, and coracobrachialis originate on the scapula.

The forearm flexors include the biceps brachii, brachialis, and brachioradialis. The extensors are the triceps brachii and anconeus. The pronators are the pronator teres and the pronator quadratus. The supinator is the only one that turns the forearm anteriorly.

The extrinsic muscles of the hands originate along the forearm and insert into the hand in order to facilitate crude movements of the wrists, hands, and fingers. The superficial anterior compartment of the forearm produces flexion. These muscles are the flexor carpi radialis, palmaris longus, flexor carpi ulnaris, and the flexor digitorum superficialis. The deep anterior compartment produces flexion as well. These are the flexor pollicis longus and the flexor digitorum profundus. The rest of the compartments produce extension. The extensor carpi radialis longus, extensor carpi radialis brevis, extensor digitorum, extensor digiti minimi, and extensor carpi ulnaris are the muscles found in the superficial posterior compartment. The deep posterior compartment includes the abductor longus, extensor pollicis brevis, extensor pollicis longus, and the extensor indicis.

Finally, the intrinsic muscles of the hands allow our fingers to make precise movements, such as typing and writing. They both originate and insert within the hand. The thenar muscles, which are located on the lateral part of the palm, are the abductor pollicis brevis, opponens pollicis, flexor pollicis brevis, and adductor pollicis. The hypothenar muscles, which are located on the medial part of the palm, are the abductor digiti minimi, flexor digiti minimi brevis, and opponens digiti minimi. The intermediate muscles, located in the middle of the palm, are the lumbricals, palmar interossei, and dorsal interossei.

Review Questions

Query 9.6.1

This interactive element is not available in this format. Visit the link or scan the QR code to access it online.

View this Interactive Content online

Critical Thinking Questions

Query 9.6.2

This interactive element is not available in this format. Visit the link or scan the QR code to access it online.

View this Interactive Content online

Query 9.6.3

This interactive element is not available in this format. Visit the link or scan the QR code to access it online.

View this Interactive Content online

Glossary

Query 9.6.4

This interactive element is not available in this format. Visit the link or scan the QR code to access it online.

View this Interactive Content online

Contributors and Attributions

- OpenStax Anatomy & Physiology (CC BY 4.0). Access for free at https://openstax.org/books/anatomy-and-physiology

This page titled 9.6: Appendicular Muscles of the Pectoral Girdle and Upper Limbs is shared under a CC BY-NC-SA 4.0 license and was authored, remixed, and/or curated by Jennifer Lange et al..

- 10.6: Appendicular Muscles of the Pectoral Girdle and Upper Limbs by Whitney Menefee, Julie Jenks, Chiara Mazzasette, and Kim-Leiloni Nguyen is licensed CC BY 4.0.

9.7: Appendicular Muscles of the Pelvic Girdle and Lower Limbs

By the end of this section, you will be able to:

- Identify the major appendicular muscles of the pelvic girdle and lower limb
- Identify the movement caused by these muscles

The appendicular muscles of the lower body position and stabilize the **pelvic girdle**, which serves as a foundation for the lower limbs. Comparatively, there is much more movement at the pectoral girdle than at the pelvic girdle. There is very little movement of the pelvic girdle because of its connection with the sacrum at the base of the axial skeleton. The pelvic girdle is less range of motion because it was designed to stabilize and support the body.

Muscles of the Thigh

What would happen if the pelvic girdle, which attaches the lower limbs to the torso, were capable of the same range of motion as the pectoral girdle? For one thing, walking would expend more energy if the heads of the femurs were not secured in the acetabula of the pelvis. The body's center of gravity is in the area of the pelvis. If the center of gravity were not to remain fixed, standing up would be difficult as well. Therefore, what the leg muscles lack in range of motion and versatility, they make up for in size and power, facilitating the body's stabilization, posture, and movement.

Gluteal and Pelvic Muscles That Move the Femur

Most muscles that insert on the femur (the thigh bone) and move it, originate on the pelvic girdle (Table 9.7.1).

- The **psoas major** (the "p" is silent when pronouncing) and **iliacus** make up the **iliopsoas group**. These muscles originate on the posterior, interior of the pelvis and the vertebral column, pass over the pubis and insert into lesser trochanter of the femur. When they pass the inguinal ligament their fibers blend together so in the thigh the joined muscle is called the **iliopsoas**. Their anterior position relative to the hip joint makes them strong hip flexors (Figure 9.7.1).
- Some of the largest and most powerful muscles in the body are the gluteal muscles or **gluteal group**. From superficial to deep as well as largest to smallest these three muscles are the **gluteus maximus, gluteus medius**, and **gluteus minimus**. Gluteus maximus is the prime mover of hip extension as well as a lateral rotator. The gluteus medius and minimus both abduct and medially rotate the hip (Figure 9.7.1). The gluteus maximus has two insertion points: one in the posterior femur and one on the superior, lateral tibia via that **iliotibial (IT) band**.

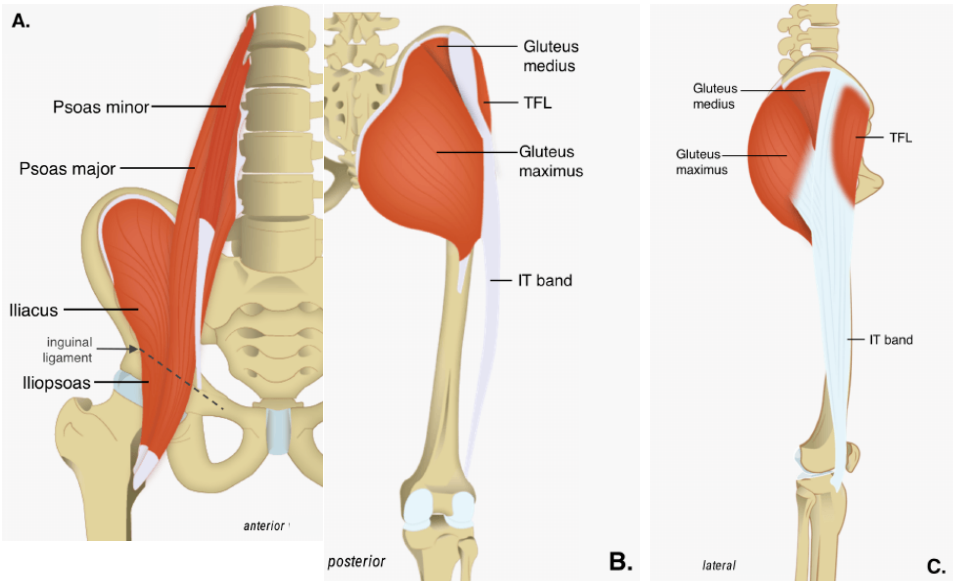

Figure 9.7.1: Muscles - Iliopsoas and Gluteal Groups. The primary of action of these muscles is hip flexion (A. iliopsoas group) and hip extension, abduction, and rotation (B. gluteal group). *(Image credits: "Iliopsoas and Gluteal Group Muscles" by Jennifer Lange are licensed under CC BY-NC-SA 4.0, based on images by University of British Columbia Clinical Anatomy)*

- Also in the gluteal compartment, the **tensor fasciae latae** (TFL) is a thick, squarish muscle in the superior aspect of the lateral thigh. It acts as a synergist of the gluteus medius in abducting the thigh. It also helps stabilize the lateral aspect of the knee by pulling on the iliotibial tract (band), making it taut (Figure 9.7.1).
- Deep to the gluteal muscles, the **piriformis**, **superior gemellus**, **obturator externus**, **inferior gemellus**, **obturator internus**, and **quadratus femoris** laterally rotate the femur at the hip (Figure 9.7.2).

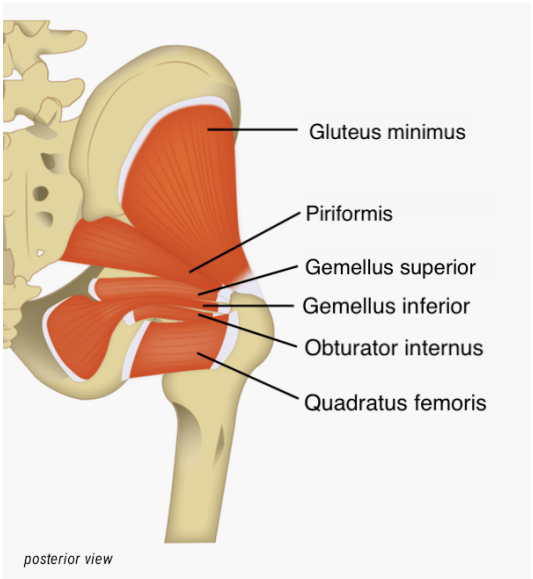

Figure 9.7.2: Muscles - Deep Gluteal Group. These small muscles stabilize the hip and help rotate it laterally. From superior to inferior they go in the the order of PG GO Q. *(Image credits: "Deep Gluteal Group Muscles" by Jennifer Lange are licensed under CC BY-NC-SA 4.0, based on images by University of British Columbia Clinical Anatomy)*

Muscles of the Medial Compartment

Six muscles are located in the medial compartment of the thigh (Figure 9.7.3). Most of these muscles perform adduction at the hip joint, and each performs other actions as well. The **adductor longus**, **adductor brevis**, **gracilis,** and **pectineus** also flex the hip joint. **Adductor magnus**, depending on which fibers are activated, can flex, extend, and laterally rotate the thigh. Gracilis is the only one of this groups of muscles that does not insert into the femur, it inserts into the posterior, medial aspect of the

superior tibia which also allows it to cause flexion at the knee joint. The only muscle in this compartment that does not adduct is the **obturator externus**, this muscle's action is to laterally rotate the hip.

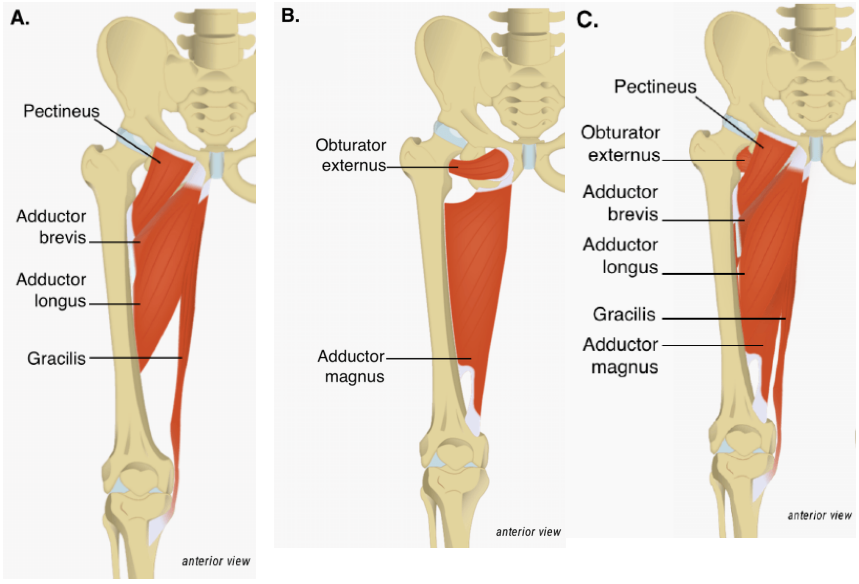

Figure 9.7.3: Muscles - Medial Thigh Compartment. All but one of the muscles in this group cause thigh adduction because they cross the hip joint on the medial side. Image A shows the more anterior muscles, image B shows the more posterior muscles, and image C shows them all. *(Image credits: "Medial Thigh Muscles" by Jennifer Lange are licensed under CC BY-NC-SA 4.0, based on images by University of British Columbia Clinical Anatomy)*

Table 9.7.1: Muscles that Move the Hip Joint

Muscle	Origin	Insertion	Movement	Image(s)
Iliopsoas group				
Iliacus	Iliac fossa; iliac crest; lateral sacrum	Lesser trochanter of femur	Flexes hip	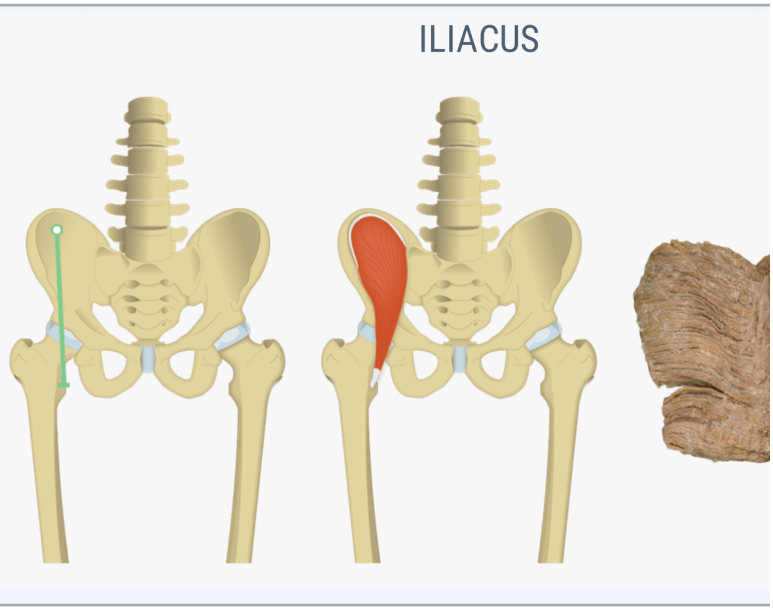

Muscle	Origin		Insertion	Movement	Image(s)
Psoas major	Lumbar vertebrae (L_1 - L_5); thoracic vertebrae (T_{12})		Lesser trochanter of femur	Flexes hip	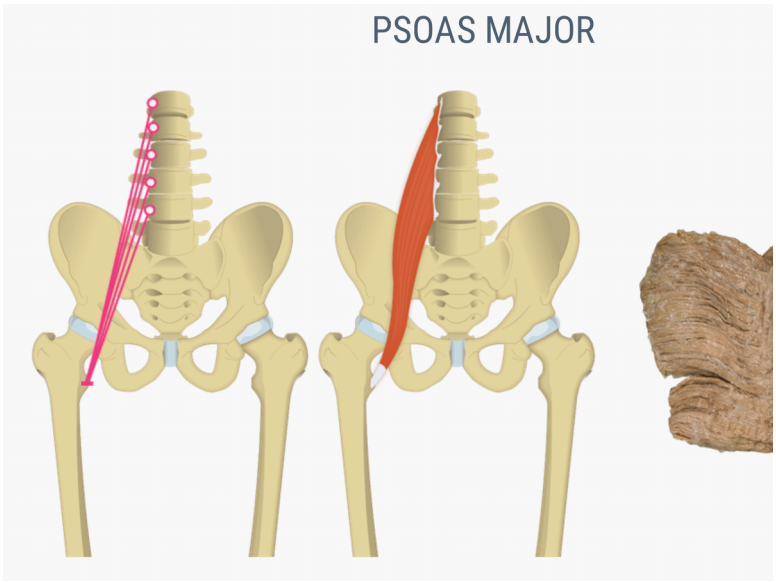
Gluteal Group					
Gluteus maximus	Dorsal ilium; sacrum; coccyx		Gluteal tuberosity of femur; iliotibial tract	Extend and laterally rotates hip	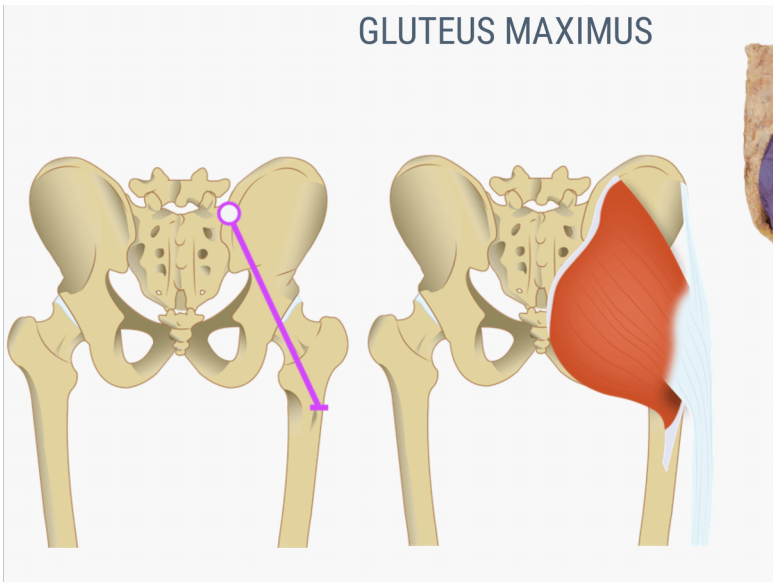

Muscle	Origin		Insertion	Movement	Image(s)
Gluteus medius	Lateral surface of ilium		Greater trochanter of femur	Abducts and medially rotates hip	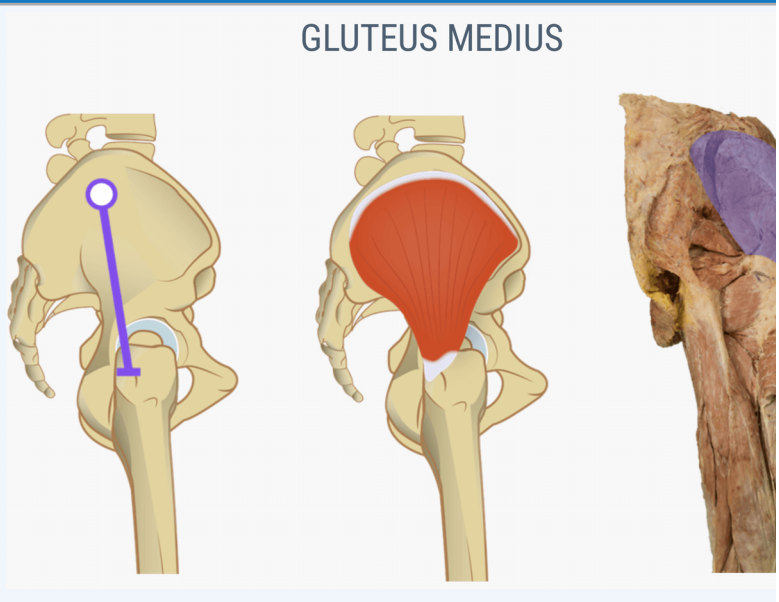
Gluteus minimus	External surface of ilium		Greater trochanter of femur	Abducts and medially rotates hip	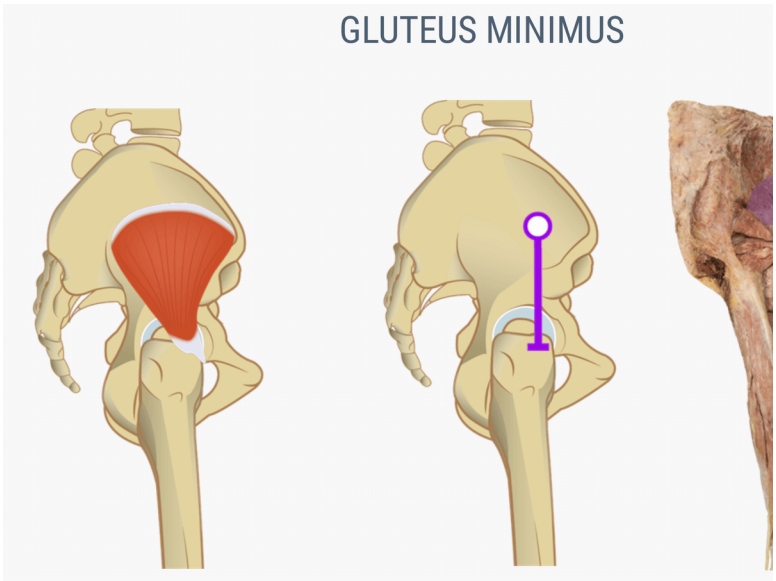

Muscle	Origin		Insertion	Movement	Image(s)
Tensor fascia lata	Anterior aspect of iliac crest; anterior superior iliac spine		Iliotibial tract	Abducts and medially rotates hip	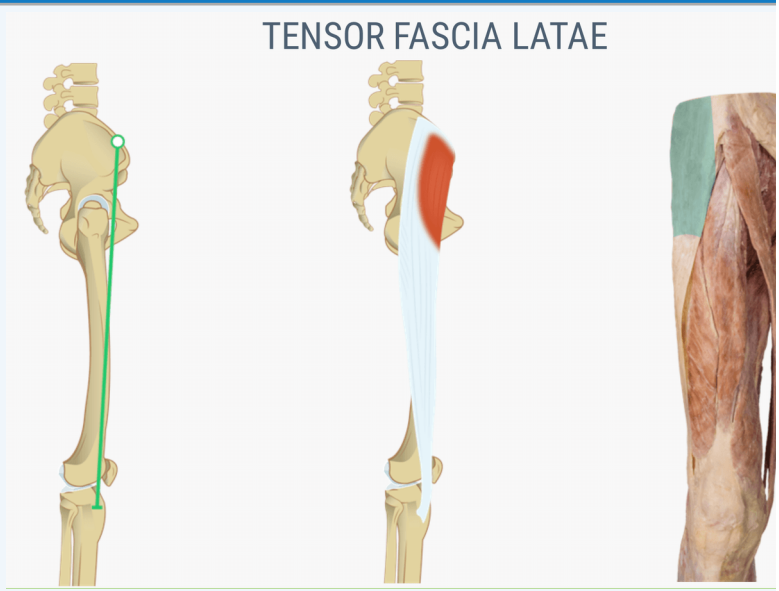
Deep Gluteal Muscles					
Inferior gemellus	Ischial tuberosity		Greater trochanter of femur	Laterally rotates hip; maintains posture by stabilizing hip joint	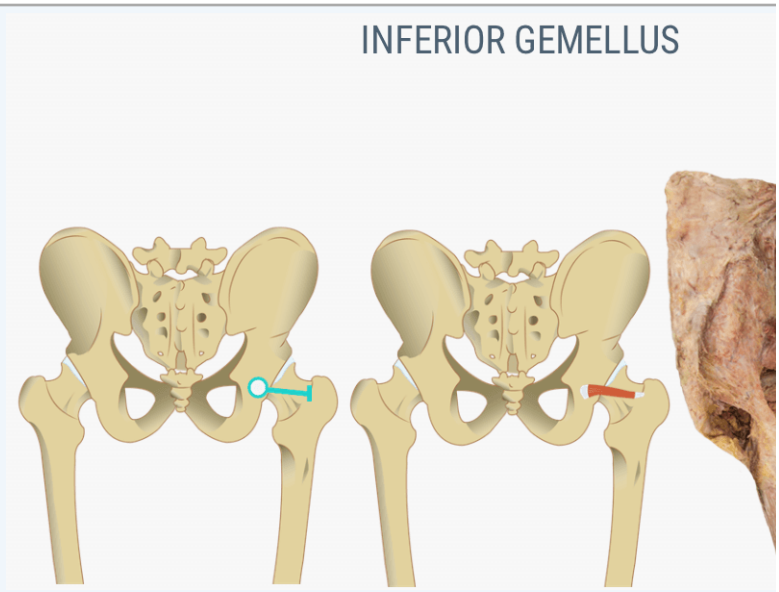

Muscle	Origin		Insertion	Movement	Image(s)
Obturator externus	Outer surfaces of obturator membrane, pubis, and ischium; margins of obturator foramen		Trochanteric fossa of posterior femur	Laterally rotates hip; maintains posture by stabilizing hip joint	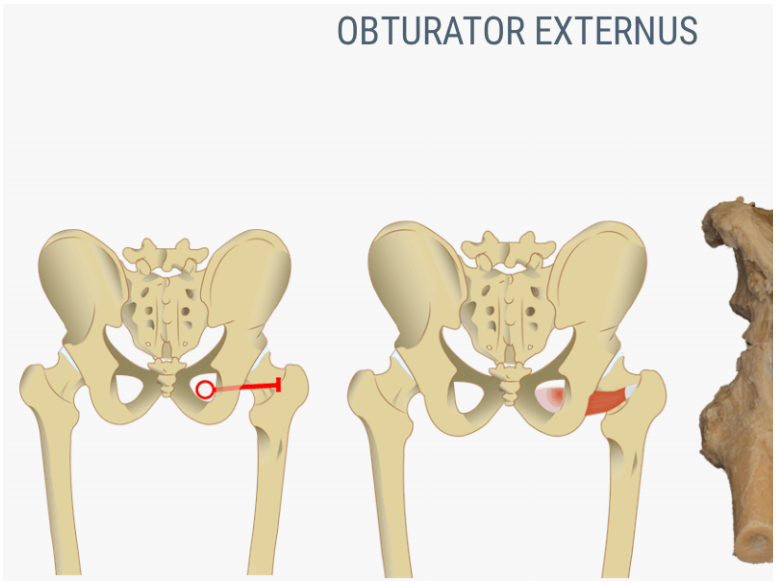
Obturator internus	Inner surface of obturator membrane; greater sciatic notch; margins of obturator foramen		Greater trochanter in front of piriformis	Laterally rotates hip; maintains posture by stabilizing hip joint	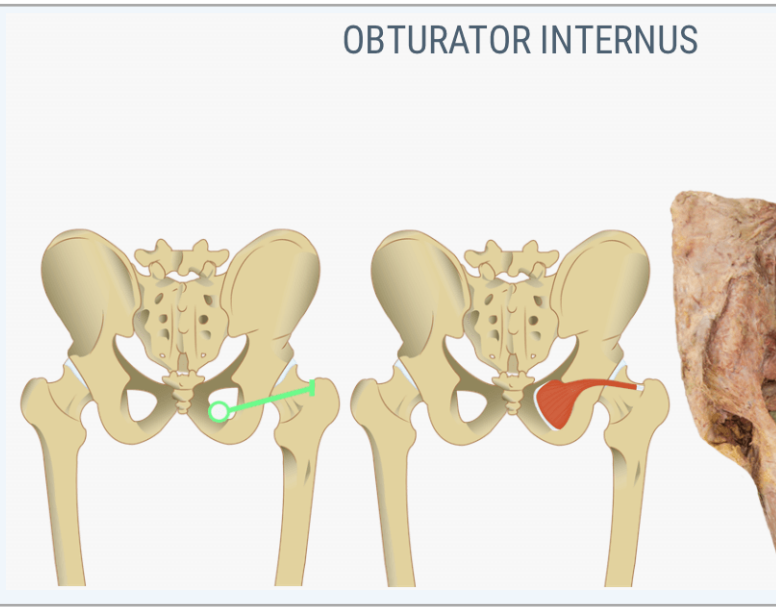

Muscle	Origin	Insertion	Movement	Image(s)
Piriformis	Anterolateral surface of sacrum	Greater trochanter of femur	Laterally rotates hip; maintains posture by stabilizing hip joint	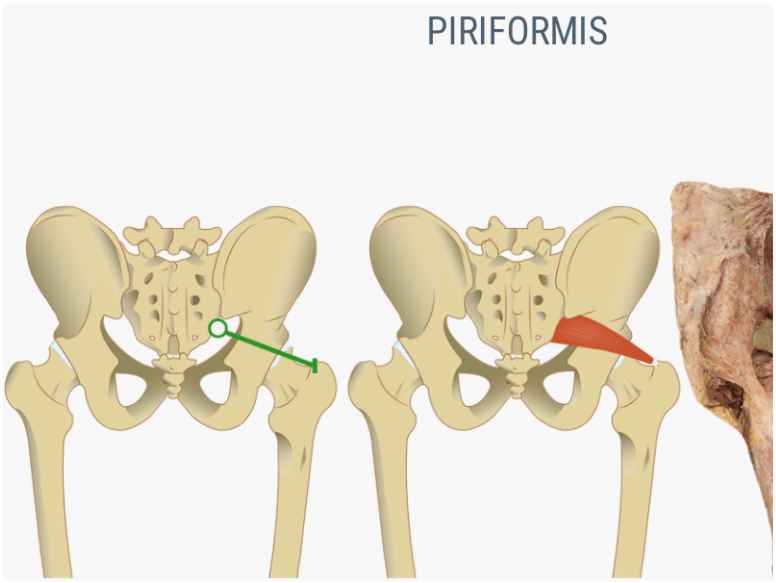
Quadratus femoris	Ischial tuberosity	Trochanteric crest of femur	Laterally rotates hip; maintains posture by stabilizing hip joint	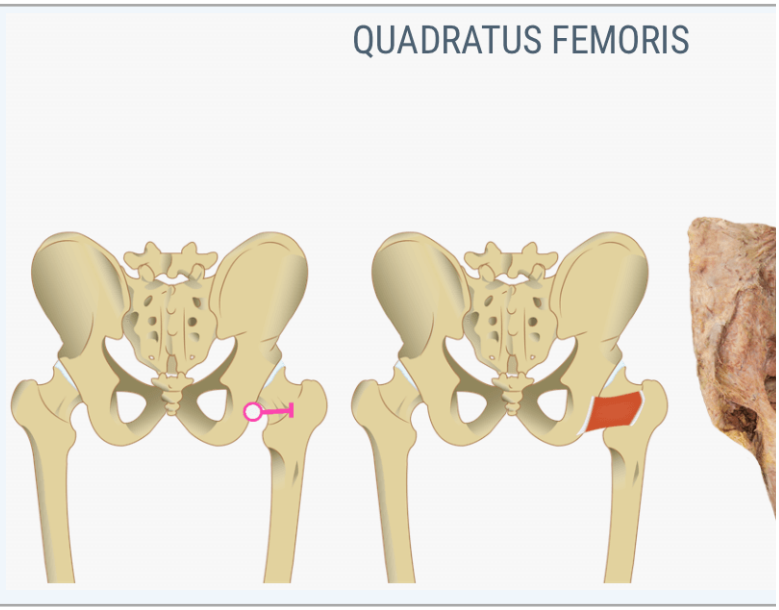

Muscle	Origin		Insertion	Movement	Image(s)
Superior gemellus	Ischial spine		Greater trochanter of femur	Laterally rotates hip; maintains posture by stabilizing hip joint	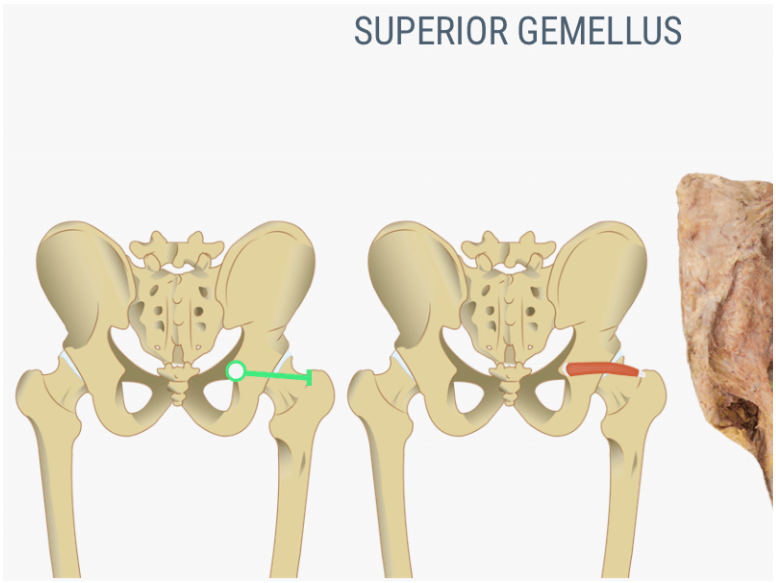
Medial Muscles					
Adductor brevis	Body of pubis; inferior ramus of pubis		Linea aspera above adductor longus	Adducts and flexes hip	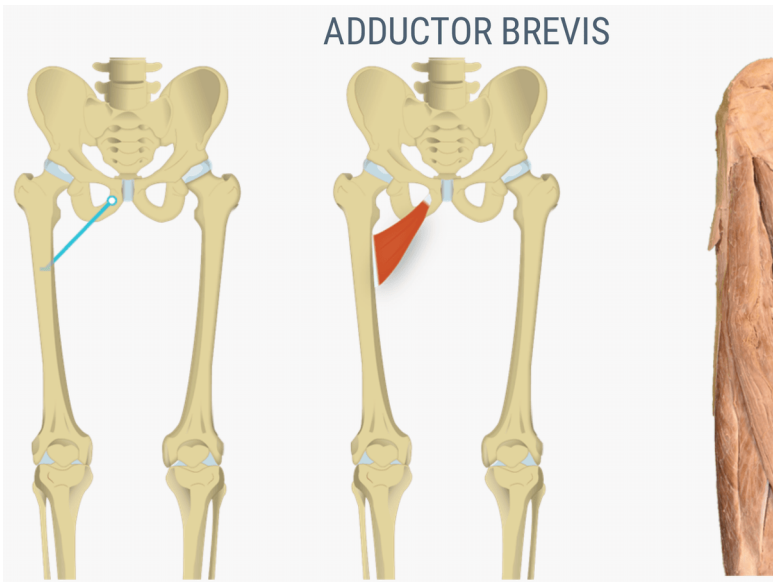

Muscle	Origin		Insertion	Movement	Image(s)
Adductor longus	Pubis near pubic symphysis		Linea aspera	Adducts and flexes hip	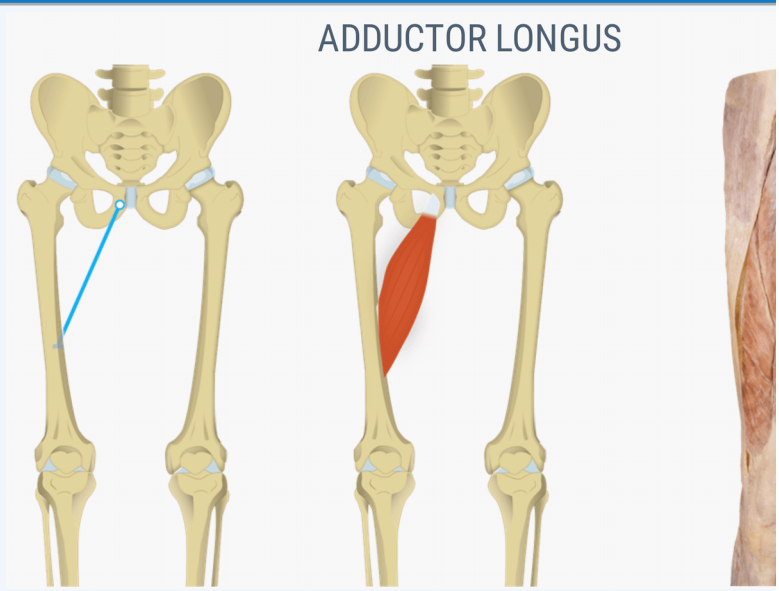
Adductor magnus	Ischial rami; pubic rami; ischial tuberosity		Linea aspera; adductor tubercle of femur	Adducts hip Posterior fibers: extends and laterally rotates hip Anterior fibers: flex hip	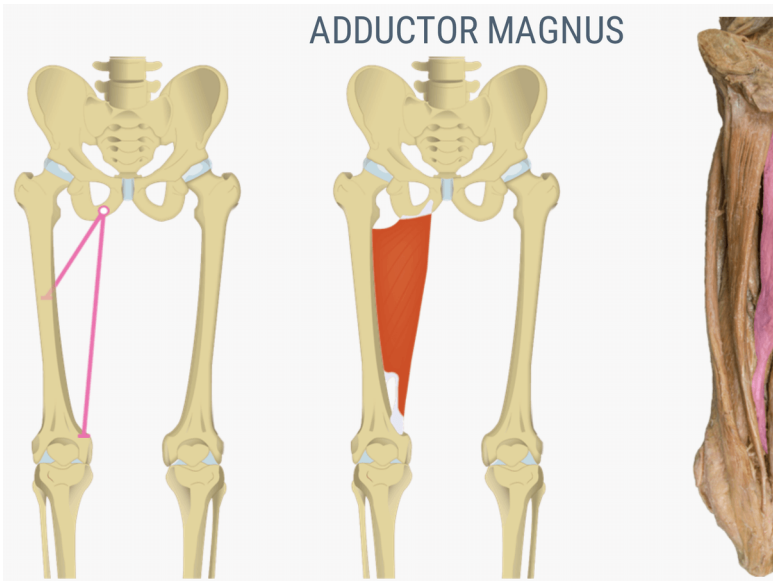

Muscle	Origin	Insertion	Movement	Image(s)
Gracilis	Inferior ramus; body of pubis; ischial ramus	Medial surface of tibia	Adducts and flexes hip; flexes knee	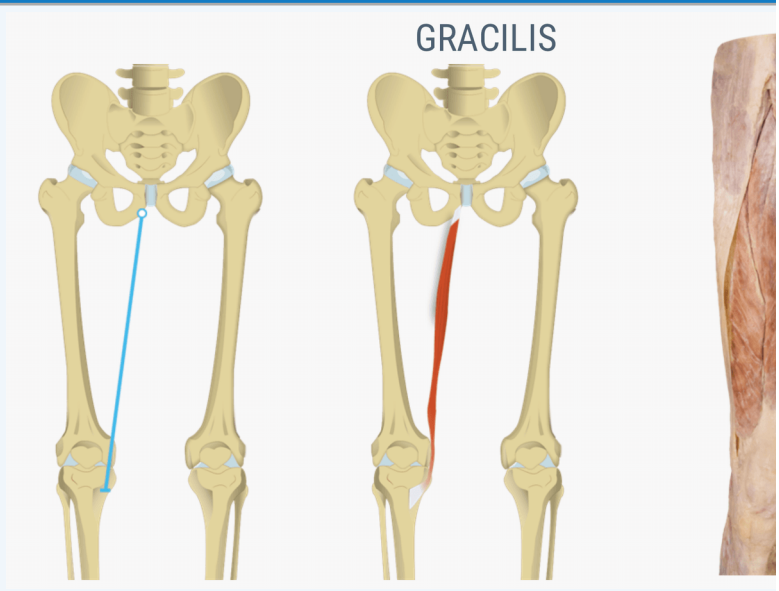
Pectineus	Pectineal line of pubis	Lesser trochanter to linea aspera of posterior aspect of femur	Adducts and flexes hip	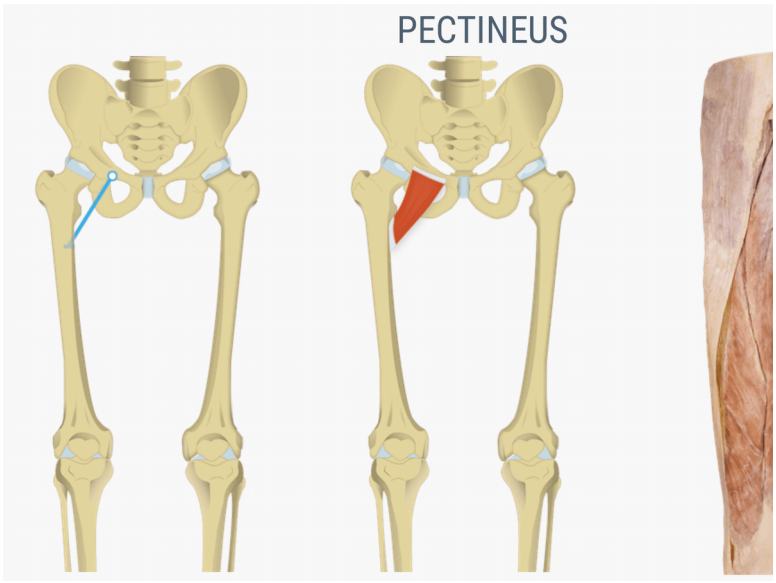

Image Credits

All images in this table are by *University of British Columbia Clinical Anatomy* and are licensed under *CC BY-NC-*

Muscles of the Anterior Compartment

The muscles of the **anterior compartment of the thigh** flex the thigh and extend the leg. This compartment contains the **quadriceps femoris group**, which actually comprises four muscles that extend and stabilize the knee (Figure 9.7.4). The **rectus femoris** is on the anterior aspect of the thigh, the **vastus lateralis** is on the lateral aspect of the thigh, the **vastus medialis** is on the medial aspect of the thigh, and the **vastus intermedius** is between the vastus lateralis and vastus medialis and deep to the rectus femoris. The tendon common to all four is the **quadriceps tendon** (patellar tendon), which inserts into the patella and continues below it as the **patellar ligament**. The patellar ligament attaches to the tibial tuberosity.

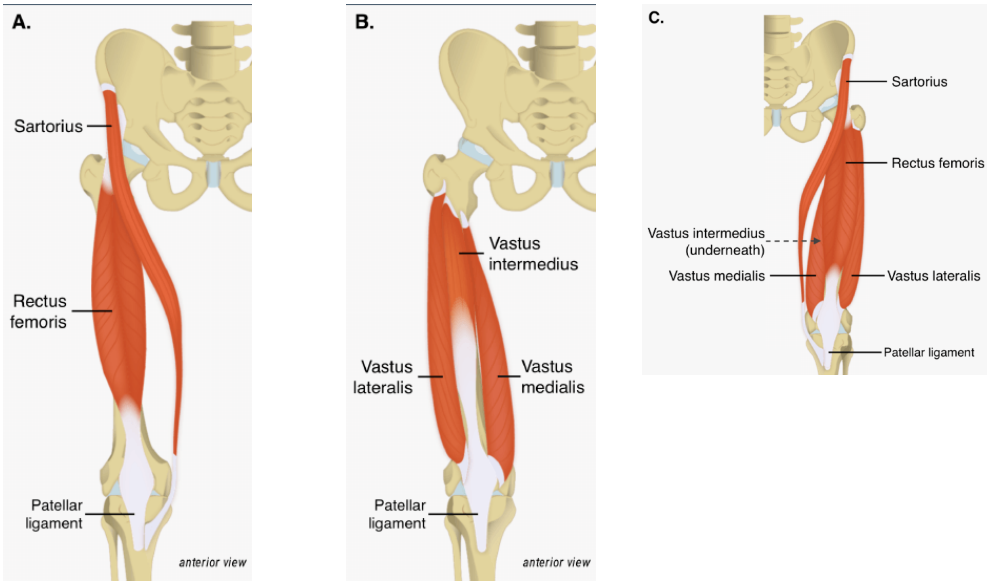

Figure 9.7.4: Muscles - Anterior Thigh. The two superficial muscles (A) act on both the hip and knee joints. The deeper muscles (B) only act on the knee joint. When all muscles are shown, the vastus intermedius cannot be seen (C) because it is deep to the rectus femoris. *(Image credits: "Anterior Thigh Muscles" by Jennifer Lange are licensed under CC BY-NC-SA 4.0, based on images by University of British Columbia Clinical Anatomy)*

In addition to the quadriceps femoris, the **sartorius** is a band-like muscle that extends from the anterior superior iliac spine to the medial side of the proximal tibia (Figure 9.7.4). This versatile muscle flexes the leg at the knee and flexes, abducts, and laterally rotates the leg at the hip. This muscle allows us to sit cross-legged.

Table 9.7.2: Thigh Muscles That Move the Femur, Tibia, and Fibula

Muscle	Origin	Insertion	Movement	Image(s)
Anterior Compartment of Thigh: Quadricepts Femoris Group				
Rectus femoris	Anterior inferior iliac spine; superior margin of acetabulum	Patella; tibial tuberosity	Moves lower leg out in front of body, as when kicking; assists in raising knee	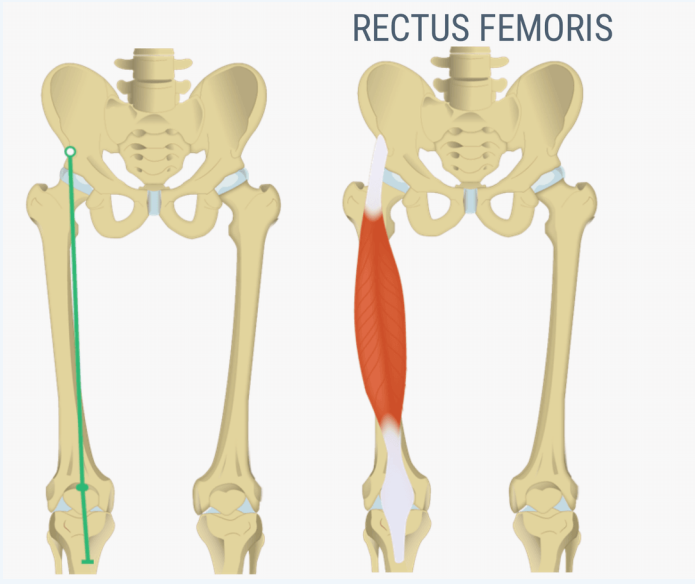

Muscle	Origin	Insertion	Movement	Image(s)
Sartorius	Anterior superior iliac spine	Medial aspect of proximal tibia	Moves back of lower legs up and back toward the buttocks, as when kneeling; assists in moving thigh diagonally upward and outward as when mounting a bike	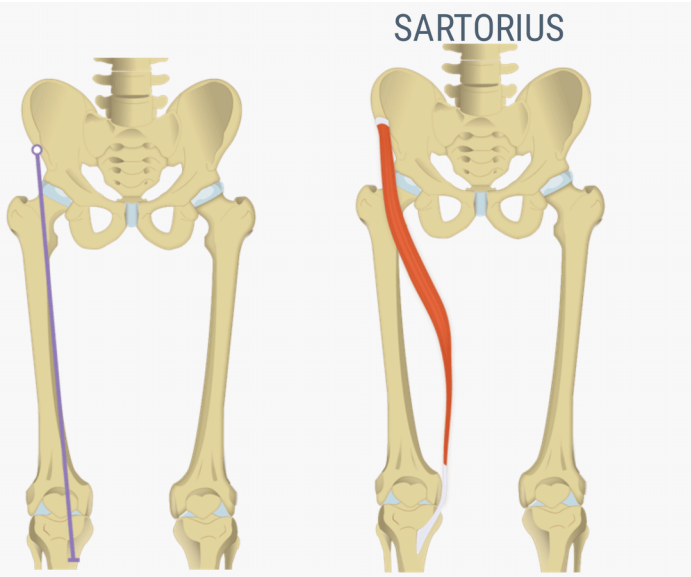
Vastus intermedius	Proximal femur shaft	Patella; tibial tuberosity	Moves lower leg out in front of body, as when kicking	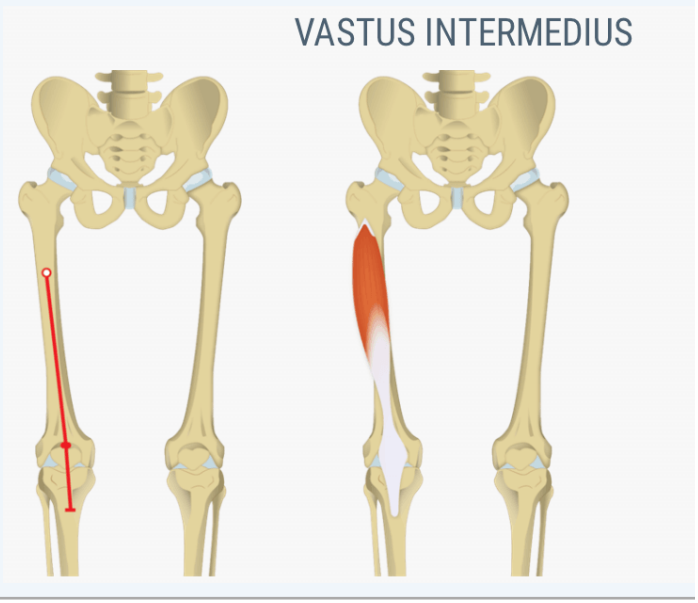

Muscle	Origin	Insertion	Movement	Image(s)
Vastus lateralis	Greater trochanter; intertrochanteric line; linea apera	Patella; tibial tuberosity	Moves lower leg out in front of body, as when kicking	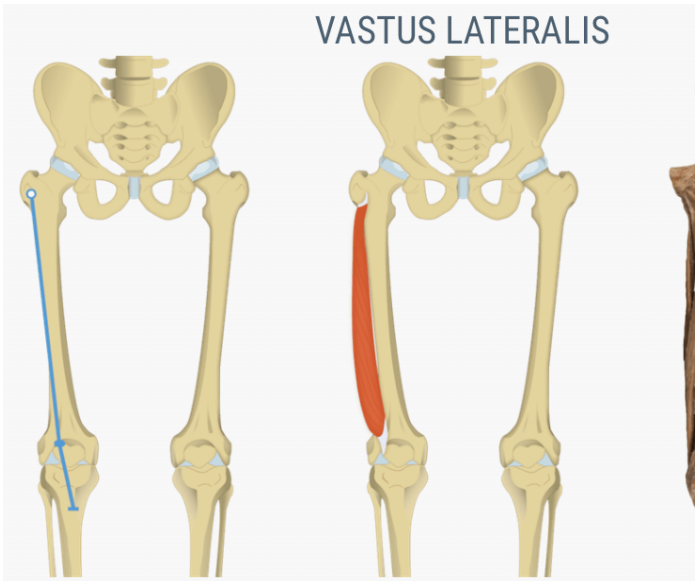
Vastus medialis	Linea aspera; intertrochanteric line	Patella; tibial tuberosity	Moves lower leg out in front of body, as when kicking	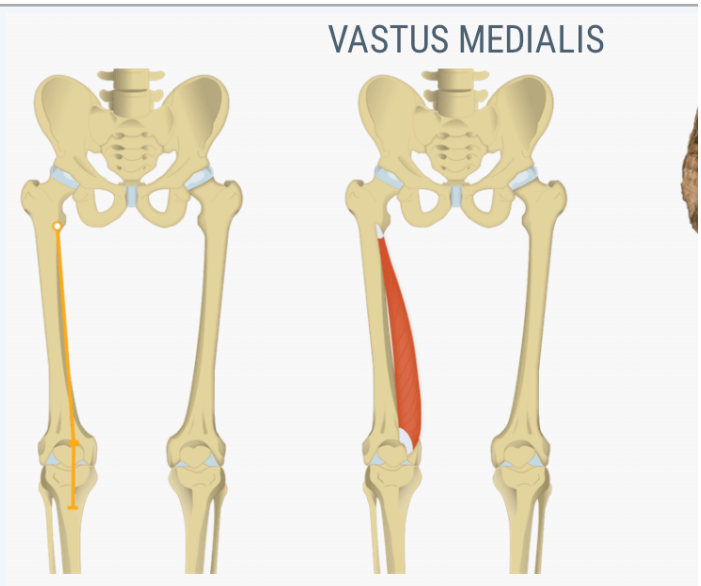
Posterior Compartment of Thigh: Hamstring Group				

Muscle	Origin	Insertion	Movement	Image(s)
Biceps femoris	Ischial tuberosity; linea aspera; distal femur	Head of fibula; lateral condyle of tibia	Moves back of lower legs up and back toward the buttocks, as when kneeling; moves thigh down and back; twists the thigh (and lower leg) outward	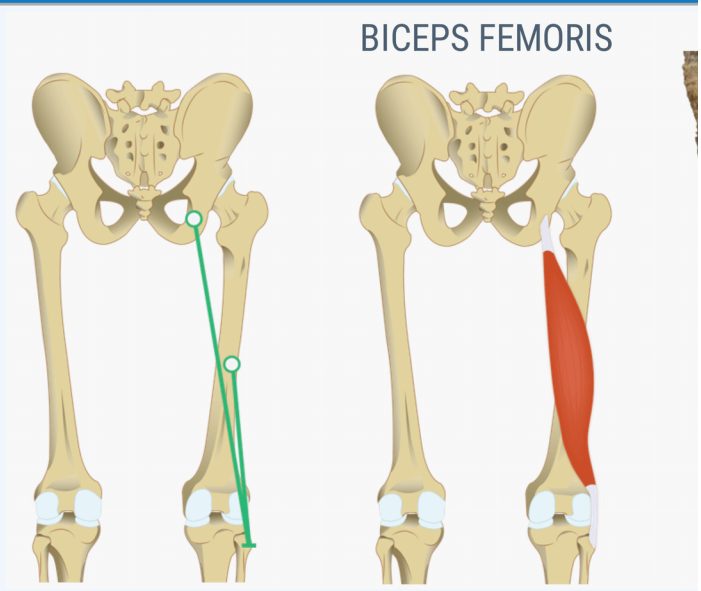
Semimembranosus	Ischial tuberosity	Medial condyle of tibia; lateral condyle of femur	Moves back of lower legs up and back toward the buttocks, as when kneeling; moves thigh down and back; twists the thigh (and lower leg) outward	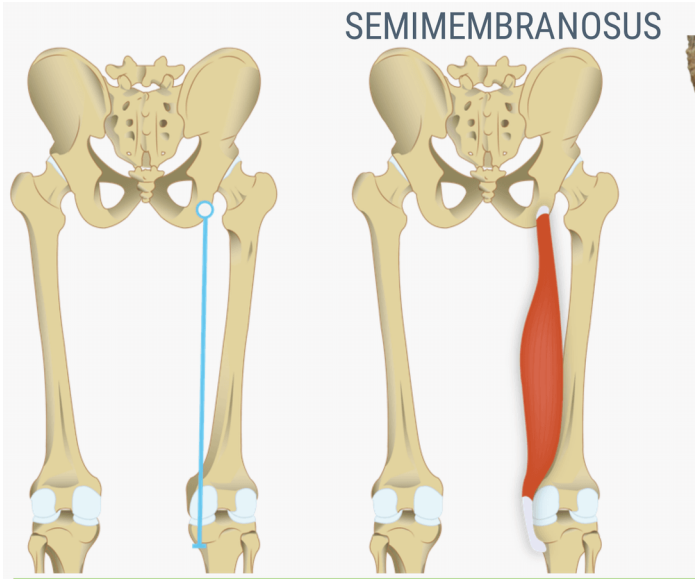

Muscle	Origin	Insertion	Movement	Image(s)
Semitendinosus	Ischial tuberosity	Upper tibial shaft	Moves back of lower legs up and back toward the buttocks, as when kneeling; moves thigh down and back; twists the thigh (and lower leg) outward	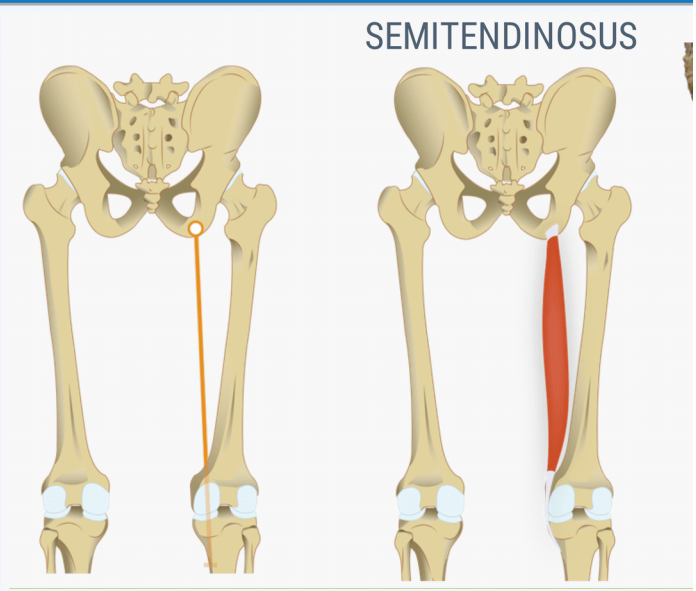

Image Credits

All images in this table are by *University of British Columbia Clinical Anatomy* and are licensed under *CC BY-NC-*

Muscles of the Posterior Compartment

The **posterior compartment of the thigh** includes muscles that flex the leg and extend the thigh. The three long muscles on the back of the knee are the **hamstring group**, which flexes the knee and extends the hip. These are the **biceps femoris (long head)**, **semitendinosus**, and **semimembranosus**. The biceps femoris also has a **short head** that is not considered part of the hamstrings because it only flexes the knee and does not extend the hip (Figure 9.7.5). The tendons of these muscles form the **popliteal fossa**, the diamond-shaped space at the back of the knee.

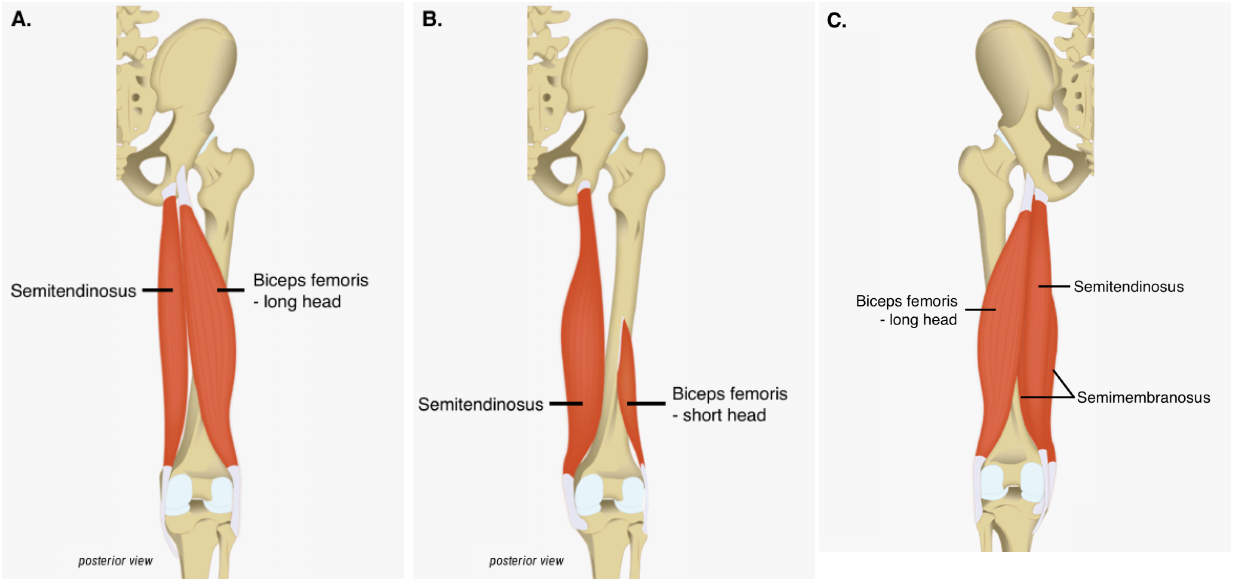

Figure 9.7.5: Muscles - Posterior Thigh. The superficial (A) and deep (B) muscles of the hamstring group cross both the hip and the knee joints. The short head of the biceps femoris (B) is not considered a hamstring because it does not do both of these functions, but it is located in the posterior thigh. When all muscles are shown, the short head cannot be seen (C) because it is deep to the long head. *(Image credits: "Posterior Thigh Muscles" by Jennifer Lange are licensed under CC BY-NC-SA 4.0, based on images by University of British Columbia Clinical Anatomy)*

Muscles That Move the Feet and Toes

The muscles that move the ankle, foot, and toes and are located in the leg are called the crural muscles. Similar to the thigh muscles, the muscles of the leg are divided by fascia into compartments, although the leg has three: anterior, lateral, and posterior (Table 9.7.3).

Muscles of the Anterior Compartment

The muscles in the **anterior compartment of the leg**: the **tibialis anterior**, a long and thick muscle on the lateral surface of the tibia, the **extensor hallucis longus**, deep under it, and the **extensor digitorum longus**, lateral to it, all contribute to raising the front of the foot when they contract. Some, but not all, people have a third muscle in this group called the **fibularis tertius** (*tertius*="*third*"), a small muscle that originates on the anterior surface of the fibula, is associated with the extensor digitorum longus and sometimes fused to it (Figure 9.7.6).

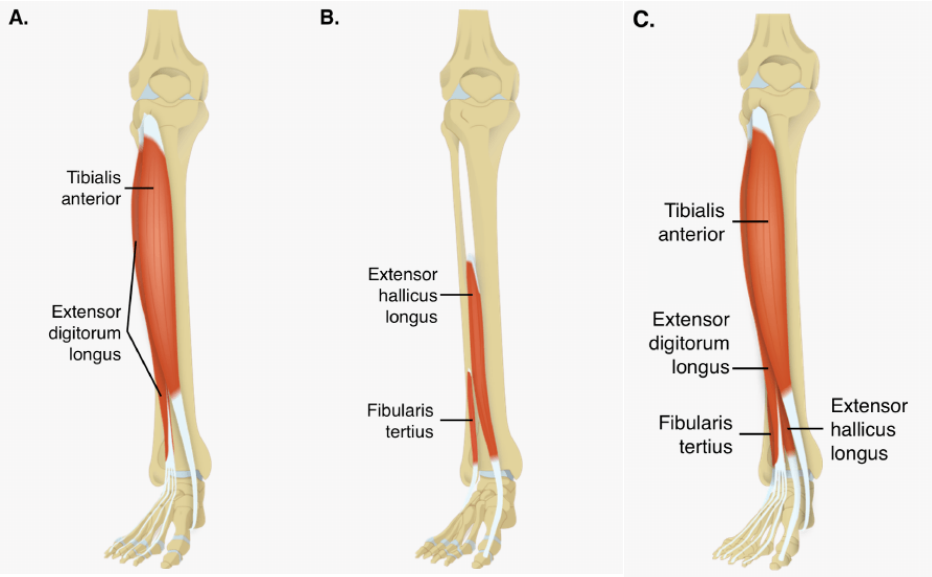

Figure 9.7.6: Muscles - Anterior Leg. The superficial (A) and deep (B) muscles of the anterior compartment of the leg cross both the ankle and joints in the foot. When all muscles are shown, only a small piece of the deep muscles can be seen (C), but you can easily identify the extensor hallicus longus because its tendon can be traced from the big toe. *(Image credits: "Anterior Leg Muscles" by Jennifer Lange are licensed under CC BY-NC-SA 4.0, based on images by University of British Columbia Clinical Anatomy)*

Muscles of the Lateral Compartment

*The **lateral compartment of the leg** includes two muscles: the **fibularis longus** (aka peroneus longus) and the **fibularis brev** peroneus brevis) (Figure 9.7.7). Fibularis longus is the more superficial of the two and it originates more proximally on the fibula the fibularis brevis. Both are strong everters of the foot and weak plantar flexors.*

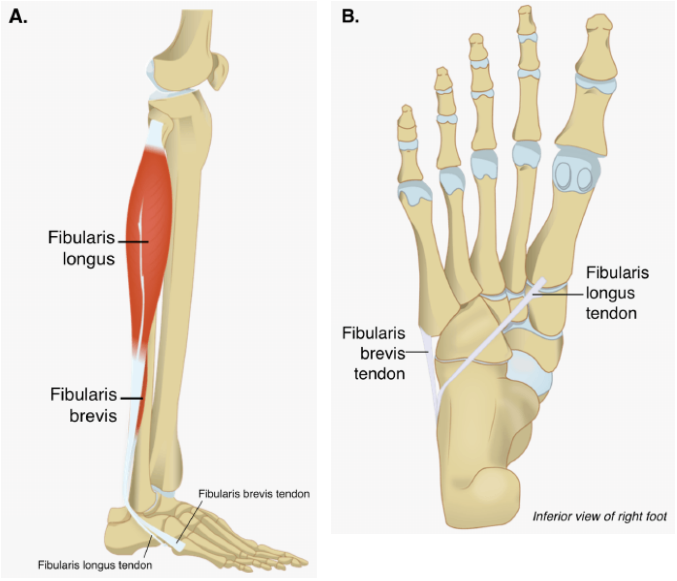

Figure 9.7.7: Muscles - Lateral Leg. The two muscles in the lateral compartment of the leg run along the length of the fibula (A). Based on their inse (B), both muscles cause eversion of the foot. (Image credits: "Lateral Leg Muscles" by Jennifer Lange are licensed under CC BY-NC-SA 4.0, based by University of British Columbia Clinical Anatomy)

Muscles of the Posterior Compartment

*The superficial muscles in the **posterior compartment of the leg** all insert onto the **calcaneal tendon** (Achilles tendon), a strc that inserts into the posterior aspect of the calcaneus, and all are plantar flexors of the ankle joint. The most superficial and vis muscle of the calf is the **gastrocnemius**. This muscle originates superior to the knee and inserts into the calcaneous, so it is res for both knee flexion and ankle plantar flexion. The gastrocnemius has two wide muscle bellies called the **medial head** and the l **head**. Deep to the gastrocnemius is the wide, flat **soleus**. This muscle is named because it resembles a flatfish. The two heads c gastrocnemius together with the soleus are collectively called the triceps surae or, more commonly, the calf muscles. The **planta** small muscle with a long tendon that runs obliquely between the two large sural muscles; some people may have two of these m whereas no plantaris is observed in about seven percent of other cadaver dissections.*

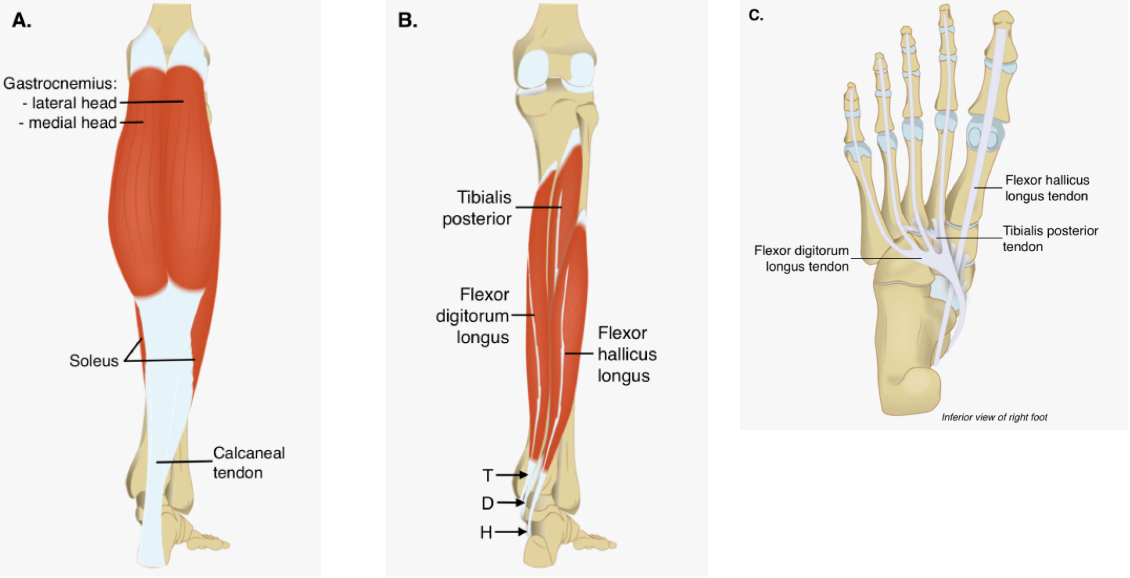

Figure 9.7.8: Posterior Leg Muscles. Superficial (A) and deep (B) views of the posterior compartment of the leg showing the muscles that plantar fl invert the foot, and flex the toes as well as their tendinous insertions (C). (Image credits: "Posterior Leg Muscles" by Jennifer Lange are licensed u NC-SA 4.0, based on images by University of British Columbia Clinical Anatomy)

*There are four deep muscles in the posterior compartment of the leg: the **flexor digitorum longus**, **flexor hallucis longus**, **tib posterior** and **popliteus.** Popliteus is a small muscle that runs diagonally across the popliteal region. Its main function is to "un knee joint through slight medial rotation and flexion. The three remaining muscles are located along the posterior surface of the the fibula, deep to the triceps surae (Figure 9.7.8). All plantarflex the ankle joint. As their names suggest, flexor digitorum longus flexes digits 2-5 and flexor hallucis longus also flexes the big toe. The secondary action of the tibialis posterior is inversion of th commonly used neumonic for the order of the tendons of these three muscles as they pass posterior to the medial malleolus is* *And Very Nervous Harry: T = **T**ibialis posterior, Dick = flexor **D**igitorum longus, A = **a**rtery, V = **v**ein, N = **n**erve, H = flexor **H**allicu*

Table 9.7.3: Muscles That Move the Feet and Toes

Prime Mover	Origin	Insertion	Movement	Image(s)
Anterior Compartment of Leg				
Extensor digitorum longus	Lateral condyle of tibia; proximal portion of fibula; interosseous membrane	Middle and distal phalanges of toes 2 - 5	Extends toes 2-4; dorsiflexion of ankle	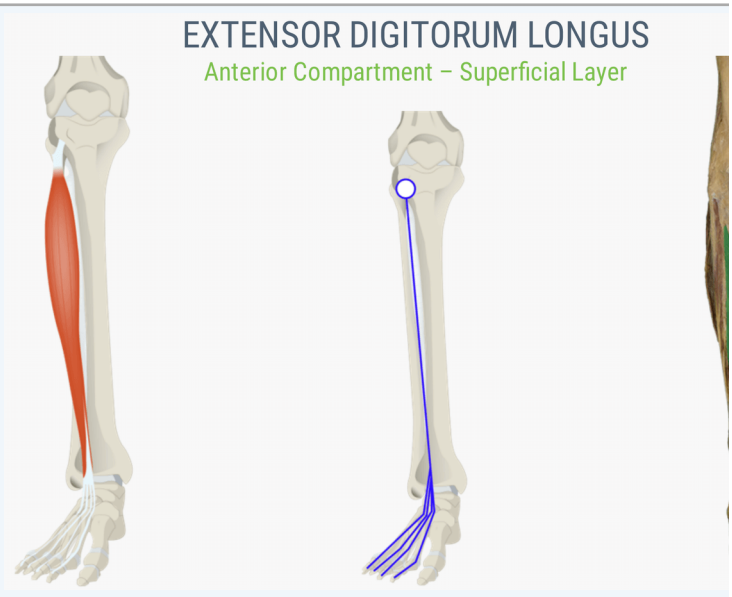

Prime Mover	Origin	Insertion	Movement	Image(s)
Extensor hallucis longus	Anteromedial fibula shaft; interosseous membrane	Distal phalanx hallux (big toe)	Extends the big toe; dorsiflexion of ankle	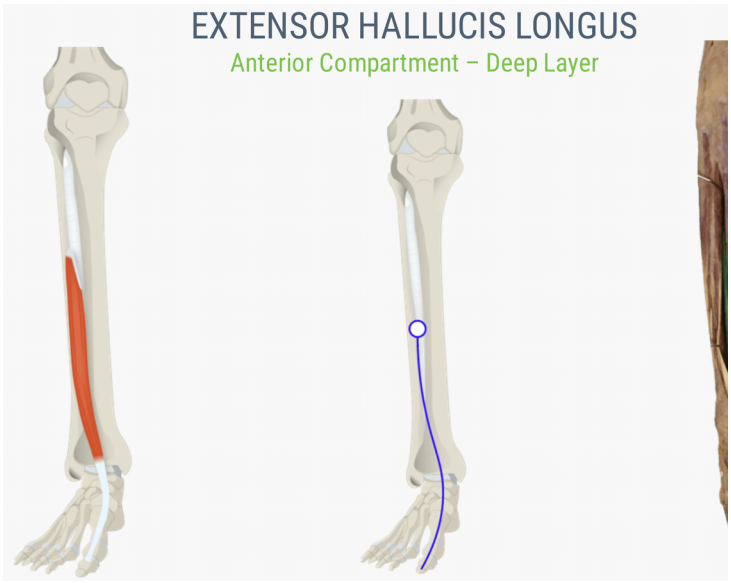
Tibialis anterior	Lateral condyle and upper tibial shaft; interosseous membrane	Interior surface of medial cuneiform; first metatarsal bone	Dorsiflexion of ankle; inversion of intertarsal	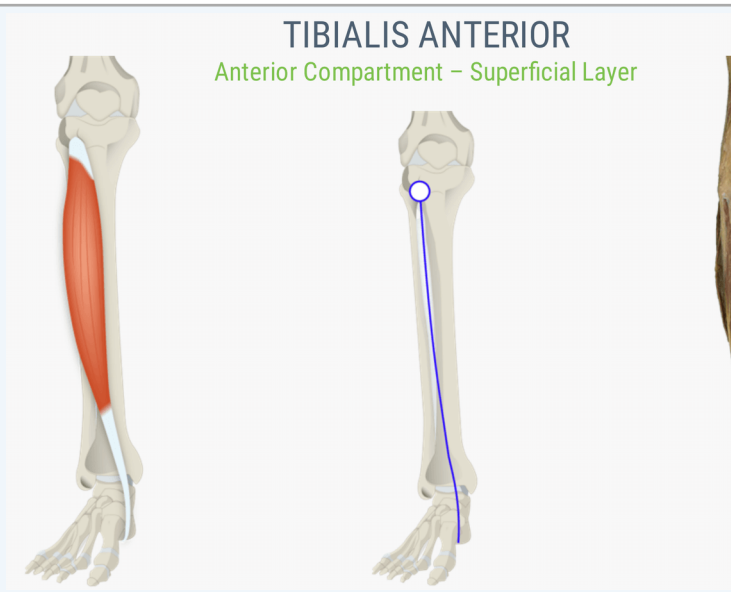
Lateral Compartment of Leg				

Prime Mover	Origin	Insertion	Movement	Image(s)
Fibularis (peroneus) brevis	Distal fibula shaft	Proximal end of fifth metatarsal	Eversion of intertarsal; plantarflexion of ankle	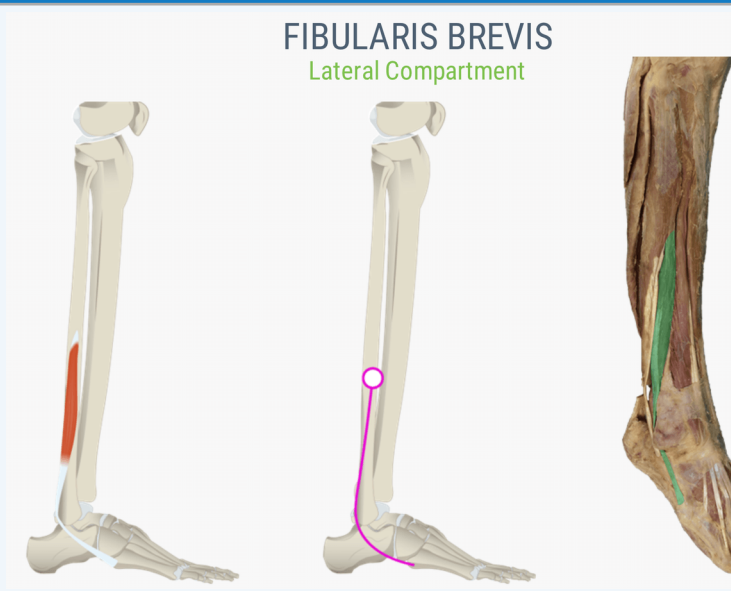
Fibularis (peroneus) longus	Upper portion of lateral fibula	First metatarsal; medial cuneiform	Eversion of intertarsal, plantarflexion of ankle	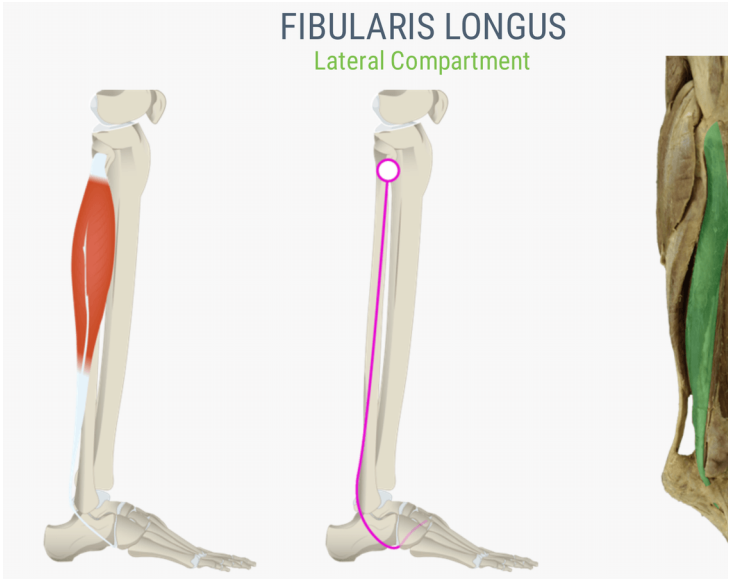
Posterior Compartment of Leg: Superficial Muscles				

Prime Mover	Origin	Insertion	Movement	Image(s)
Gastrocnemius	Medial and lateral condyles of femur	Posterior calcaneus	Plantarflexion of ankle; flexion of knee	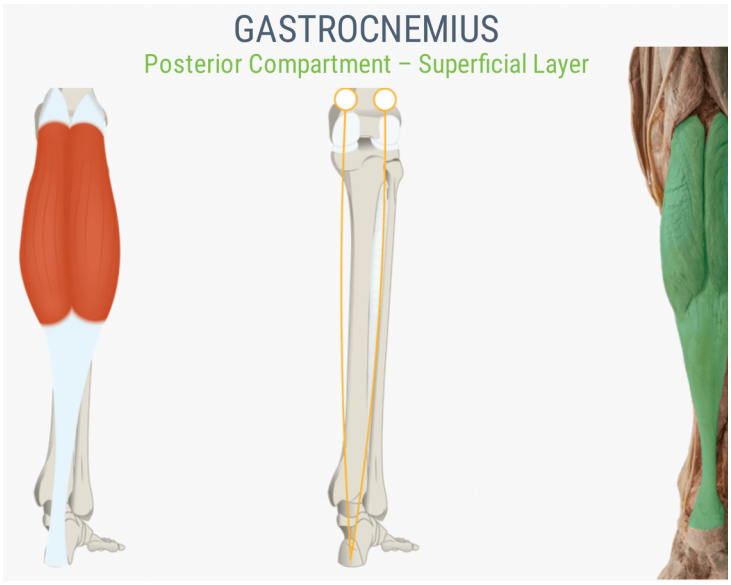
Soleus	Superior tibia; fibula; interosseous membrane	Posterior calcaneus	Plantarflexion of ankle	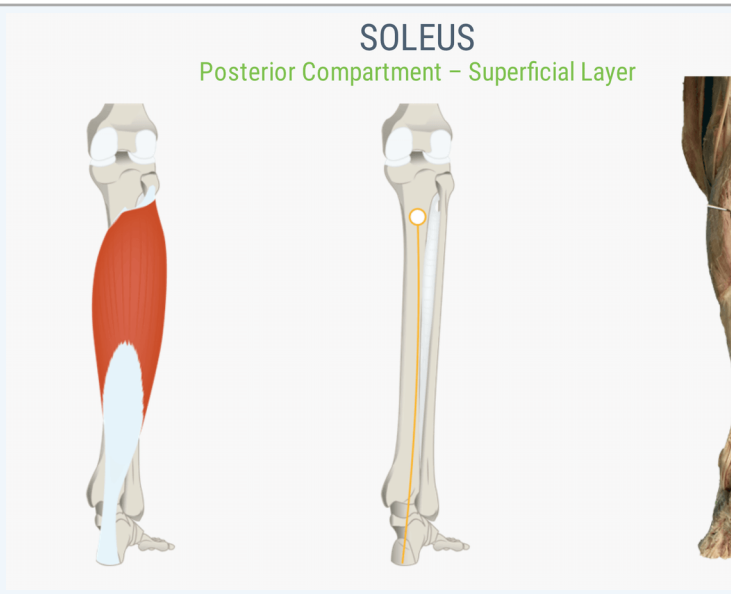
Posterior Compartment of Leg: Deep Muscles				

Prime Mover	Origin	Insertion	Movement	Image(s)
Flexor digitorum longus	Posterior tibia	Distal phalanges of toes 2 - 5	Flexion of digits 2-5; plantarflexion of ankle	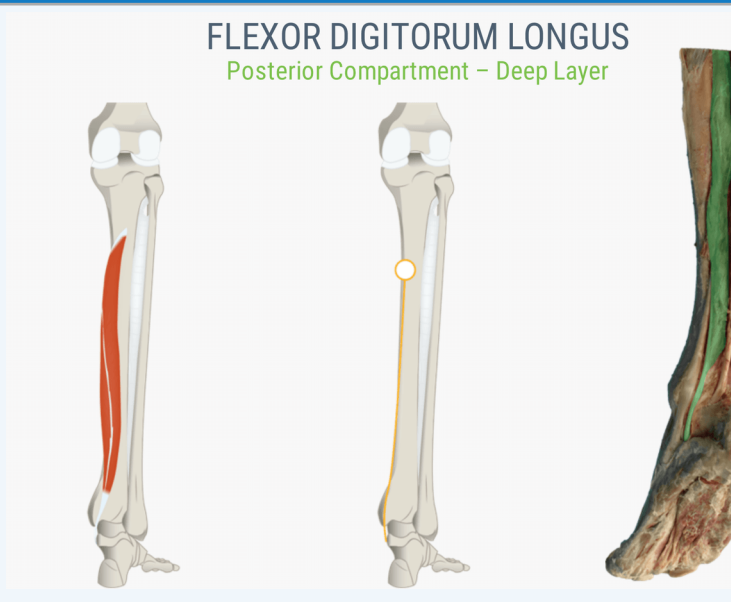
Flexor hallucis longus	Midshaft of fibula; interosseous membrane	Distal phalanx of hallux (big toe)	Flexes big toe; plantarflexion of ankle	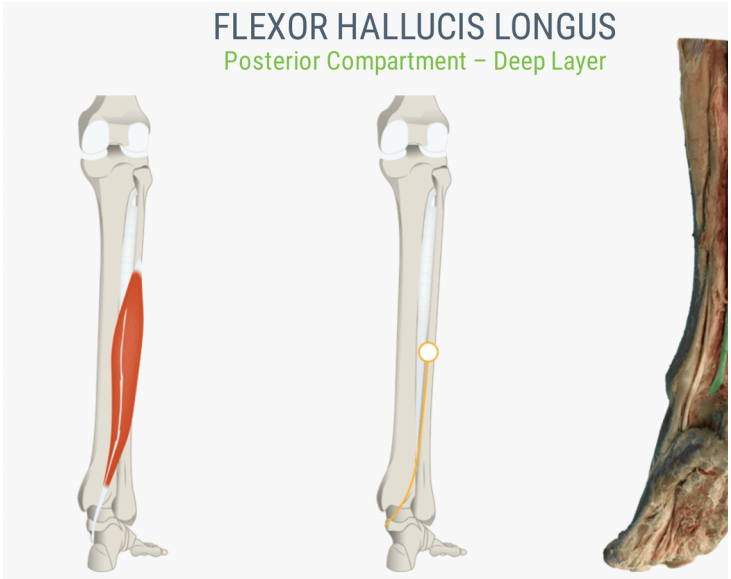

Prime Mover	Origin	Insertion	Movement	Image(s)
Tibialis posterior	Superior tibia; fibula; interosseous membrane	Tarsals and metatarsals 2 - 4	Plantarflexion of ankle; inversion of intertarsal	

Image Credits

All images in this table are by *University of British Columbia Clinical Anatomy* and are licensed under *CC BY-NC-*

The foot also has intrinsic muscles, which originate and insert within it (similar to the intrinsic muscles of the hand). These muscles primarily provide support for the foot and its arch, and contribute to movements of the toes. The principal support for the longitudinal arch of the foot is a deep fascia called **plantar aponeurosis**, which runs from the calcaneus bone to the toes (inflammation of this tissue is the cause of "plantar fasciitis," which can affect runners.

Muscles of the lower limb

Explore the muscles of the lower limb in this 3D rending of a human leg model.

This interactive element is not available in this format. Visit the link or scan the QR code to access it online.

View this Interactive Content online

Human Leg by **AnatomyPhysiologySCC** on **Sketchfab**

Concept Review

The pelvic girdle attaches the legs to the axial skeleton. The hip joint is where the pelvic girdle and the leg come together. The hip is joined to the pelvic girdle by many muscles. In the gluteal region, the psoas major and iliacus form the iliopsoas. The large and strong gluteus maximus, gluteus medius, and gluteus minimus extend and abduct the femur. Along with the gluteus maximus, the tensor fascia lata muscle forms the iliotibial tract. The lateral rotators of the femur at the hip are the piriformis, obturator internus, obturator externus, superior gemellus, inferior gemellus, and quadratus femoris. On the medial part of the thigh, the adductor longus, adductor brevis, and adductor magnus adduct the thigh and medially rotate it. The pectineus muscle adducts and flexes the femur at the hip.

The thigh muscles that move the femur, tibia, and fibula are divided into medial, anterior, and posterior compartments. The medial compartment includes the adductors, pectineus, and the gracilis. The anterior compartment comprises the quadriceps femoris, quadriceps tendon, patellar ligament, and the sartorius. The quadriceps femoris is made of four muscles: the rectus femoris, the vastus lateralis, the vastus medius, and the vastus intermedius, which together extend the knee. The posterior compartment of the thigh includes the hamstrings: the biceps femoris, semitendinosus, and the semimembranosus, which all flex the knee.

The muscles of the leg that move the foot and toes are divided into anterior, lateral, superficial- and deep-posterior compartments. The anterior compartment includes the tibialis anterior, the extensor hallucis longus, the extensor digitorum longus, and the fibularis (peroneus) tertius. The lateral compartment houses the fibularis (peroneus) longus and the fibularis (peroneus) brevis. The superficial posterior compartment has the gastrocnemius, soleus, and plantaris; and the deep posterior compartment has the popliteus, tibialis posterior, flexor digitorum longus, and flexor hallucis longus.

Review Questions

Query 9.7.1

This interactive element is not available in this format. Visit the link or scan the QR code to access it online.

View this Interactive Content online

Critical Thinking Questions

Query 9.7.2

This interactive element is not available in this format. Visit the link or scan the QR code to access it online.

View this Interactive Content online

Query 9.7.3

This interactive element is not available in this format. Visit the link or scan the QR code to access it online.

View this Interactive Content online

Glossary

Query 9.7.4

This interactive element is not available in this format. Visit the link or scan the QR code to access it online.

View this Interactive Content online

Contributors and Attributions

- OpenStax Anatomy & Physiology (CC BY 4.0). Access for free at https://openstax.org/books/anatomy-and-physiology

This page titled 9.7: Appendicular Muscles of the Pelvic Girdle and Lower Limbs is shared under a CC BY-NC-SA 4.0 license and was authored, remixed, and/or curated by Jennifer Lange et al..

- 10.7: Appendicular Muscles of the Pelvic Girdle and Lower Limbs by Whitney Menefee, Julie Jenks, Chiara Mazzasette, and Kim-Leiloni Nguyen is licensed CC BY 4.0.

9.8: Anatomical Atlas - Muscular System

A compendium of anatomical images: slides, models, and/or cadavers.

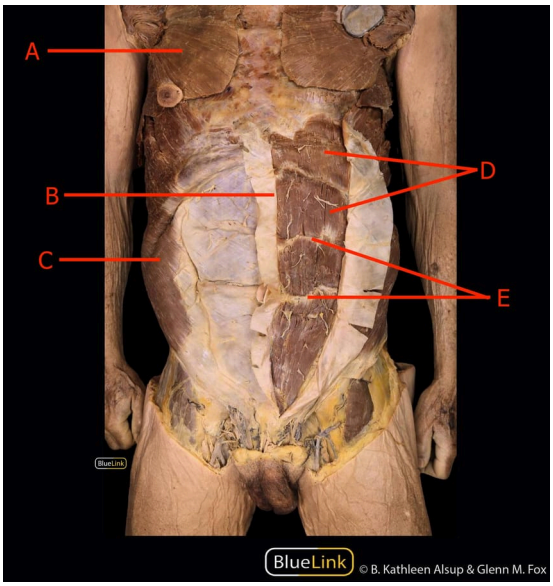

Image Credits

Cadaver images by BlueLink are licensed under CC BY-NC 4.0 with notification of the original authors. Labelling by Jennifer Lange.

Answer Key (click to show/hide answers)

A - pectoralis major

B - linea alba

C - external oblique

D - rectus abdominus

E - tendinous intersections

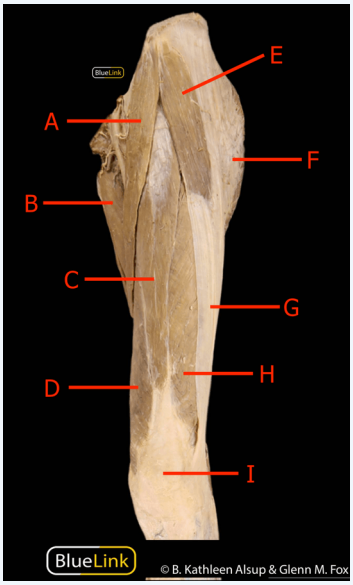

Image Credits

Cadaver images by BlueLink are licensed under CC BY-NC 4.0 with notification of the original authors. Labelling by Jennifer Lange.

Answer Key (click to show/hide answers)

A - sartorius

B - adductor longus

C - rectus femoris

D - vastus medialis

E - tensor fasciae latae

F - gluteus maximus

G - iliotibial tract/band

H - vastus lateralis

I - patella

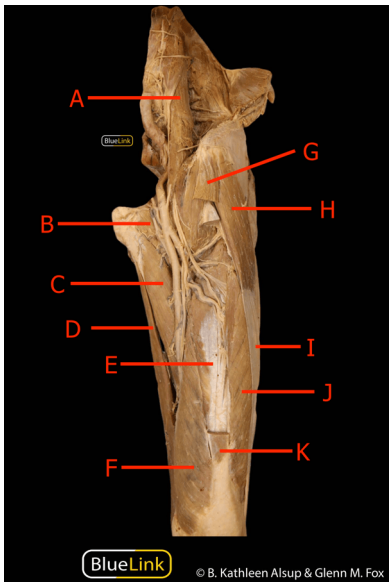

Image Credits

Cadaver images by BlueLink are licensed under CC BY-NC 4.0 with notification of the original authors. Labelling by Jennifer Lange.

Answer Key (click to show/hide answers)

A - psoas major

B - pectineus

C - adductor longus

D - grascilis

E - vastus intermedius

F - vastus medialis

G - sartorius (cut)

H - tensor fasciae latae

I - iliotibial tract/band

J - vastus lateralis

K - rectus femoris (cut)

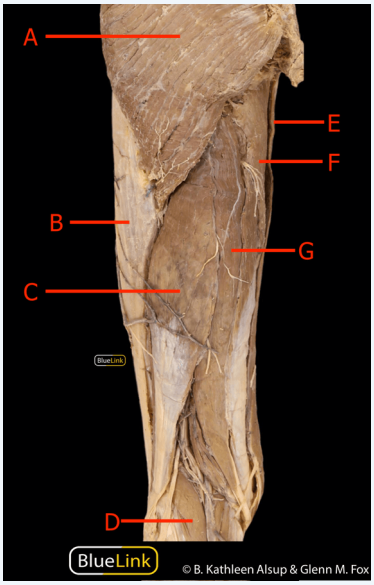

Image Credits

Cadaver images by BlueLink are licensed under CC BY-NC 4.0 with notification of the original authors. Labelling by Jennifer Lange.

Answer Key (click to show/hide answers)

A - gluteus maximus

B - iliotibial tract/band

C - biceps femoris

D - popliteus

E - grascilis

F - semimembranosus

G - semitendinosus

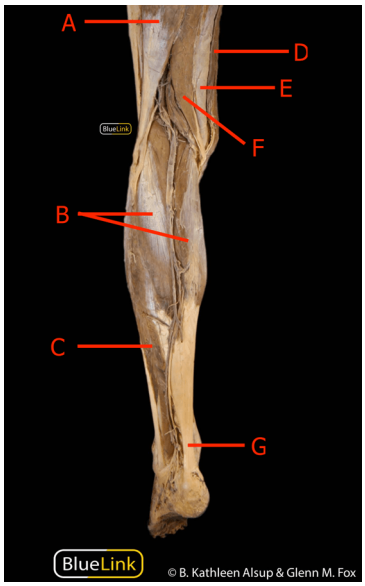

Image Credits

Cadaver images by BlueLink are licensed under CC BY-NC 4.0 with notification of the original authors. Labelling by Jennifer Lange.

Answer Key (click to show/hide answers)

A - biceps femoris

B - gastrocnemius

C - soleus

D - grascilis

E - semimembranosus

F - semitendinosus

G - calcaneal (Achilles) tendon

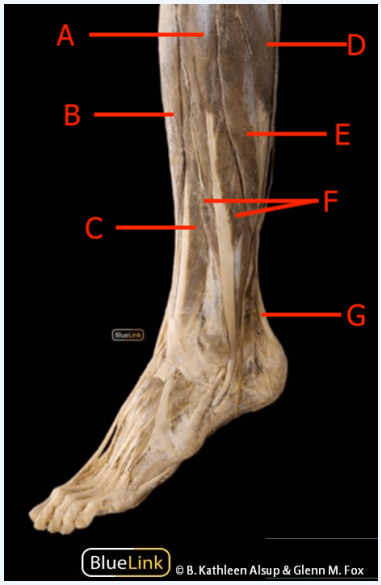

Image Credits

Cadaver images by BlueLink are licensed under CC BY-NC 4.0 with notification of the original authors. Labelling by Jennifer Lange.

Answer Key (click to show/hide answers)

A - fibularis longus

B - tibialis anterior

C - extensor digitorum longus

D - gastrocnemius

E - soleus

F - fibularis brevis

G - calcaneal (Achilles) tendon

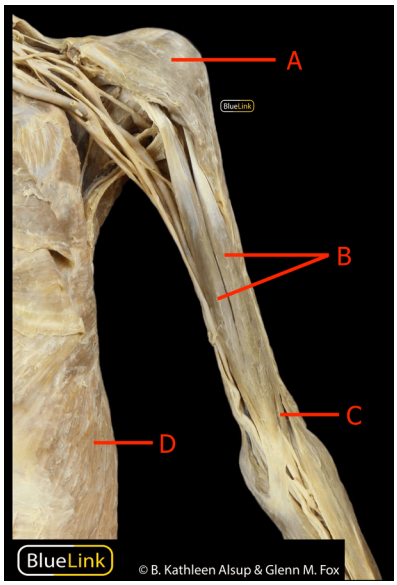

Image Credits

Cadaver images by BlueLink are licensed under CC BY-NC 4.0 with notification of the original authors. Labelling by Jennifer Lange.

Answer Key (click to show/hide answers)

A - deltoid

B - biceps brachii

C - brachialis

D - external oblique

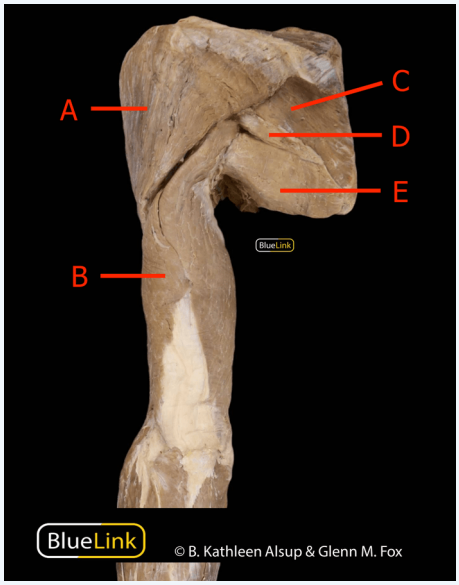

Image Credits

Cadaver images by BlueLink are licensed under CC BY-NC 4.0 with notification of the original authors. Labelling by Jennifer Lange.

Answer Key (click to show/hide answers)

A - deltoid

B - triceps brachii

C - infraspinatus

D - teres minor

E - teres major

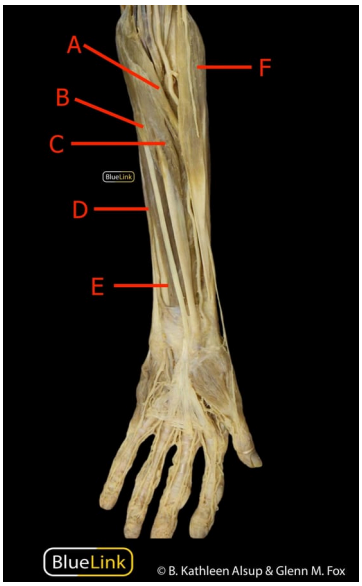

Image Credits

Cadaver images by BlueLink are licensed under CC BY-NC 4.0 with notification of the original authors. Labelling by Jennifer Lange.

Answer Key (click to show/hide answers)

A - pronator teres

B - palmaris longus

C - flexor carpi radialis

D - flexor carpi ulnaris

E - flexor digitorum superficialis

F - brachioradialis

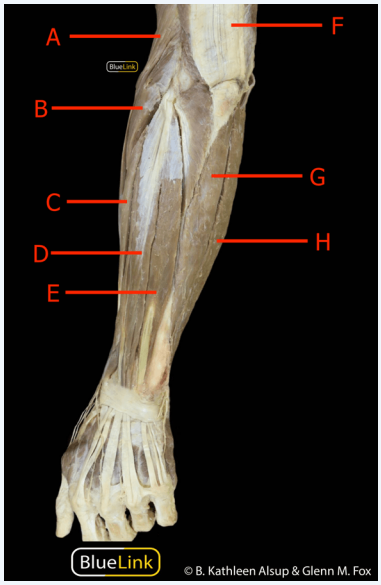

Image Credits

Cadaver images by BlueLink are licensed under CC BY-NC 4.0 with notification of the original authors. Labelling by Jennifer Lange.

Answer Key (click to show/hide answers)

A - brachioradialis

B - extensor carpi radialis longus

C - extensor carpi radialis brevis

D - extensor digitorum

E - extensor carpi ulnaris

F - triceps brachii

G - flexor carpi ulnaris

H - palmaris longus

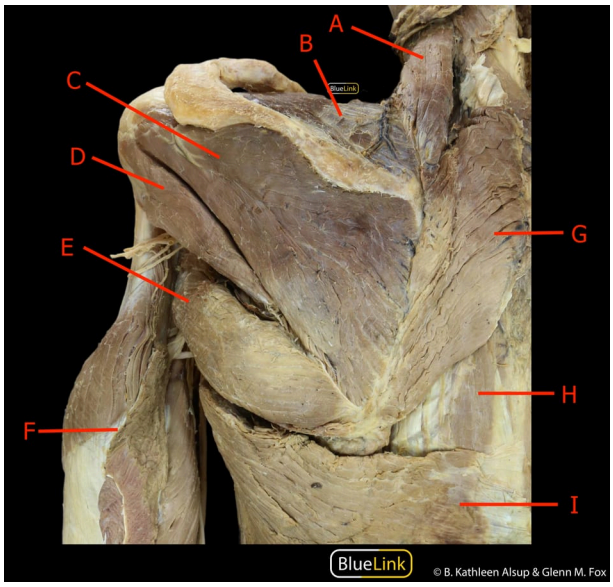

Image Credits

Cadaver images by BlueLink are licensed under CC BY-NC 4.0 with notification of the original authors. Labelling by Jennifer Lange.

Answer Key (click to show/hide answers)

A - levator scapluae

B - supraspinatus

C - infraspinatus

D - teres minor

E - teres major

F - triceps brachii

G - rhomboid major

H - erector spinae (group)

I - latissimus dorsi

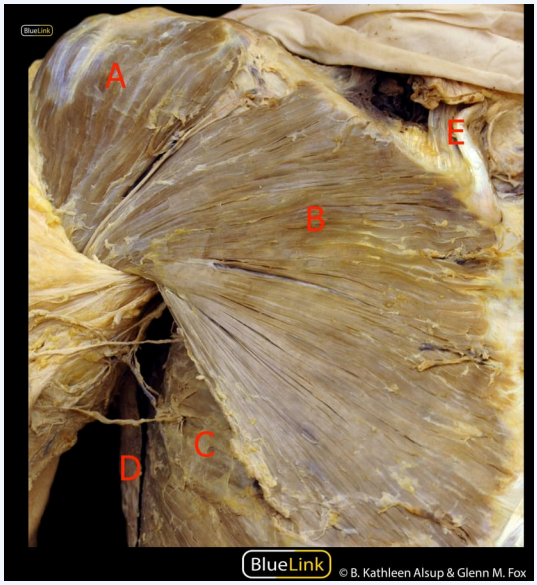

Image Credits

Cadaver images by BlueLink are licensed under CC BY-NC 4.0 with notification of the original authors. Labelling by Jennifer Lange.

Answer Key (click to show/hide answers)

A - deltoid

B - pectoralis major

C - serratus anterior

D - latissimus dorsi

E - sternocleidomastoid

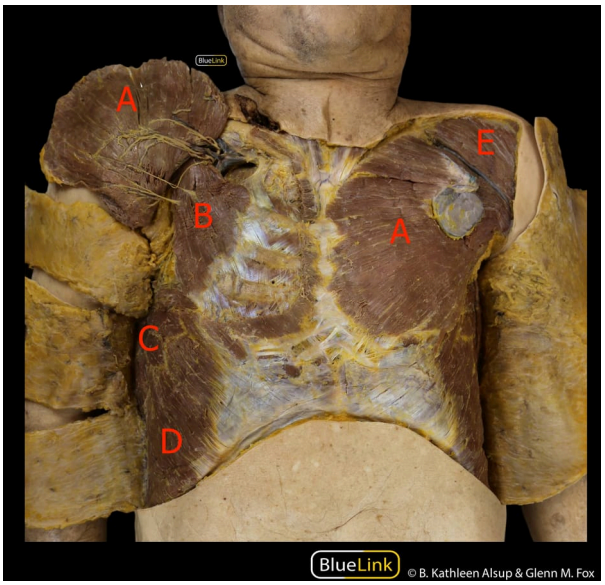

Image Credits

Cadaver images by BlueLink are licensed under CC BY-NC 4.0 with notification of the original authors. Labelling by Jennifer Lange.

Answer Key (click to show/hide answers)

A - pectoralis major

B - pectoralis minor

C - serratus anterior

D - external oblique

E - deltoid

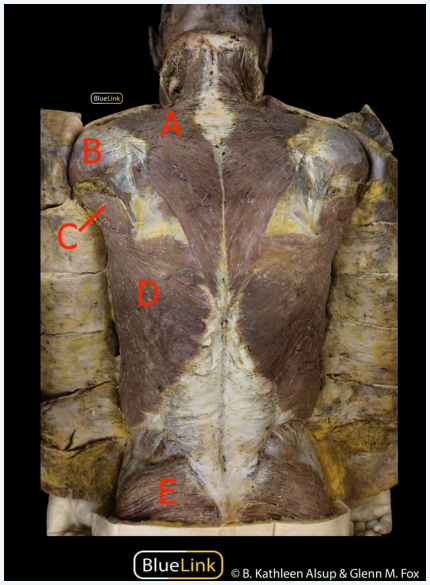

Image Credits

Cadaver images by BlueLink are licensed under CC BY-NC 4.0 with notification of the original authors. Labelling by Jennifer Lange.

Answer Key (click to show/hide answers)

A - trapezius

B - deltoid

C - teres major

D - latissimus dorsi

E - gluteus maximus

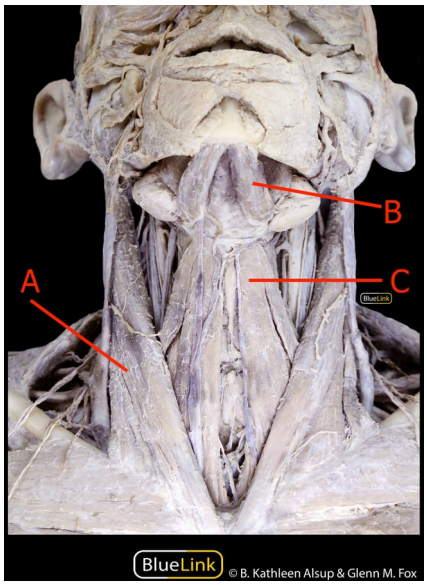

Image Credits

Cadaver images by BlueLink are licensed under CC BY-NC 4.0 with notification of the original authors. Labelling by Jennifer Lange.

Answer Key (click to show/hide answers)

A - sternocleidomastoid

B - digastric

C - sternohyoid

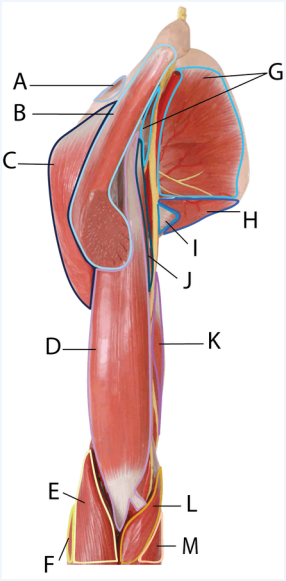

Image Credits

Model images by EUSKALANATO are licensed under CC BY-NC-SA 2.0. Labelling by Sofia Elizondo.

Answer Key (click to show/hide answers)
Anterior View

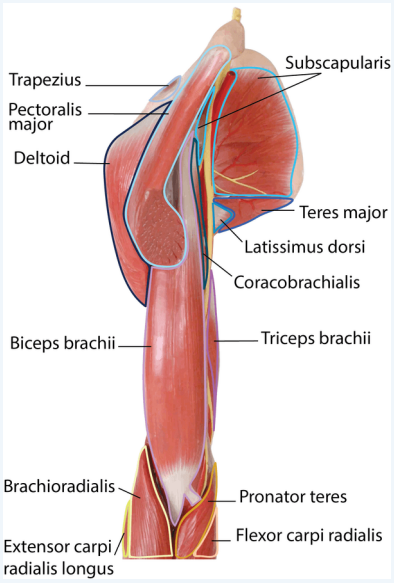

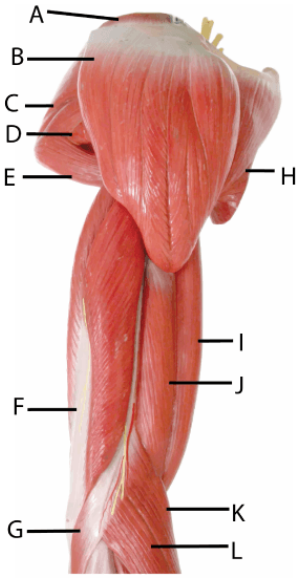

Image Credits

Model images by EUSKALANATO are licensed under CC BY-NC-SA 2.0. Labelling by Sofia Elizondo.

Answer Key (click to show/hide answers)
Lateral View

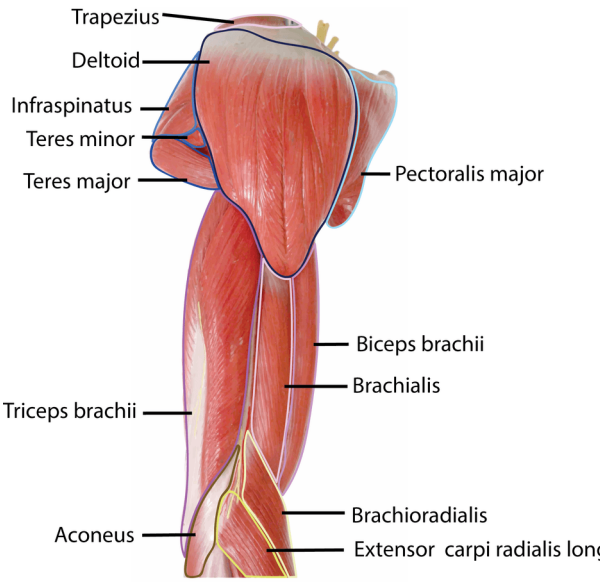

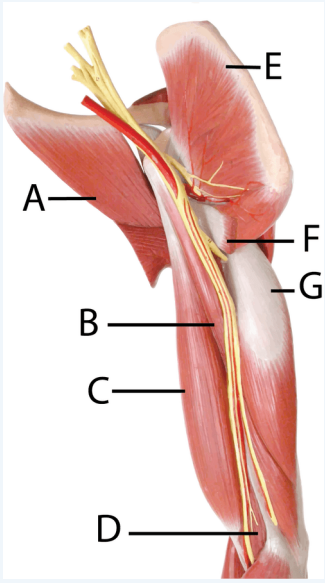

Image Credits

Model images by EUSKALANATO are licensed under CC BY-NC-SA 2.0. Labelling by Sofia Elizondo.

Answer Key (click to show/hide answers)
Medial View

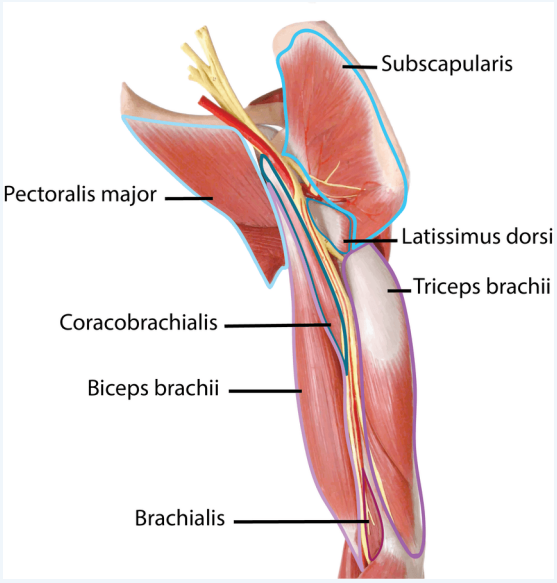

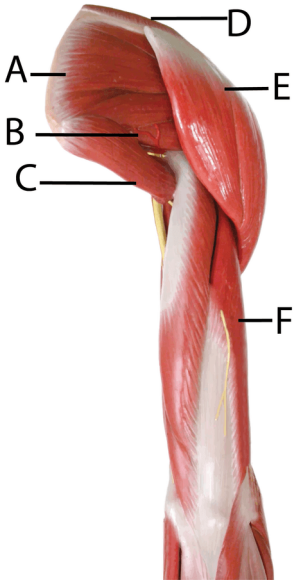

Image Credits

Model images by EUSKALANATO are licensed under CC BY-NC-SA 2.0. Labelling by Sofia Elizondo.

Answer Key (click to show/hide answers)
Posterior View

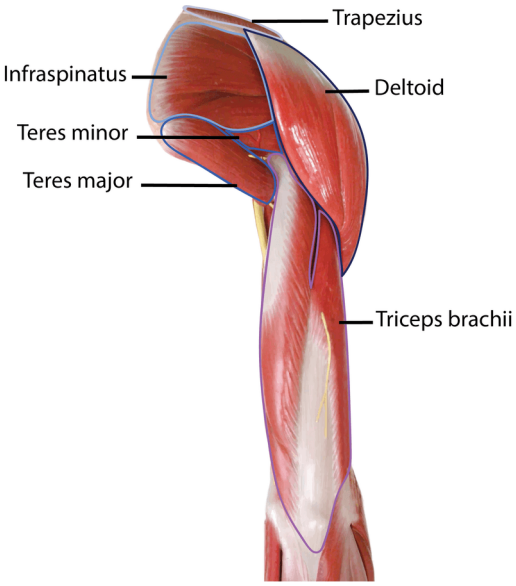

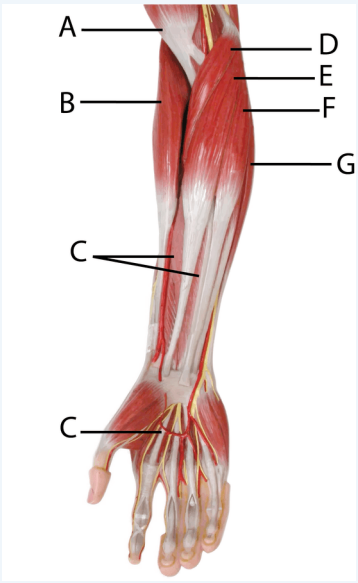

Image Credits

Model images by EUSKALANATO are licensed under CC BY-NC-SA 2.0. Labelling by Sofia Elizondo.

Answer Key (click to show/hide answers)

Anterior View

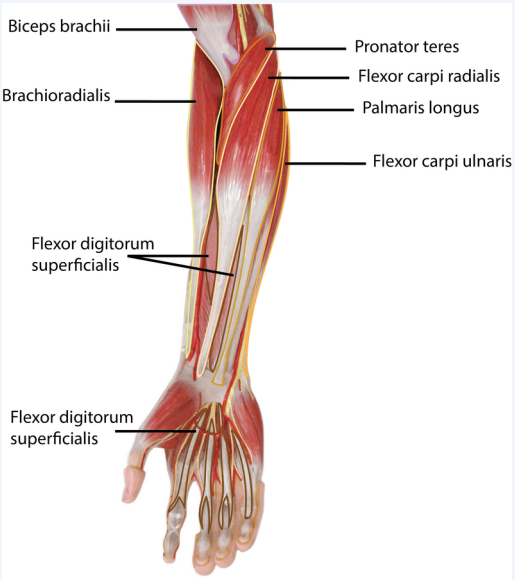

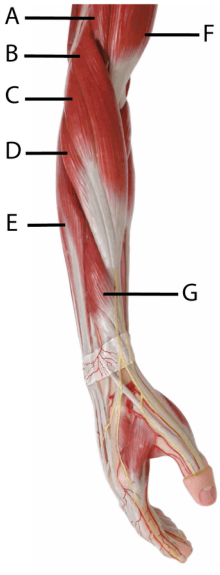

Image Credits

Model images by EUSKALANATO are licensed under CC BY-NC-SA 2.0. Labelling by Sofia Elizondo.

Answer Key (click to show/hide answers)

Medial View

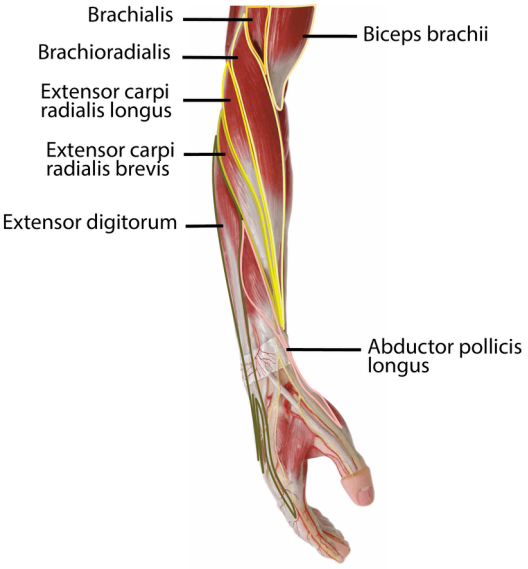

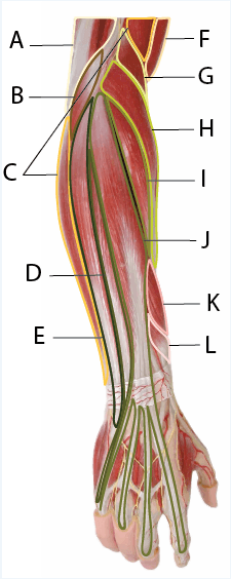

Image Credits

Model images by EUSKALANATO are licensed under CC BY-NC-SA 2.0. Labelling by Sofia Elizondo.

Answer Key (click to show/hide answers)

Posterior View

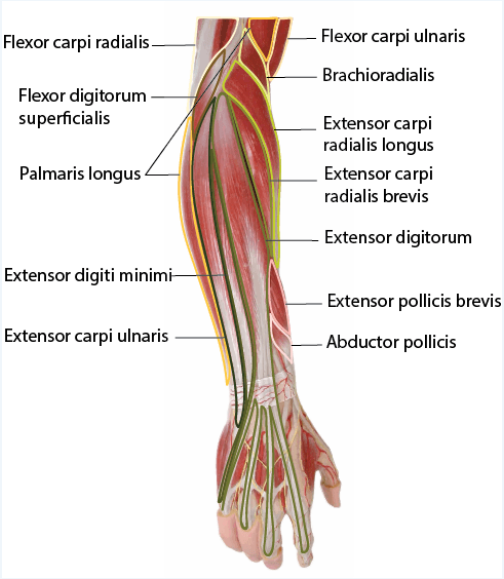

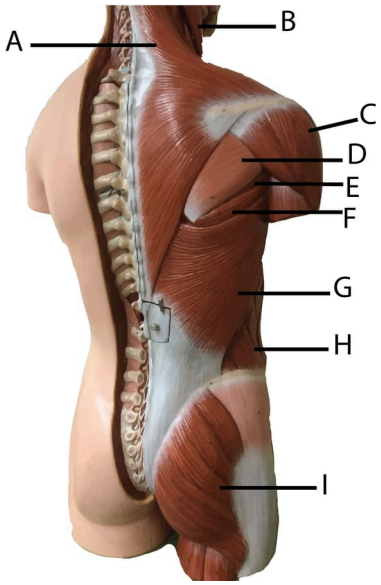

Image Credits

Torso model images by Jennifer Lange are licensed under CC BY-NC-SA 4.0. Labelling by Sofia Elizondo.

Answer Key (click to show/hide answers)

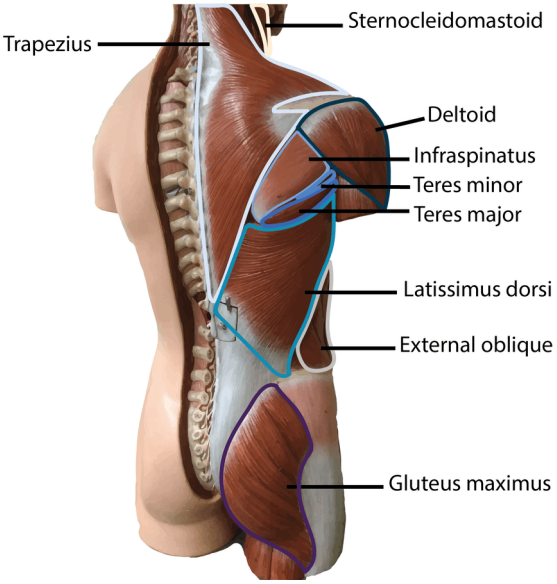

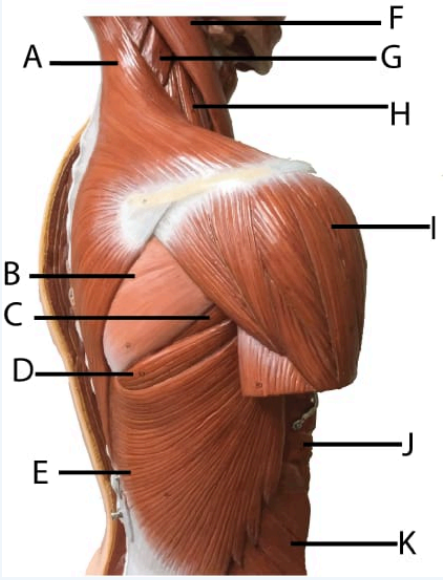

Image Credits

Torso model images by Jennifer Lange are licensed under CC BY-NC-SA 4.0. Labelling by Sofia Elizondo.

Answer Key (click to show/hide answers)

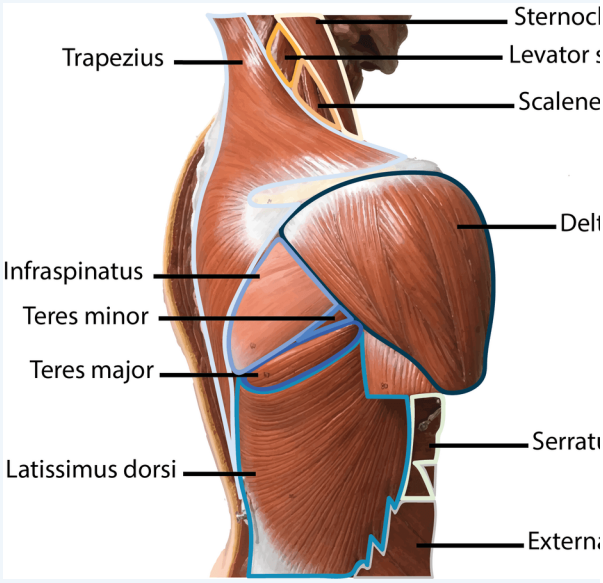

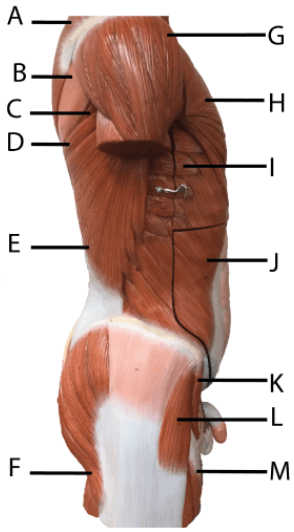

Image Credits

Torso model images by Jennifer Lange are licensed under CC BY-NC-SA 4.0. Labelling by Sofia Elizondo.

Answer Key (click to show/hide answers)

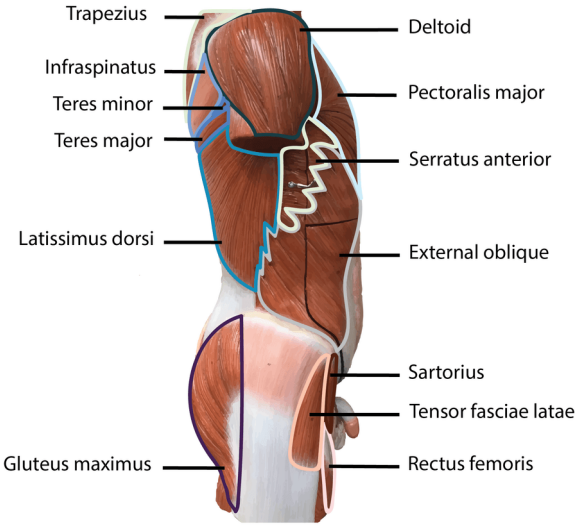

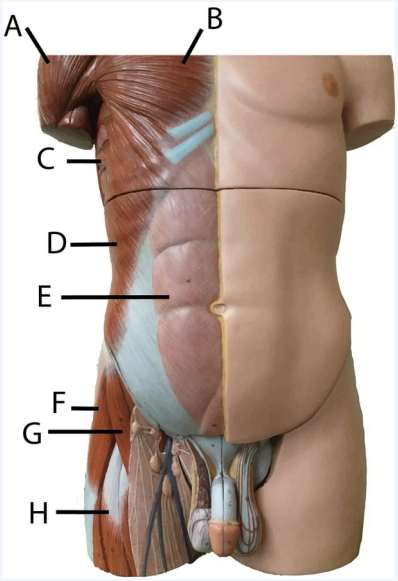

Image Credits

Torso model images by Jennifer Lange are licensed under CC BY-NC-SA 4.0. Labelling by Sofia Elizondo.

Answer Key (click to show/hide answers)

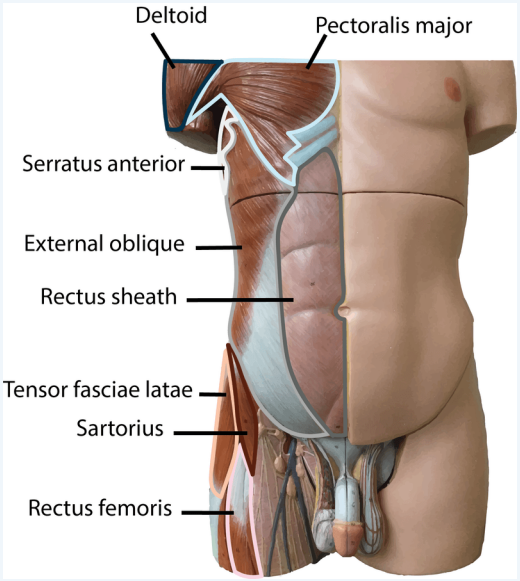

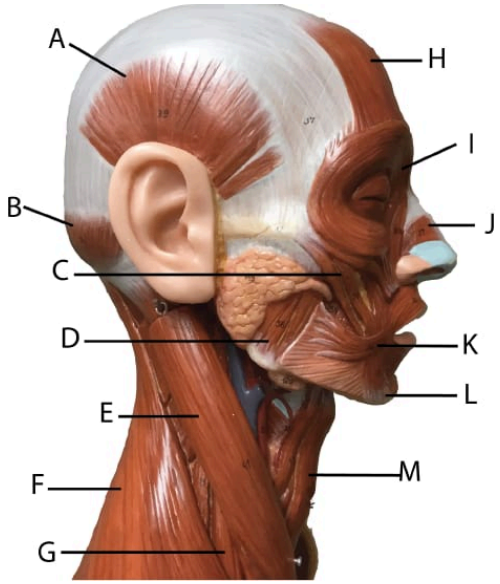

Image Credits

Torso model images by Jennifer Lange are licensed under CC BY-NC-SA 4.0. Labelling by Sofia Elizondo.

Answer Key (click to show/hide answers)

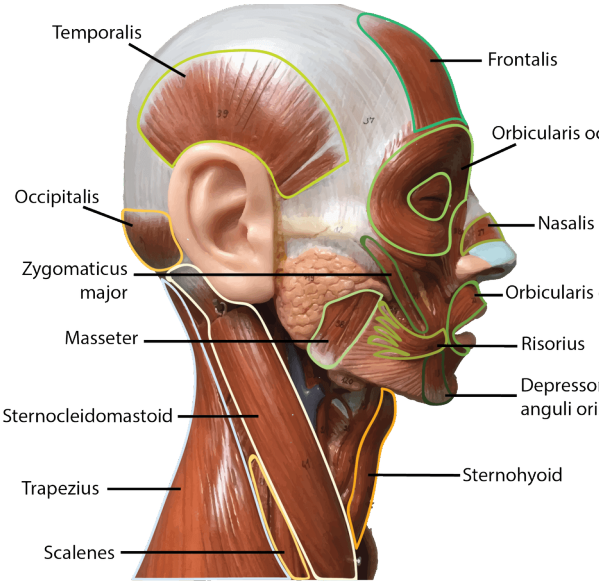

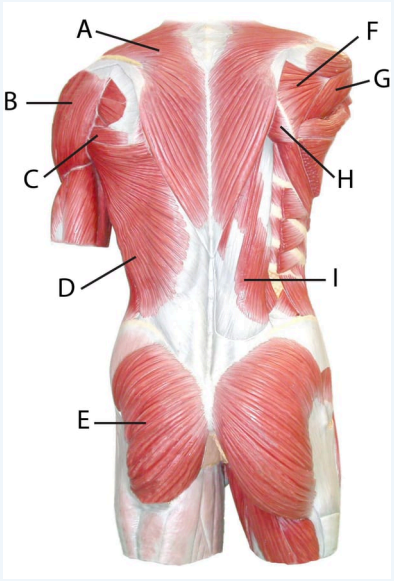

Image Credits

Model images by EUSKALANATO are licensed under CC BY-NC-SA 2.0. Labelling by Jennifer Lange.

Answer Key (click to show/hide answers)

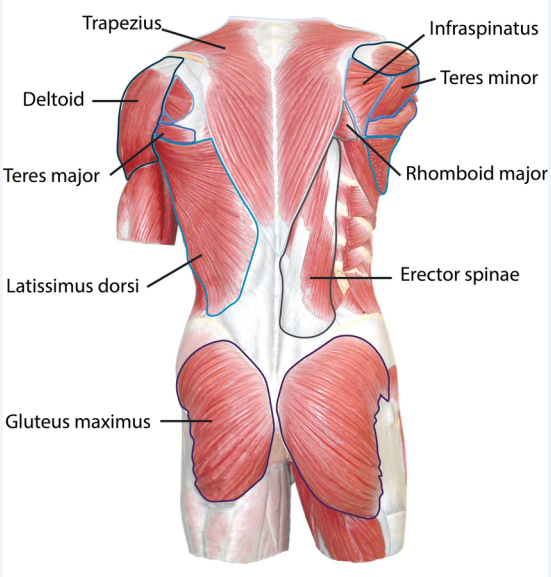

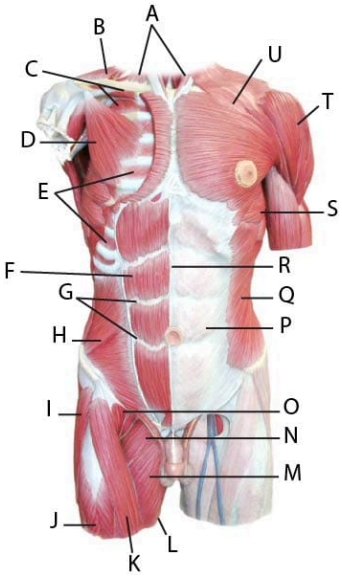

Image Credits

Model images by EUSKALANATO are licensed under CC BY-NC-SA 2.0. Labelling by Jennifer Lange.

Answer Key (click to show/hide answers)

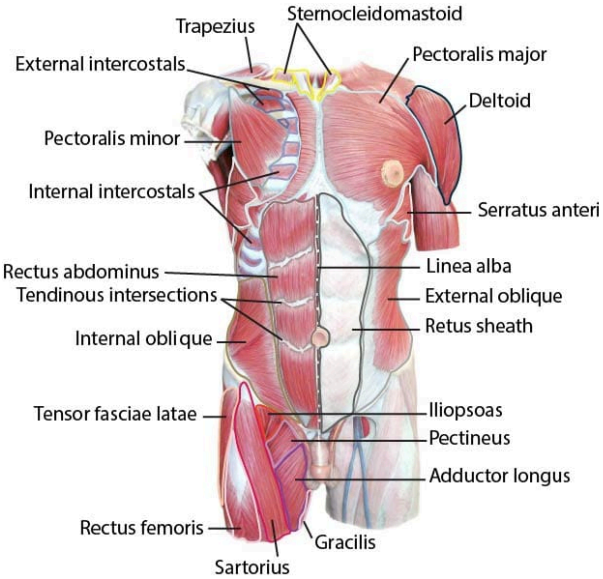

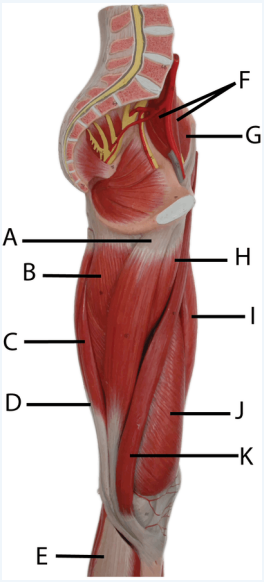

Image Credits

Model images by EUSKALANATO are licensed under CC BY-NC-SA 2.0. Labelling by Sofia Elizondo.

Answer Key (click to show/hide answers)
Medial View

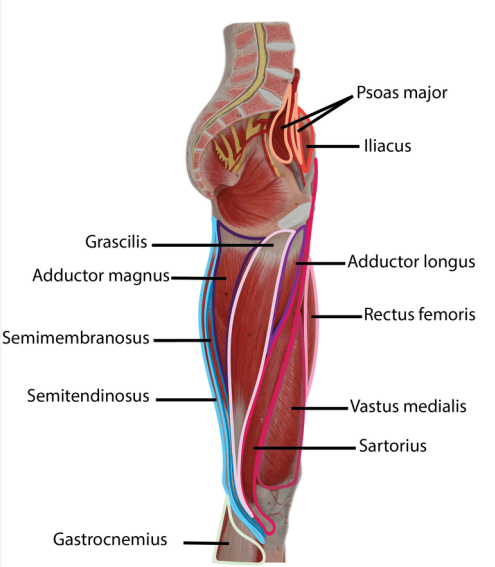

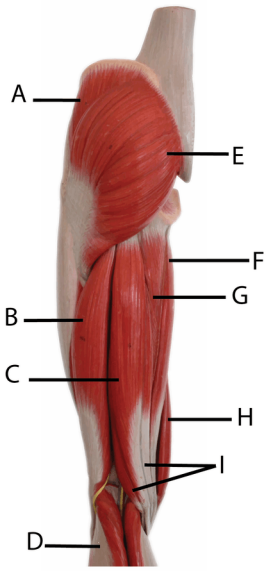

Image Credits

Model images by EUSKALANATO are licensed under CC BY-NC-SA 2.0. Labelling by Sofia Elizondo.

Answer Key (click to show/hide answers)
Posterior View

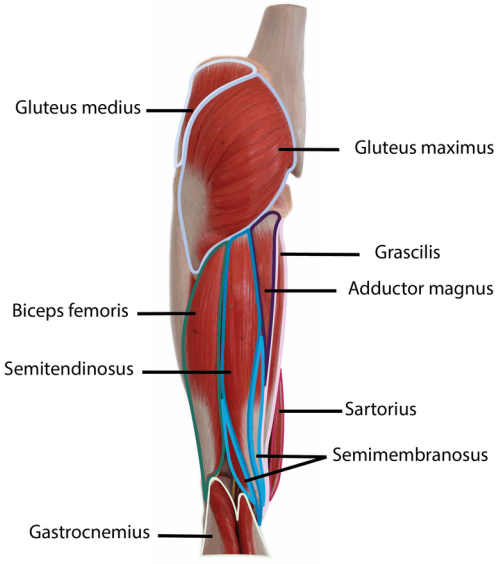

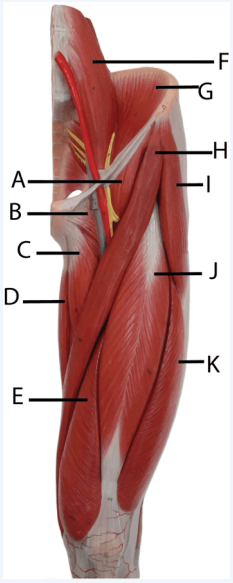

Image Credits

Model images by EUSKALANATO are licensed under CC BY-NC-SA 2.0. Labelling by Sofia Elizondo.

Answer Key (click to show/hide answers)
Anterior View

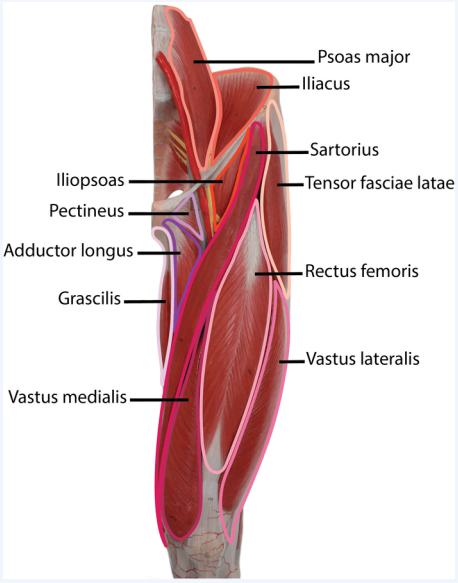

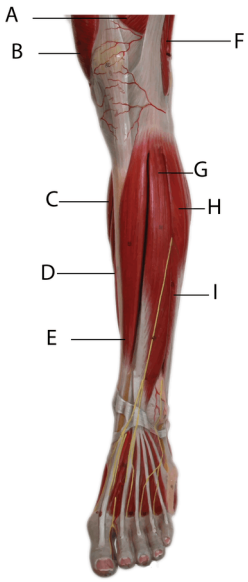

Image Credits

Model images by EUSKALANATO are licensed under CC BY-NC-SA 2.0. Labelling by Sofia Elizondo.

Answer Key (click to show/hide answers)
Anterior View

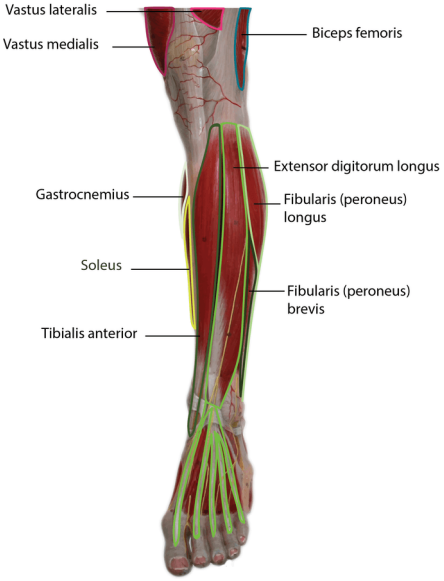

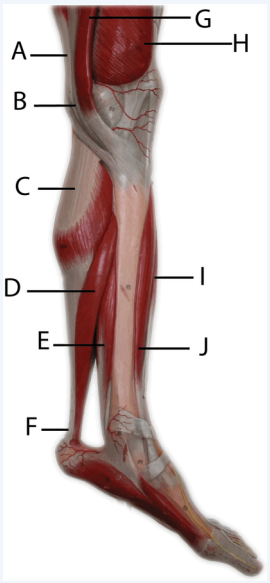

Image Credits

Model images by EUSKALANATO are licensed under CC BY-NC-SA 2.0. Labelling by Sofia Elizondo.

Answer Key (click to show/hide answers)
Medial View

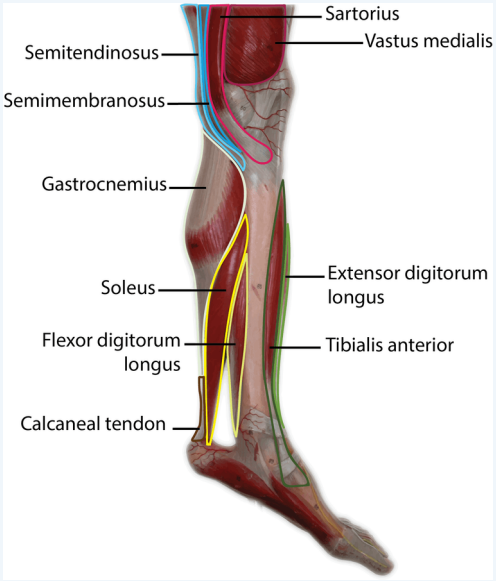

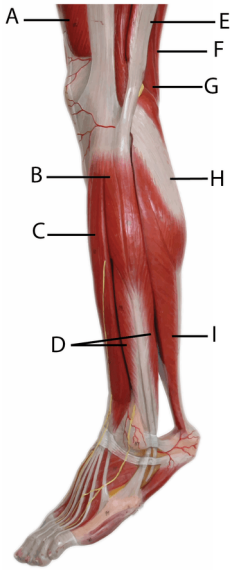

Image Credits

Model images by EUSKALANATO are licensed under CC BY-NC-SA 2.0. Labelling by Sofia Elizondo.

Answer Key (click to show/hide answers)
Lateral View

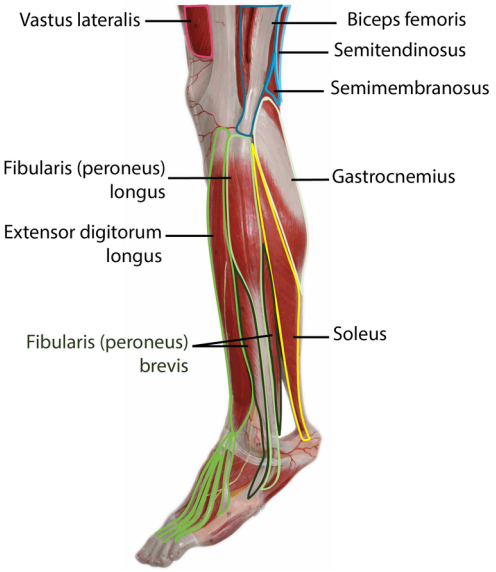

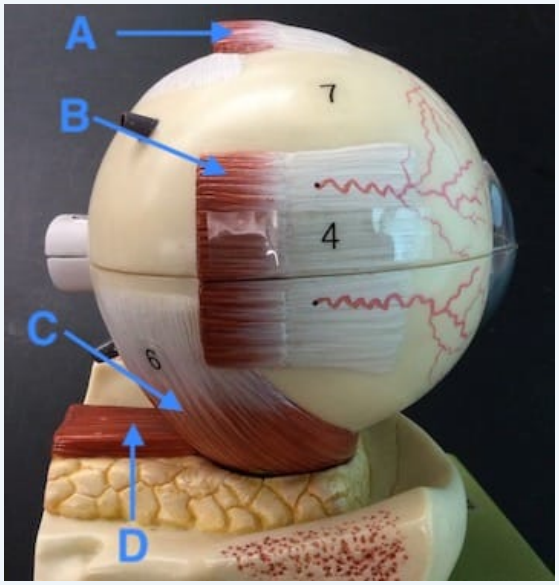

Image Credits

Eye model images by Jennifer Lange are licensed under CC BY-NC-SA 4.0.

Answer Key (click to show/hide answers)

Lateral View

A - superior rectus

B - lateral rectus

C - inferior oblique

D - inferior rectus

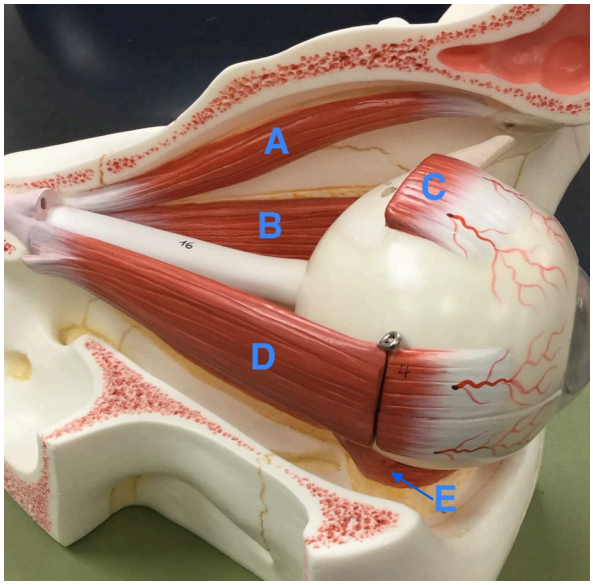

Image Credits

Eye model images by Jennifer Lange are licensed under CC BY-NC-SA 4.0.

Answer Key (click to show/hide answers)

Superolateral View

A - superior oblique

B - medial rectus

C - superior rectus

D - lateral rectus

E - inferior oblique

This page titled 9.8: Anatomical Atlas - Muscular System is shared under a CC BY-NC-SA 4.0 license and was authored, remixed, and/or curated by Jennifer Lange et al..

9.9: Practice Practical- Muscles

Query 9.9.1

This interactive element is not available in this format. Visit the link or scan the QR code to access it online.

View this Interactive Content online

Query 9.9.1

This interactive element is not available in this format. Visit the link or scan the QR code to access it online.

View this Interactive Content online

Query 9.9.1

This interactive element is not available in this format. Visit the link or scan the QR code to access it online.

View this Interactive Content online

Query 9.9.1

This interactive element is not available in this format. Visit the link or scan the QR code to access it online.

View this Interactive Content online

Query 9.9.1

This interactive element is not available in this format. Visit the link or scan the QR code to access it online.

View this Interactive Content online

Query 9.9.1

This interactive element is not available in this format. Visit the link or scan the QR code to access it online.

View this Interactive Content online

Query 9.9.1

This interactive element is not available in this format. Visit the link or scan the QR code to access it online.

View this Interactive Content online

Query 9.9.1

This interactive element is not available in this format. Visit the link or scan the QR code to access it online.

View this Interactive Content online

Query 9.9.1

This interactive element is not available in this format. Visit the link or scan the QR code to access it online.

View this Interactive Content online

Query 9.9.1

This interactive element is not available in this format. Visit the link or scan the QR code to access it online.

View this Interactive Content online

Query 9.9.1

This interactive element is not available in this format. Visit the link or scan the QR code to access it online.

View this Interactive Content online

This page titled 9.9: Practice Practical- Muscles is shared under a CC BY-NC-SA 4.0 license and was authored, remixed, and/or curated by Jennifer Lange et al..

10: NERVOUS SYSTEM AND NERVOUS TISSUE

The nervous system is responsible for controlling much of the body, both through voluntary and involuntary functions. The focus of this chapter is on nervous (neural) tissue composed of neurons and glial cells. Within this chapter, you will look at the functions of the nervous system, its divisions, the characteristics of the cells found in it and how they communicate. Lastly, you will learn how the nervous system develops.

10.1: Introduction to the Nervous System

10.2: Organization and Functions of the Nervous System

10.3: Anatomy of Nervous Tissue

10.4: Synapses

10.5: Development of the Nervous System

10.6: Anatomical Atlas - Nervous Tissue

10.7: Practice Practical - Nervous Tissue

This page titled 10: Nervous System and Nervous Tissue is shared under a CC BY-NC-SA 4.0 license and was authored, remixed, and/or curated by Jennifer Lange et al..

- 11: Nervous System and Nervous Tissue by Whitney Menefee, Julie Jenks, Chiara Mazzasette, and Kim-Leiloni Nguyen is licensed CC BY 4.0.

10.1: Introduction to the Nervous System

Chapter Learning Objectives

After studying this chapter, you will be able to:

- Name the major divisions of the nervous system, both anatomical and functional
- Describe the functional and structural differences between gray matter and white matter structures
- Recognize the structural and functional differences of the types of neurons present in the body
- List the types of glial cells and assign each to the proper division of the nervous system, along with their function(s)
- Distinguish the major functions of the nervous system: sensation, integration, and response
- Describe how neurons communicate with each other and other targets
- Understand the development of the nervous system

The study of the anatomy of the nervous system (called neuroanatomy) started very early on. The first known written record of a study of the anatomy of the human brain is an Egyptian medical document written around 3000 BC. The next major discoveries in neuroanatomy came from the Greek Alcmaeon, who determined that the brain and not the heart controlled the body, and that the senses were dependent on the brain. After Alcmaeon, many scientists, philosophers, and physicians from around the world continued to contribute to the understanding of neuroanatomy. Herophilus and Erasistratus of Alexandria were perhaps the most influential Greek neuroscientists with their studies involving dissecting brains. For several hundred years afterward, with the cultural taboo of dissection, no major progress occurred in neuroscience. However, in the Renaissance human dissections were allowed again, revitalizing the study of neuroanatomy (Figure 10.1.1). The subsequent centuries have produced a great deal of documentation and study of the neural system. However, our current level of understanding is nowhere close to its limit.

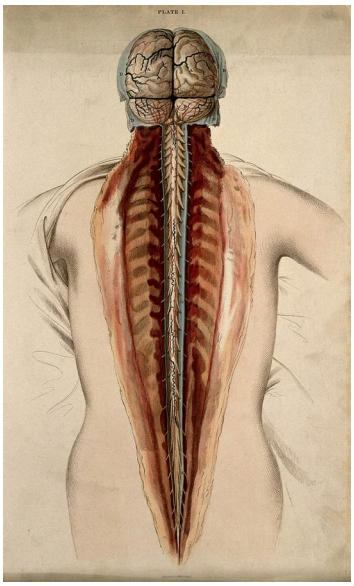

Figure 10.1.1: Dissection of Brain and Spinal Cord. Engraving with colored lines of a dissection of the human brain and spinal cord of the 19th century (Image credit: "Brain and spinal cord: dissection, back view." by W.H. Lizars, Wellcome Library is licensed under CC BY 4.0)

Contributors and Attributions

- OpenStax Anatomy & Physiology (CC BY 4.0). Access for free at https://openstax.org/books/anatomy-and-physiology

This page titled 10.1: Introduction to the Nervous System is shared under a CC BY-NC-SA 4.0 license and was authored, remixed, and/or curated by Jennifer Lange et al..

- 11.1: Introduction to the Nervous System by Whitney Menefee, Julie Jenks, Chiara Mazzasette, and Kim-Leiloni Nguyen is licensed CC BY 4.0.

10.2: Organization and Functions of the Nervous System

By the end of this section, you will be able to:

- Understand the basic structure of a neuron
- Distinguish between gray and white matter and relate their differences to the structure of neurons
- Identify the structural and functional divisions of the nervous system
- Identify the organs of the central and peripheral divisions of the nervous system
- Understand the basic functions and control of the nervous system

The picture you have in your mind of the nervous system probably includes the **brain**, the nervous tissue contained within the cranium in the cranial cavity, and the **spinal cord**, the extension of nervous tissue within the vertebral column. That suggests it is made of two organs—and you may not even think of the spinal cord as an organ—but the nervous system is a very complex structure. Within the brain, many different and separate regions are responsible for many different and separate functions. It is as if the nervous system is composed of many organs that all look similar and can only be differentiated using tools such as the microscope or an electrophysiology apparatus. In comparison, it is easy to see that the stomach is different than the esophagus or the liver, so you can imagine the digestive system as a collection of specific organs. For this reason, you will look at the organization of the nervous tissue first and the structures within it. Then you will look at the structural divisions of the nervous system by regions where the organs are located, and then the functional divisions by the specific functions achieved by the organs within it.

Nervous Tissue

Nervous tissue contains two basic types of cells: neurons and glial cells. A **glial cell** is one of a variety of cells that provide a crucial framework of tissue that supports the neurons and their activities. The **neuron** is the cell type that sends electrical signals throughout the body and both processes and sends motor and sensory information. To describe the functional divisions of the nervous system, it is important to understand the basic structure of a neuron (Figure 10.2.1). Neurons are cells and therefore have a **soma**, or **cell body**, but they also have extensions of the cell; each extension is generally referred to as a **process**. There is one important process that every neuron has called an **axon**, which is the fiber that connects a neuron with its target. Some axons are insulated by a lipid-rich substance called **myelin** that is formed by glial cells. The second type of process that branches off the soma is the **dendrite**. Dendrites are responsible for receiving most of the input from other neurons.

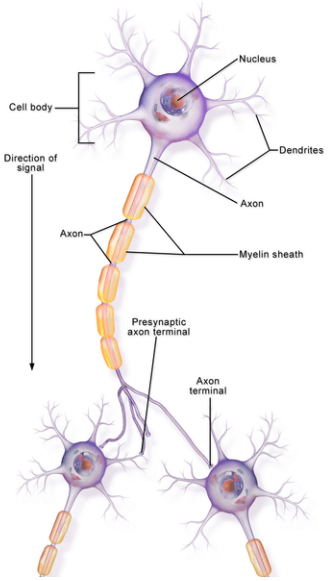

Figure 10.2.1: Basic Structure of a Neuron. Neurons have a soma (or cell body) and processes, which are extensions from the soma that receive or carry information. Processes can be diversified as dendrites which receive information or axon which carries information. The axon shown here is covered by insulating sheaths of myelin. *(Image credit: "Neuron Parts" by BruceBlaus, CC BY-SA 4.0, via Wikimedia Commons.)*

Looking at nervous tissue you can see color differences between the areas: some are white and others are red/pink (if blood is present) or brown/grey (if preserved). there are regions that predominantly contain cell bodies and regions that are largely composed of just axons. Each "color" region contains different neuron parts. The pink/brown/grey areas within nervous system structures are referred to as **gray matter** and these regions contain many cell bodies and dendrites. Those referred to as **white matter** are regions with many axons, particularly axons covered with myelin. Figure 10.2.2 demonstrates the appearance of these regions in a freshly dissected brain. The colors ascribed to these regions are what would be seen in “fresh,” or unstained, nervous tissue. Gray matter is not necessarily gray. It can be pinkish because of blood content, or even slightly tan, depending on how long the tissue has been preserved. But white matter is white because axons are insulated by the lipids of the myelin. Lipids can appear as white (“fatty”) material, much like the fat on a raw piece of chicken or beef. Actually, gray matter may have that color ascribed to it because next to the white matter, it is just darker—hence, gray.

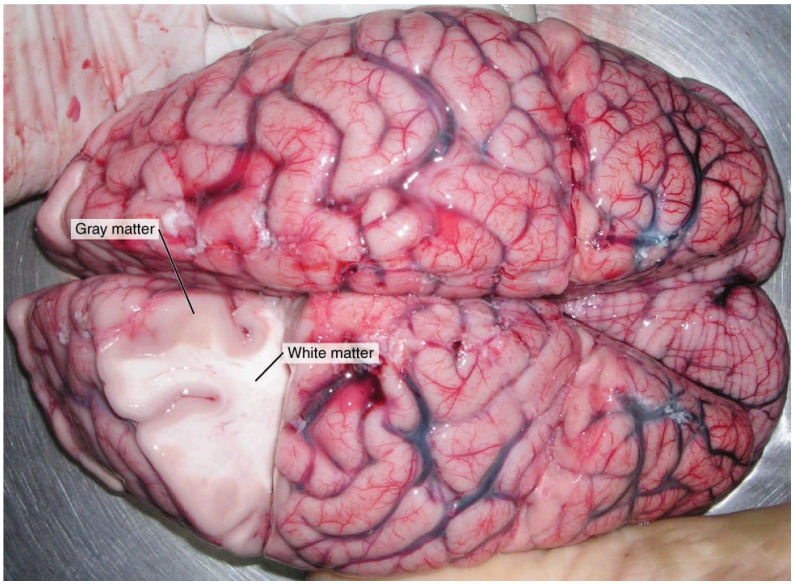

Figure 10.2.2: Gray Matter and White Matter. A brain removed during an autopsy, with a partial section dissected out to show white matter surrounded by gray matter. The gray matter makes up the outer cortex of the brain. *(Image credit: "Human Brain" by Suseno is in the Public Domain / A derivative from the original work.)*

Structural Organization of the Nervous System

The nervous system can be divided into two major regions: the central and peripheral nervous systems. The **central nervous system (CNS)** is composed of the brain and spinal cord, and the **peripheral nervous system (PNS)** is composed of ganglia (structures containing neurons outside of the CNS) and nerves (bundles of axons) (Figure 10.2.3). The brain is contained within the cranial cavity of the skull, and the spinal cord is contained within the vertebral canal of the vertebral column. It is a bit of an oversimplification to say that the CNS is what is inside these two cavities and the peripheral nervous system is outside of them, but that is one way to start to think about it. In actuality, there are some elements of the peripheral nervous system that are within the cranial or vertebral cavities. The peripheral nervous system is so named because it is on the periphery—meaning beyond the brain and spinal cord. Depending on different aspects of the nervous system, the dividing line between central and peripheral is not necessarily universal.

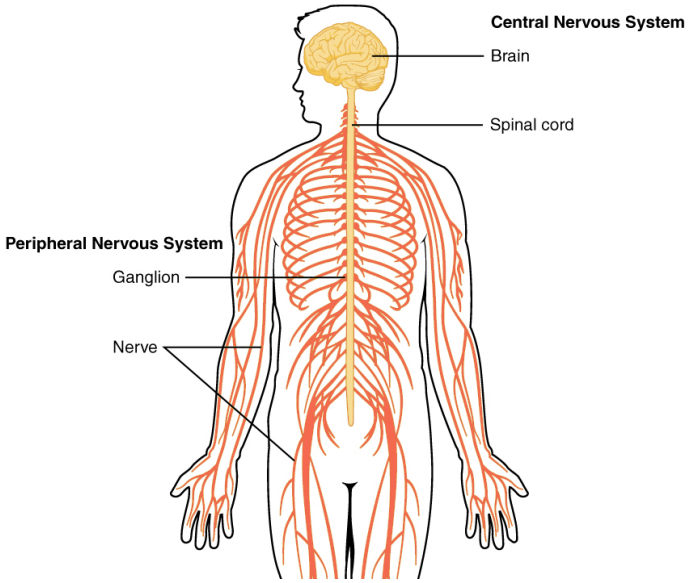

Figure 10.2.3: Structural Divisions of the Nervous System. The structures of the Central Nervous System (CNS) are the brain and spinal cord, located medially within the body. The structures of the Peripheral Nervous System (PNS) are ganglia and nerves. Ganglia are enlarged regions of the nerves that house neuron cell bodies and glial cells within the PNS. *(Image credit: "Structural divisions of the nervous system" by Jennifer Lange is licensed under CC-BY-NC-SA 4.0 , derivative from the original work.)*

The cell bodies or axons of neurons can be located in discrete anatomical structures that are specific to whether the structure is central or peripheral. A localized collection of neuron cell bodies in the CNS is referred to as a **nucleus, cortex, or horn**. In the PNS, a cluster of neuron cell bodies is referred to as a **ganglion**. Terminology applied to bundles of axons also differs depending on location. A bundle of axons, or fibers, found in the CNS is called a **tract** (or column) whereas the same thing in the PNS would be called a **nerve**. There is an important point to make about these terms, which is that they can both be used to refer to the same bundle of axons. The most obvious example of this is the axons that project from the retina of the eye into the brain. Those axons are called the optic nerve as they leave the eye, but when they are inside the cranium, they are referred to as the optic tract. Table 10.2.1 helps to clarify which of these terms apply to the central or peripheral nervous systems. There is a further classification of nerves depending on the location where they leave the central nervous system: **cranial nerves** emerge directly from the brain, while **spinal nerves** exit from different segments of the spinal cord.

	CNS	PNS
Group of Neuron Cell Bodies ***(i.e., gray matter)***	*Nucleus (brain)* *Cortex (brain)* *Horn (spinal cord)*	*Ganglion*
Bundle of Axons ***(i.e., white matter)***	*Tract or Column*	*Nerve*

Table 10.2.1: Name of structures depend on the location.

Functional Organization of the Nervous System

The nervous system can also be divided on the basis of its functions, but structural divisions and functional divisions are different. The CNS and the PNS both contribute to the same functions, but those functions can be attributed to different regions of the brain (such as the cerebral cortex or the hypothalamus) or to different ganglia in the periphery. The problem with trying to fit functional differences into anatomical divisions is that sometimes the same structure can be part of several functions. For example, the optic nerve carries signals from the retina that are either used for the conscious perception of visual stimuli, which takes place in the cerebral cortex, or for the reflexive responses of smooth muscle tissue that are processed through the brainstem.

There are two ways to consider how the nervous system is divided functionally. First, the basic functions of the nervous system are sensation, integration, and response. Secondly, control of the body can be somatic or visceral—divisions that are largely defined by the structures that are involved in the response.

Basic Functions

The nervous system is involved in receiving information about the environment around us**,** and generating responses to that information. Between these inputs and outputs a "decision" needs to be made about how to respond. The process of "thinking" integrates sensory perceptions and higher cognitive functions such as memories, learning, and emotion to produce a response.

Sensation

The first major function of the nervous system is **sensation**—receiving information about the environment to gain input about what is happening outside the body or inside the body. The sensory functions of the nervous system register **stimuli** (singular - stimulus), the presence of a change from homeostasis or a particular event in the environment. The environmental stimuli for taste and smell are chemical substances (molecules, compounds, ions, etc.), for vision is light, for hearing it is sound waves, and for balance is the perception of where your head is in space. These senses are called **special senses** because they have specialized organs to sense the environment. Stimuli inside the body are those that disturb our resting state, for example pain sensations

are perceived by the skin and by internal organs such such as the stomach. Pain, as well as other sensations such as touch and temperature, can occur at any location in the body are called **general senses** or **somatic senses**. Special and general senses receive stimuli that can be perceived consciously, meaning that you are aware of them, or unconsciously. Most stimuli that we are unaware of arise inside the internal organs, such as the stretch of an organ wall or the concentration of certain ions in the blood. These unconscious sensations are called **visceral sensations**. Sensory information is perceived by structures within the Peripheral Nervous System and travels towards the Central Nervous System. This inward direction is called **afferent** (Figure 10.2.4).

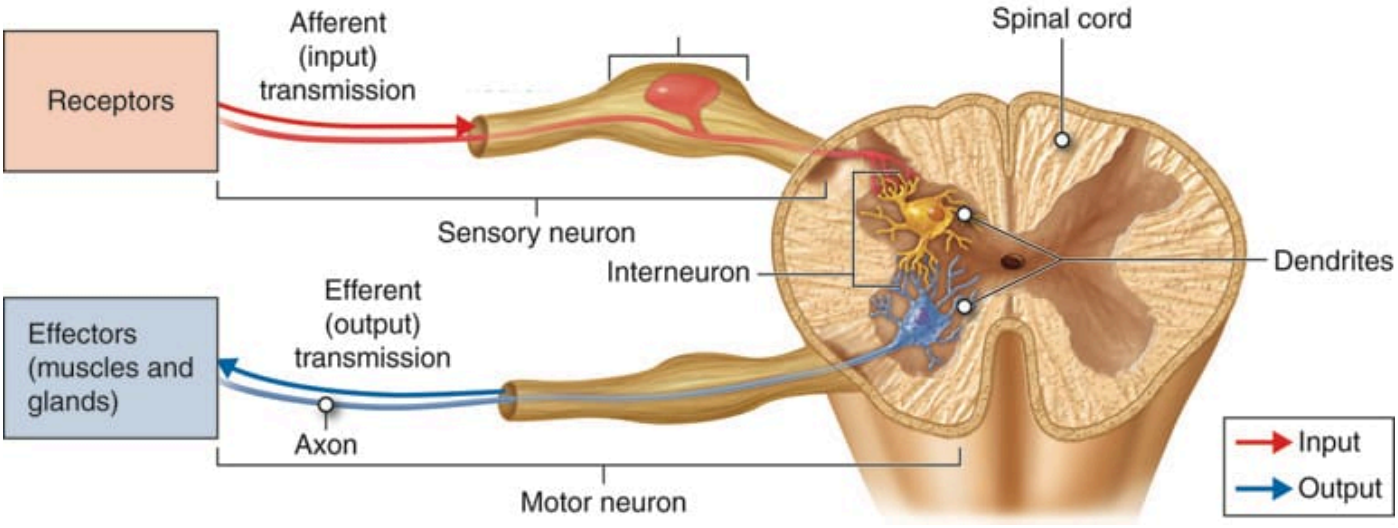

Figure 10.2.4: Sensory information travels along an afferent pathway toward the central nervous system while motor commands travel along an efferent pathway away from the central nervous system. Integration occurs at the interneurons within the spinal cord. *(Image credit: This work by Cenveo is licensed under CC BY 3.0).*

Integration

Stimuli that are received by sensory structures are communicated to the Central Nervous System where the information is processed. Stimuli are compared with, or integrated with, other stimuli, memories of previous stimuli, or the state of a person at a particular time. This leads to the specific response that will be generated. Seeing a baseball pitched to a batter will not automatically cause the batter to swing. The trajectory of the ball and its speed will need to be considered. Maybe the count is three balls and one strike, and the batter wants to let this pitch go by in the hope of getting a walk to first base. Or maybe the batter's team is so far ahead, it would be fun to just swing away.

Response

The nervous system produces a response on the basis of the sensory stimuli. An obvious response would be the movement of muscles, such as withdrawing a hand from a hot stove, but there are broader uses of the term. The nervous system can cause the contraction of all three types of muscle tissue. For example, skeletal muscle contracts to move the skeleton, cardiac muscle is influenced as heart rate increases during exercise, and smooth muscle contracts as the digestive system moves food along the digestive tract. Responses also include the neural control of glands in the body as well, such as the production and secretion of sweat by the merocrine sweat glands found in the skin to lower body temperature. Thus, muscles and glands are the targets of the motor response and they become active when stimulated to carry out the response. For this reason, they are called **effectors**. Responses can be divided into those that are voluntary or conscious (contraction of skeletal muscle) and those that are involuntary or unconscious (contraction of smooth muscles, regulation of cardiac muscle, activation of glands). Voluntary responses are governed by the somatic nervous system and involuntary responses are governed by the autonomic nervous system, which is discussed in the next chapter.

Motor information is generated by the Central Nervous System and travels to the Peripheral Nervous System. This outward direction is also **efferent** (Figure 10.2.4). Afferent and efferent sound similar. One way to remember their differences is using the acronym SAME that stands for Sensory Afferent Motor Efferent.

Controlling the Body

The nervous system can be divided into two parts mostly on the basis of a functional difference in responses. The **somatic nervous system (SNS)** is responsible for conscious perception (somatosensation) and voluntary motor responses (also called somatic responses). These are the things you consciously sense and do. Voluntary motor response means the contraction of skeletal muscle, but those contractions are not always voluntary in the sense that you have to want to perform them. Some somatic motor responses are reflexes, and often happen without a conscious decision to perform them. If your friend jumps out from behind a corner and yells “Boo!” you will be startled and you might scream or leap back. You didn’t decide to do that, and you may not have wanted to give your friend a reason to laugh at your expense, but it is a reflex involving skeletal muscle contractions. Other motor responses become automatic (in other words, unconscious) as a person learns motor skills (referred to as “habit learning” or “procedural memory”) such as walking, chewing and riding a bicycle.

The **visceral nervous sytem (VNS)** is responsible for involuntary control of the body. These are the processes that occur without you thinking about them, they operate automatically behind the scenes to keep you alive. Sensory input for visceral functions can be from sensory structures tuned to external or internal environmental stimuli. The motor output extends to smooth and cardiac muscle as well as to glandular tissue. Because these motor commands operate without CNS conscious control, the visceral motor division is also called the **autonomic nervous system (ANS).** The role of the autonomic system is to regulate the organ systems of the body, which usually means to control homeostasis. Sweat glands, for example, are controlled by the autonomic system. When you are hot, sweating helps cool your body down. That is a homeostatic mechanism. But when you are nervous, you might start sweating also. That is not homeostatic, it is the physiological response to an emotional state.

	Sensation	Integration	Motor Response
Somatic	Conscious perception of environmental changes (light, sounds, molecules in food, movement, temperature, touch, etc) through somatic sensory neurons of PNS	Information processed in brain and spinal cord (CNS)	Voluntary and reflex response via skeletal muscles
Visceral	Unconscious perception of external or internal changes (light, molecules, organ stretch, etc) through visceral sensory neurons in both CNS and PNS	Information processed in brain (particularly hypothalamus and brainstem) and spinal cord (CNS)	Involuntary movement of cardiac muscle, smooth muscle, glands. Also called the ANS.

Table 10.2.2: Basic functions of Somatic and Visceral Divisions of the Nervous System. The basic functions of the nervous system are sensation, integration and motor response (top row). These functions are carried out by all divisions of the nervous system (left column) through different neurons, anatomical regions and targets. What differentiates the somatic nervous system from the visceral nervous system is the ability to perceive and respond to stimuli at the conscious level. The visceral sensory and visceral motor (autonomic) components are unconscious.

Interactive Link

Creeping Weakness

Query 10.2.1

This interactive element is not available in this format. Visit the link or scan the QR code to access it online.

View this Interactive Content online

EVERYDAY CONNECTION: How Much of Your Brain Do You Use?

Have you ever heard the claim that humans only use 10 percent of their brains? Maybe you have seen an advertisement on a website saying that there is a secret to unlocking the full potential of your mind—as if there were 90 percent of your brain sitting idle, just waiting for you to use it. If you see an ad like that, don't click. It isn't true.

An easy way to see how much of the brain a person uses is to take measurements of brain activity while performing a task. An example of this kind of measurement is functional magnetic resonance imaging (fMRI), which generates a map of the most active areas and can be generated and presented in three dimensions (Figure 10.2.4). This procedure is different from the standard MRI technique because it is measuring changes in the tissue in time with an experimental condition or event.

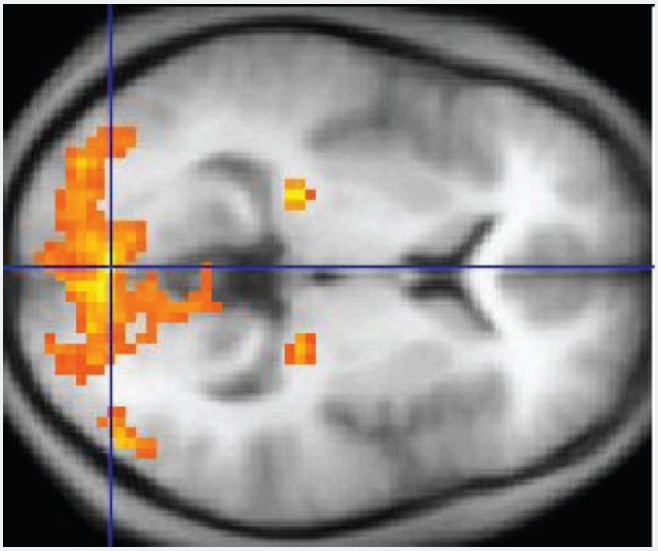

Figure 10.2.4: Functional Magnetic Resonance Imaging (fMRI) map. This imaging represents a transverse plane of the brain with the posterior side on the left and anterior side on the right. The orange areas represent highly active regions. In this particular example, the fMRI map shows activation of the visual cortex in response to visual stimuli. *(Image credit: "1206 FMRI" by OpenStax is licensed under CC BY 4.0)*

The underlying assumption is that active nervous tissue will have greater blood flow. By having the subject perform a visual task, activity all over the brain can be measured. Consider this possible experiment: the subject is told to look at a screen with a black dot in the middle (a fixation point). A photograph of a face is projected on the screen away from the center. The subject has to look at the photograph and decipher what it is. The subject has been instructed to push a button if the photograph is of someone they recognize. The photograph might be of a celebrity, so the subject would press the button, or it might be of a random person unknown to the subject, so the subject would not press the button.

In this task, visual sensory areas would be active, integrating areas would be active, motor areas responsible for moving the eyes would be active, and motor areas for pressing the button with a finger would be active. Those areas are distributed all around the brain and the fMRI images would show activity in more than just 10 percent of the brain (some evidence suggests that about 80 percent of the brain is using energy—based on blood flow to the tissue—during well-defined tasks similar to

the one suggested above). This task does not even include all of the functions the brain performs. There is no language response, the body is mostly lying still in the MRI machine, and it does not consider the autonomic functions that would be ongoing in the background.

Concept Review

Nervous tissue is composed of neurons and glial cells. The basic structure of a neuron is composed of a soma (cell body) and processes. Processes can be classified in dendrites, which receive information, and axons, which carry information. The axons are partially covered by a lipid-rich sheath called myelin. Due to the high fat content of myelin, axons covered in myelin look white. Thus, the nervous tissue can also be described as gray matter and white matter on the basis of its appearance in unstained tissue. Cell bodies of neurons cluster in regions called nuclei or ganglia, depending on their location. Axons of neurons also tend to bundle up in structures called tracts (columns) or nerves (fibers), depending on their location.

The nervous system can be separated into divisions on the basis of anatomy and physiology. The anatomical divisions are the central nervous system (CNS) and peripheral nervous system (PNS). The CNS is composed of the brain and spinal cord. In the CNS, there are localized collection of neuron cell bodies called nuclei within the gray matter and bundles of axons called tracts within the white matter. The PNS is made of collections of neuron cell bodies called ganglia, and bundle of axons called nerves. A single axon can be part of a nerve when in the PNS, and then become a tract when crossing the CNS.

Functionally, the nervous system can be divided into those regions that are responsible for sensation, those that are responsible for integration, and those that are responsible for generating responses. All of these functional areas are found in both the central and peripheral anatomy. The nervous system can also be divided on the basis of how it controls the body. The somatic nervous system (SNS) is responsible for functions that result in moving skeletal muscles. Any sensory or integrative functions that result in the movement of skeletal muscle would be considered somatic. The autonomic nervous system (ANS) is responsible for functions that affect cardiac or smooth muscle tissue, or that cause glands to produce their secretions. Autonomic functions are distributed between central and peripheral regions of the nervous system. The sensations that lead to autonomic functions can be the same sensations that are part of initiating somatic responses. Somatic and autonomic integrative functions may overlap as well. A special division of the nervous system is the enteric nervous system, which is responsible for controlling the digestive organs. Parts of the autonomic nervous system overlap with the enteric nervous system. The enteric nervous system is exclusively found in the periphery because it is the nervous tissue in the organs of the digestive system.

Review Questions

Query 10.2.2

This interactive element is not available in this format. Visit the link or scan the QR code to access it online.

View this Interactive Content online

Critical Thinking Questions

Query 10.2.3

This interactive element is not available in this format. Visit the link or scan the QR code to access it online.

View this Interactive Content online

Query 10.2.4

This interactive element is not available in this format. Visit the link or scan the QR code to access it online.

View this Interactive Content online

Glossary

Query 10.2.5

This interactive element is not available in this format. Visit the link or scan the QR code to access it online.

View this Interactive Content online

Contributors and Attributions

- OpenStax Anatomy & Physiology (CC BY 4.0). Access for free at https://openstax.org/books/anatomy-and-physiology

This page titled 10.2: Organization and Functions of the Nervous System is shared under a CC BY-NC-SA 4.0 license and was authored, remixed, and/or curated by Jennifer Lange et al..

- 11.2: Organization and Functions of the Nervous System by Whitney Menefee, Julie Jenks, Chiara Mazzasette, and Kim-Leiloni Nguyen is licensed CC BY 4.0.

10.3: Anatomy of Nervous Tissue

By the end of this section, you will be able to:

- Describe the basic structure of a neuron
- Identify the different types of neurons based on their structure and function
- List the glial cells of the CNS and describe their function
- List the glial cells of the PNS and describe their function
- Describe the process of myelination and axon regeneration

Nervous tissue is composed of two types of cells: **neurons** and **glia**, as shown in Figure 10.3.1. Neurons are the primary type of cell that most anyone associates with the nervous system. They are responsible for the computation and communication that the nervous system provides. They are electrically active and release chemical signals to target cells. Glial cells, or glia, or neuroglia, are known to play a crucial supporting role in nervous tissue. Ongoing research pursues an expanded role that glial cells play in signaling, but neurons are still considered the basis of this function. Neurons are important, but without glial support they would not be able to perform their function.

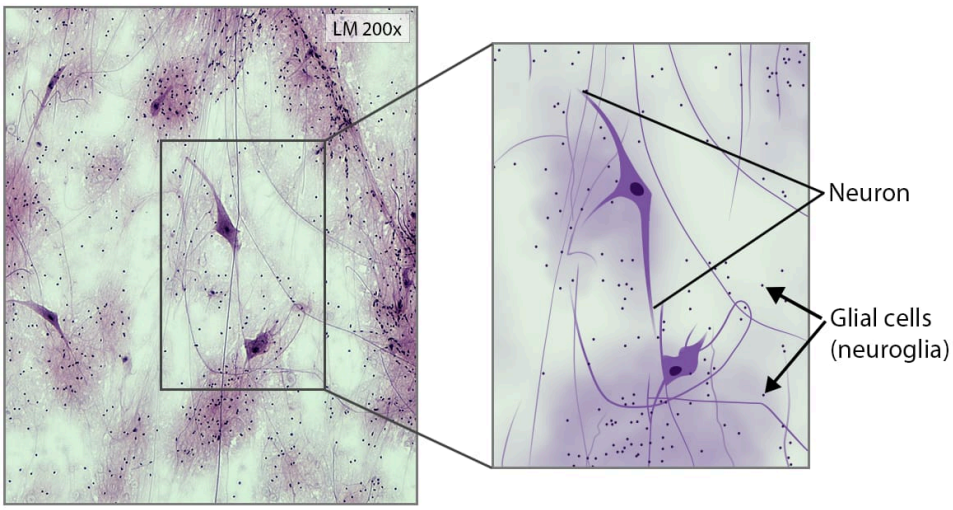

Figure 10.3.1: Nervous Tissue. A small chunk of tissue from the spinal cord was spread on a microscope slide to show neurons and glial cells. Glial cells are smaller and in larger quantities than neurons. The neuron shown is large and has multiple processes coming out of the soma. *(Image credit: "Nervous Tissue Cells" by Jennifer Lange, illustration by Claire McGuire is licensed under CC-BY-NC-SA 4.0. Micrograph provided by Berkshire Community College Bioscience Image Library is in the Public Domain.)*

Neurons

Neurons are the cells that are characteristic of nervous tissue. They are large cells with a high metabolic rate. They depend on a continuous and abundant supply of oxygen and glucose. Some neurons live an entire lifespan while others are replaced within days. Neurons do not typically undergo mitosis, thus they are not able to divide and produce new neurons. Only certain areas of the brain and the sense organ of smell house mitotic neurons. They are responsible for the electrical signals that communicate information about sensations, and that produce movements in response to those stimuli, along with inducing thought processes within the brain. An important part of the function of neurons is in their structure, or shape. The three-dimensional shape of these cells makes the immense numbers of connections within the nervous system possible.

Parts of a Neuron

As you learned in Chapter 3, the main part of a neuron is the **cell body**, which is also known as the **soma** (soma = "body"). The cell body contains the nucleus and most of the major organelles. What makes neurons special is that they have many extensions of their cell membranes, which are generally referred to as **processes**. The two types of processes are axons and dendrites. Neurons are usually described as having one, and only one, **axon**—a fiber that emerges from the cell body and projects to target cells. That single axon can branch repeatedly to communicate with many target cells. It is the axon that propagates the nerve impulse, carrying the electrical signal way from the cell body and to one or more cells. Where the axon emerges from the cell body, there is a special region referred to as the **axon hillock**. This is a tapering of the cell body toward the axon fiber and it is the location where the outgoing electrical signal is generated. The other processes of the neuron are **dendrites**, which receive information from other neurons at specialized areas of contact called **synapses**. The dendrites are usually highly branched processes, providing locations for other neurons to communicate with the cell. Information flows through a neuron from the dendrites, across the cell body, and down the axon. Figure 10.3.2 shows the relationship of these parts to one another.

Many axons are wrapped by an insulating substance called **myelin**, which is actually made of glial cells. Myelin acts as insulation much like the plastic or rubber that is used to insulate electrical wires. A key difference between myelin and the insulation on a wire is that there are gaps in the myelin covering of an axon. Each gap is called a **neurofibril node** (or **node of Ranvier)**. These gaps are exchange points for ions that allow electrical signals travel down the axon. At the end of the axon is the **axon (synaptic) terminal**, where there are usually several branches extending toward the target cell, each of which ends in an enlargement called a **synaptic knob**. These knobs are what make the connection with the target cell at the synapse.

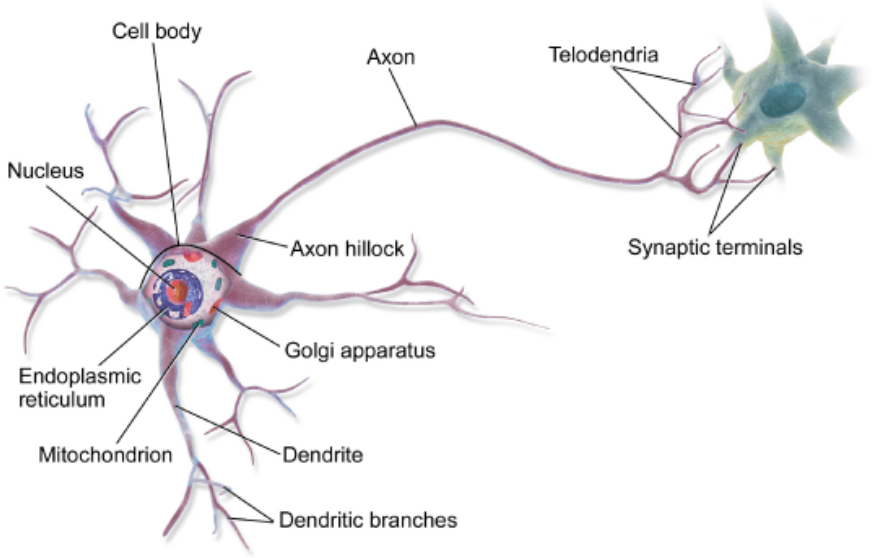

Figure 10.3.2: Parts of a Neuron. A neuron has a soma (cell body) from which processes emerge. The processes that receive information are called dendrites while the process that carry the information from the soma is called the axon. Neurons have only one axon that emerges from the axon hillock. Near its terminus the axon splits to form multiple telodendria that end in synaptic terminals. *(Image credit: "Multipolar Neuron" by BruceBlaus is licensed under CC BY 3.0, via Wikimedia Commons.)*

Types of Neurons

There are many neurons in the nervous system—a number in the trillions. And there are many different types of neurons. They can be classified by both their structure and their function. Structural classification depends on the number of processes attached to the cell body: one, two, or multiple (Figure 10.3.3). A few neurons do not have an axon, called anaxonic, and they operate using a different type of electrical signaling. The functional classification depends on which function the neuron is carrying out: sensation, integration, or motor.

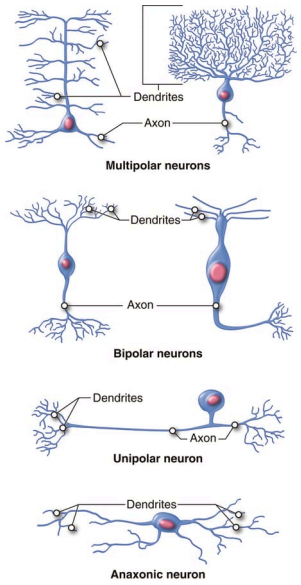

Figure 10.3.3: Neuron Classification by Structure. Unipolar neurons have one process emerging from the soma which contains both the axon and dendrites. Bipolar neurons have two processes emerging from the soma: one is an axon and the other is a dendrite. Multipolar neurons have more than two processes emerging from the soma: one is an axon and two or more other are dendrites. Some neurons do not have an axon (anaxonic)! *(Image credit: This work by Cenveo is licensed under CC BY 3.0).*

Unipolar cells have only one process emerging from the cell. True unipolar cells are only found in invertebrate animals, so the unipolar cells in humans are more appropriately called "pseudo-unipolar" cells. Invertebrate unipolar cells do not have dendrites. Human unipolar cells have an axon that emerges from the cell body, but it splits so that the axon can extend along a very long distance. At one end of the axon are dendrites, and at the other end, the axon forms synaptic connections with a target. Unipolar cells are exclusively **sensory neurons** and have two unique characteristics. First, their dendrites are receiving sensory information, sometimes directly from the stimulus itself, as is the case for sensory neurons perceiving pressure, temperature change, touch, or pain from the skin. Secondly, the cell bodies of unipolar neurons are always found in ganglia. Sensory reception is a peripheral function (those dendrites are in the periphery, perhaps in the skin) so the cell body is in the periphery, though closer to the CNS in a ganglion. The axon projects from the dendrite endings, past the cell body in a ganglion, and into the central nervous system.

Bipolar cells have two processes, which extend from each end of the cell body, opposite to each other. One is the axon and one the dendrite. Bipolar cells are not very common. They are found mainly in the olfactory epithelium (where smell stimuli are sensed), and as part of the retina, and thus are sensory neurons.

Multipolar neurons are all of the neurons that are not unipolar or bipolar. They have one axon and two or more dendrites (usually many more). With the exception of the unipolar sensory ganglion cells, and the two specific bipolar cells mentioned above, all other neurons are multipolar. Multipolar neurons can have multiple functions. Multipolar neurons can be **motor neurons** which carry commands from the brain and spinal cord to muscles and glands. Motor neurons are located in the brain, spinal cord or autonomic ganglia. Multipolar neurons can also be classified as **interneurons** which constitute the majority of neurons. These neurons carry out integrative functions (such as retrieve, process and store information) and facilitate communication between sensory and motor neurons. Interneurons are found in the brain and spinal cord.

Certain neurons in the olfactory system and in the eye do not conform to the standard model of "one, and only one" axon. A rare type of neuron, called an **anaxonic neuron** because it has no axon (an- = "without") or the axon cannot be differentiated from the dendrites. Anaxonic neurons are very small, and if you look through a microscope at the standard resolution used in histology (approximately 400X to 1000X total magnification), you will not be able to distinguish any process specifically as an axon or a dendrite. These neurons serve as local modulators.

Neurons can also be classified on the basis of where they are found, who found them, what they do, or even what chemicals they use to communicate with each other. Some neurons referred to in this section on the nervous system are named on the basis of those sorts of classifications (Figure 10.3.4). For example, a multipolar neuron that has a very important role to play in a part of the brain called the cerebellum is known as a Purkinje (commonly pronounced per-KIN-gee) cell. It is named after the anatomist who discovered it (Jan Evangilista Purkinje, 1787–1869).



Figure 10.3.4: Special Neuron Classifications. Types of neurons are named on the basis of specific criteria are: (left) the Purkinje cell in the cerebellum (was named after the scientist who originally described it) and (right)) the pyramidal cell of the cerebral cortex has a cell body that is shaped like a pyramid *(Image credit: Classic drawings of neurons by Ramon y Cajal, Internet Archive Book Images, No restrictions, via Wikimedia Commons.)*

Glial Cells

Glial cells, or neuroglia or simply glia, are the other type of cell found in nervous tissue. They are considered to be supporting cells, and many functions are directed at helping neurons complete their function for communication. The name glia comes from the Greek word that means “glue,” and was coined by the German pathologist Rudolph Virchow, who wrote in 1856: “This connective substance, which is in the brain, the spinal cord, and the special sense nerves, is a kind of glue (neuroglia) in which the nervous elements are planted.” Today, research into nervous tissue has shown that there are many deeper roles that these cells play. And research may find much more about them in the future.

There are six types of glial cells. Four of them are found in the CNS and two are found in the PNS. Table 10.3.1 outlines some common characteristics and functions.

Table 10.3.1: Glial Cell Types by Location and Basic Function.

CNS glia	PNS glia	Basic function
Astrocyte	Satellite cell	Structural and physiological support of the nervous tissue Form the blood-brain barrier (BBB)
Oligodendrocyte	Neurolemmocyte (Schwann cell)	Insulation, myelination
Microglia	-	Immune surveillance and phagocytosis
Ependymal cell	-	Creating and circulating CSF

Glial Cells of the CNS

One cell providing support to neurons of the CNS is the **astrocyte**, so named because it appears to be star-shaped under the microscope (astro- = "star"). Astrocytes have many processes extending from their main cell body (not axons or dendrites like neurons, just cell extensions). Those processes extend to interact with neurons, blood vessels, or the connective tissue covering the CNS that is called the pia mater (Figure 10.3.6). Generally, they are supporting cells for the neurons in the central nervous system. Some ways in which they support neurons in the central nervous system are: 1) forming a structural network that strengthens the nervous tissue; 2) maintaining the homeostasis of signaling molecules, water and ions in the extracellular space; 3) providing an energy storage; 4) defending the nervous tissue from oxidative stress; 5) reacting to tissue damage and replacing dead neurons; and 6) assisting neuronal development in the fetal brain. Another important role of astrocytes in the CNS is the contribution to the **blood-brain barrier (BBB)**. The blood-brain barrier (Figure 10.3.5) is a physiological barrier that keeps many substances that circulate in the rest of the body from getting into the central nervous system, restricting what can cross from circulating blood into the CNS. Nutrient molecules, such as glucose or amino acids, can pass through the BBB, but other molecules cannot. This actually causes problems with drug delivery to the CNS. Pharmaceutical companies are challenged to design drugs that can cross the BBB as well as have an effect on the nervous system. Like a few other parts of the body, the brain has a privileged blood supply. Very little can pass through by diffusion. Most substances that cross the wall of a blood vessel into the CNS must do so through an active transport process. Because of this, only specific types of molecules can enter the CNS. Glucose—the primary energy source—is allowed, as are amino acids. Water and some other small particles, like gases and ions, can enter. But most everything else cannot, including white blood cells, which are one of the body's main lines of defense. While this barrier protects the CNS from exposure to toxic or pathogenic substances, it also keeps out the cells that could protect the brain and spinal cord from disease and damage. The BBB also makes it harder for pharmaceuticals to be developed that can affect the nervous system. Aside from finding efficacious substances, the means of delivery is also crucial.

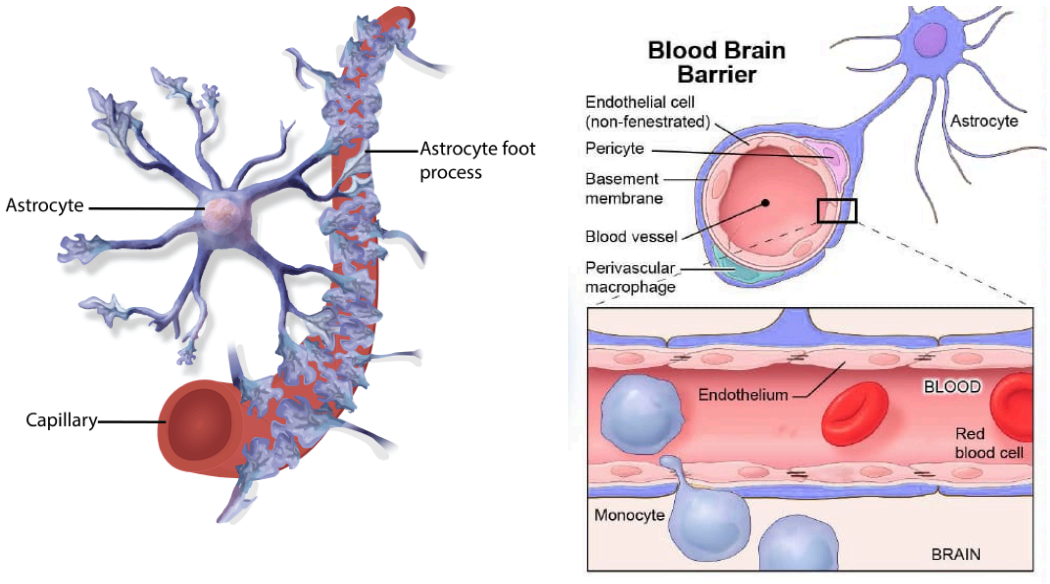

Figure 10.3.5: Blood-Brain Barrier. The foot processes of the astrocytes cover the capillaries in the brain. Having this additional layer makes passage from the blood to the brain more difficult, but immune cells such as monocytes can pass through. *(Image credits: "Astrocyte with Foot Processes" by Sofia Elizondo is licensed under CC-BY-NC-SA 4.0, modification of image by BruceBlaus; "Blood Brain Barrier" by Jennifer Lange is licensed under CC-BY-NC-SA 4.0, modification of image by NIH Medical Arts.)*

Also found in CNS tissue is the **oligodendrocyte**, sometimes called just "oligo," which is the glial cell type that insulates axons in the CNS (Figure 10.3.6). The name means "cell of a few branches" (oligo- = "few"; dendro- = "branches"; -cyte = "cell"). There are a few processes that extend from the cell body. Each one reaches out and surrounds an axon to insulate it in myelin. One oligodendrocyte will provide the myelin for multiple axon segments, either for the same axon or for separate axons. The function of myelin will be discussed below.

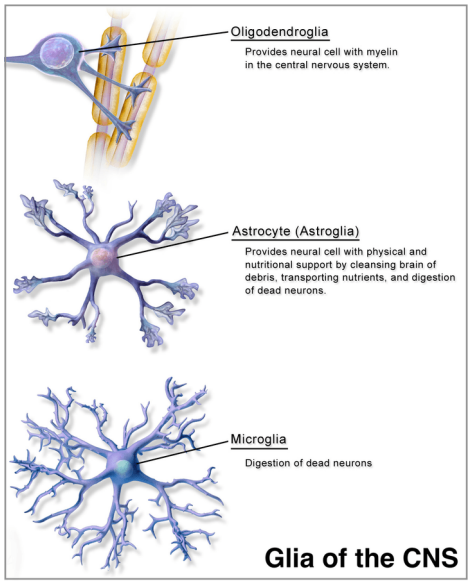

Figure 10.3.6: Glial Cells of the CNS. Astrocytes form a barrier (blood-brain barrier) between the capillaries and the nervous tissue to protect it. Microglial cells act as defenders of the nervous tissue. Finally, oligodendrocytes wrap around multiple axons to insulate them. *(Image credit: "Glia of the CNS" by BruceBlaus, CC BY-SA 4.0, via Wikimedia Commons)*

Microglia are, as the name implies, smaller than most of the other glial cells (Figure 10.3.6). Ongoing research into these cells, although not entirely conclusive, suggests that they may originate as white blood cells, called macrophages, that become part of the CNS during early development. While their origin is not conclusively determined, their function is related to what macrophages do in the rest of the body. When macrophages encounter diseased or damaged cells in the rest of the body, they ingest and digest those cells or the pathogens that cause disease. Microglia are the cells in the CNS that can do this in normal, healthy tissue, and they are therefore also referred to as CNS-resident macrophages.

The **ependymal cell** is a glial cell that filters blood to make **cerebrospinal fluid (CSF)**, the fluid that circulates through the CNS. Because of the privileged blood supply inherent in the BBB, the extracellular space in nervous tissue does not easily exchange components with the blood. Ependymal cells line each **ventricle**, one of four central cavities that are remnants of the hollow center of the neural tube formed during the embryonic development of the brain. The **choroid plexus** is a specialized structure in the ventricles where ependymal cells come in contact with blood vessels and filter and absorb components of the blood to produce cerebrospinal fluid. Because of this, ependymal cells can be considered a component of the BBB, or a place where the CSF is actively secreted. These glial cells appear similar to epithelial cells, making a single layer of cells with little intracellular space and tight connections between adjacent cells. They also have cilia on their apical surface to help move the CSF through the ventricular space. The relationship of these glial cells to the structure of the CNS is seen in Figure 10.3.7.

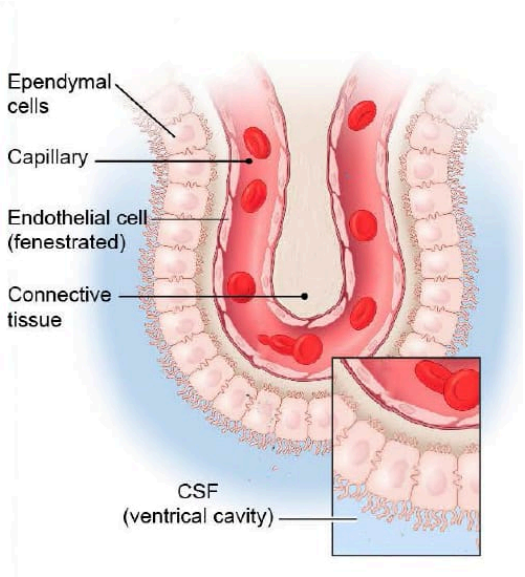

Figure 10.3.7: Ependymal Cells. The ependymal cells cover specialized capillaries in brain's fluid filled spaces. They filter the blood to produce, and then circulate, cerebrospinal fluid (CSF). *(Image credit: "Ependymal Cells - Blood-CSF Barrier" by Jennifer Lange is licensed under CC-BY-NC-SA 4.0, modification of image by NIH Medical Arts.)*

Glial Cells of the PNS

One of the two types of glial cells found in the PNS is the **satellite cell**. Satellite cells are found in sensory and autonomic ganglia, where they surround the cell bodies of neurons. This accounts for the name, based on their appearance under the microscope. They provide support, performing similar functions in the periphery as astrocytes do in the CNS—except, of course, for establishing the BBB.

The second type of glial cell is the **Schwann cell (neurolemmocyte)**, which insulate axons with myelin in the periphery. Schwann cells are different than oligodendrocytes, in that a Schwann cell wraps around a portion of only one axon segment and no others. Oligodendrocytes have processes that reach out to multiple axon segments, whereas the entire Schwann cell surrounds just one axon segment. The nucleus and cytoplasm of the Schwann cell are on the edge of the myelin sheath (Figure 10.3.8).

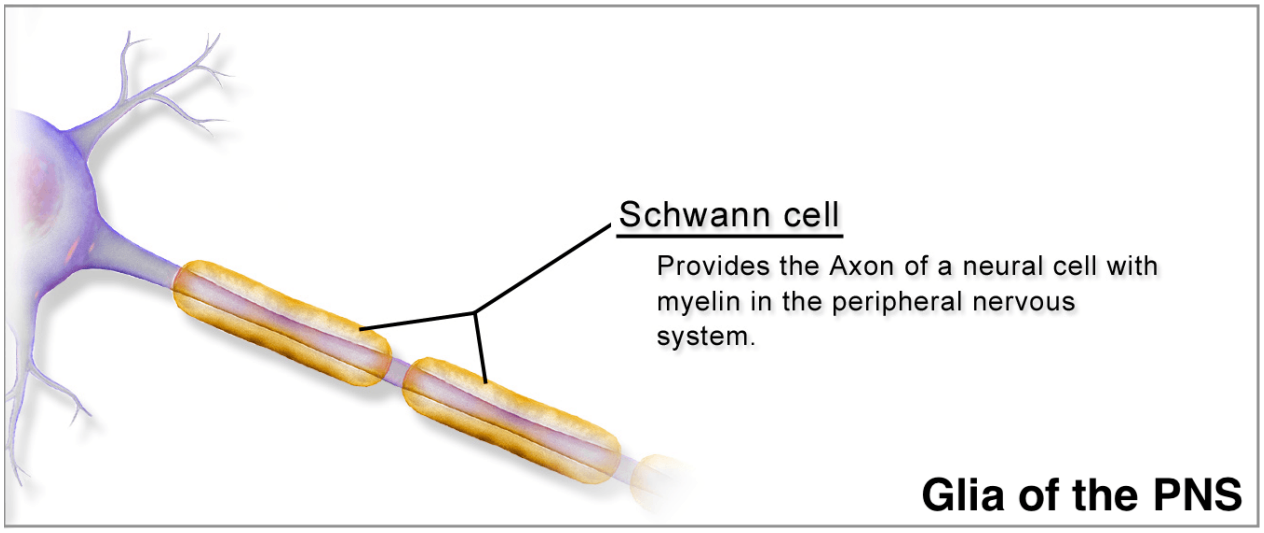

Figure 10.3.8: Glial Cells of the PNS. Satellite cells are wrapped around a unipolar neuron of a peripheral ganglion to support and protect it. Schwann cells are wrapped onto the neuron's axon to insulate it with their myelin sheath. *(Image credit: "Glia of the PNS" by BruceBlaus, CC BY-SA 4.0, via Wikimedia Commons.)*

DISORDERS OF THE...

Glial cells: Gliomas

Glioma is a type of tumor that occurs in the glial cells of the brain or spinal cord (Figure 10.3.9). Remember that tumor begins when the cell loses control over the checkpoints of mitosis and start proliferating excessively. Since neurons do not go under mitosis and can't produce new neurons, the only cells undergoing mitosis in the nervous system are the glial cells. Three types of glial cells can produce tumors. Gliomas are classified according to the type of glial cell involved in the tumor, as well as the tumor's genetic features, which can help predict how the tumor will behave over time and the treatments most likely to work. Types of glioma include:

- Astrocytomas, involving astrocytes
- Ependymomas, involving ependymal cells
- Oligodendrogliomas, involving oligodendrocytes

A glioma can affect the brain function and be life-threatening depending on its location and rate of growth. Gliomas are one of the most common types of primary brain tumors.

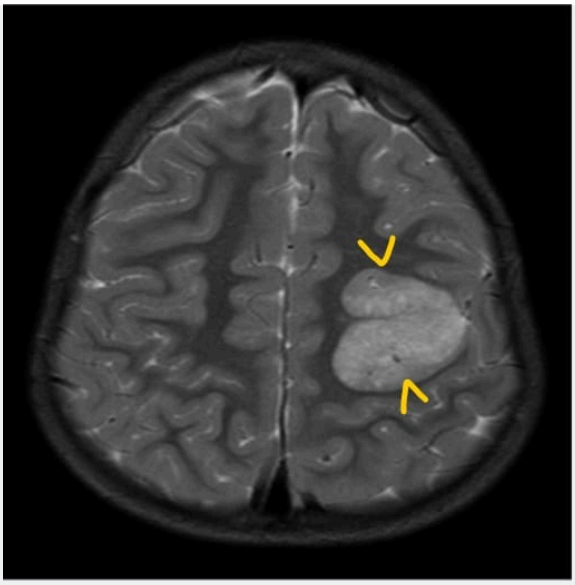

Figure 10.3.9: MRI of a 4-year old boy with a glioma. *(Image credit: "Glioma" by Manoj Kumar Raghu H Ramakrishnaiah Rohan Samant is licensed under CC BY-SA 4.0, via Wikimedia Commons.)*

Myelin

The insulation for axons in the nervous system is provided by oligodendrocytes in the CNS and Schwann cells in the PNS. These cells use the same mechanism to insulate axon segments. Myelin is a lipid-rich sheath that surrounds the axon and by doing so creates a **myelin sheath** that facilitates the transmission of electrical signals along the axon. The lipids are essentially the phospholipids of the glial cell membrane. Myelin, however, is more than just the membrane of the glial cell. It also includes important proteins that are integral to that membrane. Some of the proteins help to hold the layers of the glial cell membrane closely together. The axon has parts that are not covered by myelin called nodes of Ranvier which ensure the propagation of the electrical signal. Axons can be completely enclosed by myelin (**myelinated**) (Figure 10.3.10 and Figure 10.3.11) or not fully enclosed by it (**unmyelinated**). In the PNS unmyelinated axons generally are less than 2 µm in diameter and myelinated axons are more than 1–2 µm in diameter. In the CNS, almost all axons with diameters greater than 0.2 µm are myelinated.

In myelinated nerves, the appearance of the myelin sheath can be thought of as similar to the pastry wrapped around a hot dog for “pigs in a blanket” or a similar food. The glial cell is wrapped around the axon several times with little to no cytoplasm between the glial cell layers. For oligodendrocytes in the CNS, the rest of the cell is separate from the myelin sheath as a cell process extends back toward the cell body. A few other processes provide the same insulation for other axon segments in the area. For neurolemmocytes in the PNS, the outermost layer of the cell membrane contains cytoplasm and the nucleus of the cell as a bulge on one side of the myelin sheath. During development, the glial cell is loosely or incompletely wrapped around the axon. During myelination, the edges of this loose enclosure extend toward each other, and one end tucks under the other. The inner edge wraps around the axon, creating several layers, and the other edge closes around the outside so that the axon is completely enclosed. At the end of myelination, the myelin sheath is a thick layer that covers the axon (Figure 10.3.10).

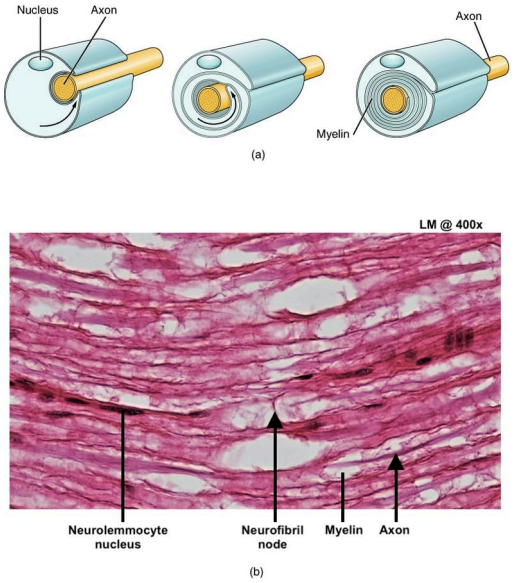

Figure 10.3.10: The Process of Myelination. In part (a), a drawing shows a myelinating neurolemmocyte wrapping several layers of cell membrane around the cell membrane of an axon segment and leaving its nucleus in the outer layer. In part (b), a histological slide shows a peripheral nerve in long section covered by myelin sheath. *(Image credit: "Myelinated Axon in PNS" by Jennifer Lange is licensed under CC BY-SA 4.0. Illustration by OpenStax is licensed under CC BY 4.0. Micrograph provided by Berkshire Community College Bioscience Image Library is in the Public Domain.)*

In unmyelinated nerves, the myelin sheath of oligodendrocytes or neurolemmocytes extends towards multiple axons. Since axons need to share the myelin sheath, they are not covered completely and one side of the axon remains unmyelinated. Since these nerves are not completely covered by myelin, their speed of electrical transmission is slower than myelinated nerves. Unmyelinated axons are primarily sensory fibers (transmitting sensations like dull pain, temperature changes, and itch) and autonomic fibers.

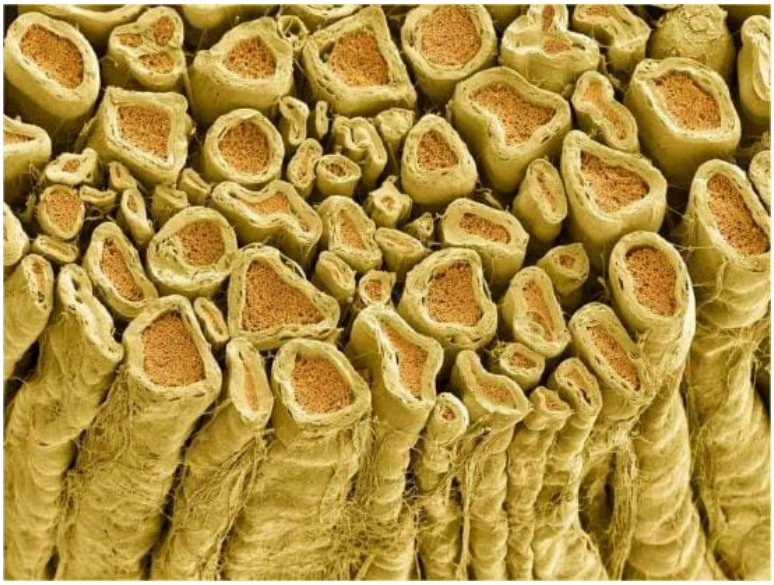

Figure 10.3.11: Myelinated Axons. This false colored scanning electron micrograph image shows the myelinated axons in a rat spinal cord. In the CNS axons are myelinated by oligodentrocytes. *(Image credit: "Myelinated Axons" by Tom Deerinck and Mark Ellisman, National Center for Microscopy and Imaging Research (NCMIR) is licensed under CC BY NC 2.0.)*

Regeneration of Axons

Traumatic injuries can cause damage to nerves. When nerves are damaged within the PNS as in the case of a laceration, the axons distal to the injury degenerate. The Schwann cells that were wrapping the injured axons proliferate to form a new tube of myelin

that guides the growing axons through physical and chemical support (Figure 10.3.12). Most of the times, axons can cross the injury site and can successfully grow back to the original targets. Sometimes the injury can affect also the surrounding tissues and form a scar that axons cannot cross. In that case, the axons are not able to grow back, unless surgery is performed to eliminate the scar tissue. The situation is different when injuries affect the CNS as in the case of spinal cord injuries. The oligodendrocytes respond to injury by undergoing apoptosis or becoming inactive. This contributes to the formation of scar tissue. Moreover, injury-activated astrocytes release molecules that inhibit axonal growth. Consequently, injured axons in the CNS are not able to grow back to their original target and nerve injuries in the CNS are permanent.

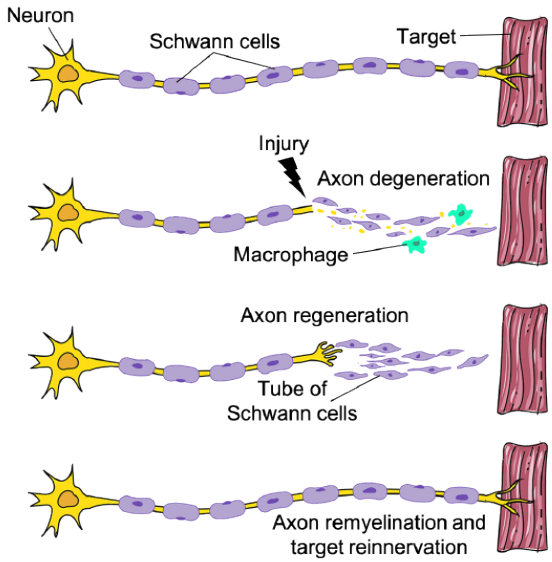

Figure 10.3.12: Axon Regeneration in the PNS. A neuron of the PNS innervates its target with its myelinated axon covered by Schwann cells. Following an injury, the part of the axon distal to the injury degenerates, leaving an axonal stump. The Schwann cells proliferate and produce new Schwann cells that form a tube to guide the axon back to its original target. Macrophages help clear up the debris from the axonal degeneration. The axonal stump grows following the tube of Schwann cells, which wrap it with myelin. The axon reaches the original target and the axon regeneration is complete. *(Image credit: "Axon Regeneration in the PNS" by Chiara Mazzasette is a derivative from the original work of Daniel Donnelly and is licensed by CC BY 4.0.)*

DISORDERS OF THE...

Nervous Tissue: Demyelinating Diseases

Several diseases can result from the demyelination of axons. The causes of these diseases are not the same; some have genetic causes, some are caused by pathogens, and others are the result of autoimmune disorders. Though the causes are varied, the results are largely similar. The myelin insulation of axons is compromised, making electrical signaling slower.

Multiple sclerosis (MS) is one such disease. It is an example of an autoimmune disease. The antibodies produced by lymphocytes (a type of white blood cell) mark myelin as something that should not be in the body. This causes inflammation and the destruction of the myelin in the central nervous system. As the insulation around the axons is destroyed by the disease, scarring becomes obvious. This is where the name of the disease comes from; sclerosis means hardening of tissue, which is what a scar is. Multiple scars are found in the white matter of the brain and spinal cord. The symptoms of MS include both somatic and autonomic deficits. Control of the musculature is compromised, as is control of organs such as the bladder.

Guillain-Barré (pronounced gee-YAN bah-RAY) syndrome is an example of a demyelinating disease of the peripheral nervous system. It is also the result of an autoimmune reaction, but the inflammation is in peripheral nerves. Sensory symptoms or motor deficits are common, and autonomic failures can lead to changes in the heart rhythm or a drop in blood pressure, especially when standing, which causes dizziness.

Concept Review

Nervous tissue contains two major cell types, neurons and glial cells. Neurons are the cells responsible for communication through electrical signals. Glial cells are supporting cells, maintaining the environment around the neurons.

Neurons are polarized cells, based on the flow of electrical signals along their membrane. Signals are received at the dendrites, are passed along the cell body, and propagate along the axon towards the target, which may be another neuron, muscle tissue, or a gland. Many axons are insulated by a lipid-rich substance called myelin. Specific types of glial cells provide this insulation.

Neurons can be categorized by their structure - how many processes project from the cell body:

- multipolar neurons - one axon, multiple dendrites
- bipolar neurons - one axon, one dendrite
- (pseudo)unipolar neurons - central and peripheral processes
- anaxonic neurons - no distinguishable axon

Several types of glial cells are found in the nervous system, and they can be categorized by the anatomical division in which they are found.

In the CNS, astrocytes, oligodendrocytes, microglia, and ependymal cells are found.

- Astrocytes are important for maintaining the chemical environment around the neuron and are crucial for regulating the blood-brain barrier.
- Oligodendrocytes are the myelinating glia in the CNS.
- Microglia act as phagocytes and play a role in immune surveillance.
- Ependymal cells are responsible for filtering the blood to produce cerebrospinal fluid, which is a circulatory fluid that performs some of the functions of blood in the brain and spinal cord because of the BBB.

In the PNS, satellite cells are supporting cells for the neurons, and Schwann cells (neurolemmocytes) insulate peripheral axons. Thanks to the Schwann cells, injured axons in the PNS can often regenerate and re-innervate their targets, while injured axons in the CNS are not able to.

Review Questions

Query 10.3.1

This interactive element is not available in this format. Visit the link or scan the QR code to access it online.

View this Interactive Content online

Critical Thinking Questions

Query 10.3.2

This interactive element is not available in this format. Visit the link or scan the QR code to access it online.

View this Interactive Content online

Query 10.3.3

This interactive element is not available in this format. Visit the link or scan the QR code to access it online.

View this Interactive Content online

Glossary

Query 10.3.4

This interactive element is not available in this format. Visit the link or scan the QR code to access it online.

View this Interactive Content online

Contributors and Attributions

- OpenStax Anatomy & Physiology (CC BY 4.0). Access for free at https://openstax.org/books/anatomy-and-physiology

This page titled 10.3: Anatomy of Nervous Tissue is shared under a CC BY-NC-SA 4.0 license and was authored, remixed, and/or curated by Jennifer Lange et al..

- 11.3: Anatomy of Nervous Tissue by Whitney Menefee, Julie Jenks, Chiara Mazzasette, and Kim-Leiloni Nguyen is licensed CC BY 4.0.

10.4: Synapses

By the end of this section, you will be able to:

- Describe the components of synapses
- Compare electrical and chemical synapses

Having looked at the components of nervous tissue, and the basic anatomy of the nervous system, next comes an understanding of how nervous tissue is capable of communicating within the nervous system. Neurons communicate with other neurons, muscles or glands through the generation and conduction of nerve impulses called **action potentials**. These electrical impulses propagate from the axon hillock to the axon terminals via changes in the electrical properties of the neuronal cell membrane. All cells have an electrical charge associated with their membrane. However, neurons and other cells are able to change their electrical charge by moving ions across the membrane. At the axon (or synaptic) terminals the action potential needs a way to pass the signal on to the next cell, which they do at structures called **synapses**.

Synapses

Neurons and their targets form synapses. The neuron that generates and conducts the action potential to the target is called a **presynaptic cell**. The target cell receiving the action potential is called a **postsynaptic cell**. While the presynaptic cell is always a neuron (because only neurons have axons and can form a synapse), the postsynaptic cell can be a neuron or another type of cell such as skeletal, cardiac or smooth muscle cells, or glands. In Figure 10.4.1, a presynaptic neuron forms synapses with two postsynaptic neurons. The nerve impulse (or signal) travels from a presynaptic neuron to a postsynaptic cell by crossing the gap between them, the **synaptic cleft**. The two methods by which the cleft is crossed are 1) electrical and 2) chemical, with chemical being the most common and most diverse.

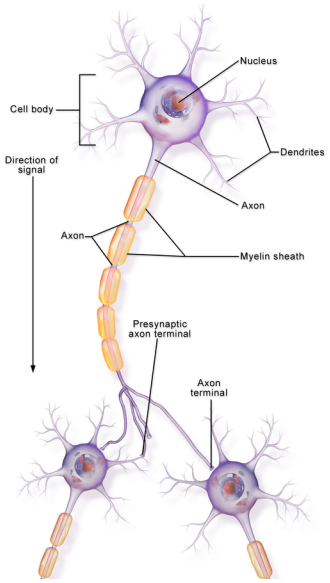

Figure 10.4.1: Presynaptic and postsynaptic neurons. A presynaptic neuron on top forms synapses with two postsynaptic neurons at the bottom. The parts of the presynaptic neuron are labeled as cell body, nucleus, dendrites and axon covered in a myelin sheath. The direction of signal shows that the electrical signal (action potential) travels from the axon of the presynaptic neuron to the axon terminals of the presynaptic neuron that are in contact with the dendrites and cell body of the postsynaptic neurons. *(Image credit: "Neuron Part 1" by BruceBlaus is licensed under CC BY-SA 4.0.)*

Chemical Synapses

Chemical synapses involve the transmission of chemical information from one cell to the next and they represent the majority

of the synapses found within the nervous system. In a **chemical synapse**, a chemical signal called a **neurotransmitter**, is released from the presynaptic cell and it affects the postsynaptic cell. There are many different types of neurotransmitters, for example acetylcholine, serotonin, dopamine, adrenaline, glutamate, etc. Each neurotransmitter has its own specific receptor on the postsynaptic membrane. Chemical synapses can then be classified based on the neurotransmitter that the cells use to communicate (for example glutamatergic synapses use glutamate). Different neurotransmitters and different receptors will determine the overall response to the stimulus. All chemical synapses have common characteristics, which can be summarized in this list and are shown in Figure 10.4.2:

- synaptic end bulb of presynaptic neuron
- neurotransmitter (packaged in vesicles)
- synaptic cleft
- receptors for neurotransmitter
- postsynaptic membrane of postsynaptic neuron

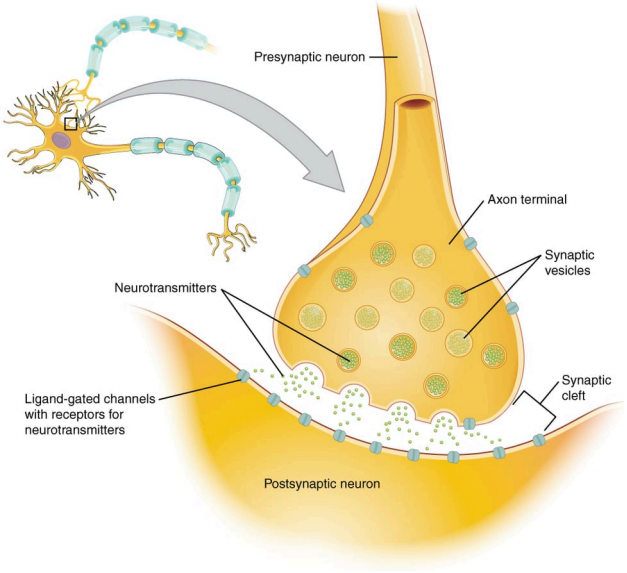

Figure 10.4.2: Chemical Synapse. The axon of the presynaptic neuron terminates at the axon terminal in a synaptic end bulb where the action potential arrives. The arrival of action potential causes the synaptic vesicles containing neurotransmitters to fuse with the membrane and release the neurotransmitters. The neurotransmitters diffuse across the synaptic cleft to bind to its receptor, in this case ligand-gated channels. Neurotransmitters will eventually be cleared from the synapse. *(Image credit: "Chemical Synapse" by Young, KA., Wise, JA., DeSaix, P., Kruse, DH., Poe, B., Johnson, E., Johnson, JE., Korol, O., Betts, JG., & Womble, M. is licensed under CC BY 4.0.)*

Electrical Synapses

In an **electrical synapse**, there is a direct connection between the presynaptic and postsynaptic cells and the connection is formed by gap junctions. Thus, the electrical charges of an action potential can pass directly from one cell to the next. If one cell delivers an action potential in an electrical synapse, the joined cell will also generate an action potential because the electrical charges will pass between the cells (Figure 10.4.3). Although representing the minority of synapses, electrical synapses are found throughout the nervous system. These synapses also occur between excitable cells other than neurons, for example between smooth muscle cells in the intestines and cardiac muscle cells in the heart.

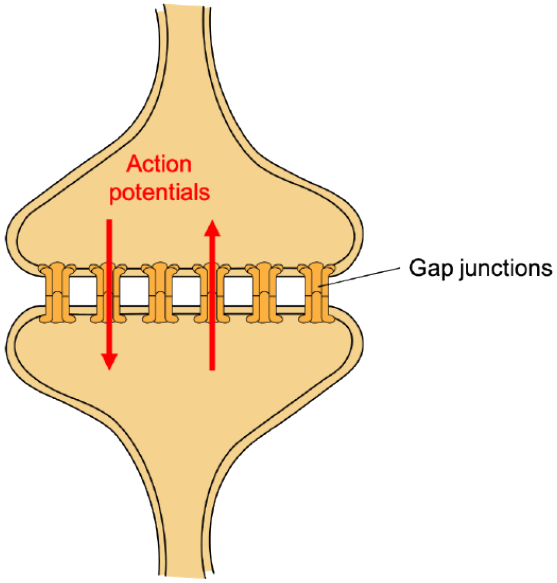

Figure 10.4.3: Electrical Synapse. Two synaptic end bulbs form an electrical synapse where gap junctions allow the passage of action potentials from one cytoplasm to the other, and vice versa. *(Image credit: "Electrical Synapse" by Chiara Mazzasette is a derivative from the original work of Daniel Donnelly and is licensed by CC BY 4.0.)*

DISORDERS OF THE...

Nervous System: Alzheimer's and Parkinson's Disease

The underlying cause of some neurodegenerative diseases, such as Alzheimer's and Parkinson's, appears to be related to proteins—specifically, to proteins behaving badly. One of the strongest theories of what causes Alzheimer's disease is based on the accumulation of beta-amyloid plaques, dense conglomerations of a protein fragment that aggregates instead of being broken down by microglia. Parkinson's disease is linked to an increase in a protein known as alpha-synuclein that is toxic to the cells of the substantia nigra nucleus in the midbrain.

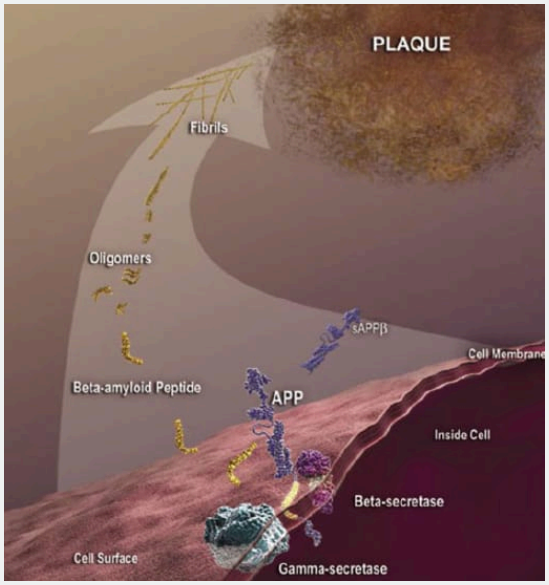

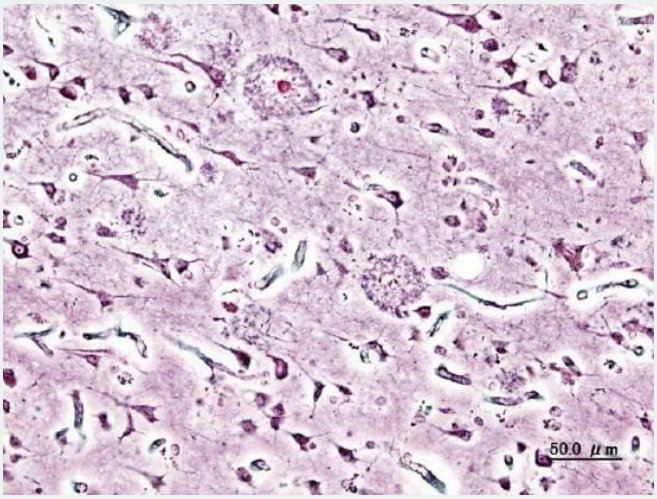

Figure 10.4.4: Beta-amyloid plaques form in the brain of Alzheimer's disease patients. These plaques form when a normal process, the slicing of the amyloid precursor protein to remove the beta-amyloid fragment, is disrupted and these fragments are not metabolized normally. Instead, the stick to each other and disrupt neuronal function.*(Image credits: Illustration: "Alzheimers_disease-Beta-amyloid_plaque_formation" by National Institute on Aging is in the Public domain, via Wikimedia Commons; Histology: "Alzheimer_dementia_(3)_presenile_onset " by KGH is licensed under CC BY-SA 3.0, via Wikimedia Commons.)*

For proteins to function correctly, they are dependent on their three-dimensional shape. The linear sequence of amino acids folds into a three-dimensional shape that is based on the interactions between and among those amino acids. When the folding is disturbed, and proteins take on a different shape, they stop functioning correctly. But the disease is not necessarily the result of functional loss of these proteins; rather, these altered proteins start to accumulate and may become toxic. For example, in Alzheimer's, the hallmark of the disease is the accumulation of these amyloid plaques in the cerebral cortex (Figure 10.4.4). The term coined to describe this sort of disease is "proteopathy" and it includes other diseases. Creutzfeld-Jacob disease, the human variant of the prion disease known as mad cow disease in the bovine, also involves the accumulation of amyloid plaques, similar to Alzheimer's. Diseases of other organ systems can fall into this group as well, such as cystic fibrosis or type 2 diabetes. Recognizing the relationship between these diseases has suggested new therapeutic possibilities. Interfering with the accumulation of the proteins, and possibly as early as their original production within the cell, may unlock new ways to alleviate these devastating diseases.

CAREER CONNECTIONS

Neurophysiologist

Figure 10.4.5 A neuroscience student can participate in research projects by monitoring and running various tests during experiments as well as doing data collection and analysis. Student Cammi Borden worked with research psychologist Dr. Kara Blacker at the Naval Medical Research Unit studying low-oxygen conditions impact on brain activity. *(Image credit: Public Domain Dedication. Public Use Notice of Limitations: https://www.dvidshub.net/about/copyright.)*

Understanding how the nervous system works could be a driving force in your career. Studying neurophysiology (Figure 10.4.5) is a very rewarding path to follow. It means that there is a lot of work to do, but the rewards are worth the effort.

The career path of a research scientist can be straightforward: college, graduate school, postdoctoral research, academic research position at a university. A Bachelor's degree in science will get you started, and for neurophysiology that might be in biology, psychology, computer science, engineering, or neuroscience. But the real specialization comes in graduate school. There are many different programs out there to study the nervous system, not just neuroscience itself. Most graduate programs are doctoral, meaning that a Master's degree is not part of the work. These are usually considered five-year programs, with the first two years dedicated to course work and finding a research mentor, and the last three years dedicated to finding a research topic and pursuing that with a near single-mindedness. The research will usually result in a few publications in scientific journals, which will make up the bulk of a doctoral dissertation. After graduating with a Ph.D., researchers will go on to find specialized work called a postdoctoral fellowship within established labs. In this position, a researcher starts to establish their own research career with the hopes of finding an academic position at a research university.

Other options are available if you are interested in how the nervous system works. Especially for neurophysiology, a medical degree might be more suitable so you can learn about the clinical applications of neurophysiology and possibly work with human subjects. An academic career is not a necessity. Biotechnology firms are eager to find motivated scientists ready to tackle the tough questions about how the nervous system works so that therapeutic chemicals can be tested on some of the most challenging disorders such as Alzheimer's disease or Parkinson's disease, or spinal cord injury.

Others with a medical degree and a specialization in neuroscience go on to work directly with patients, diagnosing and treating mental disorders. You can do this as a psychiatrist, a neuropsychologist, or a neurologist, a neurosurgeon, or an anesthesiologist.

Concept Review

Synapses are the contacts between neurons, which can either be chemical or electrical in nature. Chemical synapses are far more common. At a chemical synapse, neurotransmitter is released from the presynaptic neuron and diffuses across the synaptic cleft. The neurotransmitter binds to a receptor protein and causes a change in the postsynaptic cell's membrane (the PSP).

Review Questions

Query 10.4.1

This interactive element is not available in this format. Visit the link or scan the QR code to access it online.

View this Interactive Content online

Critical Thinking Questions

Query 10.4.2

This interactive element is not available in this format. Visit the link or scan the QR code to access it online.

View this Interactive Content online

Query 10.4.3

This interactive element is not available in this format. Visit the link or scan the QR code to access it online.

View this Interactive Content online

Glossary

Query 10.4.4

This interactive element is not available in this format. Visit the link or scan the QR code to access it online.

View this Interactive Content online

Contributors and Attributions

- OpenStax Anatomy & Physiology (CC BY 4.0). Access for free at https://openstax.org/books/anatomy-and-physiology

This page titled 10.4: Synapses is shared under a CC BY-NC-SA 4.0 license and was authored, remixed, and/or curated by Jennifer Lange et al..

- 11.4: Neuronal Communication by Whitney Menefee, Julie Jenks, Chiara Mazzasette, and Kim-Leiloni Nguyen is licensed CC BY 4.0.

10.5: Development of the Nervous System

By the end of this section, you will be able to:

- Describe the growth and differentiation of the anterior neural tube into primary and secondary vesicles
- Relate the different stages of development of the anterior neural tube to the adult brain regions
- Describe the development of the posterior neural tube into the adult spinal cord
- Explain the expansion of the ventricular system of the adult brain from the central canal of the neural tube

The brain is a complex organ composed of gray parts and white matter, which can be hard to distinguish. Starting from an embryologic perspective allows you to understand more easily how the parts relate to each other. The embryonic nervous system begins as a very simple structure—essentially just a straight line, which then gets increasingly complex. Looking at the development of the nervous system with a couple of early snapshots makes it easier to understand the whole complex system.

Many structures that appear to be adjacent in the adult brain are not connected, and the connections that exist may seem arbitrary. But there is an underlying order to the system that comes from how different parts develop. By following the developmental pattern, it is possible to learn what the major regions of the nervous system are.

Neural Tube

To begin, a sperm cell and an egg cell fuse to become a fertilized egg. The fertilized egg cell, or zygote, starts dividing to generate the cells that make up an entire organism. Sixteen days after fertilization, the developing embryo's cells belong to one of three germ layers that give rise to the different tissues in the body. The endoderm, or inner tissue, is responsible for generating the lining tissues of various spaces within the body, such as the mucosae of the digestive and respiratory systems. The mesoderm, or middle tissue, gives rise to most of the muscle and connective tissues. Finally the ectoderm, or outer tissue, develops into the integumentary system (the skin) and the nervous system. It is probably not difficult to see that the outer tissue of the embryo becomes the outer covering of the body. But how is it responsible for the nervous system?

As the embryo develops, a portion of the ectoderm differentiates into a specialized region of neuroectoderm, which is the precursor for the tissue of the nervous system. Molecular signals induce cells in this region to differentiate into the neuroepithelium, forming a **neural plate**. The cells then begin to change shape, causing the tissue to buckle and fold inward (Figure 10.5.1). A **neural groove** forms, visible as a line along the dorsal surface of the embryo. The ridge-like edge on either side of the neural groove is referred as the **neural fold**. As the neural folds come together and converge, the underlying structure forms into a tube just beneath the ectoderm called the **neural tube**. Cells from the neural folds then separate from the ectoderm to form a cluster of cells referred to as the **neural crest**, which runs lateral to the neural tube. The neural crest migrates away from the nascent, or embryonic, central nervous system (CNS) that will form along the neural groove and develops into several parts of the peripheral nervous system (PNS), including the enteric nervous tissue. Many tissues that are not part of the nervous system also arise from the neural crest, such as craniofacial cartilage and bone, and melanocytes.

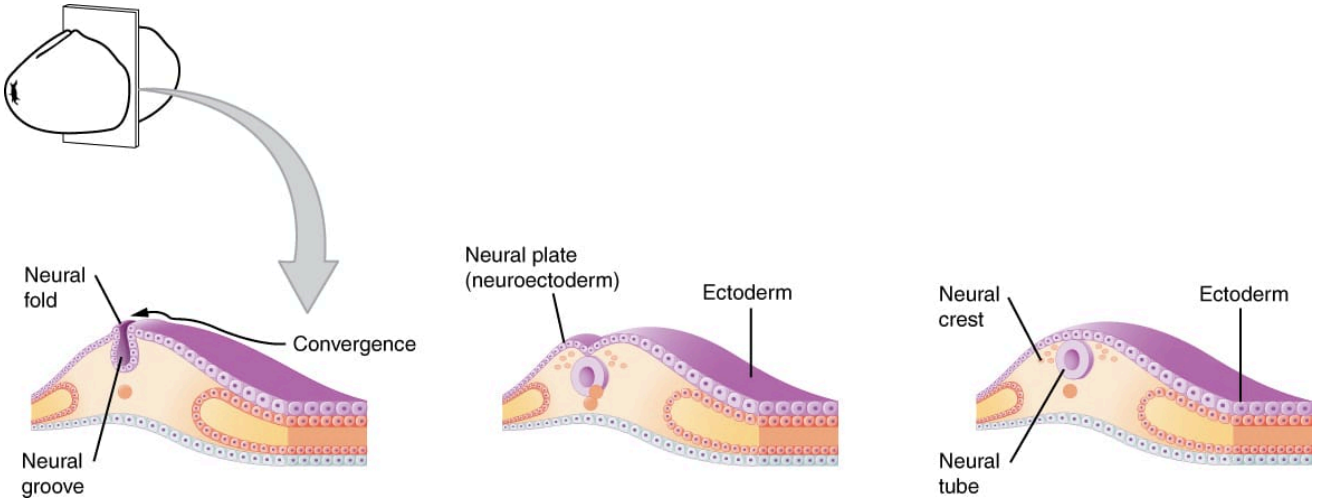

Figure 10.5.1: Early Embryonic Development of Nervous System. The neuroectoderm that forms the neural plate begins to fold inward to form the neural groove. As the two sides of the neural groove converge, they fuse together and form the neural tube, which lies beneath the ectoderm. The anterior end of the neural tube will develop into the brain, and the posterior portion will become the spinal cord. The neural crest which sits laterally to the neural tube develops into peripheral structures. *(Image credit: "Neural Tube Development" by OpenStax is licensed under CC BY 4.0)*

At this point, the early nervous system is a simple, hollow tube. It runs from the anterior end of the embryo to the posterior end. Beginning at 25 days, the anterior end develops into the brain, and the posterior portion becomes the spinal cord. This is the most basic arrangement of tissue in the nervous system, and it gives rise to the more complex structures by the fourth week of development.

Primary Vesicles

As the anterior end of the neural tube starts to develop into the brain, it undergoes a couple of enlargements; the result is the production of sac-like vesicles. Similar to a child's balloon animal, the long, straight neural tube begins to take on a new shape. Three vesicles form at the first stage, which are called **primary vesicles**. These vesicles are given names that are based on Greek words, the main root word being *enkephalon*, which means "brain" (en- = "inside"; kephalon = "head"). The prefix to each generally corresponds to its position along the length of the developing nervous system.

The **prosencephalon** (pros- = "in front") is the forward-most vesicle, and the term can be loosely translated to mean **forebrain**. The **mesencephalon** (mes- = "middle") is the next vesicle, which can be called the **midbrain**. The third vesicle at this stage is the **rhombencephalon**. The first part of this word is also the root of the word rhombus, which is a geometrical figure with four sides of equal length (a square is a rhombus with 90° angles). Whereas prosencephalon and mesencephalon translate into the English words forebrain and midbrain, there is not a word for "four-sided-figure-brain." However, the third vesicle can be called the **hindbrain**. One way of thinking about how the brain is arranged is to use these three regions—forebrain, midbrain, and hindbrain—which are based on the primary vesicle stage of development (Figure 10.5.2a).

Secondary Vesicles

The brain continues to develop, and the vesicles differentiate further (Figure 10.5.2b). The three primary vesicles become five **secondary vesicles**. The prosencephalon enlarges into two new vesicles called the **telencephalon** and the **diencephalon**. The telecephalon will become the cerebrum. The diencephalon gives rise to several adult structures; two that will be important are the thalamus and the hypothalamus. In the embryonic diencephalon, a structure known as the eye cup develops, which will eventually become the retina, the nervous tissue of the eye called the retina. This is a rare example of nervous tissue developing as part of the CNS structures in the embryo, but becoming a peripheral structure in the fully formed nervous system.

The mesencephalon does not differentiate into any finer divisions. The midbrain is an established region of the brain at the primary vesicle stage of development and remains that way. The rest of the brain develops around it and constitutes a large percentage of the mass of the brain. Dividing the brain into forebrain, midbrain, and hindbrain is useful in considering its developmental pattern, but the midbrain is a small proportion of the entire brain, relatively speaking.

The rhombencephalon develops into the **metencephalon** and **myelencephalon**. The metencephalon corresponds to the adult structure known as the pons and also gives rise to the cerebellum. The cerebellum (from the Latin meaning “little brain”) accounts for about 10 percent of the mass of the brain and is an important structure in itself. The most significant connection between the cerebellum and the rest of the brain is at the pons, because the pons and cerebellum develop out of the same vesicle. The myelencephalon corresponds to the adult structure known as the medulla oblongata. The structures that come from the mesencephalon and rhombencephalon, except for the cerebellum, are collectively considered the **brainstem**, which specifically includes the midbrain, pons, and medulla.

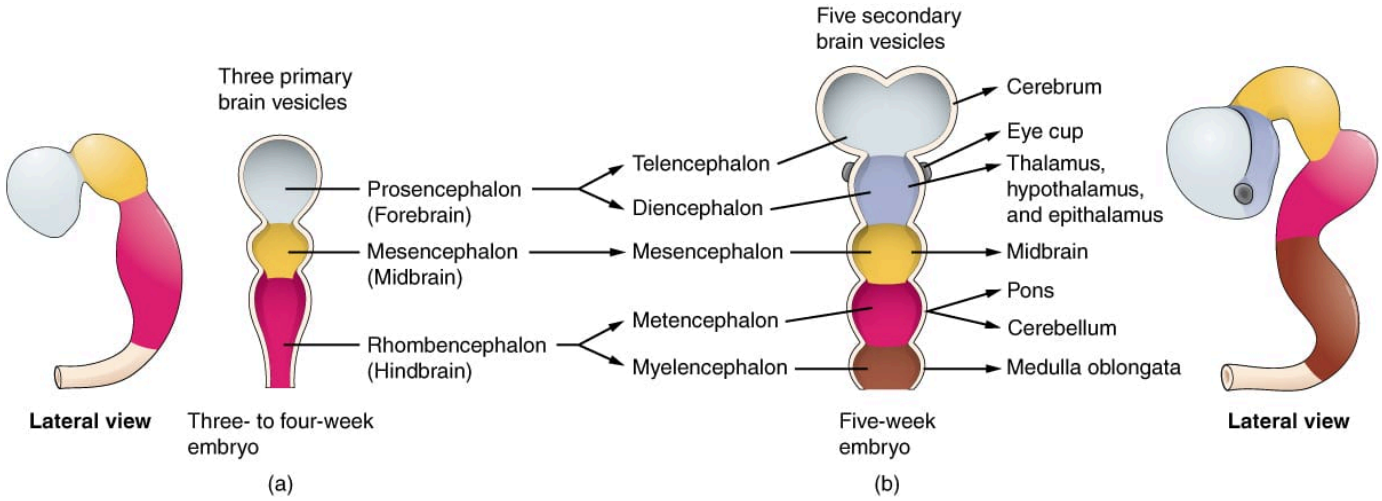

Figure 10.5.2: Primary and Secondary Vesicle Stages of Development. The embryonic brain develops complexity through enlargements of the neural tube called vesicles. In part a, the primary vesicle stage which happens around 3 to 4 weeks of embryonic development shows three vesicles: the prosencephalon is superior and anterior; the mesencephalon is inferior to the prosencephalon; and rhombencephalon is the most inferior vesicle. In part b, the secondary vesicle stage which happens at 5 weeks of embryonic development shows five regions. From anterior and superior to posterior and inferior, these regions are: telencephalon, diencephalon, mesencephalon, metencephalon and myelencephalon. *(Image credit: "Brain Vesicle Development" by OpenStax is licensed under CC BY 4.0)*

Spinal Cord Development

While the brain is developing from the anterior neural tube, the spinal cord is developing from the posterior neural tube. However, its structure does not differ from the basic layout of the neural tube. It is a long, straight cord with a small, hollow space down the center. The neural tube is defined in terms of its anterior versus posterior portions, but it also has a dorsal–ventral dimension. As the neural tube separates from the rest of the ectoderm, the side closest to the surface is dorsal, and the deeper side is ventral.

As the spinal cord develops, the cells making up the wall of the neural tube proliferate and differentiate into the neurons and glia of the spinal cord. The dorsal tissues will be associated with sensory functions, and the ventral tissues will be associated with motor functions.

Relating Embryonic Development to the Adult Brain

Embryonic development can help in understanding the structure of the adult brain because it establishes a framework on which more complex structures can be built. First, the neural tube establishes the anterior–posterior dimension of the nervous system, which is called the **neuraxis**. The embryonic nervous system in mammals can be said to have a standard arrangement. Humans (and other primates, to some degree) make this complicated by standing up and walking on two legs. The anterior–posterior dimension of the neuraxis overlays the superior–inferior dimension of the body. However, there is a major curve between the brainstem and forebrain, which is called the **cephalic flexure**. Because of this, the neuraxis starts in an inferior position—the end of the spinal cord—and ends in an anterior position, the front of the cerebrum. If this is confusing, just imagine a four-legged animal standing up on two legs. Without the flexure in the brainstem, and at the top of the neck, that animal would be looking straight up instead of straight in front (Figure 10.5.3).

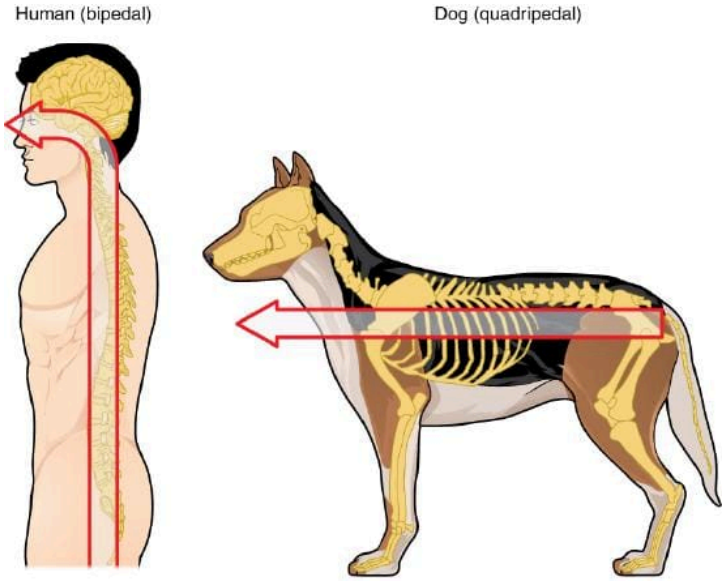

Figure 10.5.3: Human Neuraxis. The mammalian nervous system is arranged with the neural tube running along an anterior to posterior axis, from nose to tail for a four-legged animal like a dog. Humans, as two-legged animals, have a bend in the neuraxis between the brainstem and the diencephalon, along with a bend in the neck, so that the eyes and the face are oriented forward. *(Image credit: "Human Neuraxis" by OpenStax is licensed under CC BY 4.0)*

In summary, the primary vesicles help to establish the basic regions of the nervous system: forebrain, midbrain, and hindbrain. These divisions are useful in certain situations, but they are not equivalent regions. The midbrain is small compared with the hindbrain and particularly the forebrain. The secondary vesicles go on to establish the major regions of the adult nervous system that will be followed in this text. The telencephalon is the cerebrum, which is the major portion of the human brain. The diencephalon continues to be referred to by this Greek name, because there is no better term for it (dia- = "through"). The diencephalon is between the cerebrum and the rest of the nervous system and can be described as the region through which all projections have to pass between the cerebrum and everything else. The brainstem includes the midbrain, pons, and medulla, which correspond to the mesencephalon, metencephalon, and myelencephalon. The cerebellum, being a large portion of the brain, is considered a separate region. Table connects the different stages of development to the adult structures of the CNS.

One other benefit of considering embryonic development is that certain connections are more obvious because of how these adult structures are related. The retina, which began as part of the diencephalon, is primarily connected to the diencephalon. The eyes are just inferior to the anterior-most part of the cerebrum, but the optic nerve extends back to the thalamus as the optic tract, with branches into a region of the hypothalamus. There is also a connection of the optic tract to the midbrain, but the mesencephalon is adjacent to the diencephalon, so that is not difficult to imagine. The cerebellum originates out of the metencephalon, and its largest white matter connection is to the pons, also from the metencephalon. There are connections between the cerebellum and both the medulla and midbrain, which are adjacent structures in the secondary vesicle stage of development. In the adult brain, the cerebellum seems close to the cerebrum, but there is no direct connection between them.

Another aspect of the adult CNS structures that relates to embryonic development is the ventricles—open spaces within the CNS where cerebrospinal fluid circulates. They are the remnant of the hollow center of the neural tube. The four ventricles and the tubular spaces associated with them can be linked back to the hollow center of the embryonic brain (see Table 10.5.1).

Table 10.5.1 Stages of Embryonic Development

Neural tube	Primary vesicle stage	Secondary vesicle stage	Adult structures	Ventricles
Anterior neural tube	Prosencephalon	Telencephalon	Cerebrum	Lateral ventricles
Anterior neural tube	Prosencephalon	Diencephalon	Diencephalon	Third ventricle
Anterior neural tube	Mesencephalon	Mesencephalon	Midbrain	Cerebral aqueduct
Anterior neural tube	Rhombencephalon	Metencephalon	Pons cerebellum	Fourth ventricle
Anterior neural tube	Rhombencephalon	Myelencephalon	Medulla	Fourth ventricle
Posterior neural tube			Spinal cord	Central canal

Development of the Nervous System: Spina Bifida

Early formation of the nervous system depends on the formation of the neural tube. A groove forms along the dorsal surface of the embryo, which becomes deeper until its edges meet and close off to form the tube. If this fails to happen, especially in the posterior region where the spinal cord forms, a developmental defect called spina bifida occurs. The closing of the neural tube is important for more than just the proper formation of the nervous system. The surrounding tissues are dependent on the correct development of the tube. The connective tissues surrounding the CNS can be involved as well.

There are three classes of this disorder: occulta, meningocele, and myelomeningocele (Figure 10.5.4). The first type, spina bifida occulta, is the mildest because the vertebral bones do not fully surround the spinal cord, but the spinal cord itself is not affected. No functional differences may be noticed, which is what the word occulta means; it is hidden spina bifida. The other two types both involve the formation of a cyst—a fluid-filled sac of the connective tissues that cover the spinal cord called the meninges. “Meningocele” means that the meninges protrude through the spinal column but nerves may not be involved and few symptoms are present, though complications may arise later in life. “Myelomeningocele” means that the meninges protrude and spinal nerves are involved, and therefore severe neurological symptoms can be present.

Often surgery to close the opening or to remove the cyst is necessary. The earlier that surgery can be performed, the better the chances of controlling or limiting further damage or infection at the opening. For many children with meningocele, surgery will alleviate the pain, although they may experience some functional loss. Because the myelomeningocele form of spina bifida involves more extensive damage to the nervous tissue, neurological damage may persist, but symptoms can often be handled. Complications of the spinal cord may present later in life, but overall life expectancy is not reduced.

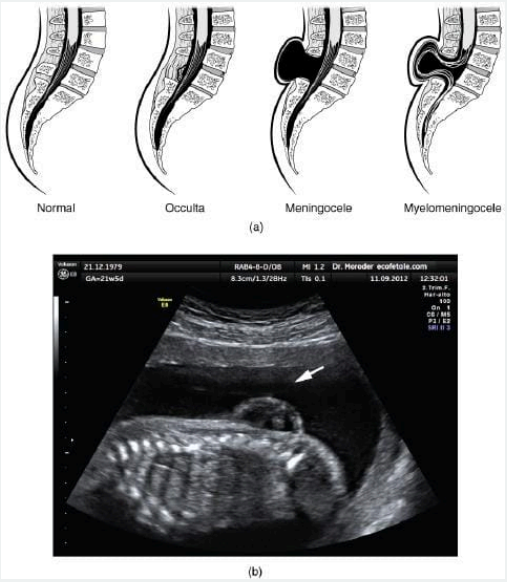

Figure 10.5.4: Spina Bifida. Spina bifida is a birth defect of the spinal cord caused when the neural tube does not completely close, but the rest of development continues. The result is the emergence of meninges and neural tissue through the vertebral column. Part (a) shows the difference between a normal spinal cord, and the three types of spina bifida: occulta, meningocele and myelomeningocele. In part (b), an ultrasound taken at 21 weeks shows a fetal myelomeningocele. *(Image credit: "Spina Bifida" by OpenStax is licensed under CC BY-SA 3.0 / Ultrasound image: "Spina bifida lombare sagittale" by Moroder is licensed under CC BY-SA 3.0)*

Concept Review

The development of the nervous system starts early in embryonic development. The outer layer of the embryo, the ectoderm, gives rise to the skin and the nervous system. A specialized region of this layer, the neuroectoderm, becomes a groove that folds in and becomes the neural tube beneath the dorsal surface of the embryo. The anterior end of the neural tube develops into the brain, and the posterior region becomes the spinal cord. Tissues at the edges of the neural groove, when it closes off, are called the neural crest and migrate through the embryo to give rise to PNS structures as well as some non-nervous tissues.

The brain develops from this early tube structure and gives rise to specific regions of the adult brain. As the neural tube grows and differentiates, it enlarges into three vesicles that correspond to the forebrain, midbrain, and hindbrain regions of the adult brain. Later in development, two of these three vesicles differentiate further, resulting in five vesicles. Those five vesicles can be aligned with the four major regions of the adult brain. The cerebrum is formed directly from the telencephalon. The diencephalon is the only region that keeps its embryonic name. The mesencephalon, metencephalon, and myelencephalon become the brainstem. The cerebellum also develops from the metencephalon and is a separate region of the adult brain.

The spinal cord develops out of the rest of the neural tube and retains the tube structure, with the nervous tissue thickening and the hollow center becoming a very small central canal through the cord. The rest of the hollow center of the neural tube corresponds to open spaces within the brain called the ventricles, where cerebrospinal fluid is found.

Multiple Choice

Query 10.5.1

This interactive element is not available in this format. Visit the link or scan the QR code to access it online.

View this Interactive Content online

Critical Thinking Questions

Query 10.5.2

This interactive element is not available in this format. Visit the link or scan the QR code to access it online.

View this Interactive Content online

Glossary

Query 10.5.3

This interactive element is not available in this format. Visit the link or scan the QR code to access it online.

View this Interactive Content online

Contributors and Attributions

- OpenStax Anatomy & Physiology (CC BY 4.0). Access for free at https://openstax.org/books/anatomy-and-physiology

This page titled 10.5: Development of the Nervous System is shared under a CC BY-NC-SA 4.0 license and was authored, remixed, and/or curated by Jennifer Lange et al..

- 11.5: Development of the Nervous System by Whitney Menefee, Julie Jenks, Chiara Mazzasette, and Kim-Leiloni Nguyen is licensed CC BY 4.0.

10.6: Anatomical Atlas - Nervous Tissue

A compendium of anatomical images: slides, models, and/or cadavers.

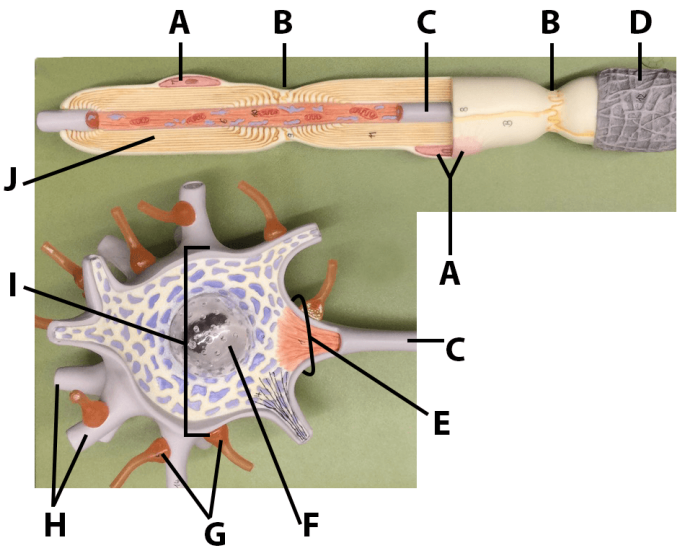

Image Credit

Neuron Model by Jennifer Lange is licensed under CC BY-NC-SA 4.0.

Answer Key (click to show/hide answers)

A - nucleus of neurolemmocyte (Schwann cell)

B - neurofibril node

C - axon

D - endoneurium

E - axon hillock

F - nucleus of neuron

G - synaptic (axon) terminals

H - dendrites

I - soma (cell body)

J - myelin sheath/myelin

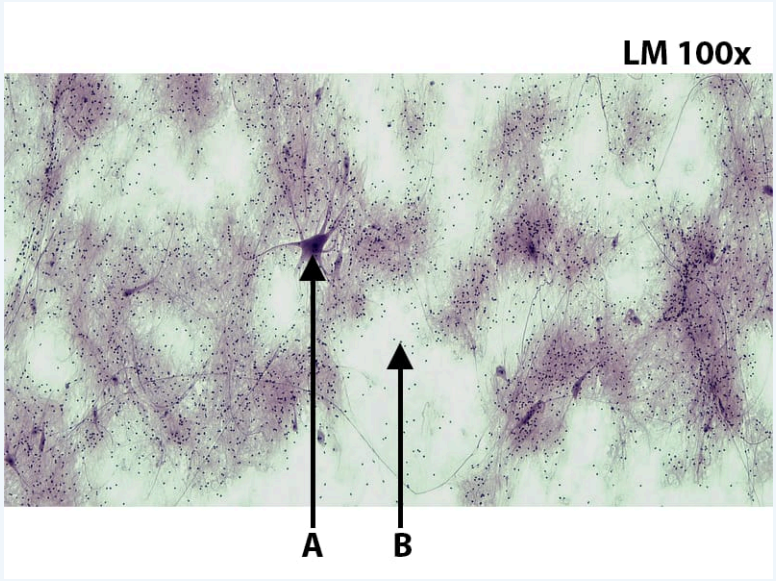

Image Credit

Nervous Tissue @100x - Atlas by Jennifer Lange is licensed under CC BY-NC-SA 4.0. Micrograph provided by Berkshire Community College Bioscience Image Library is in the Public Domain.

Answer Key (click to show/hide answers)

A - neuron

B - glial cell (neuroglia)

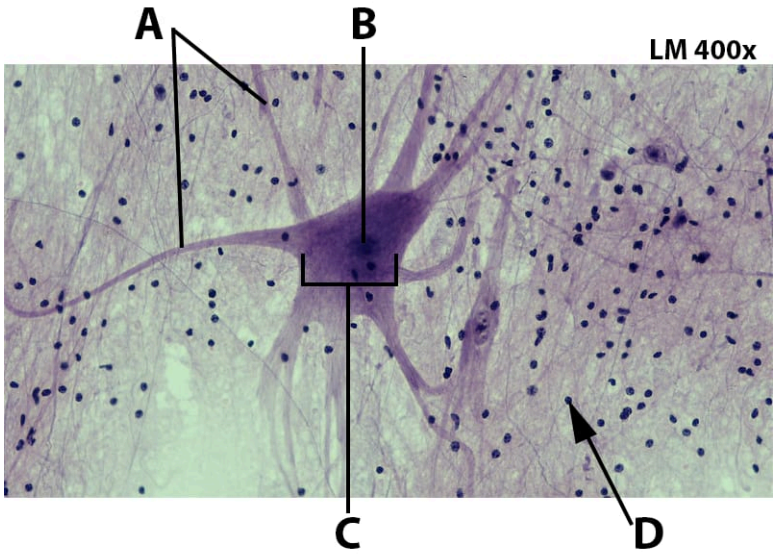

Image Credit

Nervous Tissue @400x - Atlas by Jennifer Lange is licensed under CC BY-NC-SA 4.0. Micrograph provided by Berkshire Community College Bioscience Image Library is in the Public Domain.

Answer Key (click to show/hide answers)

A - Processes (axons and/or dendrites)

B - nucleus

C - soma (cell body)

D - glial cell (neuroglia)

This page titled 10.6: Anatomical Atlas - Nervous Tissue is shared under a CC BY-NC-SA 4.0 license and was authored, remixed, and/or curated by Jennifer Lange et al..

10.7: Practice Practical - Nervous Tissue

Query 10.7.1

This interactive element is not available in this format. Visit the link or scan the QR code to access it online.

View this Interactive Content online

Query 10.7.1

This interactive element is not available in this format. Visit the link or scan the QR code to access it online.

View this Interactive Content online

Query 10.7.1

This interactive element is not available in this format. Visit the link or scan the QR code to access it online.

View this Interactive Content online

Query 10.7.1

This interactive element is not available in this format. Visit the link or scan the QR code to access it online.

View this Interactive Content online

This page titled 10.7: Practice Practical - Nervous Tissue is shared under a CC BY-NC-SA 4.0 license and was authored, remixed, and/or curated by Jennifer Lange et al..

11: CENTRAL NERVOUS SYSTEM

The central nervous system (CNS) comprehends the brain and spinal cord, while the peripheral nervous system (PNS) comprises ganglia, cranial and spinal nerves. The focus of this chapter is on the organs of the CNS and the structures that support and protect the nervous system.

11.1: Introduction to the Central Nervous System

11.2: Support and Protection of the Brain

11.3: Brain - Cerebrum

11.4: Brain - Diencephalon, Brainstem, Cerebellum and Limbic System

11.5: Spinal Cord

11.6: Anatomical Atlas - Central Nervous System

11.7: Practice Practical - Central Nervous System

This page titled 11: Central Nervous System is shared under a CC BY-NC-SA 4.0 license and was authored, remixed, and/or curated by Jennifer Lange et al..

- 12: Central and Peripheral Nervous System by Whitney Menefee, Julie Jenks, Chiara Mazzasette, and Kim-Leiloni Nguyen is licensed CC BY 4.0.

11.1: Introduction to the Central Nervous System

Chapter Learning Objectives

After studying this chapter, you will be able to:

- Describe the structures that support and protect the brain and spinal cord
- Identify the regions and anatomical landmarks of the brain and spinal cord
- Describe the functions of the regions of the cerebrum, diencephalon, brainstem, cerebellum and limbic system

Fresh, unstained nervous tissue can be described as gray or white matter, and within those two types of tissue it can be very hard to see any detail. However, as specific regions and structures have been discovered, they were related to specific functions. Understanding these structures and the functions they perform requires a detailed description of the anatomy of the nervous system. While the structures are discovered thanks to dissections of cadavers, early knowledge of the functions of the individual part of our nervous system was gathered by lesion case studies. In these studies, injuries or illnesses of the nervous system are studied to understand the relationship between the injured area and the function of it. The first, and most known, lesion case is the one of Phineas Gage (Figure 11.1.1), an American railroad worker. Phineas Gage was working on a railroad when an iron rod he was using exploded and went through his head, damaging the left prefrontal cortex. He survived the accident, but according to second-hand accounts, some aspects of his personality changed, suggesting that the prefrontal cortex is an area of the brain responsible for personality. Today, functional MRI is used to map brain activity during specific functional tasks.

In this chapter, you will look at the structures that make the central nervous system and correlate them with their functions. The central nervous system includes the brain and spinal cord. First, you will take a look at how these structures are protected and supported.

Figure 11.1.1: Phineas Gage. Phineas Gage was a railroad constructor of the 19th century who lost part of his left frontal lobe to an explosion where an iron rod went through his brain. *(Image credit: "Phineas Gage Cased Daguerreotype WilgusPhoto2008-12-19 EnhancedRetouched Color" by Jack and Beverly Wilgus, Warren Anatomical Museum is licensed under CC BY-SA 3.0.)*

Contributors and Attributions

OpenStax Anatomy & Physiology (CC BY 4.0). Access for free at openstax.org/books/anatomy-and-physiology

This page titled 11.1: Introduction to the Central Nervous System is shared under a CC BY-NC-SA 4.0 license and was authored, remixed, and/or curated by Jennifer Lange et al..

- 12.1: Introduction to the Central and Peripheral Nervous System by Whitney Menefee, Julie Jenks, Chiara Mazzasette, and Kim-Leiloni Nguyen is licensed CC BY 4.0.

11.2: Support and Protection of the Brain

By the end of this section, you will be able to:

- Describe the meninges that protect the brain
- Describe the blood vessels that supply the brain
- Name the components of the ventricular system and the regions of the brain in which each is located
- Explain the production of cerebrospinal fluid and its flow through the ventricles

Protective Coverings of the Brain

The central nervous system (CNS) is crucial to the operation of the body and any compromise of function in the brain and spinal cord can lead to severe difficulties. The brain is protected by multiple structures. First, the bones of the skull enclose and house the brain. Underneath the skeletal structures, the brain is protected by membranes made of connective tissue, called **meninges**, that surround, support, stabilize and partition the nervous tissue (Figure 11.2.1). In addition, the brain has a privileged blood supply, as suggested by the blood-brain barrier. The function of the tissue is crucial to the survival of the organism, so the contents of the blood cannot simply pass into the central nervous tissue. To protect this region from the toxins and pathogens that may be traveling through the blood stream, there is strict control over what can move out of the general systems and into the brain. Because of this privilege, the brain needs specialized structures for the maintenance of circulation. This begins with a unique arrangement of blood vessels carrying fresh blood into the brain and venous sinuses carrying deoxygenated blood out of the brain. Beyond the supply of blood, the brain filters the blood into cerebrospinal fluid (CSF), which is then circulated through the cavities of the brain, such as the subarachnoid space and the ventricles.

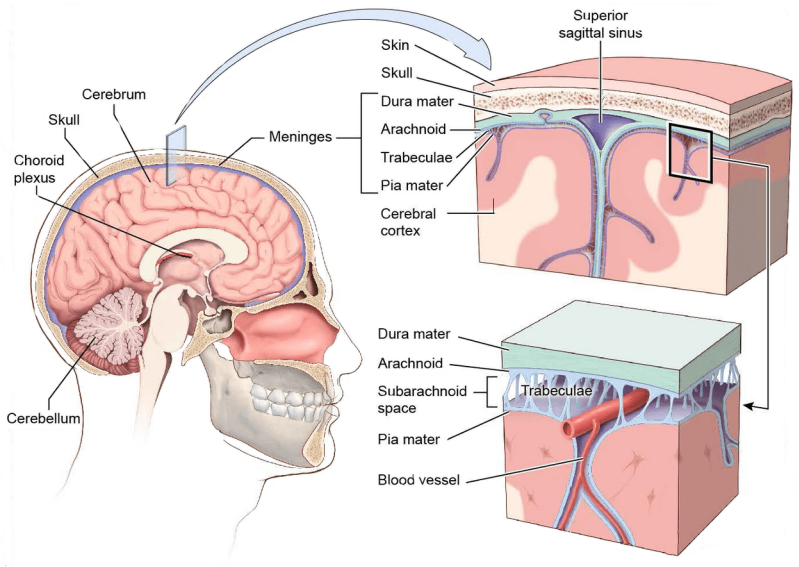

Figure 11.2.1: Protective structures of the brain. Superficially, the skin of the scalp and bones of the skull create the first layer of protection. Deep to these layers, the meninges (represented by the dura mater, arachnoid mater and pia mater) cover and partition the brain. Within the meninges, blood inside blood vessels and sinuses, and cerebrospinal fluid within the subarachnoid space and ventricles circulate to support the brain's function. *(Image credit: "Cranial Meninges" by Jennifer Lange is licensed under CC-BY-NC-SA 4.0, modification of image by NIH Medical Arts.)*

Cranial Meninges

The outer surface of the CNS is covered by a series of membranes, composed of connective tissue and mesothelial cells, called the meninges that protect, stabilize and partition the brain. From superficial to deep, the meningeal layers are the dura mater, arachnoid mater and pia mater. The **dura mater** is a thick fibrous layer and a strong protective sheath over the entire brain. It is anchored to the inner surface of the cranium and to the vertebral cavity. The **arachnoid mater** is a membrane of thin fibrous

tissue that forms a loose sac around the brain. Beneath the arachnoid mater, there is a space called the **subarachnoid space** where a thin, filamentous mesh form the **arachnoid trabeculae**, that looking like a spider web give this layer its name. Directly adjacent to the surface of the brain is the **pia mater**, a thin fibrous membrane that follows the superficial convolutions of the brain and fits into other grooves and indentations (Figure 11.2.2).

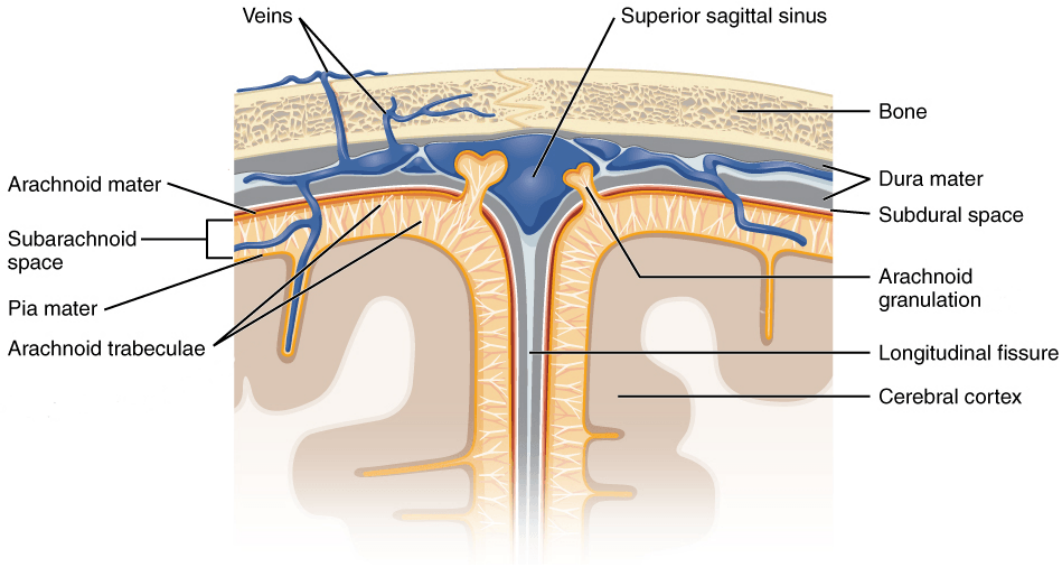

Figure 11.2.2: Meningeal Layers of the Brain. The layers of the meninges are shown under neath the bones of the skull. The dura mater is adjacent to the inner surface of the cranium. Within it, veins and the superior sagittal sinus lie. The pia mater is adjacent to the surface of the brain. The arachnoid and subarachnoid space are in-between. An arachnoid villus is shown emerging into the dural sinus to allow CSF to filter back into the blood for drainage. *(Image credit: "Meningeal Layers" by OpenStax is licensed under CC BY 4.0, modifications by Jennifer Lange.)*

Dura Mater

Like a thick cap covering the brain, the dura mater is a tough outer covering. The name comes from the Latin for “tough mother” to represent its physically protective role. It encloses the entire CNS and the major blood vessels that enter the cranium and vertebral cavity. It is directly attached to the inner surface of the bones of the cranium and to the walls of the foramen magnum and the C2-C3 vertebral canal. The dura mater of the brain has two layers, the **periosteal layer** (similar in structure to the periosteum of bones) is more superficial and attached to the skull, and the **meningeal layer** that lies deep to the periosteal layer. These two layers are usually fused together. However, in some regions of the brain they separate to form large space filled with venous blood called **dural sinuses**. The dura mater of the spinal cord is composed of only the meningeal layer. The region between the bones and the dura mater is called **epidural space**. In the cranium, the epidural space contains arteries and veins that supply and drain blood from the brain. In normal conditions, the cranial epidural space is a potential space and not a real space. However, trauma can cause the leakage of fluid (hematomas) which accumulates in the epidural space enlarging it and transforming it into a real space. In the vertebral column, the epidural space is a real space that contains areolar and adipose connective tissue for an extra layer of protective padding, as well as blood vessels. The spinal epidural space at the lumbar level is where epidural injections are administered. Deep to the dura mater, there is another potential space called the **subdural space**. As the epidural space, this space can be filled with fluid causing a subdural hematoma.

The meningeal layer of the dura mater extends into the cranial cavity at four locations. These flat partitions are called **cranial dural septa** and separate specific parts of the brain (Figure 11.2.3). The **falx cerebri** goes through the midline separation of the brain while the **falx cerebelli** separates the two cerebellar hemispheres. The **tentorium cerebelli** separates the cerebellum from the superior part of the brain (cerebrum), forming a shelf-like tent. Another partition called **diaphragma sellae** surrounds the pituitary gland.

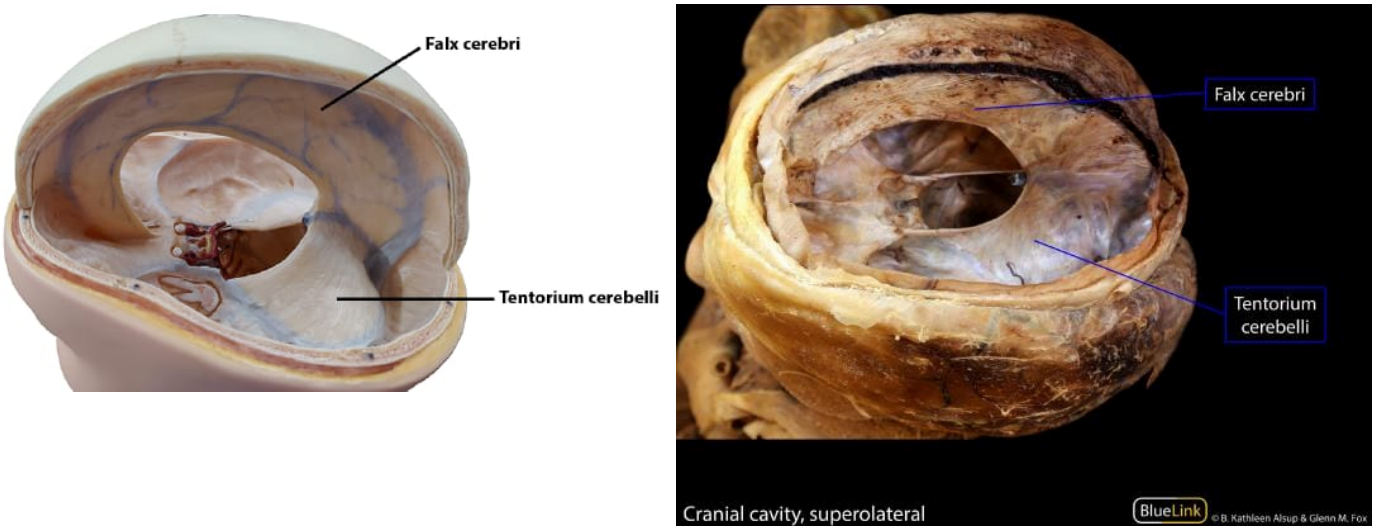

Figure 11.2.3: Cranial Dural Septa. The dura mater creates partitions called cranial dural septa. Two of these septa are the falx cerebri located in the longitudinal fissure and between the right and left cerebral hemispheres and the tentorium cerebelli between the cerebral occipital lobes and the cerebellum. *(Image credits: "Dural Septa" by Jennifer Lange is licensed under CC-BY-NC-SA 4.0; "Cranial Cavity, Superolateral" by BlueLink is licensed underCC BY-NC 4.0 with notification of the original authors.)*

Arachnoid Mater

Deep to the subdural space lies the middle layer of the meninges called the arachnoid mater (Figure 11.2.2). This layer is named for the spider-web–like projections called **arachnoid trabeculae** between this layer and the pia mater. The trabeculae are found crossing the **subarachnoid space**, which is filled with circulating CSF, making it a real space. The lining of the subarachnoid space is a modified epithelial layer, the mesothelium, that forms a continuous layer of cells providing a fluid-impermeable barrier between the CSF and the nervous tissue. One portion of the mesothelium is in the arachnoid mater, the second portion is found on the surface of the pia mater.

The arachnoid mater protrudes into the dural sinuses as the **arachnoid granulations**, where the CSF is filtered back into the blood for drainage from the nervous system.

Pia Mater

The outer surface of the CNS is covered in the thin, fibrous membrane of the pia mater (Figure 11.2.2). The name pia mater comes from the Latin for “tender mother,” suggesting the thin membrane is a gentle covering for the brain. The pia extends into every convolution of the CNS and anchors to the glial membrane that is part of the blood-brain barrier. Blood vessels that are nourishing the central nervous tissue are between the pia mater and the nervous tissue.

DISORDERS OF THE...

Meninges: Meningitis

Meningitis is an inflammation of the meninges, the three layers of fibrous membrane that surround the CNS (Figure 11.2.4). Meningitis can be caused by infection by bacteria or viruses. The particular pathogens are not special to meningitis; it is just an inflammation of that specific set of tissues from what might be a broader infection. Bacterial meningitis can be caused by Streptococcus, Staphylococcus, or the tuberculosis pathogen, among many others. Viral meningitis is usually the result of common enteroviruses (such as those that cause intestinal disorders), but may be the result of the herpes virus or West Nile virus. Bacterial meningitis tends to be more severe.

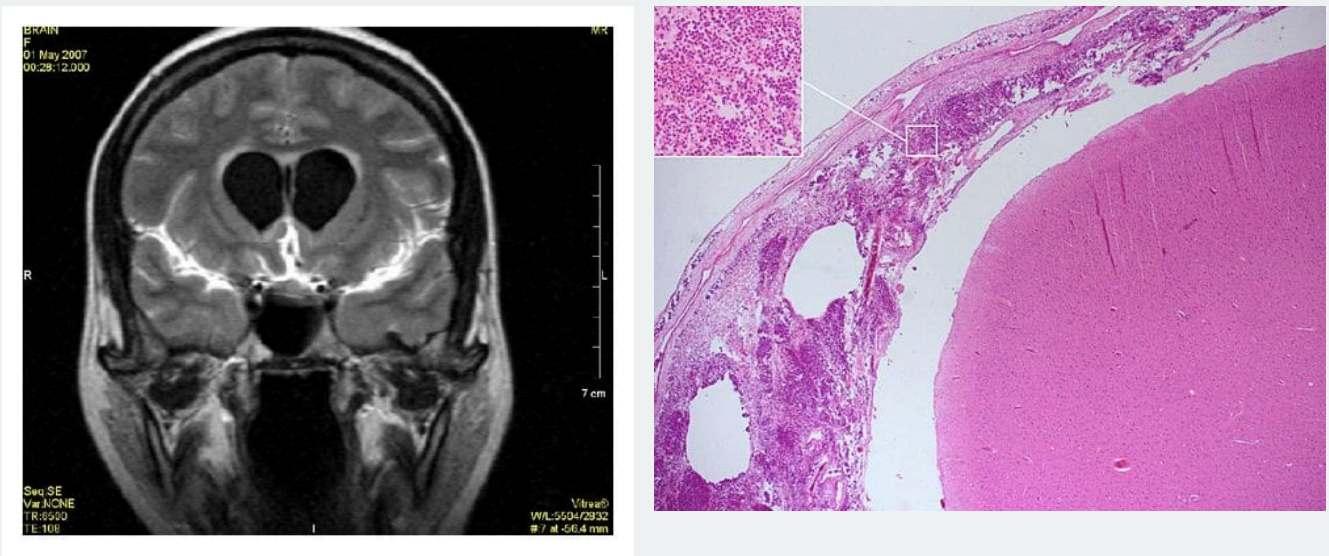

Figure 11.2.4: Meningitis. Inflammation from meningitis shows in an MRI as bright enhancements of meninges at the tentorium and in dilatation of the ventricles. White blood cells accumulate within the meningeal layers. *(Image credits: "FLAIR MRI of Meningitis" by Aneel Kumar Vaswani, Waseem Mehmood Nizamani, Muhammad Ali, Geeta Aneel, Bhesham Kumar Shahani, and Sajjad Hussain Uploaded by Mikael Häggström is licensed under CC BY 3.0, via Wikimedia Commons; "Meningitis Histopathology" by Marvin 101 is licensed under CC BY-SA 3.0, via Wikimedia Commons.)*

The symptoms associated with meningitis can be fever, chills, nausea, vomiting, light sensitivity, soreness of the neck, or severe headache. More important are the neurological symptoms, such as changes in mental state (confusion, memory deficits, and other dementia-type symptoms). A serious risk of meningitis can be damage to peripheral structures because of the nerves that pass through the meninges. Hearing loss is a common result of meningitis.

The primary test for meningitis is a lumbar puncture. A needle inserted into the lumbar region of the spinal column through the dura mater and arachnoid membrane into the subarachnoid space can be used to withdraw the fluid for chemical testing. Fatality occurs in 5 to 40 percent of children and 20 to 50 percent of adults with bacterial meningitis. Treatment of bacterial meningitis is through antibiotics, but viral meningitis cannot be treated with antibiotics because viruses do not respond to that type of drug. Fortunately, the viral forms are milder.

Blood Supply to the Brain

A lack of oxygen to the CNS can be devastating, and the cardiovascular system has specific regulatory reflexes to ensure that the blood supply is not interrupted. There are multiple routes for blood to get into the CNS, with specializations to protect that blood supply and to maximize the ability of the nervous tissue to get an uninterrupted perfusion.

Arterial Supply to the Brain

The major artery carrying recently oxygenated blood away from the heart is the aorta. The very first branches off the aorta supply the heart with nutrients and oxygen. The next branches give rise to the **common carotid arteries**, which further branch into the **internal carotid arteries**. The external carotid arteries supply blood to the tissues on the surface of the cranium. The internal carotid artery enters the cranium through the carotid canal in the temporal bone.

A second set of vessels that supply the CNS are the **vertebral arteries**, which are protected as they pass through the neck region by the transverse foramina of the cervical vertebrae. The vertebral arteries enter the cranium through the foramen magnum of the occipital bone. The two vertebral arteries then merge into the **basilar artery**, which gives rise to branches to the brainstem and cerebellum. The left and right internal carotid arteries and branches of the basilar artery all become the **circle of Willis**, a confluence of arteries that can maintain perfusion of the brain even if narrowing or a blockage limits flow through one part (Figure 11.2.5).

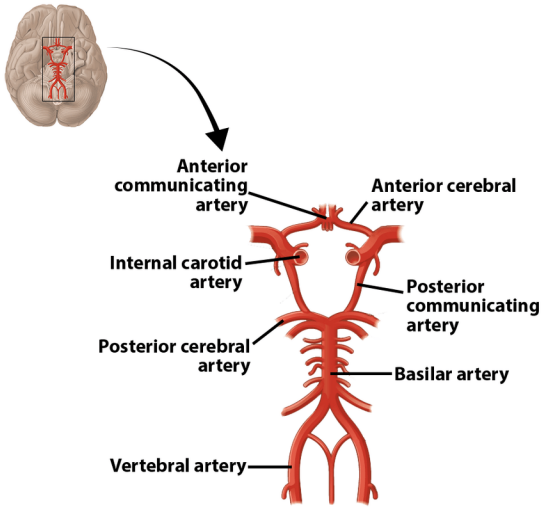

Figure 11.2.5: Circle of Willis. This inferior view shows the network of arteries serving the brain. The structure is referred to as the circle of Willis and is formed by branches of the internal carotid artery, vertebral artery and basilar artery. *(Image credit: "Cerebral Arteries" by Jennifer Lange using brain image by Justin Greene is licensed under CC-BY-NC-SA 4.0, Circle of Willis original image from OpenStax.)*

Interactive Link

Circle of Willis

Query 11.2.1

This interactive element is not available in this format. Visit the link or scan the QR code to access it online.

View this Interactive Content online

Venous Return from the Brain

After passing through the CNS, blood returns to the circulation through a series of **dural sinuses** and **cerebral veins** (Figure 11.2.6 and Figure 11.2.7). The dural sinuses are housed between the two layers of the dura mater:

- the **superior sagittal sinus** runs in the superficial aspect of the longitudinal fissure of the brain while the **inferior sagittal**

sinus runs deep in the fissure, just superior to the corpus callosum;

- at the posterior end of the corpus callosum the inferior sagittal sinus drains into the **straight sinus**, which then runs posteriorly across the superior midline surface of the cerebellum;
- the superior sagittal sinus and the straight sinus drain into the **confluence of the sinuses**, along with the **occipital sinus** coming from the inferior midline of the cerebellum, located at the point where the two cerebral hemispheres and the two cerebellar hemispheres meet;
- blood then flows into the **transverse sinuses** that travel laterally along the transverse cerebral fissure between the cerebrum and the cerebellum;
- the transverse sinuses connect to the **sigmoid sinuses**, which bend in an "S" shape to reach the jugular foramen and become the **jugular veins**. From there, the blood continues toward the heart to be pumped to the lungs for reoxygenation.

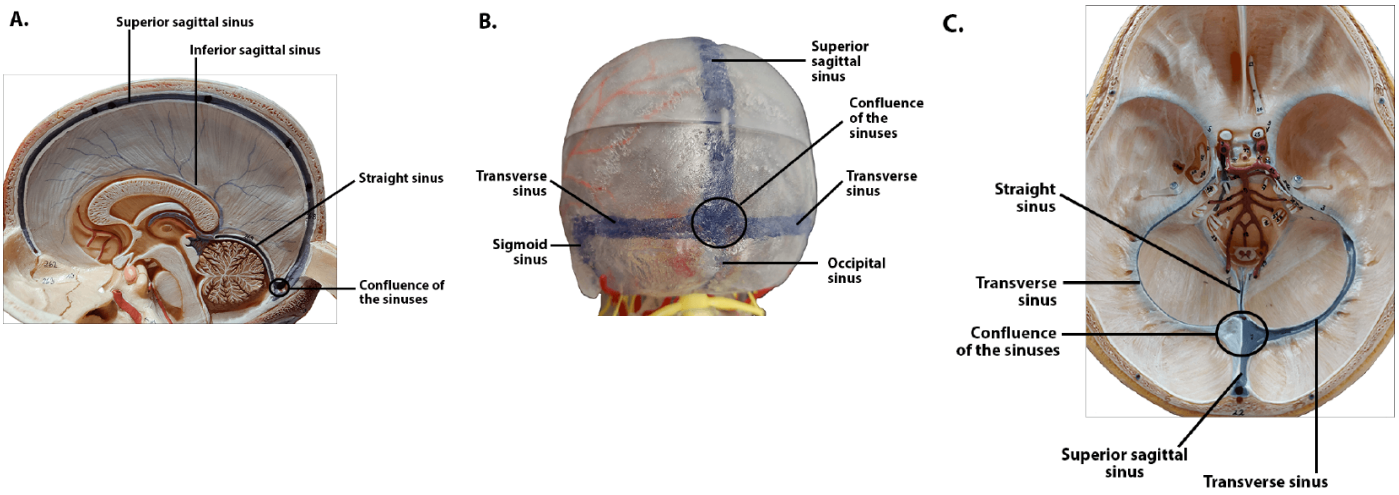

Figure 11.2.6: Locations of the Dural Sinuses. The larger dural sinuses run in the fissures of the brain - the longitudinal fissure between the right and left cerebral hemispheres and the transverse cerebral fissure between the cerebrum and the cerebellum. *(Image credit: "Dural Sinus Locations" by Jennifer Lange is licensed under CC-BY-NC-SA 4.0.)*

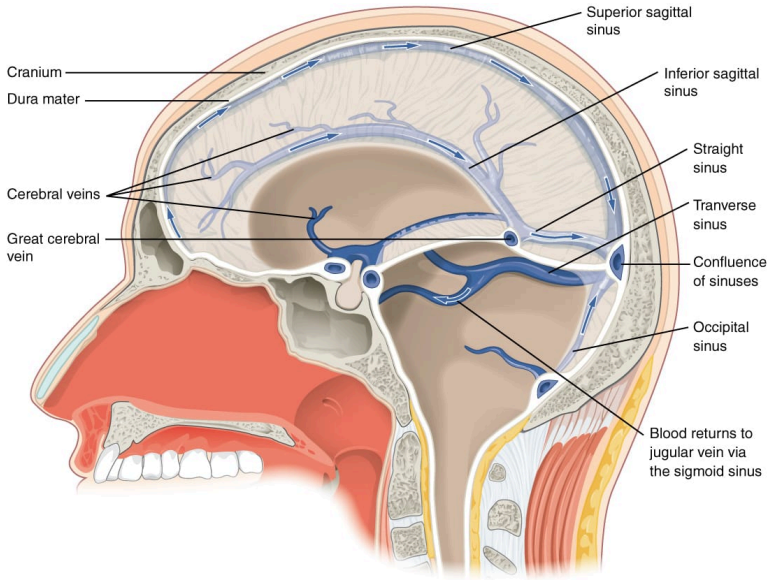

Figure 11.2.7: Flow Through Dural Sinuses. Blood drains from the brain through a series of sinuses and veins that connect to the jugular veins. (Image credit: "Brain Sinuses" by OpenStax is licensed under CC BY 4.0)

Explore 3D Brain Models

Explore the dural sinuses in 3D!

This interactive element is not available in this format. Visit the link or scan the QR code to access it online.

View this Interactive Content online

This interactive element is not available in this format. Visit the link or scan the QR code to access it online.

View this Interactive Content online

Visualizing the Dural Sinuses

MR cerebral venography (**MRV**) is an MRI examination of the head with either contrast-enhanced or non-contrast sequences to assess flow of the dural venous sinuses and cerebral veins. This test will be able to determine if an obstruction is reducing flow through one of the sinuses.

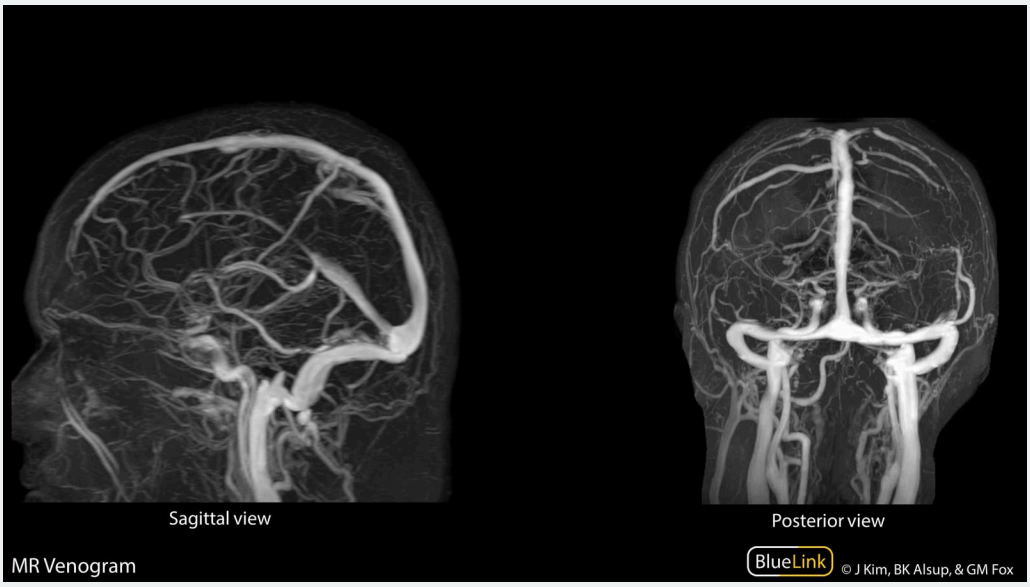

Figure 11.2.8: Normal MR Venogram - Sagittal and Posterior Views. All of the major dural sinuses can be clearly visualized. *(Image credit: "Slide16" from BlueLink is licensed under CC BY-NC 4.0 with notification of the original authors.)*

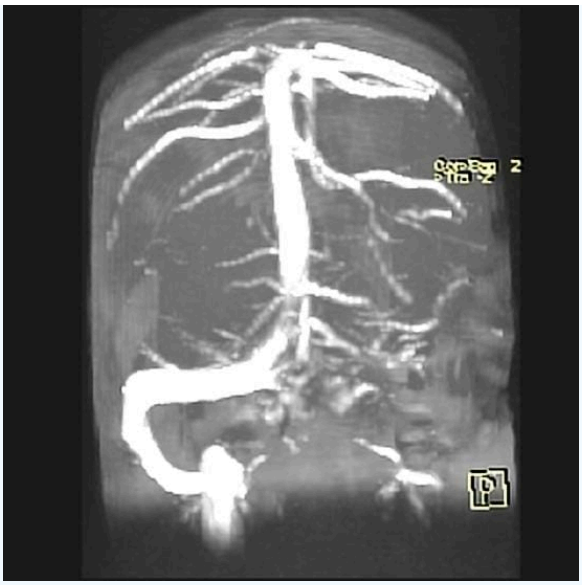

Figure 11.2.9: MRV Case Study. (*Case courtesy of Fadi Aidi, Radiopaedia.org, rID: 84329*)

Query 11.2.2

This interactive element is not available in this format. Visit the link or scan the QR code to access it online.

View this Interactive Content online

Ventricular System

Cerebrospinal fluid (CSF) is produced by a type of specialized membrane made of ependymal cells called a **choroid plexus**. Ependymal cells (one of the types of glial cells described in the introduction to the nervous system) surround blood capillaries and filter the blood to make CSF. The fluid is a clear solution with a limited amount of the constituents of blood. It is essentially water, small molecules, and electrolytes and is continuous with the interstitial fluid. Oxygen and carbon dioxide are dissolved into the CSF, as they are in blood, and can diffuse between the fluid and the nervous tissue. CSF circulates through the nervous tissue to remove metabolic wastes from the interstitial fluids of nervous tissues and return them to the blood stream. The choroid plexus lines open spaces within the brain called **ventricles**. The CSF circulates through all of the ventricles to eventually emerge into the subarachnoid space where it will be reabsorbed into the blood.

Ventricles

There are four ventricles within the brain, all of which developed from the original hollow space within the neural tube, the **central canal**. The first two are named the **lateral ventricles** and are deep within the cerebrum (Figure 11.2.10). The two lateral ventricles are shaped as a C and are located in the left and right hemispheres, and were at one time referred to as the first and second ventricles. These ventricles are connected to the **third ventricle** by two openings called the **interventricular foramina**. The third ventricle opens into a canal called the **cerebral aqueduct** that passes through the midbrain and connects the third ventricle to the **fourth ventricle**. The fourth ventricle is the space between the cerebellum and the pons and upper medulla (Figure 11.2.11). The ventricular system opens up to the subarachnoid space from the fourth ventricle. The single **median aperture** and the pair of **lateral apertures** connect to the subarachnoid space so that CSF can flow through the ventricles and around the outside of the CNS. From the fourth ventricle, CSF can continue down the central canal of the spinal cord.

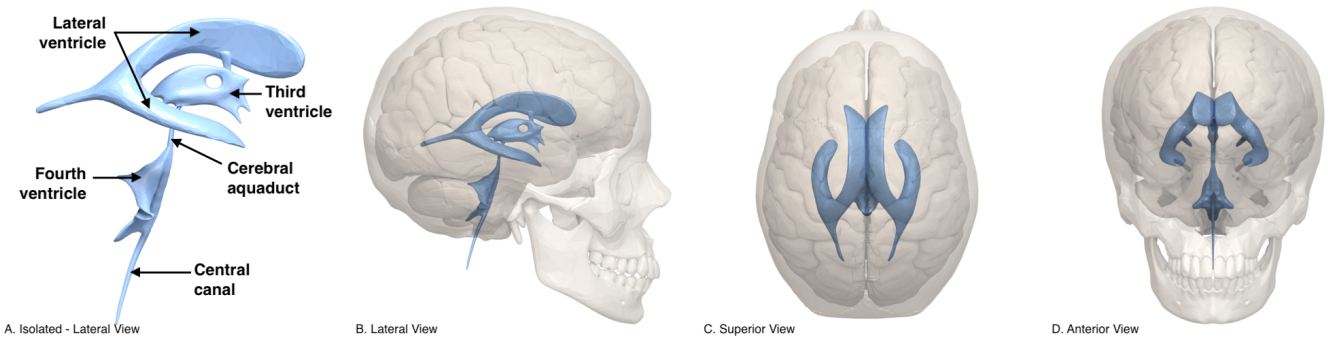

Figure 11.2.10: Ventricles. Within the brain, open spaces called ventricles are lined with ependymal cells that produce cerebrospinal fluid (CSF). Deep within the cerebral lobes are the lateral ventricles, which are connected to the third ventricle located in the diencephalon. The third ventricle opens into a canal called the cerebral aqueduct which connects to the fourth ventricle. The fourth ventricle is connected to the central canal of the spinal cord. *(Image credit: "Human Ventricular System" by BodyParts3D[1] by DBCLS. is licensed under CC BY-SA 2.1 JP, via Wikimedia Commons. Labeling by Jennifer Lange.)*

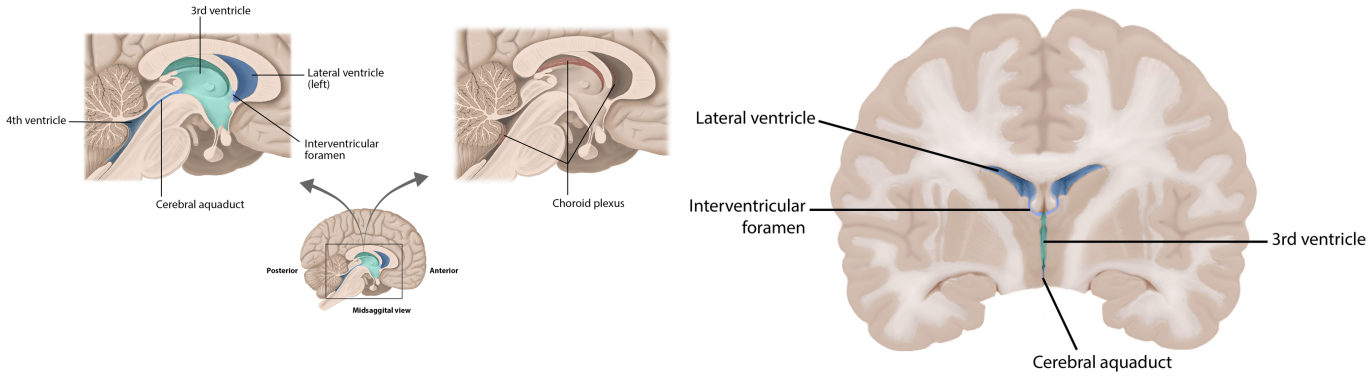

Figure 11.2.11: Brain Ventricles. The ventricles are open spaces within the brain that are partially seen within a single sagittal or coronal section. *(Image credits: "Brain Ventricles - Midsagittal View" by Justin Greene and Jennifer Lange is licensed under CC-BY-NC-SA 4.0, "Brain Ventricles - Coronal Section" by Jennifer Lange is licensed under CC-BY-NC-SA 4.0.)*

Explore 3D Brain Models

Explore the brain ventricles in 3D - you can enlarge each to full screen and then interact with the model.

This interactive element is not available in this format. Visit the link or scan the QR code to access it online.

View this Interactive Content online

Cerebrospinal Fluid Circulation

The choroid plexuses are found in all four ventricles (Figure 11.2.11). Observed in dissection, they appear as soft, fuzzy structures that may still be pink, depending on how well the circulatory system is cleared in preparation of the tissue. The CSF is produced from components extracted from the blood, so its flow out of the ventricles is tied to the pulse of cardiovascular circulation.

From the lateral ventricles, the CSF flows into the third ventricle, where more CSF is produced, and then through the cerebral aqueduct into the fourth ventricle where even more CSF is produced (Figure 11.2.12). A very small amount of CSF is filtered at any one of the plexuses, for a total of about 500 milliliters daily, but it is continuously made and pulses through the ventricular system, keeping the fluid moving. From the fourth ventricle, CSF can continue down the central canal of the spinal cord, but this is essentially a cul-de-sac, so more of the fluid leaves the ventricular system and moves into the subarachnoid space through the median and lateral apertures.

Within the subarachnoid space, the CSF flows around all of the CNS, providing two important functions. As with elsewhere in its circulation, the CSF picks up metabolic wastes from the nervous tissue and moves it out of the CNS. It also acts as a liquid cushion for the brain and spinal cord. By surrounding the entire system in the subarachnoid space, it provides a thin buffer around the organs within the strong, protective dura mater. The arachnoid granulations are outpocketings of the arachnoid membrane into the dural sinuses so that CSF can be reabsorbed into the blood, along with the metabolic wastes. From the dural sinuses, blood drains out of the head and neck through the jugular veins, along with the rest of the circulation for blood, to be reoxygenated by the lungs and wastes to be filtered out by the kidneys.

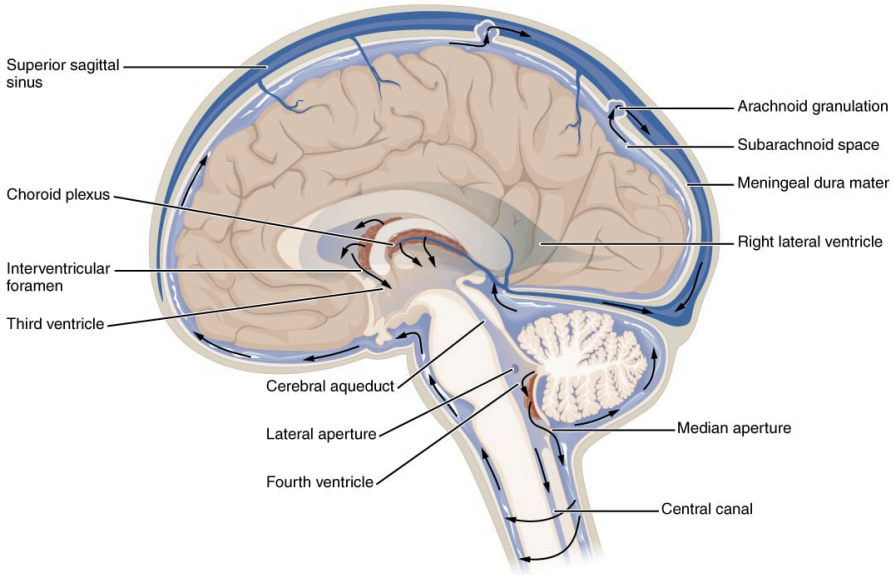

Figure 11.2.12: Cerebrospinal Fluid Circulation. The choroid plexus in all the ventricles produce CSF, which is circulated through the ventricular system and then enters the subarachnoid space through the median and lateral apertures. The CSF is then reabsorbed into the blood at the arachnoid granulations, where the arachnoid membrane emerges into the dural sinuses. *(Image credit: "CSF Circulation" by OpenStax is licensed under CC BY 4.0.)*

DISORDERS OF THE...

Central Nervous System: Strokes

The supply of blood to the brain is crucial to its ability to perform many functions. Without a steady supply of oxygen, and to a lesser extent glucose, the nervous tissue in the brain cannot keep up its extensive electrical activity. These nutrients get into the brain through the blood, and if blood flow is interrupted, neurological function is compromised.

The common name for a disruption of blood supply to the brain is a stroke. It is caused by a blockage to an artery in the brain or by blood leaking out of blood vessels (hemorrhagic stroke), see Figure 11.2.13. The blockage is caused by some type of embolus: a blood clot, a fat embolus, or an air bubble. When the blood cannot travel through the artery, the surrounding tissue that is deprived starves and dies. Strokes will often result in the loss of very specific functions. A stroke in the lateral medulla, for example, can cause a loss in the ability to swallow. Sometimes, seemingly unrelated functions will be lost because they are dependent on structures in the same region. Along with the swallowing in the previous example, a stroke in that region could affect sensory functions from the face or extremities because important white matter pathways also pass through the lateral medulla. Loss of blood flow to specific regions of the brain can lead to the loss of specific higher functions, from the ability to recognize faces to the ability to move a particular region of the body. Severe or limited memory loss can be the result of a temporal lobe stroke.

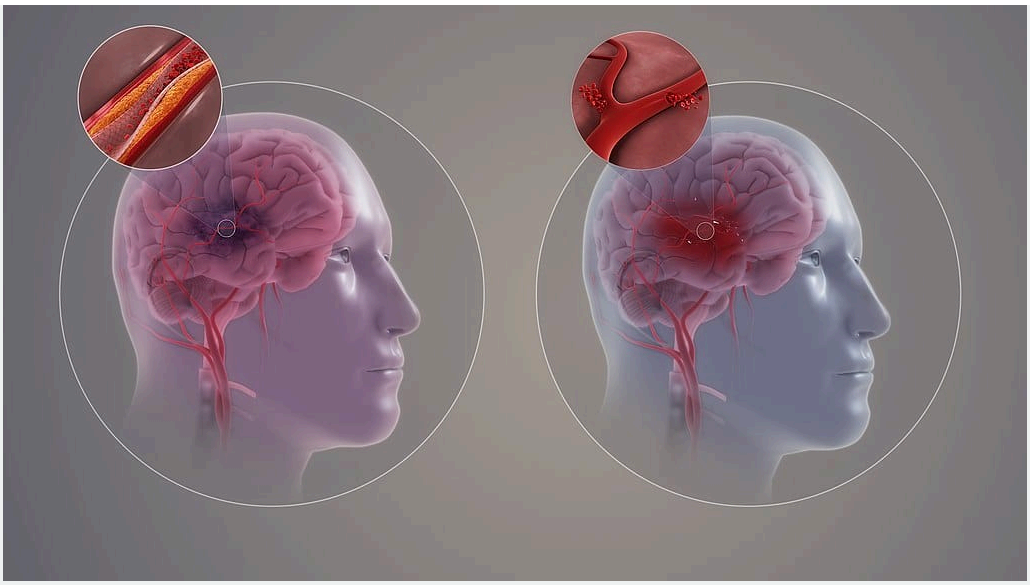

Figure 11.2.13: Types of Stroke. Blood clot stops blood flow to an area of the brain in Ischemic (left) whereas blood leaks into brain tissue in case of Hemorrhagic (right). *(Image credit: "Types of Stroke" by https://www.scientificanimations.com/, is licensed under CC BY-SA 4.0, via Wikimedia Commons.)*

Related to strokes are transient ischemic attacks (TIAs), which can also be called “mini-strokes.” These are events in which a physical blockage may be temporary, cutting off the blood supply and oxygen to a region, but not to the extent that it causes cell death in that region. While the neurons in that area are recovering from the event, neurological function may be lost. TIAs usually resolve spontaneously by the body, that is why it is called "transient".

Recovery from a stroke (or TIA) is strongly dependent on the speed of treatment. Often, the person who is present and notices something is wrong must then make a decision. The mnemonic FAST helps people remember what to look for when someone is dealing with sudden losses of neurological function. If someone complains of feeling “funny,” check these things quickly: Look at the person’s face. Does he or she have problems moving Face muscles and making regular facial expressions? Ask the person to raise his or her Arms above the head. Can the person lift one arm but not the other? Has the person’s Speech changed? Is he or she slurring words or having trouble saying things? If any of these things have happened, then it is Time to call for help.

Sometimes, treatment with blood-thinning drugs can alleviate the problem, and recovery is possible. If the tissue is damaged, the amazing thing about the nervous system is that it is adaptable. With physical, occupational, and speech therapy, victims of strokes can recover, or more accurately relearn, functions.

Concept Review

The CNS has a privileged blood supply established by the blood-brain barrier. Establishing this barrier are anatomical structures that help to protect and isolate the CNS. The skull and vertebral column are the first mean of protection of the brain and spinal cord, respectively. Layers of connective tissue called meninges support and stabilize the brain and spinal cord, as well as partition the brain into specific regions. The outer layer is the dura mater, the middle layer is the arachnoid mater and the inner layer is the pia mater.

The arterial blood to the brain comes from the internal carotid and vertebral arteries, which both contribute to the unique circle of Willis that provides constant perfusion of the brain even if one of the blood vessels is blocked or narrowed. That blood is eventually filtered to make a separate medium, the CSF, that circulates within the spaces of the brain and then into the surrounding space defined by the meninges, the protective covering of the brain and spinal cord.

The blood that nourishes the brain and spinal cord is behind the glial-cell–enforced blood-brain barrier, which limits the exchange of material from blood vessels with the interstitial fluid of the nervous tissue. Thus, metabolic wastes are collected in cerebrospinal fluid that circulates through the CNS. This fluid is produced by filtering blood at the choroid plexuses in the four

ventricles of the brain. It then circulates through the ventricles and into the subarachnoid space, between the pia mater and the arachnoid mater. From the arachnoid granulations, CSF is reabsorbed into the blood, removing the waste from the privileged central nervous tissue.

The blood, now with the reabsorbed CSF, drains out of the cranium through the dural sinuses. The dura mater is the tough outer covering of the CNS, which is anchored to the inner surface of the cranial and vertebral cavities. It surrounds the venous space known as the dural sinuses, which connect to the jugular veins, where blood drains from the head and neck.

Review Questions

Query 11.2.3

This interactive element is not available in this format. Visit the link or scan the QR code to access it online.

View this Interactive Content online

Critical Thinking Questions

Query 11.2.4

This interactive element is not available in this format. Visit the link or scan the QR code to access it online.

View this Interactive Content online

Query 11.2.5

This interactive element is not available in this format. Visit the link or scan the QR code to access it online.

View this Interactive Content online

Glossary

Query 11.2.6

This interactive element is not available in this format. Visit the link or scan the QR code to access it online.

View this Interactive Content online

Contributors and Attributions

OpenStax Anatomy & Physiology (CC BY 4.0). Access for free at https://openstax.org/books/anatomy-and-physiology

Figure	Image Credit
Figure 20.1.1: Mountain Climbers.	Image credit: "Aiguille du Midi, Mont-Blanc" by Cristian Bortes is licensed under CC BY 2.0

This page titled 11.2: Support and Protection of the Brain is shared under a CC BY-NC-SA 4.0 license and was authored, remixed, and/or curated by Jennifer Lange et al..

- 12.2: Support and Protection of the Brain by Whitney Menefee, Julie Jenks, Chiara Mazzasette, and Kim-Leiloni Nguyen is licensed CC BY 4.0.

11.3: Brain - Cerebrum

By the end of this section, you will be able to:

- Name the major regions of the adult brain
- Identify the anatomical structures of the cerebrum
- Identify the tracts associated with the white matter of the cerebrum and describe their functions
- Describe the components of the cerebral nuclei
- Describe the functional areas of the cerebral cortex and their locations

The organs of the central nervous system are the brain and spinal cord. The brain is described in terms of four major regions: the **cerebrum**, the **diencephalon**, the **brainstem**, and the **cerebellum** (Figure 11.3.1). The iconic gray mantle of the human brain, which appears to make up most of the mass of the brain, is the cerebrum. Many of the higher neurological functions, such as memory, emotion, and consciousness, are the result of cerebral function. The cerebrum is divided into different regions called lobes. Overall, the functions of the cerebrum are initiation and coordination of movement, processing of general and special senses, and high level functions such as judgment, reasoning, problem solving, and learning.

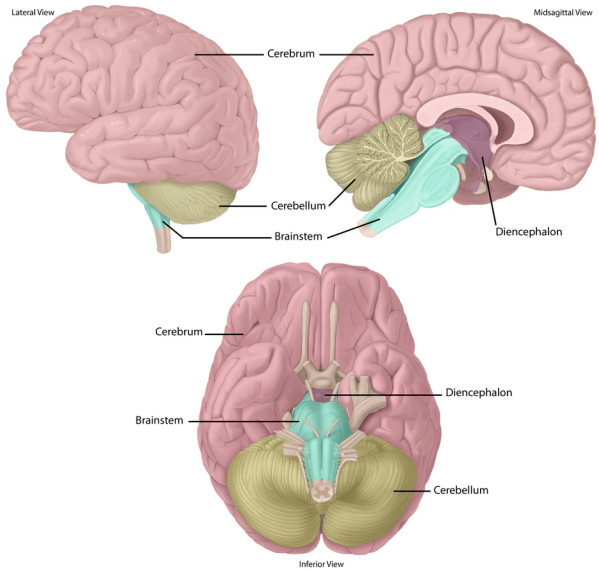

Figure 11.3.1: Major Brain Regions. On the external, lateral surface only three of the four major regions are visible: the cerebrum, the brainstem, and the cerebellum. The diencephalon is deep within the brain and can be seen in both inferior and midsagittal views. *(Image credit: "Major Brain Regions" by Justin Greene and Jennifer Lange is licensed under CC BY-NC-SA 4.0)*

Cerebrum

The cerebrum is covered by a continuous layer of gray matter that wraps around either side of the forebrain—the cerebral cortex. This thin, extensive region of wrinkled gray matter is responsible for the higher functions of the nervous system. A **gyrus** (plural = gyri) is the ridge of one of those wrinkles, and a **sulcus** (plural = sulci) is the groove between two gyri (Figure 11.3.2 and Figure 11.3.3). The pattern of these folds of tissue indicates specific regions of the cerebral cortex. The brain must fit inside the cranial cavity of the skull. Extensive folding in the cerebral cortex enables more gray matter to fit into this limited space. If the gray matter of the cortex were peeled off of the cerebrum and laid out flat, its surface area would be roughly equal to one square meter. The folding of the cortex maximizes the amount of gray matter in the cranial cavity. During embryonic development, as the telencephalon expands within the skull, the brain goes through a regular course of growth that results in everyone's brain having a similar pattern of folds.

The surface of the brain can be mapped on the basis of the locations of large gyri and sulci. Three deep sulci are visible: the **central sulcus**, the **lateral fissure (sulcus)** and the **parietoccipital sulcus**. Anterior to the central sulcus is the **precentral**

gyrus, while posterior to the central sulcus is the **postcentral gyrus** (Figure 11.3.2). There is a large separation between the two sides of the cerebrum called the **longitudinal fissure** (Figure 11.3.3). It separates the cerebrum into two distinct halves, a right and left **cerebral hemispheres**.

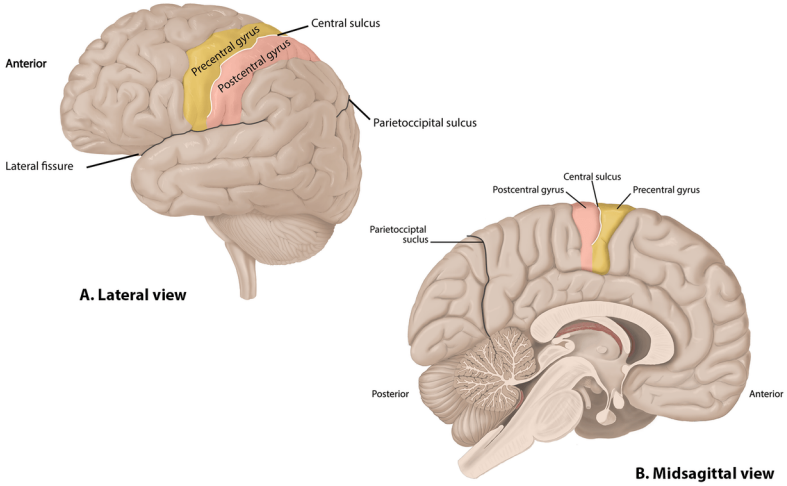

Figure 11.3.2: Cerebrum: Major Gyri and Sulci, Lateral View. The cerebrum presents ridges called gyri and grooves called sulci. The main sulci are the central sulcus, lateral fissure (sulcus) and parieto-occipital sulcus. The gyrus anterior to the central sulcus is called precentral gyrus, while the posterior one is the postcentral gyrus. *(Image credit: "Gyrus and Sulcus - Lateral and Midsagittal Views" by Justin Greene and Jennifer Lange is licensed under CC BY-NC-SA 4.0)*

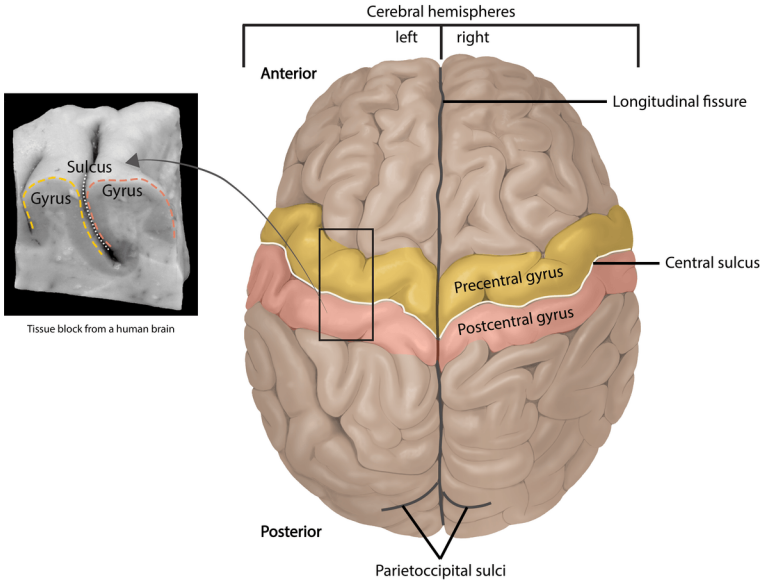

Figure 11.3.3: Superior View of the Brain. The cerebrum is medially divided by the longitudinal fissure into left and right hemispheres. The central sulcus is visible cutting the cerebrum in a coronal section. The gyrus anterior to the central sulcus is called precentral gyrus, while the posterior one is the postcentral gyrus. The enlargement shows a human brain tissue block containing the central sulcus and the two adjacent gyri. *(Image credit: "Gyrus and Sulcus - Superior View" by Justin Greene and Jennifer Lange is licensed under CC BY-NC-SA 4.0; inset image: "Pre- and Post-central gyrus" by Geyer S, Weiss M, Reimann K, Lohmann G and Turner R, via Wikimedia Commons, as modified by Jennifer Lange is licensed under CC BY-NC-SA 4.0.)*

The cerebrum comprises the outer wrinkled gray matter that is the **cerebral cortex** (from the Latin word meaning “bark of a tree”), the inner white matter that forms **tracts**, and several deep (subcortical) nuclei called **basal ganglia** (Figure 11.3.4). Deep within the cerebrum, the white matter of the **corpus callosum** provides the major pathway for communication between the two hemispheres of the cerebral cortex.

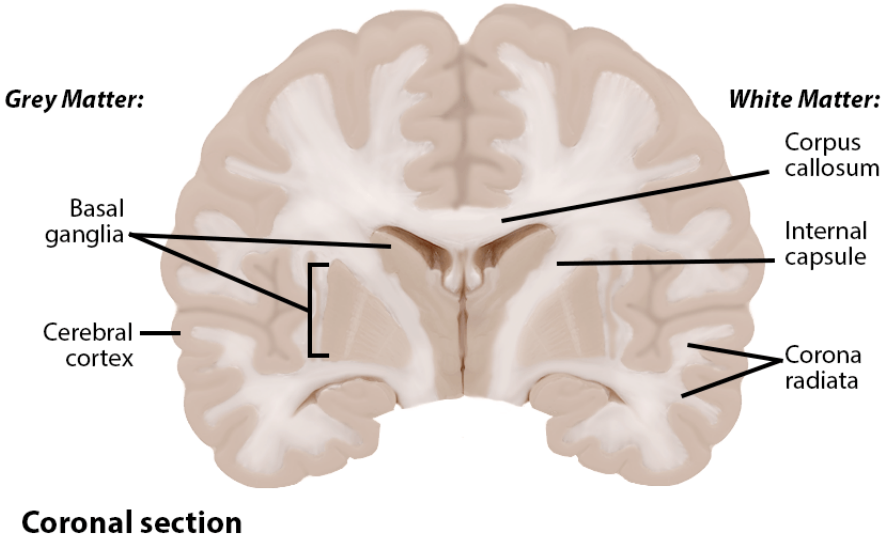

Figure 11.3.4: Coronal Section of the Brain. The coronal section shows the layers of the cerebrum. The superficial gray matter is called cerebral cortex, while the deep gray matter is composed of multiple nuclei called the basal ganglia (nuclei). The superficial and deep regions are connected by myelinated axons (white matter) called tracts. These tracts include the corpus callosum and the internal capsule. The corona radiata contains tracts of multiple fibers leading to and from the cortex. *(Image credit: "Brain Coronal Section - Grey and White Matter" by Jennifer Lange is licensed under CC BY-NC-SA 4.0.)*

Cerebral Cortex

The cortex can be separated into major regions called lobes (Figure 11.3.5). The lateral sulcus separates the **temporal lobe** from the other regions. Deep to the lateral sulcus is another lobe called **insula** (shown in Figure 11.3.5). Superior to the lateral sulcus are the **parietal lobe** and **frontal lobe**, which are separated from each other by the central sulcus. The posterior region of the cortex is the **occipital lobe**, which has no obvious anatomical border between it and the parietal or temporal lobes on the lateral surface of the brain. From the medial surface, an obvious landmark separating the parietal and occipital lobes is called the parieto-occipital sulcus (Figure 11.3.2).

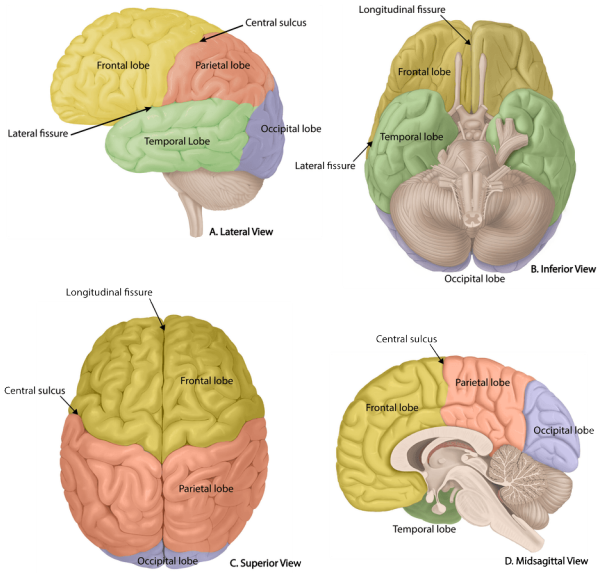

Figure 11.3.5: Lobes of the Cerebral Cortex. The cerebral cortex is divided into four lobes by the major sulci. The central sulcus separates the frontal and parietal lobes. The parieto-occipital sulcus separates the parietal and occipital lobes. The lateral sulcus separated the temporal and parietal lobes. The fifth lobe is the insula which is deep to the frontal and temporal lobes (not shown here). Each lobe corresponds to specific functions of the cerebral cortex. *(Image credit: "Lobes of the Cerebral Cortex" by Justin Greene and Jennifer Lange is licensed under CC BY-NC-SA 4.0.)*

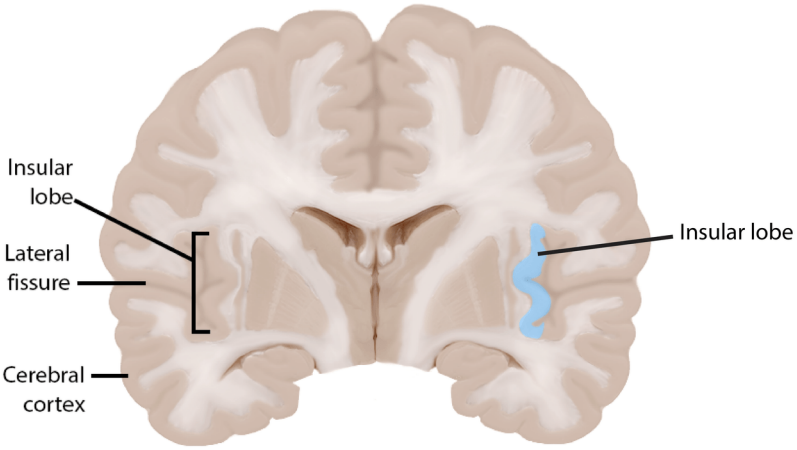

Figure 11.3.6: Insular Lobe. The insula is one of the five lobes of the cerebral cortex and is located deep in the lateral fissure, between the parietal and temporal lobes. *(Image credit: "Insular Lobe - Coronal Section" by Jennifer Lange is licensed under CC BY-NC-SA 4.0.)*

DISORDERS OF THE

Cerebral Cortex: Concussion

A concussion, also known as a mild traumatic brain injury (mTBI), is a head injury that temporarily affects brain functioning. The mechanism of injury involves either a direct blow to the head or forces elsewhere on the body that are transmitted to the head. The brain is surrounded by cerebrospinal fluid, which protects it from light trauma, but more severe impacts, or the forces associated with rapid acceleration and/or deceleration, may not be absorbed by this cushion and these forces are transferred to the brain. Such forces can occur when the head is struck by an object or surface (a 'direct impact'), or when the torso rapidly changes position (i.e. from a body check) and force is transmitted to the head (an 'indirect impact'). These strong forces cause the brain to move within the cerebral cavity and come in contact with the skull. Which part of the cerebral cortex strikes the cranial bones depends on the direction of the force, but the most common is an anterior movement followed by a reactive posterior movement that will affect both the frontal lobe and the occipital lobe. Many of the stereotypical concussion checks are examining the functioning of these two lobes: 'how many fingers am I holding up' checks for blurred vision, 'what day is today' and 'who is the president' are checking for memory recall and clarity of thinking. More serious injury may occur involving damage to the brainstem.

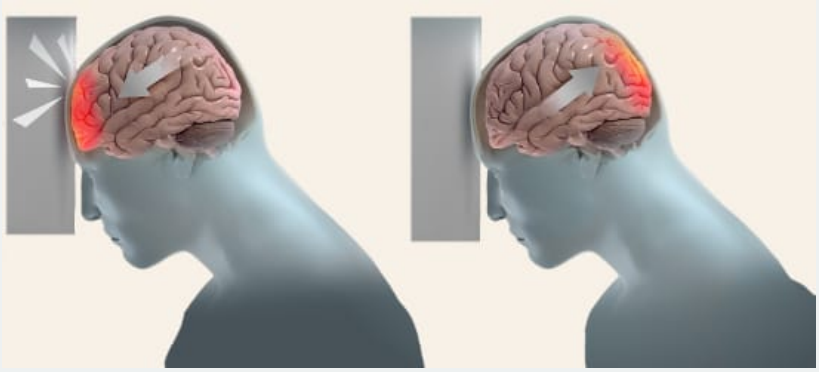

Figure 11.3.7: Concussion. A strong, sudden impact with an object can cause the brain to swing forward and then backward, causing the frontal and occipital/partial lobes to contact the skull. *(Image credit: "Concussion" by Scientific Animations, modified by Jennifer Lange Jennifer Lange is licensed under CC BY-NC-SA 4.0.)*

Symptoms may include loss of consciousness; memory loss; headaches; difficulty with thinking, concentration, or balance; nausea; blurred vision; dizziness; sleep disturbances, and mood changes. Any of these symptoms may begin immediately, or appear days after the injury.

Basal Ganglia

The basal ganglia are a group of subcortical nuclei, meaning groups of neurons that lie below the cerebral cortex. The basal ganglia is comprised of the striatum, which consists of the **caudate** nucleus and the **putamen**, the **globus pallidus**, the subthalamic nucleus in the diencephalon, and the substantia nigra in the brainstem. The basal ganglia are primarily associated with motor control, since motor disorders such as Parkinson's or Huntington's diseases stem from dysfunction of neurons within the basal nuclei. For voluntary motor behavior, the basal ganglia are involved in the initiation or suppression of behavior and can regulate movement through modulating activity in the thalamus and cortex. In addition to motor control, the basal ganglia also communicate with non-motor regions of the cerebral cortex and play a role in other behaviors such as emotional and cognitive processing.

The caudate is a long nucleus that follows the basic C-shape of the cerebrum from the frontal lobe, through the parietal and occipital lobes, into the temporal lobe. The putamen is mostly deep in the anterior regions of the frontal and parietal lobes. Together, the caudate and putamen are called the **striatum**. The globus pallidus is a layered nucleus that lies just medial to the putamen. The globus pallidus has two subdivisions, the external and internal segments, which are lateral and medial, respectively. These nuclei are depicted in a frontal section of the brain in Figure 11.3.8.

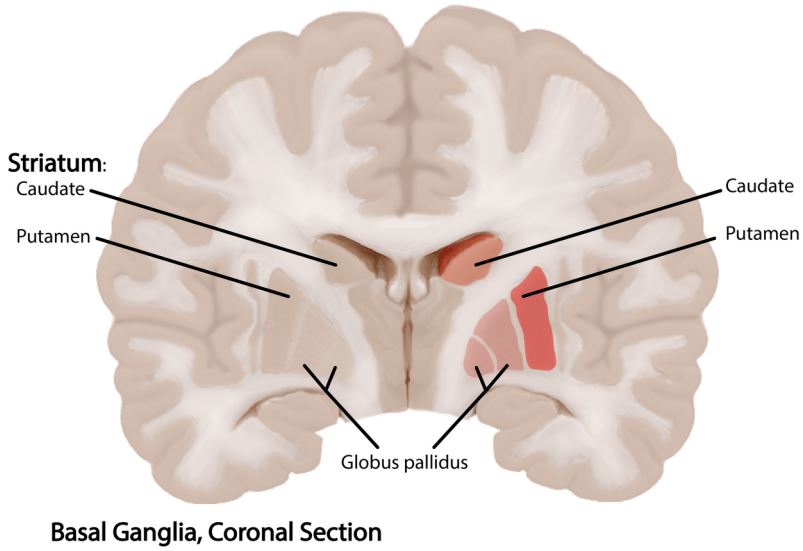

Figure 11.3.8: Frontal Section of Cerebral Cortex and Basal Ganglia. The major components of the basal ganglia, shown in a frontal section of the brain, are deep within the cerebrum. The caudate is just lateral to the lateral ventricle. The putamen is inferior to the caudate and separated by the internal capsule. The globus pallidus is medial to the putamen. *(Image credit: "Basal Ganglia - Coronal Section" by Jennifer Lange is licensed under CC BY-NC-SA 4.0.)*

White Matter Tracts

The white matter lies deep to the cerebral cortex and is mainly made by myelinated axons, which gives the white appearance. The axons are grouped into bundles called **tracts** that connect different regions of the cerebral cortex to integrate information and motor response. The white matter tracts of the cerebrum can be classified into three groups: **commissural tracts**, **association tracts** and **projection tracts** (Figure 11.3.9).

Commissural tracts extend between the two hemispheres to connect left and right regions of the cerebrum. The most prominent commissural tract, and largest white matter structure, is the **corpus callosum**. Association tracts connect different regions within the same hemisphere. Association tracts can be classified into **arcuate fibers** when they connect gyri of the same lobe or **longitudinal fasciculi** when they connect gyri in different lobes of the same hemisphere. Projection tracts extend from the cerebral cortex to the inferior regions of the brain and to the spinal cord.

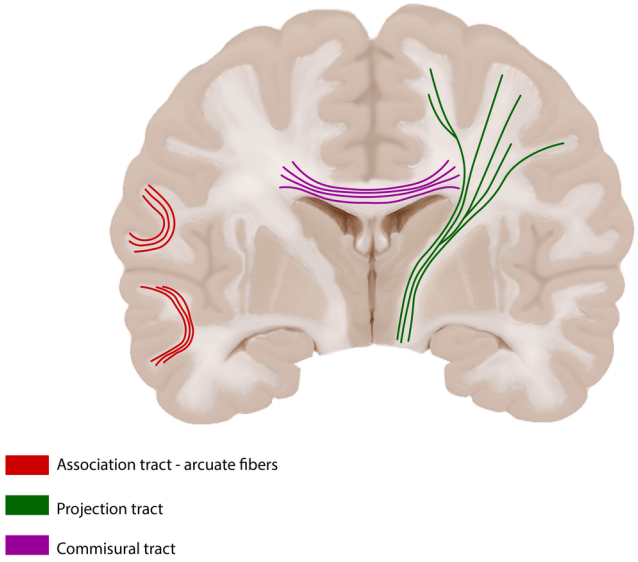

Figure 11.3.9: White Matter Tracts. The white matter of the cerebrum is organized in tracts that connect lobes and gyri within lobes. Association tracts include arcuate fibers (red) that connect gyri of the same lobe, while longitudinal fibers (not shown) connect different lobes of the same hemisphere. Commissural tracts (such as the corpus callosum, in purple) connect the two hemispheres. Projection tracts (in green) connect the cerebral cortex to inferior regions of the brain or spinal cord. *(Image credit: "White Matter Tracts" by Jennifer Lange is licensed under CC BY-NC-SA 4.0.)*

Everyday Connections

Left Brain, Right Brain

Popular media often refer to right-brained and left-brained people, as if the brain were two independent halves that work differently for different people. This is a popular misinterpretation of an important neurological phenomenon. As an extreme measure to deal with a debilitating condition, the corpus callosum may be sectioned to overcome intractable epilepsy. When the connections between the two cerebral hemispheres are cut, interesting effects can be observed.

If a person with an intact corpus callosum is asked to put their hands in their pockets and describe what is there on the basis of what their hands feel, they might say that they have keys in their right pocket and loose change in the left. They may even be able to count the coins in their pocket and say if they can afford to buy a candy bar from the vending machine. If a person with a sectioned corpus callosum is given the same instructions, they will do something quite peculiar. They will only put their right hand in their pocket and say they have keys there. They will not even move their left hand, much less report that there is loose change in the left pocket.

This interactive element is not available in this format. Visit the link or scan the QR code to access it online.

View this YouTube Video online

The reason for this is that the language functions of the cerebral cortex are localized to the left hemisphere in 95 percent of the population. Additionally, the left hemisphere is connected to the right side of the body through the corticospinal tract and the ascending tracts of the spinal cord. Motor commands from the precentral gyrus control the opposite side of the body, whereas sensory information processed by the postcentral gyrus is received from the opposite side of the body. For a verbal command to initiate movement of the right arm and hand, the left side of the brain needs to be connected by the corpus callosum. Language is processed in the left side of the brain and directly influences the left brain and right arm motor functions, but is sent to influence the right brain and left arm motor

functions through the corpus callosum. Likewise, the left-handed sensory perception of what is in the left pocket travels across the corpus callosum from the right brain, so no verbal report on those contents would be possible if the hand happened to be in the pocket.

Functional Areas of the Cerebrum

The cerebrum is responsible for the perception of sensation and for controlling the skeletal muscles. The cerebrum is also the seat of many of the higher mental functions, such as memory and learning, and language. These higher functions are distributed across various regions of the cortex, and specific locations can be said to be responsible for particular functions.

The frontal lobe is responsible for motor functions, from planning movements through executing commands to be sent to the spinal cord and periphery. The most anterior portion of the frontal lobe is the prefrontal cortex, which is associated with aspects of personality through its influence on motor responses in decision-making. The other lobes are responsible for sensory functions. The main sensation associated with the parietal lobe is **somatosensation**, meaning the general sensations associated with the body. The occipital lobe is where visual processing begins, although the other parts of the brain can contribute to visual function. The temporal lobe contains the cortical area for auditory processing, but also has regions crucial for memory formation. The insula is responsible for processing of taste sensation.

In the early 1900's, a German neuroscientist named Korbinian Brodmann performed an extensive study of the microscopic anatomy—the cytoarchitecture—of the cerebral cortex and divided the cortex into 52 separate regions on the basis of the histology of the cortex. His work resulted in a system of classification known as **Brodmann's areas**, which is still used today to describe the anatomical distinctions within the cortex (Figure 11.3.7). Continued investigation into these anatomical areas over the subsequent 100 or more years has demonstrated a strong correlation between the structures and the functions attributed to those structures. Today, we more frequently refer to these regions by their function (i.e., primary visual cortex) than by the number Brodmann assigned to them. The **primary cortical areas** are where sensory information is initially received for conscious perception or where descending motor commands are sent down to the brainstem or spinal cord to execute movements. The regions near the primary areas are each referred to as **association areas**.

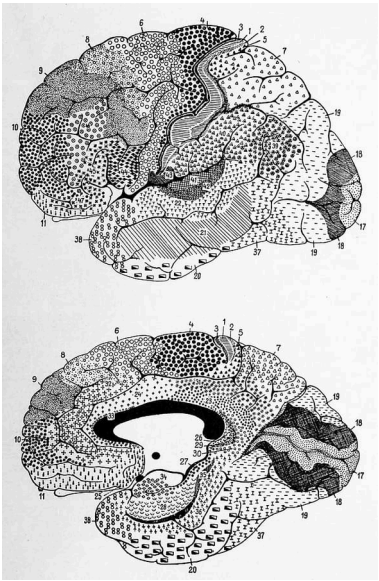

Figure 11.3.7: Brodmann's Areas of the Cerebral Cortex. On the basis of cytoarchitecture, the anatomist Korbinian Brodmann described the extensive array of cortical regions called areas and assigned to them a number, as illustrated in this figure. This is the original image from his 1909 book: Brodmann, Korbinian (1909) (in German) *Vergleichende Lokalisationslehre der Grosshirnrinde in ihren Prinzipien dargestellt auf Grund des Zellenbaues*, Leipzig: Johann Ambrosius Barth OCLC: 1040552818.

The cortical areas in the parietal, temporal, and occipital lobes are involved in conscious sensation of stimuli. In the postcentral gyrus of the parietal lobe, we find the first three areas in Brodmann's list which compose the **primary somatosensory cortex** (Figure 11.3.8). All of the tactile senses are processed in this area, including touch, pressure, tickle, pain, itch, and vibration, as well as more general senses of the body such as proprioception and kinesthesia, which are the senses of body position and movement, respectively. Next to it in the parietal lobe there is the **sensory association area** which helps the primary area to

process somatosensation.

In the most posterior part of the occipital lobe the **primary visual cortex** receives and begins processing visual information. Adjacent regions are **visual association areas**, which constitute subsequent regions of visual processing.

In the temporal lobe is the **primary auditory cortex,** where information regarding sounds detected by the inner ear are first processed, and the **auditory association area**, which further processes auditory information. Also, deep in the temporal lobe is the **primary olfactory cortex** that processes smell.

The **primary gustatory cortex** is located in the insula and is responsible for processing taste information.

The regions that control motor functions are located within the frontal lobes. In the precentral gyrus is the **primary motor cortex**. Cells from this region of the cerebral cortex are the upper motor neurons that instruct cells in the brainstem and spinal cord to move skeletal muscles. Anterior to the precentral gyrus are the motor association areas of the **premotor cortex** and the **supplementary motor cortex.** These regions help to plan and coordinate complex movements and are also involved in speech production and memory.

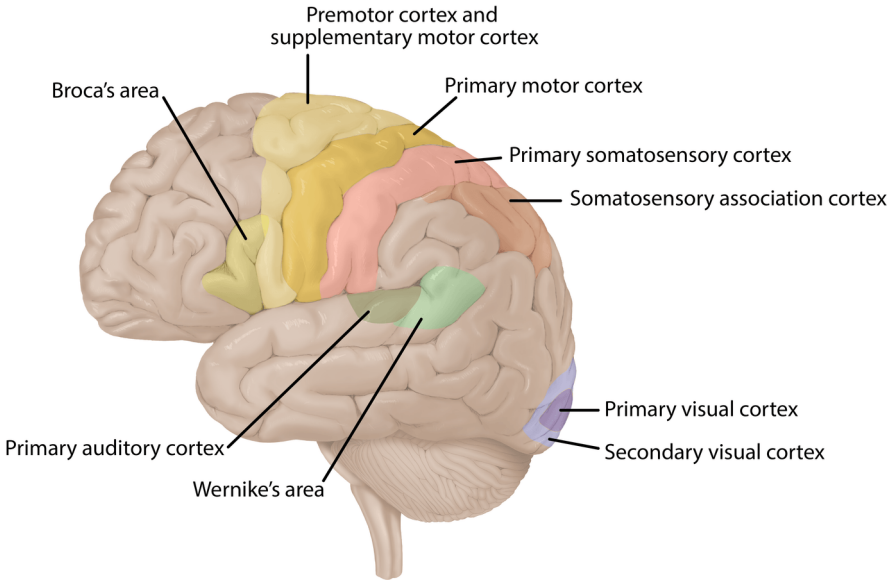

Figure 11.3.8: Functional Cortical Areas. The functions of the cerebral cortex are localized within their respective lobes. Although the exact boundaries can vary from person to person, their general area and their relative positions remain the same. *(Image credit: "Functional Areas of the Cerebral Cortex" by Justin Greene and Jennifer Lange is licensed under CC BY-NC-SA 4.0.)*

The primary somatosensory and motor cortices provide an example of the mapping of the human body in different regions of the cortex. The term homunculus comes from the Latin word for "little man" and refers to a map of the human body that is laid across a portion of the cerebral cortex. The sensory receptors are mapped onto the somatosensory cortex and this mapping is called a **sensory homunculus** (Figure 11.3.9.A). In the somatosensory cortex, the external genitals, feet, and lower legs are represented on the medial face of the gyrus within the longitudinal fissure. As the gyrus curves out of the fissure and along the surface of the parietal lobe, the body map continues through the thighs, hips, trunk, shoulders, arms, and hands. The head and face are just lateral to the fingers as the gyrus approaches the lateral sulcus. The representation of the body in this topographical map is medial to lateral from the lower to upper body. Note that this correspondence does not result in a perfectly miniature scale version of the body, but rather exaggerates the more sensitive areas of the body, such as the fingers and lower face. Less sensitive areas of the body, such as the shoulders and back, are mapped to smaller areas on the cortex. Likewise, the motor cortex contains a similar representation of neurons that control the respective body regions called the **motor homunculus** (Figure 11.3.9.B).

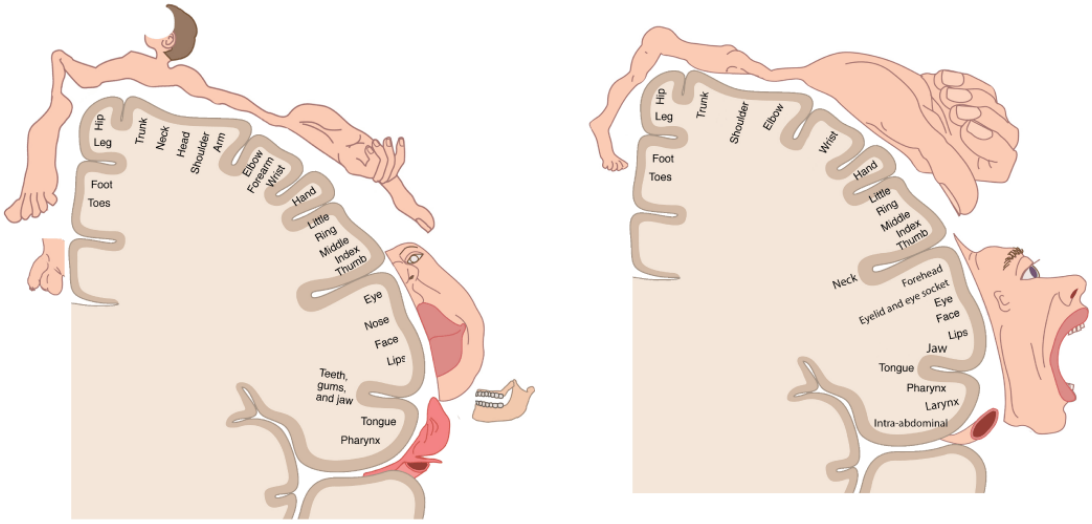

Figure 11.3.9: Homunculus. Cartoon representations of the sensory homunculus (A) and motor homunculus (B) are shown. A homunculus refers to a map of the human body that is laid adjacent to the corresponding cerebral cortex region: the sensory receptors from various areas of the body are mapped to regions in which their processing takes place and the motor neurons for muscle groups are mapped to the regions that control them. For both, the most medial region of the cortex processes information regarding the toes and feet, while the most lateral region processes sensory information regarding the face, and in particular the mouth. *(Image credits: "Sensory Homunculus" by Jennifer Lange and "Motor Homunculus" by Jennifer Lange are licensed under CC BY-NC-SA 4.0. Created from components from "Sensory Homunculus" by OpenStax via Wikimedia Commons and from "Slagter - Drawing Cortical motor and sensory homunculus - Dutch labels" by Ron Slagter.)*

A number of other regions, which extend beyond these primary or association areas of the cortex, are referred to as integrative areas. These areas are found in the spaces between the domains for particular sensory or motor functions, and they integrate multisensory information, or process sensory or motor information in more complex ways. Consider, for example, the posterior parietal cortex that lies between the somatosensory cortex and visual cortex regions. This area is called **gnostic area** and has been ascribed to the coordination of visual and motor functions, such as reaching to pick up a glass. The somatosensory function that would be part of this is the proprioceptive feedback from moving the arm and hand. The weight of the glass, based on what it contains, will influence how those movements are executed.

Memory and Learning

Where in the brain are memories made and stored? This is not an easy question to answer as "memory" is not a single entity and because multiple brain regions handle different parts of processes. One of the most important brain regions in explicit memory is the **hippocampus**, which serves as an initial processor and director of information. Damage to this area of the temporal lobe prevents the formation of new declarative memories (information that can be stated - facts, events, experiences). The hippocampus also helps us recall information about spatial relationships and the context of events. These roles arise because the hippocampus serves to hold the information as a short term memory and then projects information to cortical regions that give memories meaning and connect them to other bits of information. In addition, it also plays a main role in memory consolidation: the process of transferring new learning from short-term memory into long-term memory.

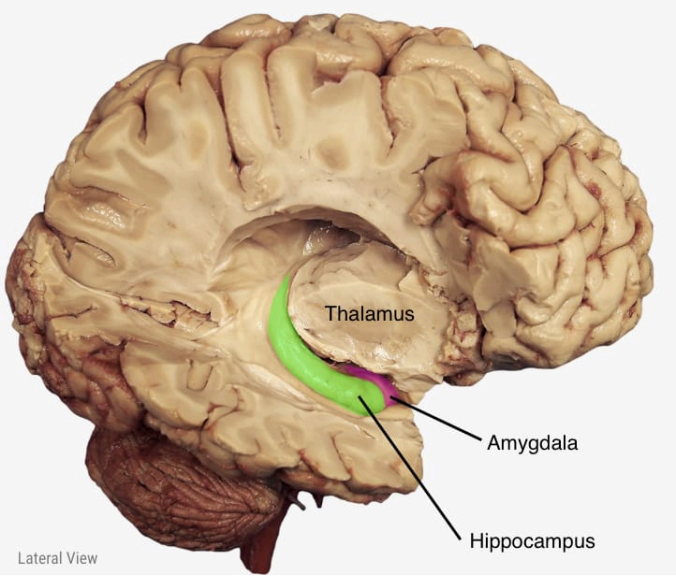

Figure 11.3.10: Hippocampus and Amygdala. Both the hippocampus and the amygdala are located within the medial aspect of the temporal lobe. The hippocampus serves as the floor of the inferior portion of the lateral ventricle. *(Image credit: "Hippocampus and Amygdala" by Functional Neuroanatomy at the University of British Columbia is licensed under CC BY-NC-SA 4.0; labels added by Jennifer Lange.)*

The storage of many of our most important emotional memories, and particularly those related to fear, is initiated and controlled by the **amygdala**. The amygdala is also located in the temporal lobe, just anterior and medial to the hippocampus. These two centers have many neuronal interconnections and the signaling between them can both enhance or suppress detailed memory formation.

The **cerebellum** plays a large role in implicit memories (procedural memory, motor learning, and classical conditioning). These are memories for motor responses that we learn through practice, such as playing the piano or writing. The cerebellum also maintains internal representations of the external world, which allow you to complete tasks such as navigating through your house in the dark and driving to work on "autopilot".

The **prefrontal cortex** is the location for our working memory. It's many interconnections with other brain regions allows it to access and temporarily hold and limited amount of information so we can "work" with it. This work could be something as simple as remembering a numerical code sent to verify our electronic identity to mentally manipulating complex concepts such as determining cancer treatment options. This region allows for reasoning and the guidance of decision-making and behavior.

Case Study - H.M.

Much of our early understanding of the locations of memory in the brain come from studying patients with memory disorders. The most famous patient in neuroscience, known for years only as H.M., had the medial portion of both his left and right temporal lobes surgically removed in 1953 in an attempt to help control the debilitating seizures he had been suffering from since a bicycle accident when he was a child. Following the surgery his seizures resolved, but also his declarative memory was significantly affected and he could not form new semantic knowledge. He lost the ability to form new memories, yet he could still remember information and events that had occurred prior to the surgery as well as form new short-term and procedural memories. Work with H.M. established fundamental principles about how memory functions are organized in the brain. After his death, patient H.M.'s identity was released. Henry Molaison, died in 2008 at the age of 82.

View this Slate video for a closer look at how memory works, as well as how researchers are now studying H.M.'s brain.

Language and Speech

Adjacent to the auditory association cortex, at the end of the lateral sulcus just anterior to the visual cortex, is **Wernicke's area** (Figure 11.3.8). Wernicke's area is responsible for the understanding of language, both written and verbal. In the lateral aspect of the frontal lobe, just anterior to the region of the motor cortex associated with the head and neck, is **Broca's area**. Broca's area

is responsible for the production of language and controlling movements responsible for speech. Both areas are located only in the left hemisphere in the majority of people. The tendency for some brain functions to be specialized in one side of the brain is called **lateralization of function**. Both regions were originally described on the basis of losses of language, both verbal and written, which is called **aphasia**. The aphasia associated with Broca's area is known as an **expressive aphasia**, which means that speech production is compromised. This type of aphasia is often described as non-fluency because the ability to say some words leads to broken or halting speech. Grammar can also appear to be lost. The aphasia associated with Wernicke's area is known as a **receptive aphasia**, which is not a loss of speech production, but a loss of understanding of content. Patients, after recovering from acute forms of this aphasia, report not being able to understand what is said to them or what they are saying themselves, but they often cannot keep from talking.

The two regions are connected by white matter tracts that run between the posterior temporal lobe and the lateral aspect of the frontal lobe. **Conduction aphasia** associated with damage to this connection refers to the problem of connecting the understanding of language to the production of speech. This is a very rare condition, but is likely to present as an inability to faithfully repeat spoken language.

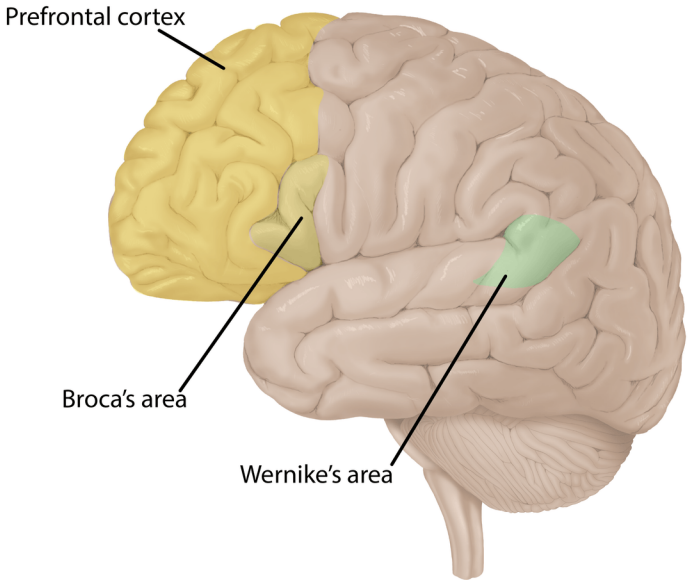

Figure 11.3.11: Functional Cortical Areas - Language and Executive Functions. Broca's area in the frontal lobe and Wernicke's area in the temporal lobe are crucial for creating and understanding language. The prefrontal cortex is responsible for executive functions such as decision making, reasoning, and working memory. *(Image credit: "Functional Areas of the Cerebral Cortex - Language and Executive Functions" by Justin Greene and Jennifer Lange is licensed under CC BY-NC-SA 4.0.)*

Judgment and Abstract Reasoning

Planning and producing responses requires an ability to make sense of the world around us. Making judgments and reasoning in the abstract are necessary to produce movements as part of larger responses. For example, when your alarm goes off, do you hit the snooze button or jump out of bed? Is 10 extra minutes in bed worth the extra rush to get ready for your day? Will hitting the snooze button multiple times lead to feeling more rested or result in a panic as you run late? How you mentally process these questions can affect your whole day.

The **prefrontal cortex** is responsible for the functions responsible for planning and making decisions. The prefrontal cortex is composed of the regions of the frontal lobe that are not directly related to specific motor functions. The most posterior region of the frontal lobe, the precentral gyrus, is the primary motor cortex. Anterior to that are the premotor cortex, Broca's area, and the supplementary motor cortex, which are all related to planning certain types of movements. Anterior to these motor association areas are the regions of the prefrontal cortex. They are the regions in which judgment, abstract reasoning, and working memory are localized. The antecedents to planning certain movements are judging whether those movements should be made, as in the example of deciding whether to hit the snooze button.

A discredited psychiatric practice to deal with various disorders was the **prefrontal lobotomy**. This procedure was common in the 1940s and early 1950s, until antipsychotic drugs became available. The connections between the prefrontal cortex and other regions of the brain were severed. The disorders associated with this procedure included some aspects of what are now referred

to as personality disorders, but also included mood disorders and psychoses. Depictions of lobotomies in popular media suggest a link between cutting the white matter of the prefrontal cortex and changes in a patient's mood and personality, though this correlation is not well understood.

Explore 3D Brain Models

Explore human brain specimens in 3D! Each of the following specimens will have slight differences in the pattern of gyri and sulci, as such variation is normal between individuals.

This interactive element is not available in this format. Visit the link or scan the QR code to access it online.

View this Interactive Content online

Whole brain with gross anatomy annotations by **TavorLab** on **Sketchfab**

This interactive element is not available in this format. Visit the link or scan the QR code to access it online.

View this Interactive Content online

Brain Before Sections by **UBC Faculty of Medicine** on **Sketchfab**

This interactive element is not available in this format. Visit the link or scan the QR code to access it online.

View this Interactive Content online

Hemi-Brain with Cerebellum by **UBC Medicine - Educational Media** on **Sketchfab**

Concept Review

The adult brain is separated into four major regions: the cerebrum, the diencephalon, the brainstem, and the cerebellum.

The cerebrum is the largest portion, it is divided into two halves called hemispheres by the longitudinal fissure.

1. **cerebral cortex** is the location of important cognitive functions, with functions localized to each of the five lobes:
    - **frontal** - responsible for motor functions, from planning movements through executing commands to be sent to the spinal cord and periphery; high order executive functions such as personality, working memory, and decision-making
    - **parietal** - processing of somatosensory information
    - **temporal** - processing of information for hearing and for smell; memory formation; fear and anxiety
    - **occipital** - initial processing of visual information
    - **insular** - initial processing of information for taste
2. **Subcortical nuclei** (deep cerebral nuclei) are responsible for augmenting cortical functions. The subcortical or basal nuclei receive input from cortical areas and compare it with the general state of the individual. The output influences the activity of part of the thalamus that can then increase or decrease cortical activity that often results in changes to motor commands.
3. **White matter tracts** are bundles of myelinated axons that connect different regions of the brain.

- commissural tracts - extend between the two hemispheres to connect left and right regions of the cerebrum; example is corpus callosum
- association tracts - connect different regions within the same hemisphere
- projection tracts - extend from the cerebral cortex to the inferior regions of the brain and to the spinal cord; example is internal capsule

Losses of language and speech functions, known as aphasias, are associated with damage to the important integration areas in the left hemisphere known as Broca's or Wernicke's areas, as well as the connections in the white matter between them. Different types of aphasia are named for the particular structures that are damaged.

Review Questions

Query 11.3.1

This interactive element is not available in this format. Visit the link or scan the QR code to access it online.

View this Interactive Content online

Glossary

Query 11.3.2

This interactive element is not available in this format. Visit the link or scan the QR code to access it online.

View this Interactive Content online

Contributors and Attributions

OpenStax Anatomy & Physiology (CC BY 4.0). Access for free at https://openstax.org/books/anatomy-and-physiology

This page titled 11.3: Brain - Cerebrum is shared under a CC BY-NC-SA 4.0 license and was authored, remixed, and/or curated by Jennifer Lange et al..

- 12.3: Brain- Cerebrum by Whitney Menefee, Julie Jenks, Chiara Mazzasette, and Kim-Leiloni Nguyen is licensed CC BY 4.0.

11.4: Brain - Diencephalon, Brainstem, Cerebellum and Limbic System

By the end of this section, you will be able to:

- Identify the components of the diencephalon and describe their functions
- Identify the structures of the brainstem and describe their functions
- Describe the structure and function of the cerebellum
- Identify the major structures of the limbic system and describe their functions

Diencephalon

The diencephalon is the one region of the adult brain that retains its name from embryologic development. The etymology of the word diencephalon translates to “through brain.” It is the connection between the cerebrum and the rest of the nervous system, with one exception. The rest of the brain, the spinal cord, and the PNS all send information to the cerebrum through the diencephalon. Output from the cerebrum passes through the diencephalon. The single exception is the system associated with olfaction, or the sense of smell, which connects directly with the cerebrum. In the earliest vertebrate species, the cerebrum was not much more than olfactory bulbs that received peripheral information about the chemical environment (to call it smell in these organisms is imprecise because they lived in the ocean).

The diencephalon is deep beneath the cerebrum and constitutes the walls of the third ventricle. The diencephalon can be described as any region of the brain with “thalamus” in its name. The major regions of the diencephalon are the **thalamus** itself, the **hypothalamus**, and the **epithalamus**, which contains the pineal gland (Figure 11.4.1).

Epithalamus

The epithalamus forms the posterior roof of the third ventricle and houses the **pineal gland**, an endocrine gland responsible for the secretion of melatonin. Melatonin regulates day-night cycles. Nuclei within the epithalamus help relay signals to the limbic system and are involved in emotional responses to odors.

Thalamus

The thalamus is a pair of oval-shaped structures that each contain a dozen nuclei, called **thalamic nuclei**. The thalamus covers the superior and lateral walls of the third ventricle. The right and left thalami are connected by a mass of gray matter called the **interthalamic adhesion**. All sensory information, except for the sense of smell, passes through the thalamus before processing by the cortex. Axons from the peripheral sensory organs, or intermediate nuclei, synapse in the thalamus, and thalamic neurons project directly to the cerebrum. It is a requisite synapse in any sensory pathway, except for olfaction. The thalamus does not just pass the information on, it also processes that information. For example, the portion of the thalamus that receives visual information will influence what visual stimuli are important, or what receives attention. The cerebrum also sends information down to the thalamus, which usually communicates motor commands. This involves interactions with the cerebellum and other nuclei in the brainstem.

Hypothalamus

Inferior and slightly anterior to the thalamus is the hypothalamus, the other major region of the diencephalon. The hypothalamus is a collection of nuclei that are largely involved in regulating homeostasis. The hypothalamus is the executive region in charge of the autonomic nervous system and the endocrine system through its regulation of the anterior pituitary gland. Other parts of the hypothalamus are involved in memory and emotion as part of the limbic system. Two groups of nuclei called the **mammillary bodies** are located on the posterior part of the hypothalamus and are important for episodic memory, which is the memory of every day events that you can recollect.

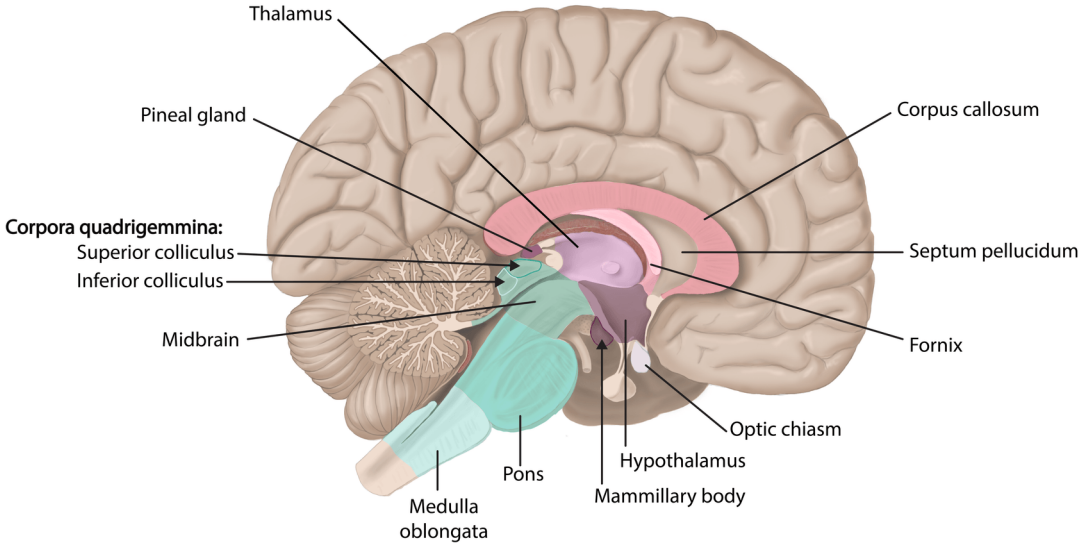

Figure 11.4.1: Midsagittal Section of the Brain. The diencephalon is composed of the thalamus, hypothalamus, and epithalamus. The brainstem comprises three regions: the midbrain, the pons, and the medulla oblongata. Two cerebral structures also visible here are white matter tracts - the corpus callosum and the fornix. *(Image credit: "Midsagittal Section of the Brain" by Justin Greene and Jennifer Lange is licensed under CC BY-NC-SA 4.0.)*

Brainstem

The **midbrain** and hindbrain (composed of the **pons** and the **medulla oblongata**) are collectively referred to as the brainstem (Figure 11.4.1 and Figure 11.4.2). The structure emerges from the ventral surface of the forebrain as a tapering cone that connects the brain to the spinal cord. Attached to the brainstem, but considered a separate region of the adult brain, is the cerebellum. The midbrain coordinates sensory representations of the visual, auditory, and somatosensory perceptual spaces. The pons is the main connection with the cerebellum. The pons and the medulla regulate several crucial functions, including the cardiovascular and respiratory systems (such as heart rhythm or breathing rate). The **reticular activating system** is found in the midbrain, pons, medulla and part of the thalamus and controls levels of wakefulness, maintains consciousness, enables people to pay attention to their environments, and is involved in sleep patterns and regulating the sleep cycle.

The cranial nerves connect through the brainstem and provide the brain with the sensory input and motor output associated with the head and neck, including most of the special senses. The major ascending and descending pathways between the spinal cord and brain, specifically the cerebrum, pass through the brainstem.

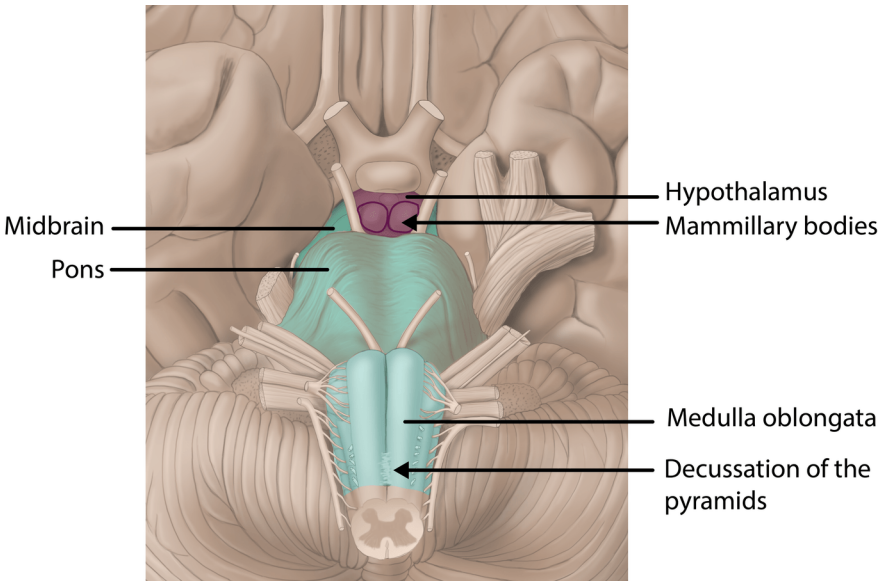

Figure 11.4.2: Inferior View of the Brain. The inferior view of the brain shows the brainstem and hypothalamus. From rostral to caudal, the midbrain, pons and medulla oblongata form the brainstem. Motor fibers from the precentral gyrus cross to the opposite side at the decussation of the pyramids in the medulla oblongata. The only part of the diencephalon visible is the hypothalamus. *(Image credit: "Inferior View of the Brain" by Justin Greene and Jennifer Lange is licensed under CC BY-NC-SA 4.0.)*

Midbrain

The mesencephalon, one of the original region of the embryonic brain, becomes the midbrain, a small region between the thalamus and pons. The **cerebral aqueduct** passes through the midbrain, creating a visual separation between the posterior tectal plate and the anterior regions.

The posterior surface of the midbrain is the tectal plate, which is composed of four bumps known together as the **corpora quadrigemina** or colliculi (singular = colliculus), which means “little hill” in Latin (Figure 11.4.2). The **superior colliculi** is the superior pair and they integrate visual information with other somatosensory spatial information to initiate movements of the eyes and head toward objects. They also coordinate visually tracking moving objects. The **inferior colliculi** is the inferior pair of these enlargements and are part of the auditory pathway. Neurons of the inferior colliculus project to the thalamus, which then sends auditory information to the cerebrum for the conscious perception of sound.

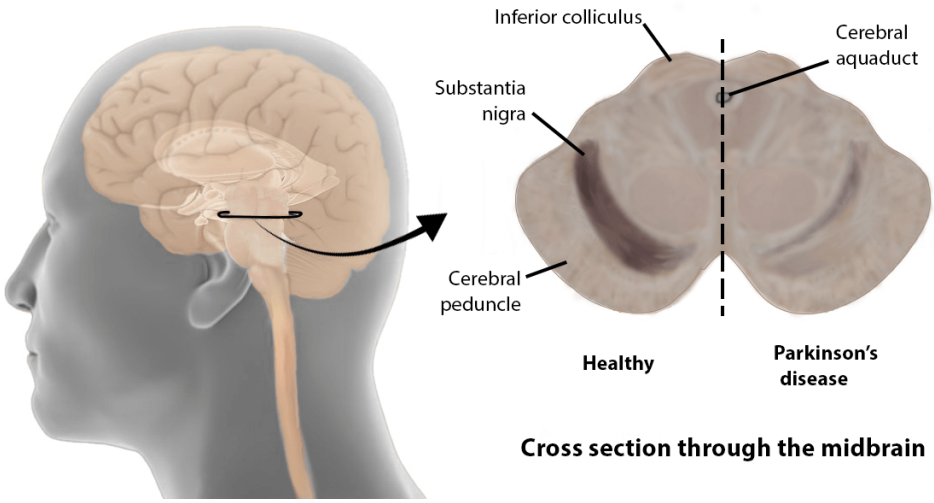

Figure 11.4.3: Midbrain - Healthy and Parkinson's Disease. *(Image credit: "Midbrain Cross Section" by Jennifer Lange is licensed under CC BY-NC-SA 4.0, modification of original by Scientific Animations.)*

The anterior surface of the midbrain is the **cerebral peduncles** containing the axons of motor neurons descending from the frontal lobe to motor nuclei in the brainstem and the spinal cord. Posterior to the cerebral peduncles, and not visible on the surface is the **substantia nigra** ("black substance") whose black appearance due to melanin production. These nuclei produce the neurotransmitter dopamine and play roles in modulating movement, emotional response, and the ability to experience pleasure and pain. The are a major component of the brain's "reward pathway" that is hijacked by most addictive drugs. Degeneration of the neurons within the substantia nigra is a hallmark of Parkinson disease (see box below).

Pons

The pons is visible on the anterior surface of the brainstem as the thick bundle of white matter attached to the cerebellum. The name of the pons is derived from its connection to the cerebellum. The word means “bridge” and refers to the thick bundle of myelinated axons that form a bulge on its ventral surface. Those fibers are axons that project from the gray matter of the pons into the contralateral cerebellar cortex. These fibers make up the **middle cerebellar peduncle** and are the major physical connection of the cerebellum to the brainstem. Gray matter regions of the pons contain neurons receiving descending input from the forebrain that is sent to the cerebellum. The pons houses autonomic nuclei important for respiration and is also involved in sensory and motor information of some cranial nerves. It houses the nuclei for cranial nerves V to VIII.

Medulla Oblongata

The medulla oblongata is the region known as the myelencephalon in the embryonic brain. The initial portion of the name, “myel,” refers to the significant white matter found in this region—especially on its exterior, which is continuous with the white matter of the spinal cord. The anterior region of the medulla oblongata shows two longitudinal ridges called **pyramids**, which house motor projection tracts (Figure 11.4.2). In the caudal region of the medulla oblongata 90% of these axons cross to the opposite side at a point called the **decussation of pyramids**. Due to this crossing, each hemisphere controls motor responses of the opposite side of the body. Posterior and lateral to each pyramid, a nucleus called **inferior olive**, is located and functions as a relay point for information on **proprioception** (body position in 3D space) coming from the spinal cord and going into the cerebellum. The medulla oblongata contains several nuclei that are associated with last five cranial nerves (CN VIII to XII). It also contains autonomic nuclei important for vital functions such as respiration, heart rate, and blood pressure, among others.

DISORDERS OF THE...

Midbrain: Parkinson's Disease

Parkinson’s disease is a disorder of the basal nuclei, specifically of the substantia nigra, that demonstrates the effects of the direct and indirect pathways. Parkinson’s disease is the result of neurons in the substantia nigra pars compacta dying. These neurons release dopamine into the striatum. Without that modulatory influence, the basal nuclei are stuck in the indirect pathway, without the direct pathway being activated. The direct pathway is responsible for increasing cortical movement commands. The increased activity of the indirect pathway results in the hypokinetic disorder of Parkinson’s disease.

Parkinson’s disease is neurodegenerative, meaning that neurons die that cannot be replaced, so there is no cure for the disorder. Treatments for Parkinson’s disease are aimed at increasing dopamine levels in the striatum. Currently, the most common way of doing that is by providing the amino acid L-DOPA, which is a precursor to the neurotransmitter dopamine and can cross the blood-brain barrier. With levels of the precursor elevated, the remaining cells of the substantia nigra pars compacta can make more neurotransmitter and have a greater effect. Unfortunately, the patient will become less responsive to L-DOPA treatment as time progresses, and it can cause increased dopamine levels elsewhere in the brain, which are associated with psychosis or schizophrenia.

Visit this site for a thorough explanation of Parkinson's disease.

Explore 3D Brain Models

Explore human brain specimens in 3D! Each of the following specimens will have slight differences in the pattern of gyri and sulci, as such variation is normal between individuals.

This interactive element is not available in this format. Visit the link or scan the QR code to access it online.

View this Interactive Content online

Brain Before Sections by **UBC Faculty of Medicine** on **Sketchfab**

This interactive element is not available in this format. Visit the link or scan the QR code to access it online.

View this Interactive Content online

Cerebellum

The **cerebellum**, as the name suggests, is the "little brain". Similar to the brain, the cerebellum contains an outer layer of gray matter, an inner layer of white matter and deep **cerebellar nuclei** (Figure 11.4.4). The white matter of the cerebellum is called **arbor vitae** ("tree of life") for its appearance that reminds that of branches of a tree. The folds of the cerebellar cortex are called **folia**, which means "leaf".

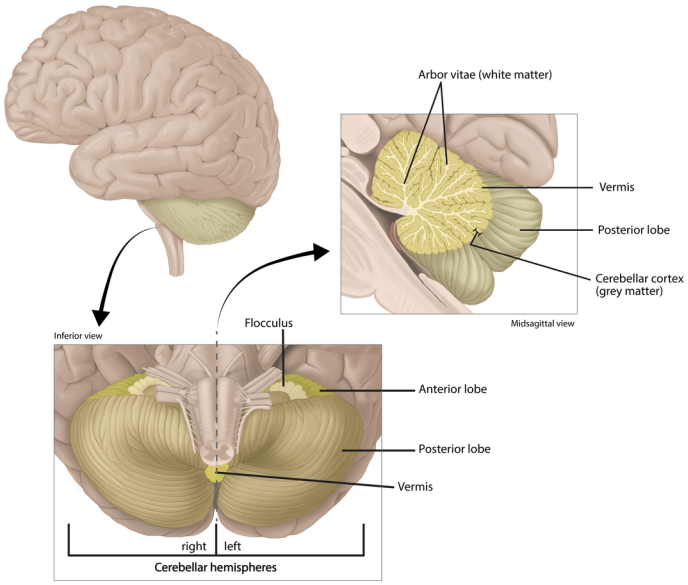

Figure 11.4.4: Cerebellum. The cerebellum is situated on the posterior surface of the brainstem. The midsagittal section shows the deep white matter forming the arbor vitae, which means "tree of life", while the cerebellar cortex is superficial. The major regions of the cerebellum are the anterior lobe, the posterior lobe, and the midline vermis. *(Image credit: "Cerebellum" by Justin Greene and Jennifer Lange is licensed under CC BY-NC-SA 4.0.)*

The cerebellum is divided into regions that are based on the particular functions and connections involved. The midline region of the cerebellum, called the **vermis**, is involved in comparing visual information, equilibrium, and proprioceptive feedback to maintain balance and coordinate movements such as walking, or gait (Figure 11.4.4). The vermis connects the two **cerebellar hemispheres**. Each hemisphere consists of two lobes, the **anterior lobe** and the **posterior lobe**, separated by the **primary fissure**. The lateral hemispheres are primarily concerned with planning motor functions through frontal lobe inputs that are returned through the thalamic projections back to the premotor and motor cortices. Processing in the midline regions targets movements of the axial musculature, whereas the lateral regions target movements of the appendicular musculature. The cerebellum is connected to the midbrain through three white matter tracts: the **superior cerebellar peduncle** connects to the midbrain, the **middle cerebellar peduncle** is the largest and connects to the pons, and the **inferior cerebellar peduncle** connects to the medulla oblongata.

The cerebellum is responsible for coordination of movement, alternating movement of arms and legs, balance, posture and gait. If the primary motor cortex of the frontal lobe sends a command down to the spinal cord to initiate walking, a copy of that instruction is sent to the cerebellum. Sensory feedback from the muscles and joints, proprioceptive information about the movements of walking, and sensations of balance are sent to the cerebellum through the inferior olive and the cerebellum compares them. If walking is not coordinated, perhaps because the ground is uneven or a strong wind is blowing, then the cerebellum sends out a corrective command to compensate for the difference between the original cortical command and the sensory feedback. The output of the cerebellum is into the midbrain, which then sends a descending input to the spinal cord to correct the messages going to skeletal muscles.

There is also strong evidence of the cerebellar role in procedural memory. The two are not incompatible; in fact, procedural memory is motor memory, such as learning to ride a bicycle. Significant work has been performed to describe the connections within the cerebellum that result in learning.

DISORDERS OF THE...

Cerebellum: Ataxia

A movement disorder of the cerebellum is referred to as **ataxia**. It presents as a loss of coordination in voluntary movements. Ataxia can also refer to sensory deficits that cause balance problems, primarily in proprioception and equilibrium. When the problem is observed in movement, it is ascribed to cerebellar damage. Sensory and vestibular ataxia would likely also present with problems in gait and station.

This interactive element is not available in this format. Visit the link or scan the QR code to access it online.

View this YouTube Video online

Ataxia is often the result of exposure to exogenous substances, focal lesions, or a genetic disorder. Focal lesions include strokes affecting the cerebellar arteries, tumors that may impinge on the cerebellum, trauma to the back of the head and neck, or MS. Alcohol intoxication or drugs such as ketamine cause ataxia, but it is often reversible. Mercury in fish can cause ataxia as well. Hereditary conditions can lead to degeneration of the cerebellum or spinal cord, as well as malformation of the brain, or the abnormal accumulation of copper seen in Wilson's disease.

Limbic System

The **limbic system** is a collection of structures of the cerebrum and diencephalon involved in emotion, motivation and memory associated with emotions. Although still debated, the structures mostly recognized in this system are the cingulate gyrus, hippocampus, amygdala, olfactory structures, and various nuclei of the diencephalon. Here we will focus on the cingulate gyrus, the hippocampus and amygdala as major structures (Figure 11.4.6). The **cingulate gyrus** is located in the longitudinal fissure, superior to the corpus callosum, surrounding the diencephalon. The cingulate gyrus focuses the attention to events that are emotionally important. The **hippocampus** is a nucleus shaped like a seahorse, hence its name. The hippocampus is essential in forming memories and storing them long-term. Lastly, the **amygdala** (or amygdaloid body) is connected to the hippocampus and is involved in multiple aspects of emotions, especially fear. It helps encoding memories based on the state of emotion that the person is in.

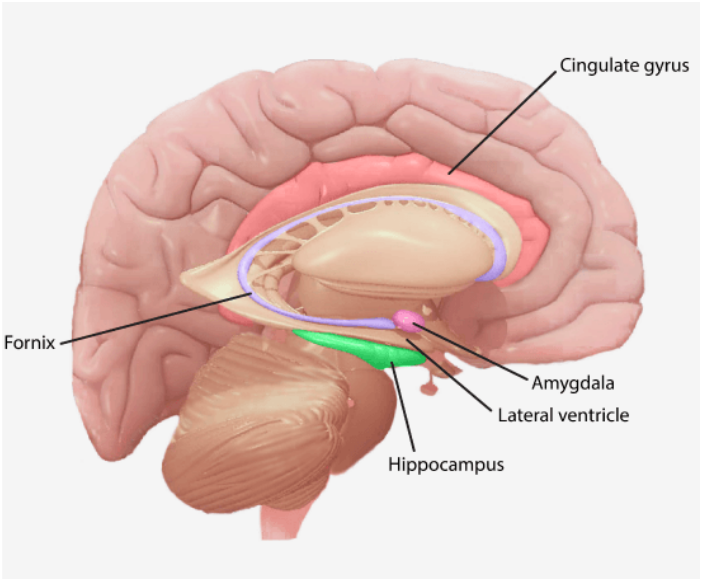

Figure 11.4.6: Limbic System. The limbic system regulates emotion and other behaviors. It includes parts of the cerebral cortex located near the midline of the brain, including the cingulate gyrus and the hippocampus and amygdala. The fornix is a tract connecting the hippocampus to the hypothalamus. *(Image credit: "Limbic System" by Jennifer Lange is licensed under CC BY-NC-SA 4.0, modification of image from Scientific Animations.)*

Concept Review

The diencephalon includes the thalamus and the hypothalamus, along with some other structures. The thalamus is a relay between the cerebrum and the rest of the nervous system. The hypothalamus coordinates homeostatic functions through the autonomic and endocrine systems.

The brainstem is composed of the midbrain, pons, and medulla. It controls the head and neck region of the body through the cranial nerves. There are control centers in the brainstem that regulate the cardiovascular and respiratory systems.

The cerebellum is connected to the brainstem, primarily at the pons, where it receives a copy of the descending input from the cerebrum to the spinal cord. It can compare this with sensory feedback input through the medulla and send output through the midbrain that can correct motor commands for coordination. The cerebellum is an important part of motor function in the nervous system. It apparently plays a role in procedural learning, which would include motor skills such as riding a bike or throwing a football. The basis for these roles is likely to be tied into the role the cerebellum plays as a comparator for voluntary movement.

The limbic system includes structures of the cerebral cortex and diencephalon that are responsible for emotion and memory. The main structures are the cingulate gyrus, hippocampus and amygdala.

Review Questions

Query 11.4.1

This interactive element is not available in this format. Visit the link or scan the QR code to access it online.

View this Interactive Content online

Critical Thinking Questions

Query 11.4.2

This interactive element is not available in this format. Visit the link or scan the QR code to access it online.

View this Interactive Content online

Glossary

Query 11.4.3

This interactive element is not available in this format. Visit the link or scan the QR code to access it online.

View this Interactive Content online

Contributors and Attributions

OpenStax Anatomy & Physiology (CC BY 4.0). Access for free at https://openstax.org/books/anatomy-and-physiology

This page titled 11.4: Brain - Diencephalon, Brainstem, Cerebellum and Limbic System is shared under a CC BY-NC-SA 4.0 license and was authored, remixed, and/or curated by Jennifer Lange et al..

- 12.4: Brain- Diencephalon, Brainstem, Cerebellum and Limbic System by Whitney Menefee, Julie Jenks, Chiara Mazzasette, and Kim-Leiloni Nguyen is licensed CC BY 4.0.

11.5: Spinal Cord

By the end of this section, you will be able to:

- Describe the structures that protect the spinal cord
- Describe the regions and structures of the spinal cord and their functions
- Explain the arrangement of gray and white matter in the spinal cord and the regional variations

The spinal cord is continuous with the brain and transmits sensory information from the periphery of the body to the brain, and motor information from the brain to the periphery. It is also a center for coordination of reflexes, as well as control of reflexes independently from the brain. In a typical adult the length of the spinal cord ranges from 42-45 cm (16-18 inches), depending on the person's height. It extends inferiorly from the medulla oblongata, at the level of the foramen magnum, to approximately the level of the L_1 vertebra. The spinal cord is divided into cervical, thoracic, lumbar, sacral and coccygeal regions. The location of these regions within the vertebral column does not match up with the location of the similarly named vertebrae (except for C_1). For example, the lumbar region of the spinal cord aligns with the inferior thoracic vertebrae. This occurs because the bone growth period of the vertebra lasts longer than the growth period of the spinal cord, thus the spinal cord stops lengthening before the vertebrae stop gaining height.

Protective Coverings of the Spinal Cord

The spinal cord, as the brain, is protected by meninges, which are continuous with the cranial meninges. From outermost to innermost, the spinal meninges are: **dura mater**, **arachnoid mater** and **pia mater** (Figure 11.5.1 and Figure 11.5.2). The spinal meninges are similar to the cranial ones, except for the dura mater. The spinal dura mater consists of a single layer of connective tissue, differing from the cranial dura mater. Moreover, at each intervertebral foramen, the dura mater extends and fuses with the connective tissue that covers spinal nerves.

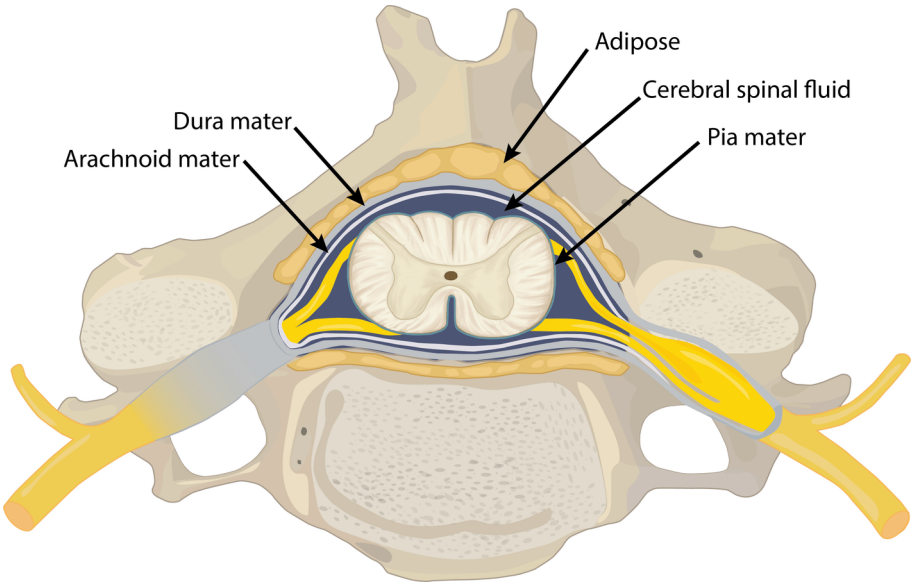

Figure 11.5.1: Spinal Cord Protection. The spinal cord is protected by a bony case, an adipose cushion, and three meningeal layers with cerebrospinal fluid. They protect the spinal cord from outside impacts and from movement within the vertebral column. *(Image credit: "Spinal Cord Protection" by Sofia Elizondo is licensed under CC BY-NC-SA 4.0; spinal cord original graphic from BlueLink.)*

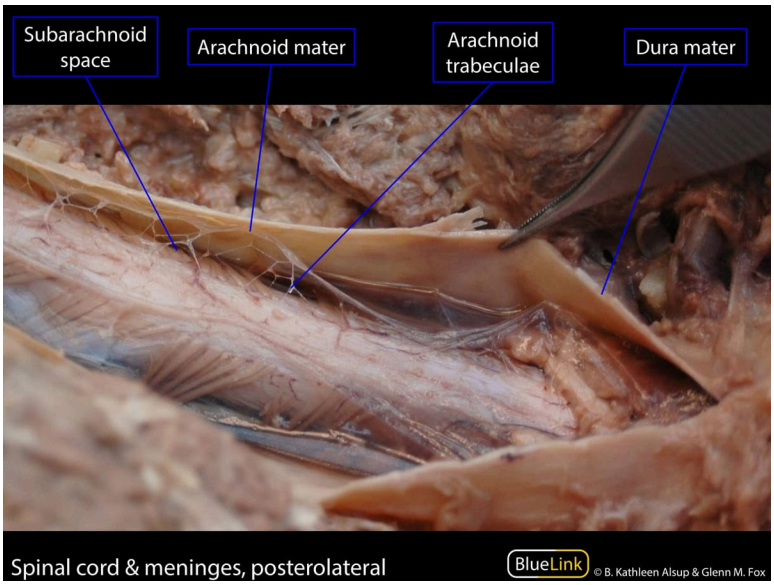

Figure 11.5.2: Spinal Cord Meninges. In this cadaver dissection, the retracting the thick dura mater reveals the thinner arachnoid mater attached to it as well as the trabeculae crossing the subarachnoid space to the pia (not visible but tightly adhered to the cord). *(Image credit: "Spinal Meninges" by BlueLink is licensed under CC BY-NC 4.0 with notification of the original authors.)*

One space between the spinal meninges also differs slightly from the ones present around the brain. The **epidural space** between the periosteum and dura mater is a real space around the spinal cord and houses areolar and adipose connective tissues (shown in Figure 11.5.3). Epidural anesthesia is injected in this space.

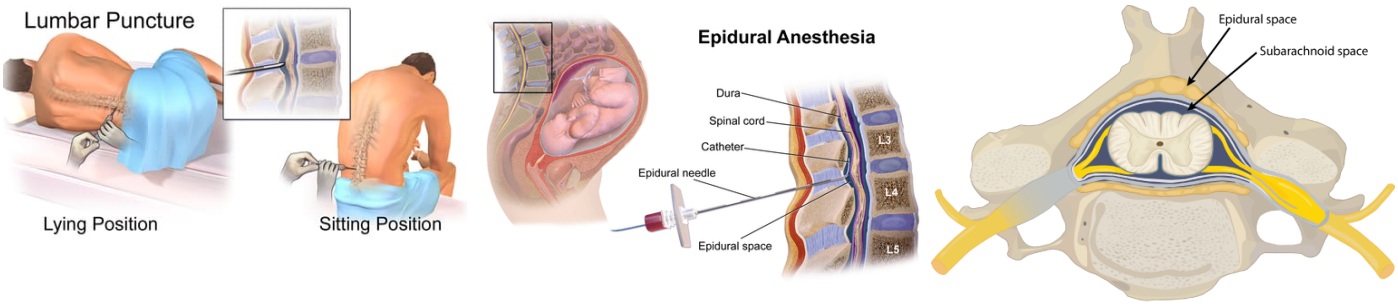

Figure 11.5.3: Epidural Space and Subarachnoid Space. The epidural space is located between the bone and the dura mater while the subarachnoid space is between the arachnoid mater and the pia mater. *(Image credits: "Lumbar Puncture" by Blausen.com staff (2014), "Medical gallery of Blausen Medical 2014", WikiJournal of Medicine 1 (2). DOI:10.15347/wjm/2014.010. ISSN 2002-4436. Licensed under CC BY 3.0, via Wikimedia Commons; "Epidural Anesthesia" by BruceBlaus is licensed under CC BY-SA 4.0, via Wikimedia Commons; "Spinal Cord Protection" by Sofia Elizondo is licensed under CC BY-NC-SA 4.0; spinal cord original graphic from BlueLink.)*

The **subarachnoid space** is filled with circulating CSF, which also provides a liquid cushion to the brain and spinal cord (Figure 11.5.3). Similar to clinical blood work, a sample of CSF can be withdrawn to find chemical evidence of neuropathology or metabolic traces of the biochemical functions of nervous tissue. Because the spinal cord does not extend through the lower lumbar region of the vertebral column, a needle can be inserted through the dura and arachnoid layers to withdraw CSF. This procedure is called a **lumbar puncture** and avoids the risk of damaging the central tissue of the spinal cord.

Spinal Cord Gross Anatomy

The description of the CNS is concentrated on the structures of the brain, but the spinal cord is another major organ of the system. The length of the spinal cord is divided into regions that correspond to the regions of the vertebral column. As shown in Figure 11.5.4, immediately inferior to the medulla oblongata is the **cervical region** of the spinal cord that contains motor neurons whose axons, together with sensory axons, extend into cervical spinal nerves. Inferior to the cervical region is the **thoracic region**, that contains neurons for the thoracic spinal nerves. The **lumbar region** is a short segment that contains neurons for the lumbar spinal nerves. Finally the **sacral region** contain neurons for the sacral nerves. The spinal cord is not the full length of the vertebral

column because the spinal cord does not grow significantly longer after the first or second year, but the skeleton continues to grow. For this reason, the names of the spinal cord regions and vertebral regions to not match up. The lumbar and sacral spinal cord segments are found between vertebral levels T9 and L2. The spinal cord ends around the L1/L2 vertebral level, forming a tapered structure known as the **conus medullaris** (or medullary cone), which corresponds to the sacral spinal cord. The nerves that emerge from the spinal cord pass through the intervertebral foramina at the corresponding vertebral segments. For example, lumbar nerves exit the vertebral canal at the respective lumbar vertebrae. As the vertebral column grows, these nerves grow with it and result in a long bundle of nerves inferior to the conus medullaris that resembles a horse's tail and therefore is named the **cauda equina**. Within the cauda equina, there is a thin strand of pia mater called **filum terminale** that helps anchoring the conus medullaris to the coccyx. At each intervertebral foramen, the spinal dura mater extends between vertebrae and surrounds the spinal nerves.

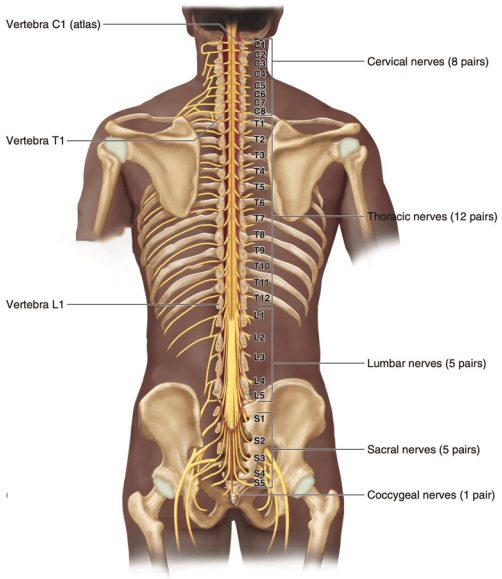

Figure 11.5.4: Gross Anatomy of the Spinal Cord. The spinal cord is divided into four regions corresponding to the spinal nerve origins: cervical, thoracic, lumbar and sacral. At the inferior end, the cord tapers to a point called the conus medullaris. The group of nerves that extend inferior to the conus medullaris to get to their exit point from the vertebral canal is called the cauda equina. *(Image credit: "Spinal Cord Gross Anatomy" by Gabrielle Spurlock is licensed under CC BY-NC-SA 4.0, modification of original by KnowledgeWorks.)*

The diameter of the spinal cord changes between the different regions because the amounts of gray and white matter change to reflect the functions of the different regions. The cervical and lumbar regions of the spinal cord show a larger diameter compared to the rest of the regions. The **cervical enlargement** (C5-T1) and **lumbar enlargement** (L2-S3) represent an increased amount of neurons in the gray matter that serve the upper limbs and lower limbs, respectively (see Figure 11.5.5).

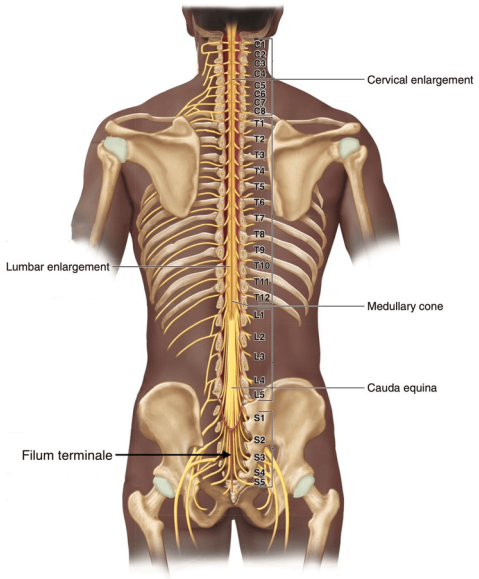

Figure 11.5.5: Gross Anatomy of the Spinal Cord. Compared to the superior cervical and thoracic regions, the cervical and lumbar enlargements have a larger diameter. The inferior end of the cord is anchored to the coccyx by the filum terminale, a thin strand of pia mater. *(Image credit: "Spinal Cord Gross Anatomy" by Gabrielle Spurlock is licensed under CC BY-NC-SA 4.0, modification of original by KnowledgeWorks.)*

Similar to the homunculi of the pre-central and post-central gyri, motor control and sensory input of the spinal cord can be mapped to specific segments of the spinal cord. Each skeletal muscle is usually innervated by multiple spinal segments, whereas each sensory region tends to correspond to a single spinal cord segment (with some overlap along the edges). (Table 11.5.1) provides an overview of the muscle groups controlled by different spinal cord segments.

Table 11.5.1: Spinal Segment Control of Muscle Groups

Spinal Cord Segments	Major Muscle Groups
C1-C3	Cervical muscles - head and neck movements
C2-T1	Muscles moving the scapula and shoulder
C3-C5	Diaphragm
C5-C8	Arm muscles
C5-T1	Forearm muscles
T5-L1	Abdominal muscles
T12-L3	Iliopsoas (hip flexion)
L4-S2	Hip extension and rotation
L2-S2	Thigh muscles
L4-S3	Leg and foot muscles
S3-Co1	Pelvic floor muscles

Spinal Cord Cross Sectional Anatomy

Whereas the brain develops out of expansions of the neural tube into primary and then secondary vesicles, the spinal cord maintains the tube structure and is only specialized into certain regions. As the spinal cord continues to develop in the newborn, anatomical features mark its surface. Viewed in cross section, the anterior midline is marked by the **anterior median fissure**, and the posterior midline is marked by the **posterior median sulcus** (Figure 11.5.6). In the central region of the spinal cord,

a **central canal** is the continuation of the fourth ventricle of the brain and contains cerebrospinal fluid (CSF). Surrounding the central canal, a horizontal line of gray matter called the **gray commissure** connects the left and right sides of the spinal cord.

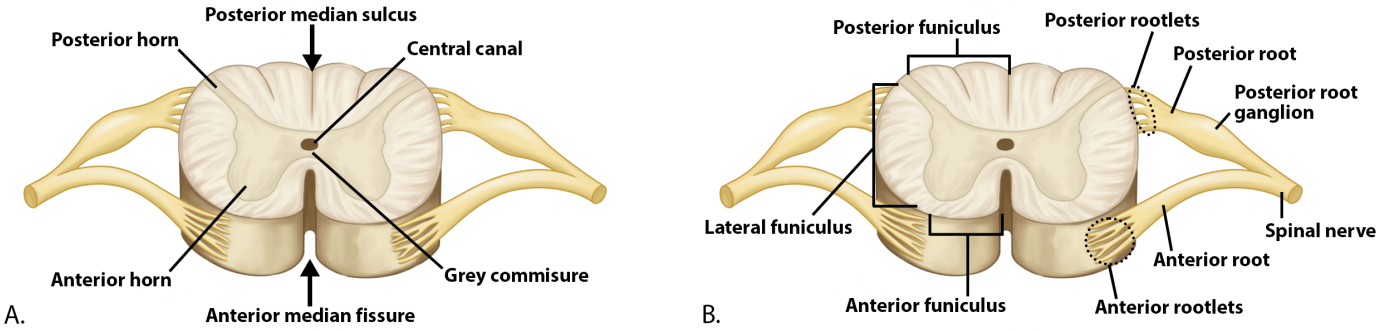

Figure 11.5.6: Cross Sectional Anatomy of the Spinal Cord. A. The grey matter of the spinal cord is deep to the white matter and it is shaped like an "H" or a butterfly. B. The white matter of the spinal cord is superficial. Emerging from the cord are the anterior and posterior rootlets, which merge to form the anterior and posterior roots. In general, the posterior structures of the spinal cord are sensory in function while the lateral and anterior structures are motor in function. *(Image credit: "Spinal Cord Cross Section" by Sofia Elizondo is licensed under CC BY-NC-SA 4.0, modification of original by BlueLink.)*

In cross-section, the gray matter of the spinal cord has the appearance of an ink-blot test, with the spread of the gray matter on one side replicated on the other—a shape reminiscent of a bulbous capital “H.” As shown in Figure 11.5.6 and Figure 11.5.8, the gray matter is subdivided into regions that are referred to as horns:

- The **posterior horn** is responsible for sensory processing and contain the axons of sensory neurons and the cell bodies of interneurons. The central processes of the bipolar sensory neurons are bundled into the posterior root and are coming directly from the posterior root ganglion which contains cell bodies of sensory neurons.
- The **anterior horn** contains the cell bodies of somatic motor neurons that control skeletal muscles. The somatic motor neurons are the largest neurons of the body and are classified as multipolar neurons. Their axons exit the spinal cord through the anterior nerve root.
- The **lateral horn**, which is only found in the thoracic, upper lumbar, and sacral regions, is a central component of the autonomic nervous system and contains cell bodies of autonomic motor neurons which innervate cardiac muscle, smooth muscle and glands (Figure 11.5.7).

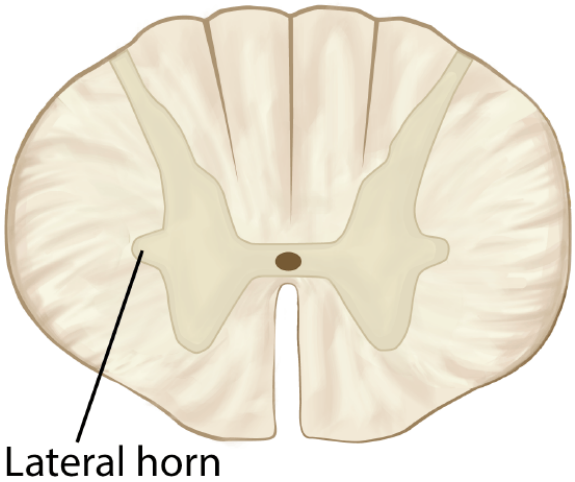

Figure 11.5.7: Lateral Horn. The lateral horn is present in the thoracic, inferior lumbar, and sacral regions of the cord. *(Image credit: "Spinal Cord Cross Section - Thoracic" by Sofia Elizondo is licensed under CC BY-NC-SA 4.0, modification of original by BlueLink.)*

Just as the gray matter is separated into horns, the white matter of the spinal cord is separated into funiculi (Figure 11.5.6 and Figure 11.5.8). Ascending tracts of nervous system fibers in these funiculi carry sensory information up to the brain, whereas **descending tracts** carry motor commands from the brain. Looking at the spinal cord longitudinally, the funiculi are further divided into columns that extend along its length as continuous bands of white matter. Between the two posterior horns of gray matter are the **posterior funiculi** composed of axons of ascending tracts. Between the two anterior horns, and bounded by the axons of motor neurons emerging from that gray matter area, are the **anterior funiculi**. The white matter on either side of the spinal cord,

between the posterior horn and the axons of the anterior horn neurons, are the **lateral funiculi**. The anterior and lateral funiculi are composed of many different column groups of axons of both ascending and descending tracts.

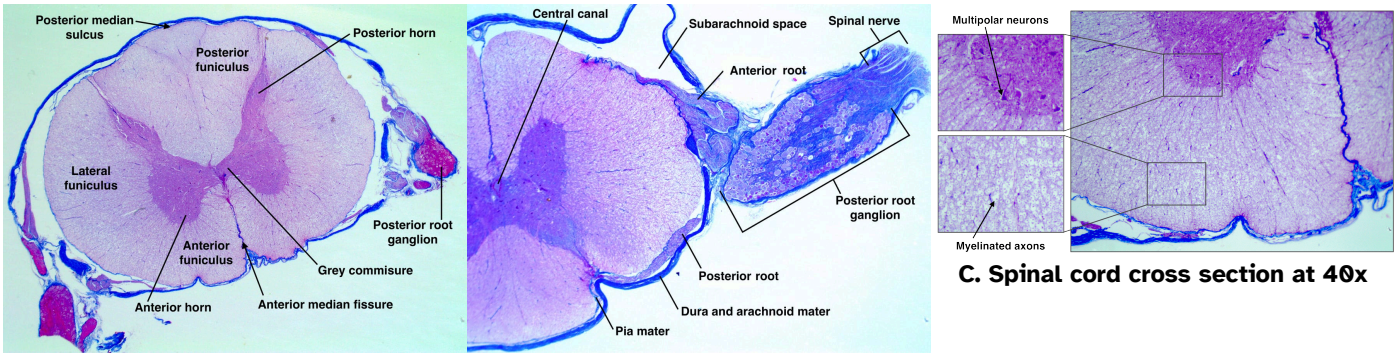

A. Spinal cord cross section at 15x

B. Spinal cord cross section at 20x

C. Spinal cord cross section at 40x

Figure 11.5.8: Spinal Cord Cross Section Histology. Histological cross sections allow for visualizing the horns and funiculi of the spinal cord. At 40x (image C) we can see the cell bodies of the multipolar neurons in the grey matter and the myelinated axons in the white matter. *(Image credit: "Spinal Cord Cross Section Histology" by Jennifer Lange are licensed under CC BY-NC-SA 4.0.)*

Regional Variations

Cross sectional views of the spinal cord vary, depending on the region from which the section was taken (Figure 11.5.8. The amount of white matter decreases between superior and inferior regions. The axons for all regions are present in the cervical spinal cord but only those for the sacral region are still present in the lumbar spinal cord, as many axons entered/exited in the intervening segments. You can imagine that the white matter for each spinal nerve is a "lane". At the level of C_1 all 31 lanes of the road are present, but as you travel inferiorly a lane exits/enters at each intervertebral foramen. At the inferior end of the cervical region 8 lanes will have headed out, leaving 23 lanes. At the inferior end of the thoracic region another 12 lanes will have headed out, leaving only 11 lanes in the lumbar region.

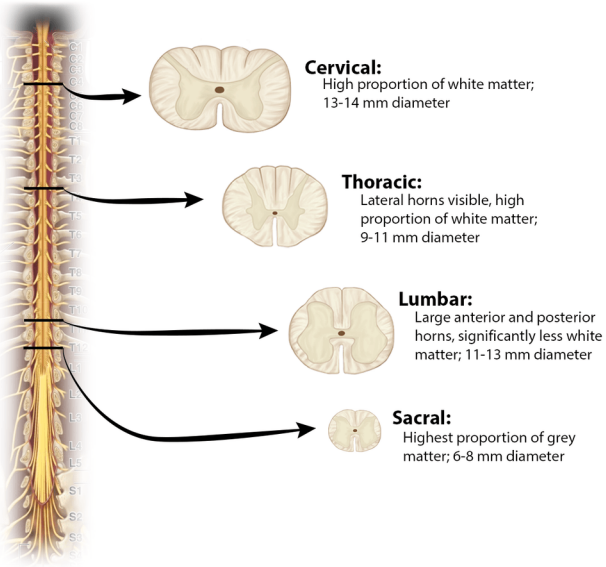

Figure 11.5.9: Spinal Cord Cross Sections - Regional Variation. Both the diameter and the relative proportions of grey and white matter vary in each region of the spinal cord. *(Image credit: "Spinal Cord Cross Sections - Regional Variations" by Jennifer Lange and Sofia Elizondo is licensed under CC BY-NC-SA 4.0, modification of originals by KnowledgeWorks (spinal cord in canal) and BlueLink (cross sections).)*

As discussed above, the volume of grey matter in each region varies by how many neurons are needed to serve each region. The grey matter in both the anterior and posterior horns is larger in both the cervical and lumbar regions to incorporate the large numbers of neurons needed for motor control and sensation in the upper and lower limbs.

Review Questions

Query 11.5.1

This interactive element is not available in this format. Visit the link or scan the QR code to access it online.

View this Interactive Content online

Glossary

Query 11.5.1

This interactive element is not available in this format. Visit the link or scan the QR code to access it online.

View this Interactive Content online

Contributors and Attributions

OpenStax Anatomy & Physiology (CC BY 4.0). Access for free at https://openstax.org/books/anatomy-and-physiology

This page titled 11.5: Spinal Cord is shared under a CC BY-NC-SA 4.0 license and was authored, remixed, and/or curated by Jennifer Lange et al..

- 12.6: Spinal Cord and Spinal Nerves by Whitney Menefee, Julie Jenks, Chiara Mazzasette, and Kim-Leiloni Nguyen is licensed CC BY 4.0.
- 15.3: Pituitary Gland and Hypothalamus by Whitney Menefee, Julie Jenks, Chiara Mazzasette, and Kim-Leiloni Nguyen is licensed CC BY 4.0.

11.6: Anatomical Atlas - Central Nervous System

A compendium of anatomical images: slides, models, and/or cadavers.

Interactive Content

This interactive element is not available in this format. Visit the link or scan the QR code to access it online.

View this Interactive Content online

Sheep Brain - Midsagittal View by **3-D Photogrammetry Anatomical Models** on **Sketchfab**

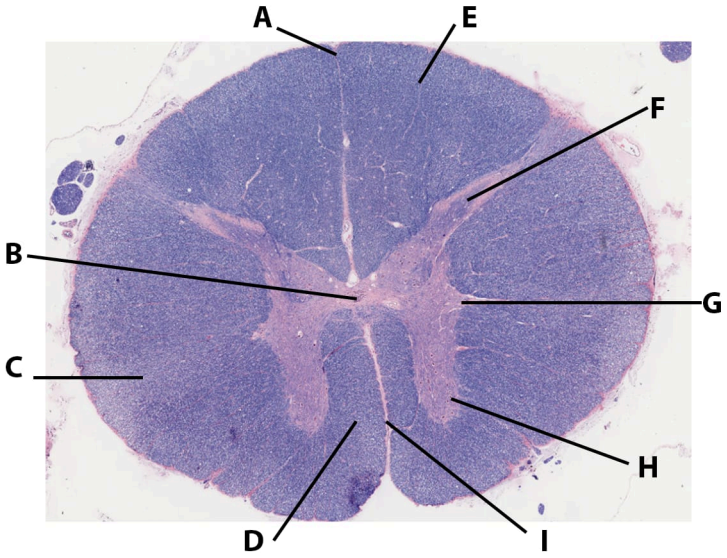

Image Credit

Thoracic Spinal Cord Histology by Jennifer Lange is licensed under CC BY-NC-SA 4.0, slide provided by the Regents of the University of Michigan Medical School under CC BY-NC-SA 4.0 © 2022.

Answer Key (click

A - poste

B - centr

C - latera

D - anter

E - poste

F - poste

G - latera

H - anter

I - anteri

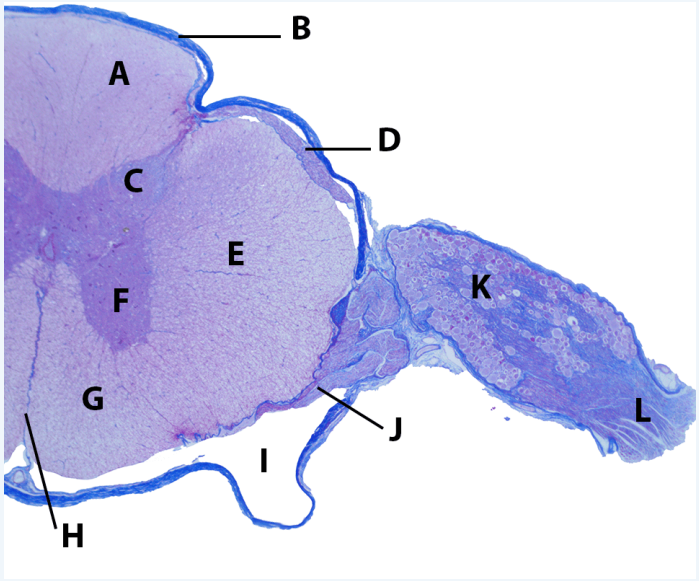

Image Credit

Spinal Cord Cross Section with Posterior Root Ganglion Histology by Jennifer Lange is licensed under CC BY-NC-SA 4.0.

Answer Key (click

A - poste

B - dura

C - poste

D - poste

E - latera

F - anter

G - anter

H - anter

I - subar

J - anteri

K - poste

L - spina

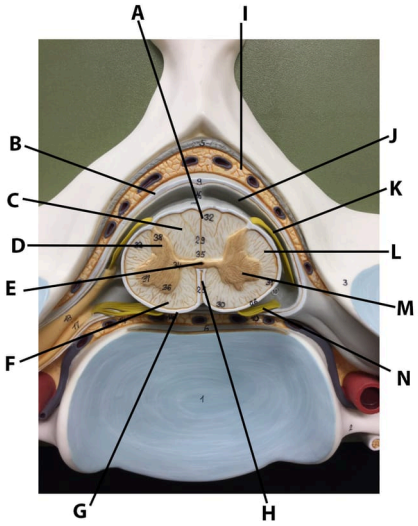

Image Credit

Spinal Cord with Vertebra Model by Jennifer Lange is licensed under CC BY-NC-SA 4.0.

Answer Key (click

A - poste

B - dura

C - poste

D - poste

E - centr

F - anter

G - pia m

H - anter

I - adipo

J - subar

K - poste

L - latera

M - ante

N - anter

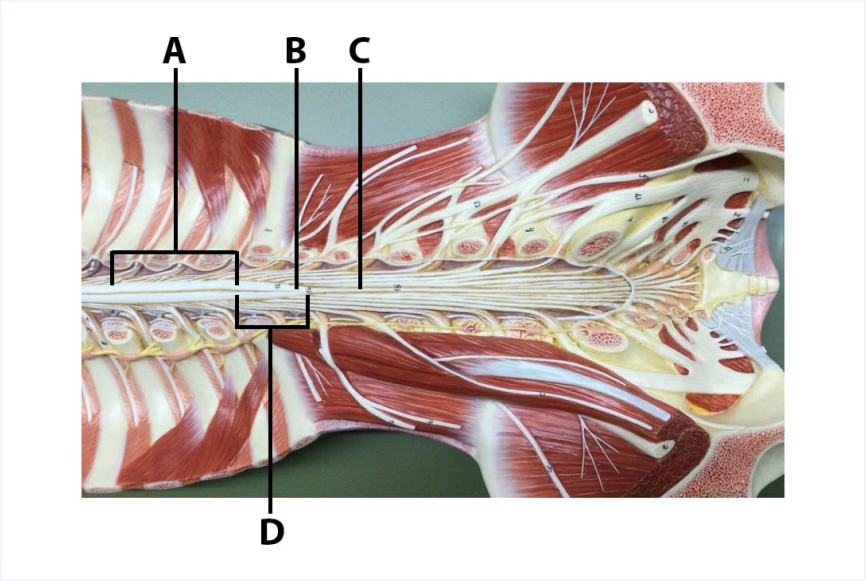

Image Credit

Spinal Cord in Spinal Canal by Jennifer Lange is licensed under CC BY-NC-SA 4.0

Answer Key (click

A - lumb

B - conu

C - filum

D - sacra

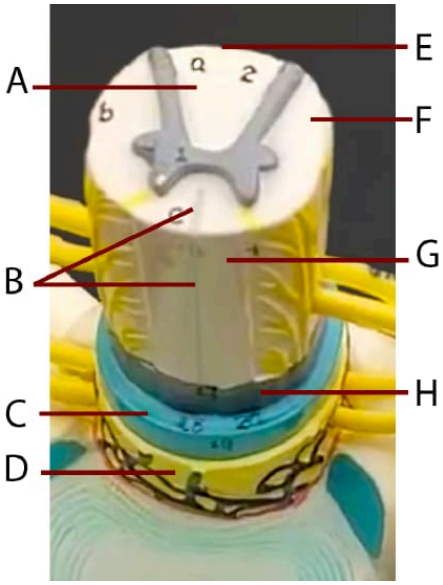

Image Credit

Thoracic Spinal Cord with Vertebrae by Jennifer Lange is licensed under CC BY-NC-SA 4.0

Answer Key (click

A - poste

B - anter

C - dura

D - adipo

E - poste

F - latera

G - anter

H - pia m

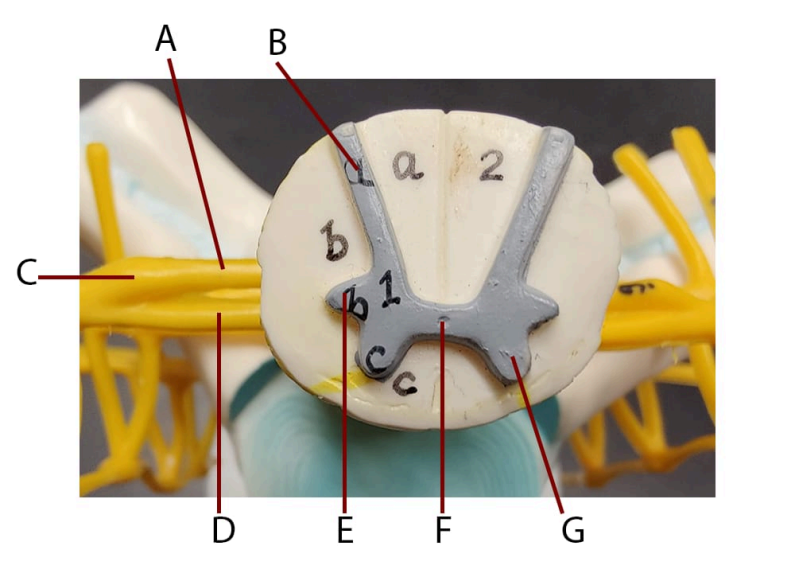

Image Credit

Thoracic Spinal Cord with Vertebrae - superior view by Jennifer Lange is licensed under CC BY-NC-SA 4.0

Answer Key (click

A - poste

B - poste

C - poste

D - anter

E - latera

F - centr

G - anter

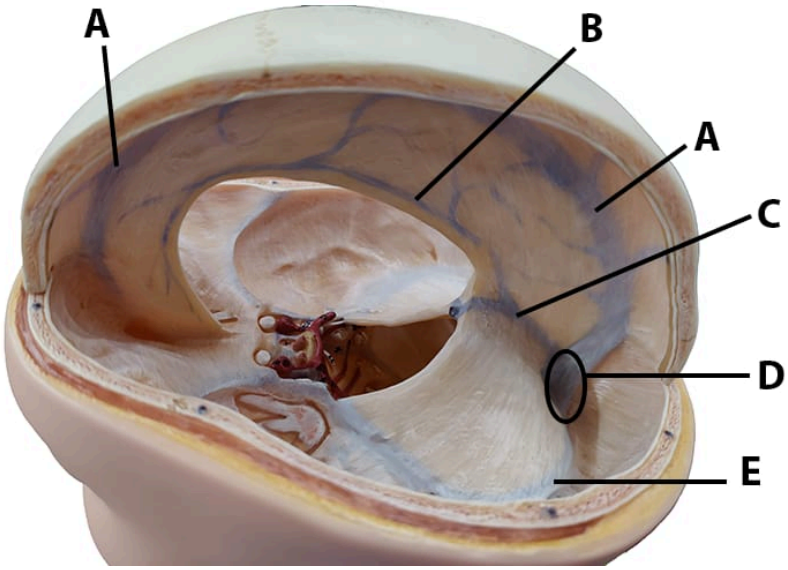

Image Credit

Dural Sinuses by Jennifer Lange is licensed under CC BY-NC-SA 4.0

Answer Key (click

A - super

B - inferi

C - straig

D - confl

E - transv

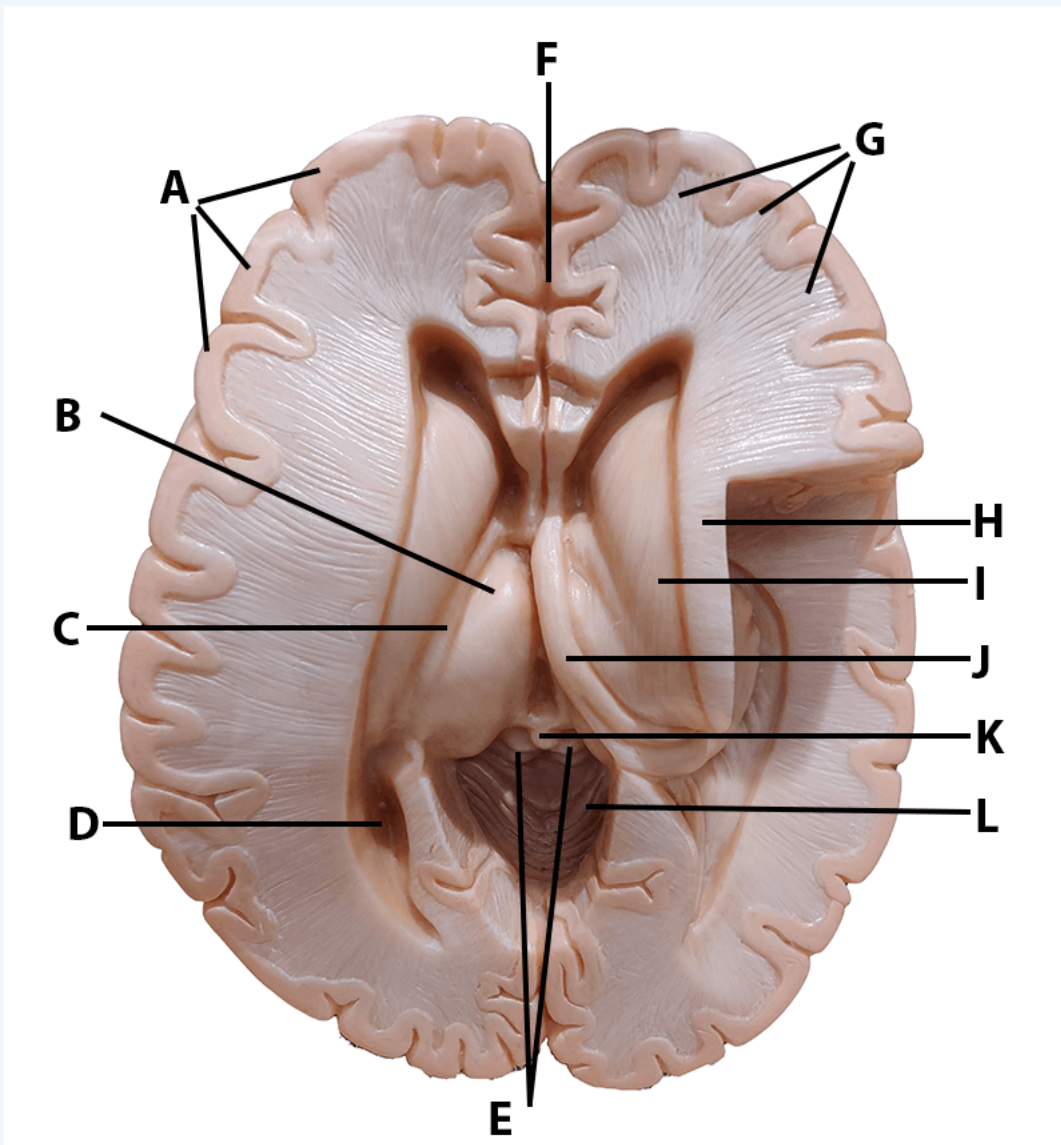

Image credit

Transverse Section of Brain Model by Jennifer Lange is licensed under [CC BY-NC-SA 4.0](#).

Answer Key (click

A - cereb

B - thala

C - interr

D - latera

E - super

F - longit

G - coror

H - corpu

I - basal

J - fornix

K - pinea

L - cereb

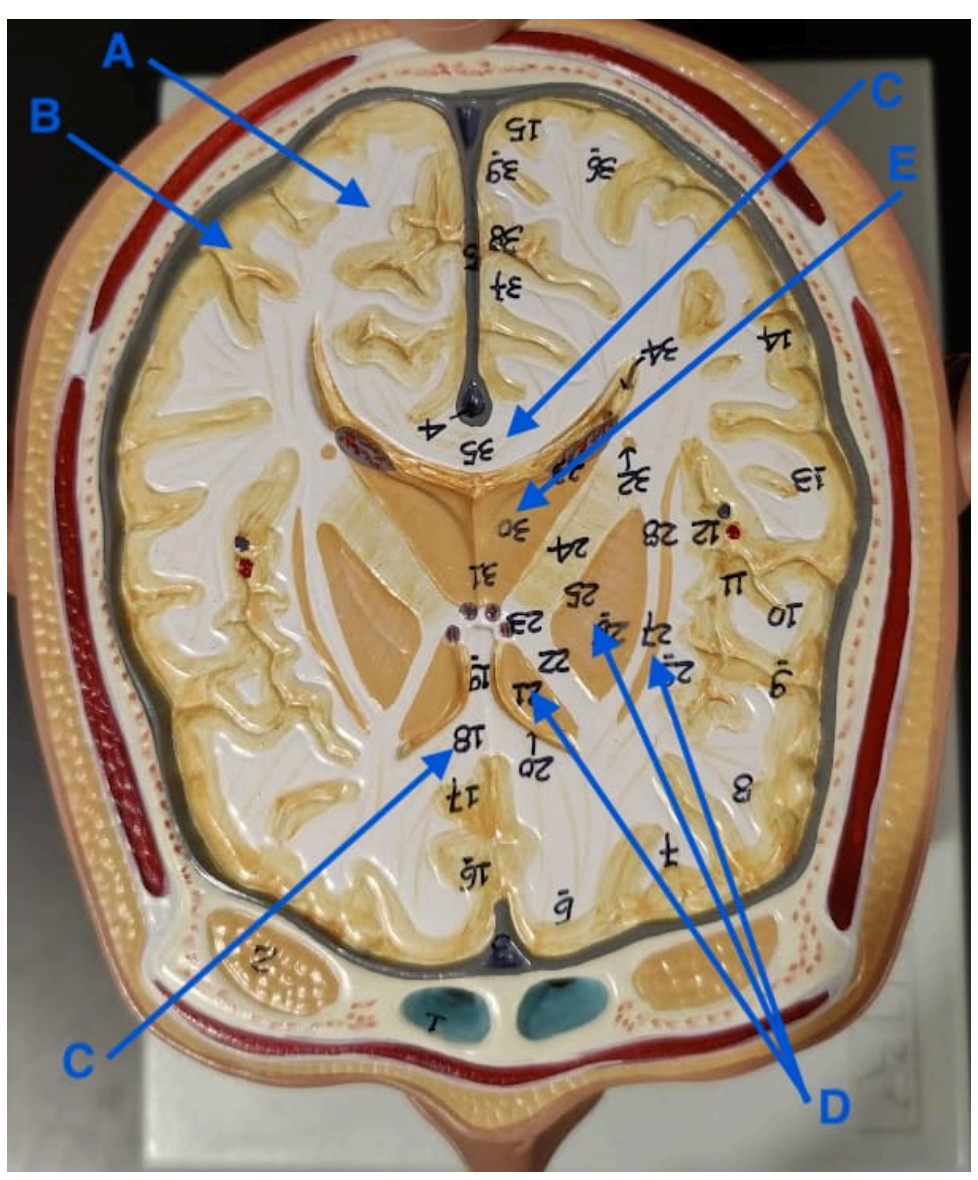

Image Credit

Brain Model Horizontal Section - Atlas by Jennifer Lange is licensed under [CC BY-NC-SA 4.0](#).

Answer Key (click

A - coror

B - cereb

C - corpu

D - basal

E - thala

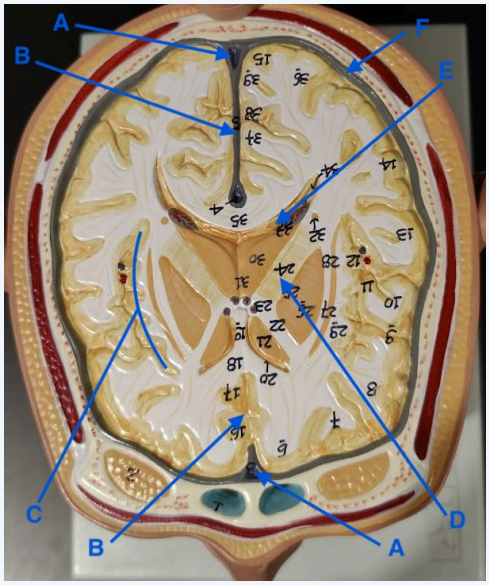

Image Credit

Brain Model Horizontal Section 2 - Atlas by Jennifer Lange is licensed under CC BY-NC-SA 4.0.

Answer Key (click

A - super

B - longit

C - insula

D - interr

E - latera

F - dura r

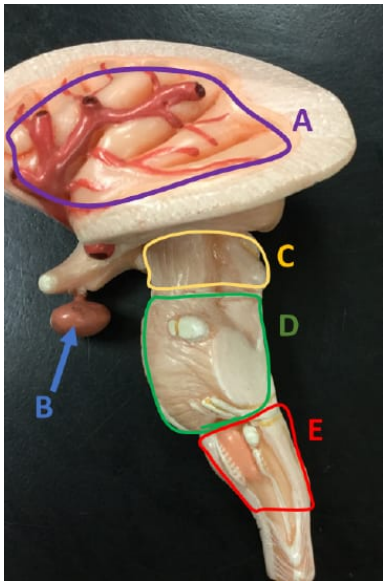

Image Credit

Brainstem Model Lateral View - Atlas by Jennifer Lange is licensed under CC BY-NC-SA 4.0.

Answer Key (click

A - insula

B - pituit

C - midb

D - pons

E - medu

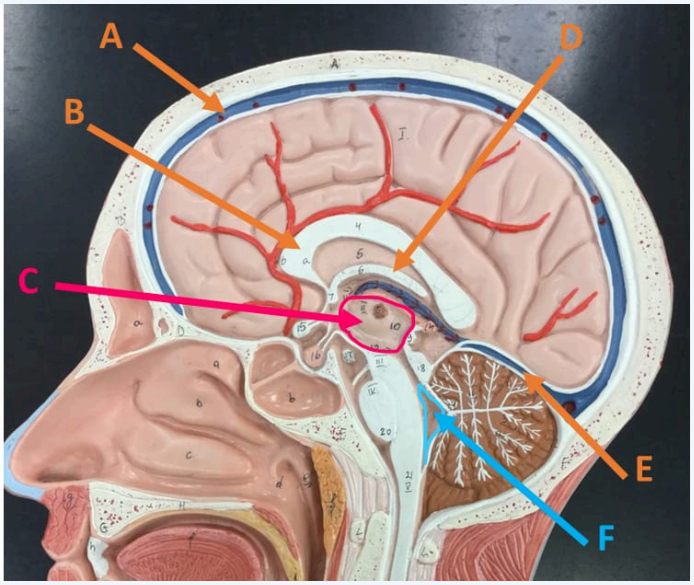

Image Credit

Head Model Lateral View 1 - Atlas by Jennifer Lange is licensed under CC BY-NC-SA 4.0

Answer Key (click

A - super

B - corpu

C - thala

D - fornix

E - straig

F - 4th ve

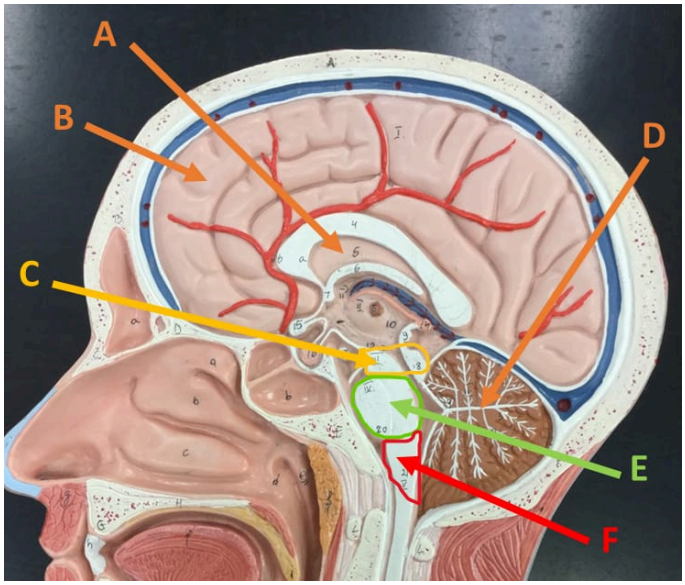

Image Credit

Head Model Lateral View 2 - Atlas by Jennifer Lange is licensed under CC BY-NC-SA 4.0

Answer Key (click

A - septu

B - cereb

C - midb

D - arbor

E - pons

F - medu

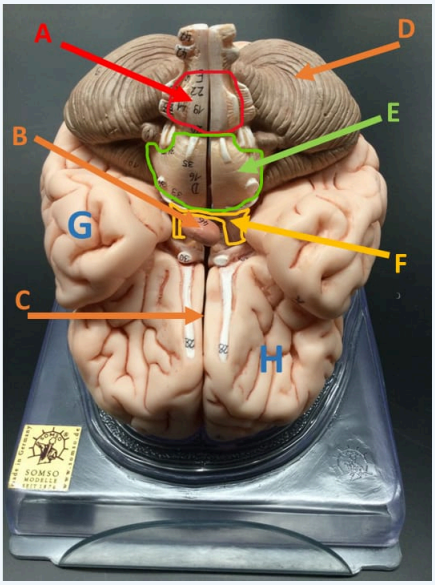

Image Credit

Brain Model Inferior View - Atlas by Jennifer Lange is licensed under CC BY-NC-SA 4.0

Answer Key (click

A - medu

B - pituit

C - longi

D - cereb

E - pons

F - midbr

G - temp

H - front

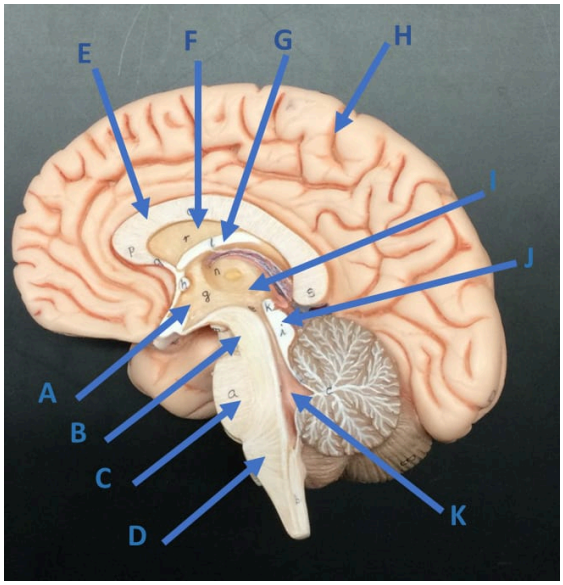

Image Credit

Brain Model Medial View 1 - Atlas by Jennifer Lange is licensed under CC BY-NC-SA 4.0

Answer Key (click

A - hypot

B - midb

C - pons

D - medu

E - corpu

F - septu

G - fornix

H - centr

I - thalar

J - tectal

K - fourth

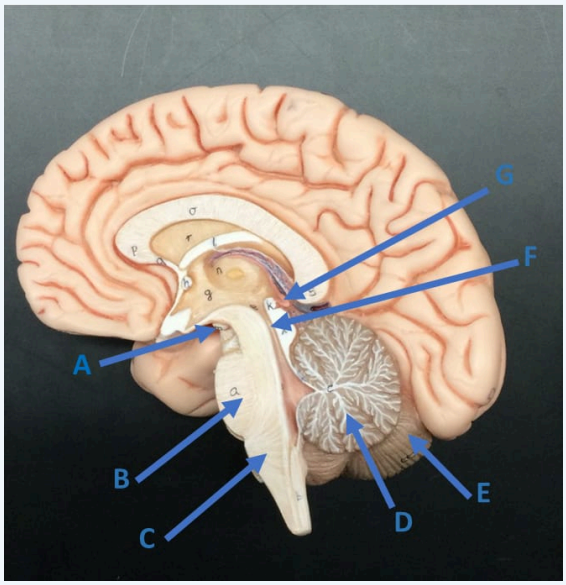

Image Credit

Brain Model Medial View 2 - Atlas by Jennifer Lange is licensed under CC BY-NC-SA 4.0

Answer Key (click

A - mam

B - pons

C - medu

D - arbor

E - corte

F - cereb

G - pinea

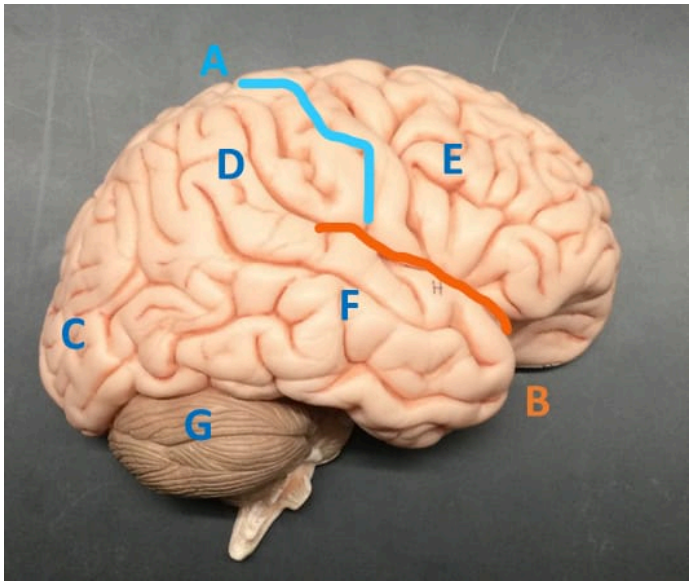

Image Credit

Brain Model Lateral View - Atlas by Jennifer Lange is licensed under CC BY-NC-SA 4.0

Answer Key (click

A - centr

B - latera

C - occip

D - parie

E - fronta

F - tempo

G - cereb

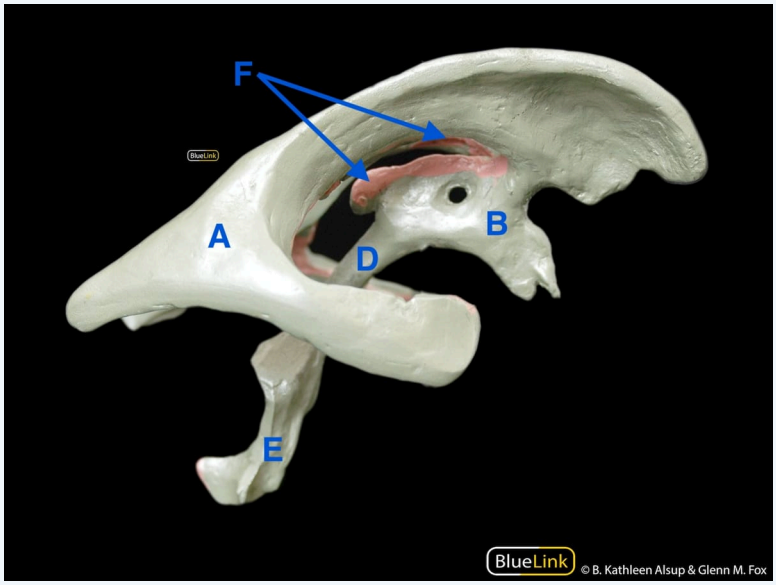

Image Credit

"Brain Ventricles - Atlas" by BlueLink is licensed under CC BY-NC 4.0 with notification of the original authors; labeling by Jennifer Lange

Answer Key (click

A - latera

B - 3rd/t

D - cereb

E - 4th/f

F - choro

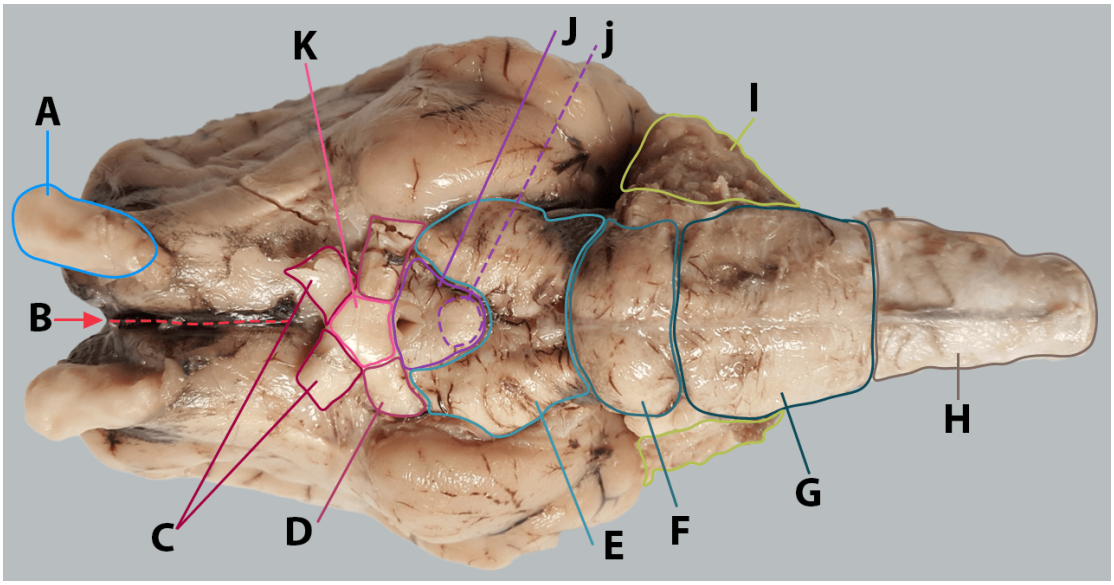

Image Credit

Sheep Brain Ventral View - Atlas by Jennifer Lange is licensed under CC BY-NC-SA 4.0, modification of original from biologycorner.

Answer Key (click

A - olfact

B - longi

C - optic

D - optic

E - midb

F - pons

G - medu

H - spina

I - cereb

J - hypot

j - mamn

K - optic

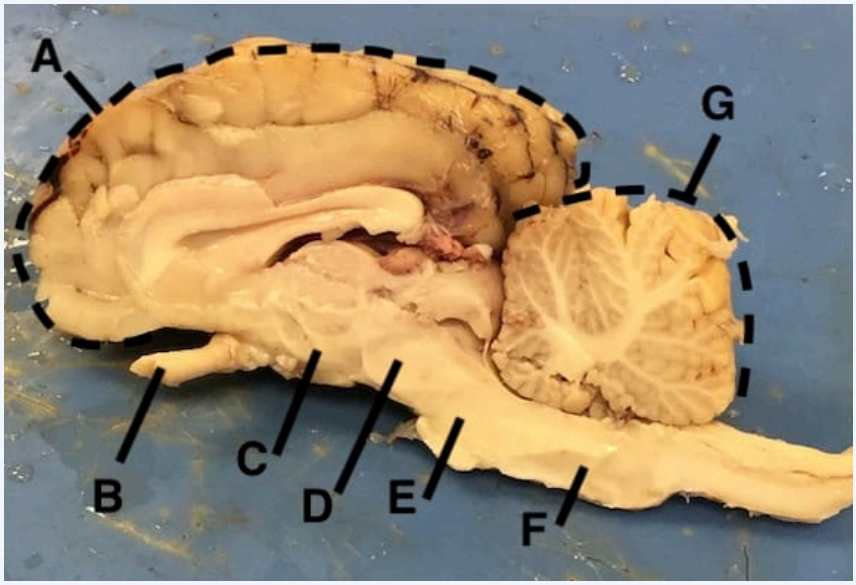

Image Credit

Sheep Brain Midsagittal View - Atlas by Jennifer Lange is licensed under CC BY-NC-SA 4.0.

Answer Key (click

A - cereb

B - optic

C - hypot

D - midb

E - pons

F - medu

G - cereb

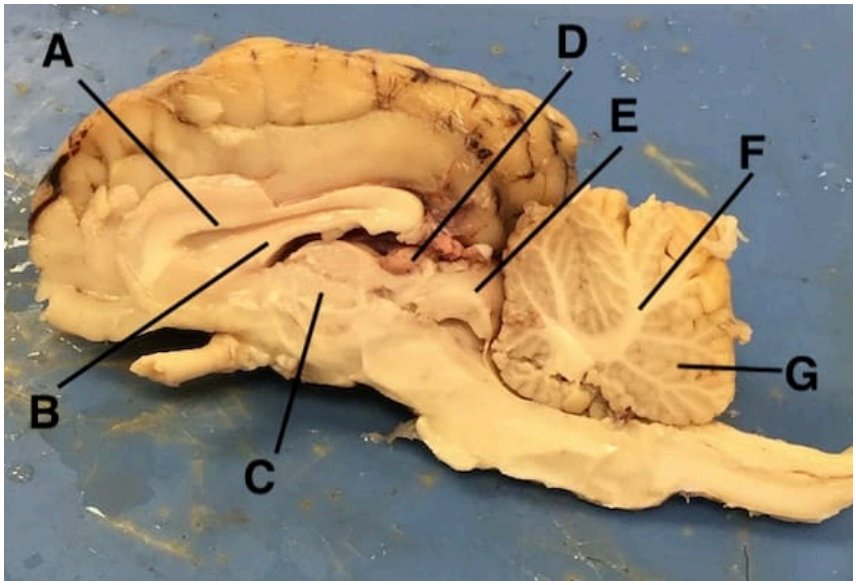

Image Credit

Sheep Brain Midsagittal View - Atlas by Jennifer Lange is licensed under CC BY-NC-SA 4.0.

Answer Key (click

A - corpu

B - fornix

C - thala

D - pinea

E - tectal

F - arbor

G - corte

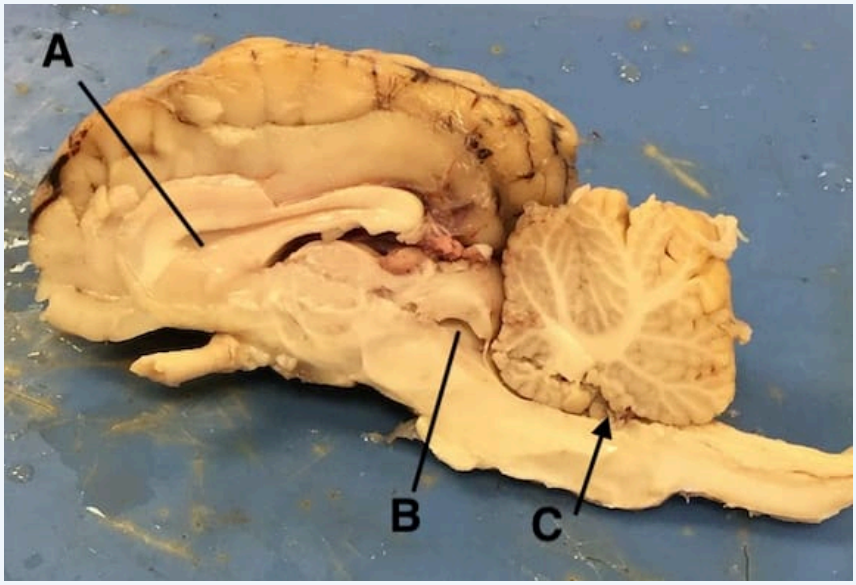

Image Credit

Sheep Brain Midsagittal View - Atlas by Jennifer Lange is licensed under CC BY-NC-SA 4.0.

Answer Key (click

A - septu

B - cereb

C - fourth

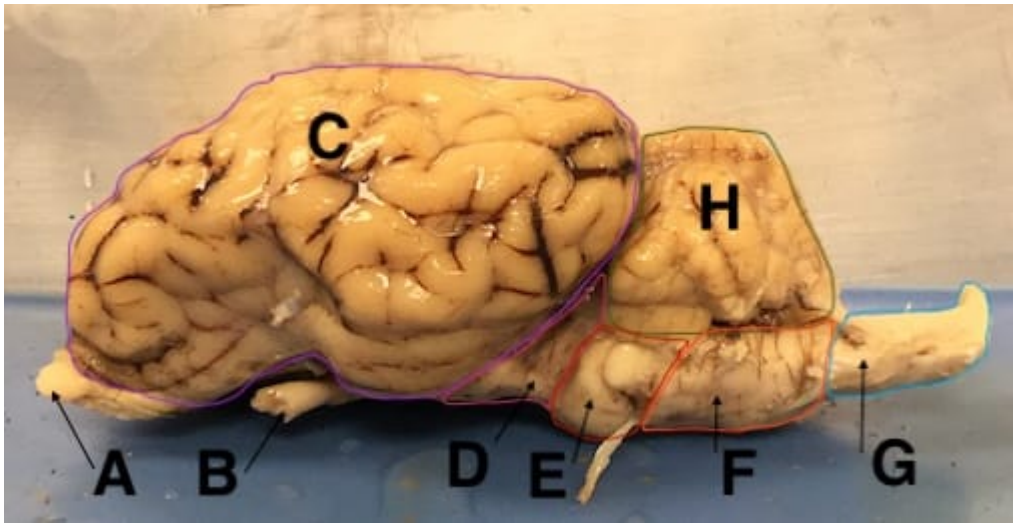

Image Credit

Sheep Brain Lateral View - Atlas by Jennifer Lange is licensed under CC BY-NC-SA 4.0.

Answer Key (click

A - olfact

B - optic

C - cereb

D - midb

E - pons

F - medu

G - spina

H - cereb

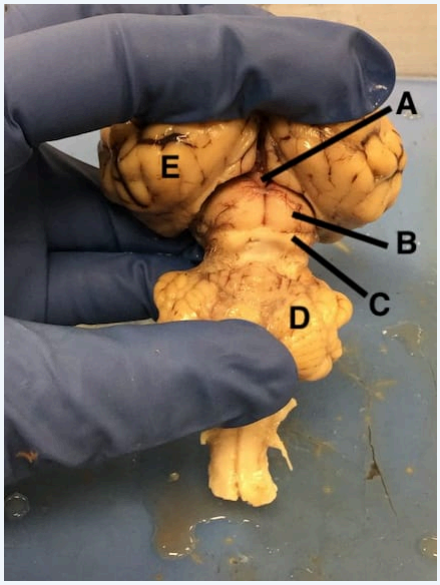

Image Credit

Sheep Brain Tectal Plate - Atlas by Jennifer Lange is licensed under CC BY-NC-SA 4.0.

Answer Key (click

A - pinea

B - super

C - inferi

D - cereb

E - occip

Image Credit

Sheep Brain Corpus Callosum - Atlas by Jennifer Lange is licensed under CC BY-NC-SA 4.0.

Answer Key (click

Corpus c

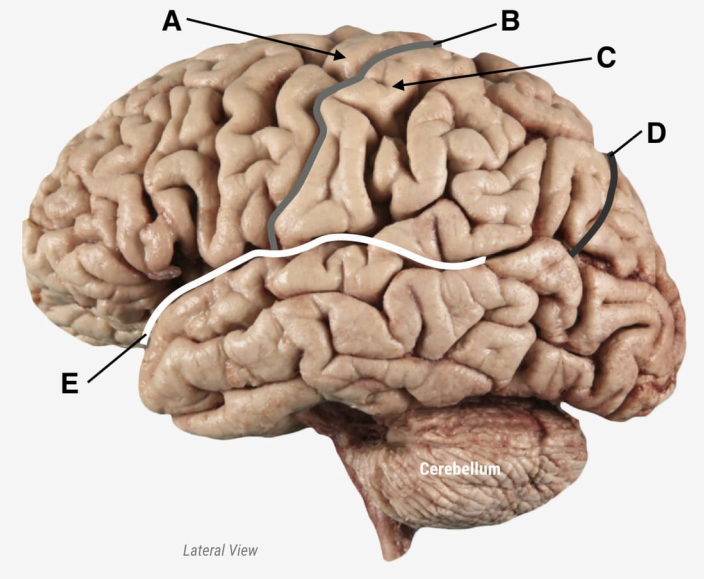

Image Credit

"Human Brain Features Lateral View - Atlas" by University of British Columbia's Clinical Anatomy is licensed under CC BY-NC-SA 4.0; labeling by Jennifer Lange.

Answer Key (click

A - Prece

B - Centr

C - Postc

D - Parie

E - Later

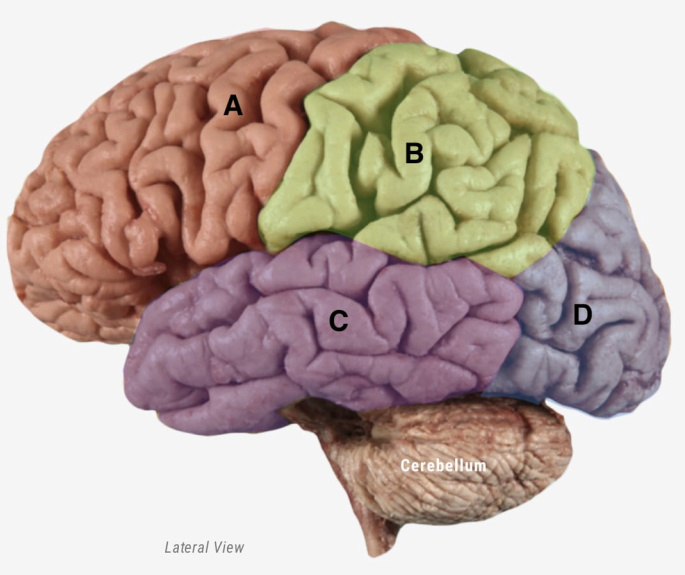

Image Credit

"Human Brain Cerebral Lobes Lateral View - Atlas" by University of British Columbia's Clinical Anatomy is licensed under CC BY-NC-SA 4.0; labeling by Jennifer Lange.

Answer Key (click

A - Front

B - Parie

C - Temp

D - Occi

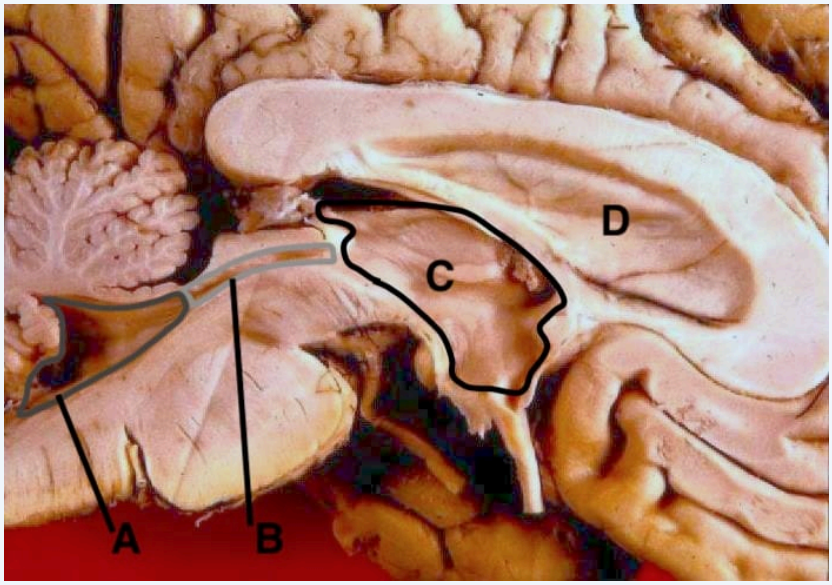

Image Credit

"Human brain left midsagittal view closeup - Ventricles Atlas" by John A. Beal, PhD Dep't. of Cellular Biology & Anatomy, Louisiana State University Health Sciences Center Shreveport is licensed under CC BY 2.5, via Wikimedia Commons; labeling by Jennifer Lange.

Answer Key (click

A - 4th/F

B - Cereb

C - 3rd/T

D - Septu

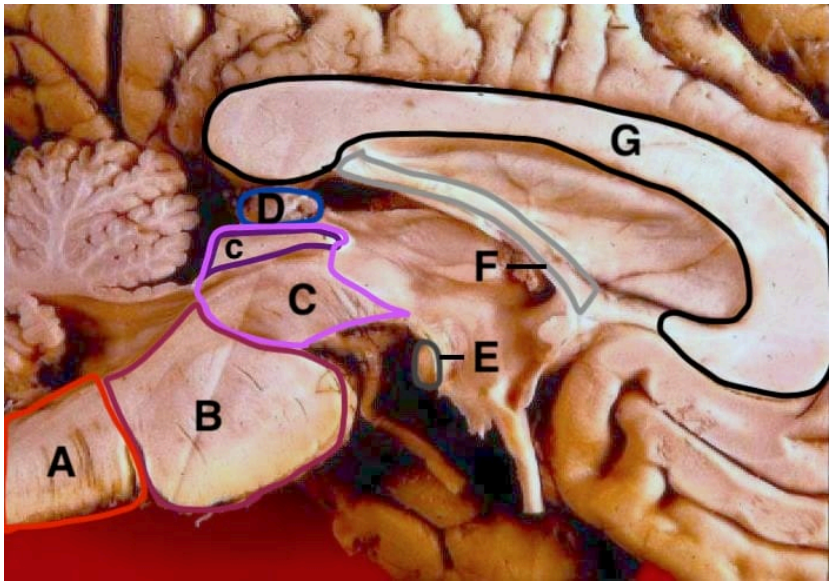

Image Credit

"Human brain left midsagittal view closeup - Features Atlas" by John A. Beal, PhD Dep't. of Cellular Biology & Anatomy, Louisiana State University Health Sciences Center Shreveport is licensed under CC BY 2.5, via Wikimedia Commons; labeling by Jennifer Lange.

Answer Key (click

A - Medu

B - Pons

C - Midb

c - tectal

D - Pinea

E - Mamı

F - Forni

G - Corp

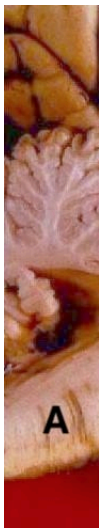

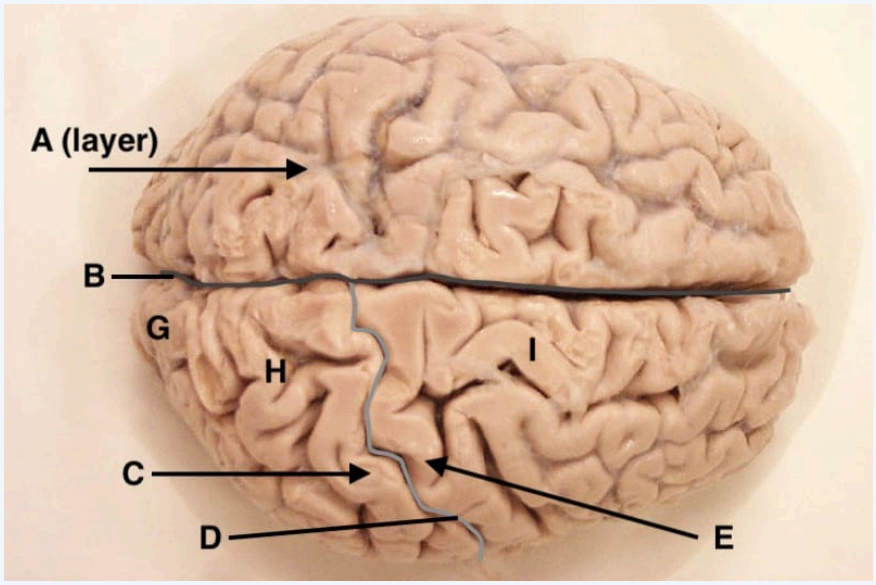

Image Credit

"Human Brain Features Superior View - Atlas" by EUSKALANATO is licensed under CC BY-NC-SA 2.0; labeling by Jennifer Lange.

Answer Key (click

A - Arach

B - Longi

C - Postc

D - Centr

E - Prece

G - Occip

H - Parie

I - Fronta

This page titled 11.6: Anatomical Atlas - Central Nervous System is shared under a CC BY-NC-SA 4.0 license and was authored, remixed, and/or curated by Jennifer Lange et al..

11.7: Practice Practical - Central Nervous System

Query 11.7.1

This interactive element is not available in this format. Visit the link or scan the QR code to access it online.

View this Interactive Content online

Query 11.7.1

This interactive element is not available in this format. Visit the link or scan the QR code to access it online.

View this Interactive Content online

Query 11.7.1

This interactive element is not available in this format. Visit the link or scan the QR code to access it online.

View this Interactive Content online

Query 11.7.1

This interactive element is not available in this format. Visit the link or scan the QR code to access it online.

View this Interactive Content online

Query 11.7.1

This interactive element is not available in this format. Visit the link or scan the QR code to access it online.

View this Interactive Content online

Query 11.7.1

This interactive element is not available in this format. Visit the link or scan the QR code to access it online.

View this Interactive Content online

Query 11.7.1

This interactive element is not available in this format. Visit the link or scan the QR code to access it online.

View this Interactive Content online

Query 11.7.1

This interactive element is not available in this format. Visit the link or scan the QR code to access it online.

View this Interactive Content online

Query 11.7.1

This interactive element is not available in this format. Visit the link or scan the QR code to access it online.

View this Interactive Content online

This page titled 11.7: Practice Practical - Central Nervous System is shared under a CC BY-NC-SA 4.0 license and was authored, remixed, and/or curated by Jennifer Lange et al..

12: PERIPHERAL NERVOUS SYSTEM

12.1: Introduction to the Peripheral Nervous System
12.2: Nerve and Ganglion Structure
12.3: Cranial Nerves
12.4: Spinal Nerves and Their Branches
12.5: Anatomical Atlas - Peripheral Nervous System
12.6: Practice Practical

This page titled 12: Peripheral Nervous System is shared under a CC BY-NC-SA 4.0 license and was authored, remixed, and/or curated by Jennifer Lange et al..

12.1: Introduction to the Peripheral Nervous System

Chapter Learning Objectives

After studying this chapter, you will be able to:

- List the cranial nerves in order of anatomical location and provide the central and peripheral connections
- Describe the major functions of each cranial nerve
- Match the spinal nerves with corresponding vertebrae and with their regional functions
- Diagram the branching pattern of the spinal nerves including the roots, rami, plexuses, and emergent nerves
- State whether each nerve is sensory, motor, or mixed; differentiate between somatic motor and visceral motor
- Trace the path of the major nerves arising from the brachial plexus, lumbar plexus, and sacral plexus

The peripheral nervous system consists of the nerves that branch out from the brain and spinal cord as well as the clusters of neuron cell bodies called ganglia. These nerves are the communication "wires" sending messages from the sensory receptors to the CNS and from the CNS to effector organs such as muscles and glands. The peripheral nervous system is divided into the sensory and motor divisions, with the motor division further subdivided into visceral motor (the autonomic nervous system) and somatic motor.

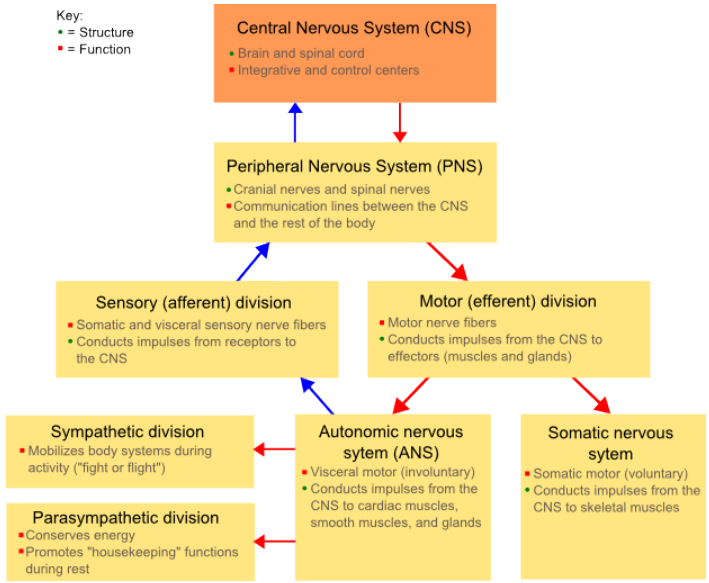

Figure 12.1.1: Organization of the peripheral nervous system. *(The original uploader was Fuzzform at English Wikipedia, CC BY-SA 3.0, via Wikimedia Commons.)*

This page titled 12.1: Introduction to the Peripheral Nervous System is shared under a CC BY-NC-SA 4.0 license and was authored, remixed, and/or curated by Jennifer Lange et al..

- 12.1: Introduction to the Central and Peripheral Nervous System by Whitney Menefee, Julie Jenks, Chiara Mazzasette, and Kim-Leiloni Nguyen is licensed CC BY 4.0.

12.2: Nerve and Ganglion Structure

The PNS is not as contained as the CNS because it is defined as everything that is not the brain or spinal cord. Some peripheral structures are incorporated into the other organs of the body. In describing the anatomy of the PNS, it is necessary to describe the common structures, the nerves and the ganglia, as they are found in various parts of the body. Many of the neural structures that are incorporated into other organs are features of the digestive system; these structures are known as the enteric nervous system and are a special subset of the PNS.

Nerve Structure

Bundles of axons in the PNS are referred to as nerves. These structures in the periphery are different than their central counterpart, called a tract. Nerves are organs, so they are composed of more than just nervous tissue. They have connective tissues invested in their structure, as well as blood vessels supplying the tissues with nourishment. The outer surface of a nerve is a surrounding layer of dense irregular connective tissue called the **epineurium**. Within the nerve, axons are further bundled into **fascicles**, which are each surrounded by their own layer of dense irregular connective tissue called the **perineurium**. Finally, individual axons (**nerve fibers**) are surrounded by areolar connective tissue called the **endoneurium** (Figure 12.2.1). These three layers are similar to the connective tissue sheaths for muscles. Nerves are associated with the region of the CNS to which they are connected, either as cranial nerves connected to the brain or spinal nerves connected to the spinal cord.

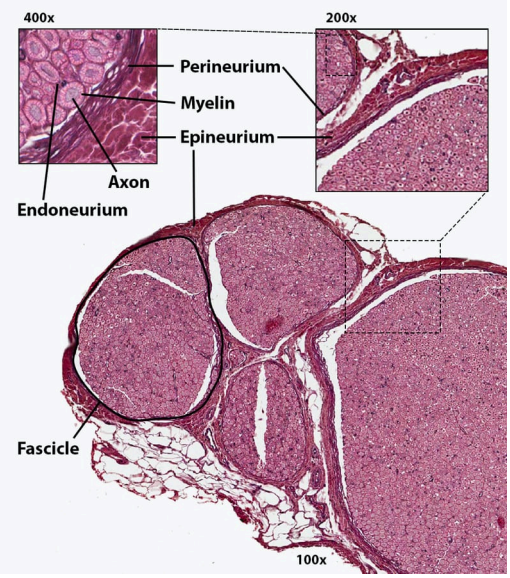

Figure 12.2.1: Nerve Structure. The structure of a nerve is organized by the layers of connective tissue on the surface, around each fascicle, and surrounding the individual nerve fibers. *(Image credit: "Nerve Structure" by Jennifer Lange; micrographs provided by Virginia Commonwealth University under CC BY-NC-SA 4.0)*

Ganglia

A ganglion (ganglia for plural) is a group of neuron cell bodies in the peripheral nervous system. Ganglia can be categorized, for the most part, as either sensory ganglia or autonomic ganglia, referring to their primary functions. A type of sensory ganglion is a **cranial nerve ganglion**. The roots of cranial nerves are within the cranium, whereas the ganglia are outside the skull. For example, the **trigeminal ganglion** is superficial to the temporal bone whereas its associated nerve is attached to the mid-pons region of the brainstem. The neurons of cranial nerve ganglia are also unipolar in shape with associated satellite cells. Another type of sensory ganglion is found associated with the spinal nerves - the **posterior (dorsal) root ganglia** (Figure 12.2.2). These ganglia, one for each spinal nerve, house the cell bodies of the sensory neurons bringing sensation from somatic regions inferior to the cranium. Within the spinal ganglia, the cell bodies of the unipolar neurons are surrounded by satellite cells (Figure 12.2.3).

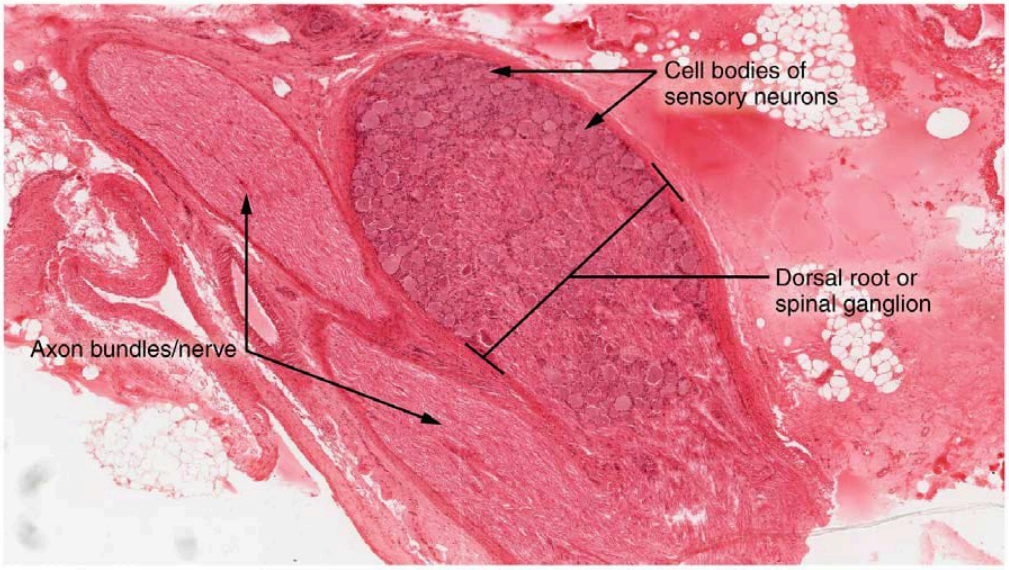

Figure 12.2.2: Posterior Root Ganglion. The cell bodies of sensory neurons, which are unipolar neurons by shape, are seen in this micrograph. Also, the fibrous region is composed of the axons of these neurons that are passing through the ganglion to be part of the dorsal nerve root (tissue source: canine). LM x 40. *(Image credit: "Dorsal Root Ganglion" by OpenStax is licensed under CC BY 4.0/Micrograph provided by the Regents of University of Michigan Medical School 2012.)*

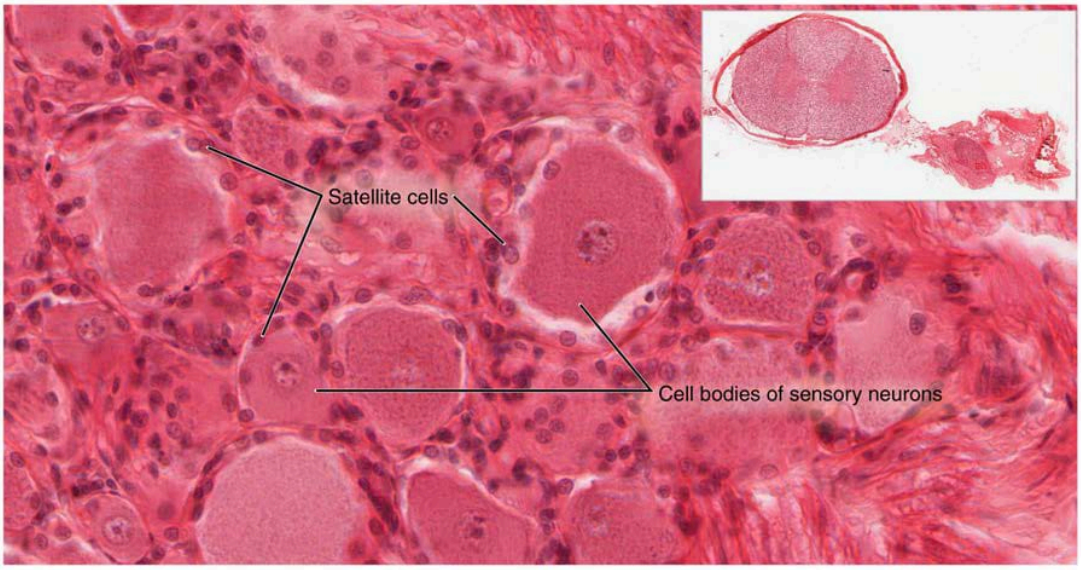

Figure 12.2.3: Close-Up of Posterior Root Ganglion. The micrograph includes both a cross-section of the lumbar spinal cord and a magnified section of the dorsal root ganglion showing cell bodies of sensory neurons surrounded by satellite cells (tissue source: canine). LM x 1600. *(Image credit: "DRG" by OpenStax is licensed under CC BY 4.0/Micrograph provided by the Regents of University of Michigan Medical School 2012)*

Autonomic ganglia differ in structure from the sensory ganglia because they contain the synapse point for the preganglionic cells projecting from the lateral horns of the spinal cord. In response to incoming signals, the neurons in the autonomic ganglia generate a new action potential that will be carried along the postganglionic axon to the effector organ/tissue. Examples of autonomic ganglia are the **sympathetic chain ganglia** (Figure 12.2.4) located lateral to the vertebral column and the **otic ganglion** near the foramen ovale.

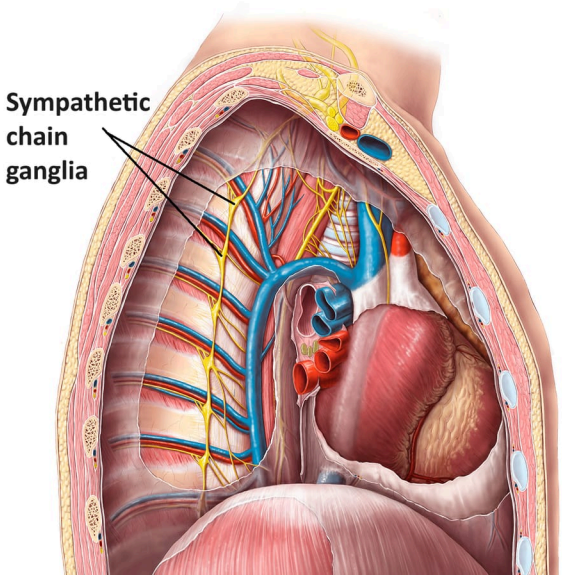

Figure 12.2.4: One group of autonomic ganglia are those found in the sympathic chain. *(Image credit: "Lateral view of opened thorax pericardium opened" by Nadja Baltensweiler, Arno Lataster, MUMC+ and Andreas Herrler, NAV, © Nadja Baltensweiler and Ned. Anatomen Vereniging, license: CC BY-NC-SA. Label by Jennifer Lange.)*

Concept Review

The PNS is composed of the groups of neuron cell bodies (ganglia) and bundles of axons (nerves) that are outside of the brain and spinal cord.

Nerves are organized into structures by layers of connective tissue that cover them. The epineurium covers the nerve, the perineurium covers the fascicles, and the endoneurium covers the individual axon. Nerves are classified as cranial nerves or spinal nerves on the basis of their connection to the brain or spinal cord, respectively.

Ganglia are of two types, sensory or autonomic. Sensory ganglia contain unipolar sensory neurons and are associated with many of the cranial nerves. Autonomic ganglia are the synapse point for neurons in the lateral horns of the spinal cord and for neurons in cranial nerve nuclei that have visceral motor functions.

Review Questions

Query 12.2.1

This interactive element is not available in this format. Visit the link or scan the QR code to access it online.

View this Interactive Content online

Critical Thinking Questions

Query 12.2.2

This interactive element is not available in this format. Visit the link or scan the QR code to access it online.

View this Interactive Content online

Glossary

Query 12.2.3

This interactive element is not available in this format. Visit the link or scan the QR code to access it online.

View this Interactive Content online

Contributors and Attributions

OpenStax Anatomy & Physiology (CC BY 4.0). Access for free at https://openstax.org/books/anatomy-and-physiology

This page titled 12.2: Nerve and Ganglion Structure is shared under a CC BY-NC-SA 4.0 license and was authored, remixed, and/or curated by Jennifer Lange et al..

- 12.5: Cranial Nerves by Whitney Menefee, Julie Jenks, Chiara Mazzasette, and Kim-Leiloni Nguyen is licensed CC BY 4.0.

12.3: Cranial Nerves

By the end of this section, you will be able to:

- Name the twelve cranial nerves and explain the functions associated with each

Cranial Nerves

The nerves attached to the brain are the cranial nerves, which are primarily responsible for the sensory and motor functions of the head and neck (with the exception of one that targets organs in the thoracic and abdominal cavities as part of the parasympathetic nervous system). There are twelve cranial nerves, which are designated CN I through CN XII for "Cranial Nerve," using Roman numerals for 1 through 12, based on the anatomical location on the inferior view of the brain, from rostral to caudal (Figure 12.3.1). They can be classified as sensory nerves, motor nerves, or a combination of both, meaning that the axons in these nerves originate out of sensory ganglia external to the cranium or motor nuclei within the brainstem. Sensory axons enter the brain to synapse in a nucleus. Motor axons connect to skeletal muscles of the head or neck or to autonomic ganglia. Three of the nerves are solely composed of sensory fibers; five are strictly motor; and the remaining four are mixed nerves.

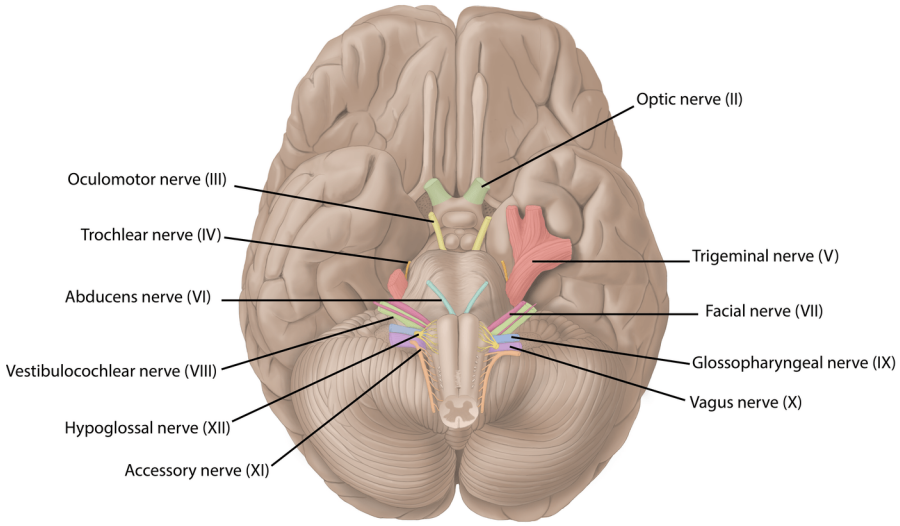

Figure 12.3.1: Cranial Nerves. The anatomical arrangement of the roots of the cranial nerves observed from an inferior view of the brain. Cranial nerves are numbered with Roman numbers from I to XII based on their exit from the brain, from rostral to caudal (CN I is not seen). *(Image credit: "Cranial Nerves" by Justin Greene and Jennifer Lange is licensed under CC BY-NC-SA 4.0.)*

Learning the cranial nerves is a tradition in anatomy courses, and students have always used mnemonic devices to remember the nerve names. A traditional mnemonic is "Oh Oh Oh To Touch And Feel Very Good Velvet Ah Heaven," in which the initial letter of each word corresponds to the initial letter in the name of each nerve. The names of the cranial nerves are listed in Table 12.3.1 along with a brief description of their function, their source (sensory ganglion or motor nucleus), and their target (sensory nucleus or skeletal muscle).

- The **olfactory nerve** is responsible for the sense of smell. It is usually not seen on the brain as its short fibers pass through the cribriform plate and thus are torn when the brain is extracted. Instead, we see the afferent nerves: the olfactory bulb and the olfactory tract.
- The **optic nerves** are responsible for the sense of vision. They enter the cranial vault through the optic canals.
- The **oculomotor nerve** is responsible for eye movements by controlling four of the extraocular muscles. It is also responsible for lifting the upper eyelid when the eyes point up, for pupillary constriction and focusing light by adjusting the lens of the eye. It passes through the superior orbital fissure.
- The **trochlear nerve** and the **abducens nerve** are both responsible for eye movement, each controlling a singular extraocular

muscle. They also pass through the superior orbital fissure.
- The **trigeminal nerve** is responsible for cutaneous sensations of the face and mouth and controlling the muscles of mastication. It has three branches, hence "tri", that pass through the superior orbital fissure, foramen rotundum, and foramen ovale.
- The **facial nerve** is responsible for the muscles involved in facial expressions as well as controlling the production and secretion of tears and of saliva. Its sensory component includes part of the sense of taste. It travels with CN VIII through the internal acoustic meatus.
- The **vestibulocochlear nerve** is responsible for the senses of hearing and balance.
- The **glossopharyngeal nerve** is responsible for controlling muscles in the oral cavity and upper throat and the production of saliva. Its sensory components include taste from the posterior tongue, blood pressure, and blood pH, pO2, and pCO2. It passes through the jugular foramen along with nerves X, and XI.
- The **vagus nerve** is responsible for both sensory and motor from/to the organs of the thoracic and abdominal cavities. It also carries motor signals to the muscles of the larynx, pharynx and soft palate. Additional sensory functions include taste and general sensory from the larynx. In innervating this broad area, the vagus nerve is responsible for the regulation of internal organ functions, such as digestion, heart rate, and respiratory rate, as well as vasomotor activity, and certain reflex actions, such as coughing, sneezing, swallowing, and vomiting.
- The **accessory nerve's spinal component** is responsible for controlling two muscles of the neck, the sternocleidomastoid and the superior portion of the trapezius.
- The **hypoglossal nerve** is responsible for controlling the muscles of the tongue. It exits the cranium through the hypoglossal canal.

Another important aspect of the cranial nerves that lends itself to a mnemonic is the functional role each nerve plays. The nerves fall into one of three basic groups. They are sensory, motor, or both (see Table 12.3.1). The sentence, “Some Say Marry Money But My Brother Says Brains Beauty Matter More,” corresponds to the type(s) of information carried by each nerve:

- **Sensory only:** the first, second, and eighth nerves are purely sensory: the olfactory (CN I), optic (CN II), and vestibulocochlear (CN VIII) nerves.
- **Motor only:** The three eye-movement nerves are all only motor: the oculomotor (CN III), trochlear (CN IV), and abducens (CN VI). The accessory (CN XI) and hypoglossal (CNXII) nerves are also strictly motor.
- **Both:** The remainder of the nerves contain both sensory and motor fibers, these are mixed nerves: the trigeminal (CN V), facial (CN VII), glossopharyngeal (CN IX), and vagus (CN X) nerves.

Table 12.3.1: Cranial Nerves

Mnemonic	#	Name	Function (S/M/B)	Central connection (nuclei)	Peripheral connection (ganglion or muscle)
Oh	I	Olfactory	Smell (S)	Olfactory bulb	Olfactory epithelium
Oh	II	Optic	Vision (S)	Hypothalamus/thalamus/ midbrain	Retina (retinal ganglion cells)
Oh	III	Oculomotor	Eye movements (M)	Oculomotor nucleus	Extraocular muscles (other 4), levator palpebrae superioris, ciliary ganglion (autonomic)
To	IV	Trochlear	Eye movements (M)	Trochlear nucleus	Superior oblique muscle
Touch	V	Trigeminal	Sensory – face and mouth; Motor - mastication (B)	Trigeminal nuclei in the midbrain, pons, and medulla	Trigeminal ganglion; Muscles of mastication
And	VI	Abducens	Eye movements (M)	Abducens nucleus	Lateral rectus muscle
Feel	VII	Facial	Motor – facial; Sensory - taste (B)	Facial nucleus, solitary nucleus, superior salivatory nucleus	Facial muscles, Geniculate ganglion, Pterygopalatine ganglion (autonomic)
Very	VIII	Vestibulocochlear	Hearing/balance (S)	Cochlear nucleus, Vestibular nucleus/ cerebellum	Spiral ganglion (hearing), Vestibular ganglion (balance)

Mnemonic	#	Name	Function (S/M/B)	Central connection (nuclei)	Peripheral connection (ganglion or muscle)
Good	IX	Glossopharyngeal	Motor – throat; Sensory - taste (B)	Solitary nucleus, inferior salivatory nucleus, nucleus ambiguus	Pharyngeal muscles, Geniculate ganglion, Otic ganglion (autonomic)
Velvet	X	Vagus	Motor/sensory – viscera (autonomic) (B); taste (S)	Medulla	Terminal ganglia serving thoracic and upper abdominal organs (heart and small intestines)
Ah	XI	Accessory	Motor – head and neck (M)	Spinal accessory nucleus	Neck muscles
Heaven	XII	Hypoglossal	Motor – tongue (M)	Hypoglossal nucleus	Muscles of the tongue

Interactive Link

Vision Loss

Query 12.3.1

This interactive element is not available in this format. Visit the link or scan the QR code to access it online.

View this Interactive Content online

AGING AND THE...

Nervous System: Anosmia

Anosmia is the loss of the sense of smell. It is often the result of the olfactory nerve being severed, usually because of blunt force trauma to the head. The sensory neurons of the olfactory epithelium have a limited lifespan of approximately one to four months, and new ones are made on a regular basis. The new neurons extend their axons into the CNS by growing along the existing fibers of the olfactory nerve. The ability of these neurons to be replaced is lost with age. Age-related anosmia is not the result of impact trauma to the head, but rather a slow loss of the sensory neurons with no new neurons born to replace them.

Smell is an important sense, especially for the enjoyment of food. There are only five tastes sensed by the tongue, and two of them are generally thought of as unpleasant tastes (sour and bitter). The rich sensory experience of food is the result of odor molecules associated with the food, both as food is moved into the mouth, and therefore passes under the nose, and when it is chewed and molecules are released to move up the pharynx into the posterior nasal cavity. Anosmia results in a loss of the enjoyment of food.

As the replacement of olfactory neurons declines with age, anosmia can set in. Without the sense of smell, many sufferers complain of food tasting bland. Often, the only way to enjoy food is to add seasoning that can be sensed on the tongue, which usually means adding table salt. The problem with this solution, however, is that this increases sodium intake, which can lead to cardiovascular problems through water retention and the associated increase in blood pressure.

Autonomic Functions

Four of these cranial nerves make up the cranial component of the autonomic nervous system, as they innervate smooth muscle, cardiac muscle, or glands.

- The oculomotor nerves are responsible for innervating the intra-ocular muscles responsible for pupillary diameter and adjusting the eyes' focal point.
- The facial and glossopharyngeal nerves control salivation and lacrimation, which are glandular secretions.
- The regulation of the organs of the thoracic and abdominal cavities such as the heart, bronchial tree, stomach, pancreas, adrenal glands, and kidneys by the vagus nerve.

Anatomical Variation

Is CN XI really a cranial nerve? Maybe.

The spinal root of the accessory nerve ascends from the superior region of the cervical spinal cord and enters the cranium through the foramen magnum. The cranial root emerges from the medulla oblongata. Reasons for the debate:

- the spinal root has numerous anastomoses with the spinal dorsal and ventral rootlets
- 20% of specimens in one study did not have a cranial root
- variation exists in axonic pathways before the jugular foramen - in some individuals the cranial root and the spinal root travel separately through the jugular foramen
- variation exists in axonic pathways after the jugular foramen - in some individuals the axons from both roots are found in the nerve's two branches, whereas in others the branches contained axons from only one root
- the cranial root has considerable functional and termination overlap with the vagus nerve, and multiple patterns of interconnections between the two have been found
- the vagus nerve and the accessory nerve develop from the same embryonic ganglion, with variable patterns of separation during development

Studies on this topic have come to opposing findings, so the real debate may end up being "what is the definition of a cranial nerve?".

For further reading:

- Johal, J., Iwanaga, J., Tubbs, K., Loukas, M., Oskouian, R.J. and Tubbs, R.S. (2019) The Accessory Nerve: A Comprehensive Review of its Anatomy, Development, Variations, Landmarks and Clinical Considerations. *Anat. Rec., 302*: 620-629. https://doi.org/10.1002/ar.23823.

- Liu HF, Won HS, Chung IH, Kim IB, Han SH (2014a) Morphological characteristics of the cranial root of the accessory nerve. *Clin Anat 27*(8): 1167–1173. https://doi.org/10.1002/ca.22451.

- Liu HF, Won HS, Chung IH, Oh CS, Kim IB (2014b) Variable composition of the internal and external branches of the accessory nerve. *Clin Anat 27*(1): 97–101. https://doi.org/10.1002/ca.22308.

- Ong CK, Chong VFH. (2010) The glossopharyngeal, vagus and spinal accessory nerves. *Eur J Radiol* *74*(2): 359–367. https://doi.org/10.1016/j.ejrad.2009.05.064.
- Ryan S, Blyth P, Duggan N, Wild M, Al-Ali S. Is the cranial accessory nerve really a portion of the accessory nerve? Anatomy of the cranial nerves in the jugular foramen. *Anatomical Science International*. 2007, 82(1):1-7. https://doi.org/10.1111/j.1447-073X.2006.00154.x.

Concept Review

The twelve cranial nerves can be strictly sensory in function, strictly motor in function, or a combination of the two functions. The olfactory nerve (CN I) and optic nerve (CN II) are responsible for the sense of smell and vision, respectively. The oculomotor nerve (CN III) is responsible for eye movements, lifting the upper eyelid and size of the pupil. The trochlear nerve (CN IV) and the abducens nerve (CN VI) are both responsible for eye movement, but do so by controlling different extraocular muscles. The trigeminal nerve (CN V) is responsible for cutaneous sensations of the face and controlling the muscles of mastication. The facial nerve (VII) is responsible for the muscles involved in facial expressions, as well as part of the sense of taste and the production of saliva. The vestibulocochlear nerve (VIII) is responsible for the senses of hearing and balance. The glossopharyngeal nerve (IX) is responsible for controlling muscles in the oral cavity and upper throat, as well as part of the sense of taste and the production of saliva. The vagus nerve (CN X) is responsible for contributing to homeostatic control of the organs of the thoracic and upper abdominal cavities. The accessory nerve (CN XI) is responsible for controlling the muscles of the neck, along with cervical spinal nerves. The hypoglossal nerve (CN XII) is responsible for controlling the muscles of the lower throat and tongue.

Review Questions

Query 12.3.2

This interactive element is not available in this format. Visit the link or scan the QR code to access it online.

View this Interactive Content online

Critical Thinking Questions

Query 12.3.3

This interactive element is not available in this format. Visit the link or scan the QR code to access it online.

View this Interactive Content online

Query 12.3.4

This interactive element is not available in this format. Visit the link or scan the QR code to access it online.

View this Interactive Content online

Glossary

Query 12.3.5

This interactive element is not available in this format. Visit the link or scan the QR code to access it online.

View this Interactive Content online

Contributors and Attributions

OpenStax Anatomy & Physiology (CC BY 4.0). Access for free at https://openstax.org/books/anatomy-and-physiology

This page titled 12.3: Cranial Nerves is shared under a CC BY-NC-SA 4.0 license and was authored, remixed, and/or curated by Jennifer Lange et al..

- 12.5: Cranial Nerves by Whitney Menefee, Julie Jenks, Chiara Mazzasette, and Kim-Leiloni Nguyen is licensed CC BY 4.0.

12.4: Spinal Nerves and Their Branches

By the end of this section, you will be able to:

- Describe the sensory and motor components of spinal nerves and the plexuses that they pass through
- Explain what a dermatome is and its clinical significance

Along the spinal cord, spinal nerves emerge that carry both sensory and motor information.

Spinal Nerves

The nerves connected to the spinal cord are the spinal nerves. The arrangement of these nerves is much more regular than that of the cranial nerves. All of the spinal nerves are combined sensory and motor axons that separate into two nerve roots. The sensory axons enter the spinal cord as the dorsal nerve root. The motor fibers, both somatic and autonomic, emerge as the ventral nerve root.

There are 31 spinal nerves, named for the level of the spinal cord at which each one emerges (Figure 12.4.1). There are

- eight pairs of cervical nerves designated C_1 to C_8,
- twelve pairs of thoracic nerves designated T_1 to T_{12},
- five pairs of lumbar nerves designated L_1 to L_5,
- five pairs of sacral nerves designated S_1 to S_5, and
- one pair of coccygeal nerves designated Co_1.

The nerves are numbered from the superior to inferior positions, and each emerges from the vertebral column through the intervertebral foramen at its level. The first nerve, C1, emerges between the first cervical vertebra and the occipital bone. The second nerve, C2, emerges between the first and second cervical vertebrae. The same occurs for C3 to C7, but C8 emerges between the seventh cervical vertebra and the first thoracic vertebra. For the thoracic and lumbar nerves, each one emerges between the vertebra that has the same designation and the next vertebra in the column. The sacral nerves emerge from the sacral foramina along the length of that unique vertebra.

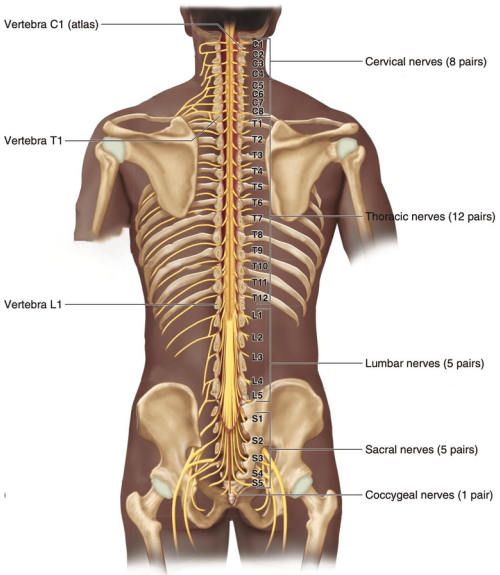

Figure 12.4.1: Spinal Cord and Spinal Nerves. The spinal nerves emerge laterally from the vertebral column with 8 in the cervical region, 12 in the thoracic region, 5 in the lumbar region, 5 in the sacral region, and 1 in the coccygeal region. *(Image credit: "Spinal Cord and Spinal Nerves" by Gabrielle Spurlock is licensed under CC BY-NC-SA 4.0, based on original by "KnowledgeWorks - Drawing Spinal nerves and plexuses - English labels" by KnowledgeWorks Global Ltd.)*

Spinal Nerve Branching

As shown in Figures 12.4.2 and 12.4.3, axons coming from the **posterior (dorsal) root ganglion** enter the posterior side through the **posterior (dorsal) nerve root**. The axons emerging from the anterior side do so through the **anterior (ventral) nerve root**. The posterior and anterior nerve roots fuse together to form the **spinal nerves**.

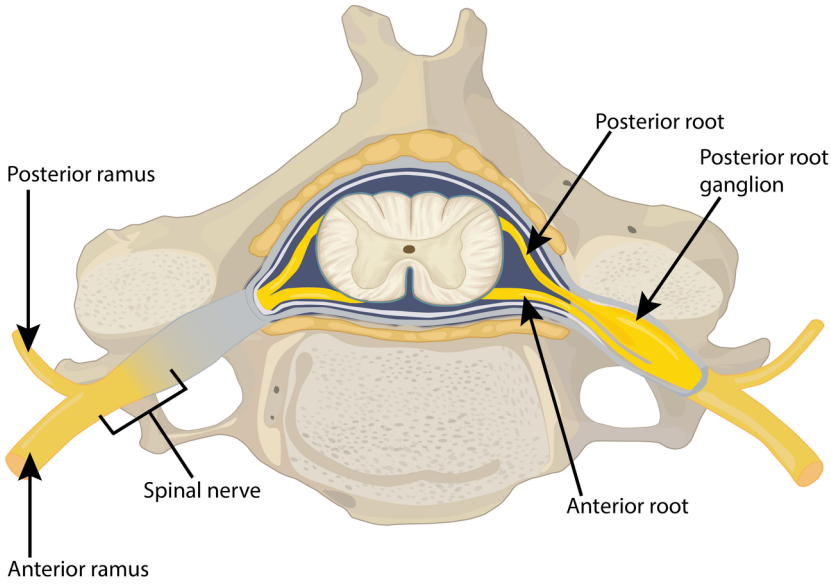

Figure 12.4.2: Spinal Cord within Vertebra. The superior view of a cross section of spinal cord within the vertebra shows the posterior and anterior roots emerging from the spinal cord and fusing to form the spinal nerve. On the posterior root, a posterior root ganglion contain sensory neuron cell bodies. After emerging from the vertebral column the spinal nerves split into rami. *(Image credit: "Spinal Cord within Vertebra" by Sofia Elizondo is licensed under CC BY-NC-SA 4.0; spinal cord original graphic from BlueLink.)*

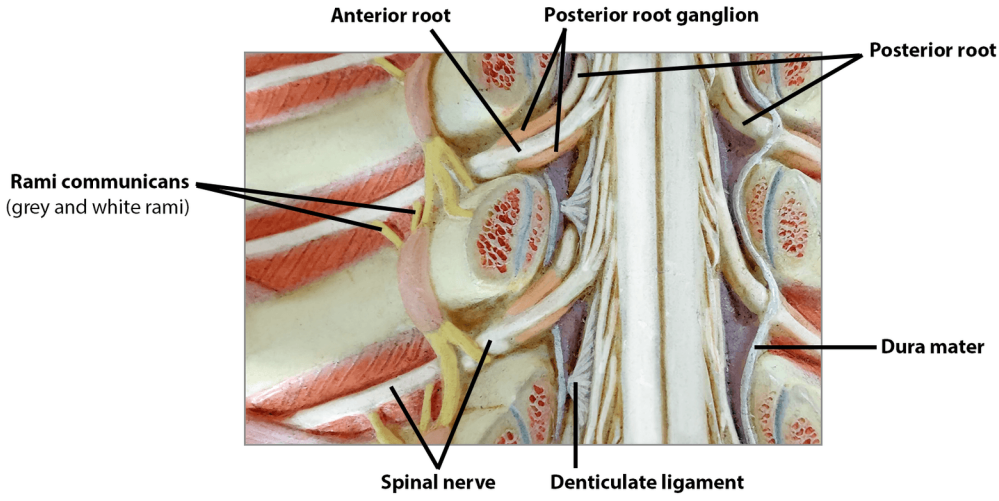

Figure 12.4.3: Spinal Cord and Spinal Nerve Branching. The posterior roots, posterior root ganglia, and the anterior roots are located in the intervertebral foraminia, where they exit the dural sheath and merge to form the spinal nerve. (*Image credit: "Spinal Cord and Spinal Nerve Branching" by Jennifer Lange is licensed under CC BY-NC-SA 4.0.*)

The posterior and anterior nerve roots join to form the spinal nerve, which thus contains mixed sensory and motor information. The spinal nerves are quite short. Lateral to the vertebral column the nerve fibers split and head to different locations in the body via the rami: those traveling in the **posterior (dorsal) ramus** serve the muscles and skin of the posterior trunk, those in the larger **anterior (ventral) ramus** travel either to the anterolateral trunk or to the limbs. Both the anterior and posterior rami are mixed nerves carrying somatic motor fibers and sensory fibers ((Figure 12.4.4). The visceral motor fibers take a different path via the **rami communicans** (grey and white rami) (Figure 12.4.3), which will be explored more in Chapter 14.

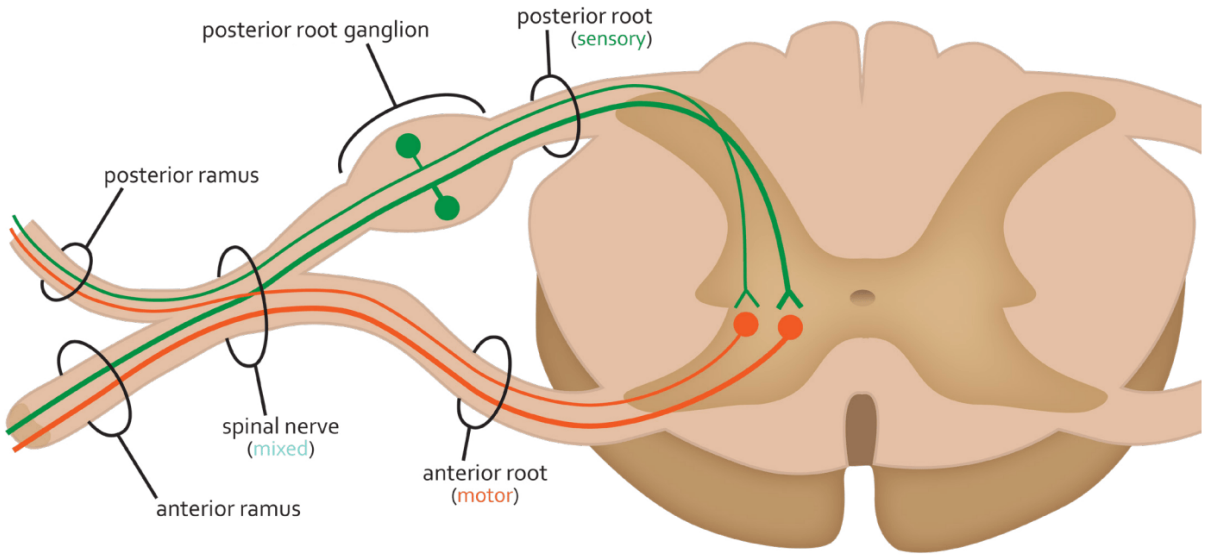

Figure 12.4.4: Spinal Roots, Nerves, and Rami. The anterior and posterior nerve roots exiting a cross section of spinal cord fuse together to form a spinal nerve, which then splits into the anterior and posterior rami. *(Image credit: "Schematic of Spinal Nerve Components" by University of British Columbia Clinical Anatomy is licensed under CC BY-NC 4.0, labeling modification by Jennifer Lange.)*

In the thoracic region (T_2-T_{12}), the anterior rami are called **intercostal nerves** because they travel deep to the intercostal muscles in the space between adjacent ribs (Figure 12.4.5).

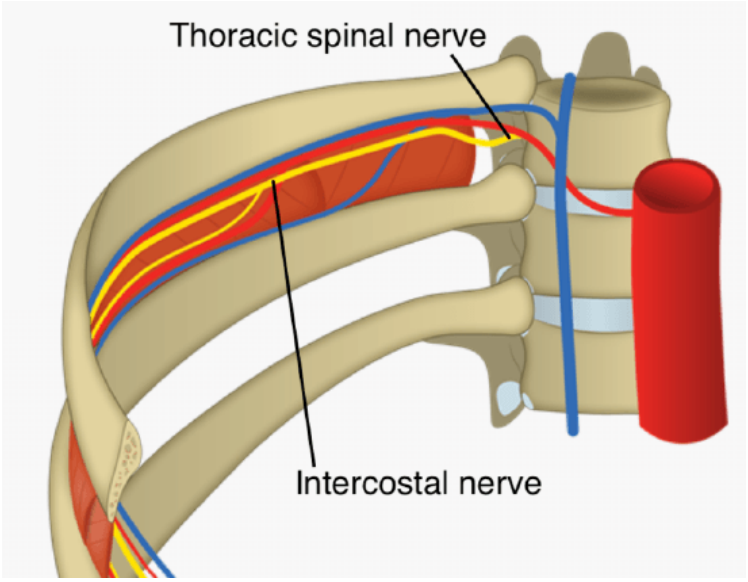

Figure 12.4.5: Intercostal Nerves. In the thoracic region each ventral ramus becomes an intercostal nerve that travels along the inferior surface of a rib to the sternum. *(Image credit: "Intercostal Nerves" by University of British Columbia Clinical Anatomy is licensed under CC BY-NC-SA 4.0, labeling by Jennifer Lange.)*

Nerve Plexuses

In the cervical, lumbar and sacral regions the nerves in the periphery are not straight continuations of the spinal nerves, but rather the reorganization of the axons in those nerves to follow different courses. Axons from different spinal nerves merge and split multiple times at four places along the length of the vertebral column, each identified as a **nerve plexus** (plexus = a braid). Of the four nerve plexuses, two are found at the cervical level, one at the lumbar level, and one at the sacral level (Figure 12.4.6).

The **cervical plexus** is composed of axons from spinal nerves C_1 through C_5. It branches into nerves in the posterior neck and head as well as the phrenic nerve, which connects to the diaphragm at the base of the thoracic cavity.

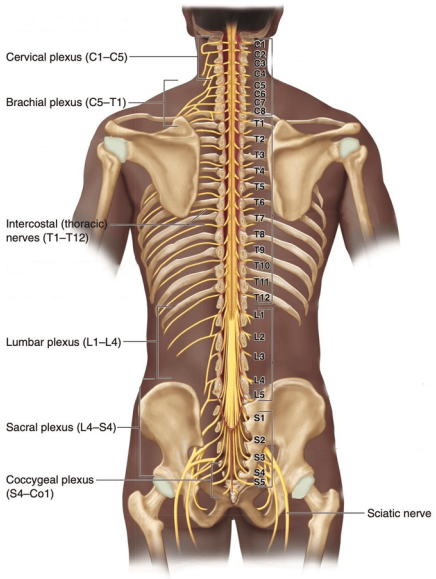

Figure 12.4.6: Nerve Plexuses of the Body. There are four main nerve plexuses in the human body. The cervical plexus supplies nerves to the posterior head and neck, as well as to the diaphragm. The brachial plexus supplies nerves to the arm. The lumbar plexus supplies nerves to the anterior leg. The sacral plexus supplies nerves to the posterior leg. *(Image credit: "Nerve Plexuses" by Gabrielle Spurlock is licensed under CC BY-NC-SA 4.0, based on original by "KnowledgeWorks - Drawing Spinal nerves and plexuses - English labels" by KnowledgeWorks Global Ltd.)*

The other plexus from the cervical level is the **brachial plexus** (Figure 12.4.7). Spinal nerves C_5 through T_1 reorganize through this plexus to give rise to the nerves of the upper limbs, as the name brachial suggests. The ventral rami of the brachial plexus rearrange to form the superior, middle and inferior **trunks**. At the clavicle, the trunks split into an **anterior division** and **posterior division**, which innervate the anterior and posterior parts of the upper limbs, respectively. At the axilla, the divisions converge to form the posterior, medial and lateral **cords**. Finally, the cords split into five **terminal branches**: the axillary, median, musculocutaneous, radial and ulnar nerves.

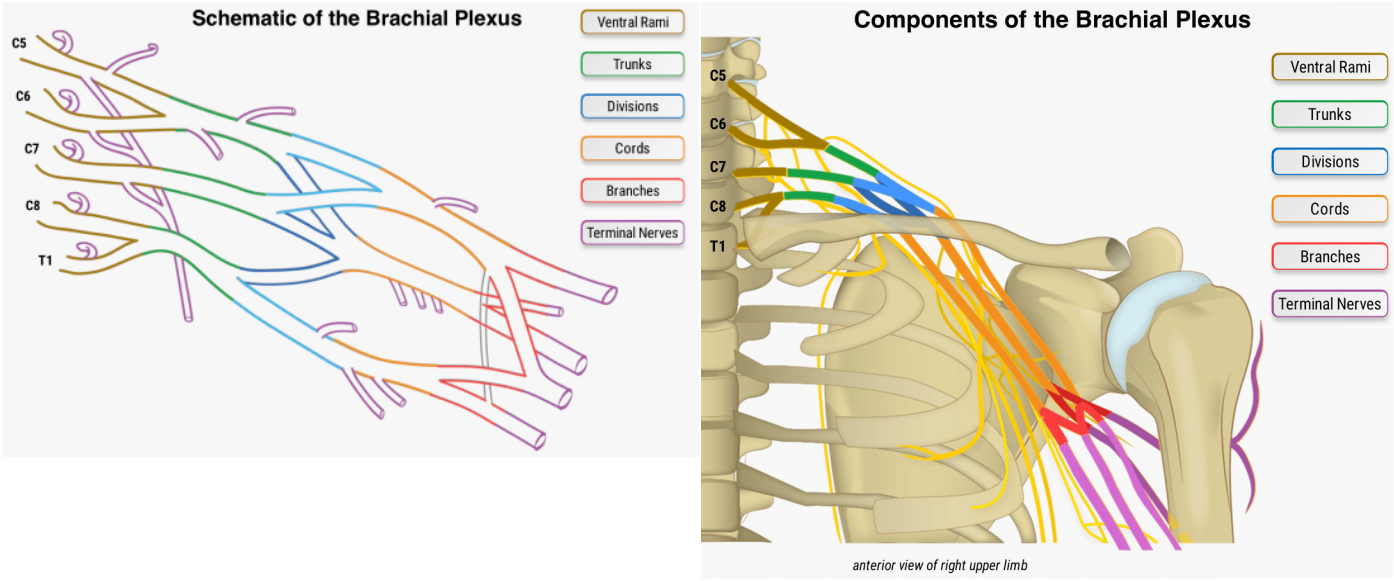

Figure 12.4.7: Brachial Plexus. Each brachial plexus is formed by axons from the C_5-T_1 anterior rami. The complex interweaving occurs as the nerve fibers extend laterally from the neck, pass posterior to the clavicle, and travel through the axilla. *(Image credits: "Brachial Plexus Components and Schematic" by University of British Columbia Clinical Anatomy are licensed under CC BY-NC-SA 4.0, slight modifications by Jennifer Lange.)*

The **lumbar plexus** is the network of nerves that arises the anterior rami of lumbar spinal nerves L1 to L4, with a small contribution from T12. The nerves arising from this group innervate the inferior abdominal wall, genitalia, and the anteromedial thigh and leg. The **sacral plexus** arises from the anterior rami of spinal nerves L4-S4. Nerves from the sacral plexus innervate the gluteal region, pelvis, perineum, posterior thigh and most of the leg and foot. The two plexuses are sometimes grouped together

into the lumbosacral plexus, since there is overlap at the L4 level (Figure 12.4.8).

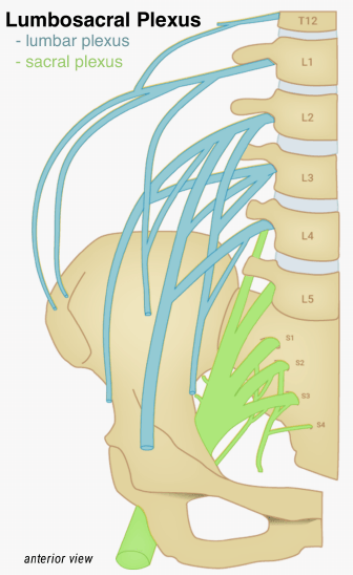

Figure 12.4.8: The Lumbosacral Plexus. The lumbar plexus gives rise to the major nerves that pass into the anterior thigh, while the sacral plexus gives rise to the major nerves that enter the thigh on the posterior side. *(Image credits: "Lumbosacral Plexus" by University of British Columbia Clinical Anatomy are licensed under CC BY-NC-SA 4.0, slight modifications by Jennifer Lange.)*

Named Nerves

Upper Limb - Branches from Brachial Plexus

The brachial plexus gives rise to five **terminal branches** that innervate the upper limb: the axillary, median, musculocutaneous, radial and ulnar nerves (Figure 12.4.9).

- **axillary nerve** innervates the deltoid and teres minor muscles, and receives sensation from the superolateral side of the arm
- **median nerve** innervates the most anterior forearm muscles as well as muscles that move the thumb. It receives sensation from the palmar region and dorsal tips of the lateral 3 and a half digits.
- **musculocutaneous nerve** innervate the anterior arm muscles and receives sensation from the lateral region of the forearm.
- **radial nerve** innervates muscles and receives sensation from the posterior arm and forearm, including the dorsal region of the lateral three digits (not including their tips).
- **ulnar nerve** innervates anterior forearm muscles as well as intrinsic hand muscles. It receives sensation from the dorsal and palmar regions of the medial one and a half digits.

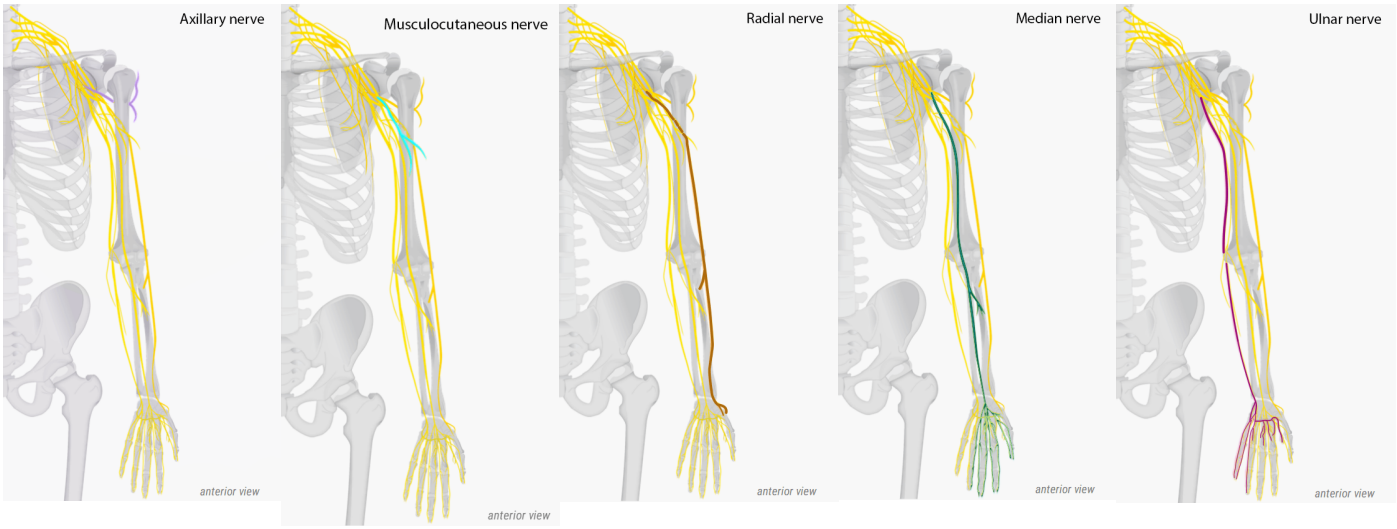

Figure 12.4.9: Branches of the Brachial Plexus. The five terminal branches of the brachial plexus are the axillary nerve, median nerve, musculocutaneous nerve, radial nerve, and ulnar nerve. *(Image credits: "Branches of the Brachial Plexus" by University of British Columbia Clinical Anatomy are licensed under CC BY-NC-SA 4.0, slight modifications by Jennifer Lange.)*

Open 3D Model

View the path of each nerve in this 3D interactive model (will open in a new window).

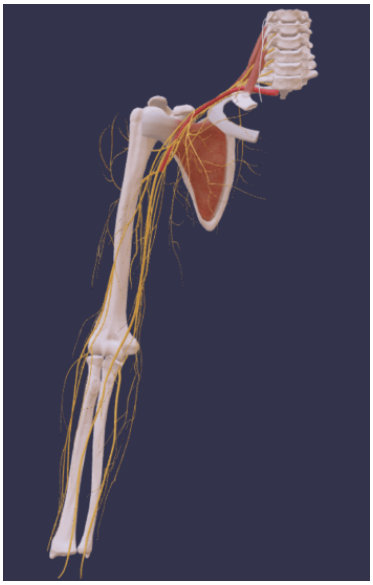

Open3D Model - brachial plexus and branches

Lower Limb - Branches from the Lumbar and Sacral Plexi

The lumbosacral plexus has two main branches that then give rise to other named nerves as well as several smaller branches. All innervate the lower limb and the pelvic region (Figure 12.4.10 and Figure 12.4.11).

- **femoral nerve:** the main branch from the lumbar plexus; its small branches innervate anterior thigh muscles and receives sensory information from the anterior and medial aspects of the thigh.
  - **saphenous nerve:** a large branch of the femoral nerve that provides sensation from the medial aspect of the lower leg and the foot. It is the longest nerve in the body.

- **sciatic nerve**: the main branch from the sacral plexus and the largest and longest nerve of the body. It extends posteriorly across the hip joint and motor and sensory fibers to the posterior thigh and lower leg. The sciatic nerve bundles together two other nerves:
  - **tibial nerve**: branch of the sciatic nerve that runs posteriorly along the midline of the lower limb and innervates the hamstrings, the posterior leg muscles, plantar foot muscles, and skin of the plantar foot.
  - **common fibular nerve**: branch of the sciatic nerve that wraps around the lateral knee and splits into two main branches:
    - **deep fibular nerve**: runs in the anterior compartment of the leg to innervate the muscles of that compartment and the skin between the first and second toes.
    - **superficial fibular nerve**: runs in the lateral compartment of the leg to innervate the muscles of that compartment as well as the muscles and skin on the superior surface of the foot.
      - **sural nerve**: arises in the midline sural (calf) region with fibers from both the common fibular and tibial nerves. It is a purely sensory nerve serving the posterior and lateral leg, ankle, and foot.
- **obturator nerve**: arises from the lumbar plexus and provides motor and sensory innervation to the medial thigh.

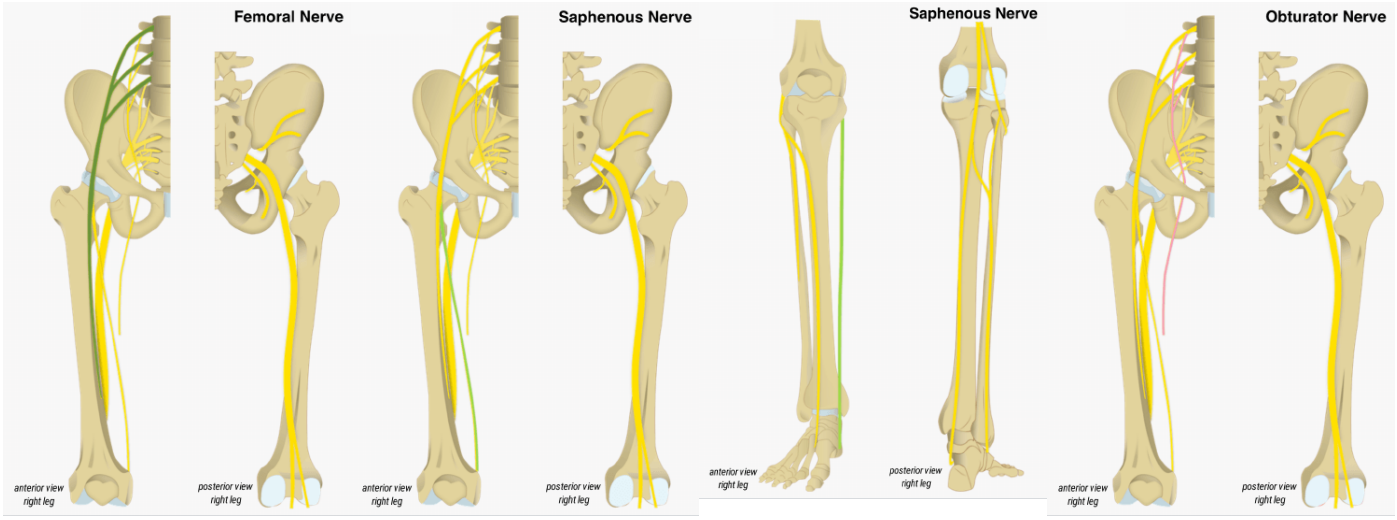

Figure 12.4.10: Major Nerves of the Lumbar Plexus. Major nerves arising from the lumbar plexus: femoral nerve, saphenous nerve, and obturator nerve. *(Image credits: "Major Nerves of the Lumbar Plexus" by University of British Columbia Clinical Anatomy are licensed under CC BY-NC-SA 4.0, slight modifications by Jennifer Lange.)*

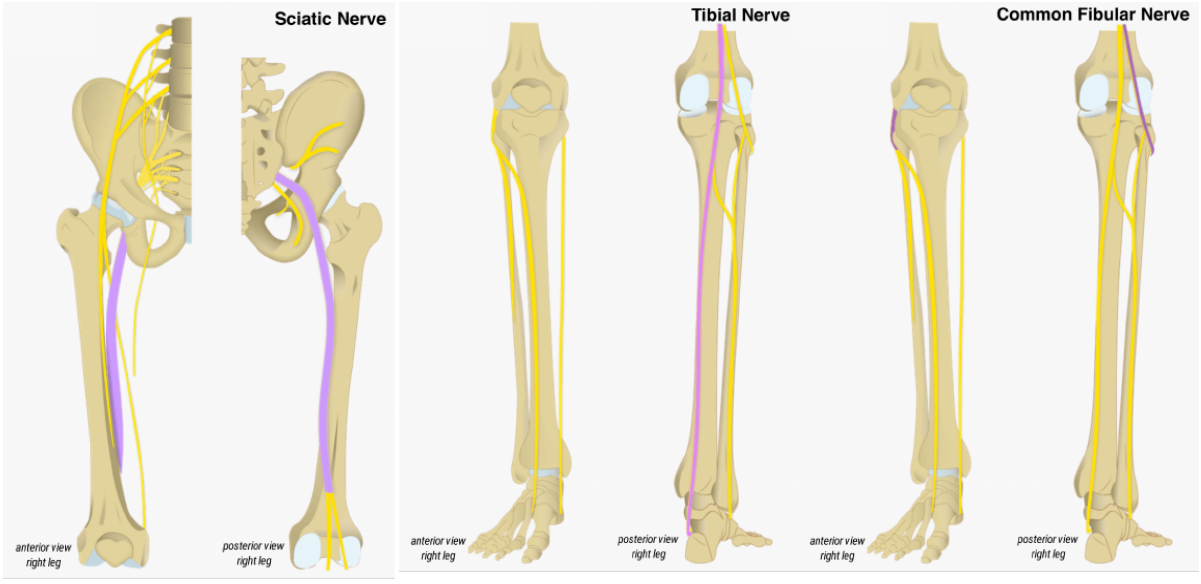

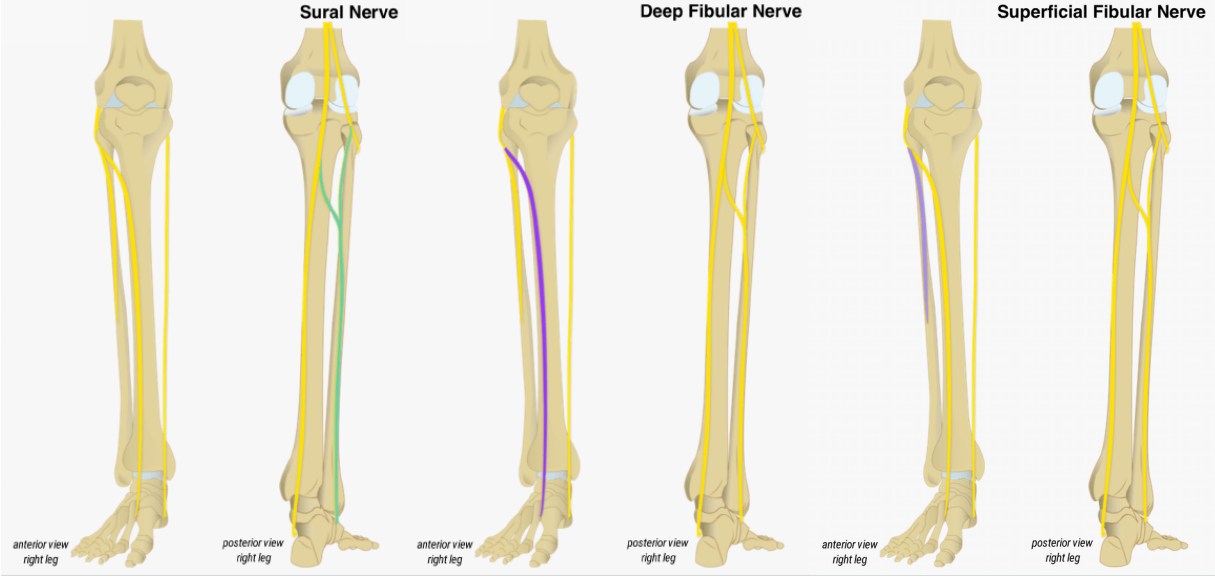

Figure 12.4.11: Major Nerves of the Sacral Plexus. The major nerve arising from the sacral plexus is the sciatic nerve, which splits into the tibial nerve and the common fibular nerve. In the leg, these branches have additional branches. *(Image credits: "Major Nerves of the Sacral Plexus" by University of British Columbia Clinical Anatomy are licensed under CC BY-NC-SA 4.0, slight modifications by Jennifer Lange.)*

DISORDERS OF THE...

Sciatic Nerve

The sciatic nerve is most commonly associated with the painful condition **sciatica**, which is the result of compression or irritation of the nerve itself or of any of the spinal nerves giving rise to it.

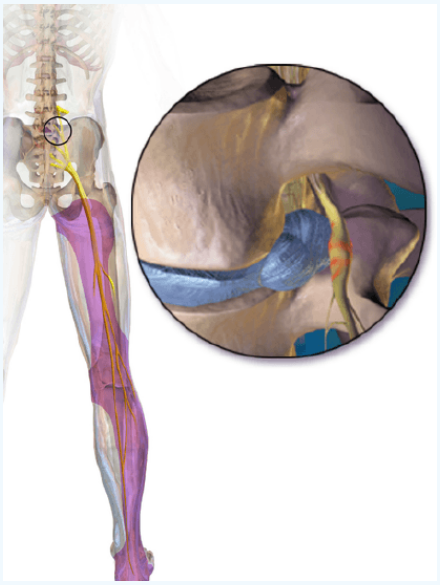

Figure 12.4.12: When an intervertebal disc herniates (bulges out) it will compress the associated spinal nerve, causing inflammation. Pain and numbness can result along the path of the sciatic nerve, with the exact location dependent upon which spinal nerve(s) is affected. *(Image credit: "Sciatica" by BruceBlaus, is licensed under CC BY-SA 4.0, via Wikimedia Commons.)*

Sciatica most often occurs when either a herniated disc or an overgrowth of bone puts pressure on part of the nerve (Figure 12.4.12) causing inflammation, pain, and, sometimes, numbness. Pain and numbness occur only on the affected side and most likely travel along the course of the nerve, from the gluteal region through the posterior thigh and into the posterolateral calf

and foot. Pain can range from a mild ache to a sharp burning pain or can feel like a bolt of electricity. Numbness can range from a mild tingling (similar to when your leg falls asleep) to a lack of sensation in the area. Severe sciatica can also result in muscle weakness in the leg or foot.

Sciatica can occur from a traumatic injury, but more likely it arises from chronic risk factors including: advanced age, obesity, prolonged sitting, diabetes, and excessive/improper movements (twisting, carrying heavy objects, lifting, etc.).

Dermatomes

The spinal nerves, which contain sensory fibers with endings in the skin, connect with the skin in a topographically organized manner, illustrated as **dermatomes** (Figure 12.4.13). For example, the fibers of eighth cervical nerve innervate the medial surface of the forearm and extend out to the fingers. All spinal nerves except C1 innervates a region on the skin. Dermatomes are important in a clinical setting as they can help identify potential damage to spinal nerves. In a sensory exam, the dermatome of a specific area is tested for sensation (for example the stroking of a cotton ball) to evaluate the functioning of the spinal nerve connected to that dermatome. Dermatomes are also associated with referred visceral pain, as the spinal nerves innervated the regions of the skin also innervate internal organs. Pain from the internal organ can then be mistakenly referred to a dermatome. For example, myocardial infarction is perceived as referred pain in the chest, left shoulder and left arm. This is because the sensory fibers that innervate the cardiac tissue travel through the T1-T4 spinal nerves, which also innervate the medial and anterior side of the body.

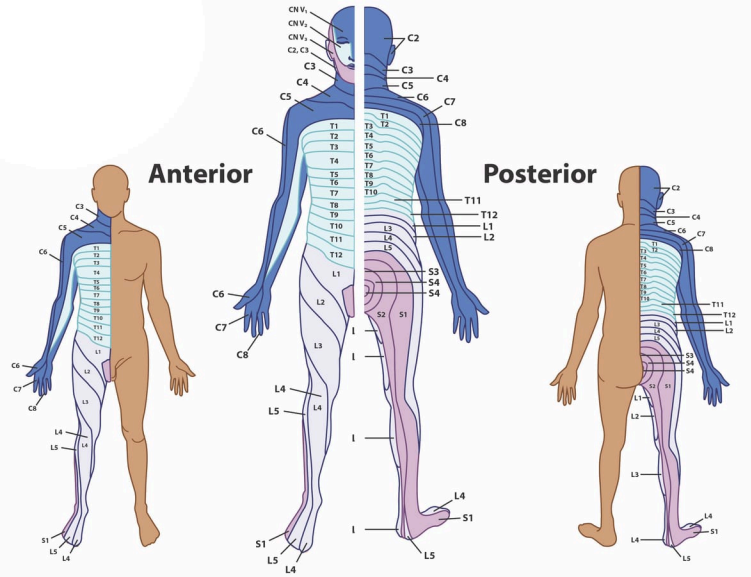

Figure 12.4.13: Dermatomes. The surface of the skin can be divided into topographic regions that relate to the location of sensory endings in the skin based on the spinal nerve that contains those fibers. *(Image credit: "Dermatomes" by BlueLink is licensed under CC BY-NC 4.0 with notification of the original authors.)*

Concept Review

The spinal cord is covered and protected by the spinal meninges, similar to the cranial ones. However, the spinal dura mater presents only one layer of tissue. Moreover, the epidural space is a real space that houses areolar and adipose connective tissues, and blood vessels.

The spinal cord is divided into segments that take the same name as the vertebral regions. However, the sacral spinal cord ends at the vertebral lumbar level (L1/L2) with the conus medullaris, while the spinal nerves continue exiting at their respective region of the vertebral column. Inferior to the conus medullaris, the spinal nerves form a bundle called the cauda equina. The spinal cord presents two enlargements at the cervical and lumbar level.

In cross section, the gray matter is deep within the spinal cord and is separated into horns. The sensory axons coming from the posterior root ganglia enter the spinal cord through the posterior nerve root and synapse in the posterior horn, where interneurons

are found. Autonomic motor neurons are found in the lateral horns, while somatic motor neurons are found in the anterior horns. Motor neurons send their axons out of the spinal cord through the anterior nerve root. The posterior and anterior root fuse to form the spinal nerve, which contains mixed sensory and motor information. The white matter is separated into columns which contain axons of sensory and motor neurons. The posterior columns contain ascending sensory tracts which are bundles of axons going towards the brain. The lateral and anterior column contain ascending sensory tracts as well as descending motor tracts, which carry the motor responses from the brain. Overall, the posterior regions of the spinal cord are responsible for ascending sensory information, while the anterior regions are responsible for descending motor information.

Spinal nerves are all mixed nerves with both sensory and motor fibers. Spinal nerves emerge from the spinal cord and reorganize through plexuses, which then give rise to systemic nerves. Thoracic spinal nerves are not part of any plexus, but give rise to the intercostal nerves directly.

Review Questions

Query 12.4.1

This interactive element is not available in this format. Visit the link or scan the QR code to access it online.

View this Interactive Content online

Glossary

Query 12.4.2

This interactive element is not available in this format. Visit the link or scan the QR code to access it online.

View this Interactive Content online

Contributors and Attributions

OpenStax Anatomy & Physiology (CC BY 4.0). Access for free at https://openstax.org/books/anatomy-and-physiology

This page titled 12.4: Spinal Nerves and Their Branches is shared under a CC BY-NC-SA 4.0 license and was authored, remixed, and/or curated by Jennifer Lange et al..

- 12.6: Spinal Cord and Spinal Nerves by Whitney Menefee, Julie Jenks, Chiara Mazzasette, and Kim-Leiloni Nguyen is licensed CC BY 4.0.

12.5: Anatomical Atlas - Peripheral Nervous System

A compendium of anatomical images: slides, models, and/or cadavers.

Image Credit

"Nervous System Flat Model - Lower Region" by Jennifer Lange is licensed under CC BY-NC-SA 4.0.

Answer Key (click to show/ hide answers)

purple - saphenous nerve

pink - sciatic nerve

dark green - common fibular nerve

light green - deep fibular nerve

orange - superficial fibular nerve

blue - tibial nerve

red - sural nerve

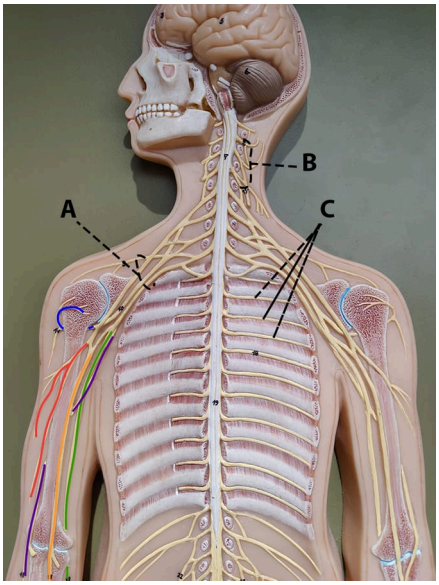

Image Credit

"Nervous System Flat Model - Upper" by Jennifer Lange is licensed under CC BY-NC-SA 4.0.

Answer Key (click to show/hide answers)

A - brachial plexus

B - cervical plexus

C - intercostal nerve

blue - axillary nerve

red - musculocutaneous nerve

green - ulnar nerve

orange - median nerve

purple - radial nerve

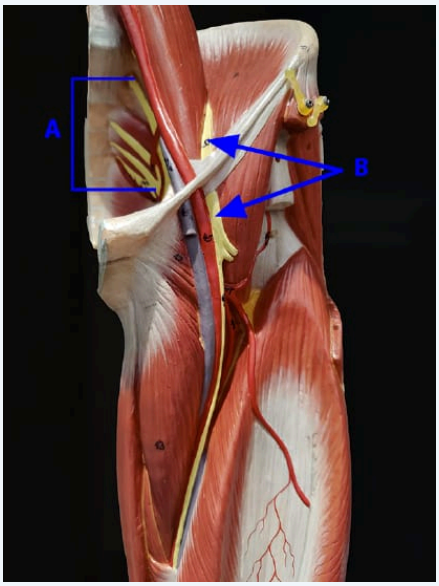

Image Credit

"Nerves - anterior thigh" by Jennifer Lange is licensed under CC BY-NC-SA 4.0.

Answer Key (click to show/hide answers)

A - sacral plexus

B - femoral nerve

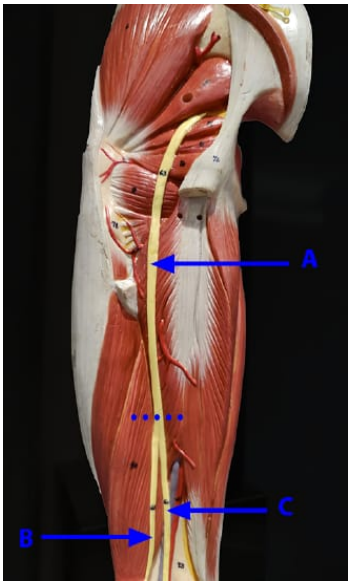

Image Credit

"Nerves - posterior thigh" by Jennifer Lange is licensed under CC BY-NC-SA 4.0.

Answer Key (click to show/hide answers)

A - sciatic nerve

B - common fibular nerve

C - tibial nerve

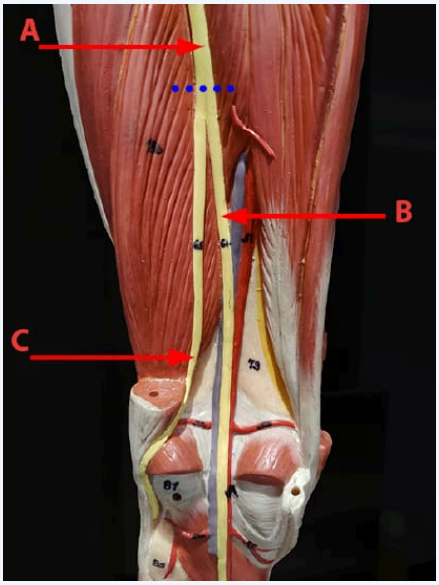

Image Credit

"Nerves - popliteal region" by Jennifer Lange is licensed under CC BY-NC-SA 4.0.

Answer Key (click to show/hide answers)

A - sciatic nerve

B - tibial nerve

C - common fibular nerve

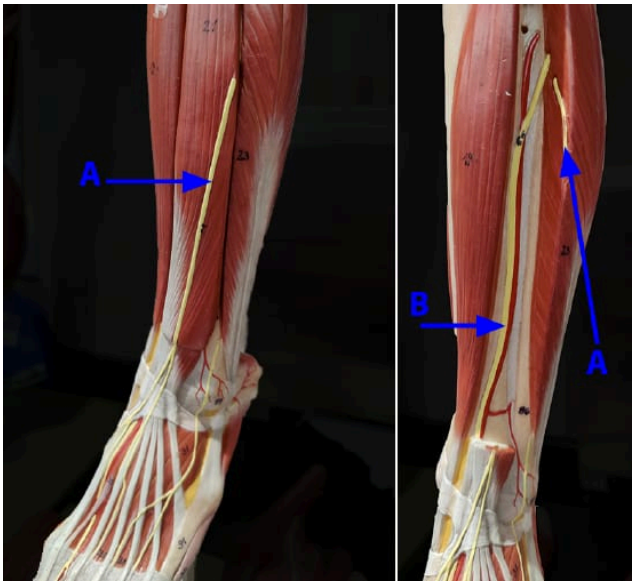

Image Credit

"Nerves - anterior leg" by Jennifer Lange is licensed under CC BY-NC-SA 4.0.

Answer Key (click to show/hide answers)

A - superficial fibular nerve

B - deep fibular nerve

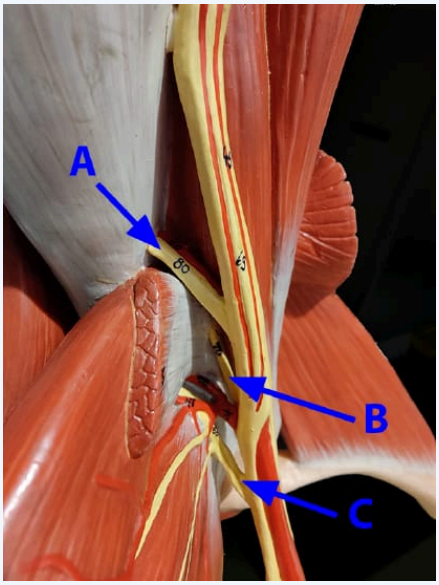

Image Credit

"Nerves - axillary" by Jennifer Lange is licensed under CC BY-NC-SA 4.0.

Answer Key (click to show/hide answers)

A - radial nerve

B - musculocutaneous nerve

C - axillary nerve

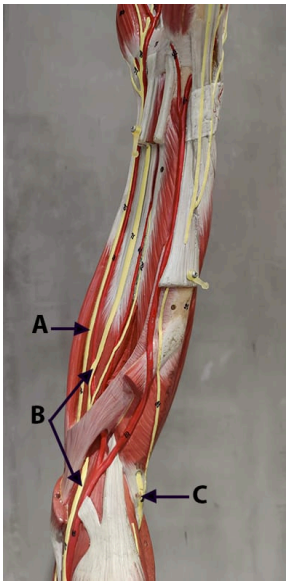

Image Credit

"Nerves - anterior forearm" by Jennifer Lange is licensed under CC BY-NC-SA 4.0.

Answer Key (click to show/hide answers)

A - ulnar nerve

B - median nerve

C - radial nerve

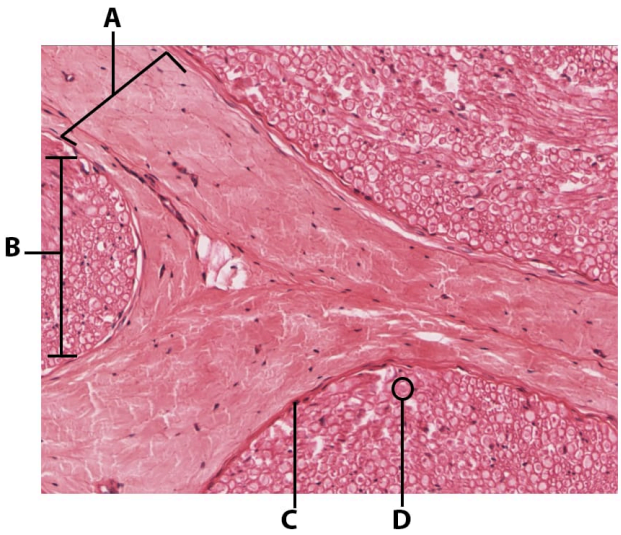

Image Credit

"Nerve histology cross section @ 100x" by Jennifer Lange is licensed under CC BY-NC-SA 4.0, slide provided by the Regents of the University of Michigan Medical School under CC BY-NC-SA 4.0 © 2022.

Answer Key (click to show/hide answers)

A - epineurium

B - nerve fascicle

C - perineurium

D - nerve fiber; myelinated axon

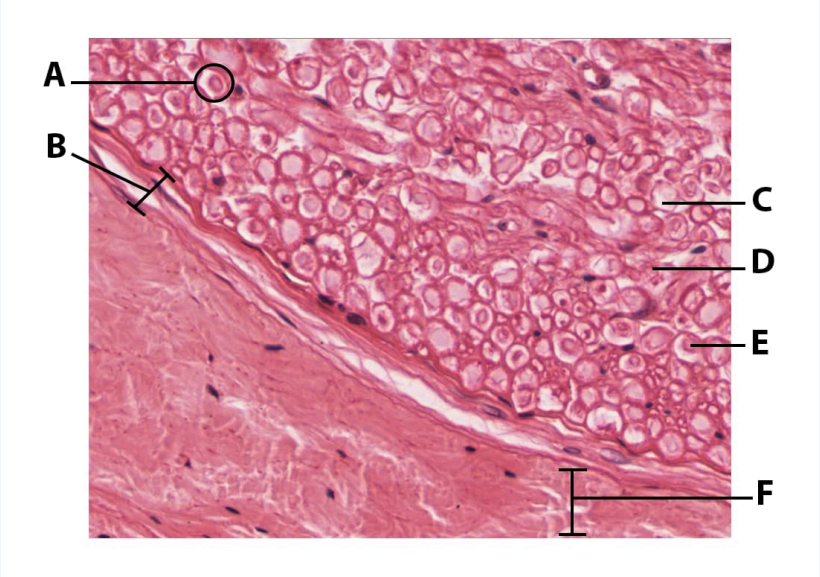

Image Credit

"Nerve histology cross section @ 400x" by Jennifer Lange is licensed under CC BY-NC-SA 4.0, slide provided by the Regents of the University of Michigan Medical School under CC BY-NC-SA 4.0 © 2022

Answer Key (click to show/hide answers)

A - nerve fiber; myelinated axon

B - perineurium

C - myelin; neurolemmocyte

D - endoneurium

E - axon

F - epineurium

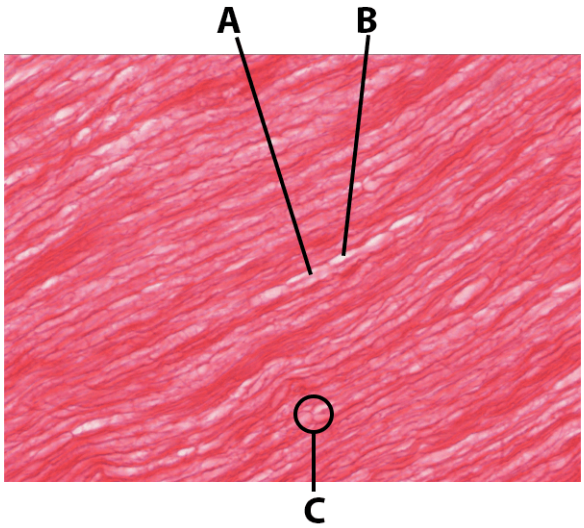

Image Credit

"Nerve histology longitudinal section @ 400x" by Jennifer Lange is licensed under CC BY-NC-SA 4.0, slide provided by the Regents of the University of Michigan Medical School under CC BY-NC-SA 4.0 © 2022

Answer Key (click to show/hide answers)

A - axon

B - myelin; neurolemmocyte

C - neurofibril node; node of Ranvier



Image Credit

"Spinal Nerve and Branches - Atlas" by Jennifer Lange is licensed under CC BY-NC-SA 4.0.

Answer Key (click to show/hide answers)

A - anterior ramus

B - posterior ramus

C - spinal nerve

D - posterior root ganglion

E - posterior root

F - anterior root

G - rami communicans (grey and white rami)

H - sympathetic chain ganglion

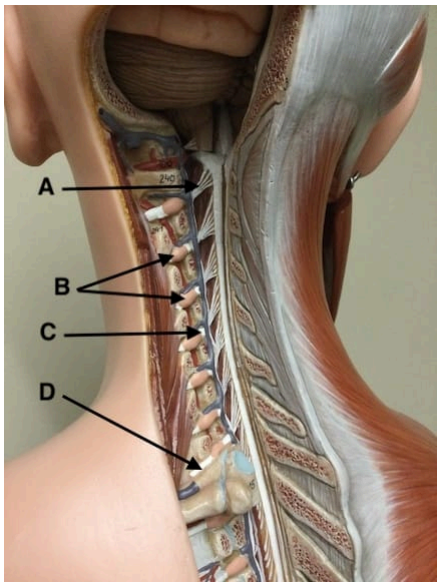

Image Credit

"Torso Model Cervical Spine - Atlas" by Jennifer Lange is licensed under CC BY-NC-SA 4.0.

Answer Key (click to show/hide answers)

A - posterior rootlets

B - posterior root ganglia

C - posterior root

D - spinal nerve

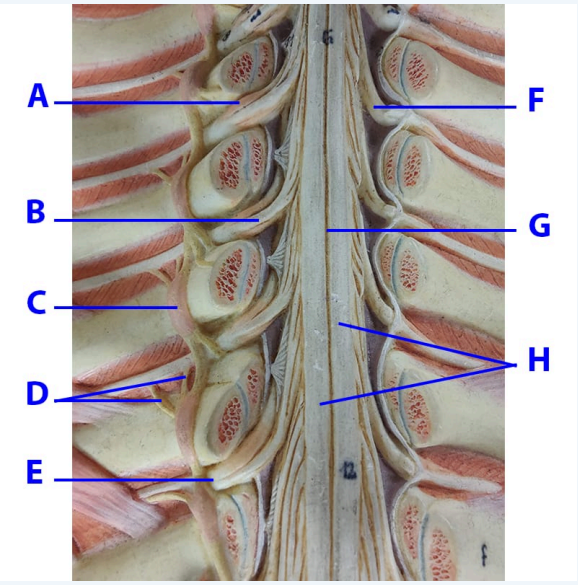

Image Credit

"Spinal Cord in Canal Model - Thoracic Close-up" by Jennifer Lange is licensed under CC BY-NC-SA 4.0.

Answer Key (click to show/hide answers)

A - posterior root ganglion

B - anterior root

C - sympathetic chain ganglion

D - rami communicans

E - spinal nerve

F - posterior root

G - anterior median fissure

H - anterior funiculi

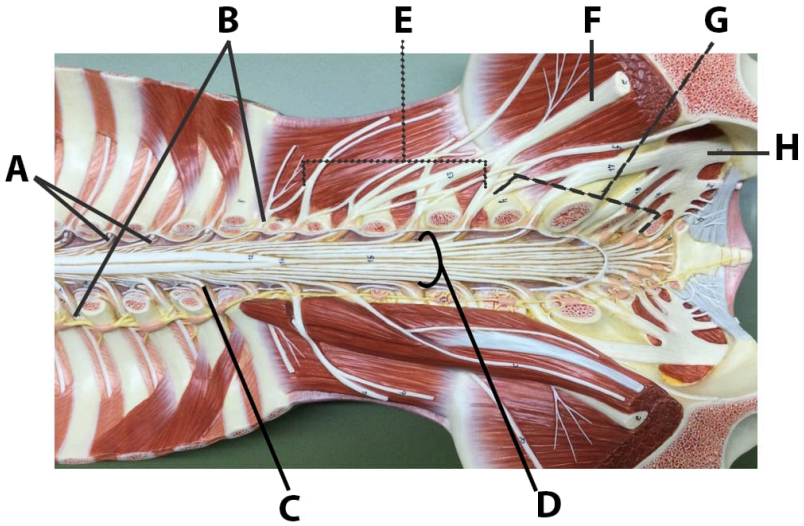

Image Credit

"Spinal Cord in Canal Model - PNS Structures" by Jennifer Lange is licensed under CC BY-NC-SA 4.0.

Answer Key (click to show/hide answers)

A - posterior root

B - spinal nerve

C - anterior root

D - cauda equina

E - lumbar plexus

F - sacral plexus

G - femoral nerve

H - sciatic nerve

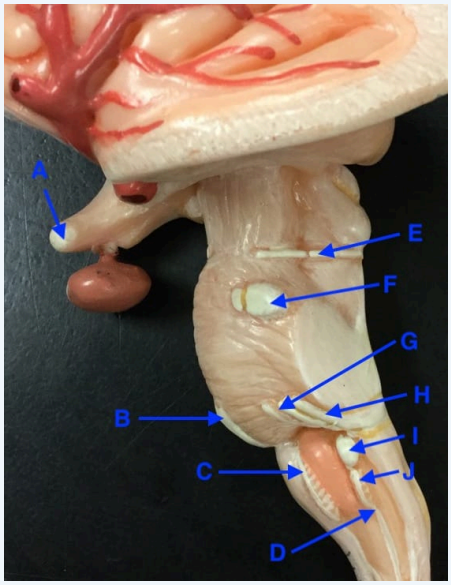

Image Credit

"Cranial Nerves on Brainstem Model Lateral - Atlas" by Jennifer Lange is licensed under CC BY-NC-SA 4.0.

Answer Key (click to show/hide answers)

A - CN II, optic nerve

B - CN VI, abducens nerve

C - CN XII, hypoglossal nerve

D - CN XI, (spinal) accessory nerve

E - CN IV, trochlear nerve

F - CN V, trigeminal nerve

G - CN VII, facial nerve

H - CN VIII, vestibulocochlear nerve

I - CN IX, glossopharyngeal nerve

J - CN X, vagus nerve

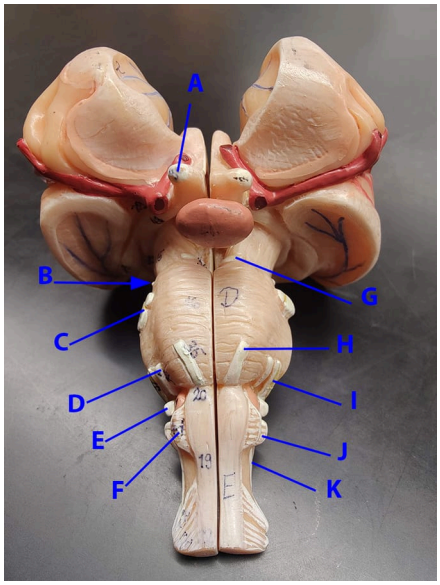

Image Credit

"Cranial Nerves on Brainstem Model Anterior - Atlas" by Jennifer Lange is licensed under CC BY-NC-SA 4.0.

Answer Key (click to show/hide answers)

A - CN II, optic nerve

B - CN IV, trochlear

C - CN V, trigeminal nerve

D - CN VII, facial nerve

E - CN IX, glossopharyngeal nerve

F - CN XII, hypoglossal nerve

G - CN III, oculomotor nerve

H - CN VI, abducens nerve

I - CN VIII, vestibulocochlear nerve

J - CN X, vagus nerve

K - CN XI, (spinal) accessory nerve

This page titled 12.5: Anatomical Atlas - Peripheral Nervous System is shared under a CC BY-NC-SA 4.0 license and was authored, remixed, and/or curated by Jennifer Lange et al..

12.6: Practice Practical

Please answer each of the following questions by typing your answer into the box(es).

Query 12.6.1

This interactive element is not available in this format. Visit the link or scan the QR code to access it online.

View this Interactive Content online

Query 12.6.1

This interactive element is not available in this format. Visit the link or scan the QR code to access it online.

View this Interactive Content online

Query 12.6.1

This interactive element is not available in this format. Visit the link or scan the QR code to access it online.

View this Interactive Content online

Query 12.6.1

This interactive element is not available in this format. Visit the link or scan the QR code to access it online.

View this Interactive Content online

Query 12.6.1

This interactive element is not available in this format. Visit the link or scan the QR code to access it online.

View this Interactive Content online

Query 12.6.1

This interactive element is not available in this format. Visit the link or scan the QR code to access it online.

View this Interactive Content online

Query 12.6.1

This interactive element is not available in this format. Visit the link or scan the QR code to access it online.

View this Interactive Content online

Query 12.6.1

This interactive element is not available in this format. Visit the link or scan the QR code to access it online.

View this Interactive Content online

Query 12.6.1

This interactive element is not available in this format. Visit the link or scan the QR code to access it online.

View this Interactive Content online

This page titled 12.6: Practice Practical is shared under a CC BY-NC-SA 4.0 license and was authored, remixed, and/or curated by Jennifer Lange et al..

13: SOMATIC SENSES

The somatic nervous system (SNS) is the part of the peripheral nervous system responsible for our conscious perception of the environment through general and special senses as well as for our voluntary motor responses to that perception by means of skeletal muscles. In this chapter, you will look at the peripheral sensory structures that receive input from environmental stimuli and trace their afferent pathways into the CNS.

13.1: Introduction to the Somatic Senses

13.2: Sensory Modalities and General Senses

13.3: Hearing and Balance

13.4: Vision

13.5: Taste and Smell

13.6: Anatomical Atlas - Somatic Senses

13.7: Practice Practical - Somatic Senses

This page titled 13: Somatic Senses is shared under a CC BY-NC-SA 4.0 license and was authored, remixed, and/or curated by Jennifer Lange et al..

- 13: Somatic Senses, Integration and Motor Responses by Whitney Menefee, Julie Jenks, Chiara Mazzasette, and Kim-Leiloni Nguyen is licensed CC BY 4.0.

13.1: Introduction to the Somatic Senses

Chapter Learning Objectives

After studying this chapter, you will be able to:

- Define general somatic sensation and special somatic sensation
- Describe the structures and functions of general somatic senses
- Explain how the structures of the eye modulate and assist with the detection of light by photoreceptors.
- Explain how the structures of the ear modulate and assist with the detection of sound by hair cells.
- Describe the structures of the vestibular apparatus and their role in equilibrium and balance.
- Describe the receptors and supporting cells responsible for chemoreception in taste and in smell.
- Trace the pathways from sensory receptors to their cerebral processing regions.

The somatic sensory system includes all the afferent, sensory receptors from the skin, skeletal muscles, joints and special senses which are responsible for our conscious perception of the environment.

Our somatic senses make us aware of our surroundings or state of our body through peripheral sensory receptors. These receptors send sensory information through cranial and spinal nerves to the central nervous system. The neurons of the central nervous system need to process the information, a step called integration. Once processed, if a motor response is required, the neurons of the central nervous system will send a signal to skeletal muscles to move.

In this chapter, we will examine the sensory components of the somatic nervous system. For the sensory input, we will look at sensory receptors of general and special senses and how the sensory information is sent to the CNS.

Figure 13.1.1: Back pain. Pain is detected by the class of receptors called nociceptors that detect potentially damaging stimuli that might cause us harm. Pain in muscles and joints is stimulated by thermal, mechanical, or chemical stimuli, which often results in poor localization and dull pain sensation. *(Image credit: "laminectomy in Iran2" by Ermateb is licensed under CC BY-NC 4.0.)*

In the United States the incidence of back pain differs by demographic characteristics (CDC, 2021):

- The percentage of adults with back pain increased with age, from 28.4% for those aged 18–29 and 35.2% for those aged 30–44 to 44.3% for those aged 45–64 and 45.6% for those aged 65 and over.
- Women (40.6%) were more likely to experience back pain than men (37.2%).
- Estimates of back pain differed among non-Hispanic white (42.7%), non-Hispanic black (35.8%), Hispanic (31.2%), and non-Hispanic Asian (24.5%) adults.
- The percentage of adults with back pain decreased as family income increased, from 44.8% in adults with income less than 100% of the federal poverty level (FPL) to 37.6% in adults with income 200% or more of FPL.

Contributors and Attributions

OpenStax Anatomy & Physiology (CC BY 4.0). Access for free at https://openstax.org/books/anatomy-and-physiology

This page titled 13.1: Introduction to the Somatic Senses is shared under a CC BY-NC-SA 4.0 license and was authored, remixed, and/or curated by Jennifer Lange et al..

- 13.1: Introduction to the Somatic Nervous System by Whitney Menefee, Julie Jenks, Chiara Mazzasette, and Kim-Leiloni Nguyen is licensed CC BY 4.0.

13.2: Sensory Modalities and General Senses

By the end of this section, you will be able to:

- Describe the different types of sensory receptors and modalities
- Describe the general somatosensory receptors

A major role of sensory receptors is to help us learn about the environment around us, or about the state of our internal environment. Stimuli from varying sources, and of different types, are received and changed into the electrochemical signals of the nervous system. This occurs when a stimulus changes the cell membrane of a sensory neuron. The stimulus causes the sensory cell to produce an action potential that is relayed into the central nervous system (CNS), where it is integrated with other sensory information—or sometimes higher cognitive functions—to become a conscious perception of that stimulus. The central integration may then lead to a motor response.

Describing sensory function with the term sensation or perception is a deliberate distinction. Sensation is the activation of sensory receptor cells at the level of the stimulus. Perception is the central processing of sensory stimuli into a meaningful pattern. Perception is dependent on sensation, but not all sensations are perceived. Receptors are the cells or structures that detect sensations. A receptor cell is changed directly by a stimulus, such as opening of ion channels in the plasma membrane.

Sensory Receptors

Stimuli in the environment activate specialized receptor cells in the peripheral nervous system. Different types of stimuli are sensed by different types of receptor cells. Receptor cells can be classified into types on the basis of three different criteria: cell type, position, and function. Receptors can be classified structurally on the basis of cell type and their position in relation to stimuli they sense. They can also be classified functionally on the basis of the **transduction** of stimuli, or how the mechanical stimulus, light, or chemical changed the cell membrane electrical properties.

Structural Receptor Types

The first structural classification of sensory receptors is based on the cell type. The cells that interpret information about the environment can be either (1) a neuron that has a **free nerve ending**, with dendrites embedded in tissue that would receive a sensation; (2) a neuron that has an **encapsulated ending** in which the sensory nerve endings are covered in connective tissue that enhances their sensitivity; or (3) a specialized **receptor cell**, which has distinct structural components that interpret a specific type of stimulus (Figure 13.2.1). The pain and temperature receptors in the dermis of the skin are examples of neurons that have free nerve endings. Also located in the dermis of the skin are lamellated corpuscles, neurons with encapsulated nerve endings that respond to pressure and touch. The cells in the retina that respond to light stimuli are an example of a specialized receptor, a **photoreceptor**.

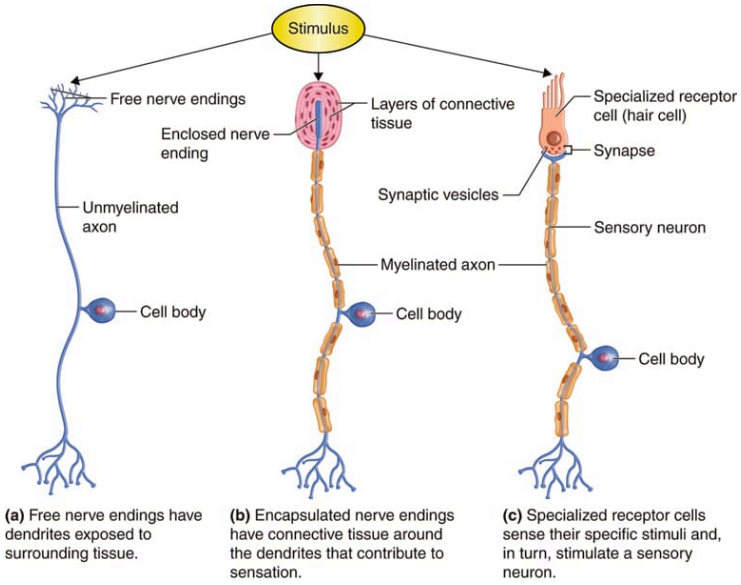

Figure 13.2.1: Receptor Classification by Cell Type. Sensory receptors can be classified on the basis of their structure. Sensory neurons can have either free nerve endings on their dendritic side such as in a or encapsulated endings where dendrites are covered by connective tissue such as in b. In c, hair cells in the inner ear are examples of specialized receptor cells. *(Image Credit: "Structural Receptor Classification" by Cenveo is licensed under CC BY 3.0).*

Another way that receptors can be classified is based on their location relative to the stimuli. An **exteroceptor** is a receptor that is located near a stimulus in the external environment, such as the somatosensory receptors that are located in the skin. An **interoceptor** is one that interprets stimuli from internal organs and tissues, such as the receptors that sense the increase in blood pressure in the aorta or carotid sinus. Finally, a **proprioceptor** is a receptor located near a moving part of the body, such as a muscle, that interprets the positions of the tissues as they move.

Functional Receptor Types

A third classification of receptors is by how the receptor transduces stimuli into electrical changes. Stimuli are of three general types. Some stimuli are ions and macromolecules that affect transmembrane receptor proteins when these chemicals diffuse across the cell membrane, for example the ones found in food. Some stimuli are physical variations in the environment that affect the electrical properties of the receptor cell membrane, for example touch. Other stimuli include the electromagnetic radiation from visible light. For humans, the only electromagnetic energy that is perceived by our eyes is visible light. Some other organisms have receptors that humans lack, such as the heat sensors of snakes, the ultraviolet light sensors of bees, or magnetic receptors in migratory birds.

Receptor cells can be further categorized on the basis of the type of stimuli they transduce. Chemical stimuli can be interpreted by a **chemoreceptor** that interprets chemical stimuli, such as an object's taste or smell. **Osmoreceptors** respond to solute concentrations of body fluids. Additionally, pain is primarily a chemical sense that interprets the presence of chemicals from tissue damage, or similar intense stimuli, through a **nociceptor**. Physical stimuli, such as pressure and vibration, as well as the sensation of sound and body position (balance), are interpreted through a **mechanoreceptor**. Another physical stimulus that has its own type of receptor is temperature, which is sensed through a **thermoreceptor** that is either sensitive to temperatures above (heat) or below (cold) normal body temperature.

Sensory Modalities

Ask anyone what the senses are, and they are likely to list the five major senses—taste, smell, touch, hearing, and sight. However, these are not all of the senses. The most obvious omission from this list is balance. Also, what is referred to simply as touch can be further subdivided into pressure, vibration, stretch, and hair-follicle position, on the basis of the type of mechanoreceptors that perceive these touch sensations. Other overlooked senses include temperature perception by thermoreceptors and pain perception by nociceptors.

Senses can be classified as either general or special. A **general sense** is one that is distributed throughout the body and

has receptor cells within the structures of other organs. Mechanoreceptors in the skin, muscles, or the walls of blood vessels are examples of this type. General senses often contribute to the sense of touch, as described above, or to **proprioception** (awareness of body position) and **kinesthesia** (awareness of body movement), or to a **visceral sense**, which is most important to autonomic functions. A **special sense** is one that has a specific organ devoted to it, namely the eye, inner ear, tongue, or nose.

Each of the senses is referred to as a **sensory modality**. Modality refers to the way that information is encoded, which is similar to the idea of transduction. The main sensory modalities can be described on the basis of how each is transduced. The chemical senses are taste and smell. The general sense that is usually referred to as touch includes chemical sensation in the form of nociception, or pain. Pressure, vibration, muscle stretch, and the movement of hair by an external stimulus, are all sensed by mechanoreceptors. Hearing and balance are also sensed by mechanoreceptors. Finally, vision involves the activation of photoreceptors.

Listing all the different sensory modalities, which can number as many as 17, involves separating the five major senses into more specific categories, or **submodalities**, of the larger sense. An individual sensory modality represents the sensation of a specific type of stimulus. For example, the general sense of touch, which is known as **somatosensation**, can be separated into light pressure, deep pressure, vibration, itch, pain, temperature, or hair movement.

Somatosensation (Touch)

Somatosensation is considered a general sense, as opposed to the special senses discussed in this section. Somatosensation is the group of sensory modalities that are associated with touch, proprioception, and interoception. These modalities include pressure, vibration, light touch, tickle, itch, temperature, pain, proprioception, and kinesthesia. This means that its receptors are not associated with a specialized organ, but are instead spread throughout the body in a variety of organs. Many of the somatosensory receptors are located in the skin (Figure 13.2.2), but receptors are also found in muscles, tendons, joint capsules, ligaments, and in the walls of visceral organs.

Two types of somatosensory signals that are transduced by **free nerve endings** are pain and temperature. These two modalities use thermoreceptors and nociceptors to transduce temperature and pain stimuli, respectively. Temperature receptors are stimulated when local temperatures differ from body temperature. Some thermoreceptors are sensitive to just cold and others to just heat. Nociception is the sensation of potentially damaging stimuli. Mechanical, chemical, or thermal stimuli beyond a set threshold will elicit painful sensations. Stressed or damaged tissues release chemicals that activate receptor proteins in the nociceptors.

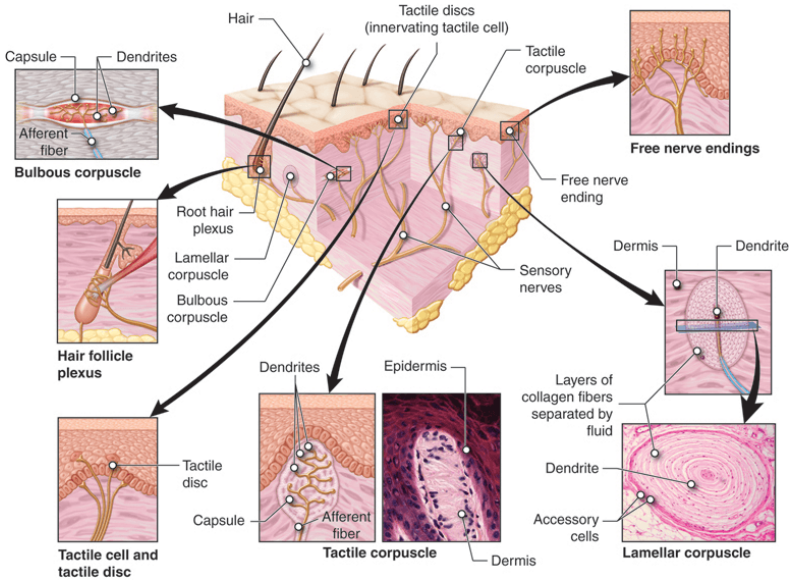

Figure 13.2.2: Sensory receptors in the skin vary in distribution and in anatomical types. *(Image credit: "Skin Sensory Receptors" by Cenveo is licensed under CC BY 3.0, recoloring by Jennifer Lange.)*

If you drag your finger across a textured surface, the skin of your finger will vibrate. Such low frequency vibrations are sensed by mechanoreceptors called Merkel cells, also known as **tactile cells and discs**, located in the stratum basale of the epidermis. Deep pressure and vibration is transduced by **lamellated (Pacinian) corpuscles**, which are receptors with encapsulated endings

found deep in the dermis, or subcutaneous tissue. Light touch is transduced by the encapsulated endings known as **tactile (Meissner) corpuscles.** Follicles are also wrapped in a plexus of nerve endings known as the **hair follicle plexus**. These nerve endings detect the movement of hair at the surface of the skin, such as when an insect may be walking along the skin. Stretching of the skin is transduced by stretch receptors known as **bulbous corpuscles**. Bulbous corpuscles are also known as Ruffini corpuscles.

Other somatosensory receptors are found in the joints and muscles. Stretch receptors monitor the stretching of tendons, muscles, and the components of joints. For example, have you ever stretched your muscles before or after exercise and noticed that you can only stretch so far before your muscles spasm back to a less stretched state? This spasm is a reflex that is initiated by stretch receptors to avoid muscle tearing. Such stretch receptors can also prevent over-contraction of a muscle. In skeletal muscle tissue, these stretch receptors are called muscle spindles. Golgi tendon organs similarly transduce the stretch levels of tendons. Bulbous corpuscles are also present in joint capsules, where they measure stretch in the components of the skeletal system within the joint. The types of nerve endings, their locations, and the stimuli they transduce are presented in Table 13.2.1.

Table** 13.2.1**: Mechanoreceptors of Somatosensation

Name	Location(s)	Stimuli
Free nerve endings	Dermis, cornea, tongue, joint capsules, visceral organs	Pain, temperature, mechanical deformation
Mechanoreceptors or Merkel's discs	Epidermal–dermal junction, mucosal membranes	Low frequency vibration (5–15 Hz)
Bulbous (or Ruffini's) corpuscle	Dermis, joint capsules	Stretch
Tactile (or Meissner's) corpuscle	Papillary dermis, especially in the fingertips and lips	Light touch, vibrations below 50 Hz
Lamellated (or Pacinian) corpuscle	Deep dermis, subcutaneous tissue	Deep pressure, high-frequency vibration (around 250 Hz)
Hair follicle plexus	Wrapped around hair follicles in the dermis	Movement of hair
Muscle spindle	In line with skeletal muscle fibers	Muscle contraction and stretch
Tendon stretch (or Golgi tendon) organ	In line with tendons	Stretch of tendon

Concept Review

The cells that transduce sensory stimuli into the electrochemical signals of the nervous system are classified on the basis of structural or functional aspects of the cells. The structural classifications are either based on the anatomy of the cell that is interacting with the stimulus (free nerve endings, encapsulated endings, or specialized receptor cell), or where the cell is located relative to the stimulus (interoceptor, exteroceptor, proprioceptor). Thirdly, the functional classification is based on how the cell transduces the stimulus into a neural signal. Chemoreceptors respond to chemical stimuli and are the basis for olfaction and gustation. Related to chemoreceptors are osmoreceptors and nociceptors for fluid balance and pain reception, respectively. Mechanoreceptors respond to mechanical stimuli and are the basis for most aspects of somatosensation, as well as being the basis of audition and equilibrium in the inner ear. Thermoreceptors are sensitive to temperature changes, and photoreceptors are sensitive to light energy.

The senses are somatosensation (sensations associated with the skin and body), gustation (taste), olfaction (smell), audition (hearing), equilibrium (balance), and vision. With the exception of somatosensation, this list represents the special senses, or those systems of the body that are associated with specific organs such as the tongue or eye. The general senses can be divided into somatosensation, which is commonly considered touch, but includes tactile, pressure, vibration, temperature, and pain perception. The general senses also include the visceral senses, which are separate from the somatic nervous system function in that they do not normally rise to the level of conscious perception. The special senses are all primarily part of the somatic nervous system in that they are consciously perceived through cerebral processes, though some special senses contribute to autonomic function.

Review Questions

Query 13.2.1

This interactive element is not available in this format. Visit the link or scan the QR code to access it online.

View this Interactive Content online

Critical Thinking Questions

Query 13.2.2

This interactive element is not available in this format. Visit the link or scan the QR code to access it online.

View this Interactive Content online

Query 13.2.3

This interactive element is not available in this format. Visit the link or scan the QR code to access it online.

View this Interactive Content online

Glossary

Query 13.2.4

This interactive element is not available in this format. Visit the link or scan the QR code to access it online.

View this Interactive Content online

Contributors and Attributions

OpenStax Anatomy & Physiology (CC BY 4.0). Access for free at https://openstax.org/books/anatomy-and-physiology

This page titled 13.2: Sensory Modalities and General Senses is shared under a CC BY-NC-SA 4.0 license and was authored, remixed, and/or curated by Jennifer Lange et al..

- 13.2: Touch, Taste and Smell by Whitney Menefee, Julie Jenks, Chiara Mazzasette, and Kim-Leiloni Nguyen is licensed CC BY 4.0.

13.3: Hearing and Balance

By the end of this section, you will be able to:

- Describe the gross and microscopic structures responsible for the special senses of hearing and balance
- Trace the pathway of auditory and equilibrium information from the inner ear to the brain

Audition (Hearing)

Hearing, or **audition**, is the transduction of sound waves into a neural signal that is made possible by the structures of the ear (Figure 13.3.1).

External Ear

The large, fleshy structure on the lateral aspect of the head is known as the **auricle**. Some sources will also refer to this structure as the pinna, though that term is more appropriate for a structure that can be moved, such as the external ear of a cat. The C-shaped curves of the auricle direct sound waves toward the **auditory canal**. The canal enters the skull through the external auditory meatus of the temporal bone. At the end of the auditory canal is the **tympanic membrane**, or ear drum, which vibrates after it is struck by sound waves. The auricle, ear canal, and tympanic membrane are often referred to as the **external ear**.

Middle Ear

The **middle ear** consists of a space, the **tympanic cavity**, spanned by three small bones called the **ossicles**. The three ossicles are the **malleus**, **incus**, and **stapes**, which are Latin names that roughly translate to hammer, anvil, and stirrup. The malleus is attached to the tympanic membrane and articulates with the incus. The incus, in turn, articulates with the stapes. The stapes is then attached to the oval window, which is the entrance to the **inner ear**, where the sound waves will be transduced into a neural signal. The tympanic cavity is connected to the pharynx through the **auditory (or Eustachian) tube**, which helps equilibrate air pressure across the tympanic membrane by providing and entrance/exit point for air. The tube is normally closed but will pop open when the muscles of the pharynx contract during swallowing or yawning. This helps to equalize the pressure on both sides of the ear drum with change in altitude, such as driving up the mountain or in a plane.

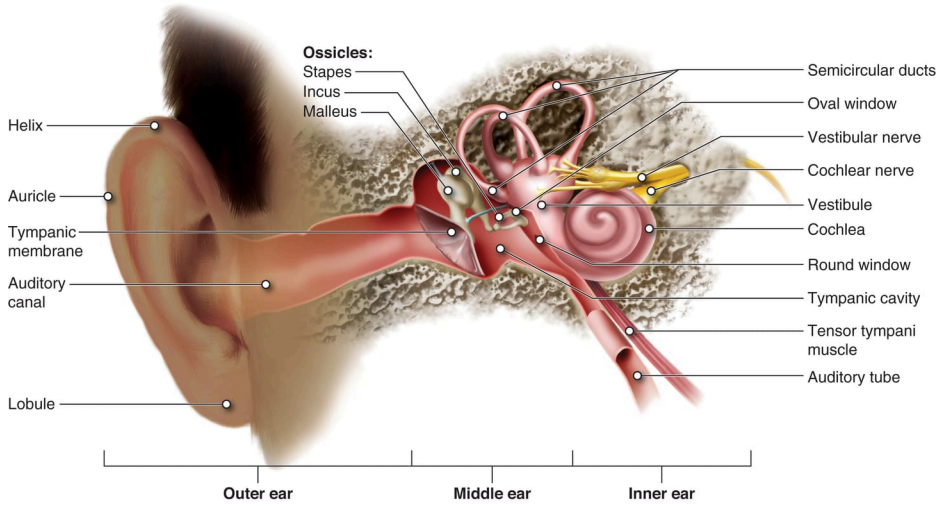

Figure 13.3.1: Structures of the Ear. The external ear contains the auricle, ear canal, and tympanic membrane. The middle ear contains the ossicles and is connected to the pharynx by the auditory tube. The inner ear contains the cochlea and vestibule, which are responsible for audition and equilibrium, respectively. *(Image credit: "External, Middle and Inner Ear" by Cenveo is licensed under CC BY 3.0.)*

Inner Ear

The inner ear is often described as a **bony labyrinth**, as it is composed of a series of canals embedded within the temporal bone (Figure 13.3.2). Within the bony labyrinth are membranes that separate tubes and spaces filled with liquid. This is called the **membranous labyrinth**. The inner ear has three separate regions, the **cochlea,** the **vestibule**, and the **semicircular canals**. The cochlea is responsible for hearing while the vestibule and semicircular canals are important for balance. The neural signals from these regions are relayed to the brainstem through separate fiber bundles called the **cochlear nerve** and the **vestibular nerve**. However, these two distinct bundles travel together from the inner ear to the brainstem as the **vestibulocochlear nerve (CN VIII)**.

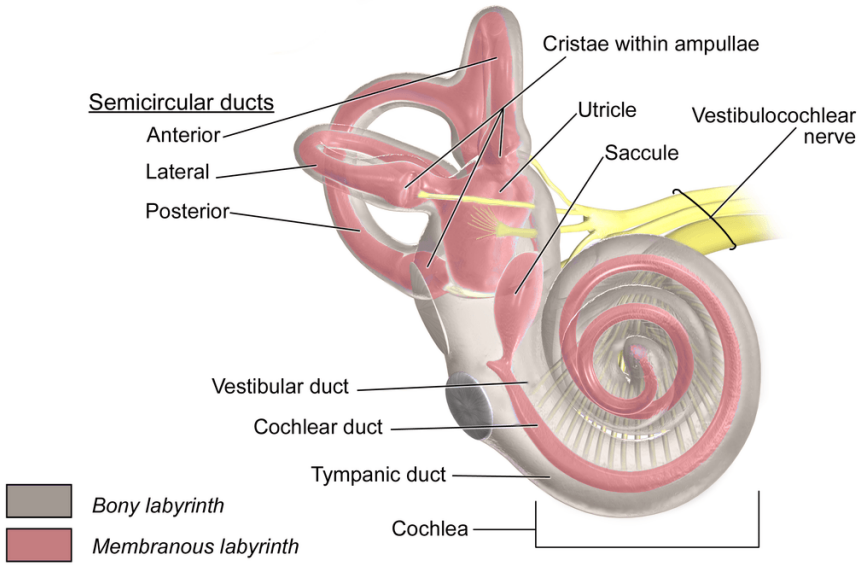

Figure 13.3.2: Inner Ear. Within the bony labyrinth are membraneous tubes and spaces that are filled with fluid. Fluid movement is the stimulus for both hearing and balance. *(Image Credit: "Inner Ear Anatomy - Cochlea and Vestibular Apparatus" by Jennifer Lange is licensed under CC BY-NC-SA 4.0, modification of original by Blausen.com staff (2014), "Medical gallery of Blausen Medical", WikiJournal of Medicine.)*

Sound is transduced into neural signals within the cochlear region of the inner ear, which contains the sensory neurons of the **spiral ganglia**. These ganglia are located within the spiral-shaped cochlea of the inner ear. The cochlea is attached to the stapes through the **oval window**. The oval window is located at the beginning of a fluid-filled tube within the cochlea called the **scala vestibuli**. The scala vestibuli extends from the oval window, traveling above the **cochlear duct**, which is the central cavity of the cochlea that contains the sound-transducing neurons. At the uppermost tip of the cochlea, the scala vestibuli curves over the top of the cochlear duct. The fluid-filled tube, now called the **scala tympani**, returns to the base of the cochlea, this time traveling under the cochlear duct. The scala tympani ends at the **round window**, which is covered by a membrane that contains the fluid within the scala.

A cross-sectional view of the cochlea shows that the scala vestibuli and scala tympani run along both sides of the cochlear duct (Figure 13.3.2 and Figure 13.3.3). The cochlear duct contains the **spiral organ (organs of Corti)**, which transduce the wave motion of the two scala into neural signals. The spiral organ lies on top of the **basilar membrane**, which separates the cochlear duct and the scala tympani. Another membrane called the **vestibular membrane** separates the cochlear duct from the scala vestibuli.

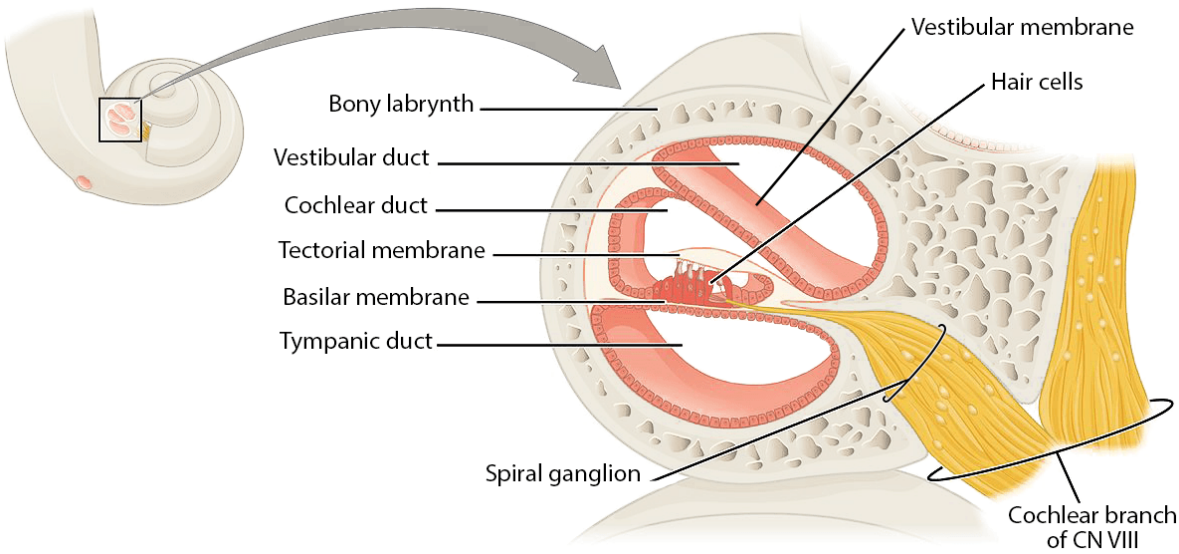

Figure 13.3.3: Cross Section of the Cochlea. The membranous labyrinth separates the cochlea in three major regions. The scala vestibuli and scala tympani lie on either side of the cochlear duct. The roof of the cochlear duct is formed by the vestibular membrane while the base of it is formed by the basilar membrane. Within the cochlear duct, the organ of Corti sits atop the basilar membrane and its cells extend towards the tectorial membrane. *(Image credit: "Section of the Cochlea" by Jennifer Lange is licensed under CC BY-NC-SA 4.0, derivative of original work by OpenStax.)*

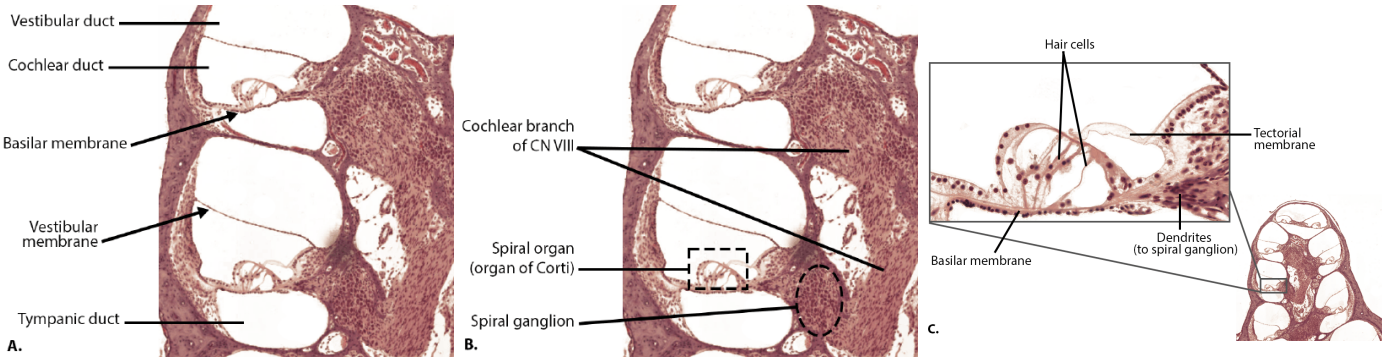

Figure 13.3.4: Histology of the Cochlea. The membranous labyrinth of the cochlea is divided into three ducts: vestibular, cochlear, and tympanic (A). The vestibular membrane forms the roof of the cochlear duct, and the floor is formed by the basilar membrane on which the spiral organ sits (B). The receptors for sound are the hair cells that sit on the basilar membrane and extends towards the tectorial membrane (C). *(Image credit: "Histology of the Cochlea" by Jennifer Lange is licensed under CC BY-NC-SA 4.0, slide provided by the Regents of the University of Michigan Medical School © 2022)*

The spiral organ contains **hair cells**, which are named for the hair-like **stereocilia** extending from the cell's apical surface (Figure 13.3.5). The stereocilia are an array of microvilli-like structures arranged from tallest to shortest. The stereocilia extend up from the hair cells to the overlying **tectorial membrane**, which is attached medially to the spiral organ. Protein fibers tether adjacent stereocilia together within each array, such that relative shifts between the basilar membrane and the tectorial membrane bend the stereocilia, causing ion channels to open. This converts the mechanical force of the fluid wave into an electrical signal.

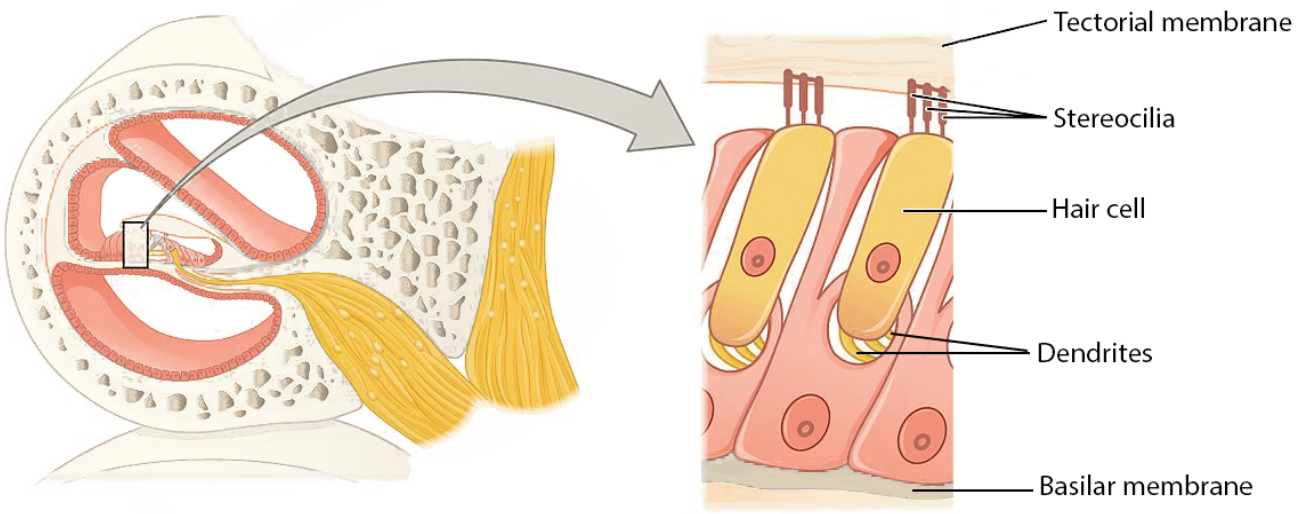

Figure 13.3.5: Hair Cells of the Spiral Organ. The hair cell is a mechanoreceptor with an array of stereocilia emerging from its apical surface. The stereocilia extend towards the tectorial membrane. The stereocilia are tethered together by proteins and bend in response to movements of the basilar membrane. *(Image credit: "Cochlear Hair Cells" by Jennifer Lange is licensed under CC BY-NC-SA 4.0, derivative of original work by OpenStax.)*

The transmission and transduction of sound require the participation of the majority of the structures of the ear. Each sound wave has a specific frequency, which depends on its pitch, and amplitude, which depends on its loudness. Sound waves are funneled into the ear canal by the auricle and reach the tympanic membrane (Figure 13.3.6). The vibration of the tympanic membrane is amplified across the ossicles. As vibrations of the ossicles travel through the oval window, the fluid of the scala vestibuli and scala tympani moves in a wave-like motion. The frequency of the fluid waves match the frequencies of the sound waves. The membrane covering the round window will bulge out or pucker in with the movement of the fluid within the scala tympani. As the fluid waves move through the scala vestibuli and scala tympani, the basilar membrane moves at a specific spot of the cochlea, depending on the frequency of the waves. Higher frequency waves move the region of the basilar membrane that is close to the base of the cochlea. Lower frequency waves move the region of the basilar membrane that is near the tip of the cochlea. When the fluid waves from the scala move the basilar membrane, the tectorial membrane slides across the stereocilia. This bends the stereocilia either toward or away from the tallest member of each array of stereocilia. When the stereocilia bend toward the tallest member of their array, tension in the protein tethers opens ion channels in the hair cell membrane. This will electrically change the hair cell membrane, triggering nerve impulses that travel down the afferent nerve fibers attached to the hair cells. When the stereocilia bend toward the shortest member of their array, the tension on the tethers slackens and the ion channels close. The relative movement of different arrays of stereocilia along the length of the basilar membrane allows the brain to perceive frequency, or pitch. The greater force of louder sounds causes an increase in the range of movement of the stereocilia of the hair cells, determining the loudness of a sound.

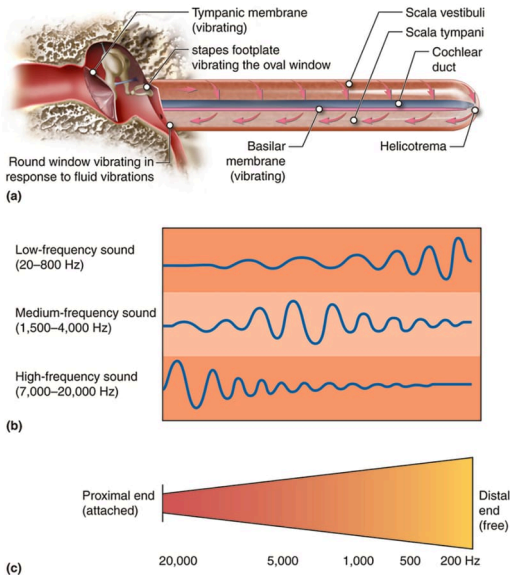

Figure 13.3.6: Transmission of Sound Waves to Cochlea. The transmission is represented in five steps. 1) Sound wave represents alternating areas of high and low pressure, whose frequency can be measured in Hz (cycles per second). 2) Tympanic membrane vibrates in response to sound wave. 3) Vibrations are amplified across the ossicles, in order malleus, incus, and stapes. 4) Vibrations against oval window set up standing wave in fluid of the scala vestibuli and scala tympani. The frequency of the standing wave is the same as the initial sound wave. 5) Pressure bends the membrane of the cochlear duct at a point of maximum vibration for a give frequency, causing hair cells of the spiral organ on the basilar membrane to vibrate. The complexity of the pressure waves is determined by the changes in amplitude and frequency of the sound waves entering the ear. *(Image credit: "Cochlear function based on wave frequency" by Cenveo is licensed under CC BY 3.0.)*

The initial afferent fibers are bipolar neurons. The dendrites of these neurons receive the signal from the hair cell then carry the signal to the cell cell body located in the spiral ganglion. Axons emerging from the spiral ganglion then carry neural signals through the **cochlear nerve** which travels within the **vestibulocochlear nerve (CN VIII),** terminating in the cochlear nuclei in the pons(Figure 13.3.7). From the cochlear nuclei the auditory information travels along multiple pathways, but the primary auditory pathway goes through the inferior colliculus (auditory reflexes) and then through the **thalamus** and into the **primary auditory cortex** of the temporal lobe.

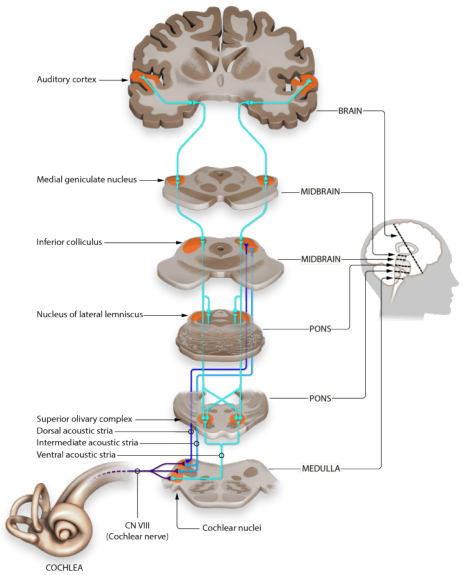

Figure 13.3.7: Auditory Pathways. The primary pathway of auditory signals goes from the cochlea to the 1) cochelar nuclei, 2) inferior colliculi, 3) medial geniculate nucleus of the thalamus, and then to 4) the primary auditory cortex in the temporal lobe. *(Image Credit: "Auditory Pathways" by Jonathan E. Peelle is licensed under CC BY 4.0, via Wikimedia Commons.)*

Equilibrium (Balance)

Along with audition, the inner ear is responsible for encoding information about **equilibrium**, the sense of balance. A similar mechanoreceptor—a hair cell with stereocilia—senses head position, head movement, and whether our bodies are in motion. These cells are located in the **vestibule** and **semicircular canals** within the inner ear. Vestibule and semicircular canals compose the **vestibular system**. The vestibule is the central part of the bony labyrinth, and is located posterior to the cochlea and anterior to the semicircular canals. Within the vestibule, the membranous labyrinth forms two chambers, the **utricle** and **saccule**, which contain endolymph. The utricle and saccule are interconnected by a narrow **endolymphatic duct** and their endolymph is confluent with that of the semicircular ducts and cochlear duct. Head position is sensed by the utricle and saccule, whereas head movement is sensed by the semicircular canals.

The utricle and saccule are both largely composed of **macula** tissue (plural = maculae). The macula is composed of hair cells surrounded by **supporting cells**. The stereocilia of the hair cells extend into a viscous gel called the **otolithic membrane** (Figure 13.3.8). On top of the otolithic membrane is a layer of calcium carbonate crystals, called **otoliths**. The otoliths essentially make the otolithic membrane top-heavy. The otolithic membrane moves separately from the macula in response to head movements. Tilting the head causes the otolithic membrane to slide over the macula in the direction of gravity. The moving otolithic membrane, in turn, bends the stereocilia, causing the hair cells to elicit electrical changes. The exact position of the head is interpreted by the brain based on the pattern of hair-cell activation.

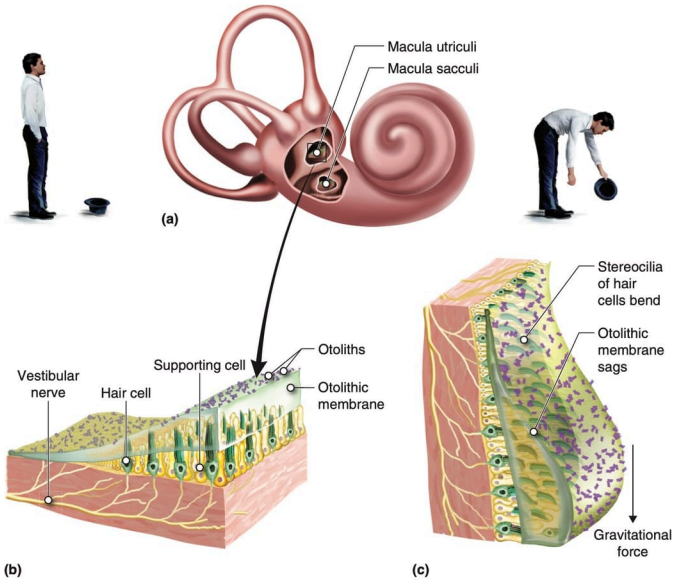

Figure 13.3.8: Linear Acceleration Coding by Maculae. The maculae within the utricle and saccule of the vestibular apparatus are specialized structures lined with supporting cells and hair cells and filled with endolymph. The maculae sense linear acceleration, such as when gravity acts on the tilting head, or if the head starts moving in a straight line. The difference in inertia between the hair cell stereocilia and the otolithic membrane in which they are embedded leads to a shearing force that causes the stereocilia to bend in the direction of that linear acceleration. *(Image credit: "Cenveo - Drawing Structure of the Maculae - English labels" by Cenveo, license: CC BY.)*

The semicircular canals are three ring-like extensions of the vestibule. One is oriented in the horizontal plane, whereas the other two are oriented in the vertical plane. The anterior and posterior vertical canals are oriented at approximately 45 degrees relative to the sagittal plane (Figure 13.3.9). The base of each semicircular canal, where it meets with the vestibule, connects to an enlarged region known as the **ampulla**. The ampulla contains the hair cells that respond to rotational movement, such as turning the head while saying “no.” The stereocilia of these hair cells extend into the **cupula**, a gelatinous membrane that attaches to the top of the ampulla. As the head rotates in a plane parallel to the semicircular canal, the fluid lags, deflecting the cupula in the direction opposite to the head movement. The semicircular canals contain several ampullae, with some oriented horizontally and others oriented vertically. By comparing the relative movements of both the horizontal and vertical ampullae, the vestibular system can detect the direction of most head movements within three-dimensional (3-D) space.

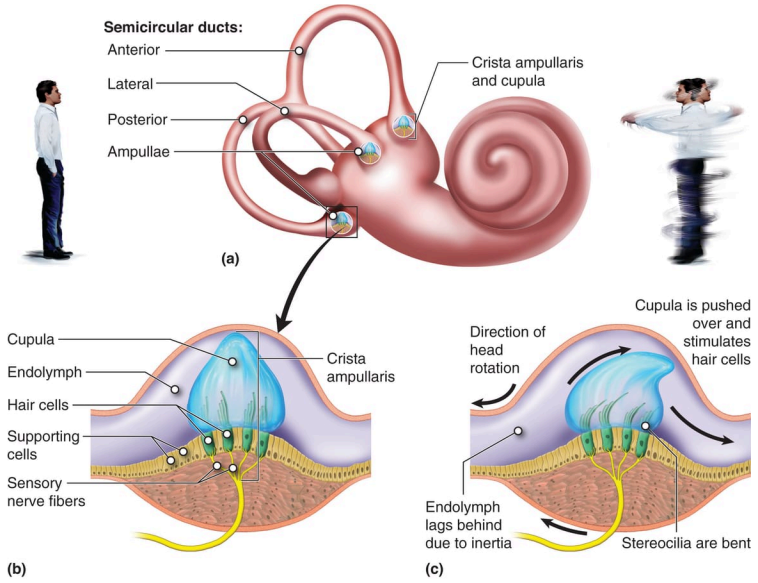

Figure 13.3.9: Rotational Coding by Semicircular Canals. Rotational movement of the head is encoded by the hair cells contained in ampullae at the base of the semicircular canals. The ampulla is filled with endolymph and contains hair cells that have stereocilia embedded in a gelatinous substance called the cupula. As one of the canals moves in an arc with the head, the endolymph moves in the opposite direction, causing the cupula and stereocilia to bend. The movement of two canals within a plane results in information about the direction *("Cenveo - Drawing Structure and Function of the Semicircular Canals - English labels" by Cenveo, license: CC BY)*

The neural signals generated in the vestibule and semicircular canals are transmitted through the **vestibular nerve** which travels within the **vestibulocochlear nerve (CN VIII)**. The nerve carries the equilibrium information into the brain, through the **thalamus**, and to **cerebral nuclei**, **brainstem** and **cerebellum**.

Structure of the Inner Ear

Explore the structure of the inner ear in the 3D rendering of an inner ear model.

This interactive element is not available in this format. Visit the link or scan the QR code to access it online.

View this Interactive Content online

Inner Ear by **AnatomyPhysiologySCC** on **Sketchfab**

Concept Review

Hearing and balance belong to the special senses with their receptors present in the inner ear.

The ear is divided in three regions: external, middle and inner ear. In the external ear, the auricle is the fleshy structure that convey sounds into the auditory canal. At the end of the canal is the tympanic membrane that vibrates and transforms sound waves into mechanical waves. The middle ear consists of a space spanned by three small bones called ossicles (malleus, incus, and stapes) that conduct the mechanical waves. The middle ear is connected to the pharynx through the Eustachian (or auditory) tube, which helps equilibrate air pressure across the tympanic membrane. The inner ear is made of a bony labyrinth lined with a membranous labyrinth that separate tubes and spaces. The space between the two labyrinths is filled with a fluid called perilymph. Inside the membranous labyrinth the space is filled with endolymph. The inner ear is responsible for transforming mechanical waves into electrical signals, which are then sent to the brain through the vestibulocochlear nerve (CN VIII).

The cochlea is a spiral-shaped tube, divided into three compartments: the scala vestibuli, scala tympani and cochlear duct. All compartments are filled with endolymph. The scala vestibuli starts at the oval window, curves over the top of the cochlear duct and becomes the scala tympani, that returns to the base of the cochlea, traveling under the cochlear duct and ends at the round window. As vibrations of the ossicles travel through the oval window, the fluid of the scala vestibuli and scala tympani moves in a wave-like motion. The cochlear duct contains several organs of Corti, which transduce the wave motion of the two scala into neural signals. The organs of Corti lie on top of the basilar membrane, which is the side of the cochlear duct located between the organs of Corti and the scala tympani. The organs of Corti contain hair cells, which are named for the hair-like stereocilia extending from the cell's apical surfaces. The stereocilia extend up from the hair cells to the overlying tectorial membrane, which is attached medially to the organ of Corti. When the pressure waves from the scala move the basilar membrane, the tectorial membrane slides across the stereocilia. This bends the stereocilia either toward or away from the tallest member of each array, which causes an electrical signal to be generated.

The vestibule and the semicircular canals are responsible for the sense of equilibrium. The vestibule is composed of the utricle and saccule. Hair cells are located in maculae of the utricle and saccule. The stereocilia of the hair cells extend into a viscous gel called the otolithic membrane, on top of which is a layer of calcium carbonate crystals, called otoliths. The vestibule senses the linear acceleration of the head and gravity. When the head moves, the otoliths move and the otolithic membrane bends the stereocilia of the hair cells. Hair cells are also located in ampullae at the base of the three semicircular canals. One is oriented in the horizontal plane, whereas the other two are oriented in the vertical plane. The stereocilia of these hair cells extend into the cupula, a membrane that attaches to the top of the ampulla. The semicircular canals sense the head rotation. As the head rotates in a plane parallel to the semicircular canal, the fluid lags, deflecting the cupula in the direction opposite to the head movement, and bending the stereocilia of the hair cells.

Review Questions

Query 13.3.1

This interactive element is not available in this format. Visit the link or scan the QR code to access it online.

View this Interactive Content online

Glossary

Query 13.3.2

This interactive element is not available in this format. Visit the link or scan the QR code to access it online.

View this Interactive Content online

Contributors and Attributions

OpenStax Anatomy & Physiology (CC BY 4.0). Access for free at https://openstax.org/books/anatomy-and-physiology

This page titled 13.3: Hearing and Balance is shared under a CC BY-NC-SA 4.0 license and was authored, remixed, and/or curated by Jennifer Lange et al..

- 13.3: Hearing, Balance and Vision by Whitney Menefee, Julie Jenks, Chiara Mazzasette, and Kim-Leiloni Nguyen is licensed CC BY 4.0.

13.4: Vision

By the end of this section, you will be able to:

- Explain the role of the accessory structures of the eye.
- Describe the gross and microscopic structures responsible for the special sense of vision
- Trace the pathway of visual information from the photoreceptors to the brain
- Explain topographical representations of visual information

Vision

Vision is the special sense of sight that is based on the detection and transduction of light stimuli from the eyes to the brain. The eye contains the receptors for light (photoreceptors) that detect light, color (wavelength), and movement.

Eye Structure

The eye itself is a hollow spherical organ that measures approximately 2.5 centimeters across in a human. Within the orbit it is surrounded by adipose tissue, which serves as the "packing peanuts" that keep the eye in place and cushioned so that it does not shift position or contact the surrounding bone. The wall of the eye is composed of three layers called tunics (Figure 13.4.1 and Figure 13.4.2).

Tunics

The outermost layer is the **fibrous tunic**, which includes the white **sclera** posteriorly and clear **cornea** anteriorly. The sclera accounts for five sixths of the surface of the eye, most of which is not visible, though humans are unique compared with many other species in having so much of the “white of the eye” visible. Think about your dog or cat - you do not see the whites of their eyes! The tough sclera (skleros = hard) is composed of dense irregular connective tissue. Functionally it give shapes to the eye and serves at the attachment point for the extraocular muscles (see chapter 9 for review). The transparent cornea covers the anterior surface of the eye. Its convex shape allows for the bending of light as it enters the eye, so any distortions of its shape will result in the inability to focus what you are looking at.

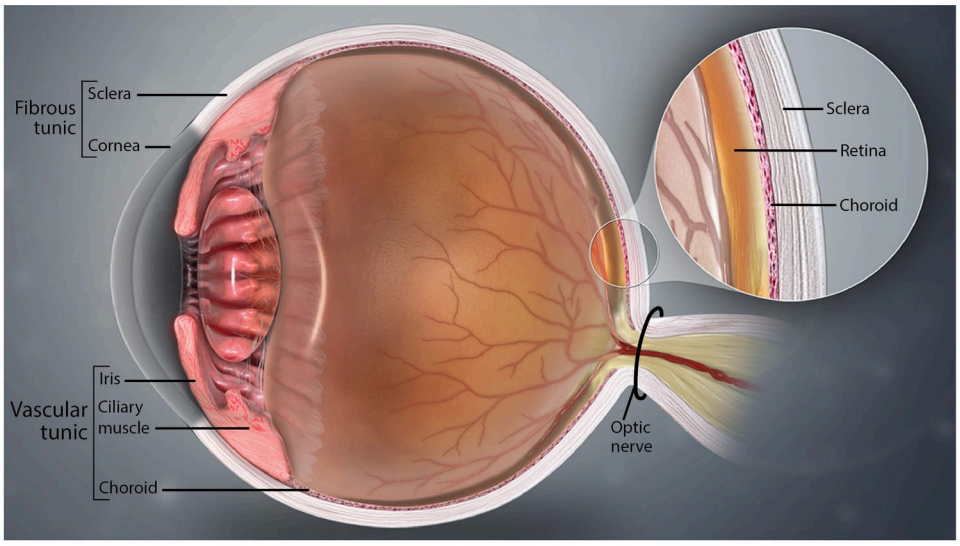

Figure 13.4.1: Tunics of the Eye. The wall of the eye is composed of three layers. From superficial to deep they are 1) fibrous tunic, 2) vascular tunic, and 3) neural tunic (also called the retina). *(Image credit: "Eye Structure - Tunics" by Sofia Elizondo is licensed under CC BY-NC-SA 4.0, modification of original by Scientific Animations.)*

The middle layer of the eye is the **vascular tunic**, which is composed of the choroid, ciliary body, and iris. The **choroid** is a layer of highly vascularized connective tissue that provides a blood supply to the eyeball. This layer is also highly pigmented, with numerous melanocytes, in order to absorb any extraneous light and prevent it from reflecting within the spherical eye. The choroid is posterior to the **ciliary body**, a muscular structure that is attached to the **lens** by **suspensory ligaments**. Contraction and relaxation of the ciliary muscle alters the thickness and curve of the lend, allowing it to adjust the focal point of light on the back of the eye. Anterior to the the ciliary body, and visible externally, is the **iris**—the colored part of the eye. The color of the iris is dependent upon multiple factors related to melanin production, but the color runs from lower melanin (blue) to high melanin (dark brown). What appears as a black circle in the center of the iris is the **pupil,** which is really a hole in the center the through which light passes. The function of the iris is to adjust the amount of light entering the eye, so the smooth muscles within it will contract/relax in order to change the pupil diameter.

The innermost layer of the eye is the **neural tunic,** the **retina**, that contains the nervous tissue responsible for absorbing light and converting it into a neural signal. The retina consists of two layers: a pigmented layer and a neural layer. The **pigmented epithelium** is a single layer of pigmented cuboidal cells containing melanin that absorb light after it passes through the retina. These cells also provide vital metabolic support for the photoreceptors. The **neural layer** consists of three main sublayers: the photoreceptor layer, a bipolar cell layer, and the ganglion cell layer. The structure of the retina will be discussed more below.

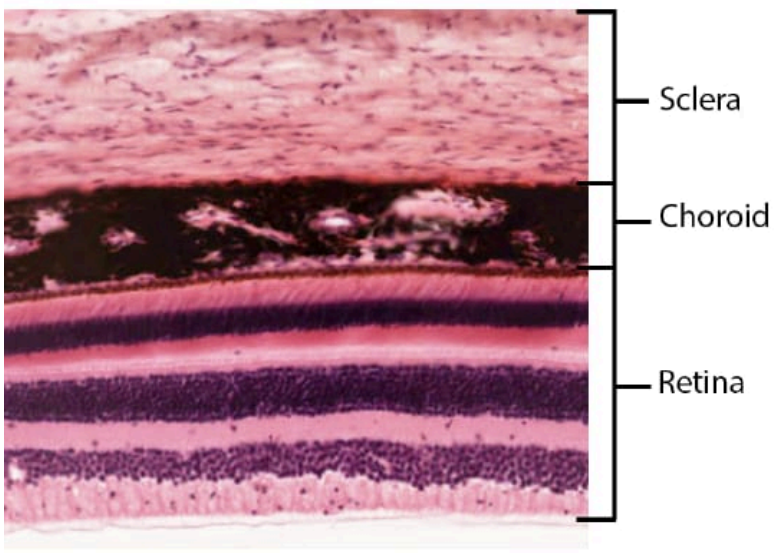

Figure 13.4.2: Histology of the Eye Wall. From superficial to deep the tunics of the wall of the eye are the sclera, choroid, and retina. The retina is subdivided into multiple layers of neurons. *(Image credit: "Histology of the eye wall" by Jennifer Lange is licensed under CC BY-NC-SA 4.0, slide provided by the Regents of the University of Michigan Medical School © 2022)*

Cavities and Chambers

The interior of the eye is divided into two cavities (Figure 13.4.3) that are filled with circulating fluids: the **anterior cavity** and the **posterior cavity**. The anterior cavity is the space between the cornea and lens that is further divided into **anterior and posterior chambers** by the iris. These chambers are filled with a watery fluid called the **aqueous humor**. The posterior cavity is the space between the lens and the the retina that is filled with a thicker fluid called the **vitreous humor**. The vitreous humor has a similar consistency to the white part of an egg.

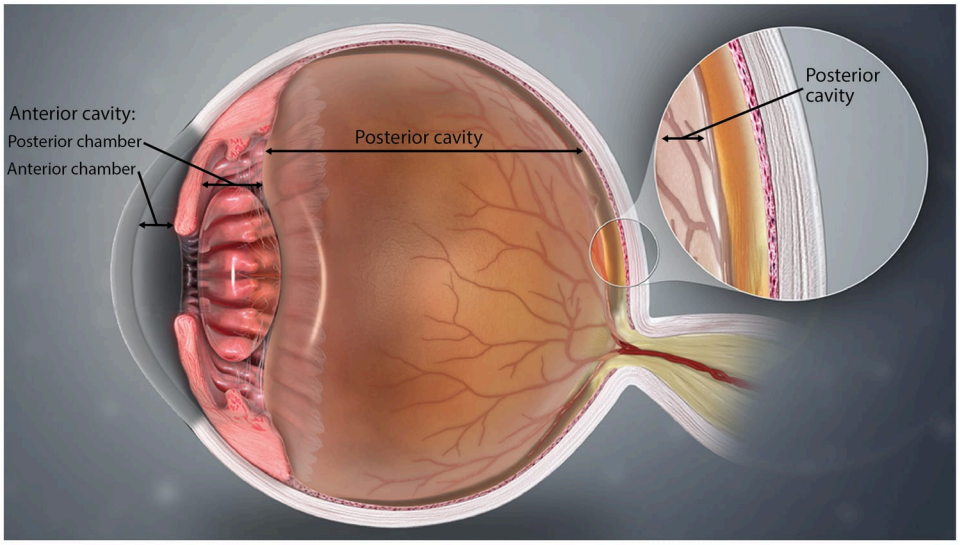

Figure 13.4.3: Cavities of the Eye. The interior of the eye is divided into two fluid filled cavities: the anterior cavity is anterior to the lens and the posterior cavity is posterior to the lens. *(Image credit: "Eye Structure - Cavities" by Sofia Elizondo is licensed under CC BY-NC-SA 4.0, modification of original by Scientific Animations.)*

Retinal Structure

The retina is composed of several layers and contains specialized cells for the initial processing of visual stimuli. The photoreceptors change their membrane electrical properties when stimulated by light energy. Light falling on the retina causes

chemical changes to pigment molecules in the photoreceptors. There are two types of photoreceptors called rods and cones (Figures 13.4.4 and 13.4.5. **Cones** each contain one of three photopigments that are specialized to absorb three different color ranges of the light spectrum: red, green, and blue. **Rods** can absorb light from across the color spectrum and they are able to function in low light conditions, for example in a darkened room. Cones need more light to function than rods, which is why you cannot see colors in a dimly lit environment. The absorption of light alters the amount of neurotransmitter the photoreceptor cells release onto **bipolar cells** (see Figure 13.4.16. Each bipolar cell receives signals from multiple photoreceptors. Multiple bipolar cells then pass their signal to a **ganglion cell**.

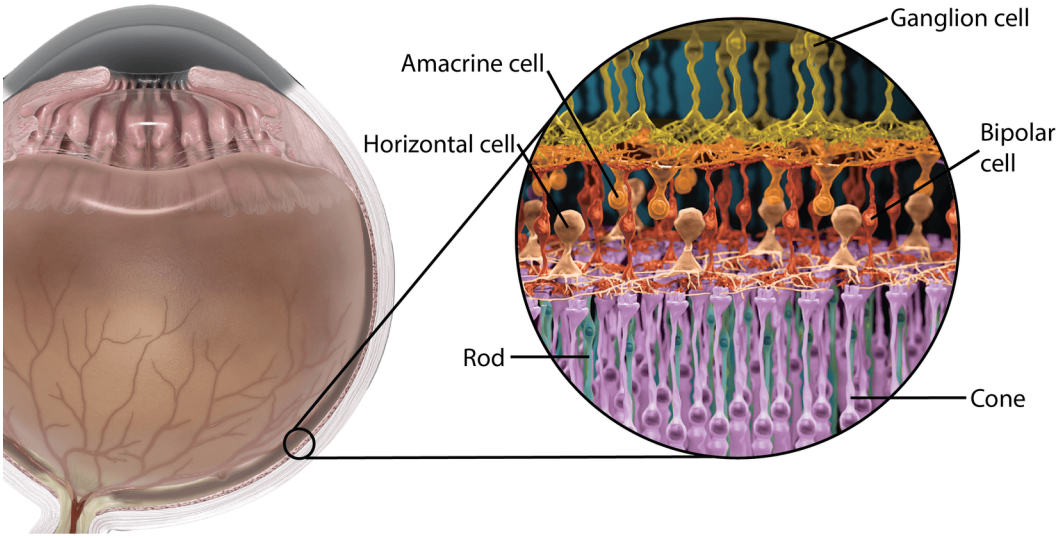

Figure 13.4.4: Neural Retina. Light absorbed by the rods and cones generates an electrical signal that is passed to the bipolar cells and then to the ganglion cells. Along the way, the signal is modified by amacrine cells and horizontal cells. *(Image credit: "Eye Structure - Neural Retina" by Sofia Elizondo is licensed under CC BY-NC-SA 4.0, modification of original by Scientific Animations.)*

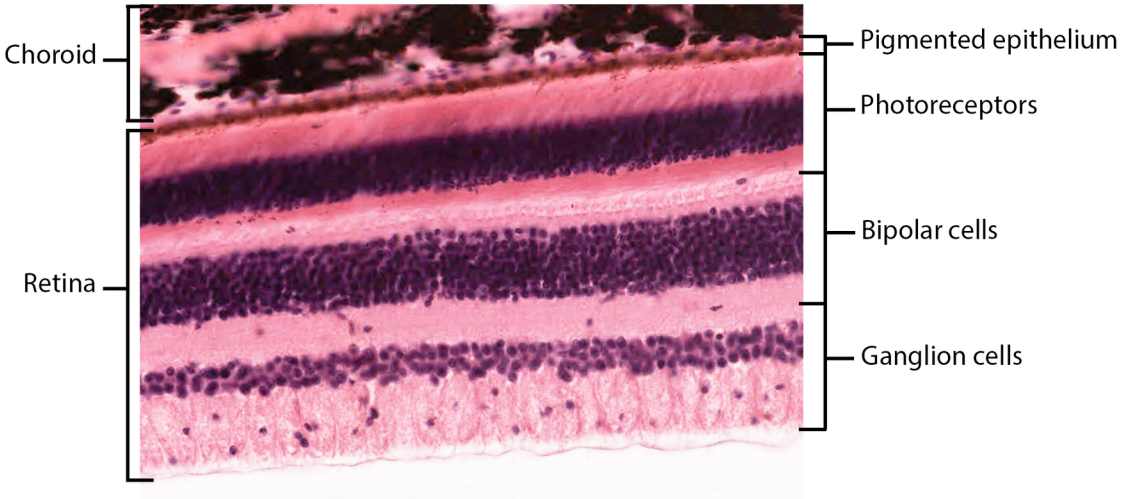

Figure 13.4.5: Histology of the Retina. The retina consists of two sublayers: the pigmented epithelium and the neural retina. The neural retina contains three layers of bipolar neurons (from the choroid to the posterior cavity) the photoreceptors, the bipolar cells, and the ganglion cells. Notice that the nuclei of the neurons are in the center of their respective cell layer and that they decrease in number as the electrical signal passes from the rods and cones through the bipolar cells and to the ganglion cells. *(Image credit: "Histology of the Retina" by Jennifer Lange is licensed under CC BY-NC-SA 4.0, slide provided by the Regents of the University of Michigan Medical School © 2022)*

The axons of ganglion cells, which form the deepest layer of the retina, located adjacent to the posterior cavity, collect at the **optic disc** and leave the eye as the **optic nerve**. Because these axons exit through the retina, there are no photoreceptors at the location where the optic nerve begins (Figure 13.4.6). This creates a "blind spot" in the retina, and a corresponding blind spot in our visual field.

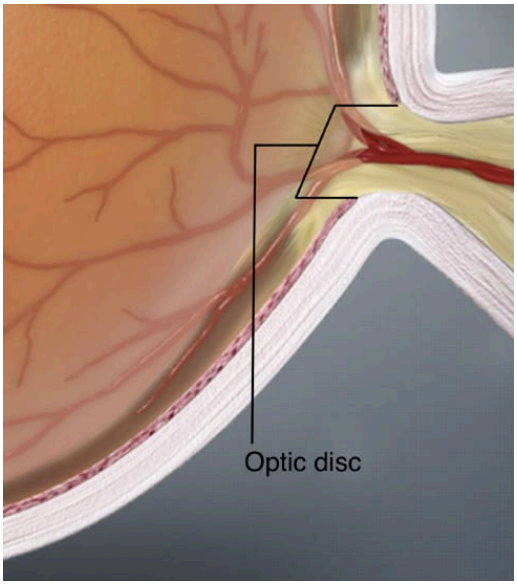

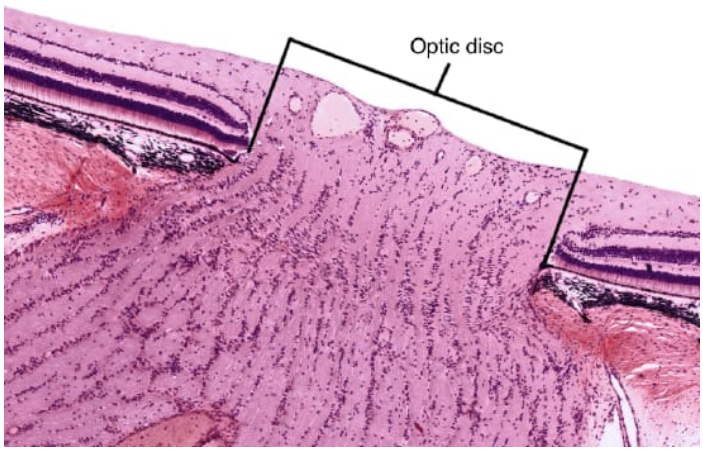

Figure \({13{.}4{.}\eatSpaces{6\): Optic Disc. No photoreceptors are located at this point because the axons of the ganglion cells are projecting through the eye wall. The inability to detect light give this area the nickname the "blind spot". *(Image credit: "Eye Structure - Optic Disc" by Jennifer Lange is licensed under CC BY-NC-SA 4.0, modification of original by Scientific Animations. "Optic Disc Histology" by Jennifer Lange is licensed under CC BY-NC-SA 4.0, slide provided by the Regents of the University of Michigan Medical School © 2022.)*

Note that the photoreceptors in the retina (rods and cones) are located behind the axons, ganglion cells, bipolar cells, and retinal blood vessels. A significant amount of light is absorbed by these structures before the light reaches the photoreceptor cells. However, at the exact center of the retina is a small region known as the **macula lutea** at which center there is a depression called the **fovea** (Figure Extra close brace or missing open brace). In these regions, the retina lacks the supporting cells and blood vessels, and only contains cones. Therefore, **visual acuity**, or the sharpness of vision, is greatest at the fovea. As one moves in either direction from this central point of the retina, visual acuity drops significantly. In addition, each photoreceptor cell of the fovea is connected to a single ganglion cell. Therefore, this ganglion cell does not have to integrate inputs from multiple photoreceptors, which reduces the accuracy of visual transduction. Toward the edges of the retina, several photoreceptors converge on retinal ganglion cells (through the bipolar cells) up to a ratio of 50 to 1. The difference in visual acuity between the fovea and peripheral retina is easily evidenced by looking directly at a word in the middle of this paragraph. The visual stimulus in the middle of the field of view falls on the fovea and is in the sharpest focus. Without moving your eyes off that word, notice that words at the beginning or end of the paragraph are not in focus. The images in your peripheral vision are focused by the peripheral retina, and have vague, blurry edges and words that are not as clearly identified. As a result, a large part of the neural function of the eyes is concerned with moving the eyes and head so that important visual stimuli are centered on the fovea.

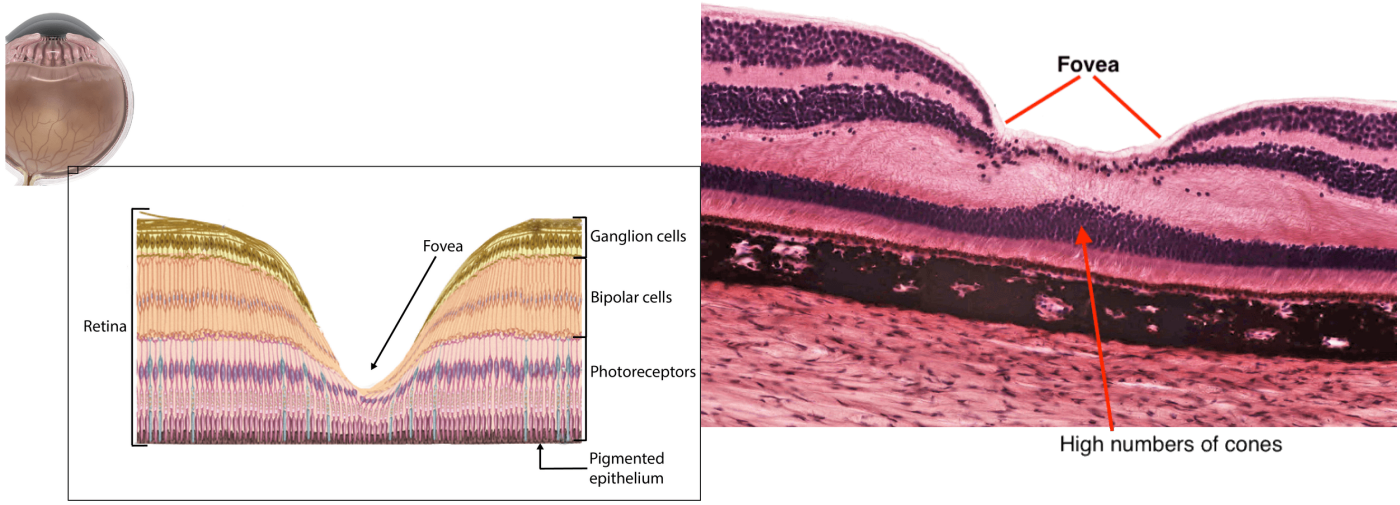

Figure 13.4.7: Fovea. At the exact center of the retina is a region called the macula lutea with a depression called the fovea. At the fovea there are no blood vessels, ganglion cells or bipolar cells to interrupt light reaching the receptor cells and only cones are present. Because more light passes to the receptor cells at the fovea, it is in this region that visual acuity is the greatest. *(Image credit: "Retinal Cell Layers at Fovea Illustration" by Sofia Elizondo is licensed under CC BY-NC SA 4.0, modification of original "Cenveo - Drawing Anatomy of the fovea - English labels" by Cenveo. "Fovea Histology" by Jennifer Lange is licensed under CC BY-NC-SA 4.0, slide provided by the Regents of the University of Michigan Medical School © 2022.)*

DISORDERS OF THE...

Retina: Macular degeneration

Macular degeneration is a common age-related eye condition that affects central vision due to a progressive deterioration of the macula (Figure 13.4.8). In early stages vision is not affected, but as the degeneration progresses central vision will become blurry or wavy. In late stages the central vision fails completely. People with macular degeneration aren't completely blind as only the central vision is affected, peripheral vision (ability to see things off to the sides) is fine. Macular degeneration typically occurs in people over the age of 50, so it is considered age-related. The cause of this condition is unknown, but, since it runs in families, it can have a genetic component. Other risk factors include being overweight, smoking, having high blood pressure (hypertension), eating a diet high in saturated fats, and Caucasian ancestry.

Figure 13.4.8: Macular Degeneration. Compare the retinal scan of the healthy right eye with the retinal scan of the affected left eye. This is an example of dry macular degeneration, showing yellow protein deposits called drusen that form underneath the retina. *(Image Credits: "Fundus photograph of normal right eye" by* Häggström, Mikael (2014) from Medical gallery of Mikael Häggström 2014, is in the public domain. "*Intermediate age related macular degeneration*" *by* National Eye Institute of the NIH, is in the public domain.*)*

Visual Pathways

The visual information of the optic nerve will be transmitted through the **thalamus** and sent to the **primary visual cortex** of the occipital lobe (Figure 13.4.9). Prior to reaching the thalamus, some of the axons cross over to the opposite side at the **optic chiasm**. This occurs because each eye sees a part of both the right visual field (everything to the right of your nose) and of the left visual field (everything to the left of your nose). In order for the occipital lobes each to process all of the information from a single visual field, some of the information needs to head to the opposite side. After this crossing, the nerve fibers from a single field of view will travel in an **optic tract** and synapse on interneurons in the **lateral geniculate nucleus** of the thalamus. The thalamic axons will travel to the occipital lobe in a tract called the **optic radiations**.

Optical

Figure 13.4.9: Visual Pathways. Information regarding stimuli from the right visual field will flow through the left side of the thalamus and then to the left occipital lobe. Information regarding stimuli from the left visual field will travel to the right occipital lobe. *(Image Credit: "Visual Pathways" by OpenStax College is licensed under CC BY 3.0, via Wikimedia Commons.)*

DISORDERS OF THE...

Visual Pathway: Bitemporal hemianopia

Visual field deficits can be disturbing for a patient. Bitemporal hemianopia is a type of partial blindness where vision is missing in the lateral half of both the right and left visual fields (Figure 13.4.8). One cause of this condition is growth of the pituitary gland that presses against the optic chiasm and interferes with signal transmission of the crossing fibers. The axons projecting to the same side of the brain are unaffected. Therefore, the patient loses the outermost areas of their field of vision and cannot see objects to their right and left yet they retain their central vision.

Figure 13.4.10: Bitemporal Hemianopia. Disruption of the visual signals passing through the optic chiasm causes loss of the lateral half of the visual field from each eye. *(Image Credit: The original uploader was Nunh-huh at English Wikipedia., CC BY-SA 3.0, via Wikimedia Commons.)*

Cerebrum

The topographic relationship between the retina and the visual cortex is maintained throughout the visual pathway. The visual field is projected onto the two retinae, as described above, with sorting at the optic chiasm. The right peripheral visual field falls on the medial portion of the right retina and the lateral portion of the left retina. The right medial retina then projects across the midline through the optic chiasm. This results in the right visual field being processed in the left visual cortex. Likewise, the left

visual field is processed in the right visual cortex. Though the chiasm is helping to sort right and left visual information, superior and inferior visual information is maintained topographically in the visual pathway. Light from the superior visual field falls on the inferior retina, and light from the inferior visual field falls on the superior retina. This topography is maintained such that the superior region of the visual cortex processes the inferior visual field and vice versa. Therefore, the visual field information is inverted and reversed as it enters the visual cortex—up is down, and left is right (Figure 13.4.11). However, the cortex processes the visual information such that the final conscious perception of the visual field is correct. The topographic relationship is evident in that information from the foveal region of the retina is processed in the center of the primary visual cortex. Information from the peripheral regions of the retina are correspondingly processed toward the edges of the visual cortex. Similar to the exaggerations in the sensory homunculus of the somatosensory cortex, the foveal-processing area of the visual cortex is disproportionately larger than the areas processing peripheral vision.

In an experiment performed in the 1960's, subjects wore prism glasses so that the visual field was inverted before reaching the eye. On the first day of the experiment, subjects would duck when walking up to a table, thinking it was suspended from the ceiling. However, after a few days of acclimation, the subjects behaved as if everything were represented correctly. Therefore, the visual cortex is somewhat flexible in adapting to the information it receives from our eyes.

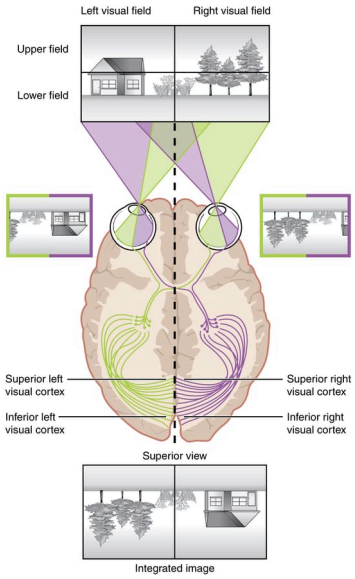

Figure 13.4.11: Topographic Mapping of the Retina onto the Visual Cortex. The visual field projects onto the retina through the lenses and falls on the retinae as an inverted, and reversed image where left is right and superior is inferior, and vice versa. The topography of this image is maintained as the visual information travels through the visual pathway to the visual cortex of the occipital lobe, resulting into an integrated image being inverted and reversed. (Image credit: "1422 Topographical Image on Retina" by OpenStax is licensed under CC BY 3.0)

The cortex has been described as having specific regions that are responsible for processing specific information; there is the visual cortex, somatosensory cortex, gustatory cortex, etc. However, our experience of these senses is not divided. Instead, we experience what can be referred to as a seamless percept. Our perceptions of the various sensory modalities—though distinct in their content—are integrated by the brain so that we experience the world as a continuous whole.

In the cerebral cortex, sensory processing begins at the **primary sensory cortex**, then proceeds to an **association area**, and finally, into a **multimodal integration area**. For example, the visual pathway projects from the retinae through the thalamus to the primary visual cortex in the occipital lobe. This area is primarily in the medial wall within the longitudinal fissure. Here, visual stimuli begin to be recognized as basic shapes. Edges of objects are recognized and built into more complex shapes. Also, inputs from both eyes are compared to extract depth information. Because of the overlapping field of view between the two eyes, the brain can begin to estimate the distance of stimuli based on **binocular depth cues**.

Accessory Structures of the Eye

The accessory structures provide a superficial covering over the anterior surface of the eye. They serve to protect the eye from physical damage, prevent objects from entering the eye socket, and keep the exposed surface lubricated and moist (Figure 13.4.12).

- The bony orbits surround the eyes, encasing them in a hard surrounding shell and anchoring the soft tissues of the eye in place.
- The eyelids, with lashes at their leading edges, help to protect the eye from abrasions by blocking and catching particles that may land on the surface of the eye. Each eyelid contains a thin covering of skin that, when closed, helps to distribute the **lacrimal fluid** (tears) to wash and lubricate the surface.
- The **conjunctiva** forms a continuous lining from the posterior side of the eyelid across the white portion of the eye. Made of stratified squamous epithelial tissue, the conjunctiva contains secretory cells, free nerve endings, and blood vessels.

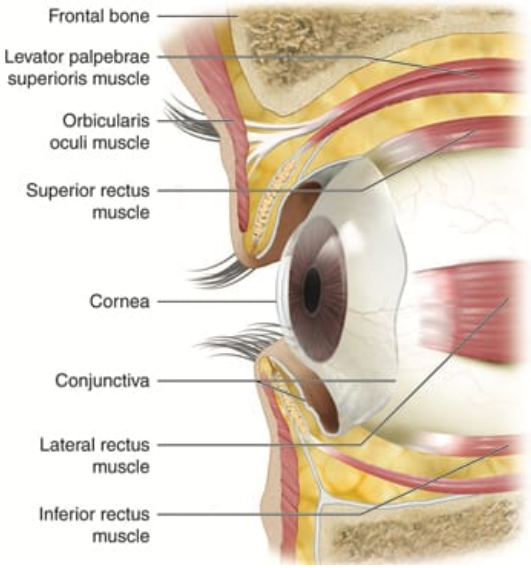

Figure 13.4.12: Protection and Support of the Eye. The eye is located within the orbit and surrounded by soft tissues such as muscles and the conjunctiva that protect and support its function. (Image credit: from "Cenveo - Drawing Anatomical features of the lacrimal system and tissues surrounding the eye - English labels" by Cenveo, license: CC BY)

Lacrimal Apparatus

The lacrimal apparatus associated with each eye is responsible for the production and drainage of lacrimal fluid (tears). The lacrimal fluid helps protect the eye by reducing friction of the eyelids, continuously cleaning the anterior surface of the eye, and preventing bacterial infection through the action of lysozyme. Tears are produced by the **lacrimal gland**, located within the superolateral depression of each orbit (Figure 13.4.13). Tears produced by this gland are dispersed on the external surface of the eye by the movement of the eyelids and then flow towards the medial surface of the eye. Small openings drain the lacrimal fluid into channels that deliver it into the nasal cavity where it mixes with the mucus.

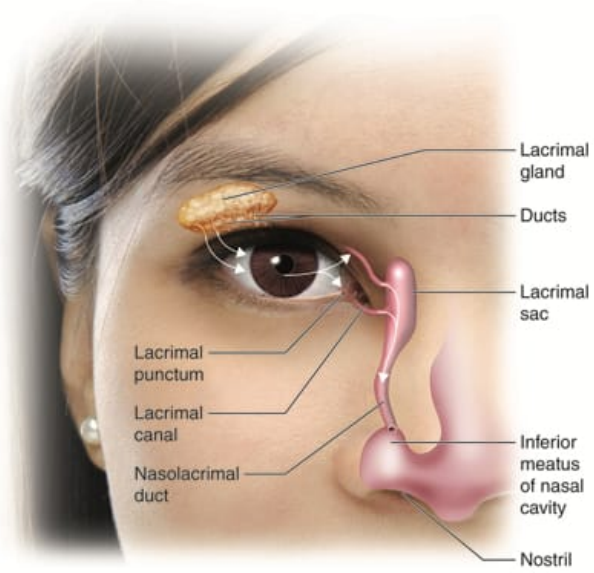

Figure 13.4.13: Lacrimal Apparatus. The lacrimal system produces lacrimal fluid that cleanses and moisturizes the anterior surface of the eye. Tears are produced by the lacrimal gland and dispersed on the external surface of the eye by the movement of the eyelids. (Image credit: from "Cenveo - Drawing Anatomical features of the lacrimal system and tissues surrounding the eye - English labels" by Cenveo, license: CC BY)

Extraocular Muscles

Movement of the eye within the orbit is accomplished by the contraction of six **extraocular muscles** that originate from the bones of the orbit and insert into the surface of the eyeball (Figure 13.4.14). Four muscles run straight from a common tendinous ring in the posterior of the orbit and insert into the surface of the eye. The insertion side of each of these muscles is in its name: the **superior rectus**, the **medial rectus**, the **inferior rectus**, and the **lateral rectus.** Contraction of one of these muscles causes movement toward the corresponding side. For example, when the superior rectus contracts, the eye rotates superiorly causing you to look up. The remaining two extraocular muscles run at an angle and cause eye rotation either clockwise or counter clockwise. The **superior oblique** originates at the posterior orbit, near the origin of the four rectus muscles. However, the tendon of the superior oblique muscles threads through a pulley-like piece of cartilage known as the **trochlea**. The tendon inserts obliquely into the superior surface of the eye. The angle of the tendon through the trochlea means that contraction of the superior oblique abducts, depresses, and internally rotates (intorsion) the eye. The **inferior oblique** muscle originates from the floor of the orbit and inserts into the inferolateral surface of the eye. When it contracts, it abducts, elevates, and externally rotates (extorsion) the eye. Rotation of the eye by the two oblique muscles is necessary because the eye is not perfectly aligned on the sagittal plane. When the eye looks up or down, the eye must also rotate slightly to compensate for the superior rectus pulling at approximately a 20-degree angle, rather than straight up. The same is true for the inferior rectus, which is compensated by contraction of the inferior oblique. A seventh muscle in the orbit is the **levator palpebrae superioris**, which is responsible for elevating and retracting the upper eyelid, a movement that usually occurs in concert with elevation of the eye by the superior rectus.

The extraocular muscles are innervated by three cranial nerves:

- the lateral rectus, which causes abduction of the eye, is innervated by the **abducens nerve (CN VI)**,
- the superior oblique is innervated by the **trochlear nerve (CN IV)**, and
- the superior rectus, inferior rectus, inferior oblique, and medial rectus are innervated by the **oculomotor nerve (CN III)**, as is the levator palpebrae superioris.

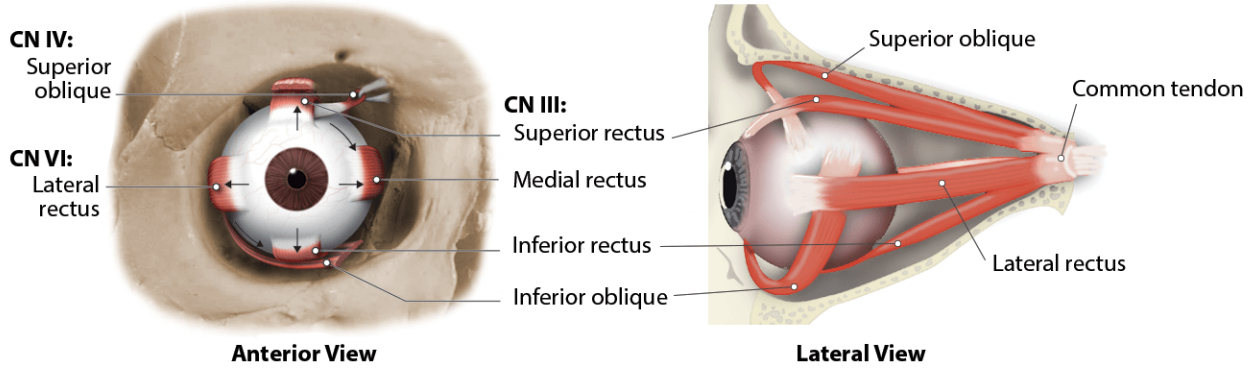

Figure 13.4.14: Extraocular Muscles. The extraocular muscles move the eye within the orbit. A lateral view of the eye shows the common tendinous ring, where the four rectus muscles originate from. The superior oblique muscle originate from the posterior orbit and its tendon threads through the trochlea to insert into the superior surface of the eye. The inferior oblique muscle originate from the inferior portion of the orbit and inserts into the inferolateral surface of the eye. An anterior view of the right eye shows the movements of the extraocular muscles. *(Image credit: "Extraocular Muscles" by Jennifer Lange is licensed under CC BY-NC-SA 4.0, based on originals "Slagter - Drawing Sagittal section of the eye and muscles of eye - no labels" by Ron Slagter, license: CC BY-NC-SA and "Cenveo - Drawing Muscles that Control Eye Movement - English labels" by Cenveo, license: CC BY.)*

Concept Review

Vision belongs to the special senses and its specialized organ is the eye. The bony orbits, eyelids, tarsal glands and lacrimal apparatus protect the eyes. The inner eyelid is a thin membrane known as the palpebral conjunctiva. The conjunctiva connects the eyelids to the eyeball. At the connection with the eyeball, a thin layer called the ocular conjunctiva forms a continuous layer on the external and anterior surface of the eye (except for the corneal region), superior to the white part of the eye, the sclera. The conjunctiva contains blood vessels and nerves that support the avascular sclera and detect foreign particles entering the eye.

The lacrimal apparatus is responsible for the production and drainage of lacrimal fluid (tears). Tears reduce friction of the eyelids, continuously clean the anterior surface of the eye, and prevent bacterial infection through the action of lysozyme. Tears are produced by the lacrimal gland, located within the superolateral depression of each orbit. The superior and inferior lacrimal puncta are small openings to drain the lacrimal fluid into channels called the superior and inferior lacrimal canaliculi. From there, the lacrimal fluid enters the lacrimal sac and drains into the nasolacrimal duct that delivers it into the nasal cavity where it mixes with the mucus.

There are six extraocular muscles innervated by the abducens nerve (CN VI), trochlear nerve (CN IV) and oculomotor nerve (CN III). The superior rectus elevates the eye, the medial rectus adducts the eye, the inferior rectus depresses the eye, the lateral rectus abducts the eye. The superior oblique abducts, depresses, and internally rotates (intorsion) the eye. The inferior oblique abducts, elevates, and externally rotates (extorsion) the eye.

The eye walls are made by three layers of tissue called tunics. The fibrous tunic includes the white sclera and the clear cornea. The vascular tunic composed of the choroid, ciliary body attached to the lens by suspensory ligaments and iris (colored part of the eye). The iris is composed of pigmented layers and two layers of smooth muscle called the sphincter pupillae and dilator pupillae, that open and close the pupil. The neural tunic (or retina) includes a pigmented layer and a neural layer that contains the photoreceptors. The eye is divided in two cavities: the anterior cavity between the cornea and lens, filled with aqueous humor, and the posterior cavity behind the lens, filled with vitreous humor. The retina is composed of several layers of cells, connected to each other, that support vision transduction. The photoreceptors are rods for light vision and cones for color vision. Retinal

ganglion cells have axons that collect at the optic disc and leave the eye as the optic nerve (CN II). At the exact center of the retina is a small area known as the macula lutea with a depression in the middle called the fovea. At the fovea, the retina lacks the supporting cells and blood vessels, and only contains cones. Therefore, visual acuity, or the sharpness of vision, is greatest at the fovea.

The visual pathway segregates information from the two eyes so that one half of the visual field projects to the other side of the brain. Within visual cortical areas, the perception of the stimuli and their location is passed along two streams, one ventral and one dorsal. The ventral visual stream connects to structures in the temporal lobe that are important for long-term memory formation. The dorsal visual stream interacts with the somatosensory cortex in the parietal lobe, and together they can influence the activity in the frontal lobe to generate movements of the body in relation to visual information.

Review Questions

Query 13.4.1

This interactive element is not available in this format. Visit the link or scan the QR code to access it online.

View this Interactive Content online

Critical Thinking Questions

Query 13.4.2

This interactive element is not available in this format. Visit the link or scan the QR code to access it online.

View this Interactive Content online

Glossary

Query 13.4.3

This interactive element is not available in this format. Visit the link or scan the QR code to access it online.

View this Interactive Content online

Contributors and Attributions

OpenStax Anatomy & Physiology (CC BY 4.0). Access for free at https://openstax.org/books/anatomy-and-physiology

This page titled 13.4: Vision is shared under a CC BY-NC-SA 4.0 license and was authored, remixed, and/or curated by Jennifer Lange et al..

- 13.4: Integration of Somatic Functions by Whitney Menefee, Julie Jenks, Chiara Mazzasette, and Kim-Leiloni Nguyen is licensed CC BY 4.0.
- 13.3: Hearing, Balance and Vision by Whitney Menefee, Julie Jenks, Chiara Mazzasette, and Kim-Leiloni Nguyen is licensed CC BY 4.0.

13.5: Taste and Smell

By the end of this section, you will be able to:

- Describe the gross and microscopic structures responsible for the special senses of taste and smell

Gustation (Taste)

Only a few recognized submodalities exist within the sense of taste, or **gustation**. Until recently, only four tastes were recognized: sweet, salty, sour, and bitter. Research at the turn of the 20th century led to recognition of the fifth taste, umami, during the mid-1980s. **Umami** is a Japanese word that means "delicious taste," and is often translated to mean savory. Very recent research has suggested that there may also be a sixth taste for fats, or lipids.

Gustation is the special sense associated with the tongue. The surface of the tongue, along with the rest of the oral cavity, is lined by a stratified squamous epithelium. Raised bumps called **papillae** (singular = papilla) contain the structures for gustatory transduction. There are four types of papillae, based on their appearance (Figure 13.5.2): circumvallate, foliate, filiform, and fungiform. Within the structure of the papillae are **taste buds** that are recessed into a **taste pore** and resemble the shape of an onion. Taste buds contain a variety of cells that support and regenerate the taste bud structure. Specialized **gustatory receptor cells** have microvilli called **taste hairs** that can absorb the chemicals contained within foods that are ingested and then release neurotransmitters based on the amount of the specific chemical in the food. These cells are not neurons, but they are in contact with the dendrites of sensory neurons.

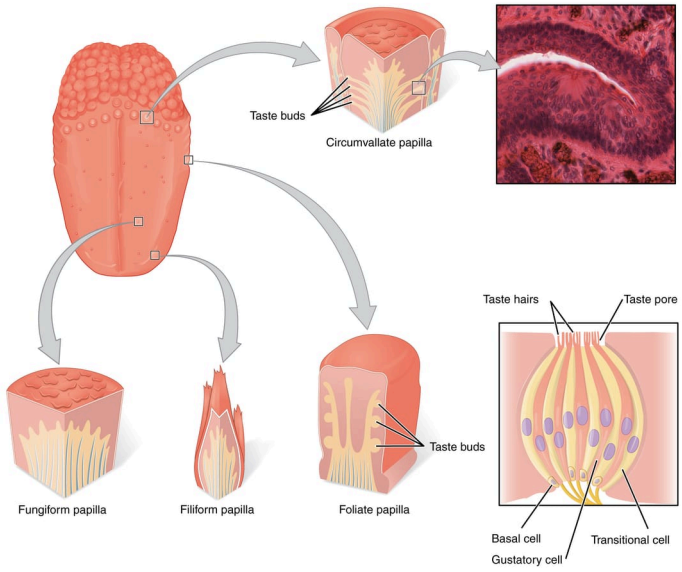

Figure 13.5.2: The Tongue. The tongue is covered with small bumps, called papillae, which contain taste buds that are sensitive to chemicals in ingested food or drink. Different types of papillae are found in different regions of the tongue. Taste buds within the papillae have a recessed taste pore and contain three types of cells: specialized gustatory receptor cells, basal cells and transitional cells. LM × 1600. (Image Credit: "The Tongue" by OpenStax is licensed under CC BY 4.0/Micrograph provided by the Regents of University of Michigan Medical School © 2012)

Once the gustatory cells are activated by the taste molecules, they release neurotransmitters onto the dendrites of sensory neurons. These neurons are part of the facial (CN VII) and glossopharyngeal (CN IX) cranial nerves, as well as a component within the vagus nerve (CN X) dedicated to the gag reflex. The facial nerve connects to taste buds in the anterior third of the tongue. The glossopharyngeal nerve connects to taste buds in the posterior two thirds of the tongue. The vagus nerve connects to taste buds in the extreme posterior of the tongue, verging on the pharynx, which are more sensitive to noxious stimuli such as bitterness. Gustatory information is then transmitted through these cranial nerves to the brain, through the **thalamus**, which acts as a relay station, and finally into the **primary gustatory cortex** of the **insula**. It is here that this information is processed and perception is initiated.

Novel studies have shown that gustatory cells are not only present on the tongue but also in the guts. In humans, sweet, umami and bitter taste cells are also present in the intestines and used to "taste" the ingested food and regulate its variations.

Olfaction (Smell)

Like taste, the sense of smell, or **olfaction**, is also responsive to chemical stimuli. Inhaled air containing **odorant molecules** (smells) enters the nasal cavity and passes by the nasal conchae. The **olfactory receptor neurons (ORNs)** are located in a small region within the superior nasal cavity (Figure 13.5.3). This region is referred to as the **olfactory epithelium** and also contains **supporting cells** and **basal cells** (not shown), with similar functions as the homonyms in the taste buds. Each olfactory receptor neuron has dendrites that extend from the apical surface of the epithelium into the mucus lining the cavity. **Olfactory glands** within the basal lamina at the interface between the olfactory epithelium and the superior connective tissue produce the mucus that lines the olfactory epithelium, The olfactory sensory neurons present nonmotile cilia called **olfactory cilia** (or hairs) that contain the chemoreceptor for a specific odorant molecule. As airborne molecules are inhaled through the nose, they pass over the olfactory epithelial region and dissolve into the mucus. These odorant molecules bind to proteins that keep them dissolved in the mucus and help transport them to the olfactory dendrites. The odorant–protein complex binds to a receptor protein within the cell membrane of an olfactory dendrite, producing an electrical change in the olfactory neurons.

The axon of an olfactory neuron extends from the basal surface of the epithelium towards the cribriform plate of the ethmoid bone forming the **olfactory nerve (CN I)**. The olfactory fibers go through an olfactory foramen in the cribriform plate and converge to form spherical structures called **glomeruli** in the **olfactory bulb**, which resides on the ventral surface of the frontal lobe. Within the glomeruli, the olfactory receptor neurons synapse with mitral cells which in turn extend their axons to form the **olfactory tract**. From there, the axons split to travel to several brain regions. Some travel to the cerebrum, specifically to the **primary olfactory cortex** that is located in the inferior and medial areas of the temporal lobe. Others project to structures within the limbic system and hypothalamus, where smells become associated with long-term memory and emotional responses. This is how certain smells trigger emotional memories, such as the smell of food associated with one's birthplace. Smell is the one sensory modality that does not synapse in the thalamus before connecting to the cerebral cortex. This intimate connection between the olfactory system and the cerebral cortex is one reason why smell can be a potent trigger of memories and emotion.

The olfactory system can recognize seven primary odors (musky, putrid, pungent, camphoraceous, ethereal, floral, peppermint) as well as thousands of odorant molecules that produce various scents. The nasal epithelium, including the olfactory cells, can be harmed by airborne toxic chemicals. Therefore, the olfactory neurons are one of the few types of neurons that undergo mitosis and is able to replace old cells. Olfactory neurons are regularly replaced within the nasal epithelium, after which the axons of the new neurons must find their appropriate connections in the olfactory bulb. These new axons grow along the axons that are already in place in the cranial nerve.

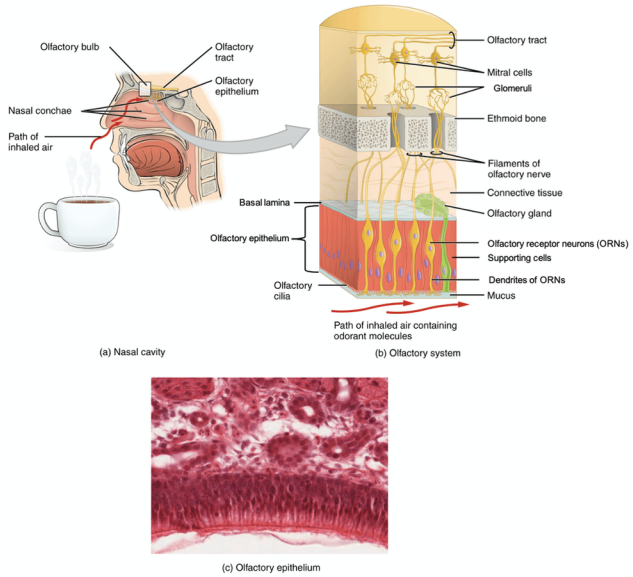

Figure 13.5.3: The Olfactory System. In (a), inhaled air passes by the nasal conchae to reach the olfactory epithelium in the superior nasal cavity. In (b), the olfactory epithelium is composed of olfactory receptor neurons and supporting cells. The dendrites of olfactory receptors neurons contain olfactory cilia that are embedded in the mucus lining the nasal cavity. The mucus is produced by olfactory glands located at the basal lamina. Axons of olfactory receptor neurons extend into the connective tissue and through the cribriform plate of the ethmoid bone, to synapse onto mitral cells in the glomeruli of the olfactory bulb. Axons of mitral cells extend towards the brain to form the olfactory tract. In (c), an histological slide (tissue source: simian) shows the olfactory epithelium. LM × 812. (Image Credit: "Olfactory System" by Chiara Mazzasette is licensed under CC BY 4.0 / A derivative from the original work)

DISORDERS OF THE...

Olfactory System: Anosmia

Blunt force trauma to the face, such as that common in many car accidents, can lead to the loss of the olfactory nerve, and subsequently, loss of the sense of smell. This condition is known as anosmia. When the frontal lobe of the brain moves relative to the ethmoid bone, the olfactory tract axons may be sheared apart. Professional fighters often experience anosmia because of repeated trauma to face and head. In addition, certain pharmaceuticals, such as antibiotics, can cause anosmia by killing all the olfactory neurons at once. If no axons are in place within the olfactory nerve, then the axons from newly formed olfactory neurons have no guide to lead them to their connections within the olfactory bulb. There are temporary causes of anosmia, as well, such as those caused by inflammatory responses related to respiratory infections or allergies.

Loss of the sense of smell can result in food tasting bland. A person with an impaired sense of smell may require additional spice and seasoning levels for food to be tasted. Anosmia may also be related to some presentations of mild depression, because the loss of enjoyment of food may lead to a general sense of despair.

The ability of olfactory neurons to replace themselves decreases with age, leading to age-related anosmia. This explains why some elderly people salt their food more than younger people do. However, this increased sodium intake can increase blood volume and blood pressure, increasing the risk of cardiovascular diseases in the elderly.

Concept Review

Somatosensation belongs to the general senses, which are those sensory structures that are distributed throughout the body and in the walls of various organs. Gustation and olfaction belong to the special senses. Gustation transduction is achieved by raised bumps on the tongue called papillae that contain taste buds, which in turn contain specialized gustatory receptor cells for chemical stimuli (”tastes”). Olfactory receptor neurons (unipolar) located in olfactory epithelium respond to chemical stimuli (“odorants”) of the nasal cavity. Their dendrites extend from the apical surface of the epithelium into the mucus lining the cavity and have receptors for odorants. Axons extend into the cribriform plate of the ethmoid bone to reach the olfactory bulb, forming

the olfactory nerve (CN I). Once the olfactory nerve crosses the CNS, it becomes the olfactory tract and sends axons to several brain regions. The axons do not synapse onto the thalamus (unlike the other special senses).

Review Questions

Query 13.5.1

This interactive element is not available in this format. Visit the link or scan the QR code to access it online.

View this Interactive Content online

Glossary

Query 13.5.2

This interactive element is not available in this format. Visit the link or scan the QR code to access it online.

View this Interactive Content online

Contributors and Attributions

OpenStax Anatomy & Physiology (CC BY 4.0). Access for free at https://openstax.org/books/anatomy-and-physiology

This page titled 13.5: Taste and Smell is shared under a CC BY-NC-SA 4.0 license and was authored, remixed, and/or curated by Jennifer Lange et al..

- 13.2: Touch, Taste and Smell by Whitney Menefee, Julie Jenks, Chiara Mazzasette, and Kim-Leiloni Nguyen is licensed CC BY 4.0.

13.6: Anatomical Atlas - Somatic Senses

A compendium of anatomical images: slides, models, and/or cadavers.

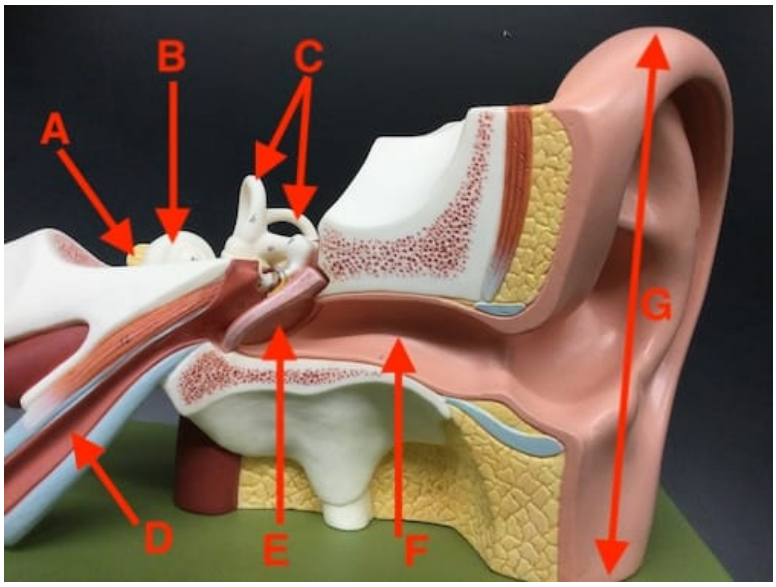

Image Credit

"Ear Model - Atlas" by Jennifer Lange is licensed under CC BY-NC-SA 4.0.

Answer Key (click to show/ hide answers)

A - Vestibulocochlear nerve (CN VIII)

B - cochlea

C - semicircular canals

D - auditory (Eustachian) tube

E - tympanic membrane

F - external auditory canal

G - auricle

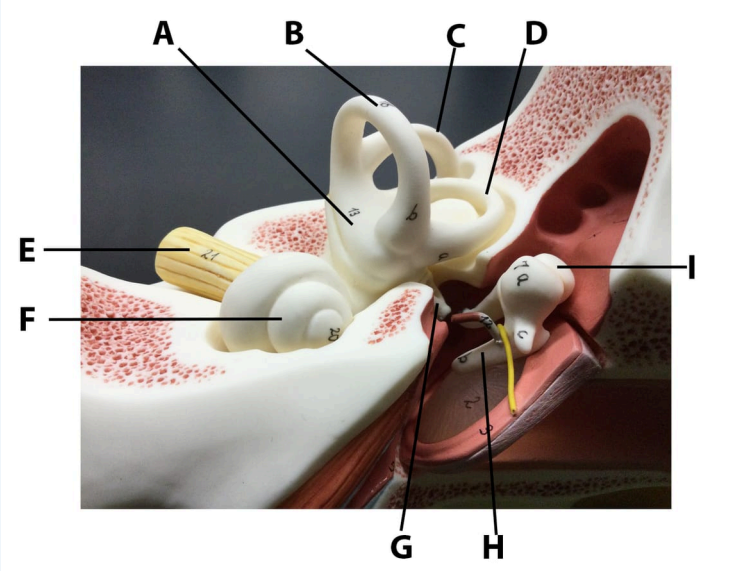

Image Credit

"Middle and Inner Ear Model - Atlas" by Jennifer Lange is licensed under CC BY-NC-SA 4.0.

Answer Key (click to show/ hide answers)

A - vestibule

B - anterior semicircular canal

C - posterior semicircular canal

D - horizontal semicircular canal

E - CN VIII, vestibulocochlear nerve

F - cochlea

G - stapes

H - malleus

I - incus

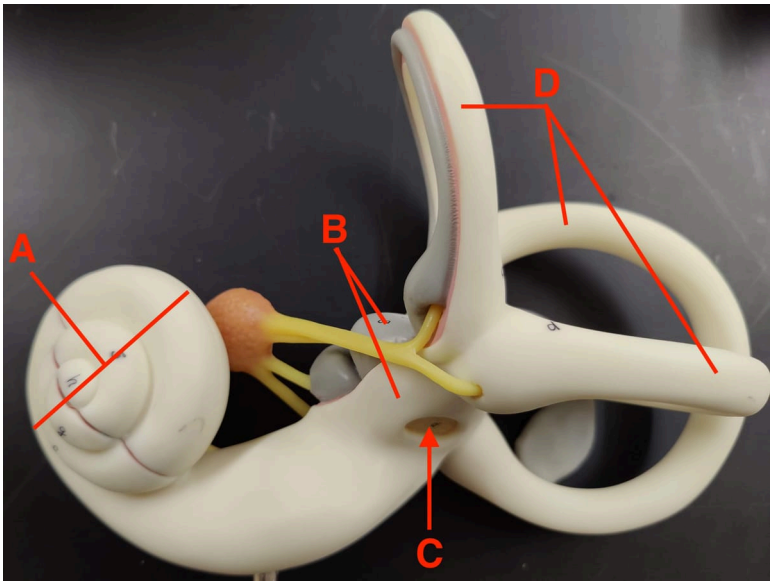

Image Credit

"Inner Ear Model - Atlas" by Jennifer Lange is licensed under CC BY-NC-SA 4.0.

Answer Key (click to show/ hide answers)

A - cochlea

B - vestibule

C - oval window

D - semicircular canals

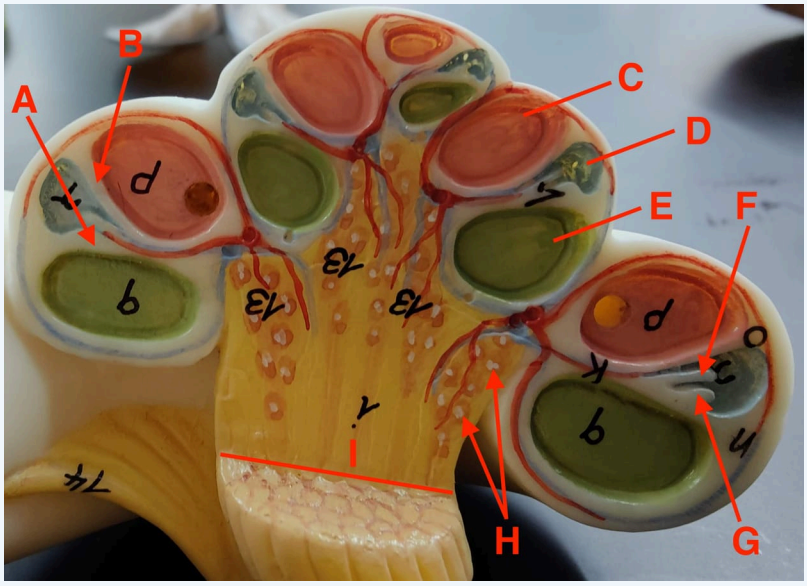

Image Credit

"Cochlear Model - Atlas" by Jennifer Lange is licensed under CC BY-NC-SA 4.0.

Answer Key (click to show/ hide answers)

A - basilar membrane

B - vestibular membrane

C - vestibular duct

D - cochlear duct

E - tympanic duct

F - tectorial membrane

G - hair cells

H - spiral ganglia

I - cochlear nerve (cochlear branch of CN VIII)

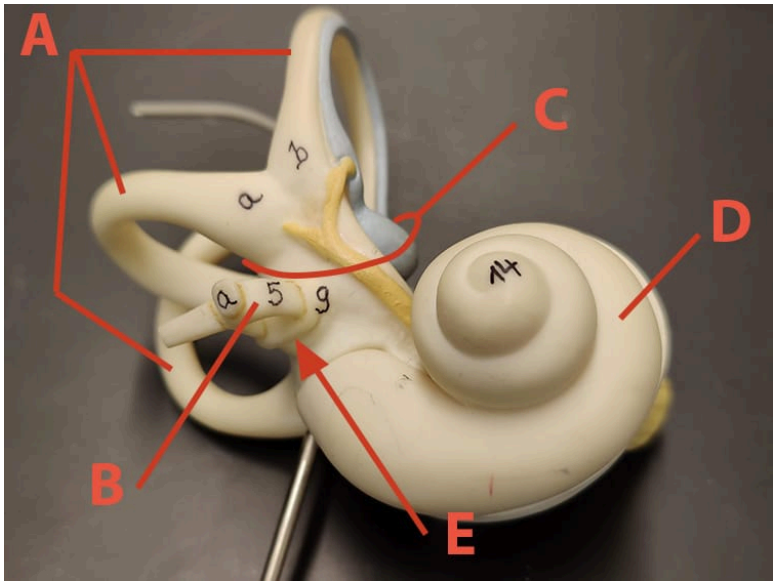

Image Credit

"Small Inner Ear Model - Atlas" by Jennifer Lange is licensed under CC BY-NC-SA 4.0.

Answer Key (click to show/ hide answers)

A - semicircular canals

B - stapes

C - vestibule

D - cochlea

E - oval window

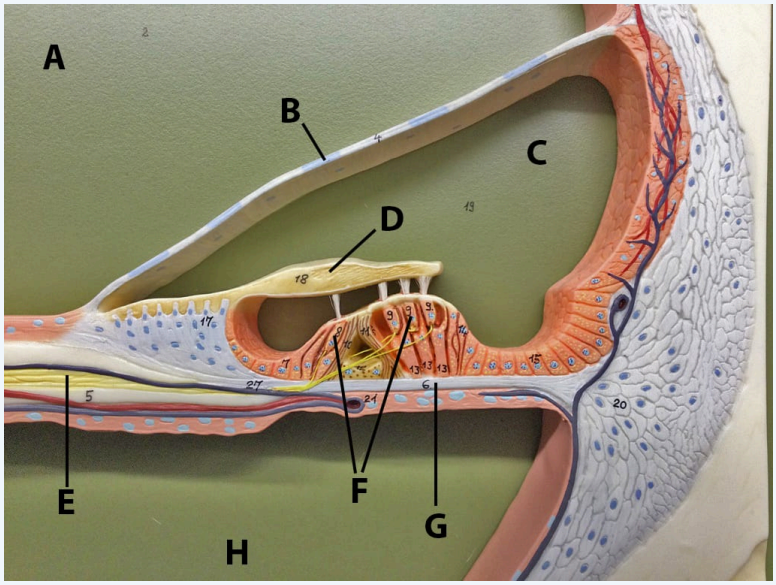

Image Credit

"Cochlear Spiral Model - Atlas" by Jennifer Lange is licensed under CC BY-NC-SA 4.0.

Answer Key (click to show/ hide answers)

A - vestibular duct

B - vestibular membrane

C - cochlear duct

D - tectorial membrane

E - dendrites of bipolar neurons

F - hair cells

G - basilar membrane

H - tympanic duct

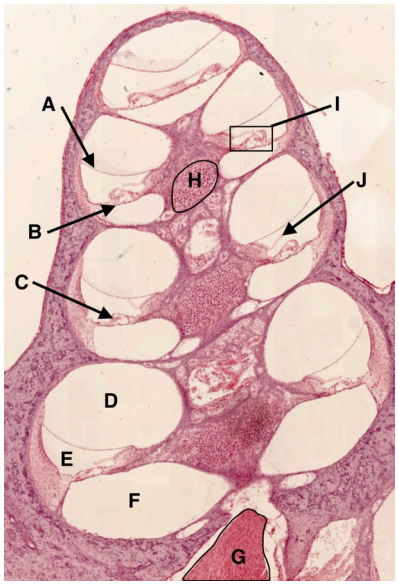

Image Credit

"Cochlear Histology - Atlas" by Jennifer Lange is licensed under CC BY-NC-SA 4.0, slide provided by the Regents of the University of Michigan Medical School © 2022.

Answer Key (click to show/ hide answers)

A - vestibular membrane

B - basilar membrane

C - hair cells

D - vestibular duct

E - cochlear duct

F - tympanic duct

G - cochlear branch of vestibulocochlear nerve (CN VIII)

H - spiral ganglion

I - spiral organ (organ of Corti)

J - tectorial membrane

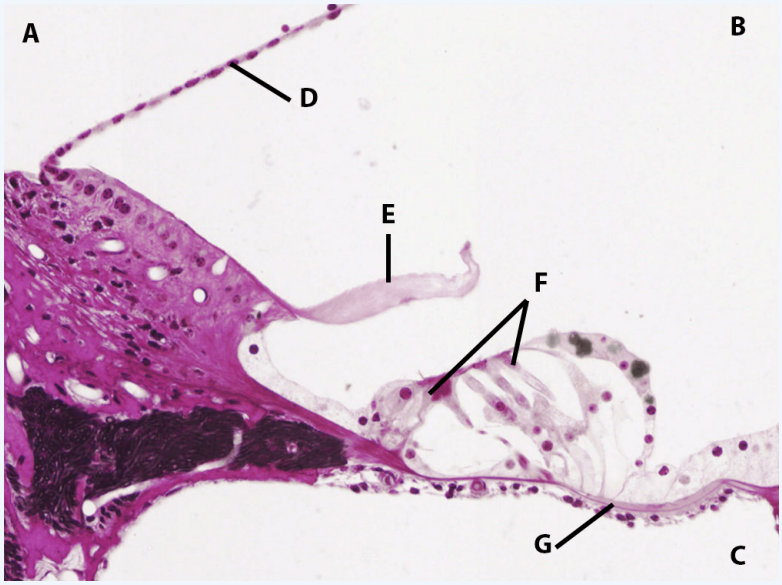

Image Credit

"Spiral Organ Histology - Atlas" by Jennifer Lange is licensed under CC BY-NC-SA 4.0, slide provided by the Regents of the University of Michigan Medical School © 2022.

Answer Key (click to show/ hide answers)

A - vestibular duct

B - cochlear duct

C - tympanic duct

D - vestibular membrane

E - tectorial membrane

F - hair cells

G - basilar membrane

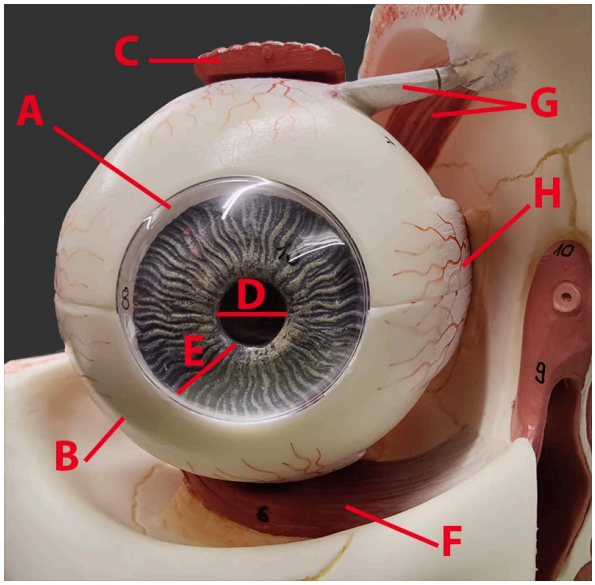

Image Credit

"Eye in Orbit Model Anterior View- Atlas" by Jennifer Lange is licensed under CC BY-NC-SA 4.0.

Answer Key (click to show/ hide answers)

A - cornea

B - sclera

C - levator palpebrae superioris muscle

D - pupil

E - iris

F - inferior oblique muscle

G - superior oblique muscle

H - medial rectus muscle

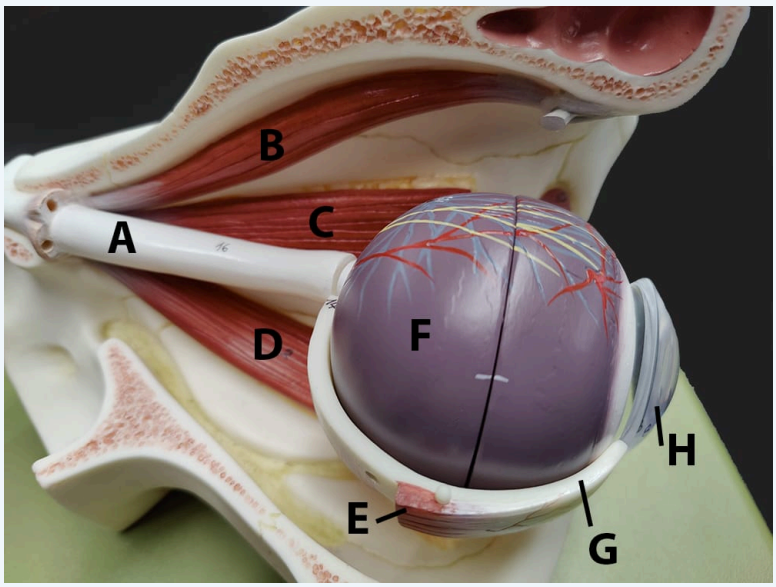

Image Credit

"Eye in Orbit Model Superior Lateral View - Atlas" by Jennifer Lange is licensed under CC BY-NC-SA 4.0.

Answer Key (click to show/ hide answers)

A - optic nerve; CN II

B - superior oblique muscle

C - medial rectus muscle

D - inferior rectus muscle

E - lateral rectus muscle

F - choroid

G - sclera

H - cornea

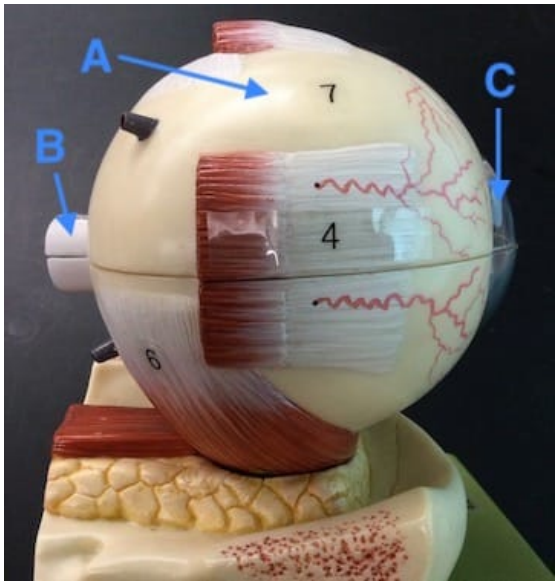

Image Credit

"Lateral View of Eye Model - Atlas" by Jennifer Lange is licensed under CC BY-NC-SA 4.0.

Answer Key (click to show/ hide answers)

A - sclera

B - optic nerve; CN II

C - cornea

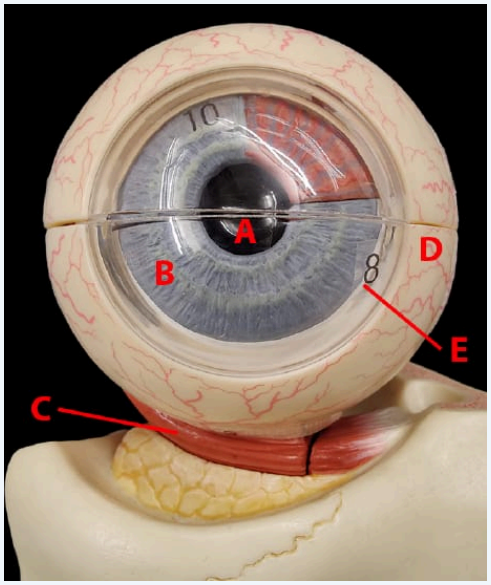

Image Credit

"Anterior View of Eye Model - Atlas" by Jennifer Lange is licensed under CC BY-NC-SA 4.0.

Answer Key (click to show/ hide answers)

A - pupil

B - iris

C - inferior rectus

D - sclera

E - cornea

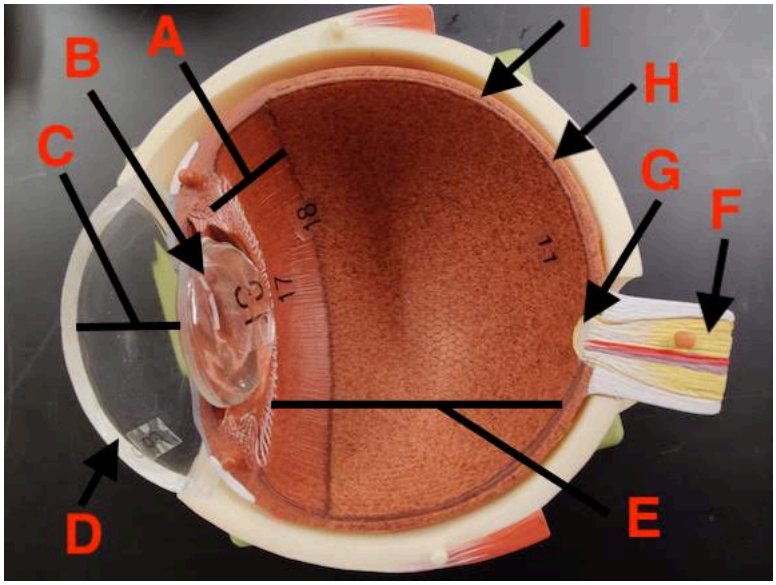

Image Credit

"Interior View of Eye Model - Atlas" by Jennifer Lange is licensed under CC BY-NC-SA 4.0.

Answer Key (click to show/ hide answers)

A - ciliary body

B - lens

C - anterior cavity

D - cornea

E - posterior cavity

F - optic nerve (CN II)

G - optic disc

H - retina

I - choroid

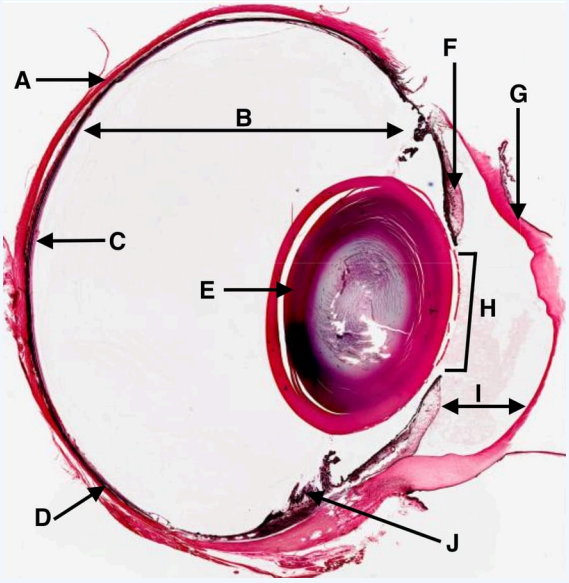

Image Credit

"Human Eye Histology - Atlas" by Jennifer Lange is licensed under CC BY-NC-SA 4.0, modification of "eye human", license: CC BY-NC-SA.

Answer Key (click to show/ hide answers)

A - sclera

B - posterior cavity

C - retina

D - choroid

E - lens

F - iris

G - cornea

H - pupil

I - anterior cavity

J - ciliary muscle (body)

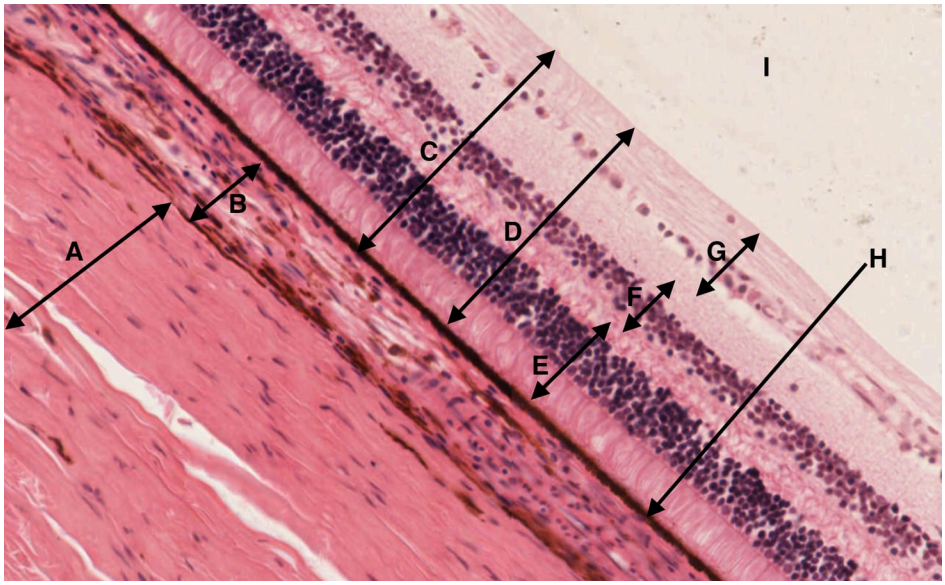

Image Credit

"Eye Wall Histology - Atlas" by Jennifer Lange is licensed under CC BY-NC-SA 4.0, slide provided by the Regents of the University of Michigan Medical School © 2022.

Answer Key (click to show/ hide answers)

A - sclera

B - choroid

C - retina

D - neural retina

E - photoreceptor layer - rods and cones

F - bipolar cell layer

G - ganglion cell layer

H - pigmented epithelium

I - posterior cavity



Image Credit

"Retina Model - Atlas" by Jennifer Lange is licensed under CC BY-NC-SA 4.0.

Answer Key (click to show/ hide answers)

A - ganglion cell layer

B - bipolar cell layer

C - photoreceptor layer

D - pigmented epithelium

E - choroid

F - sclera

G - rod

H - cone

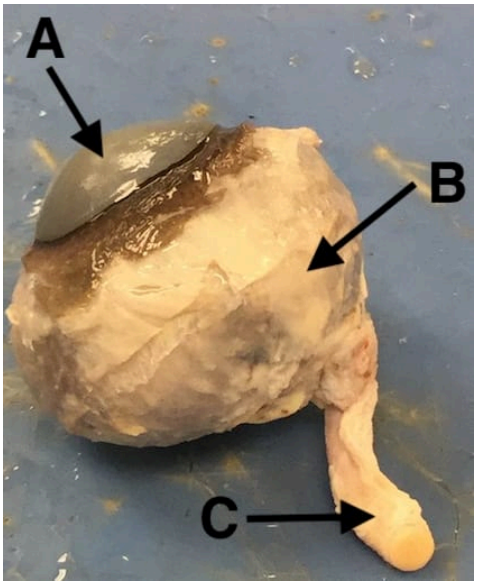

Image Credit

"Cow Eye Dissected - Exterior - Atlas" by Jennifer Lange is licensed under CC BY-NC-SA 4.0.

Answer Key (click to show/ hide answers)

A - cornea

B - sclera

C - optic nerve (CN II)



Image Credit

"Cow Eye Dissected - Interior, Anterior - Atlas" by Jennifer Lange is licensed under CC BY-NC-SA 4.0.

Answer Key (click to show/ hide answers)

A - sclera

B - iris

C - ciliary body

D - cornea

E - pupil

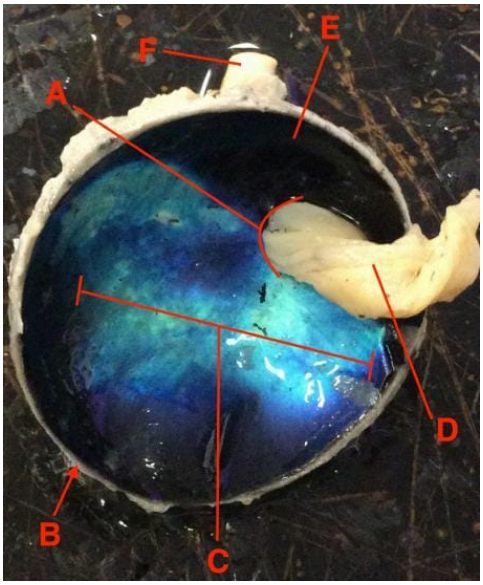

Image Credit

"Cow Eye Dissected - Interior, Posterior - Atlas" by Jennifer Lange is licensed under CC BY-NC-SA 4.0.

Answer Key (click to show/ hide answers)

A - optic disc

B - sclera

C - tapetum lucidum

D - retina

E - choroid

This page titled 13.6: Anatomical Atlas - Somatic Senses is shared under a CC BY-NC-SA 4.0 license and was authored, remixed, and/or curated by Jennifer Lange et al..

13.7: Practice Practical - Somatic Senses

Query 13.7.1

This interactive element is not available in this format. Visit the link or scan the QR code to access it online.

View this Interactive Content online

This interactive element is not available in this format. Visit the link or scan the QR code to access it online.

View this Interactive Content online

This interactive element is not available in this format. Visit the link or scan the QR code to access it online.

View this Interactive Content online

This interactive element is not available in this format. Visit the link or scan the QR code to access it online.

View this Interactive Content online

This interactive element is not available in this format. Visit the link or scan the QR code to access it online.

View this Interactive Content online

This interactive element is not available in this format. Visit the link or scan the QR code to access it online.

View this Interactive Content online

This interactive element is not available in this format. Visit the link or scan the QR code to access it online.

View this Interactive Content online

This interactive element is not available in this format. Visit the link or scan the QR code to access it online.

View this Interactive Content online

This interactive element is not available in this format. Visit the link or scan the QR code to access it online.

View this Interactive Content online

This interactive element is not available in this format. Visit the link or scan the QR code to access it online.

View this Interactive Content online

This interactive element is not available in this format. Visit the link or scan the QR code to access it online.

View this Interactive Content online

This interactive element is not available in this format. Visit the link or scan the QR code to access it online.

View this Interactive Content online

This page titled 13.7: Practice Practical - Somatic Senses is shared under a CC BY-NC-SA 4.0 license and was authored, remixed, and/or curated by Jennifer Lange et al..

14: AUTONOMIC NERVOUS SYSTEM

The autonomic nervous system (ANS) controls cardiac and smooth muscle, as well as glandular tissue, to maintain homeostasis when the body is at rest or in an emergency. It is associated with unconscious responses to regulate heart rate, blood pressure, body temperature, sweating and digestion. It can be divided into two divisions: the sympathetic divisions maintains homeostasis in conditions of "fight-or-flight" while the parasympathetic division maintains homeostasis when the body is at rest. In this chapter, you will look at the structures of the two divisions of the ANS, their reflexes and the control on the ANS exercised by the central nervous system.

14.1: Introduction to the Autonomic Nervous System

14.2: Divisions of the Autonomic Nervous System

14.3: Autonomic Synapses and Effects

14.4: Central Control of Autonomic Function

14.5: Anatomical Atlas - Autonomic Nervous System

14.6: Practice Practical - ANS

This page titled 14: Autonomic Nervous System is shared under a CC BY-NC-SA 4.0 license and was authored, remixed, and/or curated by Jennifer Lange et al..

- 14: Autonomic Nervous System by Whitney Menefee, Julie Jenks, Chiara Mazzasette, and Kim-Leiloni Nguyen is licensed CC BY 4.0.

14.1: Introduction to the Autonomic Nervous System

Chapter Learning Objectives

After studying this chapter, you will be able to:

- Describe the components of the autonomic nervous system
- Differentiate between the structures of the sympathetic and parasympathetic divisions in the autonomic nervous system
- Name the components of a visceral reflex specific to the autonomic division to which it belongs
- Describe how the central nervous system coordinates and contributes to autonomic functions

The autonomic nervous system is often associated with the “fight-or-flight response,” which refers to the preparation of the body to either run away from a threat or to stand and fight in the face of that threat. To suggest what this means, consider the (very unlikely) situation of seeing a lioness hunting out on the savannah. Though this is not a common threat that humans deal with in the modern world, it represents the type of environment in which the human species thrived and adapted. The reactions modern humans have in the modern world are based on these prehistoric situations. If your boss is walking down the hallway on Friday afternoon looking for “volunteers” to come in on the weekend, your response is the same as the prehistoric human seeing the lioness running across the savannah: fight or flight. Most likely, your response to your boss—not to mention the lioness—would be flight. Run away! The autonomic system is responsible for the physiological response to make that possible, and hopefully successful. Adrenaline starts to flood your circulatory system. Your heart rate increases. Sweat glands become active. The bronchi of the lungs dilate to allow more air exchange. Pupils dilate to increase visual information. Blood pressure increases in general, and blood vessels dilate in skeletal muscles. Time to run. Similar physiological responses would occur in preparation for fighting off the threat.

This response should sound a bit familiar. The autonomic nervous system is tied into emotional responses as well, and the fight-or-flight response probably sounds like a panic attack. In the modern world, these sorts of reactions are associated with anxiety as much as with response to a threat. It is engrained in the nervous system to respond like this. In fact, the adaptations of the autonomic nervous system probably predate the human species and are likely to be common to all mammals, and perhaps shared by many animals. That lioness might herself be threatened in some other situation. However, the autonomic nervous system is not just about responding to threats. Besides the fight-or-flight response, there are the responses referred to as “rest and digest.” If a lioness is successful in her hunting, then she is going to rest from the exertion. Her heart rate will slow. Breathing will return to normal. The digestive system has a big job to do. Much of the function of the autonomic system is based on the connections within an autonomic, or visceral, reflex.

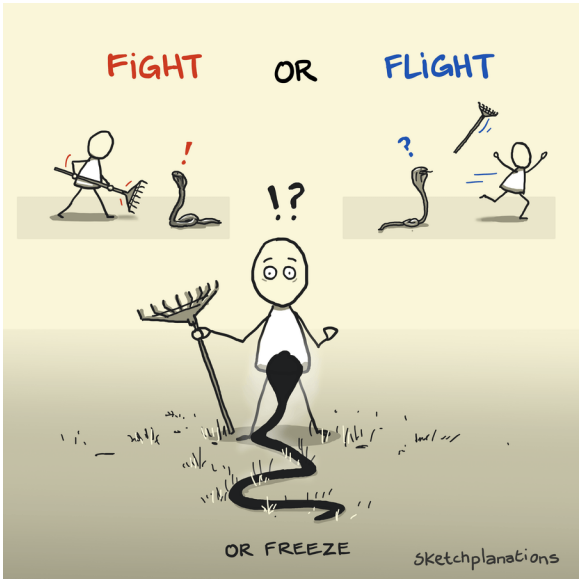

Figure 14.1.1: Fight or Flight? How does the body respond when threatened? Whether we run away, fight the foe, or stay still, our autonomic nervous system rapidly places they body systems on high alert. Encountering a snake and speaking in public both are stimuli that trigger the automatic response. *(Image credit: "Fight or Flight" by Sketchplanations is licensed under CC BY-NC 4.0.)*

Contributors and Attributions

OpenStax Anatomy & Physiology (CC BY 4.0). Access for free at https://openstax.org/books/anatomy-and-physiology

This page titled 14.1: Introduction to the Autonomic Nervous System is shared under a CC BY-NC-SA 4.0 license and was authored, remixed, and/or curated by Jennifer Lange et al..

- 14.1: Introduction to the Autonomic Nervous System by Whitney Menefee, Julie Jenks, Chiara Mazzasette, and Kim-Leiloni Nguyen is licensed CC BY 4.0.

14.2: Divisions of the Autonomic Nervous System

By the end of this section, you will be able to:

- Compare and contrast the somatic and autonomic nervous systems
- Describe the functional differences between the sympathetic and parasympathetic divisions
- Outline the anatomical differences between the two divisions of the ANS
- Describe the preganglionic neurons, ganglia, nerves and pathways of the two divisions of the ANS

Comparison between the Somatic and Autonomic Nervous System

The nervous system can be divided into two functional parts: the **somatic nervous system (SNS)** and the **autonomic nervous system (ANS)**. The major difference between these two systems is based on whether you are conscious of its process. The somatic nervous system consciously detects sensory stimuli from the special senses, skin and proprioceptors. The autonomic nervous system reflexively responds to visceral sensory stimuli, such as levels of carbon dioxide concentration in the blood or stretch caused by blood pressure, that you are not consciously aware of. Moreover, the motor efferent branches of these two systems innervate different **target effectors**. While the somatic motor neurons innervate and cause contraction of skeletal muscles, autonomic motor neurons innervate and control cardiac and smooth muscle, as well as glandular tissue. Thus, the motor response of the somatic nervous system is voluntary while the one of the autonomic nervous system is involuntary.

Another major difference between these two systems lies within the number of lower motor neurons that are involved in the response. In the somatic nervous system, a single lower somatic motor neuron of the brainstem or spinal cord extends from the CNS towards a skeletal muscle through a cranial or spinal nerve, respectively (Figure 14.2.1). These somatic motor neurons have large myelinated axons that release acetylcholine (ACh) at neuromuscular junctions.

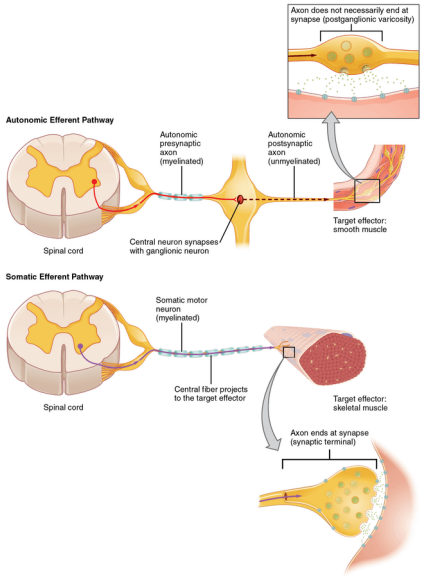

Figure 14.2.1: Comparison of Somatic and Visceral Motor Pathways. The somatic motor pathway has a single efferent neuron between the CNS and the target effector organ whereas the visceral motor pathway has two efferent neurons. *(Image credit: "Comparison of Somatic and Visceral Motor Pathways" by Jennifer Lange, with muscle by Justin Greene, is licensed under CC BY-NC-SA 4.0, modification of original by OpenStax College, CC BY 3.0, via Wikimedia Commons.)*

In comparison, the autonomic nervous system is composed of a chain of two lower motor neurons (Figure 14.2.1). The cell body of the first of the two ANS motor neurons is located in the brainstem or spinal cord and is called a **preganglionic neuron**. The axon of the preganglionic neuron extends outside of the CNS through cranial or spinal nerves forming a **preganglionic fiber**. This fiber projects to an **autonomic ganglion** of the peripheral nervous system. Preganglionic neurons have small myelinated axons that release acetylcholine (ACh) to excite a second motor neuron. The second motor neuron is called a **ganglionic neuron**.

The cell body of the ganglionic neuron resides within the autonomic ganglion and its axon extends to an effector (cardiac muscle, smooth muscle, or gland) forming a **postganglionic fiber**. Ganglionic neurons have small unmyelinated axons that release either acetylcholine (ACh) or norepinephrine (NE) to either excite or inhibit an effector, depending on the type of receptors present on the effector. The differences between the somatic motor and visceral motor systems are summarized in Table 14.2.1.

Table* 14.2.1*: Comparison of Somatic and Visceral Motor Systems

Feature	Somatic Motor	Visceral Motor
Type of control	Voluntary	Involuntary
Number of neurons in pathway	One: extends from CNS to effector	Two: preganglionic from CNS to ganglion; postganglionic from ganglion to effector
Ganglia	None	Autonomic ganglia: sympathetic chain ganglia, intramural or terminal
Effectors	Skeletal muscle fibers	Smooth muscle fibers, cardiac muscle, glands
Effector response	Excitation	Excitation or inhibition
Neurotransmitter(s) released	Acetylcholine (Ach)	Preganglionic: Acetylcholine (Ach) Postganglionic: Acetylcholine (Ach) or norepinephrine (NE)
Myelination	Myelinated	Preganglionic: myelinated Postganglionic: unmyelinated
Simplified Pathway	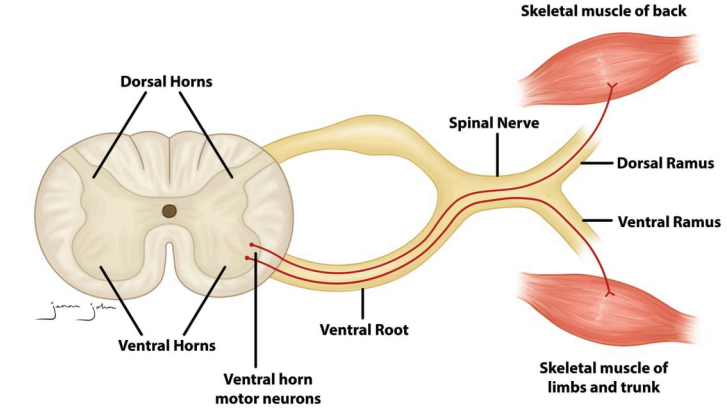 *(Image credit: "Somatic Motor Pathway" by Gabrielle Spurlock is licensed under CC BY-NC-SA 4.0, modification of original by BlueLink licensed under CC BY-NC 4.0 with notification of the original authors.)*	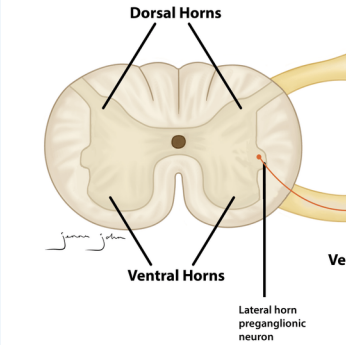 *(Image credit: "Autonomic Motor licensed under CC BY-NC-SA 4.0 by BlueLink licensed under CC B original authors.)*

Divisions of the Autonomic Nervous System

The autonomic nervous system regulates many of the internal organs through a balance of two aspects, or divisions. The two divisions of the autonomic nervous system are the **sympathetic division** and the **parasympathetic division**. From a functional point of view, the sympathetic system is associated with the **fight-or-flight response**, while the parasympathetic activity is

referred to by the epithet **rest-and-digest**. Homeostasis is the balance between the two divisions since one system complements the other. For example, the parasympathetic division will be more active when you need to conserve energy and replenish nutrient stores. The sympathetic division will activate when during exercise, stress or emergency situations. Many autonomic target effectors have dual innervation by both divisions of the autonomic nervous system, which determines their activity. For example, the heart receives connections from both the sympathetic and parasympathetic divisions: one causes heart rate to increase, whereas the other causes heart rate to decrease. From an anatomical point of view, both divisions use preganglionic and ganglionic neurons to innervate cardiac muscle, smooth muscle and glands. However, the location of preganglionic neurons within the CNS is different between the two divisions. Moreover, the location of the ganglia as well as the length of preganglionic and postganglionic axons differ in the two divisions. In the following sections, you will examine the functional and anatomical features of the sympathetic and parasympathetic divisions.

Sympathetic Division

To respond to a threat—to fight or to run away—the sympathetic system causes diverse effects as many different effector organs are activated together for a common purpose. More oxygen needs to be inhaled and delivered to skeletal muscle. The respiratory, cardiovascular, and musculoskeletal systems are all activated together. Additionally, sweating keeps the excess heat that comes from muscle contraction from causing the body to overheat. The digestive system shuts down so that blood is not absorbing nutrients when it should be delivering oxygen to skeletal muscles. To coordinate all these responses, the connections in the sympathetic system diverge from a limited region of the central nervous system (CNS) to a wide array of ganglia that project to the many effector organs simultaneously. The complex set of structures that compose the output of the sympathetic system make it possible for these disparate effectors to come together in a coordinated, systemic change.

The sympathetic division of the autonomic nervous system influences various organ systems of the body through connections emerging from the first thoracic (T1) and second lumbar (L2) spinal segments (Figure 14.2.2). It is referred to as the **thoracolumbar system** to reflect this anatomical basis. Sympathetic preganglionic neurons are located in the lateral horns of any of these spinal regions and project to ganglia adjacent to the vertebral column through the anterior roots of the spinal cord.

Sympathetic Neurons, Ganglia and Nerves

The majority of ganglia of the sympathetic system belong to a network of **sympathetic chain (or trunk) ganglia** that runs lateral to the vertebral column (Figure 14.2.2). For this reason, these ganglia can also be called **paravertebral ganglia**. The ganglia appear as a series of clusters of neurons linked by ascending and descending axonal bridges called **sympathetic trunks**. There are typically 23 ganglia in the sympathetic chain on either side of the spinal column. Three correspond to the cervical region, 12 are in the thoracic region, four are in the lumbar region, and four correspond to the sacral region. The thoracic and lumbar sympathetic preganglionic fibers travel sequentially through ventral roots, spinal nerves and bundles of myelinated axons called **white rami communicans** (singular = ramus communicans) to reach the correspondent paravertebral ganglia (Figure 14.2.2). Here preganglionic sympathetic fibers either synapse with ganglionic neurons or often pass on through the sympathetic chain ganglion into one of its emerging nerves to synapse with ganglionic neurons elsewhere. Postganglionic fibers then travel through additional nerves to their destination in one of the organs. Many of the fibers from the postganglionic neurons in the sympathetic chain ganglia pass back into the spinal nerves through **gray rami communicans** composed of unmyelinated axons and carry sympathetic information through the spinal nerves.

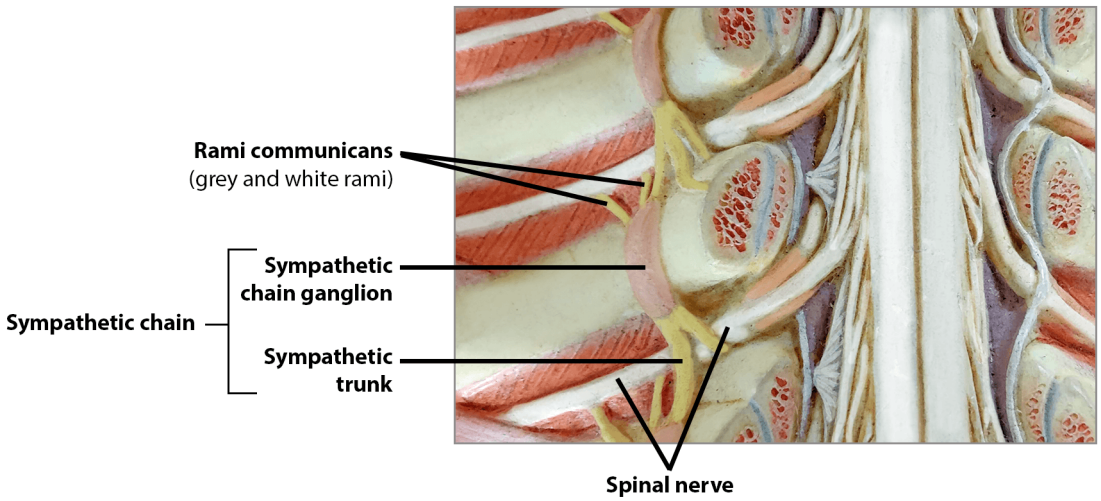

Figure 14.2.2: Sympathetic Chain. The sympathetic chain is a series of ganglia connected to each other by the sympathetic trunks. They are connected to the spinal nerve by the rami communicans. (*Image credit: "Spinal Cord and Spinal Nerve Branching - ANS" by Jennifer Lange is licensed under CC BY-NC 4.0.*)

The cervical and sacral paravertebral ganglia are not connected to the spinal cord directly through the spinal nerves, but through sympathetic trunks. Among the cervical ganglia, the **superior cervical ganglion** contains ganglionic neurons that innervate structures of the head and neck such the dilator pupillae and superior tarsal muscles of the eye, the lacrimal gland, mucous membranes of the nose, palate and mouth, and salivary glands. The **middle and inferior cervical ganglia** contain ganglionic neurons that innervate neck and thoracic organs such as the larynx, trachea, pharynx, smooth muscle of arteries and heart.

Preganglionic sympathetic axons extending from T5-L2 do not synapse in a sympathetic chain ganglion and instead continue through the chain anteriorly towards the abdominal and pelvic organs (Figure 14.2.3). These axons typically terminate in three autonomic ganglia called **prevertebral (or collateral) ganglia:** the **celiac ganglion,** the **superior mesenteric ganglion**, and the **inferior mesenteric ganglion**. They are referred to as prevertebral because they are anterior to the vertebral column and descending aorta. The prevertebral ganglia are associated with controlling organs in the abdominal cavity, and are also considered part of the enteric nervous system.

The neurons of the sympathetic autonomic ganglia are multipolar in shape, with dendrites radiating out around the cell body where synapses from the spinal cord neurons are made. Because the sympathetic ganglia are adjacent to the vertebral column, preganglionic sympathetic fibers are relatively short, and they are myelinated. Compared with the preganglionic fibers, postganglionic sympathetic fibers are long because of the relatively greater distance from the ganglion to the target effector. These postganglionic fibers are unmyelinated. A diagram that shows the connections of the sympathetic system is somewhat like a circuit diagram that shows the electrical connections between different receptacles and devices. In Figure 14.2.3, the neural pathways of the sympathetic system are intentionally simplified.

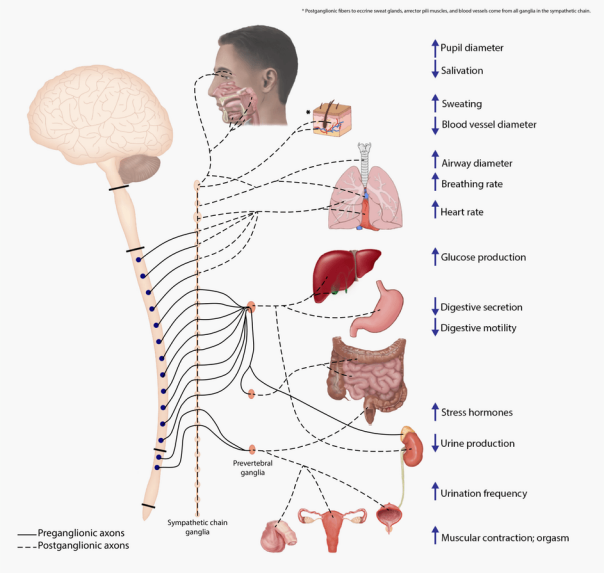

Figure 14.2.3: Sympathetic Innervation. Neurons from the lateral horns of the spinal cord extend their preganglionic nerve fibers (solid lines) to the sympathetic chain ganglia on the lateral sides of the vertebral column. Axons may terminate here or pass through and terminate in prevertebral (collateral) ganglia that are anterior to the vertebral column. Axons from the ganglionic neurons, called postganglionic nerve fibers (dashed lines), then project to target effectors throughout the body. *(Image credit: "ANS - Sympathetic Division Innervation" by Jennifer Lange is licensed under CC BY-NC-SA 4.0. Image incorporates originals from Functional Neuroanatomy, KnowledgeWorks, Patrick J. Lynch, and Ron Slagter.)*

Sympathetic Pathways

A sympathetic preganglionic axon leaving the lateral horn of the thoracolumbar spinal cord enters the sympathetic chain ganglia, where it branches toward 10-20 targets. To continue with the analogy of the circuit diagram, there are four different types of "junctions" that connect the sympathetic preganglionic axons with their effectors. The type of pathway is determined by the location and type of target effector organ being innervated. In all cases, the preganglionic axon extends into the spinal nerve at the same level as its spinal cord segment. Then it can then either

1. synapse in the paravertebral ganglion and carry information through the spinal nerve at the same level (spinal nerve pathway),
2. ascend to a more superior or descend to a more inferior paravertebral ganglion, synapse there and carry information through sympathetic nerves (sympathetic nerve pathway),
3. descend to a prevertebral (collateral) ganglion, synapse there and carry information through a splanchnic nerve (splanchnic nerve pathway), or
4. project directly to the adrenal medulla (adrenal medulla pathway).

All of these branches mean that one preganglionic neuron can influence different regions of the sympathetic system very broadly, by acting on widely distributed organs. In the following paragraphs, you will examine these four different pathways. Except for the adrenal medulla pathway, these connections are represented in Figure 14.2.4.

The **spinal nerve pathway** is the most direct connection. The sympathetic preganglionic nerve projects to the sympathetic chain ganglion at the same level as the target effector. The myelinated preganglionic fiber extending from the lateral horns of the spinal cord projects to the sympathetic chain ganglion through the ventral root and spinal nerve. Through the white ramus communicans, the fiber reaches and synapses with the ganglionic neuron in the sympathetic chain ganglion. The postganglionic fiber then projects to the target effector via the gray ramus communicans, which is formed by unmyelinated axons. An example of this type is spinal nerve T1 that synapses with the T1 sympathetic chain ganglion to innervate the skin (Figure 14.2.4.a). Indeed, this pathway generally innervates integumentary structures such as sweat glands, arrector pili muscles, and blood vessels of the skin in the neck, torso and limbs.

The **postganglionic sympathetic nerve pathway** occurs when the target effectors are located superior or inferior to the spinal segment at which the sympathetic preganglionic fiber emerges. With respect to the "wiring" involved, the synapse with the ganglionic neuron occurs at sympathetic chain ganglia superior or inferior to the location of the preganglionic neuron. In order to do this, the preganglionic fiber travels through sympathetic trunks to reach the superior or inferior sympathetic chain ganglion.

The postganglionic fiber does not leave the ganglion through the gray ramus communicans. Instead, it extends away from the ganglion through a sympathetic nerve. An example of this is spinal nerve T1 that innervates the eye. The spinal nerve tracks up through the sympathetic trunks until it reaches the superior cervical ganglion, where it synapses with the ganglionic neuron and projects to the eye through a sympathetic nerve (Figure 14.2.4.b). This pathway innervates viscera of head (sweat glands, arrector pili muscles, blood vessels of the skin; dilator pupillae, tarsal muscle and gland of the eye; salivary glands) and neck, and thoracic organs such as esophagus, heart, lungs, thoracic blood vessels.

Not all axons from the central neurons terminate in the sympathetic chain ganglia. The **splanchnic nerve pathway** include branches from the ventral nerve root that continue through the sympathetic chain ganglion and on to one of the prevertebral (collateral) ganglia as the greater splanchnic nerve or lesser splanchnic nerve. For example, the greater splanchnic nerve at the level of T5 synapses with a prevertebral (collateral) ganglion outside the sympathetic chain before making the connection to the postganglionic nerves that innervate the stomach (Figure 14.2.4.c). This pathway innervates abdominopelvic organs such as stomach, intestines, kidneys, ureters, urinary bladder and reproductive organs.

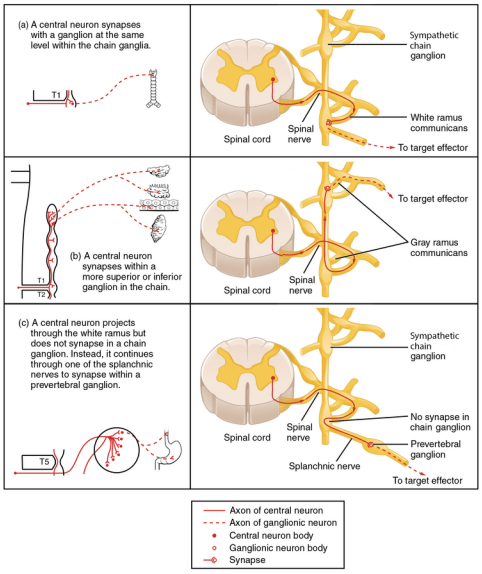

Figure 14.2.4: Sympathetic Pathways. The axon from a central sympathetic neuron in the spinal cord can project to the periphery in a number of different ways. (a) represents the spinal nerve pathway where the preganglionic fiber projects out and synapses onto a ganglionic neuron at the same level which then carries the information out through the spinal nerve. (b) represents the postganglionic sympathetic nerve pathway where a preganglionic branch projects and synapses onto a more superior or inferior ganglion in the chain which then carries the information out through a sympathetic nerve. (c) represents the splanchnic nerve pathway where a preganglionic branch extends through the white ramus communicans, but does not terminate on a ganglionic neuron in the chain. Instead, it projects through one of the splanchnic nerves to a prevertebral (collateral) ganglion. *(Image credit: "Sympathetic Pathways" by OpenStax is licensed under CC BY 4.0, modification by Jennifer Lange.)*

There is one additional way that preganglionic sympathetic fibers can control their effector organs and it is through the **adrenal medulla pathway**. In this unique pathway the preganglionic fiber does not terminate in a ganglion but instead projects to the **adrenal medulla**, the interior portion of the adrenal gland (Figure 14.2.5). These axons are still referred to as preganglionic fibers, but the target is not a ganglion per se. The cells in the adrenal medulla that are contacted by the preganglionic fibers are neurosecretory cells that develop from the neural crest along with the sympathetic chain ganglia. These cells in the adrenal medulla release epinephrine and norepinephrine into the bloodstream, rather than using axons to communicate with target structures. This hormonal component means that the sympathetic chemical signal can spread throughout the body very quickly and affect many organ systems at once. At the same time, these hormones remain in the bloodstream longer than neurotransmitters, prolonging the sympathetic effects.

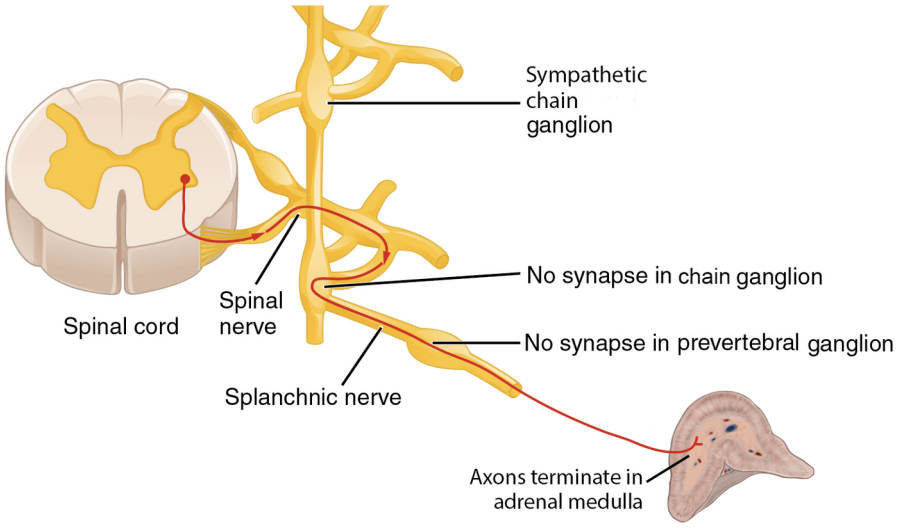

Figure 14.2.5: Sympathetic Adrenal Medulla Pathway. Preganglionic axons from the lateral horns project through the sympathetic ganglia and terminate directly onto cells in the medulla of the adrenal gland. *(Image credit: "Sympathetic Adrenal Medulla Pathway" by Jennifer Lange is licensed under CC BY-NC-SA 4.0, modification of original by OpenStax.)*

Parasympathetic Division

The parasympathetic division of the autonomic nervous system is named because its central neurons are located away from (para- = “apart from”) the thoracolumbar region of the spinal cord which is dedicated to the sympathetic division. Indeed, the parasympathetic system can also be referred to as the **craniosacral system** because the preganglionic neurons are located in nuclei of the brainstem and the lateral horn of the sacral spinal cord (S2 to S4). In Figure 14.2.6, the neural pathways of the parasympathetic system are intentionally simplified.

Parasympathetic Neurons, Ganglia and Nerves

The connections, or “circuits,” of the parasympathetic division are similar to the general layout of the sympathetic division with a few specific differences. The parasympathetic preganglionic fibers from the cranial region travel in cranial nerves, whereas parasympathetic preganglionic fibers from the sacral region travel in spinal nerves. The targets of these fibers are **terminal ganglia**, which are located near the target effector, and **intramural ganglia**, which are found within the walls of the target organ. Terminal ganglia receive input from cranial nerves or sacral spinal nerves. The terminal ganglia that receive input from cranial nerves are found in the head and neck, as well as the thoracic and upper abdominal cavities, whereas the terminal ganglia that receive sacral input are in the lower abdominal and pelvic cavities. The postganglionic fiber projects from the terminal ganglia a short distance to the target effector, or to the specific target tissue within the organ.

The cranial nerves associated with the parasympathetic system are the oculomotor nerve (CN III), facial nerve (VII), glossopharyngeal nerve (CN IX) and vagus nerve (CN X). These nerves generate from particular nuclei of the brainstem. The remaining parasympathetic preganglionic axons originate from neurons of the lateral horns of the S2-S4 segments of the spinal cord. These axons project to terminal or intramural ganglia of pelvic organs. The specific ganglia and targets of each parasympathetic pathway are summarized in Table 14.2.2.

Table 14.2.2: Ganglia and Targets of the Parasympathetic Nerves

Nerve	Parasympathetic Ganglion	Target(s)
CN III - Oculomotor nerve	Ciliary ganglion in posterior orbit	Sphincter pupillae of iris, ciliary muscle
CN VII - Facial nerve	Pterygopalatine ganglion - posterior to maxillary sinus	Lacrimal gland, glands in nasal cavities

Nerve	Parasympathetic Ganglion	Target(s)
	Submandibular ganglion - deep to posterior mandible, superior to submandibular salivary gland	Submandibular and sublingual salivary glands
CN IX - Glossopharyngeal nerve	Otic ganglion - inferior to foramen ovale	Parotid salivary gland
CN X - Vagus nerve	Terminal and intramural ganglia - thoracic and abdominal organs, gonads	Heart, respiratory tract, digestive tract, liver, pancreas, kidneys, etc.
Spinal nerves S2-S4	Terminal and intramural ganglia - pelvic organs	Rectum, anus, urinary bladder, reproductive tracts

Comparing the relative lengths of axons in the parasympathetic system, the preganglionic fibers are long and the postganglionic fibers are short because the ganglia are close to—and sometimes within—the target effectors. Parasympathetic preganglionic axons tend to have fewer than 4 branches. The lack of divergent branches in parasympathetic preganglionic axons prevents a systemic response and facilitates discrete and localized effects on one group of organs at a time.

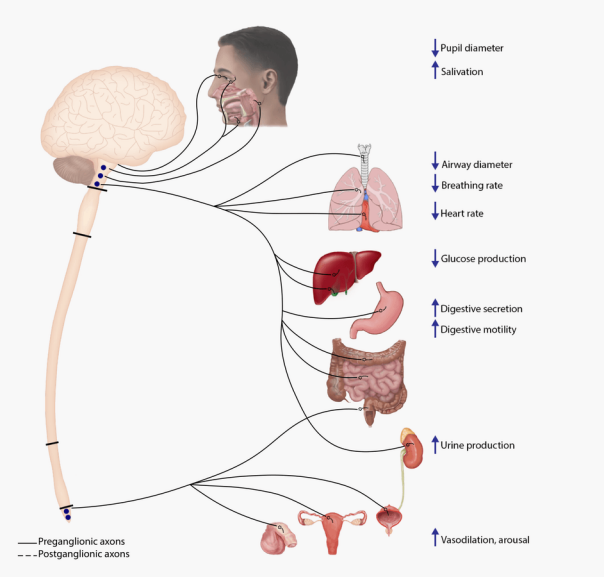

Figure 14.2.6: Parasympathetic Innervation. Neurons from brain-stem nuclei, or from the lateral horn of the sacral spinal cord, extend their preganglionic nerve fibers (shown in red) to terminal ganglia near the effector organs or to intramural ganglia within the walls of the effector organs. Postganglionic axons (shown in black) from these ganglionic neurons then project the short distance to target effectors *(Image credit: "ANS - Parasympathetic Division Innervation" by Jennifer Lange is licensed under CC BY-NC-SA 4.0. Image incorporates originals from Functional Neuroanatomy, KnowledgeWorks, Patrick J. Lynch, and Ron Slagter.)*

Everyday Connections

Fight or Flight? What About Fright and Freeze?

The original usage of the epithet “fight or flight” comes from a scientist named Walter Cannon who worked at Harvard in 1915. The concept of homeostasis and the functioning of the sympathetic system had been introduced in France in the previous century. Cannon expanded the idea, and introduced the idea that an animal responds to a threat by preparing to stand and fight or run away. The nature of this response was thoroughly explained in a book on the physiology of pain, hunger, fear, and rage.

When students learn about the sympathetic system and the fight-or-flight response, they often stop and wonder about other responses. If you were faced with a lioness running toward you, would you run or would you stand your ground? Some people would say that they would freeze and not know what to do. So isn’t there really more to what the autonomic system does than fight, flight, rest, or digest. What about fear and paralysis in the face of a threat?

> The common epithet of “fight or flight” is being enlarged to be “fight, flight, or fright” or even “fight, flight, fright, or freeze.” Cannon’s original contribution was a catchy phrase to express some of what the nervous system does in response to a threat, but it is incomplete. The sympathetic system is responsible for the physiological responses to emotional states. The name “sympathetic” can be said to mean that (sym- = “together”; -pathos = “pain,” “suffering,” or “emotion”).

Concept Review

The nervous system can be divided into two functional parts: the somatic nervous system (SNS) and the autonomic nervous system (ANS). The differences between these two systems lie on multiple features: the conscious level of their processes, their targets, the number of lower motor neurons involved and the neurotransmitters used. The autonomic nervous system reflexively responds to visceral sensory stimuli, such as levels of carbon dioxide concentration in the blood or stretch caused by blood pressure, that you are not consciously aware of and involuntarily controls cardiac and smooth muscle, as well as glandular tissue. The autonomic nervous system has a chain of two lower autonomic motor neurons. The first neuron is called a preganglionic neuron and resides in the brainstem or lateral horns of the spinal cord. This neuron releases ACh to a second neuron called a ganglionic neuron that is located in ganglia. The axons of ganglionic neurons are called postganglionic fibers. These nerves extend to target effectors and release either ACh or norepinephrine (NE).

The primary responsibilities of the autonomic nervous system are to regulate homeostatic mechanisms in the body. The way we respond to the world around us, to manage the internal environment on the basis of the external environment, is divided between two parts of the autonomic nervous system. The sympathetic division responds to threats and produces a readiness to confront the threat or to run away: the fight-or-flight response. The parasympathetic division plays the opposite role. When the external environment does not present any immediate danger, a restful mode descends on the body, and the digestive system is more active.

The sympathetic output of the nervous system originates out of the lateral horn of the thoracolumbar spinal cord. An axon from one of these central neurons projects by way of the ventral spinal nerve root, spinal nerve and white rami communicans to a sympathetic chain (paravertebral) ganglion. The preganglionic fibers can synapse on ganglionic neurons here or extend to one of the prevertebral (collateral) ganglia via the splanchnic nerves (splanchnic nerve pathway). Postganglionic fibers of sympathetic chain ganglia can either return to the spinal nerve through the gray rami communicantes (spinal nerve pathway) or extend away from the ganglion through a sympathetic nerve (postganglionic sympathetic pathway). The sympathetic system also has a specialized preganglionic connection to the adrenal medulla that causes epinephrine and norepinephrine to be released into the bloodstream rather than exciting a neuron that contacts an organ directly (adrenal medulla pathway).

The parasympathetic output is based in the brainstem and sacral spinal cord. Neurons from particular nuclei in the brainstem carry parasympathetic information through four cranial nerves: oculomotor nerve (CN III), facial nerve (VII), glossopharyngeal nerve (CN IX) and vagus nerve (CN X). In the sacral spinal cord, preganglionic neurons of the lateral horn project out through pelvic splanchnic nerves. Cranial and sacral preganglionic fibers extend to terminal and intramural ganglia located close to or within the wall of target effectors. The postganglionic fibers of the ganglionic neurons then contact the target tissues within the organ to induce rest-and-digest responses. Due to the fact that parasympathetic ganglia are either close to or within the target organ, parasympathetic preganglionic axons are longer and postganglionic axons are shorter, compared to the sympathetic division.

Review Questions

Query 14.2.1

This interactive element is not available in this format. Visit the link or scan the QR code to access it online.

View this Interactive Content online

Critical Thinking Questions

Query 14.2.2

This interactive element is not available in this format. Visit the link or scan the QR code to access it online.

View this Interactive Content online

Glossary

Query 14.2.3

This interactive element is not available in this format. Visit the link or scan the QR code to access it online.

View this Interactive Content online

Contributors and Attributions

OpenStax Anatomy & Physiology (CC BY 4.0). Access for free at https://openstax.org/books/anatomy-and-physiology

This page titled 14.2: Divisions of the Autonomic Nervous System is shared under a CC BY-NC-SA 4.0 license and was authored, remixed, and/or curated by Jennifer Lange et al..

- 14.2: Divisions of the Autonomic Nervous System by Whitney Menefee, Julie Jenks, Chiara Mazzasette, and Kim-Leiloni Nguyen is licensed CC BY 4.0.

14.3: Autonomic Synapses and Effects

By the end of this section, you will be able to:

- Describe the signaling molecules involved in communication within the two divisions of the autonomic nervous system
- Determine the effect of the autonomic nervous system on the regulation of the various organ systems
- Explain dual innervation

Autonomic Neurotransmitters

The main signaling molecules of the autonomic nervous system are **acetylcholine** (ACh) and **norepinephrine** (NE, also called noradrenaline). The adrenal medulla, which is a modified sympathetic ganglion, releases **epinephrine** (or adrenaline). Cells that release acetylcholine are called **cholinergic**, while cells that release norepinephrine or epinephrine are called **adrenergic**. These molecules will bind to specific receptors on the target cells. Acetylcholine can bind to both **nicotinic receptors** and **muscarinic receptors**. Norepinephrine and epinephrine can bind to **adrenergic receptors**. For each of these classes of receptors, there are multiple subtypes (which we will not discuss in this book) that make the cells respond differently to the binding of the same molecule. Depending on the receptor type and subtype, the molecules released will cause either stimulation or inhibition. Thus, the effects of the autonomic divisions depend on the type of signaling molecule and receptor involved.

- All preganglionic fibers, both sympathetic and parasympathetic, are cholinergic and release ACh (Table 14.3.1).
- All ganglionic neurons have nicotinic receptors in their cell membranes, which leads to the stimulation and firing of an action potential from the ganglionic fibers in both sympathetic and parasympathetic divisions.
- Most sympathetic postganglionic fibers are adrenergic and release norepinephrine.
- The adrenal medulla which is part of the sympathetic division is also adrenergic and releases epinephrine.
- Parasympathetic postganglionic fibers are cholinergic and release ACh.

This pattern assures that effector organs under the control of both sympathetic and parasympathetic systems can respond differently. Target cells can contain various types and subtypes of receptors and their response will vary depending on the type of receptor and on the neurotransmitter released on them.

Autonomic targets that are innervated by both divisions of the autonomic system respond based on which neurotransmitter is released and what receptor is present. For example, regions of the heart that establish heart rate are contacted by postganglionic fibers from both systems. If norepinephrine is released, it binds to an adrenergic receptor which causes the heart rate to increase. If ACh is released, it binds to a muscarinic receptor that causes the heart rate to slow. Without this parasympathetic input, the heart would work at a rate of approximately 100 beats per minute (bpm). The sympathetic system speeds that up, as it would during exercise, to 120–140 bpm, for example. The parasympathetic system slows it down to the resting heart rate of 60–80 bpm.

(Table 14.3.1) Comparison of Sympathetic and Parasympathetic Signaling Molecules

Feature	Sympathetic Division	Parasympathetic Division
Preganglionic axons	release ACh (cholinergic)	release ACh (cholinergic)
Ganglionic neurons	contain nicotinic (ACh) receptors	contain nicotinic (ACh) receptors
Postganglionic axons	release NE (adrenergic); release ACh (cholinergic) only in blood vessels of skeletal muscle and sweat glands	release ACh (cholinergic)
Adrenal medulla	contain muscarinic (ACh) receptors; releases epinephrine (adrenergic)	

Autonomic Effects

Organ systems are balanced between the input from the sympathetic and parasympathetic divisions. When something upsets that balance, the homeostatic mechanisms strive to return it to its regular state. For each organ system, there may be more of a sympathetic or parasympathetic tendency to the resting state. For example, the resting heart rate is the result of the parasympathetic system slowing the heart down from its intrinsic rate of 100 bpm, consequently the heart can be said to be in parasympathetic tone.

Many effector organs of the autonomic nervous system have **dual innervation**, meaning that they receive competing inputs from the sympathetic and parasympathetic divisions. These divisions each play a role in effecting change, usually in competing directions. At the level of the target effector, the signal of which system is sending the message is strictly chemical and depending on the division involved and neurotransmitter released, the effects would be diverse. For example, the heart and the eye are examples of organs with dual innervation. The sympathetic system increases heart rate, whereas the parasympathetic system decreases heart rate. The sympathetic system dilates the pupil of the eye, whereas the parasympathetic system constricts the pupil.

In some organs, opposing effects are achieved without dual innervation. For example, the arrector pili muscles, sweat glands, and blood vessels to skeletal muscles and skin are primarily under sympathetic control. Blood pressure is partially determined by the contraction of smooth muscle in the walls of blood vessels. The parasympathetic system has no significant input to the systemic blood vessels, so the sympathetic system determines their tone. The sympathetic system causes vasoconstriction of blood vessels. However, the increasing metabolic activity of muscles causes (paracrine) vasodilation. This allows for blood flow to increase for those skeletal muscles that will be active in the fight-or-flight response.

Not always the sympathetic and parasympathetic divisions have opposite effects and, in a few cases, the two systems cooperate. The best example of cooperative effects occurs in the male sexual function. In reproductive organs, blood vessels of erectile tissues are innervate with parasympathetic projection, making them an exception. Acetylcholine released by these postganglionic parasympathetic fibers cause the vessels to dilate, leading to the engorgement of the erectile tissue and penile erection. At the same time, the sympathetic nervous system stimulates ejaculation by causing the contractions of the seminal vesicle and prostate gland. This synergistic effect facilitates reproduction. Table 14.3.2 summarizes the effects on different organs of the sympathetic and parasympathetic divisions.

Table 14.3.2 Effects of Sympathetic and Parasympathetic Divisions

Target Effector	Sympathetic Effect	Parasympathetic Effect
Arrector pili muscles	Contraction to cause hair erection	None
Sweat glands	Secretion	None
Salivary glands	Inhibits	Stimulates
Pupils	Dilation	Constriction
Ciliary muscle	None	Contraction for near vision
Heart	Increases heart rate	Decreases heart rate
Blood vessels of the heart (coronary)	Vasoconstriction or vasodilation	Vasodilation
Blood vessels to skeletal muscles	Vasodilation	None
Blood vessels to skin and other organs	Vasoconstriction to increase blood pressure	None
Blood vessels to gastrointestinal (GI) tract	Vasoconstriction	Vasodilation
Bronchi of lungs	Dilation	Constriction
Gastrointestinal (GI) tract gland secretion	Inhibits	Stimulates
Gallbladder	Inhibits	Stimulates
Peristalsis (motility)	Inhibits	Stimulates
Sphincters	Contraction (close)	Relaxation (open)
Urinary bladder	Relaxation	Contraction

Target Effector	Sympathetic Effect	Parasympathetic Effect
Internal urethral sphincter	Contraction (close)	Relaxation (open)
Penis	Stimulates ejaculation	Stimulates erection
Clitoris	None	Stimulates erection

DISORDERS OF THE...

Nervous System: Kehr's Sign

Kehr's sign is the presentation of pain in the left shoulder, chest, and neck regions following rupture of the spleen. The spleen is in the upper-left abdominopelvic quadrant, but the pain is more in the shoulder and neck. How can this be? The sympathetic fibers connected to the spleen are from the celiac ganglion, which would be from the mid-thoracic to lower thoracic region whereas parasympathetic fibers are found in the vagus nerve, which connects in the medulla of the brainstem. However, the neck and shoulder would connect to the spinal cord at the mid-cervical level of the spinal cord. These connections do not fit with the expected correspondence of visceral and somatosensory fibers entering at the same level of the spinal cord.

The incorrect assumption would be that the visceral sensations are coming from the spleen directly. In fact, the visceral fibers are coming from the diaphragm. The nerve connecting to the diaphragm takes a special route. The phrenic nerve is connected to the spinal cord at cervical levels 3 to 5. The motor fibers that make up this nerve are responsible for the muscle contractions that drive ventilation. These fibers have left the spinal cord to enter the phrenic nerve, meaning that spinal cord damage below the mid-cervical level is not fatal by making ventilation impossible. Therefore, the visceral fibers from the diaphragm enter the spinal cord at the same level as the somatosensory fibers from the neck and shoulder.

The diaphragm plays a role in Kehr's sign because the spleen is just inferior to the diaphragm in the upper-left quadrant of the abdominopelvic cavity. When the spleen ruptures, blood spills into this region. The accumulating hemorrhage then puts pressure on the diaphragm. The visceral sensation is actually in the diaphragm, so the referred pain is in a region of the body that corresponds to the diaphragm, not the spleen

Concept Review

All preganglionic fibers are cholinergic and release acetylcholine (ACh). All ganglionic neurons (the targets of these preganglionic fibers) have nicotinic receptors in their cell membranes. Most sympathetic postganglionic fibers are adrenergic and release norepinephrine. The adrenal medulla which is part of the sympathetic division is also adrenergic and releases epinephrine. Parasympathetic postganglionic fibers are cholinergic and release ACh. Target cells can contain various types and subtypes of receptors and their response will vary depending on the type of receptor and on the neurotransmitter released on them. The sympathetic postganglionic fibers that contact the blood vessels within skeletal muscle and sweat glands in the integument release ACh instead of norepinephrine. This does not create any problem because there is no parasympathetic input to these organs.

For each organ system, there may be more of a sympathetic or parasympathetic tendency to the resting state, which is known as the autonomic tone of the system. Many effector organs of the autonomic nervous system have dual innervation, meaning that they receive competing inputs from the sympathetic and parasympathetic divisions. The sympathetic system increases heart rate, whereas the parasympathetic system decreases heart rate. The sympathetic system dilates the pupil of the eye, whereas the parasympathetic system constricts the pupil. The competing inputs can contribute to the resting tone of the organ system. Heart rate is normally under parasympathetic tone, whereas blood pressure is normally under sympathetic tone. The heart rate is slowed by the autonomic system at rest, whereas blood vessels retain a slight constriction at rest. In a few systems of the body, the competing input from the two divisions is not the norm. The sympathetic tone of blood vessels is caused by the lack of parasympathetic input to the systemic circulatory system. Only certain regions receive parasympathetic input that relaxes the smooth muscle wall of the blood vessels. Sweat glands are another example of organs that only receive input from the sympathetic

system. Not always the sympathetic and parasympathetic divisions have opposite effects and, in a few cases, the two systems cooperate.

Critical Thinking Questions

Query 14.3.1

This interactive element is not available in this format. Visit the link or scan the QR code to access it online.

View this Interactive Content online

Glossary

Query 14.3.2

This interactive element is not available in this format. Visit the link or scan the QR code to access it online.

View this Interactive Content online

Contributors and Attributions

OpenStax Anatomy & Physiology (CC BY 4.0). Access for free at https://openstax.org/books/anatomy-and-physiology

This page titled 14.3: Autonomic Synapses and Effects is shared under a CC BY-NC-SA 4.0 license and was authored, remixed, and/or curated by Jennifer Lange et al..

- 14.3: Autonomic Synapses, Effects and Reflexes by Whitney Menefee, Julie Jenks, Chiara Mazzasette, and Kim-Leiloni Nguyen is licensed CC BY 4.0.

14.4: Central Control of Autonomic Function

By the end of this section, you will be able to:

- Describe the role of higher centers of the brain in autonomic regulation
- Explain how the hypothalamus exercises autonomic control
- Explain how the amygdala influences the autonomic function
- Describe the function of the medulla and the pathways important to descending control of the autonomic system

Autonomic control is based on the visceral reflexes, composed of the afferent and efferent branches. These homeostatic mechanisms are based on the balance between the two divisions of the autonomic system, which results in tone for various organs that is based on the predominant input from the sympathetic or parasympathetic systems. Coordinating that balance requires integration that begins with brain structures like the hypothalamus and continues into the brainstem and spinal cord.

Central Control of Autonomic Reflexes

The autonomic nervous system is controlled and influenced by the cerebral cortex, hypothalamus, limbic system, medulla oblongata and spinal cord. The **hypothalamus** is the control center for many homeostatic mechanisms, as it regulates both autonomic function and endocrine function. The hypothalamus receives visceral and somatic sensory input as well as information related to emotions from the limbic system. Stimulation of specific regions within the hypothalamus result in parasympathetic effects such as slowing of the heart, constriction of the pupil, and salivary secretion. On the other hand, stimulation other hypothalamic regions results in sympathetic effects such as increased in heart rate and blood pressure, pupillary dilation, and the fight-or-flight response. Axons from both regions project to autonomic nuclei within the brainstem and the spinal cord to maintain homeostasis.

Pupillary Reflexes

The optic nerve projects primarily to the thalamus, which is the necessary relay to the occipital cortex for conscious visual perception. Another projection of the optic nerve, however, goes to the hypothalamus. The hypothalamus then uses this visual system input to drive the pupillary reflexes. If the retina is activated by high levels of light, the hypothalamus stimulates the parasympathetic response which stimulates the circular fibers of the iris to contract and constrict the pupil. If the optic nerve message shows that low levels of light are falling on the retina, the hypothalamus activates the sympathetic response which dilates the pupil (Figure 14.4.1). When light hits the retina in one eye, both pupils contract. When that light is removed, both pupils dilate again back to the resting position. When the stimulus is unilateral (presented to only one eye), the response is bilateral (both eyes). The same is not true for somatic reflexes. If you touch a hot radiator, you only pull that arm back, not both. Central control of autonomic reflexes is different than for somatic reflexes.

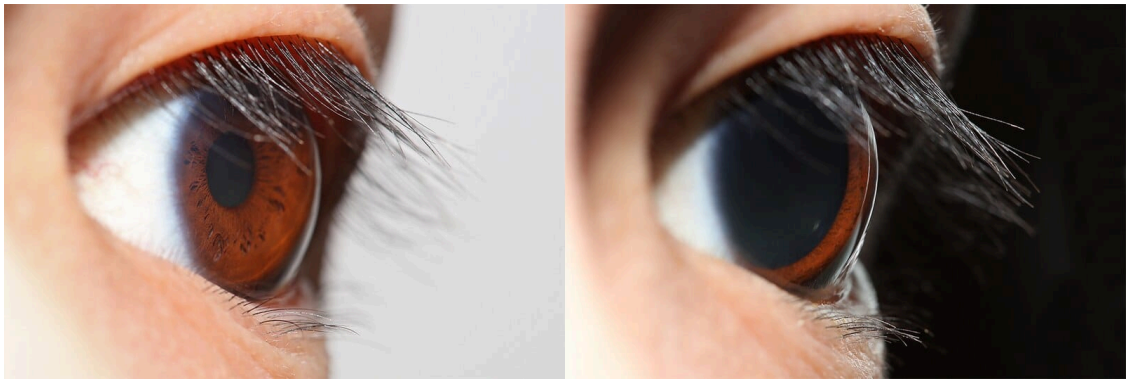

Figure 14.4.1: Pupillary Light Reflex. Three-quarter views of an Asian male human eye, taken consecutively in well lit (left) and dim (right) environments to illustrate pupil size changes in dark adaptation. The pupil measured 3mm on the left, and 9mm on the right. *(Image credit: "Pupillary light reflex" by RapidReflex is licensed under CC BY-SA 4.0.)*

Fight-or-Flight

The **amygdala** is a group of nuclei in the medial region of the temporal lobe that is part of the limbic system. The amygdala sends signals to the hypothalamus indicating various forms of stress (psychological, physical, or physiologic) and the hypothalamus will stimulate the sympathetic fight-or-flight response. The hypothalamus will also stimulate the release of stress hormones through its control of the endocrine system in response to amygdala input.

Cardiovascular Center

Has your heart ever "skipped a beat" at the surprise appearance of someone you love? Your heart does not literally miss a contraction, but its rate does increase and decrease in response to stimuli that trigger feelings of surprise, excitement, and fear. The medulla oblongata contains nuclei referred to as the **cardiovascular center**, which controls the smooth and cardiac muscle of the cardiovascular system through autonomic connections. When descending inputs from the hypothalamus stimulate this area, the sympathetic system can increase activity in the cardiovascular system by making your heart beat faster and stronger and by increasing blood pressure in the arteries. When all is calm and stress is low, the hypothalamus signals the motor nucleus for the parasympathetic functions ascribed to the vagus nerve to decrease the heart rate and decrease blood pressure.

EVERYDAY CONNECTIONS

Exercise and the Autonomic System

In addition to its association with the fight-or-flight response and rest-and-digest functions, the autonomic system is responsible for certain everyday functions. For example, it comes into play when homeostatic mechanisms dynamically change, such as the physiological changes that accompany exercise. Getting on the treadmill and putting in a good workout will cause the heart rate to increase, breathing to be stronger and deeper, sweat glands to activate, and the digestive system to suspend activity. These are the same physiological changes associated with the fight-or-flight response, but there is nothing chasing you on that treadmill.

This is not a simple homeostatic mechanism at work because “maintaining the internal environment” would mean getting all those changes back to their set points. Instead, the sympathetic system has become active during exercise so that your body can cope with what is happening. A homeostatic mechanism is dealing with the conscious decision to push the body away from a resting state. The heart, actually, is moving away from its homeostatic set point. Without any input from the autonomic system, the heart would beat at approximately 100 bpm, and the parasympathetic system slows that down to the resting rate of approximately 70 bpm. But in the middle of a good workout, you should see your heart rate at 120–140 bpm. You could say that the body is stressed because of what you are doing to it. Homeostatic mechanisms are trying to keep blood pH in the normal range, or to keep body temperature under control, but those are in response to the choice to exercise.

Concept Review

The autonomic system integrates sensory information and higher cognitive processes to generate output, which balances homeostatic mechanisms. The central autonomic structure is the hypothalamus, which coordinates sympathetic and parasympathetic efferent pathways to regulate activities of the organ systems of the body. The majority of hypothalamic output travels through the medial forebrain bundle and the dorsal longitudinal fasciculus to influence brainstem and spinal components of the autonomic nervous system. The medial forebrain bundle also connects the hypothalamus with higher centers of the limbic system where emotion can influence visceral responses. The amygdala is a structure within the limbic system that influences the hypothalamus in the regulation of the autonomic system, as well as the endocrine system.

These higher centers have descending control of the autonomic system through brainstem centers, primarily in the medulla, such as the cardiovascular center. This collection of medullary nuclei regulates cardiac function, as well as blood pressure. Sensory input from the heart, aorta, and carotid sinuses project to these regions of the medulla. The solitary nucleus increases sympathetic tone of the cardiovascular system through the cardiac accelerator and vasomotor nerves. The nucleus ambiguus and the dorsal motor nucleus both contribute fibers to the vagus nerve, which exerts parasympathetic control of the heart by decreasing heart rate.

Review Questions

Query 14.4.1

This interactive element is not available in this format. Visit the link or scan the QR code to access it online.

View this Interactive Content online

Critical Thinking Questions

Query 14.4.2

This interactive element is not available in this format. Visit the link or scan the QR code to access it online.

View this Interactive Content online

Query 14.4.3

This interactive element is not available in this format. Visit the link or scan the QR code to access it online.

View this Interactive Content online

Glossary

Query 14.4.4

This interactive element is not available in this format. Visit the link or scan the QR code to access it online.

View this Interactive Content online

Contributors and Attributions

OpenStax Anatomy & Physiology (CC BY 4.0). Access for free at https://openstax.org/books/anatomy-and-physiology

This page titled 14.4: Central Control of Autonomic Function is shared under a CC BY-NC-SA 4.0 license and was authored, remixed, and/or curated by Jennifer Lange et al..

- 14.4: Central Control Autonomic Function by Whitney Menefee, Julie Jenks, Chiara Mazzasette, and Kim-Leiloni Nguyen is licensed CC BY 4.0.

14.5: Anatomical Atlas - Autonomic Nervous System

A compendium of anatomical images: slides, models, and/or cadavers.

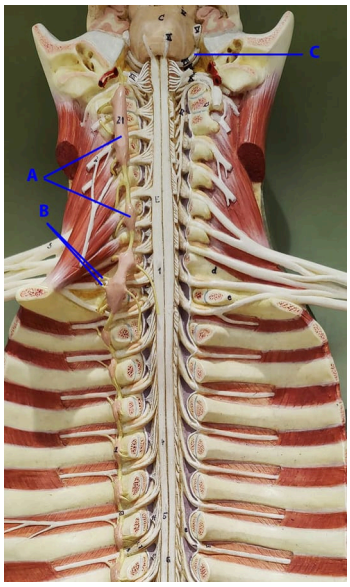

Image Credit

"Spinal Cord in Canal Model - ANS structures" by Jennifer Lange is licensed under CC BY-NC-SA 4.0.

Answer Key (click to show/hide answers)

A - sympathetic chain ganglia

B - rami communicans (grey and white rami)

C - Facial nerve (CN VII)

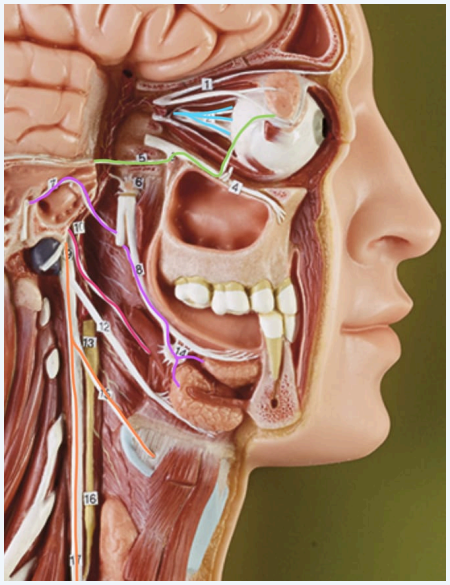

Image Credit

"Parasympathetic Nerve Pathways" by Jennifer Lange is licensed under CC BY-NC-SA 4.0.

Answer Key (click to show/hide answers) - Branches of Parasympathetic Cranial Nerves

Blue - Oculomotor nerve (CN III), to iris and ciliary body

Green - Facial nerve (CN VII), to lacrimal gland

Purple - Facial nerve (CN VII), to salivary glands

Pink - Cranial root of accessory nerve (CN XI), to pharynx

Orange - Vagus nerve (CN X) and branch (15) to larynx

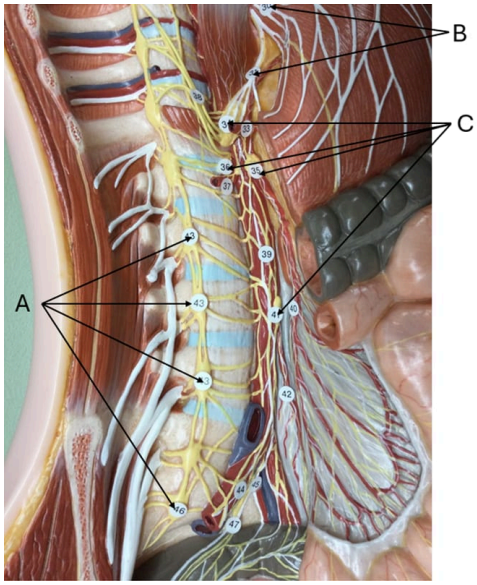

Image Credit

"ANS - Inferior section of Model" by Jennifer Lange is licensed under CC BY-NC-SA 4.0.

Answer Key (click to show/hide answers)

Note: Sympathetic Division structures are yellow and Parasympathetic Division structures are white.

A - Sympathetic chain ganglia

B - Parasympathetic CN X (Vagus) branches

C - Sympathetic prevertebral ganglia

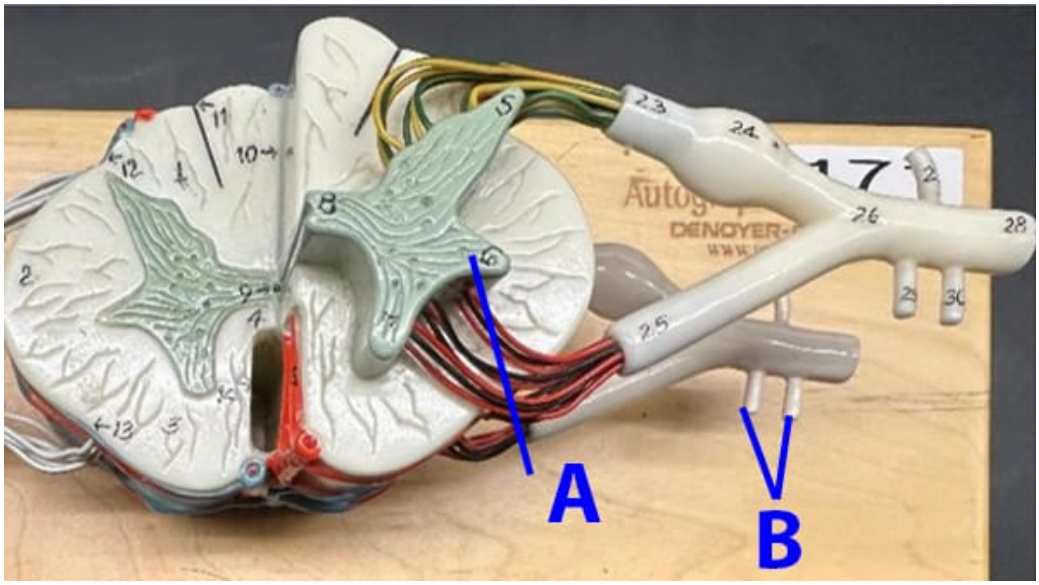

Image Credit

"Spinal Cord Model - ANS structures" by Jennifer Lange is licensed under CC BY-NC-SA 4.0.

Answer Key (click to show/hide answers)

A - lateral horn

B - rami communicans (grey and white rami)

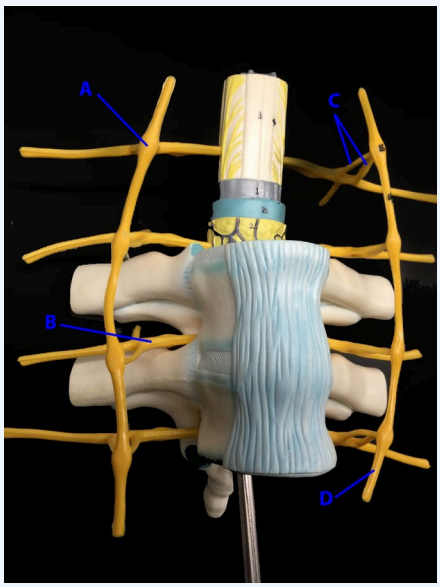

Image Credit

"Spinal Cord Model - Rami Branching Atlas" by Jennifer Lange is licensed under CC BY-NC-SA 4.0.

Answer Key (click to show/hide answers)

A - sympathetic chain ganglion

B - spinal nerve

C - rami communicans (grey and white rami)

D - sympathetic chain

This page titled 14.5: Anatomical Atlas - Autonomic Nervous System is shared under a CC BY-NC-SA 4.0 license and was authored, remixed, and/or curated by Jennifer Lange et al..

14.6: Practice Practical - ANS

Query 14.6.1

This interactive element is not available in this format. Visit the link or scan the QR code to access it online.

View this Interactive Content online

Query 14.6.1

This interactive element is not available in this format. Visit the link or scan the QR code to access it online.

View this Interactive Content online

This page titled 14.6: Practice Practical - ANS is shared under a CC BY-NC-SA 4.0 license and was authored, remixed, and/or curated by Jennifer Lange et al..

15: ENDOCRINE SYSTEM

15.1: Introduction to the Endocrine System

15.2: An Overview of the Endocrine System

15.3: Pituitary Gland and Hypothalamus

15.4: Thyroid Gland and Parathyroid Glands

15.5: Adrenal Glands

15.6: Pineal Gland

15.7: Gonadal and Placental Hormones

15.8: Endocrine Pancreas

15.9: Organs with Secondary Endocrine Functions

15.10: Development and Aging of the Endocrine System

15.11: Anatomical Atlas - Endocrine System

15.12: Practice Practical- Endocrine System

This page titled 15: Endocrine System is shared under a CC BY-NC-SA 4.0 license and was authored, remixed, and/or curated by Jennifer Lange et al..

- 15: Endocrine System by Whitney Menefee, Julie Jenks, Chiara Mazzasette, and Kim-Leiloni Nguyen is licensed CC BY 4.0.

15.1: Introduction to the Endocrine System

Chapter Learning Objectives:

After studying this chapter, you will be able to:

- Identify the contributions of the endocrine system to homeostasis
- Discuss the chemical composition of hormones and the mechanisms of hormone action
- Summarize the site of production, regulation, and effects of the hormones of the pituitary, thyroid, parathyroid, adrenal, and pineal glands
- Discuss the hormonal regulation of the reproductive system
- Explain the role of the pancreatic endocrine cells in the regulation of blood glucose
- Identify the hormones released by the heart, kidneys, and other organs with secondary endocrine functions
- Discuss several common diseases associated with endocrine system dysfunction
- Discuss the embryonic development of, and the effects of aging on, the endocrine system

You may never have thought of it this way, but when you send a text message to two friends to meet you at six, you're sending digital signals that (you hope) will affect their behavior—even though they are some distance away. Similarly, certain cells send chemical signals to other cells in the body that influence their behavior. This long-distance intercellular communication, coordination, and control is critical for homeostasis, and it is the fundamental function of the endocrine system.

Figure 15.1.1: Humulin R. Humulin is human insulin made through recombinant DNA technology. Prior to its development, diabetics used insulin isolated from pig and cow pancreases. (Image credit: "Humulin R, Insulin, 1987" by the National Museum of American History is licensed under CC BY-NC-ND 2.0.)

Contributors and Attributions

- OpenStax Anatomy & Physiology (CC BY 4.0). Access for free at https://openstax.org/books/anatomy-and-physiology

This page titled 15.1: Introduction to the Endocrine System is shared under a CC BY-NC-SA 4.0 license and was authored, remixed, and/or curated by Jennifer Lange et al..

- 15.1: Introduction to the Endocrine System by Whitney Menefee, Julie Jenks, Chiara Mazzasette, and Kim-Leiloni Nguyen is licensed CC BY 4.0.

15.2: An Overview of the Endocrine System

By the end of this section, you will be able to:

- Distinguish the types of intercellular communication and their importance
- Identify the major organs and tissues of the endocrine system and their location in the body
- Explain the role of hormones in controlling body functions via the bloodstream
- Discuss the role of feedback loops in hormone control

Communication is a process in which a sender transmits signals to one or more receivers to control and coordinate actions. In the human body, two major organ systems participate in relatively "long distance" communication: the nervous system and the endocrine system. Together, these two systems are primarily responsible for maintaining homeostasis in the body.

Neural and Endocrine Signaling

The nervous system uses two types of intercellular communication—electrical and chemical signaling—either by the direct action of an electrical potential, or in the latter case, through the action of chemical neurotransmitters. In a synapse, neurotransmitters act locally and rapidly. The target cell responds within milliseconds of receiving the chemical "message"; this response then ceases very quickly once the neural signaling ends. In this way, neural communication enables body functions that involve quick, brief actions, such as movement, sensation, and cognition.

In contrast, the **endocrine system** uses just one method of communication: chemical signaling. These signals are sent by the endocrine organs, which secrete chemicals — the **hormones** — into the extracellular fluid. Hormones are transported primarily via the bloodstream throughout the body, where they bind to receptors on target cells, inducing a characteristic response. As a result, endocrine signaling requires more time than neural signaling to prompt a response in target cells, though the precise amount of time varies with different hormones. For example, the hormones released when you are confronted with a dangerous or frightening situation, called the fight-or-flight response, occur by the release of adrenal hormones—epinephrine and norepinephrine—within seconds. In contrast, it may take up to 48 hours for target cells to respond to certain reproductive hormones.

In addition, endocrine signaling is typically less specific than neural signaling. The same hormone may play a role in a variety of different physiological processes depending on the target cells involved. For example, the hormone oxytocin promotes uterine contractions in women during labor. It is also important in breastfeeding, and may be involved in the sexual response and in feelings of emotional attachment in both males and females.

In general, the nervous system involves quick responses to rapid changes in the external environment, and the endocrine system is usually slower acting—taking care of the internal environment of the body, maintaining homeostasis, and controlling reproduction (Table 15.2.1). So how does the fight-or-flight response that was mentioned earlier happen so quickly if hormones are usually slower acting? It is because the two systems are connected. It is the fast action of the nervous system in response to the danger in the environment that stimulates the adrenal glands to secrete their hormones. As a result, the nervous system can cause rapid endocrine responses to keep up with sudden changes in both the external and internal environments when necessary.

Table 15.2.1: A Comparison of the Endocrine and Nervous Systems

	Endocrine system	Nervous system
Signaling mechanism(s)	Chemical	Chemical/electrical
Primary chemical signal	Hormones	Neurotransmitters
Distance traveled	Long or short	Always short
Response time	Fast or slow	Always fast

Structures of the Endocrine System

The endocrine system consists of cells, tissues, and organs that secrete hormones as a primary or secondary function. The hormones secreted by **endocrine glands** diffuse into the blood and can then travel great distances throughout the body within the blood vessels. The primary function of these ductless glands is to secrete their hormones into the blood, and blood vessels then transport the hormones throughout the body. The endocrine system includes the pituitary, thyroid, parathyroid, adrenal, and pineal glands (summarized in Figure 15.2.1 and covered in more detail in subsequent sections of this chapter). Some glands have both endocrine and non-endocrine functions. For example, the pancreas contains cells that function in digestion as well as cells that secrete the hormones insulin and glucagon, which regulate blood glucose levels. The hypothalamus, thymus, heart, kidneys, stomach, small intestine, liver, skin, female ovaries, and male testes are other organs that contain cells with endocrine function. Moreover, adipose tissue has long been known to produce hormones, and recent research has revealed that even bone tissue has endocrine functions.

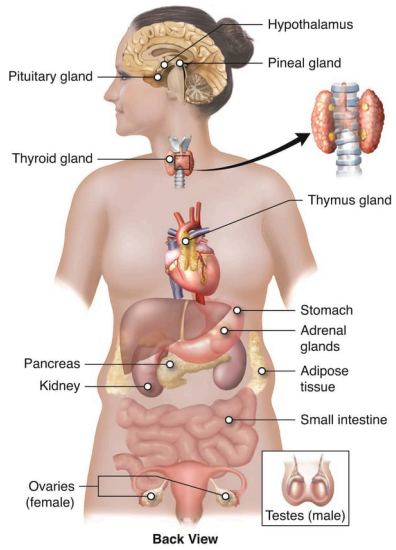

Figure 15.2.1: Endocrine System. Endocrine glands and cells are located throughout the body and play an important role in homeostasis. *(Image credit: "KnowledgeWorks - Drawing Overview of endocrine glands - English labels" by KnowledgeWorks Global Ltd., is licensed under CC BY.)*

The ductless endocrine glands are not to be confused with the body's **exocrine system**, whose glands release their secretions through ducts. Examples of exocrine glands include the sebaceous and sweat glands of the skin. As just noted, the pancreas also has an exocrine function: most of its cells secrete pancreatic juice through the pancreatic and accessory ducts to the lumen (inside) of the small intestine.

Hormones

Although a given hormone may travel throughout the body in the bloodstream, it will affect the activity only of its target cells; that is, cells with receptors for that particular hormone. Once the hormone binds to the receptor, a chain of events is initiated that leads to the target cell's response. Hormones play a critical role in the regulation of physiological processes because of the target cell responses they regulate. These responses contribute to human reproduction, growth and development of body tissues, metabolism, fluid and electrolyte balance, sleep, and many other body functions. The major hormones of the human body and their effects are identified in Table 15.2.2.

Table 15.2.2: Endocrine Glands and Their Major Hormones

Endocrine gland	Associated hormones	Effect
Pituitary (anterior)	Growth hormone (GH)	Promotes growth of body tissues

Endocrine gland	Associated hormones	Effect
Pituitary (anterior)	Prolactin (PRL)	Promotes milk production
Pituitary (anterior)	Thyroid-stimulating hormone (TSH)	Stimulates thyroid hormone release
Pituitary (anterior)	Adrenocorticotropic hormone (ACTH)	Stimulates glucocorticoid release by adrenal cortex
Pituitary (anterior)	Follicle-stimulating hormone (FSH)	Stimulates gamete (egg or sperm) production
Pituitary (anterior)	Luteinizing hormone (LH)	Stimulates androgen production by gonads
Pituitary (posterior)	Antidiuretic hormone (ADH; aka vasopressin)	Stimulates water reabsorption by kidneys
Pituitary (posterior)	Oxytocin	Stimulates uterine contractions during childbirth
Thyroid	Thyroxine (T_4), triiodothyronine (T_3)	Stimulate basal metabolic rate
Thyroid	Calcitonin	Reduces blood Ca^{2+} levels
Parathyroid	Parathyroid hormone (PTH)	Increases blood Ca^{2+} levels
Adrenal (cortex)	Aldosterone	Increases blood Na^{+} levels
Adrenal (cortex)	Cortisol, corticosterone, cortisone	Increase blood glucose levels, involved in stress response
Adrenal (medulla)	Epinephrine, norepinephrine	Stimulate fight-or-flight response
Pineal	Melatonin	Regulates sleep cycles
Pancreas	Insulin	Reduces blood glucose levels
Pancreas	Glucagon	Increases blood glucose levels
Testes	Testosterone	Stimulates development of male secondary sex characteristics and sperm production
Ovaries	Estrogens and progesterone	Stimulate development of female secondary sex characteristics and prepare the body for childbirth

Types of Hormones

The hormones of the human body can be divided into two major groups on the basis of their chemical properties: hormones that are soluble in water, most of which are derived from amino acids (the building blocks of proteins), and steroid hormones, which are not soluble in water as they are derived from the lipid cholesterol. The chemical properties of the hormones in each group affect much of how they work including how they are distributed to target cells, the type of receptors they bind to, and other aspects of function such as how long effects can last.

Regulation of Hormone Secretion: Feedback Loops

To prevent abnormal hormone levels and a potential disease state, hormone levels must be tightly controlled. The body maintains this control by balancing hormone production and degradation. Feedback loops govern the initiation and maintenance of most hormone secretion in response to various stimuli. The contribution of feedback loops to homeostasis will only be briefly reviewed

here.

Positive feedback loops are characterized by the release of additional hormone in response to an original hormone release. The release of oxytocin during childbirth is a positive feedback loop. The initial release of oxytocin begins to signal the uterine muscles to contract, which pushes the fetus toward the cervix, causing it to stretch. This, in turn, signals the pituitary gland to release more oxytocin, causing labor contractions to intensify. The release of oxytocin decreases after the birth of the child (Figure 15.2.2).

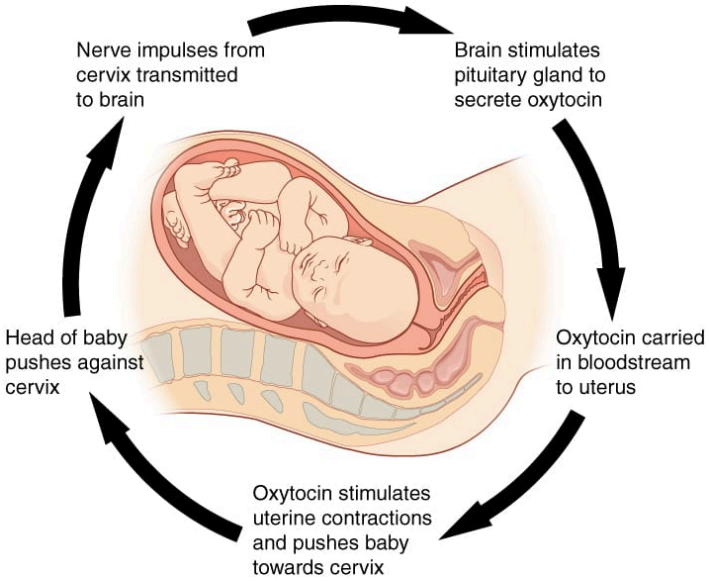

Figure 15.2.2: Positive Feedback Loop. Normal childbirth is driven by a positive feedback loop. A positive feedback loop results in a change in the body's status, rather than a return to homeostasis. *(Image credit: "Pregnancy-Positive Feedback" by OpenStax is licensed under CC BY 4.0.)*

The more common method of hormone regulation is the **negative feedback loop**. Negative feedback is characterized by the inhibition of further secretion of a hormone in response to adequate levels of that hormone. This allows blood levels of the hormone to be regulated within a narrow range. An example of a negative feedback loop is the release of insulin from the pancreas. Eating causes blood glucose levels to rise (stimulus). The beta cells in the pancreas detect blood glucose levels (receptor) and then compare the current level to the optimal level or set-point (control center). When blood glucose rises above the set-point the beta-cells will release the hormone insulin into the blood, which will cause the liver and other cells to take in glucose (effectors). This response decreases the initial stimulus by lowering the blood glucose level and decreases the secretion of insulin (Figure 15.2.3).

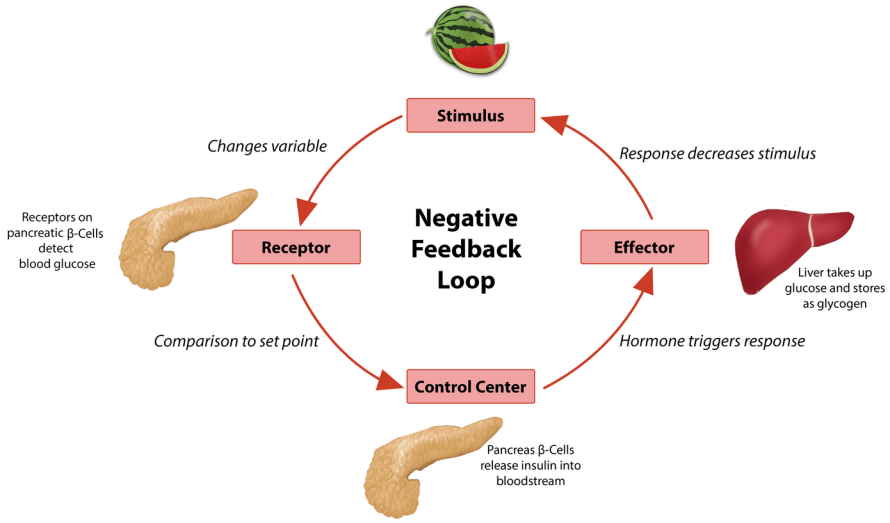

Figure 15.2.3: Negative Feedback Loop. In negative feedback loops the response acts to reduce the stimulus and to maintain homeostasis. *(Image credit: "Negative Feedback Loop" by Jennifer Lange is licensed under CC BY-NC-SA 4.0. Pancreas image by Ron Slagter; liver image by Ron Slagter.)*

EVERYDAY CONNECTIONS

Bisphenol A and Endocrine Disruption

You may have heard news reports about the effects of a chemical called bisphenol A (BPA) in various types of food packaging. BPA is used in the manufacturing of hard plastics and epoxy resins. Common food-related items that may contain BPA include the lining of aluminum cans, plastic food-storage containers, drinking cups, as well as baby bottles and “sippy” cups. Other uses of BPA include medical equipment, dental fillings, and the lining of water pipes.

Research suggests that BPA is an endocrine disruptor, meaning that it negatively interferes with the endocrine system, particularly during the prenatal and postnatal development period. In particular, BPA mimics the hormonal effects of estrogens and has the opposite effect—that of androgens. The U.S. Food and Drug Administration (FDA) notes in their statement about BPA safety that although traditional toxicology studies have supported the safety of low levels of exposure to BPA, recent studies using novel approaches to test for subtle effects have led to some concern about the potential effects of BPA on the brain, behavior, and prostate gland in fetuses, infants, and young children. The FDA is currently facilitating decreased use of BPA in food-related materials. Many US companies have voluntarily removed BPA from baby bottles, “sippy” cups, and the linings of infant formula cans, and most plastic reusable water bottles sold today boast that they are “BPA free.” In contrast, both Canada and the European Union have completely banned the use of BPA in baby products.

The potential harmful effects of BPA have been studied in both animal models and humans and include a large variety of health effects, such as developmental delay and disease. For example, prenatal exposure to BPA during the first trimester of human pregnancy may be associated with wheezing and aggressive behavior during childhood. Adults exposed to high levels of BPA may experience altered thyroid signaling and male sexual dysfunction. BPA exposure during the prenatal or postnatal period of development in animal models has been observed to cause neurological delays, changes in brain structure and function, sexual dysfunction, asthma, and increased risk for multiple cancers. In vitro studies have also shown that BPA exposure causes molecular changes that initiate the development of cancers of the breast, prostate, and brain. Although these studies have implicated BPA in numerous ill health effects, some experts caution that some of these studies may be flawed and that more research needs to be done. In the meantime, the FDA recommends that consumers take precautions to limit their exposure to BPA. In addition to purchasing foods in packaging free of BPA, consumers should avoid carrying or storing foods or liquids in bottles with the recycling code 3 or 7. Foods and liquids should not be microwave-heated in any form of plastic: use paper, glass, or ceramics instead.

CAREER CONNECTIONS

Endocrinologist

Endocrinology is a specialty in the field of medicine that focuses on the treatment of endocrine system disorders. Endocrinologists—medical doctors who specialize in this field—are experts in treating diseases associated with hormonal systems, ranging from thyroid disease to diabetes mellitus. Endocrine surgeons treat endocrine disease through the removal, or resection, of the affected endocrine gland.

Patients who are referred to endocrinologists may have signs and symptoms or blood test results that suggest excessive or impaired functioning of an endocrine gland or endocrine cells. The endocrinologist may order additional blood tests to determine whether the patient's hormonal levels are abnormal, or they may stimulate or suppress the function of the suspect endocrine gland and then have blood taken for analysis. Treatment varies according to the diagnosis. Some endocrine disorders, such as type 2 diabetes, may respond to lifestyle changes such as modest weight loss, adoption of a healthy diet, and regular physical activity. Other disorders may require medication, such as hormone replacement, and routine monitoring by the endocrinologist. These include disorders of the pituitary gland that can affect growth and disorders of the thyroid gland that can result in a variety of metabolic problems.

Some patients experience health problems as a result of the normal decline in hormones that can accompany aging. These patients can consult with an endocrinologist to weigh the risks and benefits of hormone replacement therapy intended to boost their natural levels of reproductive hormones.

In addition to treating patients, endocrinologists may be involved in research to improve the understanding of endocrine system disorders and develop new treatments for these diseases.

Concept Review

The endocrine system consists of cells, tissues, and organs that secrete hormones critical to homeostasis. The body coordinates its functions through two major types of communication: neural and endocrine. Neural communication includes both electrical and chemical signaling between neurons and target cells. Endocrine communication involves chemical signaling via the release of hormones into the extracellular fluid. From there, hormones diffuse into the bloodstream and may travel to distant body regions, where they elicit a response in target cells. Endocrine glands are ductless glands that secrete hormones. Many organs of the body with other primary functions—such as the heart, stomach, and kidneys—also have hormone-secreting cells.

Hormones are released upon stimulation that is of either chemical or neural origin. Regulation of hormone release is primarily achieved through negative feedback. Various stimuli may cause the release of hormones, but there are three major types. Humoral stimuli are changes in ion or nutrient levels in the blood. Hormonal stimuli are changes in hormone levels that initiate or inhibit the secretion of another hormone. Finally, a neural stimulus occurs when a nerve impulse prompts the secretion or inhibition of a hormone.

Review Questions

Query 15.2.1

This interactive element is not available in this format. Visit the link or scan the QR code to access it online.

View this Interactive Content online

Critical Thinking Questions

Query 15.2.2

This interactive element is not available in this format. Visit the link or scan the QR code to access it online.

View this Interactive Content online

Query 15.2.3

This interactive element is not available in this format. Visit the link or scan the QR code to access it online.

View this Interactive Content online

Glossary

Query 15.2.4

This interactive element is not available in this format. Visit the link or scan the QR code to access it online.

View this Interactive Content online

Contributors and Attributions

- OpenStax Anatomy & Physiology (CC BY 4.0). Access for free at https://openstax.org/books/anatomy-and-physiology

This page titled 15.2: An Overview of the Endocrine System is shared under a CC BY-NC-SA 4.0 license and was authored, remixed, and/or curated by Jennifer Lange et al..

- 15.2: An Overview of the Endocrine System by Whitney Menefee, Julie Jenks, Chiara Mazzasette, and Kim-Leiloni Nguyen is licensed CC BY 4.0.

15.3: Pituitary Gland and Hypothalamus

By the end of this section, you will be able to:

- Explain the interrelationships of the anatomy of the hypothalamus and the posterior and anterior lobes of the pituitary gland
- Identify the two hormones released from the posterior pituitary, their target cells, and their principal actions
- Identify the six hormones produced by the anterior lobe of the pituitary gland

The hypothalamus–pituitary complex can be thought of as the “command center” of the endocrine system. This complex secretes several hormones that directly produce responses in target tissues, as well as hormones that regulate the synthesis and secretion of hormones of other glands. In addition, the hypothalamus–pituitary complex coordinates the messages of the endocrine and nervous systems. In many cases, a stimulus received by the nervous system must pass through the hypothalamus–pituitary complex to be translated into hormones that can initiate a response.

The **hypothalamus** is a structure of the diencephalon of the brain located anterior and inferior to the thalamus (Figure 15.3.1). It has both neural and endocrine functions, producing and secreting many hormones. In addition, the hypothalamus is anatomically and functionally related to the **pituitary gland** (or hypophysis), a bean-sized organ suspended from it by a stem called the **infundibulum** (or pituitary stalk). The pituitary gland is cradled within the sella turcica of the sphenoid bone of the skull. It consists of two lobes that arise from distinct parts of embryonic tissue: the posterior pituitary (neurohypophysis) is neural tissue, whereas the anterior pituitary (also known as the adenohypophysis) is glandular tissue that develops from the primitive digestive tract. The hormones secreted by the posterior and anterior pituitary, and the intermediate zone between the lobes are summarized in Table 15.3.1.

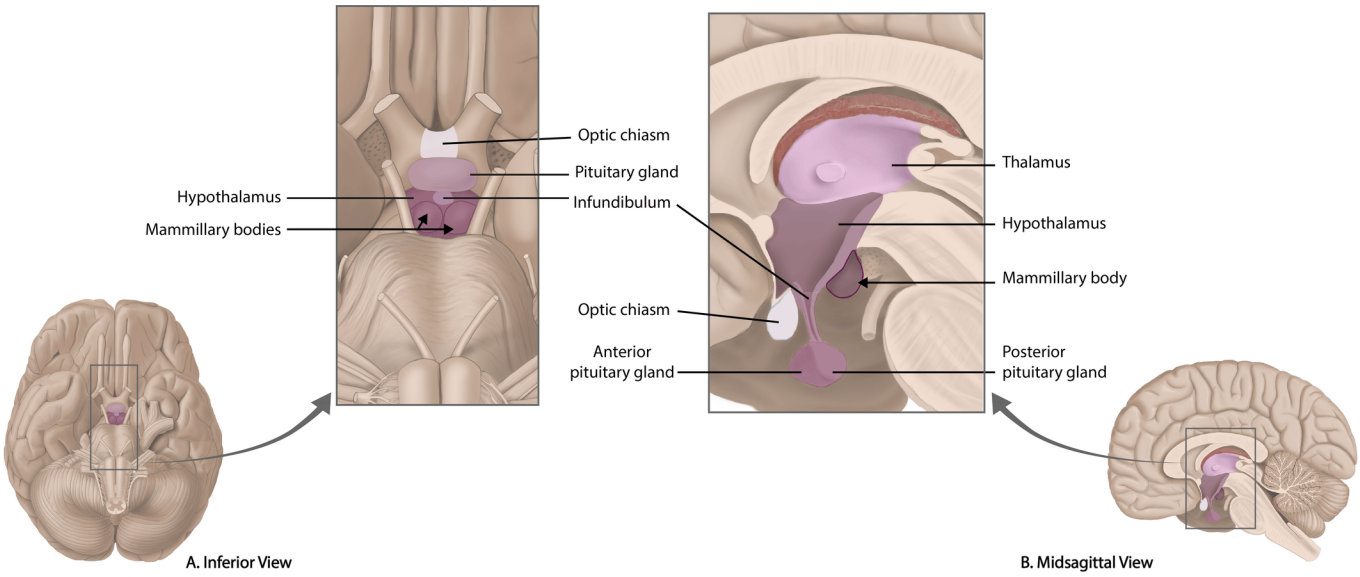

Figure 15.3.1: Hypothalamus–Pituitary Complex. The hypothalamus region of the brain lies inferior and anterior to the thalamus. It connects to the pituitary gland by way of the stalk-like infundibulum. The pituitary gland consists of an anterior and posterior lobe, with each lobe releasing different hormones in response to signals from the hypothalamus. *(Image credit: "Hypothalamus and Pituitary Gland" by Jennifer Lange and Justin Greene is licensed under CC BY-NC-SA 4.0.)*

Table 15.3.1: Pituitary Hormones

Pituitary lobe	Associated hormones	Effect
Anterior	Growth hormone (GH)	Promotes growth of body tissues
Anterior	Prolactin (PRL)	Promotes milk production from mammary glands

Pituitary lobe	Associated hormones	Effect
Anterior	Thyroid-stimulating hormone (TSH)	Stimulates thyroid hormone release from thyroid
Anterior	Adrenocorticotropic hormone (ACTH)	Stimulates hormone release by adrenal cortex
Anterior	Follicle-stimulating hormone (FSH)	Stimulates gamete production in gonads
Anterior	Luteinizing hormone (LH)	Stimulates androgen production by gonads
Anterior (intermediate)	Melanocyte stimulating hormone (MSH)	Stimulates melanin formation in melanocytes
Posterior	Antidiuretic hormone (ADH)	Stimulates water reabsorption by kidneys
Posterior	Oxytocin	Stimulates smooth muscle contractions in male and female reproductive tracts and uterine contractions during childbirth

Posterior Pituitary

The posterior pituitary is actually an extension of the neurons of the paraventricular and supraoptic nuclei of the hypothalamus. The cell bodies of these regions rest in the hypothalamus, but their axons descend as the hypothalamic–hypophyseal tract within the infundibulum and end in axon terminals that comprise the posterior pituitary (Figure 15.3.2).

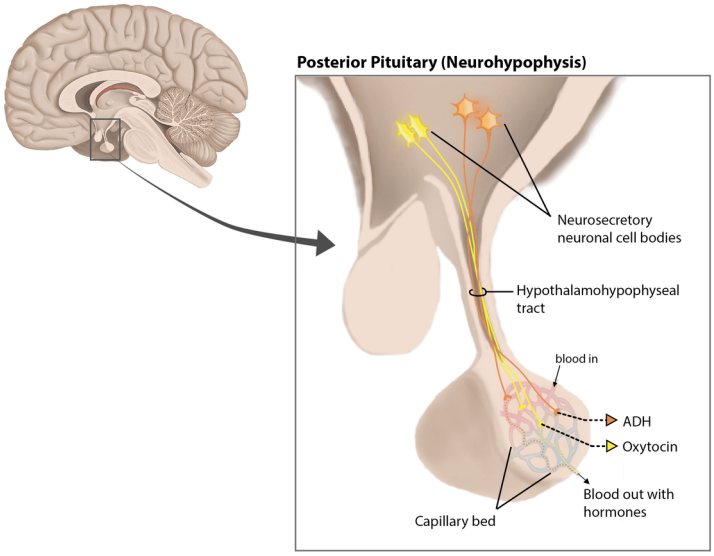

Figure 15.3.2: Posterior Pituitary Gland. Neurosecretory cells in the supraoptic nucleus of the hypothalamus release antidiuretic hormone (ADH) and neurosecretory cells in the paraventricular nucleus of the hypothalamus release oxytocin (OT). The hormones move through the axons in the hypothalamohypophyseal tract that run through the infundibulum to their axon terminals located in the posterior lobe of the pituitary gland. These hormones are stored or released into the bloodstream via the capillary bed in the posterior pituitary gland. *(Image credit: "Posterior Pituitary" by Jennifer Lange and Justin Greene is licensed under CC BY-NC-SA 4.0.)*

The posterior pituitary gland does not produce hormones, but rather stores and secretes hormones produced by the hypothalamus. The paraventricular nucleus produces the hormone oxytocin, whereas the supraoptic nucleus produces antidiuretic hormone (ADH). These hormones travel along the axons into storage sites in the axon terminals of the posterior pituitary. In response to signals from the same hypothalamic neurons, the hormones are released from the axon terminals into the bloodstream.

Anterior Pituitary

The anterior pituitary originates from the digestive tract in the embryo and migrates toward the brain during fetal development. There are three regions: the pars distalis is the most anterior, the pars intermedia is adjacent to the posterior pituitary, and the pars tuberalis is a slender “tube” that wraps the infundibulum.

Recall that the posterior pituitary does not synthesize hormones, but merely stores them. In contrast, the anterior pituitary does manufacture hormones. However, the secretion of hormones from the anterior pituitary is regulated by two classes of hormones. These hormones—secreted by the hypothalamus—are the releasing hormones that stimulate the secretion of hormones from the anterior pituitary and the inhibiting hormones that inhibit secretion.

Hypothalamic hormones are secreted by neurons, but enter the anterior pituitary through blood vessels (Figure 15.3.3). Within the infundibulum is a bridge of capillaries that connects the hypothalamus to the anterior pituitary. This network, called the **hypophyseal portal system**, allows hypothalamic hormones to be transported to the anterior pituitary without first entering the systemic circulation. The system originates from the superior hypophyseal artery, which branches off the carotid arteries and transports blood to the hypothalamus. The branches of the superior hypophyseal artery form the hypophyseal portal system (see Figure 15.3.3). Hypothalamic releasing and inhibiting hormones travel through a primary capillary plexus to the portal veins, which carry them into the anterior pituitary. Hormones produced by the anterior pituitary (in response to releasing hormones) enter a secondary capillary plexus, and from there drain into the circulation.

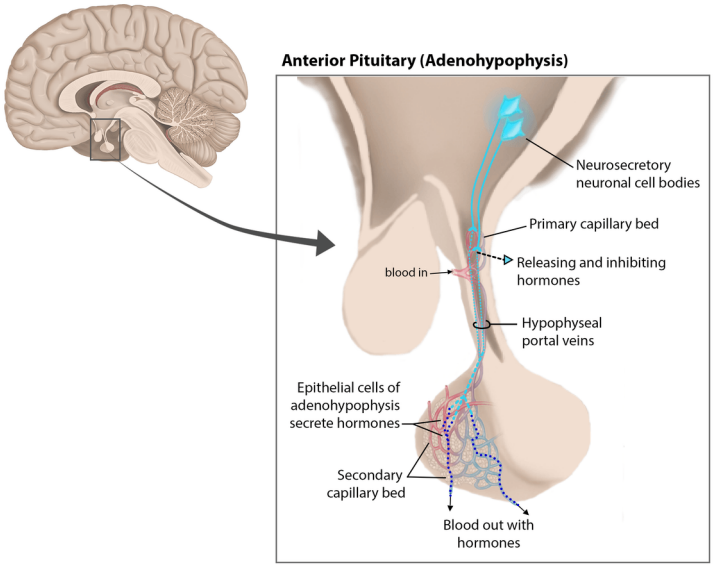

Figure 15.3.3: Anterior Pituitary Gland. The anterior pituitary manufactures six hormones. Neurosecretory cells in the hypothalamus produces separate hormones that stimulate or inhibit hormone production in the anterior pituitary. Hormones from the hypothalamus travel by neuron axons to the primary capillary bed of the hypophyseal portal system located in the infundibulum. The hormones move through hypophyseal portal veins in the infundibulum to the secondary capillary bed in the anterior pituitary. Hormones produced in the anterior pituitary are released into the bloodstream via the secondary capillary bed. *(Image credit: "Anterior Pituitary" by Jennifer Lange and Justin Greene is licensed under CC BY-NC-SA 4.0.)*

Six hormones are synthesized in the anterior pituitary. These are the growth hormone (GH), thyroid-stimulating hormone (TSH), adrenocorticotropic hormone (ACTH), follicle-stimulating hormone (FSH), luteinizing hormone (LH), and prolactin. Of the hormones of the anterior pituitary, TSH, ACTH, FSH, and LH are collectively referred to as tropic hormones (trope- = “turning”) because they turn on or off the function of other endocrine glands.

The cells in the zone between the pituitary lobes (in humans considered part of the anterior pituitary) secrete a **hormone** known as melanocyte-stimulating hormone (MSH). MSH is capable of darkening of the skin by inducing melanin production in the skin’s melanocytes. People also show increased MSH production during pregnancy; in combination with estrogens, it can lead to darker skin pigmentation, especially the skin of the areolas and labia minora.

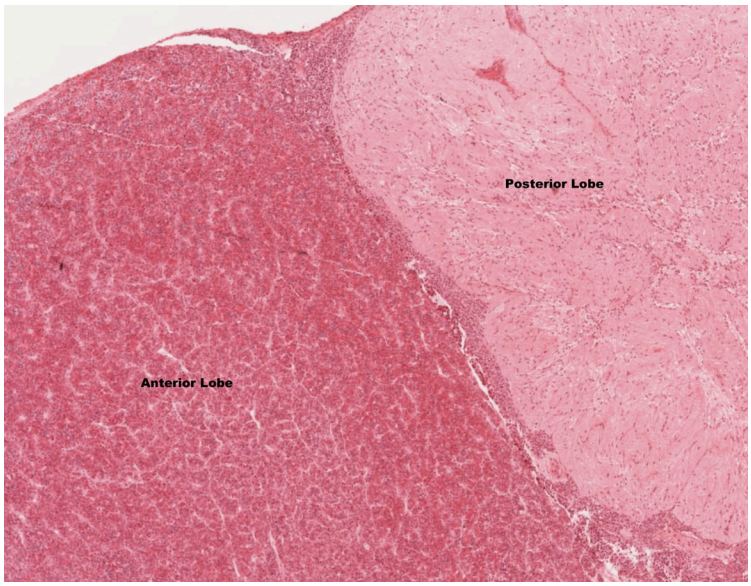

Figure 15.3.4: The Pituitary Gland. The pituitary gland consist of the anterior and posterior lobe. The anterior lobe is responsible for manufacturing hormones while the posterior lobe is where hormones from the hypothalamus are stored. *(Image Credit: "Pituitary Gland" by Yancy Aquino is licensed under CC BY-NC-SA 4.0, slide provided by the Regents of the University of Michigan Medical School © 2022.)*

Concept Review

The hypothalamus–pituitary complex is located in the diencephalon of the brain. The hypothalamus and the pituitary gland are connected by a structure called the infundibulum, which contains vasculature and nerve axons. The pituitary gland is divided into two distinct structures with different embryonic origins. The posterior lobe houses the axon terminals of hypothalamic neurons. It stores and releases into the bloodstream two hypothalamic hormones: oxytocin (OT) and antidiuretic hormone (ADH). The anterior lobe is connected to the hypothalamus by the vasculature of the hypophyseal portal system in the infundibulum and produces and secretes six hormones. Their secretion is regulated, however, by releasing and inhibiting hormones from the hypothalamus. The six anterior pituitary hormones are: growth hormone (GH), thyroid-stimulating hormone (TSH), adrenocorticotropic hormone (ACTH), follicle-stimulating hormone (FSH), luteinizing hormone (LH), and prolactin (PRL). Figure 15.3.4 is a summary of the pituitary hormones and their principal effects.

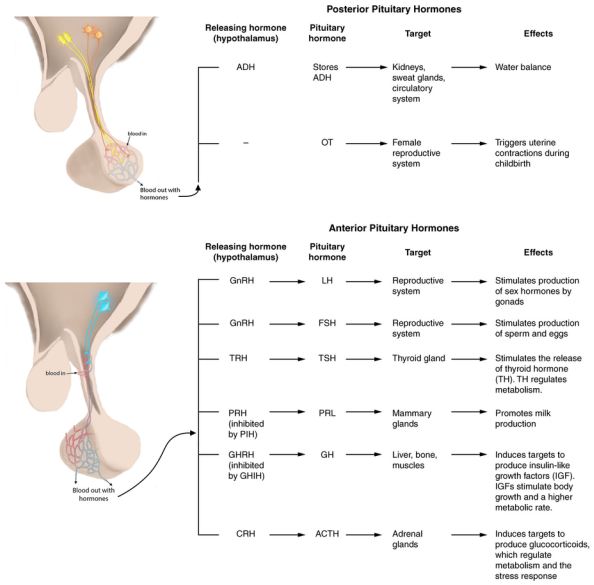

Figure 15.3.4: Major Pituitary Hormones. Major pituitary hormones and their target organs and effects. *(Image credit: "Major Pituitary Hormones" by Jennifer Lange and Justin Greene is licensed under CC BY-NC-SA 4.0, modification of original by OpenStax.)*

Review Questions

Query 15.3.1

This interactive element is not available in this format. Visit the link or scan the QR code to access it online.

View this Interactive Content online

Critical Thinking Questions

Query 15.3.2

This interactive element is not available in this format. Visit the link or scan the QR code to access it online.

View this Interactive Content online

Glossary

Query 15.3.3

This interactive element is not available in this format. Visit the link or scan the QR code to access it online.

View this Interactive Content online

Contributors and Attributions

OpenStax Anatomy & Physiology (CC BY 4.0). Access for free at https://openstax.org/books/anatomy-and-physiology

This page titled 15.3: Pituitary Gland and Hypothalamus is shared under a CC BY-NC-SA 4.0 license and was authored, remixed, and/or curated by Jennifer Lange et al..

- 15.3: Pituitary Gland and Hypothalamus by Whitney Menefee, Julie Jenks, Chiara Mazzasette, and Kim-Leiloni Nguyen is licensed CC BY 4.0.

15.4: Thyroid Gland and Parathyroid Glands

By the end of this section, you will be able to:

- Describe the location and anatomy of the thyroid gland
- Identify the hormones produced by the follicular cells and the parafollicular cells of the thyroid
- Describe the location and structure of the parathyroid glands
- Describe the hormonal control of blood calcium levels

Thyroid Gland

The **thyroid gland**, a butterfly-shaped organ, is located anterior to the trachea, just inferior to the larynx (Figure 15.4.1). The medial region, called the isthmus, is flanked by wing-shaped left and right lobes. Each of the thyroid lobes has a pair of parathyroid glands embedded on its posterior surface. The tissue of the thyroid gland is composed mostly of thyroid follicles lined with simple cuboidal epithelium (Figure 15.4.2). The **follicles** are made up of a central cavity filled with a sticky fluid called **colloid**. Surrounded by a wall of epithelial follicle cells, the colloid is the center of thyroid hormone production, and that production is dependent on the essential and unique component of thyroid hormones: iodine.

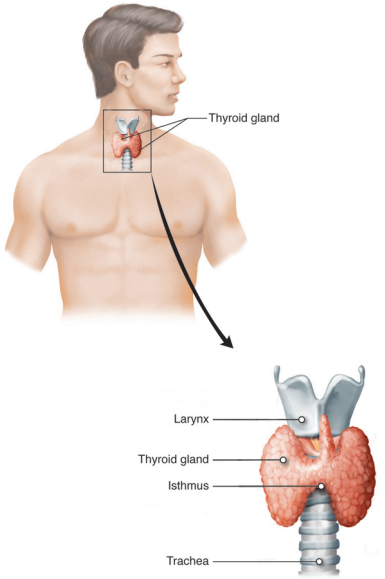

Figure 15.4.1: Thyroid Gland. The thyroid gland is located in the neck where it wraps around the anterior of the trachea just inferior to the thyroid cartilage of the larynx. *(Image Credit: "Thyroid Gland Location" by Gabrielle Spurlock is licensed under CC BY-NC-SA 4.0, modification of original by "KnowledgeWorks - Drawing Thyroid gland and its vascularisation - English labels".)*

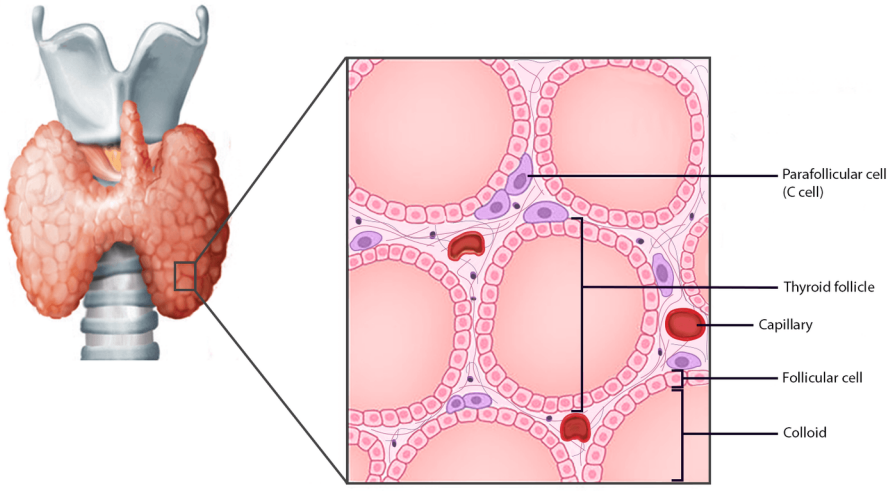

Figure 15.4.2: Thyroid Follicles. Each spherical thyroid follicle contains an external layer of epithelial follicular cells surrounding the colloid. Parafollicular cells are scattered in the connective tissue surrounding the follicles. *(Image Credit: "Thyroid Follicles" by Jennifer Lange is licensed under CC BY-NC-SA 4.0. Includes modification of original by "KnowledgeWorks - Drawing Thyroid gland and its vascularisation - English labels".)*

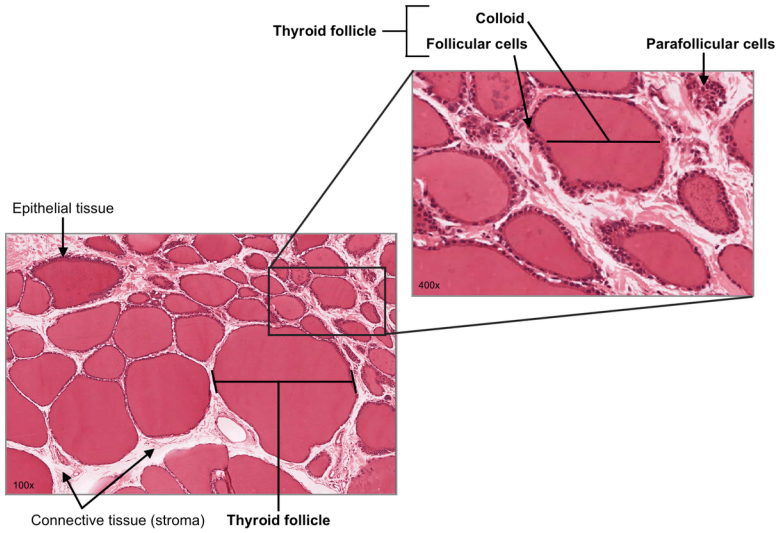

Figure 15.4.3: Thyroid Gland Histology. Visibly, the thyroid gland is dominated by the colloid of the follicles. Higher magnification is needed to clearly see the follicular cells and the parafollicular cells. *(Image credit: "Thyroid Gland Histology" by Jennifer Lange is licensed under CC BY-NC-SA 4.0. Micrograph from Digital Histology is licensed under CC BY-NC-SA 4.0.)*

DISORDERS OF THE...

Endocrine System: Iodine Deficiency, Hypothyroidism, and Hyperthyroidism

As discussed above, dietary iodine is required for the synthesis of T_3 and T_4. But for much of the world's population, foods do not provide adequate levels of this mineral, because the amount varies according to the level in the soil in which the food was grown, as well as the irrigation and fertilizers used. Marine fish and shrimp tend to have high levels because they concentrate iodine from seawater, but many people in landlocked regions lack access to seafood. Thus, the primary source of dietary iodine in many countries is iodized salt. Fortification of salt with iodine began in the United States in 1924, and international efforts to iodize salt in the world's poorest nations continue today.

Dietary iodine deficiency can result in the impaired ability to synthesize T_3 and T_4, leading to a variety of severe disorders. When T_3 and T_4 cannot be produced, TSH is secreted in increasing amounts. As a result of this hyperstimulation, thyroglobulin accumulates in the thyroid gland follicles, increasing their deposits of colloid. The accumulation of colloid increases the overall size of the thyroid gland, a condition called a goiter (Figure 15.4.4). A goiter is only a visible indication of the deficiency. Other iodine deficiency disorders include impaired growth and development, decreased fertility, and prenatal and infant death. Moreover, iodine deficiency is the primary cause of preventable intellectual disability worldwide. Neonatal hypothyroidism (cretinism) is characterized by cognitive deficits, short stature, and sometimes deafness and muteness in children and adults born to mothers who were iodine-deficient during pregnancy.

Figure 15.4.4: Goiter. A goiter is the abnormal enlargement of the thyroid gland. *(Image credit: "Goiter" by Almazi is licensed under CC BY 4.0)*

In the absence of iodine deficiency, inflammation of the thyroid gland is the more common cause of low blood levels of thyroid hormones. Called hypothyroidism, the condition is characterized by a low metabolic rate, weight gain, cold extremities, constipation, reduced libido, menstrual irregularities, and intellectual disability.

In contrast, hyperthyroidism—an abnormally elevated blood level of thyroid hormones—is often caused by a pituitary or thyroid tumor. In Graves' disease, the hyperthyroid state results from an autoimmune reaction in which antibodies overstimulate the follicle cells of the thyroid gland. Hyperthyroidism can lead to an increased metabolic rate, excessive body heat and sweating, diarrhea, weight loss, tremors, and increased heart rate. The person's eyes may bulge (called exophthalmos) as antibodies produce inflammation in the soft tissues of the orbits.

Calcitonin

The thyroid gland also secretes a hormone called **calcitonin** that is produced by the parafollicular cells (also called clear cells or C cells) that stud the tissue between distinct follicles (Figure 15.4.2 and Figure 15.4.3). Calcitonin is released in response to a rise in blood calcium levels.

The hormones secreted by the thyroid gland are summarized in Table 15.4.1.

Parathyroid Glands

The **parathyroid glands** are tiny, round structures usually found embedded in the posterior surface of the thyroid gland (Figure 15.4.5). A thick connective tissue capsule separates the glands from the thyroid tissue. Most people have four parathyroid glands, but occasionally there are more in tissues of the neck or chest.

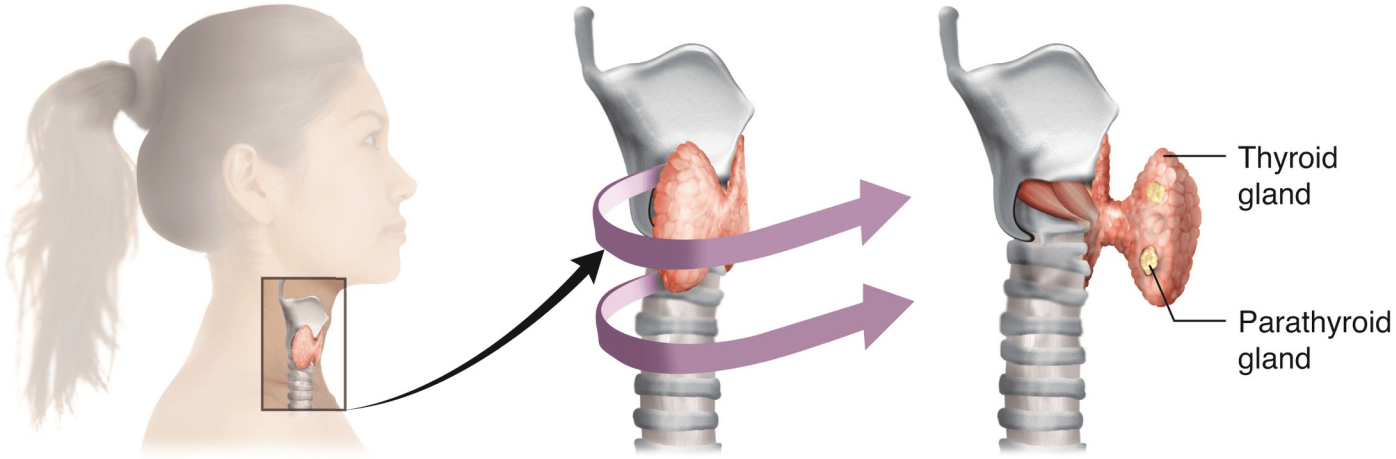

Figure 15.4.5: The Parathyroid Glands. Typically four parathyroid glands are embedded in the posterior surface of the thyroid gland alongside the superior portion of the trachea, two on the left and two on the right, with the superior set just inferior to the cricoid cartilage of the larynx. *(Image credit: "KnowledgeWorks - Drawing Location of the parathyroid glands - English labels" by KnowledgeWorks Global Ltd. is licensed under CC BY.)*

The primary functional cells of the parathyroid glands are the chief cells. These epithelial cells produce and secrete **parathyroid hormone (PTH)**, a major hormone involved in the regulation of blood calcium levels (Figure 15.4.6). When blood calcium levels drop too low, PTH is released from the parathyroid glands into the bloodstream. Parathyroid hormone encourages the release of stored calcium from the bones and stimulates the kidneys to reabsorb calcium. In bones, PTH inhibits osteoblast activity while stimulating osteoclast activity, resulting in calcium being released from bone matrix into the bloodstream. In the kidneys, PTH stimulates an increase in calcium reabsorption into the bloodstream and also stimulates the release of **calcitriol**. Calcitriol targets the intestines to stimulate increased absorption of calcium from food. The hormone secreted by the parathyroid glands is summarized in Table 15.4.1.

DISORDERS OF THE...

Endocrine System: Hyperparathyroidism and Hypoparathyroidism

Abnormally high activity of the parathyroid gland can cause **hyperparathyroidism**, a disorder caused by an overproduction of PTH that results in excessive calcium reabsorption from bone. Hyperparathyroidism can significantly decrease bone density, leading to spontaneous fractures or deformities. As blood calcium levels rise, cell membrane permeability to sodium is decreased, and the responsiveness of the nervous system is reduced. At the same time, calcium deposits may collect in the body's tissues and organs, impairing their functioning.

In contrast, abnormally low blood calcium levels may be caused by parathyroid hormone deficiency, called **hypoparathyroidism**, which may develop following injury or surgery involving the thyroid gland. Low blood calcium increases membrane permeability to sodium, resulting in muscle twitching, cramping, spasms, or convulsions. Severe deficits can paralyze muscles, including those involved in breathing, and can be fatal.

Concept Review

The thyroid gland is a butterfly-shaped organ located in the neck anterior to the trachea. The parathyroid glands are four small nodules on the posterior surface of the thyroid gland.

Calcium is required for a variety of important physiologic processes, including neuromuscular functioning; thus, blood calcium levels are closely regulated. The parathyroid glands are small structures located on the posterior of the thyroid gland that produce parathyroid hormone (PTH), which regulates blood calcium levels. Low blood calcium levels cause the production and secretion of PTH. In contrast, elevated blood calcium levels trigger secretion of the thyroid hormone calcitonin.

Thyroid hormones regulate basal metabolism, oxygen use, nutrient metabolism, the production of ATP, and calcium homeostasis. The thyroid hormones triiodothyronine (T_3) and thyroxine (T_4) are produced and secreted by the follicular cells in response to

thyroid-stimulating hormone (TSH) from the anterior pituitary. Synthesis of the amino acid–derived T_3 and T_4 hormones requires iodine. Insufficient amounts of iodine in the diet can lead to goiter and many other disorders.

The parathyroid glands are embedded in the posterior surface of the thyroid gland alongside the superior portion of the trachea, two on the left and two on the right, with the superior set just inferior to the cricoid cartilage of the larynx.

Table* 15.4.1*: Thyroid and Parathyroid Hormones

Associated hormones	Target(s)	Effect(s)	Associated Disorders
Thyroid Hormone: Thyroxine (T_4), triiodothyronine (T_3)	Most body cells	Stimulate basal metabolic rate	Hypothyroidism: goiter Hyperthyroidism: Graves disease
Calcitonin	Bones, kidneys	Reduces blood Ca^{+2} levels; increases Ca^{+2} deposition in bone	Hypersecretion: increased risk of some cancers; renal failure
Parathyroid Hormone	Bones, kidneys	Increases blood Ca^{+2} levels; decreases Ca^{+2} deposition in bone	Hypersecretion: increased risk of fractures, kidney stones, constipation; decreased mental activity and coma.

Review Questions

Query 15.4.1

This interactive element is not available in this format. Visit the link or scan the QR code to access it online.

View this Interactive Content online

Query 15.4.2

This interactive element is not available in this format. Visit the link or scan the QR code to access it online.

View this Interactive Content online

Critical Thinking Questions

Query 15.4.3

This interactive element is not available in this format. Visit the link or scan the QR code to access it online.

View this Interactive Content online

Query 15.4.4

This interactive element is not available in this format. Visit the link or scan the QR code to access it online.

View this Interactive Content online

Glossary

Query 15.4.5

This interactive element is not available in this format. Visit the link or scan the QR code to access it online.

View this Interactive Content online

Contributors and Attributions

- OpenStax Anatomy & Physiology (CC BY 4.0). Access for free at https://openstax.org/books/anatomy-and-physiology

This page titled 15.4: Thyroid Gland and Parathyroid Glands is shared under a CC BY-NC-SA 4.0 license and was authored, remixed, and/or curated by Jennifer Lange et al..

- 15.4: Thyroid Gland by Whitney Menefee, Julie Jenks, Chiara Mazzasette, and Kim-Leiloni Nguyen is licensed CC BY 4.0.
- 15.5: Parathyroid Glands by Whitney Menefee, Julie Jenks, Chiara Mazzasette, and Kim-Leiloni Nguyen is licensed CC BY 4.0.

15.5: Adrenal Glands

By the end of this section, you will be able to:

- Describe the location and structure of the adrenal glands
- Identify the hormones produced by the adrenal cortex and adrenal medulla, and summarize their target cells and effects

The **adrenal glands**, also known as the suprarenal glands, are wedges of glandular and neuroendocrine tissue adhering to the top of the kidneys by a fibrous capsule of dense connective tissue (Figure 15.5.1). The adrenal glands have a rich blood supply and experience one of the highest rates of blood flow in the body. Adrenal hormones are released into the circulation via the left and right suprarenal veins. The adrenal gland consists of an outer cortex and an inner medulla.

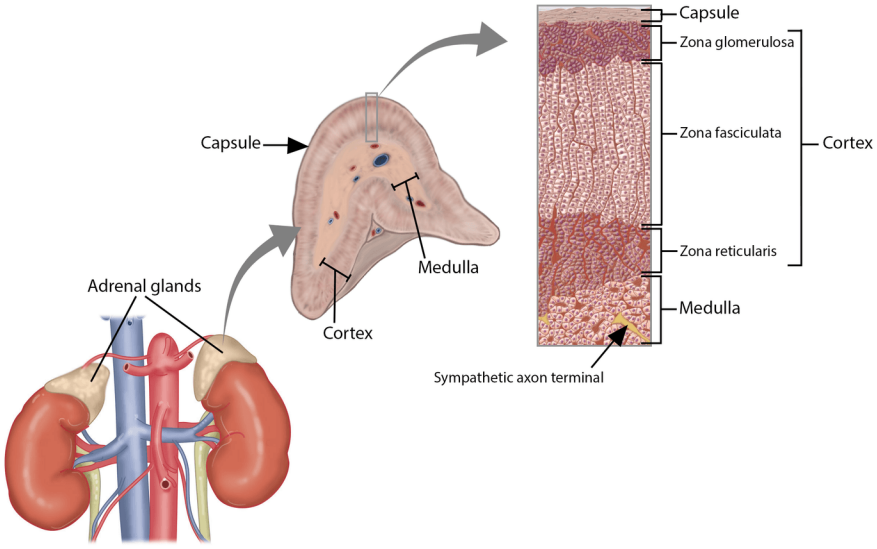

Figure 15.5.1: The Adrenal Glands. Both adrenal glands sit atop the kidneys and are composed of an outer cortex and an inner medulla, all surrounded by a connective tissue capsule. The cortex can be subdivided into additional zones. *(Image credit: "The Adrenal Glands" by Jennifer Lange is licensed under CC BY-NC-SA 4.0; includes section of "Slagter - Drawing Anatomy of the kidney, adrenal glands and bladder - no labels" by Ron Slagter, license: CC BY-NC-SA.)*

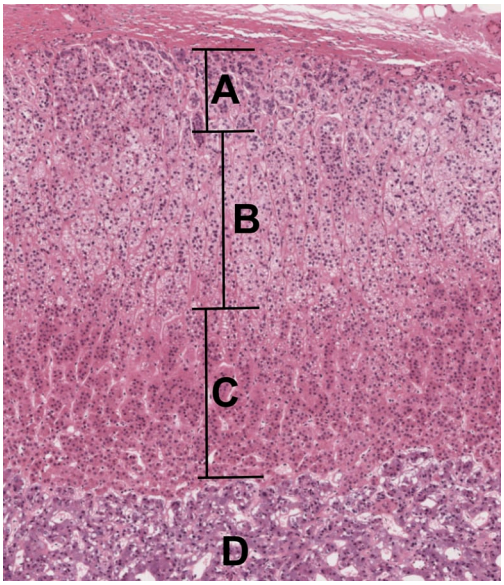

Figure 15.5.2:The Adrenal Gland slide. The adrenal gland is locacted on top of each kidney. The histolgy seen here shows the different parts of the gland that is responsible for the production of different types of hormones. A - Zona Glomerulosa, B - Zona Fasciculata, C - Zona Reticularis, and D - Medulla. (*Image credit: "Histology of Adrenal Gland" by Yancy Aquino is licensed under CC BY-NC-SA 4.0, slide provided by the Regents of the University of Michigan Medical School © 2022 under CC BY-NC-SA 3.0.*)

STRESS!

One of the major functions of the adrenal gland is to respond to stress. Stress can be either physical or psychological or both. Physical stresses include exposing the body to injury, walking outside in cold and wet conditions without a coat on, or malnutrition. Psychological stresses include the perception of a physical threat, a fight with a loved one, or just a bad day at school.

The body responds in different ways to short-term stress and long-term stress following a pattern known as the **general adaptation syndrome (GAS)**. Stage one of GAS is called the **alarm reaction**. This is short-term stress, the fight-or-flight response, mediated by the hormones epinephrine and norepinephrine from the adrenal medulla. Their function is to prepare the body for extreme physical exertion. Both epinephrine and norepinephrine signal the liver and skeletal muscle cells to convert glycogen into glucose, resulting in increased blood glucose levels. These hormones increase the heart rate, pulse, and blood pressure to prepare the body to fight the perceived threat or flee from it. In addition, the pathway dilates the airways, raising blood oxygen levels. It also prompts vasodilation, further increasing the oxygenation of important organs such as the lungs, brain, heart, and skeletal muscle. At the same time, it triggers vasoconstriction to blood vessels serving less essential organs such as the gastrointestinal tract, kidneys, and skin, and down regulates some components of the immune system. Other effects include a dry mouth, loss of appetite, pupil dilation, and a loss of peripheral vision.Once this stress is relieved, the body quickly returns to normal.

If the stress is not relieved quickly, the body adapts to the stress in the second stage called the **stage of resistance**. If a person is starving for example, the body may send signals to the gastrointestinal tract to maximize the absorption of nutrients from food.

If the stress continues for a longer term however, the body responds with symptoms quite different than the fight-or-flight response. During the **stage of exhaustion**, individuals may begin to suffer depression, the suppression of their immune response, severe fatigue, or even a fatal heart attack. These symptoms are mediated by the hormones of the adrenal cortex, especially cortisol.

The Adrenal Cortex

The adrenal cortex consists of multiple layers of lipid-storing cells that occur in three structurally distinct regions: the **zona**

glomerulosa, the **zona fasciculata**, and the **zona reticularis**. Each region secretes its own set of steroid hormones important for the regulation of the long-term stress response, blood pressure and blood volume, nutrient uptake and storage, fluid and electrolyte balance, and inflammation.

Hormones of the Zona Glomerulosa

The most superficial region of the adrenal cortex is the zona glomerulosa, which produces a group of hormones collectively referred to as **mineralocorticoids** because of their effect on body minerals, especially sodium and potassium. These hormones are essential for fluid and electrolyte balance.

Aldosterone is the major mineralocorticoid. It is important in the regulation of the concentration of sodium (Na^+) and potassium (K^+) ions in urine, sweat, and saliva. For example, it is released in response to elevated blood K^+, low blood Na^+, low blood pressure, or low blood volume. In response, aldosterone increases the excretion of K^+ and the retention of Na^+, which in turn increases blood volume and blood pressure. Its secretion is prompted when CRH from the hypothalamus triggers ACTH release from the anterior pituitary.

Aldosterone is also a key component of the renin-angiotensin-aldosterone system (RAAS) in which specialized cells of the kidneys secrete the enzyme renin in response to low blood volume or low blood pressure. Renin the triggers and enzymatic cascade that results in the production of angiotensin II, which has three major functions:

1. Initiating vasoconstriction of the arterioles, decreasing blood flow;
2. Stimulating kidney tubules to reabsorb NaCl and water, increasing blood volume;
3. Signaling the adrenal cortex to secrete aldosterone, the effects of which further contribute to fluid retention, restoring blood pressure and blood volume.

For individuals with hypertension, or high blood pressure, drugs are available that block the production of angiotensin II. These drugs, known as ACE inhibitors, block the enzyme that produces angiotensin II, thus mitigating the latter's ability to increase blood pressure.

Hormones of the Zona Fasciculata

The intermediate region of the adrenal cortex is the zona fasciculata, named as such because the cells form small fascicles (bundles) separated by tiny blood vessels. These cords of cells are oriented perpendicular to the surface of the organ. The cells of the zona fasciculata produce hormones called **glucocorticoids** because of their role in glucose metabolism. The most important of these is **cortisol**, some of which the liver converts to cortisone. In response to long-term stressors, the hypothalamic-pituitary-adrenal (HPA) axis activates: 1) the hypothalamus secretes CRH, which 2) triggers the release of ACTH by the anterior pituitary, and 3) ACTH triggers the release of the glucocorticoids. The overall effect is to inhibit tissue building while stimulating the breakdown of stored nutrients to maintain adequate fuel supplies. In conditions of long-term stress, for example, cortisol promotes the catabolism of glycogen to glucose, the catabolism of stored triglycerides into fatty acids and glycerol, and the catabolism of muscle proteins into amino acids. The hippocampus, which is part of the temporal lobe of the cerebral cortices and important in memory formation, is highly sensitive to stress levels because of its many glucocorticoid receptors.

You are probably familiar with prescription and over-the-counter medications containing glucocorticoids, such as cortisone injections into inflamed joints, prednisone tablets and steroid-based inhalers used to manage severe asthma, and hydrocortisone creams applied to relieve itchy skin rashes. These drugs reflect another role of cortisol—the down regulation of the immune system, which inhibits the inflammatory response.

Hormones of the Zona Reticularis

The deepest region of the adrenal cortex is the zona reticularis, which produces small amounts of a class of steroid sex hormones called androgens. During puberty and most of adulthood, androgens are produced in the gonads. The androgens produced in the zona reticularis supplement the gonadal androgens. They are produced in response to ACTH from the anterior pituitary and are converted in the tissues to testosterone or estrogens. After menopause in those with ovaries, as the functions of the ovaries decline, the main source of estrogens becomes the androgens produced by the zona reticularis.

Table 15.5.1: Hormones of the Adrenal Glands

Adrenal gland region	Associated hormones	Effect
Adrenal cortex (Zona Glomerulosa)	Aldosterone	Increases blood Na^+ levels
Adrenal cortex (Zona Fasciculata)	Cortisol, corticosterone, cortisone	Increase blood glucose levels
Adrenal cortex (Zona Reticularis)	Androgens	Supplement gonadal androgens
Adrenal medulla	Epinephrine, norepinephrine	Stimulate fight-or-flight response

The Adrenal Medulla

The **adrenal medulla** is the central portion of the adrenal gland composed of **chromaffin cells**, which are modified postganglionic sympathetic neurons. The adrenal medulla develops from neural crest cells, which are also the origin of sympathetic ganglia. These cells secrete epinephrine and norepinephrine into the bloodstream and have the general effect of preparing the body for fight or flight. The adrenal medulla has features of both the neural and endocrine systems: it is made of modified neural tissue and its activity is regulated by a direct neural input, while the outputs are released into blood and act at distant sites by activating specific receptors. The actions of the medullary hormones are far more rapid and short-lived than those of most "classic" hormones.

DISORDERS OF THE...

Endocrine System: Disorders Involving the Adrenal Glands

Several disorders are caused by the dysregulation of the hormones produced by the adrenal glands. For example, Cushing's disease is a disorder characterized by high blood glucose levels and the accumulation of lipid deposits on the face and neck. It is caused by hypersecretion of cortisol. The most common source of Cushing's disease is a pituitary tumor that secretes cortisol or ACTH in abnormally high amounts. Other common signs of Cushing's disease include the development of a moon-shaped face, a buffalo hump on the back of the neck, rapid weight gain, and hair loss. Chronically elevated glucose levels are also associated with an elevated risk of developing type 2 diabetes. In addition to hyperglycemia, chronically elevated glucocorticoids compromise immunity, resistance to infection, and memory, and can result in rapid weight gain and hair loss.

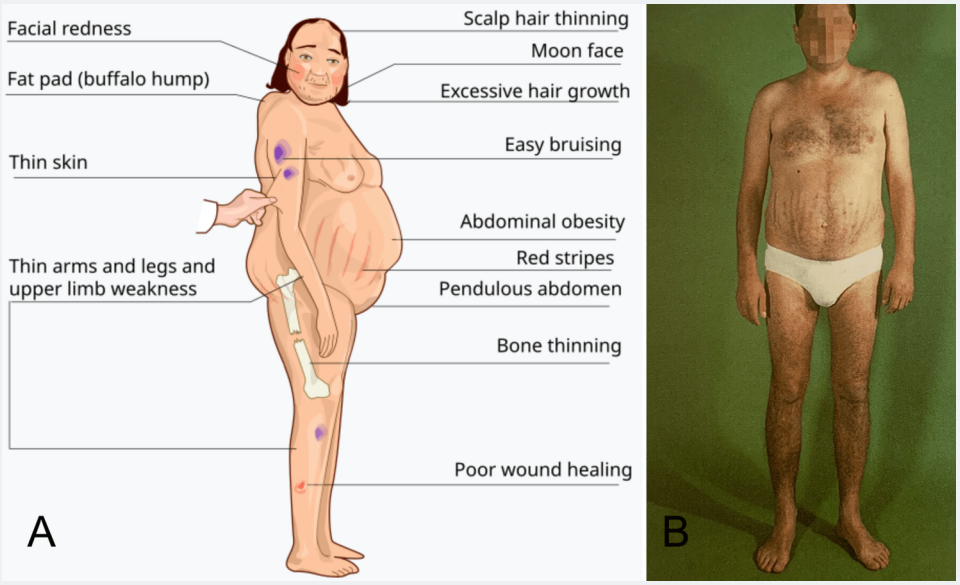

Figure 15.5.3: A. The different symptoms of a person with Cushing's syndrome. B. A picture of a person with Cushing's syndrome showing the prominent stretch marks on the abdomen. *(Image credit: "A. Cushing Syndrome Symptoms" and "B. Cushign Syndrome" by Yancy Aquino is licensed under CC BY-NC-SA 4.0, modification of original by OpenStax.)*

In contrast, the hyposecretion of corticosteroids can result in Addison's disease, a rare disorder that causes low blood glucose levels and low blood sodium levels. The signs and symptoms of Addison's disease are vague and are typical of other disorders as well, making diagnosis difficult. They may include general weakness, abdominal pain, weight loss, nausea, vomiting, sweating, and cravings for salty food.



Figure 15.5.4: Addison's Disease. A 69-year-old female with tiredness and a persistent tan. Facial appearance at presentation (left), showing pigmentation, and after treatment (right). *(Image credit: "Addison's Disease" by Yancy Aquino is licensed under CC BY-NC-SA 4.0, modification of original by OpenStax.)*

Concept Review

The adrenal glands, located superior to each kidney, consist of two regions: the adrenal cortex and adrenal medulla. The adrenal cortex—the outer layer of the gland—produces mineralocorticoids, glucocorticoids, and androgens. The adrenal medulla, at the core of the gland, produces epinephrine and norepinephrine.

The adrenal glands mediate a short-term stress response and a long-term stress response. A perceived threat results in the secretion of epinephrine and norepinephrine from the adrenal medulla, which mediate the fight-or-flight response. The long-term stress response is mediated by the secretion of CRH from the hypothalamus, which triggers ACTH, which in turn stimulates the secretion of corticosteroids from the adrenal cortex. The mineralocorticoids, chiefly aldosterone, cause sodium and fluid retention, which increases blood volume and blood pressure.

Review Questions

Query 15.5.1

This interactive element is not available in this format. Visit the link or scan the QR code to access it online.

View this Interactive Content online

Critical Thinking Questions

Query 15.5.2

This interactive element is not available in this format. Visit the link or scan the QR code to access it online.

View this Interactive Content online

Glossary

Query 15.5.3

This interactive element is not available in this format. Visit the link or scan the QR code to access it online.

View this Interactive Content online

Contributors and Attributions

- OpenStax Anatomy & Physiology (CC BY 4.0). Access for free at https://openstax.org/books/anatomy-and-physiology

This page titled 15.5: Adrenal Glands is shared under a CC BY-NC-SA 4.0 license and was authored, remixed, and/or curated by Jennifer Lange et al..

- 15.6: Adrenal Glands by Whitney Menefee, Julie Jenks, Chiara Mazzasette, and Kim-Leiloni Nguyen is licensed CC BY 4.0.

15.6: Pineal Gland

By the end of this section, you will be able to:

- Describe the location and structure of the pineal gland
- Discuss the function of melatonin

Recall that the hypothalamus, part of the diencephalon of the brain, sits inferior and somewhat anterior to the thalamus. Inferior but somewhat posterior to the thalamus is the **pineal gland**, a tiny endocrine gland whose functions are not entirely clear. The **pinealocyte** cells that make up the pineal gland are known to produce and secrete the hormone **melatonin**, which is derived from serotonin.

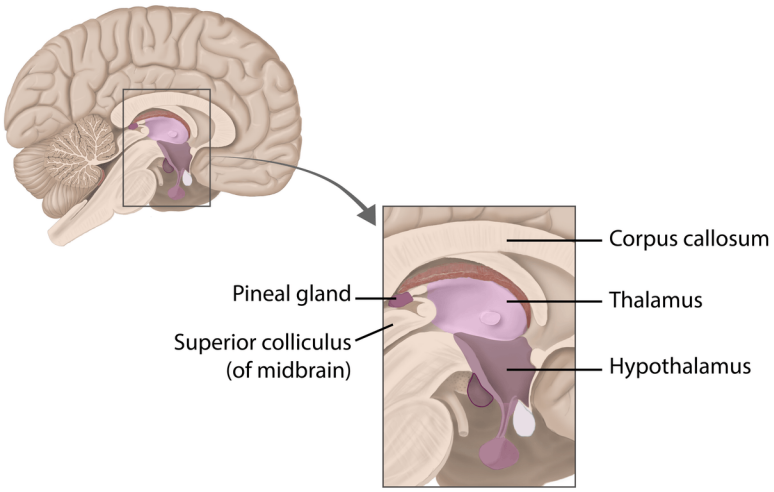

Figure 15.6.1: The Pineal Gland. The pineal gland is situated posterior to the thalamus, inferior to the tail of the corpus callosum, and superior to the superior colliculus. *(Image credit: "Diencephalon - Pineal Gland" by Jennifer Lange and Justin Greene is licensed under CC BY-NC-SA 4.0.)*

The secretion of melatonin varies according to the level of light received from the environment. When photons of light stimulate the retinas of the eyes, a nerve impulse is sent to a region of the hypothalamus called the suprachiasmatic nucleus (SCN), which is important in regulating biological rhythms. From the SCN, the nerve signal is carried to the spinal cord and eventually to the pineal gland, where the production of melatonin is inhibited. As a result, blood levels of melatonin fall, promoting wakefulness. In contrast, as light levels decline—such as during the evening—melatonin production increases, boosting blood levels and causing drowsiness.

The secretion of melatonin may influence the body's circadian rhythms, the dark-light fluctuations that affect not only sleepiness and wakefulness, but also appetite and body temperature. Interestingly, children have higher melatonin levels than adults, which may prevent the release of gonadotropins from the anterior pituitary, thereby inhibiting the onset of puberty. Finally, an antioxidant role of melatonin is the subject of current research.

Jet lag occurs when a person travels across several time zones and feels sleepy during the day or wakeful at night. Traveling across multiple time zones significantly disturbs the light-dark cycle regulated by melatonin. It can take up to several days for melatonin synthesis to adjust to the light-dark patterns in the new environment, resulting in jet lag. Some air travelers take melatonin supplements to induce sleep.

Concept Review

The pineal gland is an endocrine structure of the diencephalon of the brain, and is located inferior and posterior to the thalamus. It is made up of pinealocytes. These cells produce and secrete the hormone melatonin in response to low light levels. High blood levels of melatonin induce drowsiness. Jet lag, caused by traveling across several time zones, occurs because melatonin synthesis takes several days to readjust to the light-dark patterns in the new environment.

Review Questions

Query 15.6.1

This interactive element is not available in this format. Visit the link or scan the QR code to access it online.

View this Interactive Content online

Critical Thinking Questions

Query 15.6.2

This interactive element is not available in this format. Visit the link or scan the QR code to access it online.

View this Interactive Content online

Query 15.6.3

This interactive element is not available in this format. Visit the link or scan the QR code to access it online.

View this Interactive Content online

Glossary

Query 15.6.4

This interactive element is not available in this format. Visit the link or scan the QR code to access it online.

View this Interactive Content online

Contributors and Attributions

- OpenStax Anatomy & Physiology (CC BY 4.0). Access for free at https://openstax.org/books/anatomy-and-physiology

This page titled 15.6: Pineal Gland is shared under a CC BY-NC-SA 4.0 license and was authored, remixed, and/or curated by Jennifer Lange et al..

- 15.7: Pineal Gland by Whitney Menefee, Julie Jenks, Chiara Mazzasette, and Kim-Leiloni Nguyen is licensed CC BY 4.0.

15.7: Gonadal and Placental Hormones

By the end of this section, you will be able to:

- Identify the primary hormones produced by the testes and the ovaries and explain their functions
- Identify the cells in the ovaries and testes that produce these hormones
- Name the hormones produced by the placenta and state their functions

This section briefly discusses the hormonal role of the gonads—the testes and ovaries—which produce the sex cells (sperm and ova, respectively) and secrete the gonadal hormones (Table 15.7.1). The roles of the gonadotropins released from the anterior pituitary (FSH and LH) were discussed earlier. The anatomy of these organs is covered in more detail in the Reproductive System chapter.

Hormones of the Testes

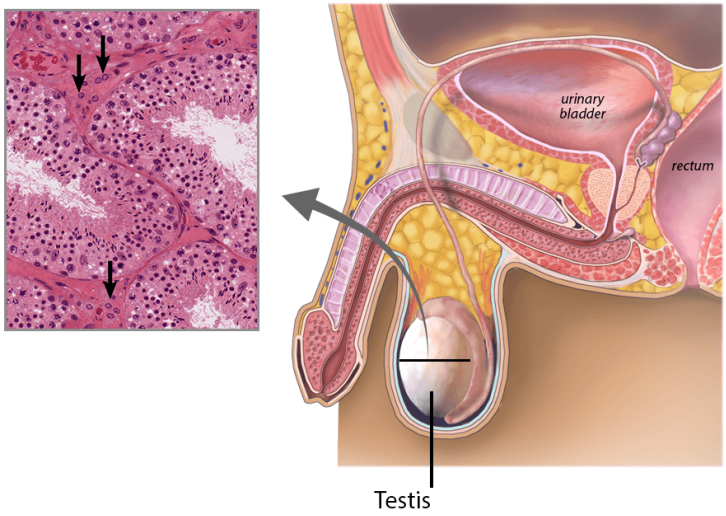

Figure 15.7.1: Testes - Interstitial Cells. The testosterone producing interstitial cells (arrows) of the testes are located in the connective tissue between the tubules with developing sperm. *(Image credit: "Varicocele" by BruceBlaus is licensed under CC BY-SA 4.0, modifications and labeling by Jennifer Lange. Micrograph by Digital Histology is licensed under CC BY-NC-SA 4.0.)*

The primary hormone of the testes is **testosterone**, which produced by the **interstitial cells** (of Leydig) (Figure 15.7.1). Testosterone is a steroid hormone important in the development of the male reproductive system, the maturation of sperm cells, and the development of male secondary sex characteristics such as a deepened voice, body hair, and increased muscle mass. Interestingly, testosterone is also produced in the ovaries, but at a much reduced level. In addition, the testes produce the peptide hormone **inhibin**, which inhibits the secretion of FSH from the anterior pituitary gland. FSH stimulates spermatogenesis, or sperm cell production.

Hormones of the Ovaries

The primary hormones produced by the ovaries are **estrogens**, which include estradiol, estriol, and estrone. Estrogens play an important role in a larger number of physiological processes, including the development of the female reproductive system, regulation of the menstrual cycle, the development of female secondary sex characteristics such as increased adipose tissue and the development of breast tissue, and the maintenance of pregnancy. Another significant ovarian hormone is **progesterone**, which contributes to regulation of the menstrual cycle and is important in preparing the body for pregnancy as well as maintaining pregnancy. In addition, the granulosa cells of the ovarian follicles produce inhibin, which—as in those with testes—inhibits the

secretion of FSH.

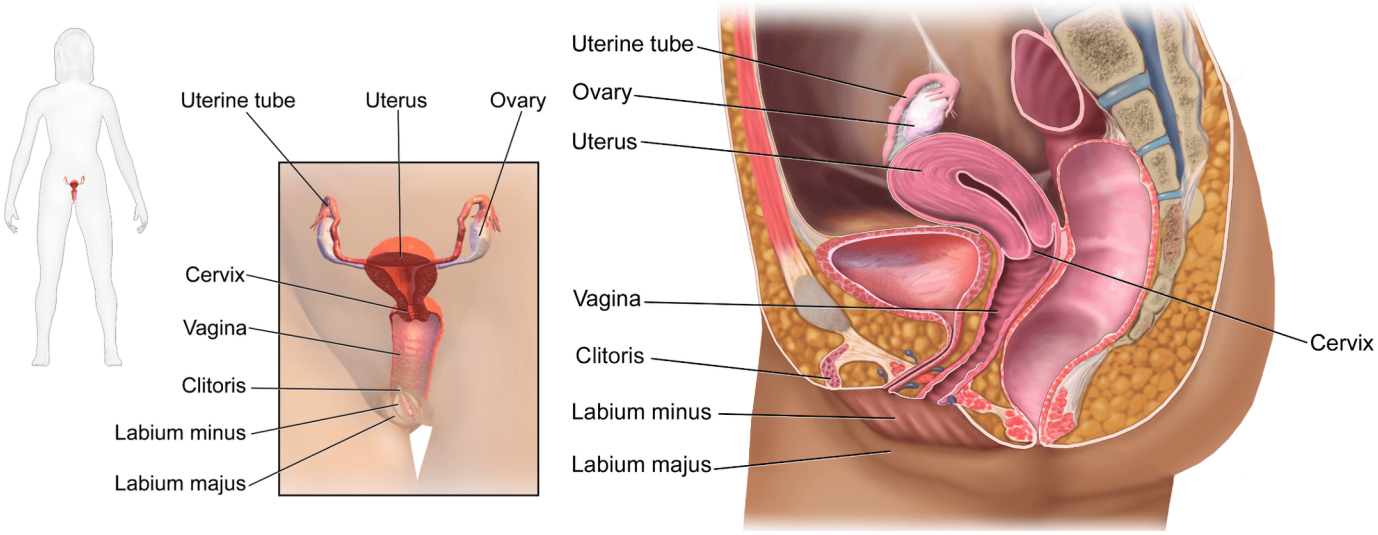

Figure 15.7.3: Female Reproductive System. The major organs of the female reproductive system are located inside the pelvic cavity. *(Image credit: "Female Reproductive System - Anterior and Midsagittal" by Blausen.com staff (2014), from the Medical gallery of Blausen Medical 2014, WikiJournal of Medicine, is licensed under CC BY 3.0. Modifications by Jennifer Lange.)*

Hormones of the Placenta

During the initial stages of pregnancy, an organ called the placenta develops within the uterus. The placenta supplies oxygen and nutrients to the fetus, excretes waste products, and produces and secretes estrogens and progesterone. The placenta produces **human chorionic gonadotropin** (hCG) as well. The hCG hormone promotes progesterone synthesis and reduces the mother's immune function to protect the fetus from immune rejection. The hormones controlling reproduction are summarized in Table 15.7.1.

Table* 15.7.1*: Reproductive Hormones

Organ	Associated hormones	Effect
Testes	Testosterone	Stimulates development of male secondary sex characteristics and sperm production
Testes	Inhibin	Inhibits FSH release from pituitary
Ovaries	Estrogens and progesterone	Stimulate development of female secondary sex characteristics and prepare the body for childbirth
Placenta	Human chorionic gonadotropin	Promotes progesterone synthesis during pregnancy and inhibits immune response against fetus

EVERYDAY CONNECTIONS

Anabolic Steroids

The endocrine system can be exploited for illegal or unethical purposes. A prominent example of this is the use of steroid drugs by professional athletes.

Commonly used for performance enhancement, anabolic steroids are synthetic versions of the sex hormone testosterone. By boosting natural levels of this hormone, athletes experience increased muscle mass. Synthetic versions of human growth hormone are also used to build muscle mass.

The use of performance-enhancing drugs is banned by all major collegiate and professional sports organizations in the United States because they impart an unfair advantage to athletes who take them. In addition, the drugs can cause significant and dangerous side effects. For example, anabolic steroid use can increase cholesterol levels, raise blood pressure, and damage the liver. Altered testosterone levels (both too low or too high) have been implicated in causing structural damage to the heart, and increasing the risk for cardiac arrhythmias, heart attacks, congestive heart failure, and sudden death. Paradoxically, steroids can cause shriveled testes and enlarged breast tissue in men. In females, their use can cause analogous effects such as an enlarged clitoris and growth of facial hair. In both sexes, their use can promote increased aggression (commonly known as “roid-rage”), depression, sleep disturbances, severe acne, and infertility.

Concept Review

The reproductive system in both males and females is regulated by follicle-stimulating hormone (FSH) and luteinizing hormone (LH, also called interstitial cell stimulating hormone or ICSH in males) produced by the anterior lobe of the pituitary gland in response to gonadotropin-releasing hormone (GnRH) from the hypothalamus. In males, FSH stimulates sperm maturation, which is inhibited by the hormone inhibin. The steroid hormone testosterone, a type of androgen, is released in response to ICSH and is responsible for the maturation and maintenance of the reproductive system, as well as the development of male secondary sex characteristics. In females, FSH promotes egg maturation and LH signals the secretion of sex hormones: estrogens and progesterone. Both of these hormones are important in the development and maintenance of the female reproductive system, as well as maintaining pregnancy. The placenta develops during early pregnancy, and secretes several hormones important for maintaining the pregnancy.

Review Questions

Query 15.7.1

This interactive element is not available in this format. Visit the link or scan the QR code to access it online.

View this Interactive Content online

Critical Thinking Questions

Query 15.7.2

This interactive element is not available in this format. Visit the link or scan the QR code to access it online.

View this Interactive Content online

Glossary

Query 15.7.3

This interactive element is not available in this format. Visit the link or scan the QR code to access it online.

View this Interactive Content online

Contributors and Attributions

- OpenStax Anatomy & Physiology (CC BY 4.0). Access for free at https://openstax.org/books/anatomy-and-physiology

This page titled 15.7: Gonadal and Placental Hormones is shared under a CC BY-NC-SA 4.0 license and was authored, remixed, and/or curated by Jennifer Lange et al..

- 15.8: Gonadal and Placental Hormones by Whitney Menefee, Julie Jenks, Chiara Mazzasette, and Kim-Leiloni Nguyen is licensed CC BY 4.0.

15.8: Endocrine Pancreas

By the end of this section, you will be able to:

- Describe the location and structure of the pancreas, and the morphology and function of the pancreatic islets
- Compare and contrast the functions of insulin and glucagon

The **pancreas** is a long, slender retroperitoneal organ, most of which is located posterior to the bottom half of the stomach (Figure 15.8.1). It is bordered on its right by the retroperitoneal section of the duodenum and on its left by the spleen. The acinar cells of the pancreas line many short cul-de-sac-shaped areas connected directly to the pancreatic duct that drains transversely through the core of the pancreas to the duodenum nestled against its right side. Although it is primarily an exocrine gland, with its acinar cells secreting a variety of digestive enzymes that comprise pancreatic juice that will function outside the epithelial lining of the small intestine, the pancreas also has an endocrine function. Scattered around the cul-de-sacs of acinar cells throughout the pancreas are about a million **pancreatic islets**—clusters of cells formerly known as the islets of Langerhans— that secrete the hormones glucagon, insulin, somatostatin, and pancreatic polypeptide (PP).

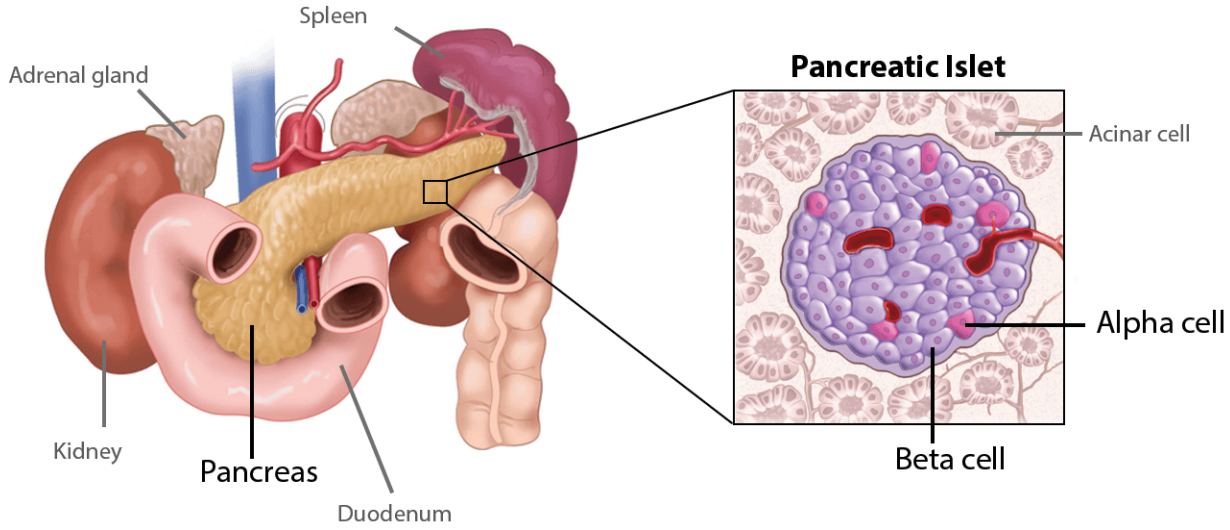

Figure 15.8.1: The Pancreas. The endocrine portion of the pancreas is small clusters of cells called pancreatic islets. Multiple hormones are secreted by the islets, with the two regulating blood glucose levels coming from the beta cells (insulin) and alpha cells (glucagon). *(Image credit: "Endocrine Pancreas" by Jennifer Lange is licensed under CC BY-NC-SA 4.0, derivatives of original works "Leiden - Drawing pancreas and neighbouring organs - no labels" by Ron Slagter and "Endocrine Pancreas" by Cenveo.)*

Cells and Secretions of the Pancreatic Islets

Each pancreatic islet (Figure 15.8.1 and Figure 15.8.2) contains four types of cells whose secretions move into the bloodstream to travel to their target cells:

- The **alpha cell** produces the hormone glucagon and makes up approximately 20 percent of each islet. Glucagon plays an important role in blood glucose regulation; low blood glucose levels stimulate its release.
- The **beta cell** produces the hormone insulin and makes up approximately 75 percent of each islet. Elevated blood glucose levels stimulate the release of insulin.
- The **delta cell** accounts for four percent of the islet cells and secretes the peptide hormone somatostatin. Recall that somatostatin is also released by the hypothalamus (as GHIH), and the stomach and intestines also secrete it. An inhibiting hormone, pancreatic somatostatin inhibits the release of both glucagon and insulin.
- The **PP cell** accounts for about one percent of islet cells and secretes the pancreatic polypeptide hormone. It is thought to play a role in appetite, as well as in the regulation of pancreatic exocrine and endocrine secretions. Pancreatic polypeptide

released following a meal may reduce further food consumption; however, it is also released in response to fasting.

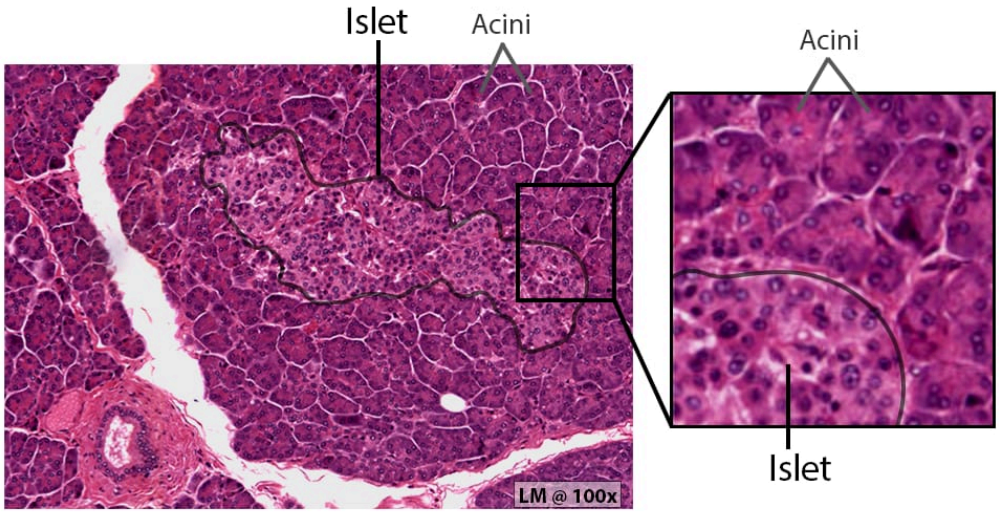

Figure 15.8.2: Histology of the Pancreas. On slides the pancreatic islets are seen as clusters of smaller, lighter staining cells that the surrounding blocks of acini (acinar cells). *(Image credit: "Histology of the Pancreas" by Jennifer Lange is licensed under CC BY-NC-SA 4.0, slide provided by the Regents of the University of Michigan Medical School © 2022.)*

Regulation of Blood Glucose Levels by Insulin and Glucagon

Glucose is required for cellular respiration and is the preferred fuel for all body cells. The body derives glucose from the breakdown of the carbohydrate-containing foods and drinks we consume. Glucose not immediately taken up by cells for fuel can be stored by the liver and muscles as glycogen, or converted to triglycerides and stored in the adipose tissue. Hormones regulate both the storage and the utilization of glucose as required. Receptors located in the pancreas sense blood glucose levels, and subsequently the pancreatic cells secrete glucagon or insulin to maintain normal levels.

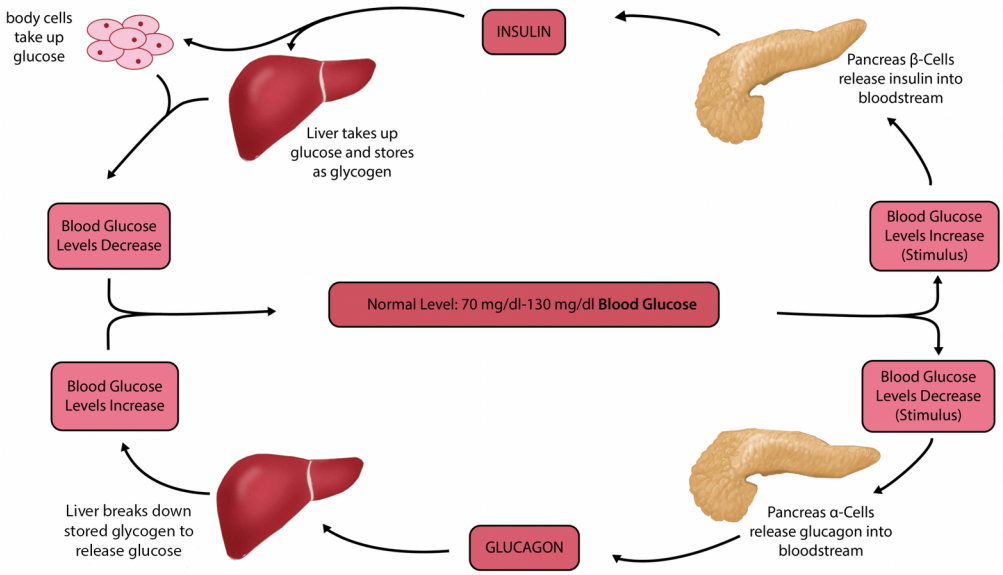

Figure 15.8.3: Glucose Homeostasis. Blood glucose levels are regulated by two pancreatic hormones that act antagonistically. *(Image credit: "Glucose Homeostasis" by Gabrielle Spurlock is licensed under CC BY-NC-SA 4.0. Pancreas image by Ron Slagter; liver image by Ron Slagter.)*

INTERACTIVE LINK

Pancreas Location and Endocrine Function

Query 15.8.1

This interactive element is not available in this format. Visit the link or scan the QR code to access it online.

View this Interactive Content online

Table 15.8.1: Hormones of the Pancreas

Associated hormone (and the cells that secretes it)	Effect
Insulin (beta cells)	Reduces blood glucose levels
Glucagon (alpha cells)	Increases blood glucose levels
Somatostatin (delta cells)	Inhibits insulin and glucagon release

DISORDERS OF THE...

Endocrine System: Diabetes Mellitus

Dysfunction of insulin production and secretion, as well as the target cells' responsiveness to insulin, can lead to a condition called diabetes mellitus. An increasingly common disease, diabetes mellitus has been diagnosed in more than 18 million adults in the United States, and more than 200,000 children. It is estimated that up to 7 million more adults have the condition but have not been diagnosed. In addition, approximately 79 million people in the US are estimated to have pre-diabetes, a condition in which blood glucose levels are abnormally high, but not yet high enough to be classified as diabetes.

There are two main forms of diabetes mellitus. Type 1 diabetes is an autoimmune disease affecting the beta cells of the pancreas. Certain genes are recognized to increase susceptibility. The beta cells of people with type 1 diabetes do not produce insulin; thus, synthetic insulin must be administered by injection or infusion. This form of diabetes accounts for less than five percent of all diabetes cases.

Type 2 diabetes accounts for approximately 95 percent of all cases. It is acquired, and lifestyle factors such as poor diet, inactivity, and the presence of pre-diabetes greatly increase a person's risk. About 80 to 90 percent of people with type 2 diabetes are overweight or obese. In type 2 diabetes, cells become resistant to the effects of insulin. In response, the pancreas increases its insulin secretion, but over time, the beta cells become exhausted. In many cases, type 2 diabetes can be reversed by moderate weight loss, regular physical activity, and consumption of a healthy diet; however, if blood glucose levels cannot be controlled, the diabetic will eventually require insulin.

Two of the early manifestations of diabetes are excessive urination and excessive thirst. They demonstrate how the out-of-control levels of glucose in the blood affect kidney function. The kidneys are responsible for filtering glucose from the blood. Excessive blood glucose draws water into the urine, and as a result the person eliminates an abnormally large quantity of sweet urine. The use of body water to dilute the urine leaves the body dehydrated, and so the person is unusually and continually thirsty. The person may also experience persistent hunger because the body cells are unable to access the glucose in the bloodstream.

Over time, persistently high levels of glucose in the blood injure tissues throughout the body, especially those of the blood vessels and nerves. Inflammation and injury of the lining of arteries lead to atherosclerosis and an increased risk of heart attack and stroke. Damage to the microscopic blood vessels of the kidney impairs kidney function and can lead to kidney failure. Damage to blood vessels that serve the eyes can lead to blindness. Blood vessel damage also reduces circulation to the limbs, whereas nerve damage leads to a loss of sensation, called neuropathy, particularly in the hands and feet. Together, these changes increase the risk of injury, infection, and tissue death (necrosis), contributing to a high rate of toe, foot, and lower leg amputations in people with diabetes. Uncontrolled diabetes can also lead to a dangerous form of metabolic acidosis called ketoacidosis. Deprived of glucose, cells increasingly rely on fat stores for fuel. However, in a glucose-deficient state, the liver is forced to use an alternative lipid metabolism pathway that results in the increased production of ketone bodies (or ketones), which are acidic. The build-up of ketones in the blood causes ketoacidosis, which—if left untreated—may lead to a life-threatening "diabetic coma." Together, these complications make diabetes the seventh leading cause of death in the United States.

Diabetes is diagnosed when lab tests reveal that blood glucose levels are higher than normal, a condition called hyperglycemia. The treatment of diabetes depends on the type, the severity of the condition, and the ability of the patient to make lifestyle changes. As noted earlier, moderate weight loss, regular physical activity, and consumption of a healthful diet can reduce blood glucose levels. Some patients with type 2 diabetes may be unable to control their disease with these lifestyle changes, and will require medication. Historically, the first-line treatment of type 2 diabetes was insulin. Research advances have resulted in alternative options, including medications that enhance pancreatic function.

Concept Review

The pancreas has both exocrine and endocrine functions. The pancreatic islet cell types include alpha cells, which produce glucagon; beta cells, which produce insulin; delta cells, which produce somatostatin; and PP cells, which produce pancreatic polypeptide. Insulin and glucagon are involved in the regulation of glucose metabolism. Insulin is produced by the beta cells in response to high blood glucose levels. It enhances glucose uptake and utilization by target cells, as well as the storage of excess glucose for later use. Dysfunction of the production of insulin or target cell resistance to the effects of insulin causes diabetes mellitus, a disorder characterized by high blood glucose levels. The hormone glucagon is produced and secreted by the alpha cells of the pancreas in response to low blood glucose levels. Glucagon stimulates mechanisms that increase blood glucose levels, such as the catabolism of glycogen into glucose.

Review Questions

Query 15.8.2

This interactive element is not available in this format. Visit the link or scan the QR code to access it online.

View this Interactive Content online

Critical Thinking Questions

Query 15.8.3

This interactive element is not available in this format. Visit the link or scan the QR code to access it online.

View this Interactive Content online

Glossary

Query 15.8.4

This interactive element is not available in this format. Visit the link or scan the QR code to access it online.

View this Interactive Content online

Contributors and Attributions

- OpenStax Anatomy & Physiology (CC BY 4.0). Access for free at https://openstax.org/books/anatomy-and-physiology

This page titled 15.8: Endocrine Pancreas is shared under a CC BY-NC-SA 4.0 license and was authored, remixed, and/or curated by Jennifer Lange et al..

- 15.9: Endocrine Pancreas by Whitney Menefee, Julie Jenks, Chiara Mazzasette, and Kim-Leiloni Nguyen is licensed CC BY 4.0.

15.9: Organs with Secondary Endocrine Functions

2

By the end of this section, you will be able to:

- Identify the organs with a secondary endocrine function, the hormone(s) they produce, and the effects of the hormone(s)

In your study of anatomy and physiology, you have already encountered a few of the many organs of the body that have secondary endocrine functions. Here, you will learn about the hormone-producing activities of the heart, gastrointestinal tract, kidneys, skeleton, adipose tissue, skin, and thymus.

Heart

When the body experiences an increase in blood volume or pressure, the cells of the heart's atrial wall stretch. In response, specialized cells in the wall of the atria produce and secrete the hormone **atrial natriuretic peptide (ANP)**. ANP signals the kidneys to reduce sodium reabsorption, thereby decreasing the amount of water reabsorbed from the urine filtrate and reducing blood volume. Other actions of ANP include the inhibition of renin secretion, thus inhibition of the renin-angiotensin-aldosterone system (RAAS) and vasodilation. Therefore, ANP aids in decreasing blood pressure, blood volume, and blood sodium levels.

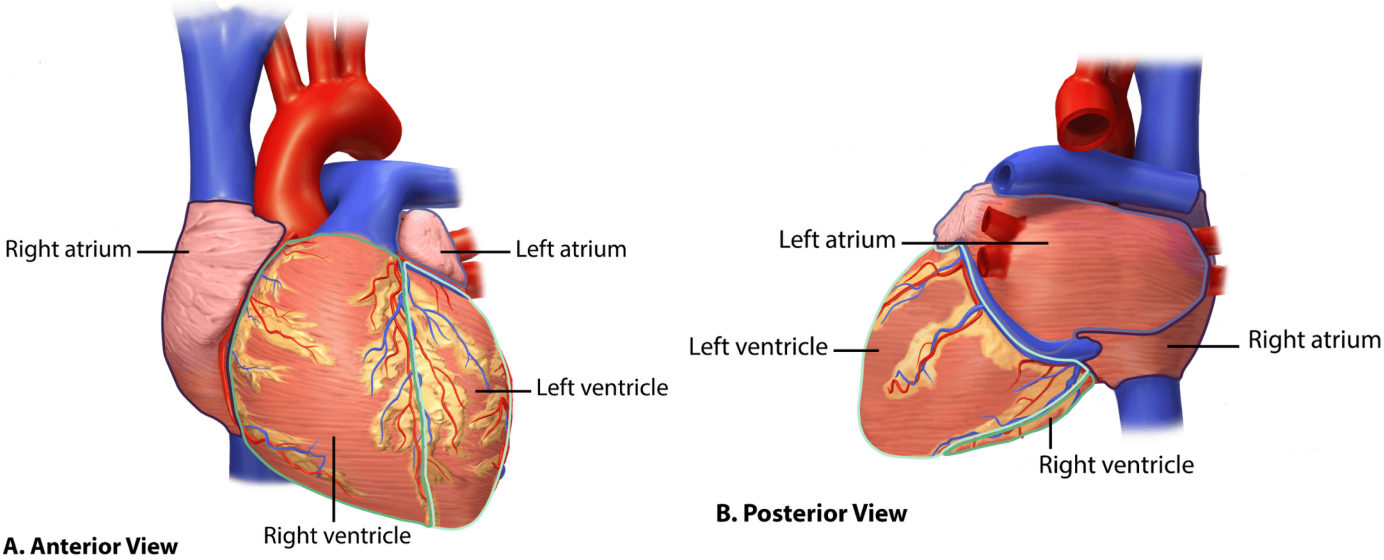

Figure 15.9.1:Superficial Heart Anatomy. Inside the pericardium, the surface features of the heart are visible. (Caption from OpenStax) *(Image credits: "Heart Chambers Anterior View" by Jennifer Lange is licensed under CC BY-NC-SA 4.0, modification of original "Blausen 0451 - Anterior view of the heart - English labels" by Blausen Medical Communications, Inc.; "Heart Chambers Posterior View" by Jennifer Lange is licensed under under CC BY-NC-SA 4.0, modification of original "Blausen 0456 Heart Posterior" by Blausen Medical Communications, Inc.)*

Gastrointestinal Tract

The endocrine cells of the GI tract are located in the mucosa of the stomach and small intestine. Some of these hormones are secreted in response to eating a meal and aid in digestion. An example of a hormone secreted by the stomach cells is gastrin, a peptide hormone secreted in response to stomach distention that stimulates the release of hydrochloric acid. Secretin is a peptide hormone secreted by the small intestine as acidic chyme (partially digested food and fluid) moves from the stomach. It stimulates the release of bicarbonate from the pancreas, which buffers the acidic chyme, and inhibits the further secretion of hydrochloric acid by the stomach. Cholecystokinin (CCK) is another peptide hormone released from the small intestine. It promotes the secretion of pancreatic enzymes and the release of bile from the gallbladder, both of which facilitate digestion.

Other hormones produced by the intestinal cells aid in glucose metabolism, such as by stimulating the pancreatic beta cells to secrete insulin, reducing glucagon secretion from the alpha cells, or enhancing cellular sensitivity to insulin.

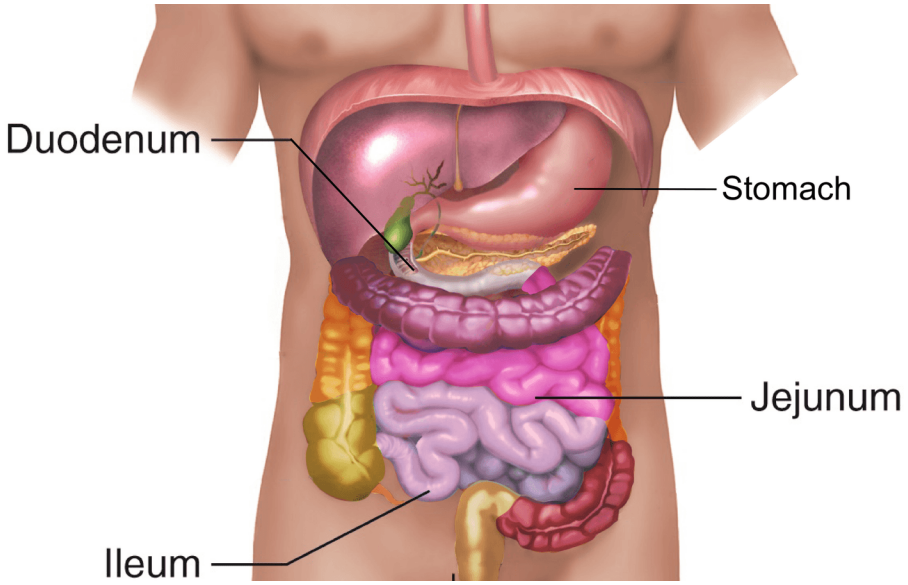

Figure 15.9.2: The Stomach and the Small Intestine. The three regions of the small intestine are the duodenum, jejunum, and ileum. (Image credit: "Drawing of Abdominal Organs" by "KnowledgeWorks - Drawing Abdominal organs - no labels" by KnowledgeWorks Global Ltd. and Open Learning Initiative, license: CC BY-NC-SA. edited by Gabrielle Spurlock and Yancy Aquino)

Kidneys

The kidneys participate in several complex endocrine pathways and produce certain hormones. A decline in blood flow to the kidneys stimulates them to release the enzyme renin, triggering the renin-angiotensin-aldosterone (RAAS) system, and stimulating the reabsorption of sodium and water. The reabsorption increases blood flow and blood pressure. The kidneys also play a role in regulating blood calcium levels through the production of calcitriol from vitamin D_3, which is released in response to the secretion of parathyroid hormone (PTH). In addition, the kidneys produce the hormone **erythropoietin (EPO)** in response to low oxygen levels. EPO stimulates the production of red blood cells (erythrocytes) in the bone marrow, thereby increasing oxygen delivery to tissues. You may have heard of EPO as a performance-enhancing drug (in a synthetic form).

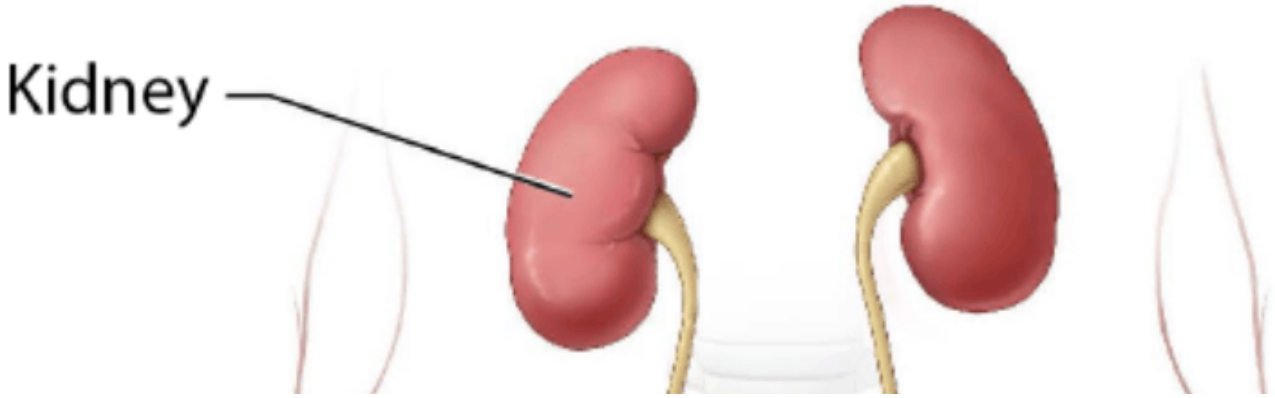

Figure 15.9.3: Kidneys. Responsible for the production of erythropoietin (EPO). (*Image credit: "Kidneys" by Yancy Aquino is licensed under CC BY-NC-SA 4.0, modification of originals "Organs of the Urinary System" by NIH Medial Arts is licensed under CC-BY-NC 2.0.*)

Skeleton

Although bone has long been recognized as a target for hormones, only recently have researchers recognized that the skeleton itself produces at least two hormones. Fibroblast growth factor 23 (FGF23) is produced by bone cells in response to increased

blood levels of vitamin D_3 or phosphate. It triggers the kidneys to inhibit the formation of calcitriol from vitamin D_3 and to increase phosphorus excretion. Osteocalcin, produced by osteoblasts, stimulates the pancreatic beta cells to increase insulin production. It also acts on peripheral tissues to increase their sensitivity to insulin and their utilization of glucose.

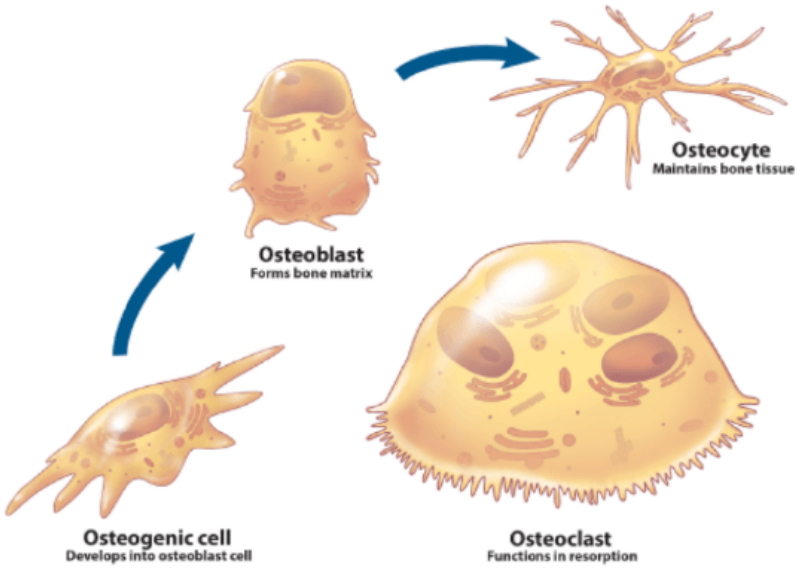

Figure 15.9.4:Bone Cells. Four types of cells are found within bone tissue. Osteogenic cells are undifferentiated and develop into osteoblasts. When osteoblasts get trapped within the calcified matrix, their structure and function changes, and they become osteocytes. Osteoclasts develop from monocytes and macrophages and differ in appearance from other bone cells. *(Image credit: "Bone Cells" by BlueLink is licensed under CC BY-NC 4.0 with notification of the original authors.)*

Adipose Tissue

Adipose tissue produces and secretes several hormones involved in lipid metabolism and storage. One important example is **leptin**, a protein manufactured by adipocytes that circulates in amounts directly proportional to levels of body fat. Leptin is released in response to food consumption and acts by binding to brain neurons involved in energy intake and expenditure. Binding of leptin produces a feeling of satiety after a meal, thereby reducing appetite. It also appears that the binding of leptin to brain receptors triggers the sympathetic nervous system to regulate bone metabolism, increasing deposition of cortical bone. Adiponectin—another hormone synthesized by adipocytes—appears to reduce cellular insulin resistance and to protect blood vessels from inflammation and atherosclerosis. Its levels are lower in people who are obese, and rise following weight loss.

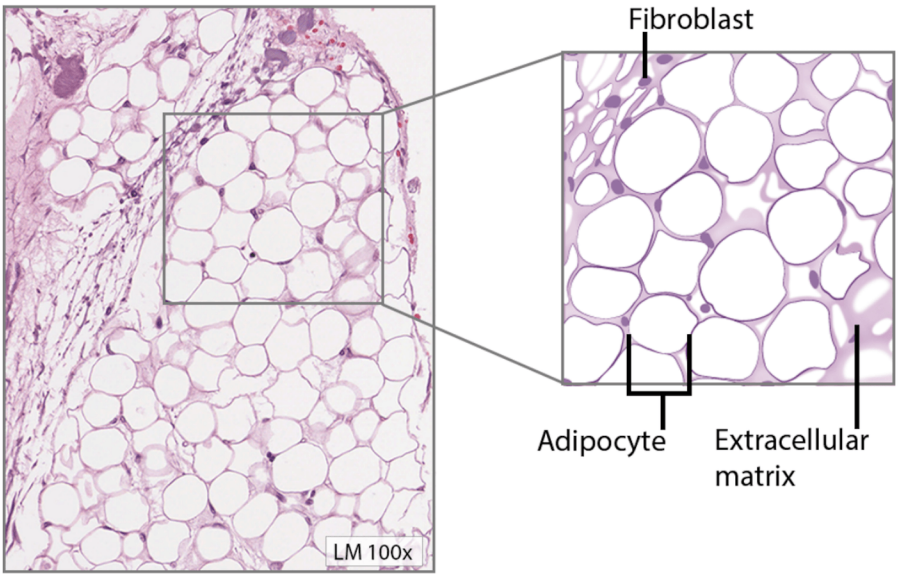

Figure 15.9.5: Adipose Tissue. This is a loose connective tissue that consists of adipocytes and limited extracellular matrix. Adipocytes store fat for energy and provides insulation. The number of adipocytes stays constant after adolescence, the cells just change in size. *(Image credit: "Adipose Tissue" by Jennifer Lange, illustration by Claire McGuire is licensed under CC-BY-NC-SA 4.0. Micrograph provided by Berkshire Community College Bioscience Image Library is in the Public Domain.)*

Skin

The skin functions as an endocrine organ in the production of the inactive form of vitamin D_3, cholecalciferol. When cholesterol present in the epidermis is exposed to ultraviolet radiation, it is converted to cholecalciferol, which then enters the blood. In the liver, cholecalciferol is converted to an intermediate that travels to the kidneys and is further converted to calcitriol, the active form of vitamin D_3. Vitamin D is important in a variety of physiological processes, including intestinal calcium absorption and immune system function. In some studies, low levels of vitamin D have been associated with increased risks of cancer, severe asthma, and multiple sclerosis. Vitamin D deficiency in children causes rickets, and in adults, osteomalacia—both of which are characterized by bone deterioration.

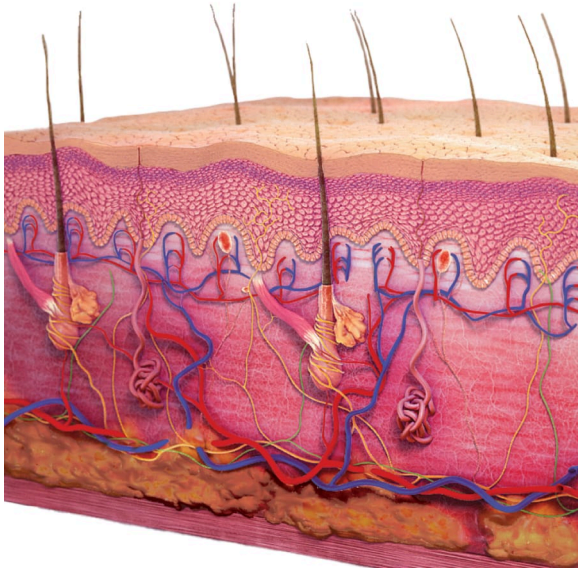

Figure 15.9.6: Skin. The skin is responsible for the production of cholecalciferol, an inactive form of vitamin D_3. *(Image credit: "Layers of the Skin" by Sophia Elizondo and Jennifer Lange is licensed under CC BY-NC-SA 4.0, modification of original by Scientific Animations.)*

Thymus

The thymus is an organ of the immune system that is larger and more active during infancy and early childhood, and begins to atrophy as we age. Its endocrine function is the production of a group of hormones called thymosins that contribute to the development and differentiation of T lymphocytes, which are immune cells. Although the role of thymosins is not yet well understood, it is clear that they contribute to the immune response. Thymosins have been found in tissues other than the thymus and have a wide variety of functions, so the thymosins cannot be strictly categorized as thymic hormones.

Liver

The liver is responsible for secreting at least four important hormones or hormone precursors: insulin-like growth factor (somatomedin), angiotensinogen, thrombopoetin, and hepcidin. Insulin-like growth factor-1 is the immediate stimulus for growth in the body, especially of the bones. Angiotensinogen is the precursor to angiotensin, mentioned earlier, which increases blood pressure. Thrombopoetin stimulates the production of the blood's platelets. Hepcidins block the release of iron from cells in the body, helping to regulate iron homeostasis in our body fluids.

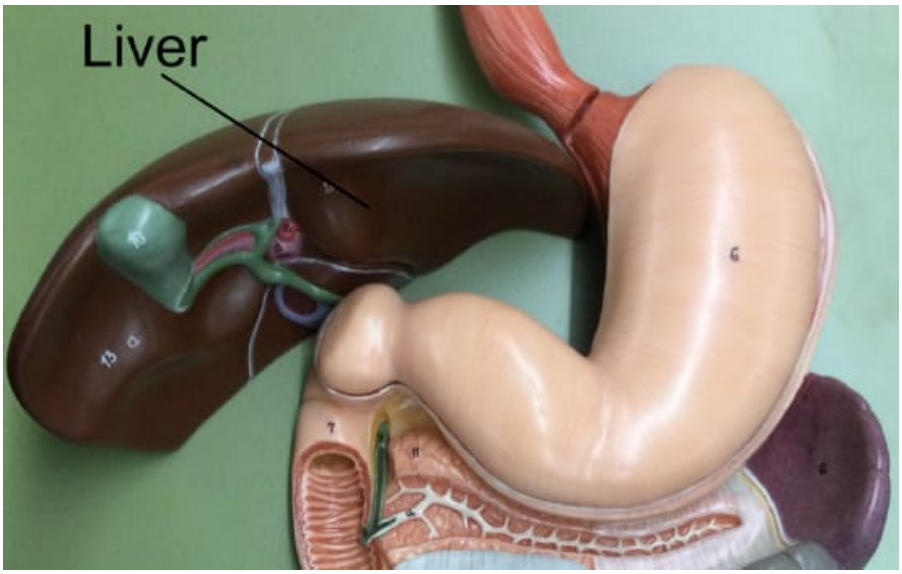

Figure 15.9.7: Liver. The liver is responsible for the production of some hormones that are used during digestion. (*Image credit: "Liver" by Jennifer Lange is licensed under CC BY-NC-SA 4.0*)

The major hormones of these organs with secondary endocrine functions are summarized in Table 15.9.1.

Table 15.9.1: Organs with Secondary Endocrine Functions and Their Major Hormones

Organ	Major hormones	Effects
Heart	Atrial natriuretic peptide (ANP)	Reduces blood volume, blood pressure, and Na^+ concentration
Gastrointestinal tract	Gastrin, secretin, and cholecystokinin	Aid digestion of food and buffering of stomach acids
Gastrointestinal tract	Glucose-dependent insulinotropic peptide (GIP) and glucagon-like peptide 1 (GLP-1)	Stimulate beta cells of the pancreas to release insulin
Kidneys	Renin	Stimulates release of aldosterone
Kidneys	Calcitriol	Aids in the absorption of Ca^{2+}
Kidneys	Erythropoietin	Triggers the formation of red blood cells in the bone marrow

Organ	Major hormones	Effects
Skeleton	FGF23	Inhibits production of calcitriol and increases phosphate excretion
Skeleton	Osteocalcin	Increases insulin production
Adipose tissue	Leptin	Promotes satiety signals in the brain
Adipose tissue	Adiponectin	Reduces insulin resistance
Skin	Cholecalciferol	Modified to form vitamin D
Thymus (and other organs)	Thymosins	Among other things, aids in the development of T lymphocytes of the immune system
Liver	Insulin-like growth factor-1	Stimulates bodily growth
Liver	Angiotensinogen	Raises blood pressure
Liver	Thrombopoetin	Causes increase in platelets
Liver	Hepcidin	Blocks release of iron into body fluids

Concept Review

Some organs have a secondary endocrine function. For example, the walls of the atria of the heart produce the hormone atrial natriuretic peptide (ANP), the gastrointestinal tract produces the hormones gastrin, secretin, and cholecystokinin, which aid in digestion, and the kidneys produce erythropoietin (EPO), which stimulates the formation of red blood cells. Even bone, adipose tissue, and the skin have secondary endocrine functions.

Review Questions

Query 15.9.1

This interactive element is not available in this format. Visit the link or scan the QR code to access it online.

View this Interactive Content online

Critical Thinking Questions

Query 15.9.2

This interactive element is not available in this format. Visit the link or scan the QR code to access it online.

View this Interactive Content online

Glossary

Query 15.9.3

This interactive element is not available in this format. Visit the link or scan the QR code to access it online.

View this Interactive Content online

Contributors and Attributions

- OpenStax Anatomy & Physiology (CC BY 4.0). Access for free at https://openstax.org/books/anatomy-and-physiology

This page titled 15.9: Organs with Secondary Endocrine Functions is shared under a CC BY-NC-SA 4.0 license and was authored, remixed, and/or curated by Jennifer Lange et al..

- 15.10: Organs with Secondary Endocrine Functions by Whitney Menefee, Julie Jenks, Chiara Mazzasette, and Kim-Leiloni Nguyen is licensed CC BY 4.0.

15.10: Development and Aging of the Endocrine System

By the end of this section, you will be able to:

- Describe the embryonic origins of the endocrine system
- Discuss the effects of aging on the endocrine system

The endocrine system arises from all three embryonic germ layers. The endocrine glands that produce the steroid hormones, such as the gonads and adrenal cortex, arise from the mesoderm. In contrast, endocrine glands that arise from the endoderm and ectoderm produce the amino acid-based hormones. The pituitary gland arises from two distinct areas of the ectoderm: the anterior pituitary gland arises from the oral ectoderm, whereas the posterior pituitary gland arises from the neural ectoderm at the base of the hypothalamus. The pineal gland also arises from the ectoderm. The two structures of the adrenal glands arise from two different germ layers: the adrenal cortex from the mesoderm and the adrenal medulla from ectoderm neural cells. The endoderm gives rise to the thyroid and parathyroid glands, as well as the pancreas and the thymus.

As the body ages, changes occur that affect the endocrine system, sometimes altering the production, secretion, and catabolism of hormones. For example, the structure of the anterior pituitary gland changes as vascularization decreases and the connective tissue content increases with increasing age. This restructuring affects the gland's hormone production. For example, the amount of human growth hormone that is produced declines with age, resulting in the reduced muscle mass commonly observed in the elderly.

The adrenal glands also undergo changes as the body ages; as fibrous tissue increases, the production of cortisol and aldosterone decreases. Interestingly, the production and secretion of epinephrine and norepinephrine remain normal throughout the aging process.

A well-known example of the aging process affecting an endocrine gland is menopause and the decline of ovarian function. With increasing age, the ovaries decrease in both size and weight and become progressively less sensitive to gonadotropins. This gradually causes a decrease in estrogen and progesterone levels, leading to menopause and the inability to reproduce. Low levels of estrogens and progesterone are also associated with some disease states, such as osteoporosis, atherosclerosis, and hyperlipidemia, or abnormal blood lipid levels.

Testosterone levels also decline with age, a condition called andropause (or viropause); however, this decline is much less dramatic than the decline of estrogens in women, and much more gradual, rarely affecting sperm production until very old age. Although this means that males maintain their ability to father children for decades longer than females, the quantity, quality, and motility of their sperm is often reduced.

As the body ages, the thyroid gland produces less of the thyroid hormones, causing a gradual decrease in the basal metabolic rate. The lower metabolic rate reduces the production of body heat and increases levels of body fat. Parathyroid hormones, on the other hand, increase with age. This may be because of reduced dietary calcium levels, causing a compensatory increase in parathyroid hormone. However, increased parathyroid hormone levels combined with decreased levels of calcitonin (and estrogens in women) can lead to osteoporosis as PTH stimulates demineralization of bones to increase blood calcium levels. Notice that osteoporosis is common in both elderly males and females.

Increasing age also affects glucose metabolism, as blood glucose levels spike more rapidly and take longer to return to normal in the elderly. In addition, increasing glucose intolerance may occur because of a gradual decline in cellular insulin sensitivity. Almost 27 percent of Americans aged 65 and older have diabetes.

Concept Review

The endocrine system originates from all three germ layers of the embryo, including the endoderm, ectoderm, and mesoderm. In general, different hormone classes arise from distinct germ layers. Aging affects the endocrine glands, potentially affecting hormone production and secretion, and can cause disease. The production of hormones, such as human growth hormone, cortisol, aldosterone, sex hormones, and the thyroid hormones, decreases with age.

Review Questions

Query 15.10.1

This interactive element is not available in this format. Visit the link or scan the QR code to access it online.

View this Interactive Content online

Critical Thinking Questions

Query 15.10.2

This interactive element is not available in this format. Visit the link or scan the QR code to access it online.

View this Interactive Content online

Contributors and Attributions

- OpenStax Anatomy & Physiology (CC BY 4.0). Access for free at https://openstax.org/books/anatomy-and-physiology

This page titled 15.10: Development and Aging of the Endocrine System is shared under a CC BY-NC-SA 4.0 license and was authored, remixed, and/or curated by Jennifer Lange et al..

- 15.11: Development and Aging of the Endocrine System by Whitney Menefee, Julie Jenks, Chiara Mazzasette, and Kim-Leiloni Nguyen is licensed CC BY 4.0.

15.11: Anatomical Atlas - Endocrine System

A compendium of anatomical images: slides, models, and/or cadavers.

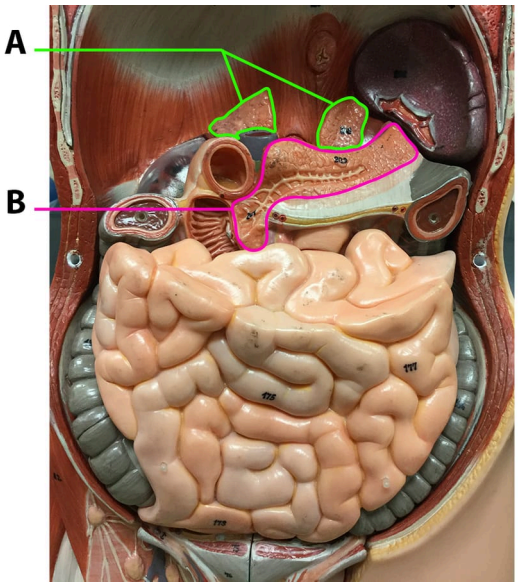

Image Credit

"Torso Model Abdominal Region - Endocrine Organs" by Jennifer Lange is licensed under CC BY-NC-SA 4.0.

Answer Key (click to show/ hide answers)

A - Adrenal glands

B - Pancreas

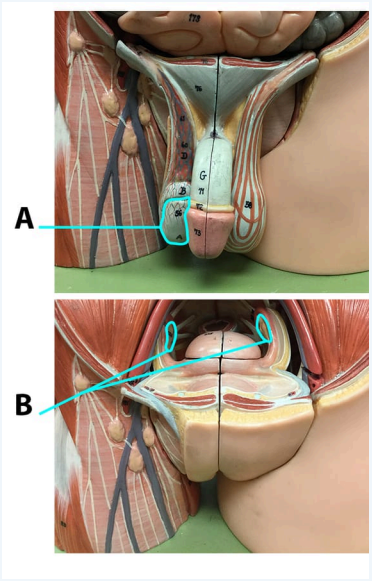

Image Credit

"Torso Model Pelvic Region - Endocrine Organs" by Jennifer Lange is licensed under CC BY-NC-SA 4.0.

Answer Key (click to show/ hide answers)

A - Testis (testes = plural)

B - Ovaries

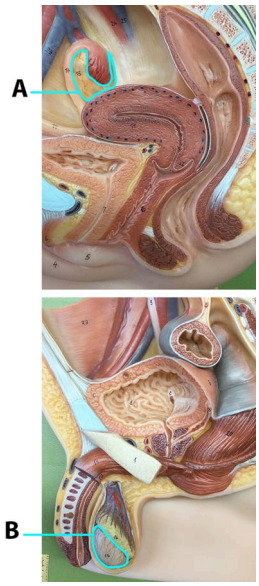

Image Credit

"Midsagittal Reproductive Systems Models - Endocrine Organs" by Jennifer Lange is licensed under CC BY-NC-SA 4.0.

Answer Key (click to show/ hide answers)

A - Ovary

B - Testis

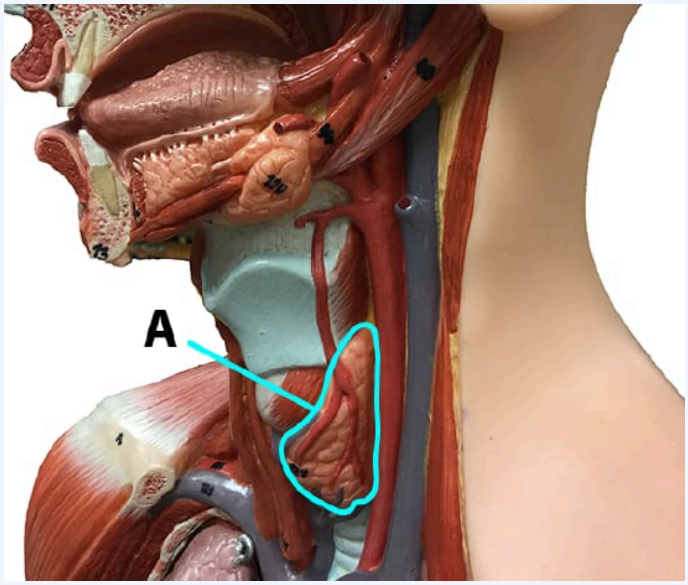

Image Credit

"Torso Model Cervical Region - Endocrine Organ" by Jennifer Lange is licensed under CC BY-NC-SA 4.0.

Answer Key (click to show/ hide answers)

A - Thyroid gland

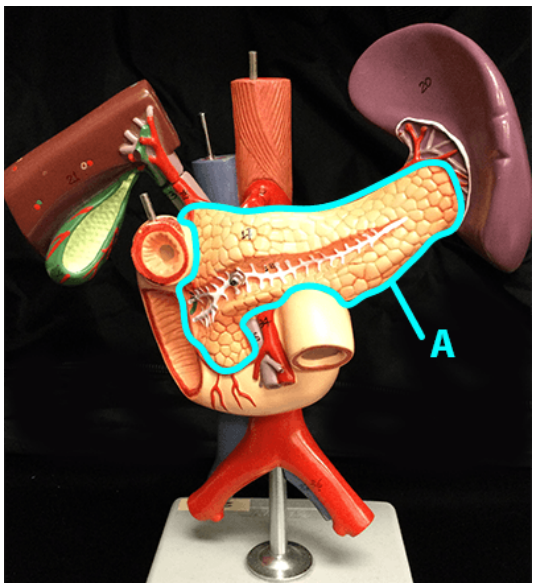

Image Credit

"Posterior Abdominal Organs - Pancreas" by Jennifer Lange is licensed under CC BY-NC-SA 4.0.

Answer Key (click to show/ hide answers)

A - Pancreas

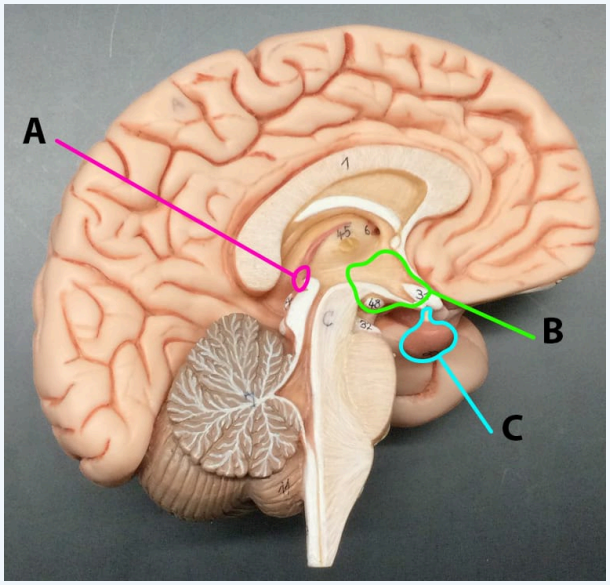

Image Credit

"Brain Model Midsagittal - Endocrine Structures" by Jennifer Lange is licensed under CC BY-NC-SA 4.0.

Answer Key (click to show/ hide answers)

A - Pineal gland

B - Hypothalamus

C - Pituitary gland

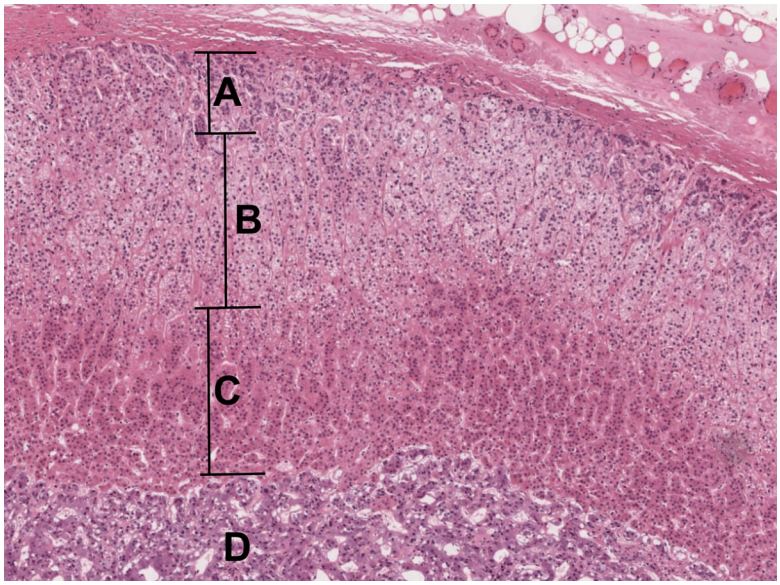

Image Credit

"Adrenal Gland Histology @ 100x - Atlas" by Yancy Aquino is licensed under CC BY-NC-SA 4.0, slide provided by the Regents of the University of Michigan Medical School © 2022.

Answer Key (click to show/ hide answers)

Adrenal Gland Slide @ 100x:

A
- Zona glomerulosa

B - Zona fasciculata

C - Zona reticularis

D - Medulla

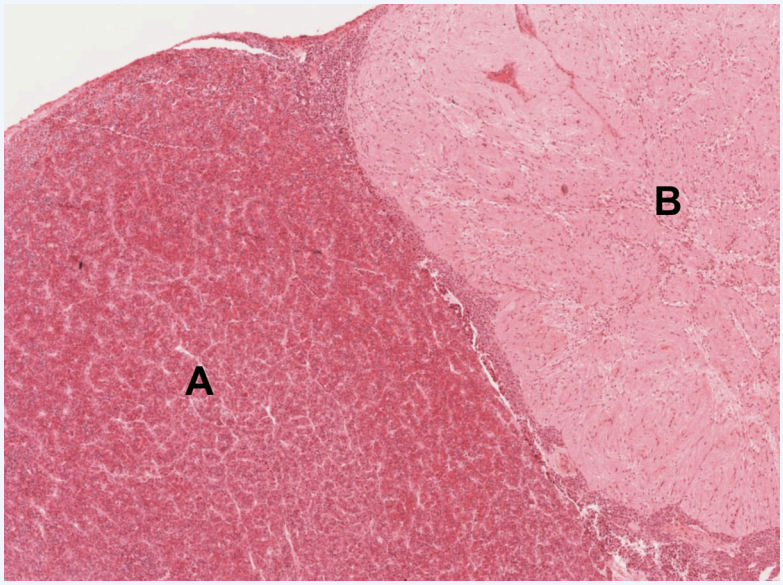

Image Credit

"Pituitary Gland Histology @ 100x - Atlas" is licensed under CC BY-NC-SA 4.0, slide provided by the Regents of the University of Michigan Medical School © 2022.

Answer Key (click to show/ hide answers)

Pituitary Gland Slide @ 100x:

A - Anterior lobe of the pituitary gland

B - Posterior lobe of the pituitary gland

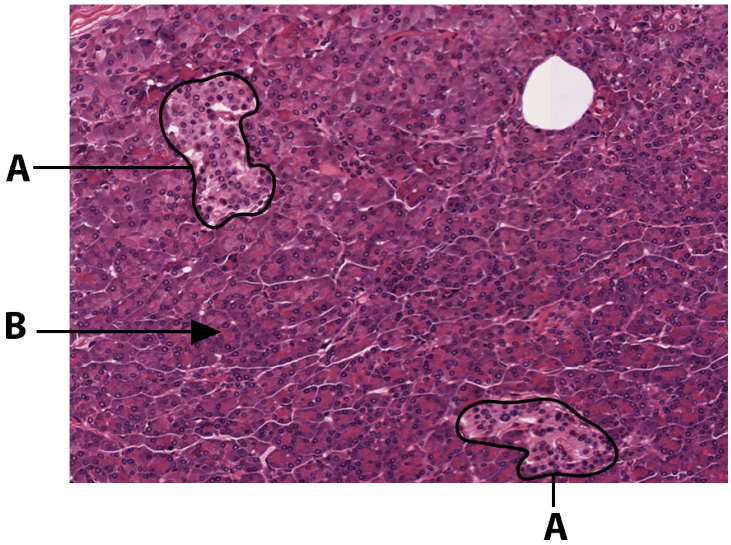

Image Credit

"Pancreas Histology @ 400x - Atlas" by Jennifer Lange is licensed under CC BY-NC-SA 4.0, slide provided by the Regents of the University of Michigan Medical School © 2022.

Answer Key (click to show/ hide answers)

Pancreas Slide @ 400x:

A - pancreatic islet (of Langerhans)

B - pancreatic acini (acinar cells)

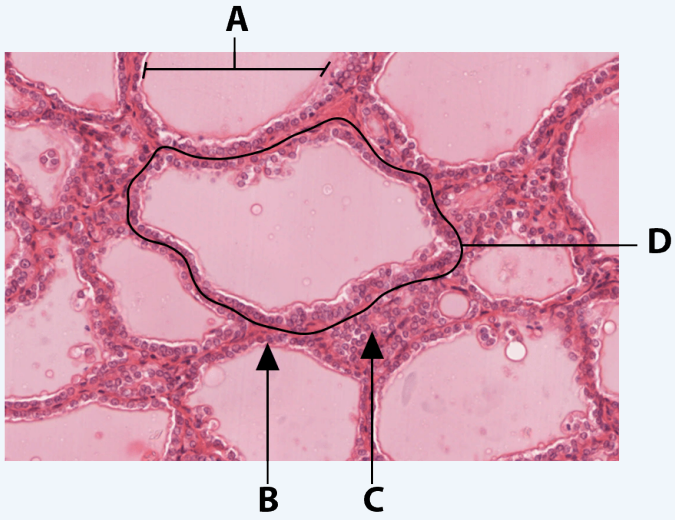

Image Credit

"Thyroid Gland Histology @ 400x - Atlas" by Jennifer Lange is licensed under CC BY-NC-SA 4.0, slide provided by the Regents of the University of Michigan Medical School © 2022.

Answer Key (click to show/ hide answers)

Thyroid Gland Slide @ 400x:

A - colloid

B - follicular cells

C - parafollicular cells

D - thyroid follicle

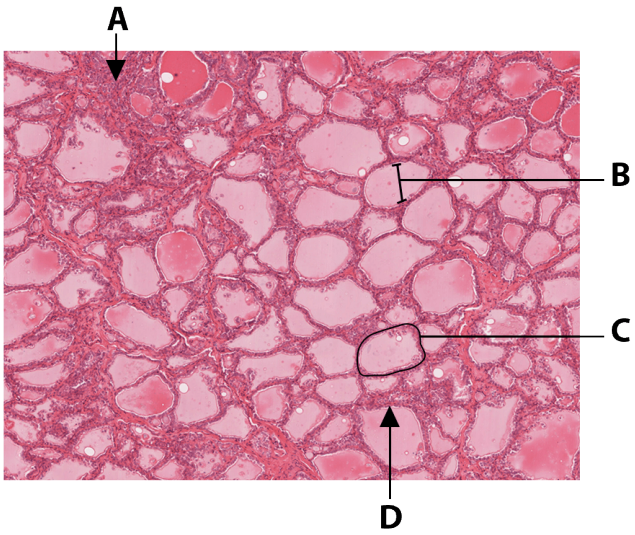

Image Credit

"Thyroid Gland Histology @ 100x - Atlas" by Jennifer Lange is licensed under CC BY-NC-SA 4.0, slide provided by the Regents of the University of Michigan Medical School © 2022.

Answer Key (click to show/ hide answers)

Thyroid Gland Slide @ 100x:

A - parafollicular cells

B - colloid

C - thyroid follicle

D - follicular cells

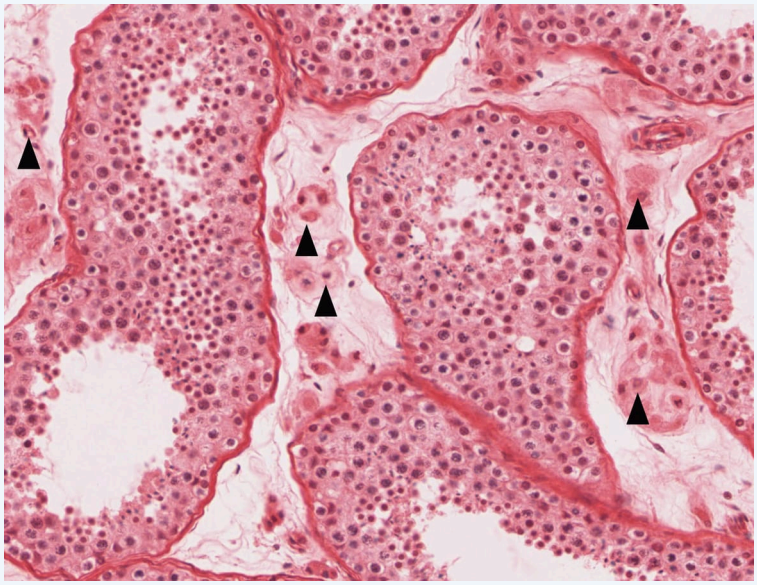

Image Credit

"Testis Histology @ 400x - Endocrine Cells" by Jennifer Lange is licensed under CC BY-NC-SA 4.0, slide provided by the Regents of the University of Michigan Medical School © 2022.

Answer Key (click to show/ hide answers)

Testis Slide @ 400x:

Arrows - Interstitial cells (of Leydig)

This page titled 15.11: Anatomical Atlas - Endocrine System is shared under a CC BY-NC-SA 4.0 license and was authored, remixed, and/or curated by Jennifer Lange et al..

15.12: Practice Practical- Endocrine System

Answer the following question by writing your answer in the space provided.

Query 15.12.1

This interactive element is not available in this format. Visit the link or scan the QR code to access it online.

View this Interactive Content online

Query 15.12.1

This interactive element is not available in this format. Visit the link or scan the QR code to access it online.

View this Interactive Content online

Query 15.12.1

This interactive element is not available in this format. Visit the link or scan the QR code to access it online.

View this Interactive Content online

Query 15.12.1

This interactive element is not available in this format. Visit the link or scan the QR code to access it online.

View this Interactive Content online

Query 15.12.1

This interactive element is not available in this format. Visit the link or scan the QR code to access it online.

View this Interactive Content online

Query 15.12.1

This interactive element is not available in this format. Visit the link or scan the QR code to access it online.

View this Interactive Content online

Query 15.12.1

This interactive element is not available in this format. Visit the link or scan the QR code to access it online.

View this Interactive Content online

This page titled 15.12: Practice Practical- Endocrine System is shared under a CC BY-NC-SA 4.0 license and was authored, remixed, and/or curated by Jennifer Lange et al..

16: CARDIOVASCULAR SYSTEM - BLOOD

16.1: Introduction to Blood
16.2: An Overview of Blood
16.3: Erythrocytes
16.4: Leukocytes and Platelets
16.5: Production of the Formed Elements
16.6: Anatomical Atlas - Blood
16.7: Practice Practical- Blood

This page titled 16: Cardiovascular System - Blood is shared under a CC BY-NC-SA 4.0 license and was authored, remixed, and/or curated by Jennifer Lange et al..

- 16: Cardiovascular System - Blood by Whitney Menefee, Julie Jenks, Chiara Mazzasette, and Kim-Leiloni Nguyen is licensed CC BY 4.0.

16.1: Introduction to Blood

Chapter Learning Objectives:

After studying this chapter, you will be able to:

- Identify the primary functions of blood, its fluid and cellular components, and its physical characteristics
- Identify the most important proteins and other solutes present in blood plasma
- Describe the formation of the formed element components of blood
- Discuss the structure and function of red blood cells and hemoglobin
- Classify and characterize white blood cells
- Describe the structure and function of platelets
- Discuss a variety of blood disorders

Single-celled organisms do not need blood. They obtain nutrients directly from and excrete wastes directly into their environment. The human organism cannot do that. Our large, complex bodies need blood to deliver nutrients to and remove wastes from our trillions of cells. The heart pumps blood throughout the body in a network of blood vessels. Together, these three components—blood, heart, and vessels—make up the cardiovascular system. This chapter focuses on the fluid connective tissue that serves as a medium of transport: blood.

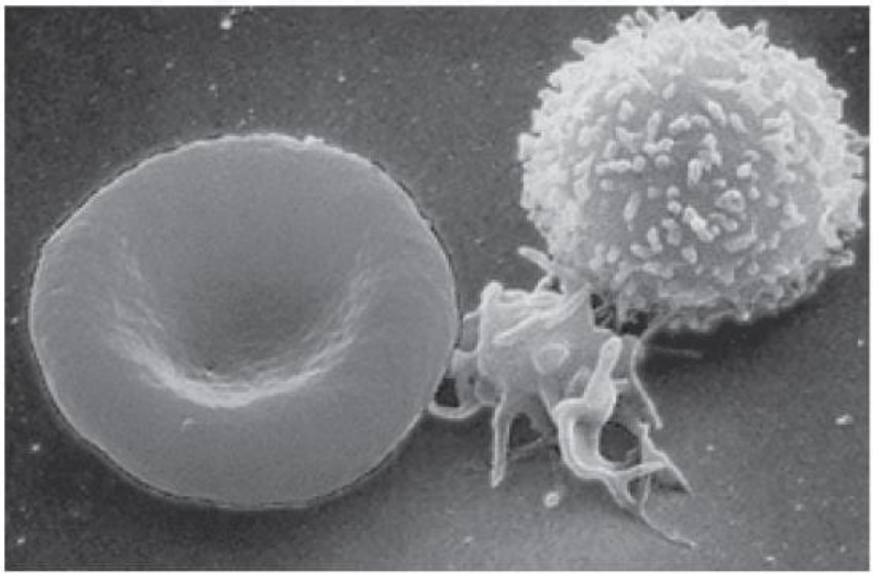

Figure 16.1.1: Red Blood Cell, Platelet, and White Blood Cell. A single drop of blood contains millions of red blood cells, white blood cells, and platelets. A red blood cell (left), platelet (middle), and a white blood cell (right) are shown here, isolated from a scanning electron micrograph. (Image credit: "Blood Cells" by OpenStax is licensed under CC BY 3.0)

Contributors and Attributions

- OpenStax Anatomy & Physiology (CC BY 4.0). Access for free at https://openstax.org/books/anatomy-and-physiology

This page titled 16.1: Introduction to Blood is shared under a CC BY-NC-SA 4.0 license and was authored, remixed, and/or curated by Jennifer Lange et al..

- 16.1: Introduction to Blood by Whitney Menefee, Julie Jenks, Chiara Mazzasette, and Kim-Leiloni Nguyen is licensed CC BY 4.0.

16.2: An Overview of Blood

By the end of this section, you will be able to:

- Identify the primary functions of blood in transportation, defense, and maintenance of homeostasis
- Name the fluid component of blood and the three major types of formed elements, and identify their relative proportions in a blood sample
- Identify the composition of blood plasma, including its most important solutes and plasma proteins

Recall that **blood** is a connective tissue. Like all connective tissues, it is made up of cellular elements and an extracellular matrix. The cellular elements—referred to as the **formed elements** include **erythrocytes** (aka red blood cells or RBCs), **leukocytes** (aka white blood cells or WBCs), and cell fragments called **platelets** (aka thrombocytes). The extracellular matrix, called **plasma**, makes blood unique among connective tissues because it is fluid. This fluid, which is mostly water, perpetually suspends the formed elements and enables them to circulate throughout the body within the cardiovascular system.

Composition of Blood

You have probably had blood drawn from a superficial vein in your arm, which was then sent to a lab for analysis. Some of the most common blood tests—for instance, those measuring lipid or glucose levels in plasma—determine which substances are present within blood and in what quantities. Other blood tests check for the composition of the blood itself, including the quantities and types of formed elements.

One such test, called a **hematocrit**, measures the percentage of erythrocytes in a blood sample. Erythrocytes are the specific cells that carry oxygen in the blood. The hematocrit test is performed by spinning the blood sample in a specialized centrifuge, a process that causes the heavier elements suspended within the blood sample to separate from the lightweight, liquid plasma (Figure 16.2.1). Because the heaviest elements in blood are the iron-containing erythrocytes, these settle at the very bottom of the hematocrit tube. Located above the erythrocytes is a pale, thin layer composed of the remaining formed elements of blood: leukocytes and platelets. The layer containing the leukocytes and platelets is referred to as the **buffy coat** because of its color; it normally constitutes less than 1 percent of a blood sample. Above the buffy coat is the blood plasma, normally a pale, straw-colored fluid matrix, that constitutes the remainder of the sample.

The hematocrit test allows one to measure the volume of erythrocytes after centrifugation and the result is also commonly referred to as **packed cell volume (PCV)**. In normal blood, about 45 percent of a sample is erythrocytes. The hematocrit of any one sample can vary significantly, ranging from 37–52 percent based on sex hormones and other factors. Normal hematocrit values for adult females with XX chromosomes range from 37 to 47 percent, with a mean value of 41 percent. For XY males, hematocrit values range from 42 to 52 percent, with a mean of 47 percent. Testosterone stimulates erythropoiesis (RBC production), which increases the hematocrit in adult XY males. XX females who are menstruating experience an overall decrease in their hematocrit, and the RBC percentage fluctuates across the menstrual cycle.

The percentage of other formed elements, the leukocytes and platelets, is extremely small so it is not normally considered with the hematocrit. Thus the mean plasma percentage is the percent of blood that is not erythrocytes: for females, it is approximately 59 percent (or 100 minus 41 percent), and for males, it is approximately 53 percent (or 100 minus 47 percent).

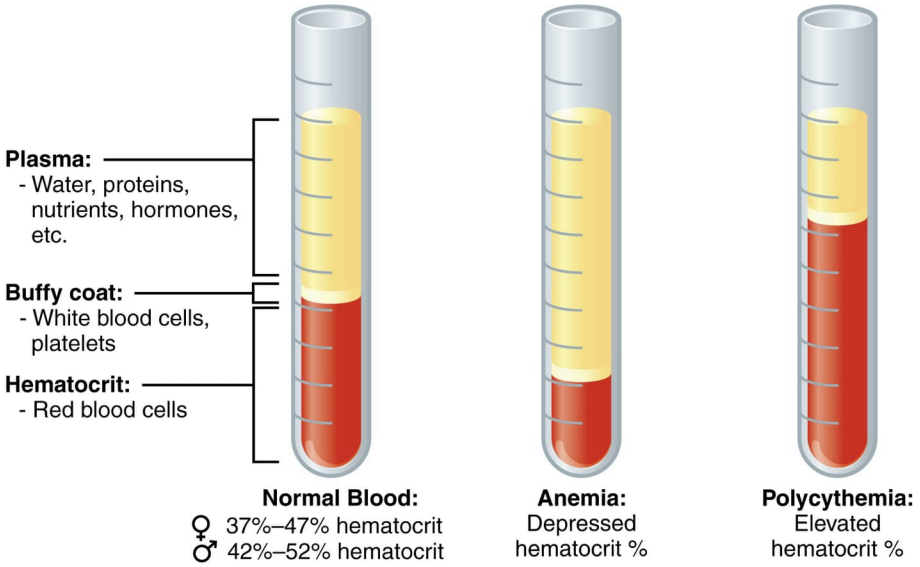

Figure 16.2.1: Composition of Blood. The cellular elements of blood include a vast number of erythrocytes and comparatively fewer leukocytes and platelets. Plasma is the fluid in which the formed elements are suspended. A sample of blood spun in a centrifuge reveals a straw-colored plasma as the lightest component. It floats at the top of the tube separated from the heaviest elements, the erythrocytes, by a buffy coat of leukocytes and platelets. Hematocrit is the percentage of the total sample that is comprised of erythrocytes. A normal hematocit (shown just above 40 percent) is compared with a depressed hematocrit (shown just above 20 percent), which indicates anemia, and an elevated hematocrit (shown above 60 percent), which indicates polycythemia. *(Image credit: "Composition of Blood" by OpenStax is licensed under CC BY 3.0.)*

Characteristics of Blood

When you think about blood, the first characteristic that probably comes to mind is its color. Blood that has just taken up oxygen in the lungs is bright red, and blood that has released oxygen in the tissues is a more dusky red. This is because hemoglobin is a pigment that changes color depending upon the degree of oxygen saturation.



Figure 16.2.2: Shades of Red Blood. The bright red hue of oxygenated blood is shown on the left while the deeper red hue of deoxygenated blood is shown on the right. *("Drops of Blood Medium" by unknown author is licensed under CC BY 3.0.)*

Blood is viscous and somewhat sticky to the touch. It has a viscosity approximately five times greater than water. Viscosity is a measure of a fluid's thickness or resistance to flow, and is influenced by the presence of the plasma proteins and formed elements within the blood. The viscosity of blood has a dramatic impact on blood pressure and flow. Consider the difference in

flow between water and honey. The more viscous honey would demonstrate a greater resistance to flow than the less viscous water. The same principle applies to blood.

The normal temperature of blood is slightly higher than normal body temperature—about 38 °C (or 100.4 °F), compared to 37 °C (or 98.6 °F) for an internal body temperature reading, although daily variations of 0.5 °C are normal. Although the surface of blood vessels is relatively smooth, as blood flows through them, it experiences some friction and resistance, especially as vessels age and lose their elasticity, thereby producing heat. This accounts for its slightly higher temperature.

The pH of blood averages about 7.4; it is maintained within an extremely tight range from 7.35 to 7.45 in a healthy person. At an average pH of 7.4, blood is somewhat more basic (alkaline) on a chemical scale than pure water, which has a pH of 7.0. Blood contains numerous buffers that contribute to the regulation of pH.

Blood constitutes approximately 8 percent of adult body weight. Adult males typically average about 5 to 6 liters of blood. Females average 4 to 5 liters.

Blood Plasma

Like other fluids in the body, plasma is composed primarily of water; in fact, it is about 92 percent water. Dissolved or suspended within this water is a mixture of substances, most of which are proteins. There are literally hundreds of substances dissolved or suspended in the plasma, although many of them are found only in very small quantities.

Plasma Proteins

About 7 percent of the volume of plasma—nearly all that is not water—is made of proteins. These include several plasma proteins (proteins that are unique to the plasma), plus a much smaller number of regulatory proteins, including enzymes and some hormones. The major components of plasma are summarized in Table 16.2.1.

The three major groups of plasma proteins are as follows:

- **Albumin** is the most abundant of the plasma proteins. Manufactured by the liver, albumin molecules serve as binding proteins—transport vehicles for lipids such as fatty acids and steroid hormones like testosterone. Recall that lipids are hydrophobic; however, their binding to albumin enables them to be transported in the watery plasma. Albumin is also the most significant contributor to the osmotic pressure of blood; that is, its presence holds water inside the blood vessels and draws water from the tissues, across blood vessel walls, and into the bloodstream. This in turn helps to maintain both blood volume and blood pressure. Albumin normally accounts for approximately 54 percent of the total plasma protein content; clinically, this measures as 3.5–5.0 g/dL blood.
- The second most common plasma proteins are the **globulins**. A heterogeneous group, there are three main subgroups known as alpha, beta, and gamma globulins. The alpha and beta globulins transport iron, lipids, and the fat-soluble vitamins A, D, E, and K to the cells; like albumin, they also contribute to osmotic pressure. The gamma globulins are proteins involved in immunity and are better known as an **antibodies** or **immunoglobulins**. Although other plasma proteins are produced by the liver, immunoglobulins are produced by specialized leukocytes known as plasma cells. Globulins make up approximately 38 percent of the total plasma protein volume; clinically, this measures as 1.0–1.5 g/dL blood.
- The least abundant plasma protein is **fibrinogen**. Like albumin and the alpha and beta globulins, fibrinogen is produced by the liver. It is essential for blood clotting. Fibrinogen accounts for about 7 percent of the total plasma protein volume; clinically, this measures as 0.2–0.45 g/dL blood.

Other Plasma Solutes

In addition to proteins, plasma contains a wide variety of other substances. These include various electrolytes, such as sodium, potassium, and calcium ions; dissolved gases, such as oxygen, carbon dioxide, and nitrogen; various organic nutrients, such as vitamins, lipids, glucose, and amino acids; and metabolic wastes. All of these non-protein solutes combined contribute approximately 1 percent to the total volume of plasma.

Table** 16.2.1**: Summary of Major Blood Components

Component and % of blood	Subcomponent and % of component	Type and % (where appropriate)	Site of production	Major function(s)
Plasma - 46-63%	Water - 92 %	Fluid	Absorbed by intestinal tract or produced by metabolism	Transport medium
	Plasma proteins - 7 %	Albumin - 54-60 %	Liver	Maintain osmotic concentration, transport lipid molecules
		Globulins - 35-38 %	Liver (Alpha and Beta globulins)	Transport, maintain osmotic concentration
			Plasma Cells [Gamma globulins (immunoglobulins)]	Immune response (antibody)
		Fibrinogen - 4-7 %	Liver	Blood clotting
	Regulatory proteins - <1 %	Hormones and enzymes	Various sources	Regulate various body functions
	Other solutes - 1 %	Nutrients, gases, and wastes	Absorbed by intestinal tract, exchanged in respiratory system	Numerous and varied
Formed Elements - 37-54 %	Erythrocytes - 99 %	Erythrocytes	Red bone marrow	Transports gases, primarily oxygen and some carbon dioxide
	Leukocytes - <1 %	Agranular and granular	Red bone marrow	Immune responses
	Platelets - <1 %	Platelets	Megakaryocytes: red bone marrow	Hemostasis

CAREER CONNECTIONS

Phlebotomy and Medical Lab Technology

Phlebotomists are professionals trained to draw blood (phleb- = “a blood vessel”; -tomy = “to cut”). When more than a few drops of blood are required, phlebotomists perform a venipuncture, typically of a surface vein in the arm. They perform a capillary stick on a finger, an earlobe, or the heel of an infant when only a small quantity of blood is required. An arterial stick is collected from an artery and used to analyze blood gases. After collection, the blood may be analyzed by medical laboratories or perhaps used for transfusions, donations, or research. While many allied health professionals practice phlebotomy, the American Society of Phlebotomy Technicians issues certificates to individuals passing a national examination, and some large labs and hospitals hire individuals expressly for their skill in phlebotomy.

Figure 16.2.3: A medical laboratory technician tests a blood agar plate for *Staphylococcus aureus*. *(U.S. Army photo by Jason W. Edwards is made available by Defense Visual Information Distribution Service; public domain.)*

Medical or clinical laboratories employ a variety of individuals in technical positions (Figure 16.2.3):

- Medical technologists (MT), also known as clinical laboratory technologists (CLT), typically hold a bachelor's degree and certification from an accredited training program. They perform a wide variety of tests on various body fluids, including blood. The information they provide is essential to the primary care providers in determining a diagnosis and in monitoring the course of a disease and response to treatment.
- Medical laboratory technicians (MLT) typically have an associate's degree but may perform duties similar to those of an MT.
- Medical laboratory assistants (MLA) spend the majority of their time processing samples and carrying out routine assignments within the lab. Clinical training is required, but a degree may not be essential to obtaining a position.

Formed Elements

The formed elements (Figure 16.2.4) include erythrocytes (RBCs), leukocytes (WBCs), and platelets (thrombocytes). These cells are formed mostly in the red bone marrow (not within the blood itself) and one of them, platelets, are circulating fragments of a much larger cell so referring to them as cells (even thrombocytes) is a misnomer. It is for this reason that this group is not labeled as cellular components of blood.

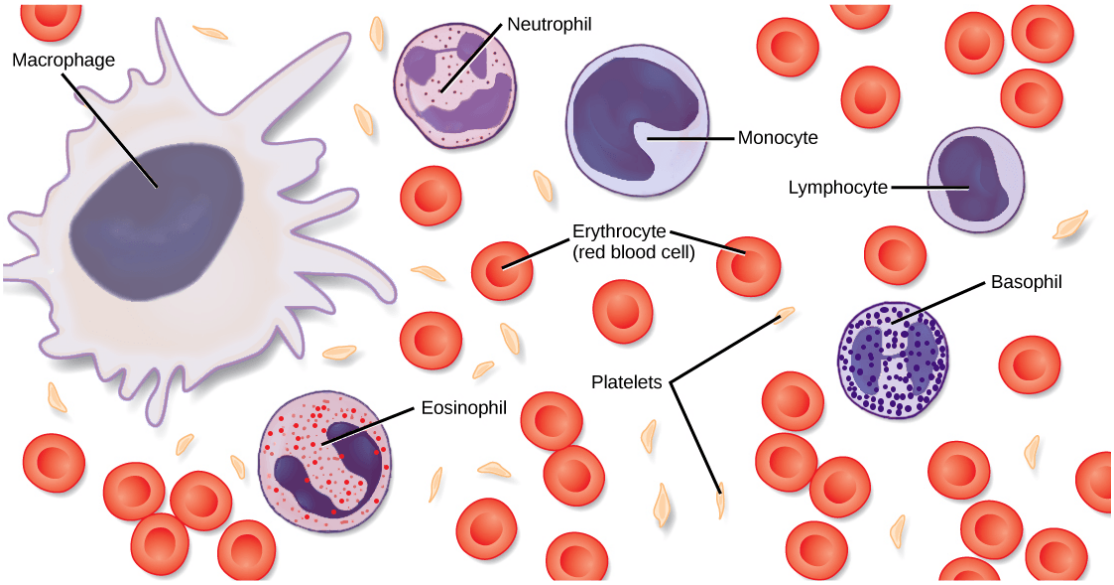

Figure 16.2.4: Formed Elements of Blood. Formed elements in the blood include red blood cells (erythrocytes), white blood cells (leukocytes - basophils, eosinophils, lymphocytes, monocytes, and neutrophils), and platelets. Macrophages are activated monocytes that exit the blood vessels. *(Image credit: "Formed Elements of Blood" by Jennifer Lange is licensed under CC BY-NC-SA 4.0, modification of original by OpenStax.)*

Erythrocytes function to carry oxygen through the bloodstream so it may be delivered throughout the body. There are several different types of leukocytes that have unique functions contributing to the body's housekeeping and sickness fighting efforts. Platelets function in helping to maintain blood volume (a process called hemostasis) by forming blood clots to prevent blood loss.

The formed elements are summarized in Table 16.2.2. Each category of formed element is covered in more detail in a dedicated section of this chapter.

Table** 16.2.2 **Summary of Formed Elements in Blood

Formed Element	Major subtypes	Numbers present per microliter (µL); mean (range)	Appearance in a standard blood smear	Summary of functions	Comments
Erythrocytes (red blood cells)		5.2 million (4.4-6.0 million)	Flattened biconcave disc; no nucleus; pale red color	Transport oxygen and some carbon dioxide between tissues and lungs	Lifespan of approximately 120 days
Leukocytes (white blood cells)	Neutrophils (granulocyte)	4150 (1800-7300)	Nuclear lobes increase with age; pale lilac granules	Phagocytic; particularly against bacteria	Most common; lifespan of minutes to days

Formed Element	Major subtypes	Numbers present per microliter (μL); mean (range)	Appearance in a standard blood smear	Summary of functions	Comments
	Eosinophils (granulocyte)	165 (0-700)	Nucleus generally two-lobed; bright red-orange granules	Phagocytic; particularly against parasite; release antihistamines; increase in allergies and parasitic infections.	Lifespan of minutes to days.
	Basophils (granulocyte)	44 (0-150)	Nucleus generally two-lobed but difficult to see due to presence of heavy, dense, dark purple granules	Promotes inflammation; granules contains histamine	Least common; lifespan unknown
	Lymphocytes (agranulocyte)	2185 (1500-4000)	Spherical cells with a single often large nucleus occupying much of the cell's volume; stains purple; seen in large (natural killer cells) and small (B and T cells) variants	Primarily specific (adaptive) immunity: T cells directly attack other cells; B cells release antibodies; natural killer cells are like T cells but nonspecific	Initial cells originate in bone marrow, but secondary production occurs in lymphatic tissue; several distinct subtypes; memory cells form after exposure to a pathogen and rapidly increase responses to subsequent exposure; lifespan of many years
	Monocytes (agranulocyte)	455 (200-950)	Largest leukocyte with an indented or horseshoe-shaped nucleus	Very effective phagocytic cells engulfing pathogens or worn-out cells; also serve as antigen-presenting cells (APCs) for other components of the immune system	Produced in red bone marrow; referred to as macrophages after leaving circulation

Formed Element	Major subtypes	Numbers present per microliter (µL); mean (range)	Appearance in a standard blood smear	Summary of functions	Comments
Platelets		350,000 (150,000-500,000)	Cellular fragments surrounded by a plasma membrane and containing granules; purple stain	Hemostasis plus release growth factors for repair and healing of tissue	Formed from megakaryocytes that remain in the red bone marrow and shed platelets into circulation

In addition to measuring the hematocrit, a very common blood test is a **complete blood count (or CBC) with differential**. A small amount of blood is taken from a vein, usually in the arm. Then the sample is analyzed by a CBC machine, also called a hematology analyzer, that documents the quantity and morphology of the cellular elements. The sample can be further analyzed by a medical laboratory scientist or a pathologist if needed. The report includes numbers for each specific type of leukocyte for the differential portion, along with some other information about the sizes, shapes, and characteristics of each element. The grid on the slide allows counts to be converted into concentrations of each formed element in the blood that can be compared with expected values such as those listed in Table 16.2.2. Elevated or low levels of each type of formed element can indicate specific health concerns.

Complete Blood Count

Why is this test run and what does running the test involve?

This interactive element is not available in this format. Visit the link or scan the QR code to access it online.

View this YouTube Video online

A CBC counts the cells in your blood and the differential counts the percentage and absolute numbers of each type of white blood cell. There are many reasons your levels may not be in the normal range. For example:

- Abnormal levels of red blood cells, hemoglobin, or hematocrit may be a sign of dehydration, anemia, heart disease, or too little iron in your body.
- A low white cell count may be a sign of an autoimmune disorder, bone marrow disorder, or cancer.
- A high white cell count may be a sign of an infection or a reaction to a medicine.

The results of CBC with differential results look like this sample:

Component	Your Value	Standard Range	Units	Flag
White Blood Cell Count	5.4	4.0 - 11.0	K/uL	
Red Blood Cell Count	5.20	4.40 - 6.00	M/uL	
Hemoglobin	16.0	13.5 - 18.0	g/dL	
Hematocrit	47.2	40.0 - 52.0	%	
MCV	91	80 - 100	fL	
MCH	30.8	27.0 - 33.0	pg	
MCHC	33.9	31.0 - 36.0	g/dL	
RDW	12.7	<16.4 -	%	
Platelet Count	149	150 - 400	K/uL	L
Differential Type	Automated			
Neutrophil %	56	49.0 - 74.0	%	
Lymphocyte %	23	26.0 - 46.0	%	L
Monocyte %	13	2.0 - 12.0	%	H
Eosinophil %	7	0.0 - 5.0	%	H
Basophil %	1	0.0 - 2.0	%	
Abs. Neutrophil	3.1	2.0 - 8.0	K/uL	
Abs. Lymphocyte	1.2	1.0 - 5.1	K/uL	
Abs. Monocyte	0.7	0.0 - 0.8	K/uL	
Abs. Eosinophil	0.4	0.0 - 0.5	K/uL	
Abs. Basophil	0.0	0.0 - 0.2	K/uL	

Figure 16.2.5: Example Complete Blood Count test results with differential. (CBC by Paul Irish is licensed under CC BY 2.0.)

If any of your levels are abnormal (Figure 16.2.5), it doesn't always mean you have a medical condition that needs treatment. Diet, activity level, medicines, having a menstrual period, not drinking enough water, and other factors can affect the results. Talk with your provider to learn what your results mean.

Concept Review

Blood is a fluid connective tissue critical to the transportation of nutrients, gases, and wastes throughout the body; to defend the body against infection and other threats; and to the homeostatic regulation of pH, temperature, and other internal conditions. Blood is composed of formed elements—erythrocytes, leukocytes, and cell fragments called platelets—and a fluid extracellular matrix called plasma. More than 90 percent of plasma is water. The remainder is mostly plasma proteins—mainly albumin, globulins, and fibrinogen—and other dissolved solutes such as glucose, lipids, electrolytes, and dissolved gases. Because of the formed elements, the plasma proteins, and other solutes, blood is sticky and more viscous than water. It is also slightly alkaline, and its temperature is slightly higher than normal body temperature.

Review Questions

Query 16.2.1

This interactive element is not available in this format. Visit the link or scan the QR code to access it online.

View this Interactive Content online

Critical Thinking Questions

Query 16.2.2

This interactive element is not available in this format. Visit the link or scan the QR code to access it online.

View this Interactive Content online

Query 16.2.3

This interactive element is not available in this format. Visit the link or scan the QR code to access it online.

View this Interactive Content online

Glossary

Query 16.2.4

This interactive element is not available in this format. Visit the link or scan the QR code to access it online.

View this Interactive Content online

Contributors and Attributions

OpenStax Anatomy & Physiology (CC BY 4.0). Access for free at https://openstax.org/books/anatomy-and-physiology

This page titled 16.2: An Overview of Blood is shared under a CC BY-NC-SA 4.0 license and was authored, remixed, and/or curated by Jennifer Lange et al..

- 16.2: An Overview of Blood by Whitney Menefee, Julie Jenks, Chiara Mazzasette, and Kim-Leiloni Nguyen is licensed CC BY 4.0.

16.3: Erythrocytes

By the end of this section, you will be able to:

- Describe the structure and function of erythrocytes
- Discuss the various steps in the lifecycle of an erythrocyte

The **erythrocyte**, commonly known as a red blood cell (or RBC), is by far the most common formed element. A single drop of blood contains millions of erythrocytes and just thousands of leukocytes. Specifically, males have about 5.4 million erythrocytes per microliter (μL) of blood, and females have approximately 4.8 million per μL. In fact, erythrocytes are estimated to make up about 25 percent of the total cells in the body. Erythrocytes are also smaller than leukocytes and most other body cells, with a mean diameter of only about 7–8 micrometers (μm) (Figure 16.3.1, see Table 16.2.2 Summary of Formed Elements in Blood).

Due to their chemical properties, oxygen and carbon dioxide molecules largely cannot be transported dissolved in plasma. Thus, the primary functions of erythrocytes are to pick up inhaled oxygen from the lungs and transport it to the body's tissues, and to pick up some (about 24 percent) carbon dioxide waste at the tissues and transport it to the lungs for exhalation. Although leukocytes typically leave the blood vessels to perform their defensive functions, erythrocytes remain in the blood vessels and movement of erythrocytes from the blood vessels is abnormal.

Production of erythrocytes in red bone marrow occurs at the staggering rate of more than 2 million cells per second. For this production to occur, a number of raw materials must be present in adequate amounts. These include the same nutrients that are essential to the production and maintenance of any cell, such as glucose, lipids, and amino acids. However, erythrocyte production also requires several trace elements including not only iron, but copper, zinc, and the B vitamins folic acid (folate) and vitamin B_{12}. Erythrocytes live up to 120 days in circulation, after which the worn-out cells are removed by a type of white blood cell called a **macrophage**, located primarily within the red bone marrow, liver, and spleen. Organelles within the macrophages break down the hemoglobin and plasma membrane components of the erythrocytes. The amino acid, heme, and iron components of the degraded erythrocytes' hemoglobin are recycled when possible.

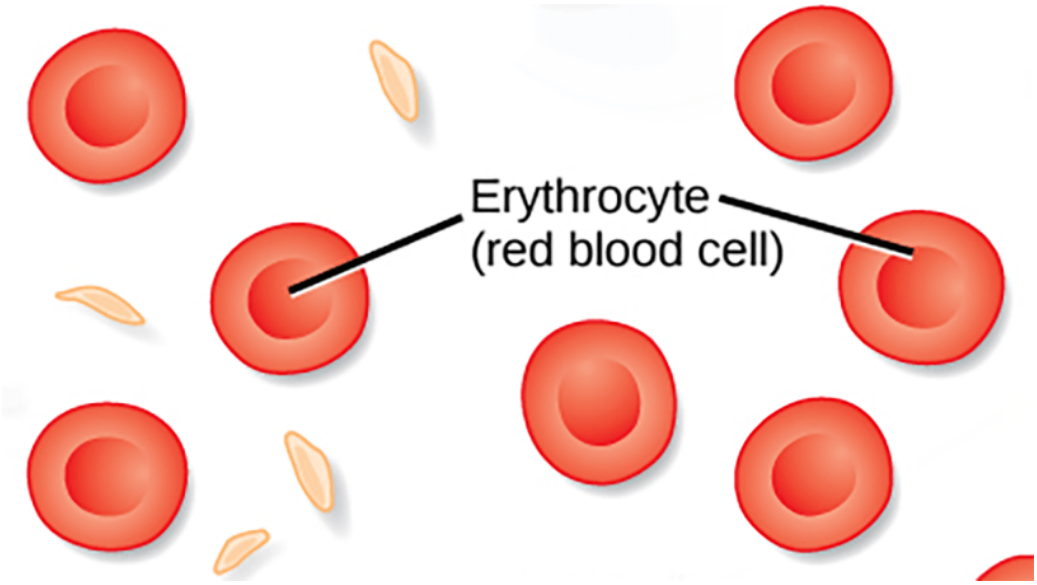

Figure 16.3.1: Erythrocytes. Erythrocytes are most numerous blood cells. They are red in color and biconcave in shape. *(Image credit: "Erythrocytes" by Jennifer Lange is licensed under CC BY-NC-SA 4.0, modification of original by OpenStax.)*

Shape and Structure of Erythrocytes

As an erythrocyte matures in the red bone marrow, it extrudes (pushes out) its nucleus and most of its other organelles. During the first day or two that it is in the circulation, an immature erythrocyte, known as a **reticulocyte**, will still typically contain remnants

of organelles focused on making functional hemoglobin protein complexes. After the first day or two in circulation however, the erythrocyte matures and finishes the differentiation process by shedding its remaining membrane-bound organelles, meaning it will no longer make any new proteins, essentially leaving it as a sac of roughly 300 million hemoglobin molecules. Being absent of organelles also means erythrocytes lack mitochondria, causing them to rely on anaerobic respiration. This means that they do not utilize any of the oxygen they are transporting, maximizing its delivery to the tissues. Reticulocytes do retain some structural proteins, such as the cytoskeletal element spectrin, that help them maintain their unique shape and also enable them to change their shape to squeeze through capillaries. Reticulocytes should comprise approximately 1–2 percent of the erythrocyte count and provide a rough estimate of the rate of erythrocyte production, with abnormally low or high rates indicating problems with underproduction or overproduction of erythrocytes, respectively.

Erythrocytes are uniquely shaped as biconcave discs; that is, they are plump at their periphery and very thin in the center (Figure 16.3.2). Since they lack most organelles, there is more interior space for the presence of the hemoglobin molecules that transport gases. The biconcave shape also provides a greater surface area across which gas exchange can occur, relative to its volume; a sphere of a similar diameter would have a lower surface area-to-volume ratio. In the capillaries, the oxygen carried by the erythrocytes can diffuse into the plasma and then through the capillary walls to reach the cells, whereas some of the carbon dioxide produced by the cells as a waste product diffuses into the capillaries to be picked up by the erythrocytes. Capillary beds are extremely narrow, slowing the passage of the erythrocytes and providing an extended opportunity for gas exchange to occur. However, the space within capillaries can be so minute that, despite their own small size, erythrocytes may have to fold in on themselves if they are to make their way through. Fortunately, their structural proteins like spectrin are flexible, allowing them to bend over themselves to a surprising degree, then spring back again when they enter a wider vessel. In wider vessels, erythrocytes may stack up much like a roll of coins, forming a rouleaux, from the French word for “roll.”

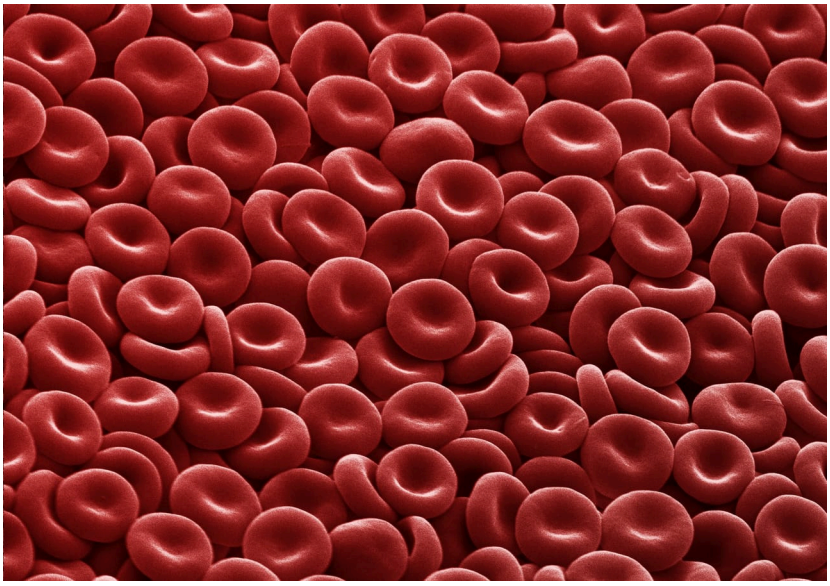

Figure 16.3.2: Shape of Erythrocytes. Erythrocytes are biconcave discs with very shallow centers. This shape optimizes the ratio of surface area to volume, facilitating gas exchange. It also enables them to fold up as they move through narrow blood vessels. (Image credit: "Jn7ws94a-2" by Annie Cavanagh is licensed under CC BY-SA 4.0)

Hemoglobin

Hemoglobin is a large molecule made up of proteins and iron. It consists of four folded chains of a protein called **globin**, designated alpha chain 1 and 2, and beta chain 1 and 2. Each of these globin molecules is bound to a red pigment molecule called **heme**, which contains an ion of iron (Fe^{2+}) (Figure 16.3.3). Each iron ion in the heme can bind to one oxygen molecule; therefore, each hemoglobin molecule can transport four oxygen molecules. An individual erythrocyte may contain about 300 million hemoglobin molecules, and therefore can bind to and transport up to 1.2 billion oxygen molecules.

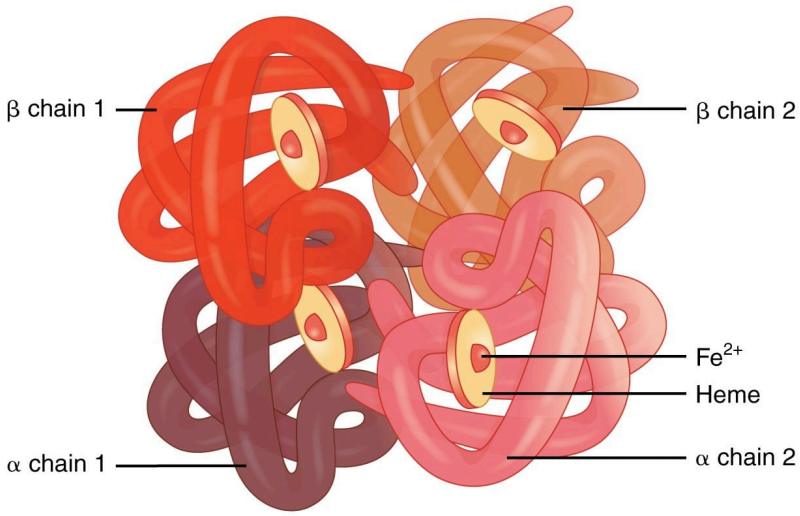

Figure 16.3.3: Hemoglobin. A molecule of hemoglobin contains four globin protein subunits, each of which is bound to one molecule of the iron-containing red pigmented heme. A single erythrocyte can contain 300 million hemoglobin molecules, and thus more than 1 billion oxygen molecules. (Image credit: "Hemoglobin" by OpenStax is licensed under CC BY 3.0)

In the lungs, hemoglobin picks up oxygen, which binds to the iron ions, forming **oxyhemoglobin**. The bright red, oxygenated hemoglobin travels to the body tissues, where it releases some of the oxygen molecules, becoming darker red **deoxyhemoglobin**, sometimes referred to as reduced hemoglobin. Oxygen release depends on the need for oxygen in the surrounding tissues, so hemoglobin rarely if ever leaves all of its oxygen behind. In the capillaries, carbon dioxide enters the bloodstream. About 76 percent dissolves in the plasma, some of it remaining as dissolved CO_2, and the remainder forming bicarbonate ions. About 23–24 percent of it binds to the amino acids in hemoglobin, forming a molecule known as **carbaminohemoglobin**. From the capillaries, the hemoglobin carries carbon dioxide back to the lungs, where it releases it for exchange of oxygen.

In determining oxygenation of tissues, the value of greatest interest in healthcare is the percent saturation; that is, the percentage of hemoglobin sites occupied by oxygen in a patient's blood. Percent saturation is normally monitored using a device known as a pulse oximeter, which is applied to a thin part of the body, typically the tip of the patient's finger. The device works by sending two different wavelengths of light (one red, the other infrared) through the finger and measuring the light with a photodetector as it exits. Hemoglobin absorbs light differentially depending upon its saturation with oxygen. The machine calibrates the amount of light received by the photodetector against the amount absorbed by the partially oxygenated hemoglobin and presents the data as percent saturation. Normal pulse oximeter readings range from 95–100 percent. Lower percentages reflect **hypoxemia**, or low blood oxygen. The term hypoxia is more generic and simply refers to low oxygen levels. Oxygen levels are also directly monitored from free oxygen in the plasma typically following an arterial stick. When this method is applied, the amount of oxygen present is expressed in terms of partial pressure of oxygen or simply pO_2 and is typically recorded in units of millimeters of mercury, mm Hg.

The kidneys filter about 180 liters (~380 pints) of blood in an average adult each day, or about 20 percent of the total resting blood volume, and thus serve as ideal sites for receptors that monitor oxygen saturation for the body. In response to hypoxemia, less oxygen will exit the vessels supplying the kidney, resulting in hypoxia (low oxygen concentration) in the tissue fluid of the kidney where oxygen concentration is actually monitored. Interstitial fibroblasts in the connective tissue within the kidney secrete a hormone called erythropoietin (EPO) to stimulate erythrocyte production and restore oxygen levels. In a classic negative-feedback loop, as oxygen saturation rises, EPO secretion falls, and vice versa, thereby maintaining homeostasis. Populations dwelling at high elevations, with inherently lower levels of oxygen in the atmosphere, naturally maintain a hematocrit higher than people living at sea level. Consequently, people traveling to high elevations may experience symptoms of hypoxemia, such as fatigue, headache, and shortness of breath, for a few days after their arrival. In response to the hypoxemia, the kidneys secrete EPO to step up the production of erythrocytes until homeostasis is achieved once again. To avoid the symptoms of hypoxemia, or altitude sickness, mountain climbers typically rest for several days to a week or more at a series of camps situated at increasing elevations to allow EPO levels and, consequently, erythrocyte counts to rise. When climbing the tallest peaks, such as Mt. Everest and K2 in the Himalayas, many mountain climbers rely upon bottled oxygen as they near the summit.

DISORDERS OF THE....

Erythrocytes

Changes in the levels of erythrocytes can have significant effects on the body's ability to effectively deliver oxygen to the tissues. Ineffective hematopoiesis results in insufficient numbers of erythrocytes and results in one of several forms of anemia. An overproduction of erythrocytes produces a condition called polycythemia. The primary drawback with polycythemia is not a failure to directly deliver enough oxygen to the tissues, but rather the increased viscosity of the blood, which makes it more difficult for the heart to circulate the blood.

The size, shape, and number of erythrocytes, and the number of hemoglobin molecules can have a major impact on a person's health. When the blood is not carrying sufficient oxygen to the tissues, the general condition is called **anemia**. There are more than 400 types of anemia and more than 3.5 million Americans suffer from this condition related typically to an insufficient number of erythrocytes or a deficiency of hemoglobin. Anemia can be broken down into three major groups: those caused by blood loss, those caused by faulty or decreased erythrocyte production, and those caused by excessive destruction of erythrocytes. Clinicians often use two groupings in diagnosis: The kinetic approach focuses on evaluating the production, destruction, and removal of erythrocytes, whereas the morphological approach examines the erythrocytes themselves, paying particular emphasis to their size and shape. A common test is the mean corpuscle volume (MCV), which measures size. Normal-sized cells are referred to as normocytic, smaller-than-normal cells are referred to as microcytic, and larger-than-normal cells are referred to as macrocytic. Reticulocyte counts are also important and may reveal inadequate production of erythrocytes. The effects of the various anemias are widespread, because reduced numbers of erythrocytes or hemoglobin will result in lower levels of oxygen being delivered to body tissues. Since oxygen is required for tissue functioning, anemia produces fatigue, lethargy, and an increased risk for infection. An oxygen deficit in the brain impairs the ability to think clearly, and may prompt headaches and irritability. Lack of oxygen leaves the patient short of breath, even as the heart and lungs work harder in response to the deficit.

Blood loss anemias are fairly straightforward. In addition to bleeding from wounds or other lesions, these forms of anemia may be due to ulcers, hemorrhoids, inflammation of the stomach (gastritis), and some cancers of the gastrointestinal tract. The excessive use of aspirin or other non-steroidal anti-inflammatory drugs (NSAIDs) such as ibuprofen can trigger ulceration and gastritis. Excessive menstruation and loss of blood during childbirth are also potential causes.

Anemias caused by faulty or decreased erythrocyte production include sickle cell anemia, iron deficiency anemia, vitamin deficiency anemia, and diseases of the red bone marrow and stem cells.

- A characteristic change in the shape of erythrocytes is seen in **sickle cell disease** (also referred to as sickle cell anemia). A genetic disorder, it is caused by production of an abnormal type of hemoglobin, called hemoglobin S, which delivers less oxygen to tissues and causes erythrocytes to assume a sickle (or crescent) shape, especially at low oxygen concentrations (Figure 16.3.5). These abnormally shaped cells can then become lodged in narrow capillaries because they are unable to fold in on themselves to squeeze through, blocking blood flow to tissues and causing a variety of serious problems from painful joints to delayed growth and even blindness and cerebrovascular accidents (strokes). Sickle cell anemia is a genetic condition particularly found in individuals of African descent.

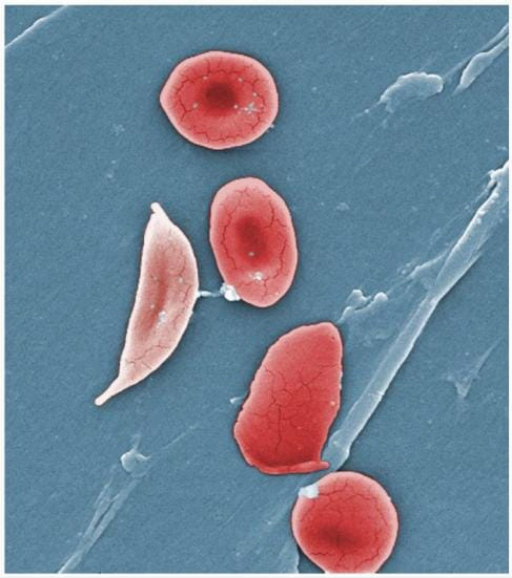

Figure 16.3.5: Sickle Cells. Sickle cell anemia is caused by a mutation in one of the hemoglobin genes. Erythrocytes produce an abnormal type of hemoglobin, which causes the cell to take on a sickle or crescent shape. *(Image credit: "Sickle Cells" by OpenStax is licensed under CC BY 3.0.)*

- Iron deficiency anemia is the most common type and results when the amount of available iron is insufficient to allow production of sufficient heme. This condition can occur in individuals with a deficiency of iron in the diet and is especially common in teens and children as well as in vegans and vegetarians. Additionally, iron deficiency anemia may be caused by either an inability to absorb and transport iron or slow, chronic bleeding.
- Vitamin-deficient anemias generally involve insufficient vitamin B_{12} and folate.
  - Megaloblastic anemia involves a deficiency of vitamin B_{12} and/or folate, and often involves diets deficient in these essential nutrients. Lack of meat or a viable alternate source, and overcooking or eating insufficient amounts of vegetables may lead to a lack of folate.
  - Pernicious anemia is caused by poor absorption of vitamin B_{12} and is often seen in patients with Crohn's disease (a severe intestinal disorder often treated by surgery), surgical removal of the intestines or stomach (common in some weight loss surgeries), intestinal parasites, and AIDS.
  - Pregnancies, some medications, excessive alcohol consumption, and some diseases such as celiac disease are also associated with vitamin deficiencies. It is essential to provide sufficient folic acid during the early stages of pregnancy to reduce the risk of neurological defects, including spina bifida, a failure of the neural tube to close.
- Assorted disease processes can also interfere with the production and formation of erythrocytes and hemoglobin. If myeloid stem cells are defective or replaced by cancer cells, there will be insufficient quantities of erythrocytes produced.
  - Aplastic anemia is the condition in which there are deficient numbers of the stem cells used to produce erythrocytes. Aplastic anemia is often inherited, or it may be triggered by radiation, medication, chemotherapy, or infection.
  - **Thalassemia** is an inherited condition typically occurring in individuals from the Middle East, the Mediterranean, African, and Southeast Asia, in which maturation of the erythrocytes does not proceed normally. The most severe form is called Cooley's anemia.
  - Lead exposure from industrial sources or even dust from paint chips of iron-containing paints or pottery that has not been properly glazed may also lead to destruction of the red marrow.
- Various disease processes also can lead to anemias. These include chronic kidney diseases often associated with a decreased production of EPO, hypothyroidism, some forms of cancer, lupus, and rheumatoid arthritis.

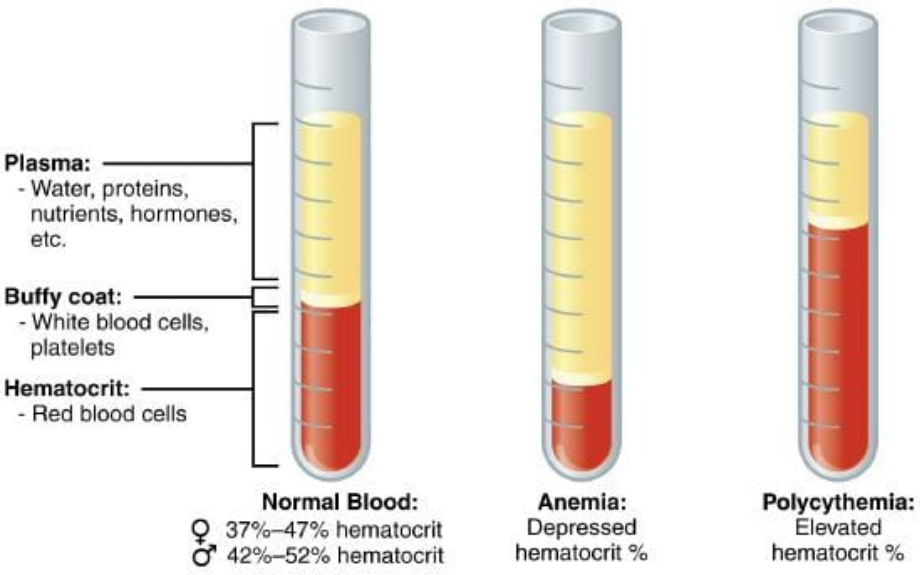

Figure 16.3.6: Normal and Abnormal Hematocrits. In anemias the hematocrit (percentage of RBC) is decreased and in polycythemia the hematocrit is increased. *(Image credit: "Composition of Blood" by OpenStax College is licensed under CC BY 3.0, via Wikimedia Commons.)*

In contrast to anemia, an elevated erythrocyte count is called **polycythemia** and is detected in a patient's elevated hematocrit. It can occur transiently in a person who is dehydrated; when water intake is inadequate or water losses are excessive, the plasma volume falls. As a result, the hematocrit rises. For reasons mentioned earlier, a mild form of polycythemia is chronic but normal in people living at high altitudes. Some elite athletes train at high elevations specifically to induce this phenomenon. Finally, a type of red bone marrow disease called polycythemia vera (from the Greek vera = "true") causes an excessive production of immature erythrocytes. Polycythemia vera can dangerously elevate the viscosity of blood, raising blood pressure and making it more difficult for the heart to pump blood throughout the body. It is a relatively rare disease that occurs more often in men than women, and is more likely to be present in patients over 60 years of age.

Concept Review

The most abundant formed element in blood, erythrocytes are red, biconcave discs packed with an oxygen-carrying compound called hemoglobin. The hemoglobin molecule contains four globin proteins bound to a pigment molecule called heme, which contains an ion of iron. In the bloodstream, iron picks up oxygen in the lungs and drops it off in the tissues; the amino acids in hemoglobin then transport some carbon dioxide from the tissues back to the lungs. Erythrocytes live only 120 days on average, and thus must be continually replaced. Worn-out erythrocytes are phagocytized by macrophages and their hemoglobin is broken down. The breakdown products are recycled or removed as wastes; globin is broken down into amino acids for synthesis of new proteins; iron is stored in the liver or spleen or used by the bone marrow for production of new erythrocytes; and the remnants of heme are converted into bilirubin, or other waste products that are taken up by the liver and excreted in the bile or removed by the kidneys. Anemia is a deficiency of erythrocytes or hemoglobin, whereas polycythemia is an excess of erythrocytes.

Review Questions

Query 16.3.1

This interactive element is not available in this format. Visit the link or scan the QR code to access it online.

View this Interactive Content online

Critical Thinking Questions

Query 16.3.2

This interactive element is not available in this format. Visit the link or scan the QR code to access it online.

View this Interactive Content online

Query 16.3.3

This interactive element is not available in this format. Visit the link or scan the QR code to access it online.

View this Interactive Content online

Glossary

Query 16.3.4

This interactive element is not available in this format. Visit the link or scan the QR code to access it online.

View this Interactive Content online

Contributors and Attributions

OpenStax Anatomy & Physiology (CC BY 4.0). Access for free at https://openstax.org/books/anatomy-and-physiology

This page titled 16.3: Erythrocytes is shared under a CC BY-NC-SA 4.0 license and was authored, remixed, and/or curated by Jennifer Lange et al..

- 16.3: Erythrocytes by Whitney Menefee, Julie Jenks, Chiara Mazzasette, and Kim-Leiloni Nguyen is licensed CC BY 4.0.

16.4: Leukocytes and Platelets

By the end of this section, you will be able to:

- Describe the general characteristics of leukocytes
- Classify leukocytes according to their lineage, their main structural features, and their primary functions
- Discuss the most common malignancies involving leukocytes
- Identify the lineage, basic structure, and function of platelets

Leukocytes

The **leukocyte**, commonly known as a white blood cell (or WBC), is a major component of the body's defenses against disease. Leukocytes protect the body against invading microorganisms and body cells with mutated DNA, and they clean up debris. You may find it helpful to reference the image Formed Elements in a Blood Sample (Figure 16.3.1) and the Table 16.2.2 Summary of Formed Elements in Blood along with this content.

Characteristics of Leukocytes

Although leukocytes and erythrocytes both originate from hematopoietic stem cells in the red bone marrow, they are very different from each other in many significant ways. For instance, leukocytes are far less numerous than erythrocytes; typically there are only 5000 to 10,000 per μL. They are also larger than erythrocytes and are the only formed elements that are complete cells in circulation, possessing a nucleus and organelles. Although there is just one type of erythrocyte, there are many types of leukocytes. Most of these types have a much shorter lifespan than that of erythrocytes, some as short as a few hours, or even a few minutes in the case of acute infection.

One of the most distinctive characteristics of leukocytes is their movement. Whereas erythrocytes spend their days circulating within the blood vessels, leukocytes routinely leave the bloodstream to perform their defensive functions in the body's tissues. For leukocytes, the vascular network is often simply a highway they travel and soon exit to reach their true destination. When they arrive, they may differentiate further and be given distinct names, such as macrophage or microglia, depending on their function. As shown in Figure 16.4.1, they leave the capillaries—the smallest blood vessels—or other small vessels through a process known as **emigration** (from the Latin for "removal") or **diapedesis** (dia- = "through"; -pedan = "to leap") in which they squeeze through adjacent cells in a blood vessel wall.

Once they have exited the capillaries, some leukocytes will take up residence in lymphatic tissue, bone marrow, the spleen, the thymus, or other organs. Others will move about through the tissue spaces very much like amoebae, continuously extending their plasma membranes, sometimes wandering freely, and sometimes moving toward the direction in which they are drawn by chemical signals. This attracting of leukocytes occurs because of **positive chemotaxis** (literally "movement in response to chemicals"), a phenomenon in which injured or infected cells and nearby leukocytes emit the equivalent of a chemical "911" call, attracting more leukocytes to the site. In clinical medicine, the differential counts of the types and percentages of leukocytes present are often key indicators in making a diagnosis and selecting a treatment.

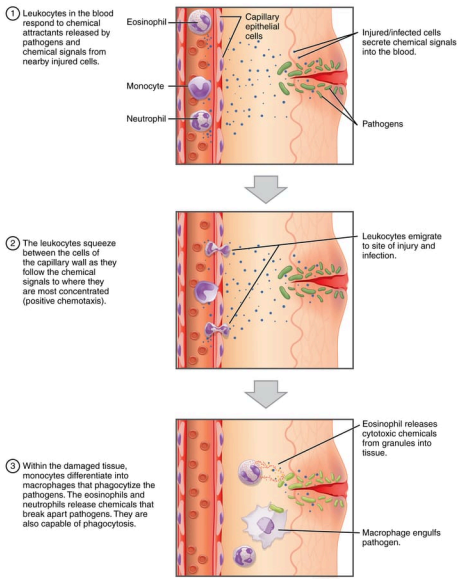

Figure 16.4.1: Emigration or Diapedesis. Injured and/or infected cells secrete chemical signals into the blood. Leukocytes in the blood respond to chemical attractants released by pathogens and chemical signals from nearby injured cells. The leukocytes emigrate or squeeze between the cells of the capillary wall as they follow the chemical signals to where they are most concentrated (positive chemotaxis). Within the damaged tissue, monocytes differentiate into macrophages that phagocytize the pathogens. The eosinophils and neutrophils release cytotoxic chemicals that break apart pathogens from granules into the tissue. They are also capable of phagocytosis. exit the blood vessel and then move through the connective tissue of the dermis toward the site of a wound. Some leukocytes, such as the eosinophil and neutrophil, are characterized as granular leukocytes. They release chemicals from their granules that destroy pathogens; they are also capable of phagocytosis. The monocyte differentiates into a macrophage that then phagocytizes the pathogens. (Image credit: "Emigration" by OpenStax is licensed under CC BY 3.0)

Classification of Leukocytes

When scientists first began to observe stained blood slides, it quickly became evident that leukocytes could be divided into two groups, according to whether their cytoplasm contained highly visible granules:

- **Granular leukocytes** (granulocytes) contain abundant granules within the cytoplasm. They include neutrophils, eosinophils, and basophils (you can view their lineage from myeloid stem cells in Figure 16.5.1 Hemopoietic System of Bone Marrow).
- While granules are not totally lacking in **agranular leukocytes** (agranulocytes), they are far fewer and less obvious. Agranular leukocytes include monocytes, which also arise from myeloid stem cells and mature into macrophages that are phagocytic, and lymphocytes, which arise from the lymphoid stem cell line.

Granular Leukocytes

We will consider the granular leukocytes (granulocytes) in order from most common to least common. All of these are produced in the red bone marrow and have a short lifespan of hours to days. They typically have a lobed nucleus and are classified according to which type of stain best highlights their granules (Figure 16.4.2).

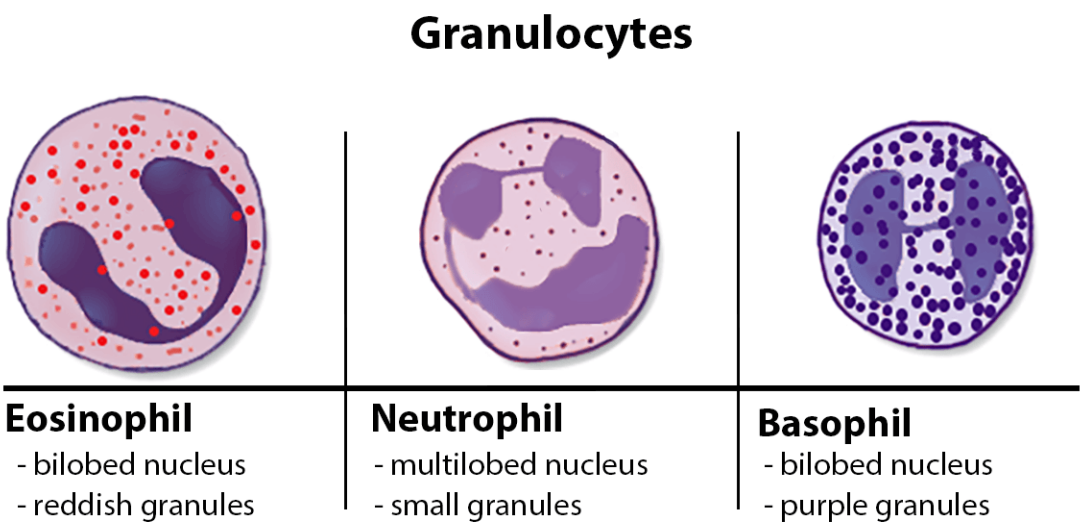

Figure 16.4.2: Granulocytes. A neutrophil has small granules that stain light lilac and a nucleus with two to five lobes. An eosinophil's granules are slightly larger and stain reddish-orange, and its nucleus has two lobes. A basophil has large granules that stain dark blue to purple and a two-lobed nucleus. *(Image credit: "Granulocytes" by Jennifer Lange is licensed under CC BY-NC-SA 4.0, modification of original by OpenStax.)*

The most common of all the leukocytes, **neutrophils** (Figure 16.4.3) will normally comprise 50–70 percent of the total leukocyte count. They are 10–12 μm in diameter, significantly larger than erythrocytes. They are called neutrophils because their granules show up most clearly with stains that are chemically neutral (neither acidic nor basic). The granules are numerous but quite fine and normally appear light lilac. The nucleus has a distinct lobed appearance and may have two to five lobes, the number increasing with the age of the cell. Older neutrophils have increasing numbers of lobes and are often referred to as **polymorphonuclear** (a nucleus with many forms), or simply "polys." Younger and immature neutrophils begin to develop lobes and are known as "bands."

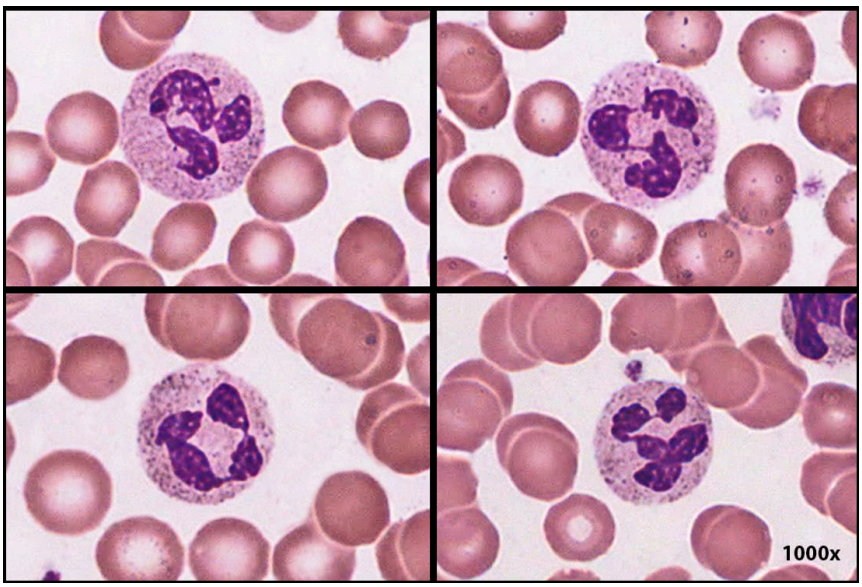

Figure 16.4.3: Neutrophils. Visually neutrophils are about twice the size of RBCs and have a nucleus with 3-5 lobes that can have a variety of appearances. *(Image credit: "Neutrophil" micrographs by Virginia Commonwealth University are licensed under CC BY-NC-SA 4.0)*

Neutrophils are rapid responders to the site of infection and are efficient phagocytes with a preference for bacteria. Their granules

include vesicles filled with substances that help them neutralize infectious agents: **lysozyme**, an enzyme capable of lysing, or breaking down, bacterial cell walls; oxidants such as hydrogen peroxide; and **defensins**, proteins that bind to and puncture bacterial and fungal plasma membranes so that the cell contents leak out. Abnormally high counts of neutrophils indicate infection and/or inflammation, particularly triggered by bacteria, but are also found in burn patients and others experiencing unusual stress. A burn injury increases the proliferation of neutrophils in order to fight off infection that can result from the destruction of the barrier of the skin. Low counts may be caused by drug toxicity and other disorders, and may increase an individual's susceptibility to infection.

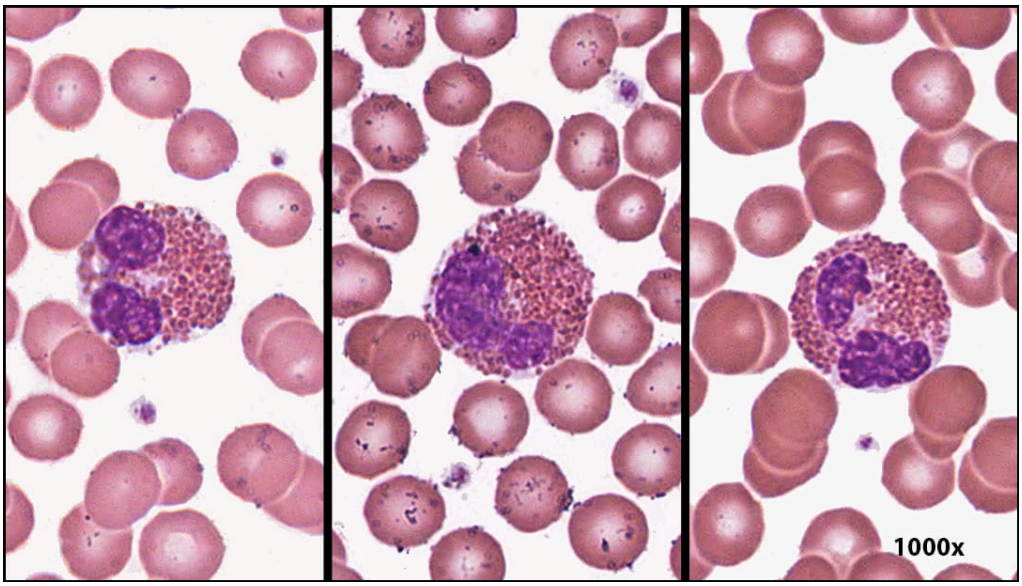

Figure 16.4.4: Eosinophils. Visually eosinophils are about twice the size of RBCs, have a nucleus with 2 lobes and have abundant reddish granules that are easy to see. *(Image credit: "Eosinophil" micrographs by Virginia Commonwealth University are licensed under CC BY-NC-SA 4.0.)*

Eosinophils typically represent 2–4 percent of the total leukocyte count. They are also 10–12 μm in diameter. The granules of eosinophils stain best with an acidic stain known as eosin (Figure 16.4.4). The nucleus of the eosinophil will typically have two lobes and, if stained properly, the granules will have a distinct red to orange color.

The granules of eosinophils include vesicles filled with antihistamine molecules, which counteract the activities of histamines, inflammatory chemicals produced by basophils and mast cells. Some eosinophil granules contain molecules toxic to parasitic worms, which can enter the body through the integument, or when an individual consumes raw or undercooked fish or meat. Eosinophils are also capable of phagocytosis and are particularly effective at disposing of antigen-antibody complexes. Antibodies are immunoglobulin proteins produced by certain lymphocytes that carry out several functional aspects of the specific immune response. Antibodies are designed to match-up to a specific molecule, typically a protein called an antigen, on the surface of an invading pathogen such as a parasitic worm, bacterium, or viral particle. Antibodies can also match up with a ubiquitous molecule (such as one on the surface of a pollen granule) and cause an allergic reaction. In this case the antigen is called an allergen, but antibody-antigen complexes are formed during the body's response to the presence of the allergen as if it were the antigen of an invading pathogen. Because it is the function of the eosinophils to use phagocytosis to clear out the debris associated with antibody-antigen complexes, high counts of eosinophils are typical of patients experiencing allergies and some autoimmune diseases, but eosinophils can also be elevated in the case of parasitic worm infestations. Low counts may be due to drug toxicity and stress.

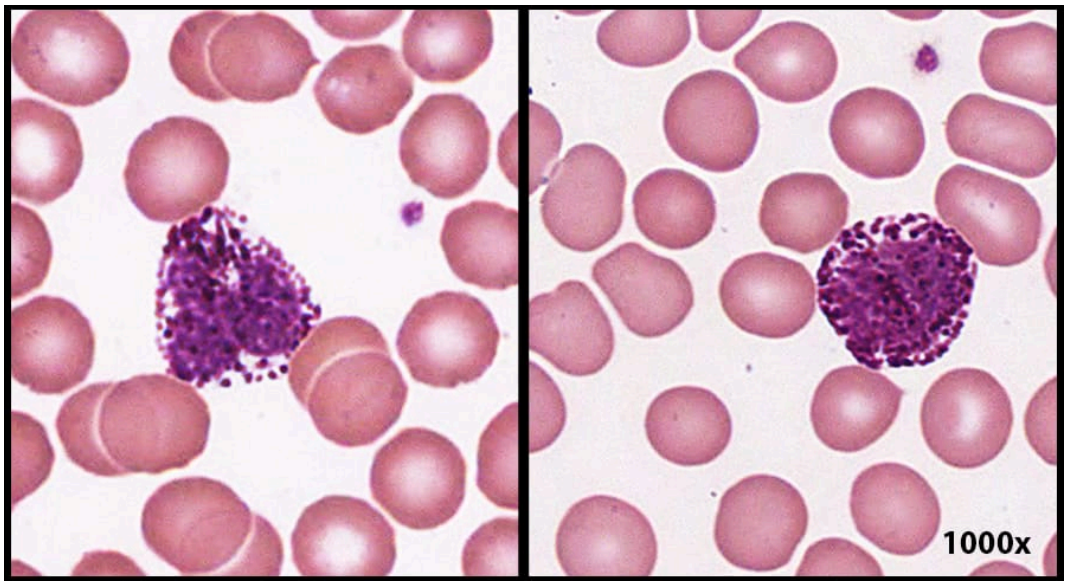

Figure 16.4.5: Basophils. Visually basophils are about twice the size of RBCs, have a nucleus with 2 lobes and have abundant dark blue or dark purple granules that are easy to see and often obscure the nucleus. *(Image credit: "Basophil" micrographs by Virginia Commonwealth University are licensed under CC BY-NC-SA 4.0.)*

Basophils are the least common leukocytes, typically comprising less than one percent of the total leukocyte count. They are slightly smaller than neutrophils and eosinophils at 8–10 μm in diameter. The granules of basophils stain best with basic (alkaline) stains. Basophils contain large granules that pick up a dark blue stain and are so common they may make it difficult to see the two-lobed nucleus (Figure 16.4.5).

In general, basophils intensify the inflammatory response. They share this trait with mast cells of connective tissue proper. In the past, mast cells were considered to be basophils that left the circulation. However, this appears not to be the case, as the two cell types develop from different lineages.

The granules of basophils release histamines, which contribute to inflammation, and heparin, which opposes blood clotting. High counts of basophils are associated with allergies, parasitic infections, and hypothyroidism. Low counts are associated with pregnancy, stress, and hyperthyroidism.

Agranular Leukocytes

Agranular leukocytes (agranulocytes) contain smaller, less-visible granules in their cytoplasm than do granular leukocytes. The nucleus is simple in shape, sometimes with an indentation but without distinct lobes. There are two major types of agranulocytes: lymphocytes and monocytes (Figure 16.4.6).

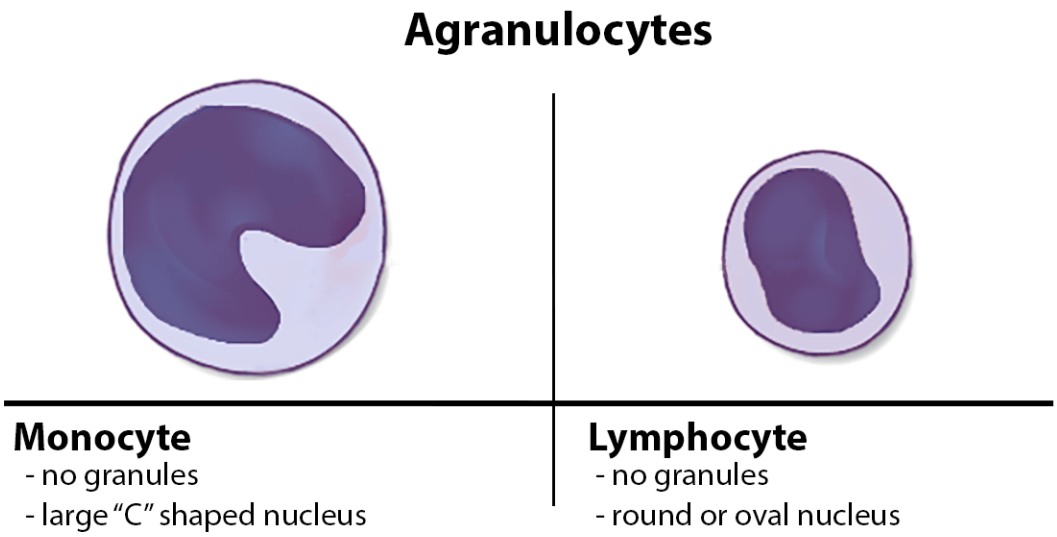

Figure 16.4.6: Agranulocytes. The cytoplasm of agranulocytes appears smooth. A monocyte is the largest WBC. It has a large nucleus shaped like a bean or a "C" and abundant cytoplasm. A lymphocyte, when un-activated, is the smallest WBC. Its nucleus is round or oval in shape and it occupies most of the interior of the cell. *(Image credit: "Agranulocytes" by Jennifer Lange is licensed under CC BY-NC-SA 4.0, modification of original by OpenStax.)*

Lymphocytes are the only formed element of blood that arises from lymphoid stem cells. Although they form initially in the red bone marrow, much of their subsequent development and reproduction occurs in the lymphatic tissues. Lymphocytes are the second most common type of leukocyte, accounting for about 20–30 percent of all leukocytes, and are an essential part of the immune response. The size range of lymphocytes is quite extensive, with some authorities recognizing two size classes and others three. Typically, the large cells are 10–14 μm and have a smaller nucleus-to-cytoplasm ratio (Figure 16.4.7). The smaller cells are typically 6–9 μm with a larger volume of nucleus to cytoplasm, creating a "halo" effect. A few cells may fall outside these ranges, at 14–17 μm. This finding has led to the three size range classification.

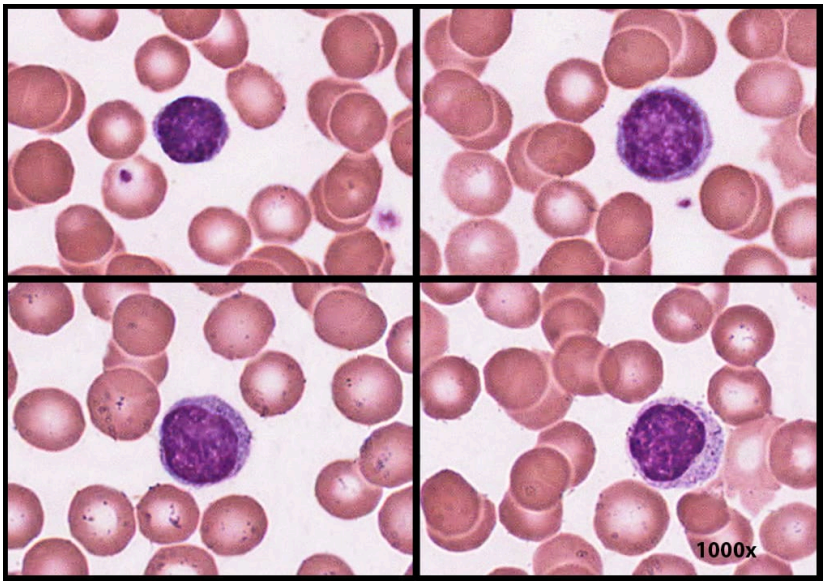

Figure 16.4.7: Lymphocytes. Lymphocytes are the smallest leukocytes and typically have a round or oval nucleus with a small ring of cytoplasm. They come in a variety of sizes, but none have abundant cytoplasm compared to the size of the nucleus. *(Image credit: "Lymphocyte" micrographs by Virginia Commonwealth University are licensed under CC BY-NC-SA 4.0.)*

The three major groups of lymphocytes include natural killer cells, B cells, and T cells. **Natural killer (NK) cells** are capable of recognizing cells that do not express "self" proteins on their plasma membrane or that contain foreign or abnormal markers. These "non-self" cells include abnormal body cells such as cancer cells, cells infected with a virus, and other cells with atypical surface proteins. Thus, they provide generalized, nonspecific immunity. The larger lymphocytes are typically NK cells.

B cells and T cells, also called **B lymphocytes** and **T lymphocytes**, play prominent roles in defending the body against specific pathogens (disease-causing microorganisms) and are involved in specific immunity. One form of B cells (plasma cells) produces the antibodies or immunoglobulins that bind to specific foreign or abnormal components of plasma membranes. This is also referred to as humoral (body fluid) immunity, since antibodies are proteins dissolved in body fluids. T cells provide cellular-level immunity by physically attacking foreign or diseased cells. A **memory cell** is a variety of both B and T cells that forms after exposure to a pathogen and mounts rapid responses upon subsequent exposures. Unlike other leukocytes, memory cells may live for many years. B cells undergo a maturation process in the bone marrow (B for bone marrow), whereas T cells undergo maturation in the thymus (T for thymus). This site of the maturation process gives rise to the name B and T cells. Smaller lymphocytes are either B or T cells; they cannot be differentiated in a normal blood smear.

Abnormally high lymphocyte counts are characteristic of viral infections as well as some types of cancer. Abnormally low lymphocyte counts are characteristic of prolonged (chronic) illness or immunosuppression, including that caused by HIV infection and drug therapies that often involve steroids.

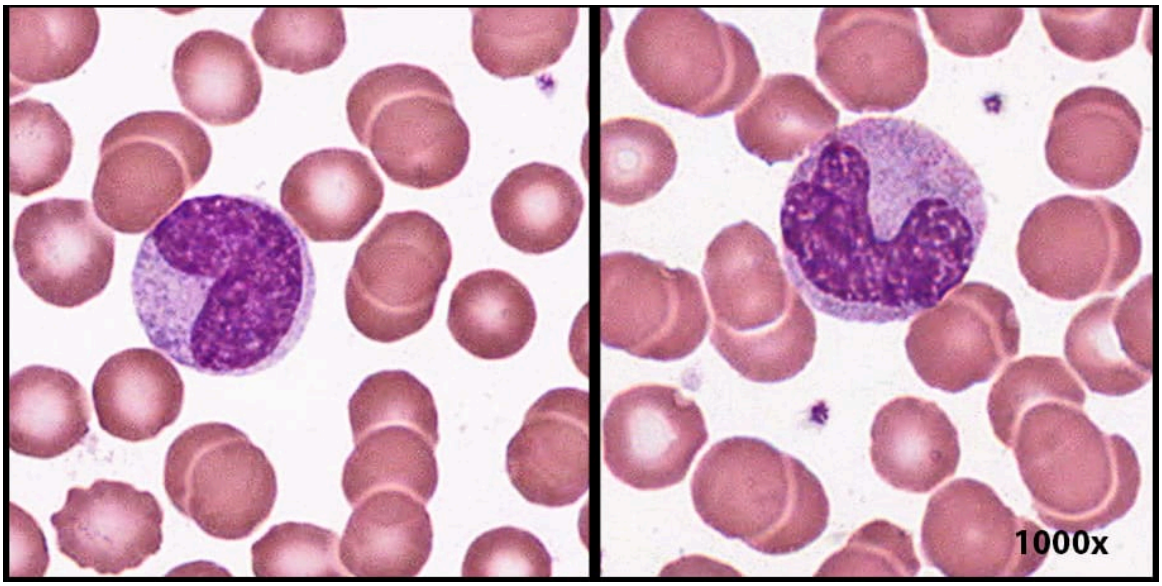

Figure 16.4.8: Monocytes. Monocytes are the largest leukocytes and typically have an indented nucleus ("C" or "U" shaped) with a volume of cytoplasm that is on par with the size of the nucleus. *(Image credit: "Monocyte" micrographs by Virginia Commonwealth University are licensed under CC BY-NC-SA 4.0.)*

Monocytes originate from myeloid stem cells and they normally represent 2–8 percent of the total leukocyte count. They are typically easily recognized by their large size of 12–20 μm and indented or horseshoe-shaped nuclei Figure 16.4.8. Macrophages are monocytes that have left the circulation and further differentiated; macrophages are larger than monocytes and feature many extensions of the plasma membrane spread evenly around their periphery to increase their surface area. Macrophages phagocytize debris, foreign pathogens, worn-out erythrocytes, and many other dead, worn out, or damaged cells. Macrophages also release antimicrobial defensins and chemotactic chemicals that attract other leukocytes to the site of an infection. Some macrophages reside permanently in specific locations of the body, whereas others wander primarily through the matrix of connective tissues patrolling for abnormal cells.

Abnormally high counts of monocytes are associated with viral or fungal infections, tuberculosis, some forms of leukemia, and other chronic diseases. Abnormally low counts are typically caused by suppression of the red bone marrow.

Lifecycle of Leukocytes

Most leukocytes have a relatively short lifespan, typically measured in hours or days. Production of all leukocytes begins in the bone marrow. Secondary production and maturation of lymphocytes occurs in specific regions of lymphatic tissue known as germinal centers. Lymphocytes are fully capable of mitosis and may produce clones of cells with identical properties. This capacity enables an individual to maintain immunity throughout life to many threats that have been encountered in the past.

DISORDERS OF THE....

Leukocytes

Leukopenia is a condition in which too few leukocytes are produced. If this condition is pronounced, the individual may be unable to ward off disease. Excessive leukocyte proliferation is known as **leukocytosis**. Although leukocyte counts are high, the cells themselves are often nonfunctional, leaving the individual at increased risk for disease.

Leukemia is a cancer involving an abundance of leukocytes. It may involve only one specific type of leukocyte from either the myeloid line (myelocytic leukemia) or the lymphoid line (lymphocytic leukemia). In chronic leukemia, mature leukocytes accumulate and fail to die. In acute leukemia, there is an overproduction of young, immature leukocytes. In both conditions the cells do not function properly.

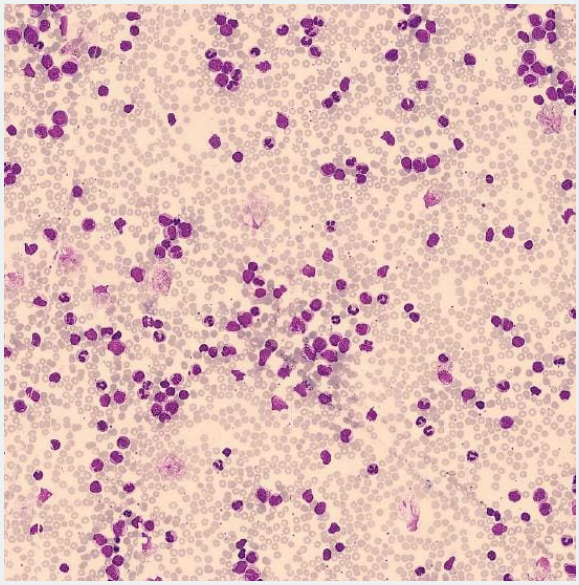

Figure 16.4.9: Chronic Myelogenous Leukemia. Notice the overabundance of white blood cells in this blood smear. *(Image credit: "CML Accelerated Phase" by El*Falal via Wikimedia Commons is licensed under CC BY-SA 4.0 International.)*

Lymphoma is a form of cancer in which masses of malignant T and/or B lymphocytes collect in lymph nodes, the spleen, the liver, and other tissues. As in leukemia, the malignant leukocytes do not function properly, and the patient is vulnerable to infection. Some forms of lymphoma tend to progress slowly and respond well to treatment. Others tend to progress quickly and require aggressive treatment, without which they are rapidly fatal.

Platelets

Platelets are essential for the formation of blood clots to prevent blood loss in the event of damage to a blood vessel wall.

Characteristics and Functions of Platelets

You may occasionally see platelets referred to as **thrombocytes**, but because this name suggests they are a type of cell, it is misleading. A platelet is not a cell but rather a fragment of the cytoplasm of a cell called a **megakaryocyte** that is surrounded by a plasma membrane. Megakaryocytes are descended from myeloid stem cells and are large, typically 50–100 μm in diameter, and contain an enlarged, lobed nucleus (Figure 16.4.10). These remain within red bone marrow tissue and ultimately form platelet-precursor extensions that extend through the walls of bone marrow capillaries to release into the circulation thousands of cytoplasmic fragments, each enclosed by a bit of plasma membrane. These enclosed fragments are platelets. Each megakaryocyte releases 2,000–3,000 platelets during its lifespan. Following platelet release, megakaryocyte remnants, which are little more than a cell nucleus, are consumed by macrophages.

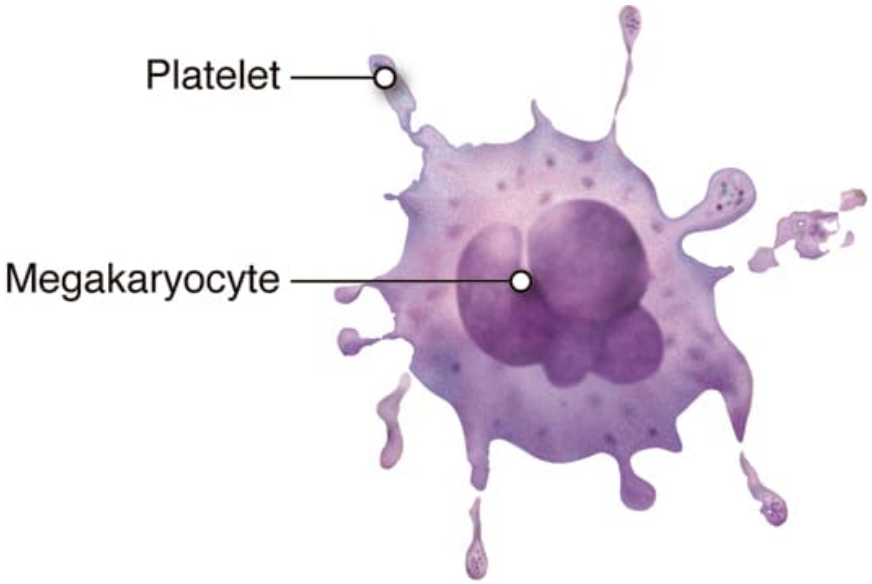

Figure 16.4.10: Megakaryocyte and Platelets. A platelet is a fragment of a cell. When activated, its plasma membrane gains surface area with many hairlike extensions and becomes sticky. *(Image credit: "Megakaryocyte and Platelets" by Cenveo is licensed under CC BY 3.0.)*

Platelets are relatively small, 2–4 μm in diameter, but numerous, with typically 150,000–160,000 per μL of blood. After entering the circulation, approximately one-third migrate to the spleen for storage for later release in response to any rupture in a blood vessel. They then become activated to perform their primary function, which is to limit blood loss. Activated platelets develop hair-like extensions to increase their surface area and become sticky. Platelets remain only about 10 days, then are phagocytized by macrophages.

Platelets are critical to **hemostasis**, the stoppage of blood flow following damage to a vessel. The process of hemostasis involves three steps: vascular spasm, platelet plug formation, and **coagulation** (formation of a blood clot). During vascular spasm, smooth muscle in the wall of the damaged vessel responds to signal chemicals and pain receptors detecting the damage by constricting to restrict blood flow through the damaged area (the body's own way of applying pressure to the bleeding wound). The **platelet plug** is a temporary attempt to seal the damaged vessel wall. It forms when activated platelets clump and attach to the damaged area of the vessel wall. As the platelets form this initial plug, they also release signaling chemicals to initiate a cascade of events that allows the more durable and long-lasting blood clot to form. A **blood clot** is comprised of a mesh of elongated, fibrous **fibrin** proteins (activated from the plasma protein fibrinogen by clotting factors) that trap sticky platelets and red blood cells (Figure 16.4.11). Platelets also secrete a variety of growth factors essential for growth and repair of tissue, particularly connective tissue. Infusions of concentrated platelets are now being used in some therapies to stimulate healing.

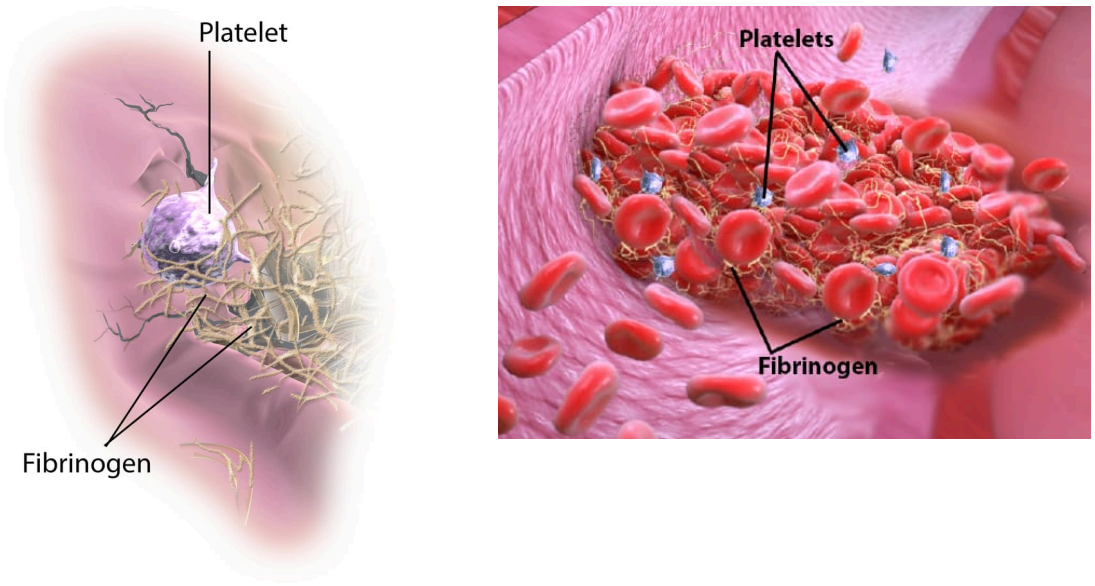

Figure 16.4.11: Blood Clot. A blood clot forms when a vessel wall is damaged. Inactive platelets and fibrinogen circulate in blood and both are activated if a vessel wall is damaged. Activated platelets grow in surface area and stick together, while fibrin becomes fibrous, creating a net-like mesh that sticks to the platelets and traps erythrocytes in the clot as well. *(Image Credits: "Blood Clot" by Jennifer Lange is licensed under CC BY-NC-SA 4.0, modification of originals by Scientific Animations and the National Science Foundation.)*

DISORDERS OF THE....

Platelets

Thrombocytosis is a condition in which there are too many platelets. This may trigger formation of unwanted blood clots (thrombosis), a potentially fatal disorder.

If there is an insufficient number of platelets, called **thrombocytopenia**, blood may not clot properly and excessive bleeding may result. **Hemophilia** is a group of genetic disorders also marked by excessive bleeding, but caused by inadequate production of one or more clotting factors, resulting in failure of the blood to properly clot.

Concept Review

Leukocytes function in body defenses. They squeeze out of the walls of blood vessels through emigration or diapedesis, then may move through tissue fluid or become attached to various organs where they fight against pathogenic organisms, diseased cells, or other threats to health. Granular leukocytes, which include neutrophils, eosinophils, and basophils, originate from myeloid stem cells, as do monocytes, one type of agranular leukocyte. The other agranular leukocytes, NK cells, B cells, and T cells, which are all types of lymphocytes, arise from the lymphoid stem cell line. The most abundant leukocytes are the neutrophils, which are first responders to infections, especially with bacteria. About 20–30 percent of all leukocytes are lymphocytes, which are critical to the body's defense against specific threats. Leukemia and lymphoma are malignancies involving leukocytes. Platelets are fragments of cells known as megakaryocytes that dwell within the bone marrow. While many platelets are stored in the spleen, others enter the circulation and are essential for hemostasis; they also produce several growth factors important for repair and healing.

Review Questions

Query 16.4.1

This interactive element is not available in this format. Visit the link or scan the QR code to access it online.

View this Interactive Content online

Critical Thinking Questions

Query 16.4.2

This interactive element is not available in this format. Visit the link or scan the QR code to access it online.

View this Interactive Content online

Query 16.4.3

This interactive element is not available in this format. Visit the link or scan the QR code to access it online.

View this Interactive Content online

Glossary

Query 16.4.4

This interactive element is not available in this format. Visit the link or scan the QR code to access it online.

View this Interactive Content online

Contributors and Attributions

- OpenStax Anatomy & Physiology (CC BY 4.0). Access for free at https://openstax.org/books/anatomy-and-physiology

This page titled 16.4: Leukocytes and Platelets is shared under a CC BY-NC-SA 4.0 license and was authored, remixed, and/or curated by Jennifer Lange et al..

- 16.4: Leukocytes and Platelets by Whitney Menefee, Julie Jenks, Chiara Mazzasette, and Kim-Leiloni Nguyen is licensed CC BY 4.0.

16.5: Production of the Formed Elements

By the end of this section, you will be able to:

- Trace the generation of the formed elements of blood from bone marrow stem cells
- Discuss the role of hemopoietic growth factors in promoting the production of the formed elements

The lifespan of the formed elements is very brief. Although one type of leukocyte called memory cells can survive for years, most erythrocytes, leukocytes, and platelets normally live only a few hours to a few weeks. Thus, the body must form new blood cells and platelets quickly and continuously. When you donate a unit of blood during a blood drive (approximately 475 mL, or about 1 pint), your body typically replaces the donated plasma within 24 hours, but it takes about 4 to 6 weeks to replace the blood cells. This restricts the frequency with which donors can contribute their blood. The process by which this replacement occurs is called **hemopoiesis**, or hematopoiesis (from the Greek root haima- = "blood"; -poiesis = "production").

Sites of Hemopoiesis

Prior to birth, hemopoiesis occurs in a number of tissues, beginning with the yolk sac of the developing embryo, and continuing in the fetal liver, spleen, lymphatic tissue, and eventually the red bone marrow. Following birth, most hemopoiesis occurs in the red marrow, a connective tissue within the spaces of spongy (cancellous) bone tissue. In children, hemopoiesis can occur in the medullary cavity of long bones; in adults, the process is largely restricted to the cranial and pelvic bones, the vertebrae, the sternum, and the proximal epiphyses of the femur and humerus.

Throughout adulthood, the liver and spleen maintain their ability to generate the formed elements. This process is referred to as extramedullary hemopoiesis (meaning hemopoiesis outside the medullary cavity of adult bones). When a disease such as bone cancer destroys the bone marrow, causing hemopoiesis to fail, extramedullary hemopoiesis may be initiated.

Differentiation of Formed Elements from Stem Cells

All formed elements arise from stem cells of the red bone marrow. Recall that stem cells undergo mitosis plus cytokinesis (cellular division) to give rise to new daughter cells; one of these remains a stem cell and the other differentiates into one of any number of diverse cell types. Stem cells may be viewed as occupying a hierarchal system, with some loss of the ability to diversify at each step. The **totipotent stem cell** is the zygote, or fertilized egg. The totipotent (toti- = "all") stem cell gives rise to all cells of the human body. The next level is the **pluripotent stem cell**, which gives rise to multiple types of cells of the body and some of the supporting fetal membranes. Beneath this level, the mesenchymal cell is a stem cell that develops only into types of connective tissue, including fibrous connective tissue, bone, cartilage, and blood, but not epithelium, muscle, and nervous tissue. One step more specific on the hierarchy of stem cells is the **hemopoietic stem cell**, or **hemocytoblast**. All of the formed elements of blood originate from this specific type of cell.

Hemopoiesis begins when the hemopoietic stem cell is exposed to appropriate chemical stimuli collectively called **hemopoietic growth factors**, which prompt it to undergo mitosis (cell division). One daughter cell remains a hemopoietic stem cell, allowing hemopoiesis to continue. The other daughter cell differentiates to become either of two types of more specialized stem cells (Figure 16.5.1):

- **Lymphoid stem cells** give rise to a class of leukocytes known as lymphocytes, which include the various T cells, B cells, and natural killer (NK) cells, all of which function in immunity. However, hemopoiesis of lymphocytes progresses somewhat differently from the process for the other formed elements. In brief, lymphoid stem cells quickly migrate from the bone marrow to lymphatic tissues, including the lymph nodes, spleen, and thymus, where their production and differentiation continues. B cells are so named since they mature in the bone marrow, while T cells mature in the thymus.
- **Myeloid stem cells** give rise to all the other formed elements, including the erythrocytes, megakaryocytes that produce platelets, and a myeloblast lineage that gives rise to monoblasts and three forms of granular leukocytes: neutrophils, eosinophils, and basophils. Monoblasts become agranular monocytes.

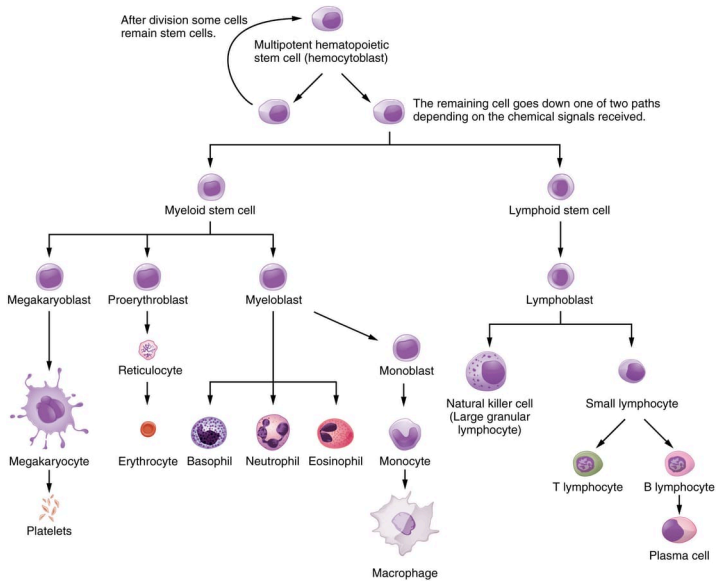

Figure 16.5.1: Hemopoietic System of Bone Marrow. Hemopoiesis, or hematopoiesis, is the proliferation and differentiation of the formed elements of blood. (Image credit: "Hematopoietic System of the Bone Marrow" by Julie Jenks is licensed under CC BY 4.0 / A derivative from the original work)

Lymphoid and myeloid stem cells do not immediately divide and differentiate into mature formed elements. As you can see in Figure 16.5.1, there are several intermediate stages of precursor cells (literally, forerunner cells), many of which can be recognized by their names, which have the suffix "-blast". For instance, megakaryoblasts are the precursors of megakaryocytes, and proerythroblasts become reticulocytes, which eject their nucleus and most other organelles before maturing into erythrocytes.

Lymphoid stem cells give rise to a lymphoblast lineage that gives rise to small lymphocytes and larger, granular natural killer cells (NK cells). Small lymphocytes give rise to T lymphocytes (T cells) and B lymphocytes (B cells).

Bone Marrow Sampling and Transplants

Sometimes, a healthcare provider will order a **bone marrow biopsy**, a diagnostic test of a sample of red bone marrow, or a **bone marrow transplant**, a treatment in which a donor's healthy bone marrow—and its stem cells—replaces the faulty bone marrow of a patient. These tests and procedures are often used to assist in the diagnosis and treatment of various severe forms of anemia, such as thalassemia and sickle cell anemia, as well as some types of cancer, specifically leukemia.

In the past, when a bone marrow sample or transplant was necessary, the procedure would have required inserting a large-bore needle into the region near the iliac crest of the pelvic bones (os coxae). This location was preferred, since its location close to the body surface makes it more accessible, and it is relatively isolated from most vital organs. Unfortunately, the procedure is quite painful.

Now, direct sampling of bone marrow can often be avoided. In many cases, stem cells can be isolated in just a few hours from a sample of a patient's blood. The isolated stem cells are then grown in culture using the appropriate hemopoietic growth factors, and analyzed or sometimes frozen for later use.

For an individual requiring a transplant, a matching donor is essential to prevent the immune system from destroying the donor cells—a phenomenon known as tissue rejection. To treat patients with bone marrow transplants, it is first necessary to destroy the patient's own diseased marrow through radiation and/or chemotherapy. Donor bone marrow stem cells are then intravenously infused. From the bloodstream, they establish themselves in the recipient's bone marrow.

Concept Review

Through the process of hemopoiesis, the formed elements of blood are continually produced, replacing the relatively short-lived erythrocytes, leukocytes, and platelets. Hemopoiesis begins in the red bone marrow, with hemopoietic stem cells that differentiate into myeloid and lymphoid lineages. Myeloid stem cells give rise to most of the formed elements. Lymphoid stem cells give rise

only to the various lymphocytes designated as B and T cells, and NK cells.

Review Questions

Query 16.5.1

This interactive element is not available in this format. Visit the link or scan the QR code to access it online.

View this Interactive Content online

Critical Thinking Questions

Query 16.5.2

This interactive element is not available in this format. Visit the link or scan the QR code to access it online.

View this Interactive Content online

Query 16.5.3

This interactive element is not available in this format. Visit the link or scan the QR code to access it online.

View this Interactive Content online

Glossary

Query 16.5.4

This interactive element is not available in this format. Visit the link or scan the QR code to access it online.

View this Interactive Content online

Contributors and Attributions

- OpenStax Anatomy & Physiology (CC BY 4.0). Access for free at https://openstax.org/books/anatomy-and-physiology

This page titled 16.5: Production of the Formed Elements is shared under a CC BY-NC-SA 4.0 license and was authored, remixed, and/or curated by Jennifer Lange et al..

- 16.5: Production of the Formed Elements by Whitney Menefee, Julie Jenks, Chiara Mazzasette, and Kim-Leiloni Nguyen is licensed CC BY 4.0.

16.6: Anatomical Atlas - Blood

A compendium of anatomical images: slides, models, and/or cadavers.

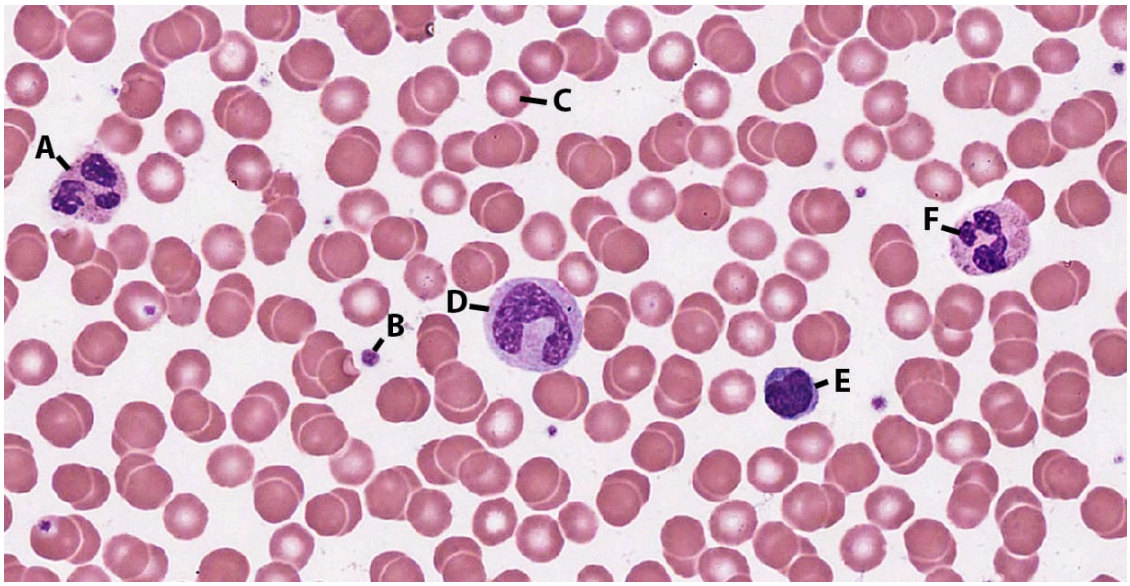

Image Credit

"Blood Smear 1" by Jennifer Lange; micrographs provided by Virginia Commonwealth University under CC BY-NC-SA 4.0.

Answer Key
show/hide a

A -

B -

C -
ery
blo

D -

E -

F -

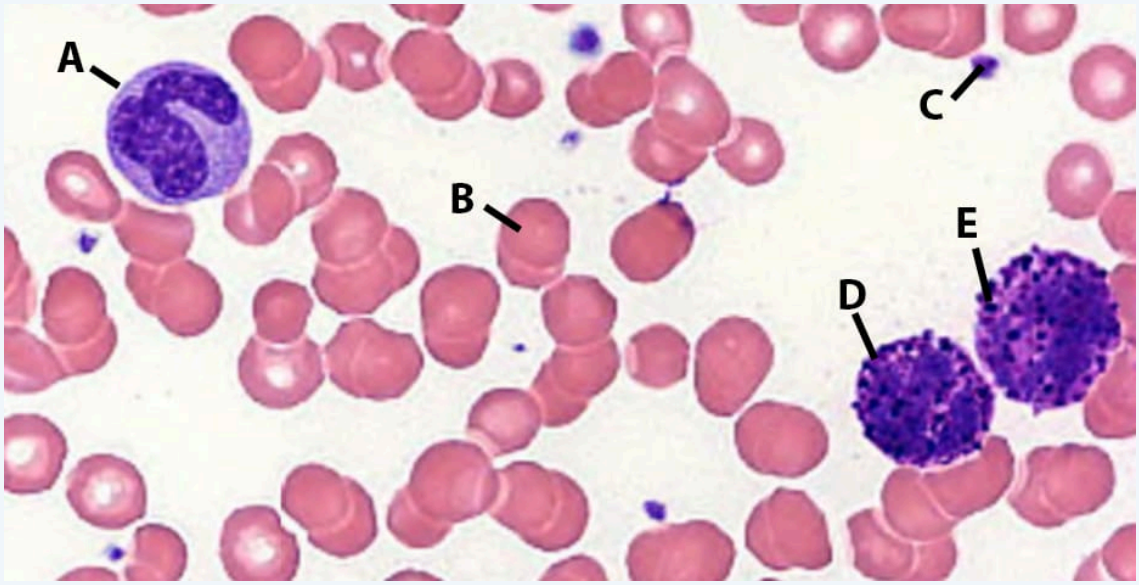

Image Credit

"Blood Smear 2" by Jennifer Lange is licensed under CC BY-NC-SA 4.0, slide provided by the Regents of the University of Michigan Medical School © 2022.)

Answer Key
show/hide a

A -

B -
(re

C -

D -

E -

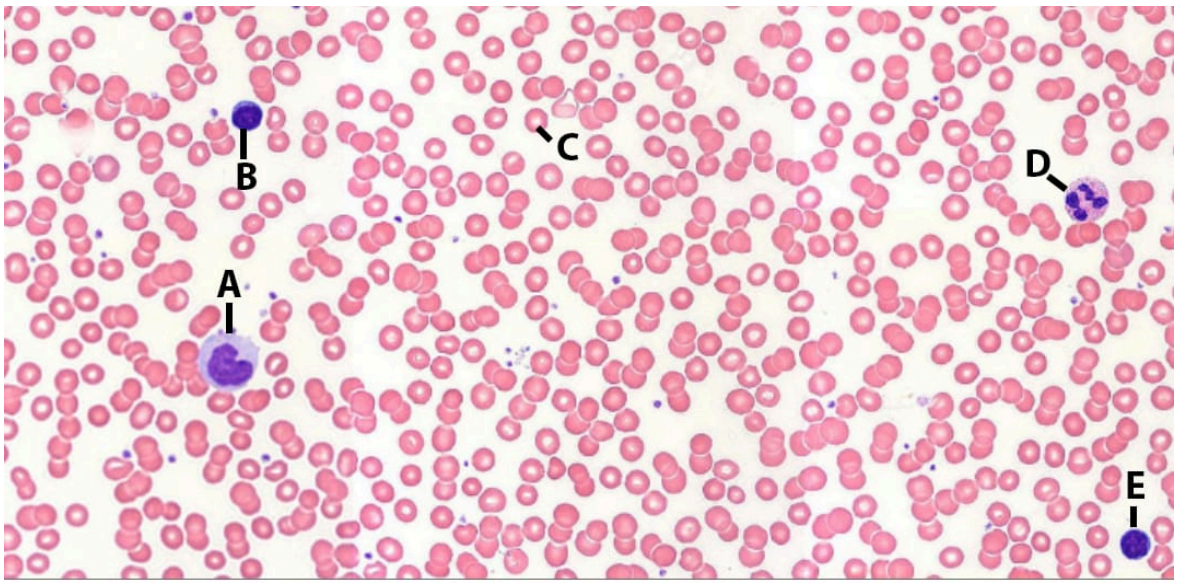

Image Credit

"Blood Smear 3" by Jennifer Lange is licensed under CC BY-NC-SA 4.0, slide provided by the Regents of the University of Michigan Medical School © 2022.)

Answer Key
show/hide a

A -

B -

C -
(re

D -

E -

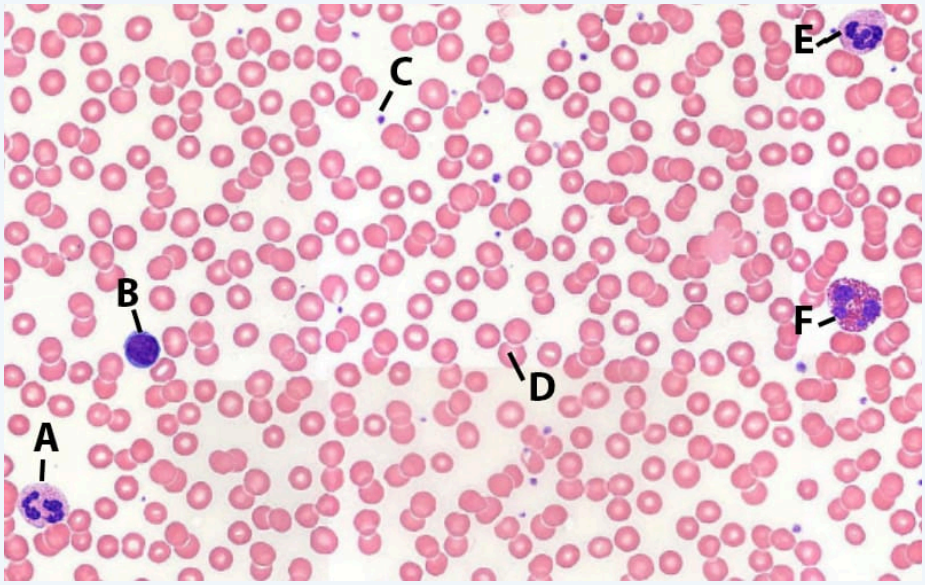

Image Credit

"Blood Smear 4" by Jennifer Lange is licensed under CC BY-NC-SA 4.0, slide provided by the Regents of the University of Michigan Medical School © 2022.)

Answer Key (click to show/hide answers)

A -

B -

C -

D - (red

E -

F -

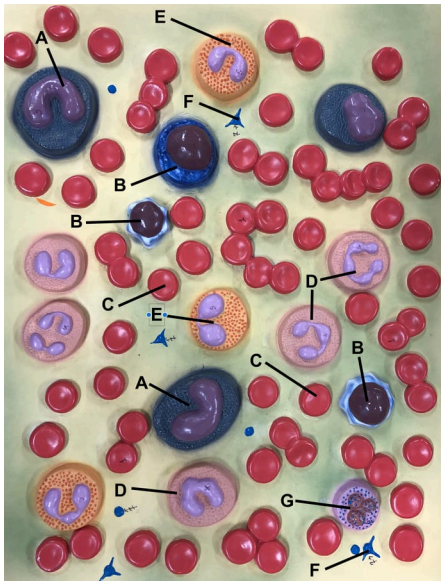

Image Credit

"Blood Cell Model" by Yancy Aquino under CC BY-NC-SA 4.0.

Answer Key (click to show/hide answers)

A - monocyte

B - lymphocyte

C - erythrocyte (red blood cell)

D - neutrophil

E - eosinophil

F - platelet

G - basophil

This page titled 16.6: Anatomical Atlas - Blood is shared under a CC BY-NC-SA 4.0 license and was authored, remixed, and/or curated by Jennifer Lange et al..

16.7: Practice Practical- Blood

Answer the following question by writing your answer in the space provided.

Query 16.7.1

This interactive element is not available in this format. Visit the link or scan the QR code to access it online.

View this Interactive Content online

Query 16.7.1

This interactive element is not available in this format. Visit the link or scan the QR code to access it online.

View this Interactive Content online

Query 16.7.1

This interactive element is not available in this format. Visit the link or scan the QR code to access it online.

View this Interactive Content online

Query 16.7.1

This interactive element is not available in this format. Visit the link or scan the QR code to access it online.

View this Interactive Content online

Query 16.7.1

This interactive element is not available in this format. Visit the link or scan the QR code to access it online.

View this Interactive Content online

Query 16.7.1

This interactive element is not available in this format. Visit the link or scan the QR code to access it online.

View this Interactive Content online

Query 16.7.1

This interactive element is not available in this format. Visit the link or scan the QR code to access it online.

View this Interactive Content online

Query 16.7.1

This interactive element is not available in this format. Visit the link or scan the QR code to access it online.

View this Interactive Content online

This page titled 16.7: Practice Practical- Blood is shared under a CC BY-NC-SA 4.0 license and was authored, remixed, and/or curated by Jennifer Lange et al..

17: CARDIOVASCULAR SYSTEM - HEART

17.1: Introduction to the Heart
17.2: Heart Anatomy
17.3: Cardiac Muscle and Electrical Activity
17.4: Coronary Circulation
17.5: Development of the Heart
17.6: Anatomical Atlas - Heart
17.7: Practice Practical- Heart

This page titled 17: Cardiovascular System - Heart is shared under a CC BY-NC-SA 4.0 license and was authored, remixed, and/or curated by Jennifer Lange et al..

17.1: Introduction to the Heart

Chapter Learning Objectives

After studying this chapter, you will be able to:

- Describe the size, shape, and location of the heart
- Identify and describe the interior and exterior parts of the human heart
- Describe the path of blood through the cardiac circuits
- Compare atrial and ventricular systole and diastole
- Explain the cardiac conducting system
- Describe the process and purpose of an electrocardiogram
- Describe fetal heart development

In this chapter, you will explore the remarkable pump that propels the blood into the vessels. The heart functions as a “double pump,” since its contraction develops the pressure that ejects blood into the major vessels for two separate circuits of blood flow: blood from the left side of the heart flows into the aorta for the systemic circuit and blood from the right side of the heart flows into the pulmonary trunk for the pulmonary circuit. From these vessels, blood is distributed to the remainder of the body. Although the connotation of the term “pump” suggests a mechanical device made of steel and plastic, the anatomical structure is a living, sophisticated muscle. As you read this chapter, try to keep these twin concepts in mind: pump and muscle.

Although the term “heart” is an English word, cardiac (heart-related) terminology can be traced back to the Latin term, “kardia.” Cardiology is the study of the heart, and cardiologists are the physicians who deal primarily with the heart.

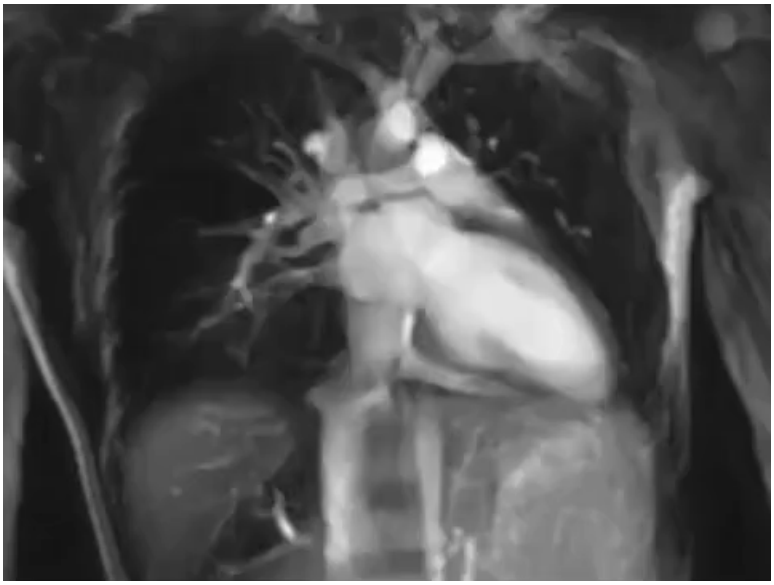

Figure 17.1.1: Human Heart. The real-time heartbeat of an adolescent human female visualized with Magnetic Resonance Imaging. (Image credit: "Heart MRI" by Alith3204 is licensed under CC BY-SA 4.0<https://creativecommons.org/licenses/by-sa/4.0>, via Wikimedia Commons)

Contributors and Attributions

- OpenStax Anatomy & Physiology (CC BY 4.0). Access for free at https://openstax.org/books/anatomy-and-physiology

This page titled 17.1: Introduction to the Heart is shared under a CC BY-NC-SA 4.0 license and was authored, remixed, and/or curated by Jennifer Lange et al..

- 17.1: Introduction to the Heart by Whitney Menefee, Julie Jenks, Chiara Mazzasette, and Kim-Leiloni Nguyen is licensed CC BY 4.0.

17.2: Heart Anatomy

By the end of this section, you will be able to:

- Describe the location and position of the heart within the body cavity
- Describe the internal and external anatomy of the heart
- Identify the tissue layers of the heart and pericardium
- Compare systemic circulation to pulmonary circulation
- Trace the pathway of oxygenated and deoxygenated blood through the chambers of the heart

The vital importance of the heart is obvious. If one assumes an average rate of contraction of 75 contractions per minute, a human heart would contract approximately 108,000 times in one day, more than 39 million times in one year, and nearly 3 billion times during a 75-year lifespan. Each of the major pumping chambers of the heart ejects approximately 70 mL of blood per contraction in a resting adult. This would be equal to 5.25 liters of fluid per minute and approximately 14,000 liters per day. Over one year, that would equal 10,000,000 liters or 2.6 million gallons of blood sent through roughly 60,000 miles of vessels.

Location and Position of the Heart

The human heart is located within the thoracic cavity, medially between the lungs in the region known as the mediastinum. The mediastinum also includes the portions of the major blood vessels, the trachea, and the esophagus that are positioned between the lungs medially. Figure 17.2.1 shows the position of the heart within the thoracic cavity. Within the mediastinum, the heart is separated from the other mediastinal structures and is held in place by a tough wrapping known as the pericardium, or pericardial sac. The sac also limits the range of motion of the heart as it beats. The double layered pericardial sac creates a thin space surrounding the heart called the **pericardial cavity** that is filled with serous fluid to prevent friction as the heart beats.

The dorsal surface of the heart lies near the bodies of the vertebrae and its anterior surface sits deep to the sternum and costal cartilages. The great veins, the superior and inferior venae cavae, and the great arteries, the aorta and pulmonary trunk, are attached to the superior surface of the heart, called the base. The base of the heart is located at the level of the third costal cartilage, as seen in Figure 17.2.1. The inferior tip of the heart, the apex, lies just to the left of the sternum between the junction of the fourth and fifth ribs near their articulation with the costal cartilages. The heart is also rotated slightly around its vertical axis such that the more of the right side of the heart is visible in an anterior view while more of the left side is visible in a posterior view. It is important to remember the position and orientation of the heart when placing a stethoscope on the chest of a patient and listening for heart sounds, and also when looking at images taken from a midsagittal perspective. The slight deviation of the apex to the left is reflected in a depression in the medial surface of the inferior lobe of the left lung, called the **cardiac notch**.

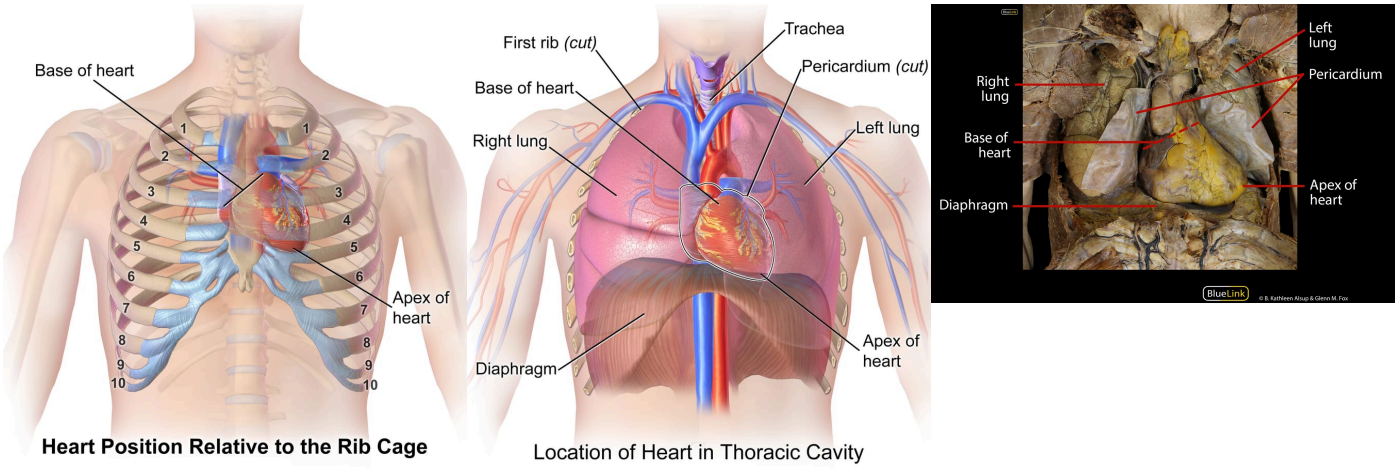

Figure 17.2.1: Location of Heart in the Thorax. The heart is located within the thoracic cavity, medially between the lungs in the mediastinum. It is about the size of a fist, is broad at the top, and tapers toward the base. (Caption from OpenStax) *(Image credits: "Blausen 0467 - Heart position relative to the rib cage - English labels" by Blausen.com staff (2014), license: CC BY. Source: "Medical gallery of Blausen Medical 2014" https://en.wikiversity.org/wiki/Wiki...n_Medical_2014 "Blausen 0458 - Heart position in the thoracic cavity - English labels" by Blausen.com staff (2014), license: CC BY. Source: "Medical gallery of Blausen Medical 2014" https://en.wikiversity.org/wiki/Wiki...n_Medical_2014. "Cadaver Heart" by BlueLink is licensed under CC BY-NC 4.0 with notification of the original authors.)*

EVERYDAY CONNECTION

CPR

The position of the heart in the torso between the vertebrae and sternum (see Figure 17.2.2 for the position of the heart within the thorax) allows for individuals to apply an emergency technique known as cardiopulmonary resuscitation (CPR) if the heart of a patient should stop. If one hand is placed over the other in the middle of the chest about two finger-widths superior to the xiphoid process (Figure 17.2.2), it is possible to manually compress the blood within the heart enough to push some of the blood within it into the pulmonary and systemic circuits. This is particularly critical for the brain, as irreversible damage and death of neurons occur within minutes of loss of blood flow. Current standards call for compression of the chest at least 5 cm deep and at a rate of 100 compressions per minute, a rate equal to the beat in “Staying Alive,” recorded in 1977 by the Bee Gees. If you are unfamiliar with this song, a version is available on www.youtube.com. At this stage, the emphasis is on performing high-quality chest compressions, rather than providing artificial respiration. CPR is generally performed until the patient regains spontaneous contraction or is declared dead by an experienced healthcare professional.

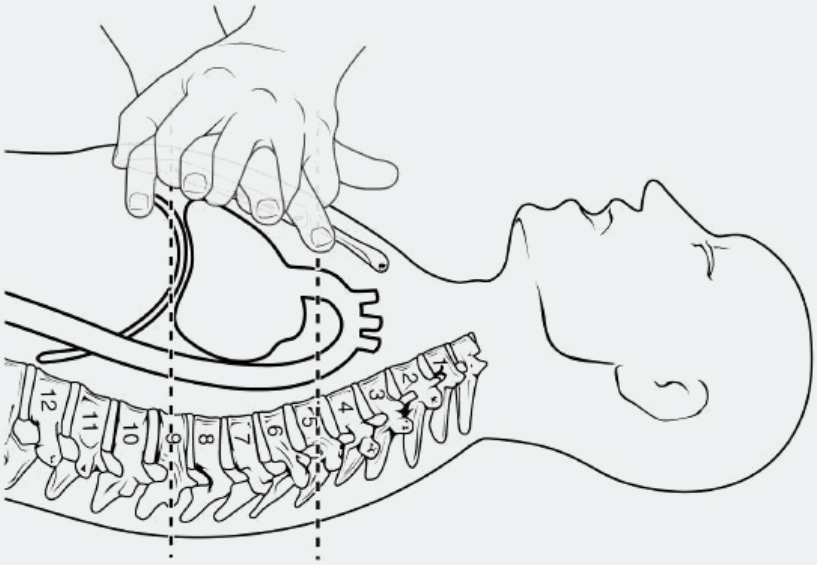

Figure 17.2.2: CPR Technique. If the heart should stop, CPR can maintain the flow of blood until the heart resumes beating. By applying pressure to the sternum, the blood within the heart will be squeezed out of the heart and into the circulation. Proper positioning of the hands on the sternum to perform CPR would be between the lines at T4 and T9, or directly superior to two finger-widths above the xiphoid process. (Image credit: "CPR Technique" by OpenStax College is licensed under CC BY 3.0)

When performed by untrained or overzealous individuals, CPR can result in broken ribs or a broken sternum, and can inflict additional severe damage on the patient. It is also possible, if the hands are placed too low on the sternum, to manually drive the xiphoid process into the liver, a consequence that may prove fatal for the patient. Proper training is essential. This proven life-sustaining technique is so valuable that virtually all medical personnel as well as concerned members of the public should be certified and routinely re-certified in its application. CPR courses are offered at a variety of locations, including colleges, hospitals, the American Red Cross, and some commercial companies. They normally include practice of the compression technique on a mannequin.

The shape of the heart is similar to a pinecone, rather broad at the superior surface (the **base,** on the posterior side) and tapering to the **apex** (Figure 17.2.1). The apex of the heart is inferior and to the left while the base of the heart is superior and posterior.

A typical heart is approximately the size of your fist: 12 cm (5 in) in length, 8 cm (3.5 in) wide, and 6 cm (2.5 in) in thickness. Heart size is dependent on body size, the typical range is 250 to 350 grams (about 1/2 to 3/4 of a pound). The heart of a well-trained athlete, especially one specializing in aerobic sports, can be considerably larger than this. Cardiac muscle responds to exercise in a manner similar to that of skeletal muscle. That is, exercise results in the addition of protein myofilaments that increase the size of the individual cells without increasing their numbers, a concept called hypertrophy. Hearts of athletes can pump blood more effectively at lower rates than those of non-athletes. Enlarged hearts are not always a result of exercise; they can result from pathologies, such as **hypertrophic cardiomyopathy**. The cause of an abnormally enlarged heart muscle is unknown, but hearts with this condition often have mutation(s) in one of the proteins of the sarcomere, such as myosin or troponin (Popa-Fotea *et al*, 2019). The condition can be inherited, is often undiagnosed and can cause sudden death in apparently otherwise healthy young people.

Pulmonary and Systemic Circuits

There are two distinct but linked circuits in the human blood circulation called the pulmonary and systemic circuits. Although both circuits transport blood and everything it carries, we can initially view the circuits from the point of view of gases. The **pulmonary circuit** transports blood to and from the lungs, where it picks up oxygen and delivers carbon dioxide for exhalation. The **systemic circuit** transports **oxygenated blood** to virtually all of the tissues of the body and returns relatively deoxygenated blood and carbon dioxide to the heart to be sent back to the pulmonary circulation.

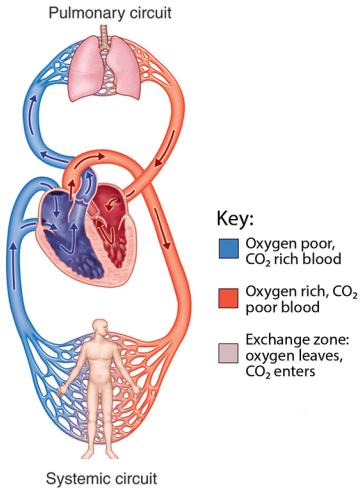

Figure 17.2.3: Cardiovascular System Circuits. The pulmonary circuit moves blood from the right side of the heart to the lungs and back to the heart. The systemic circuit moves blood from the left side of the heart to the head and body and returns it to the right side of the heart to repeat the cycle. The arrows indicate the direction of blood flow, and the colors show the relative levels of oxygen concentration. (Caption from OpenStax) *(Image Credit: "Systemic and Pulmonary Circuits" by Jennifer Lange is licensed under CC BY-NC-SA 4.0, modification of original by Open Learning Initiative.)*

Pericardium and the Heart Wall

The heart is contained within the pericardium. This serous membrane attaches to the large blood vessels superior to the heart and to the diaphragm and helps to anchor the heart in place within the thoracic cavity. The wall of the heart is composed of three layers of unequal thickness. From superficial to deep, these are the epicardium, the myocardium, and the endocardium (see Figure 17.2.4). The outermost layer of the wall of the heart is also the innermost layer of the pericardium, the epicardium, or the visceral pericardium discussed earlier.

The multi-layered membrane that directly surrounds the heart and defines the pericardial cavity is called the **pericardium** or **pericardial sac**. It also surrounds the “roots” of the major vessels, or the areas of closest proximity to the heart. The pericardium, which literally translates as “around the heart,” consists of two distinct sublayers: the sturdy outer **fibrous pericardium** and the inner **serous pericardium**. The fibrous pericardium is made of tough, dense irregular connective tissue that protects the heart and maintains its position in the thorax while also limiting the heart's motion during the heartbeat. The more delicate serous pericardium consists of two layers: the **parietal pericardium**, which is fused to the fibrous pericardium, and an inner **visceral pericardium**, or **epicardium**, which is fused to the heart and is part of the heart wall. The pericardial cavity, filled with lubricating serous fluid, lies between the epicardium and the parietal pericardium. The serous layers of the pericardium consist of a simple squamous epithelium anchored by a layer of areolar connective tissue. The areolar connective tissue connects the parietal pericardium to the fibrous pericardium and it connects the epicardium to the myocardium. The epithelial tissue secretes the lubricating serous fluid that fills the pericardial cavity and reduces friction as the heart contracts. Adipose connective tissue can also be found in the epicardium, particularly in the areas where blood vessels run along the heart's surface. Figure 17.2.4 illustrates the pericardial membrane and the layers of the heart.

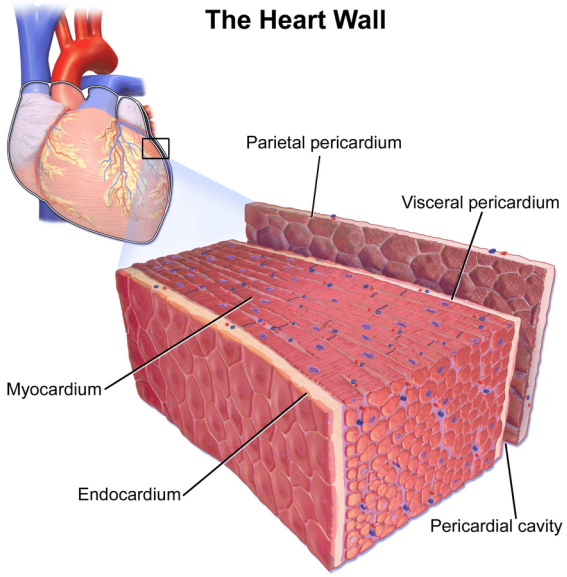

Figure 17.2.4:Pericardial Membranes and Layers of the Heart Wall. The pericardial membrane that surrounds the heart consists of three layers and the pericardial cavity. The heart wall also consists of three layers. The pericardial membrane and the heart wall share the epicardium. (Caption from OpenStax) *(Image credit: "Heart Wall" by Jennifer Lange is licensed under CC BY-NC-SA 4.0, modification of original by Blausen.com staff (2014).)*

The middle and thickest layer is the **myocardium.** Composed primarily of cardiac muscle, with small amounts of endomysium, the contractile force of the myocardium propels blood forward through the pulmonary and systemic circuits. As with skeletal muscle, the amount of force generated increases with increasing numbers of myofibers.

The myocardium is built upon a framework of dense connective tissue called the cardiac skeleton (covered in detail later in this section). It is the contraction of the myocardium that pumps blood through the heart and into the major arteries. The muscle pattern is elegant and complex, as the muscle cells swirl and spiral to form the chambers of the heart. To create this complex 3D structure, cardiac muscle cells approximately follow a figure 8 pattern around the atria and around the roots of the great vessels. Deeper ventricular muscles also form a figure 8 around the two ventricles and proceed toward the apex. More superficial layers of ventricular muscle wrap around both ventricles. This complex swirling pattern allows the heart to pump blood more effectively by decreasing the size of each interior chamber during contraction. Figure 17.2.5 illustrates the arrangement of muscle cells.

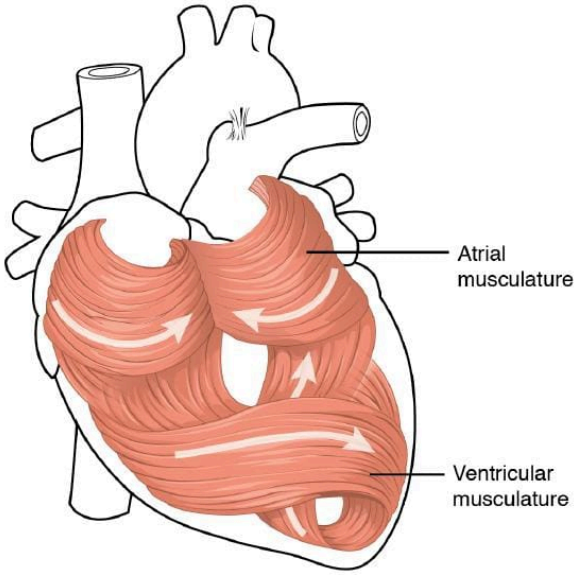

Figure 17.2.5: Cardiac Musculature. The swirling pattern of cardiac muscle tissue contributes significantly to the heart's ability to pump blood effectively. *(Image credit: "Heart Musculature" by OpenStax is licensed under CC BY 3.0.)*

Although the ventricles on the right and left sides pump the same amount of blood per contraction, the muscle of the left ventricle

is much thicker and better developed than that of the right ventricle. In order to overcome the high resistance required to pump blood into the long systemic circuit, the left ventricle must generate a great amount of pressure. The right ventricle does not need to generate as much pressure, since the pulmonary circuit is shorter and provides less resistance. Figure 17.2.6 illustrates the differences in muscular thickness needed for each of the ventricles.

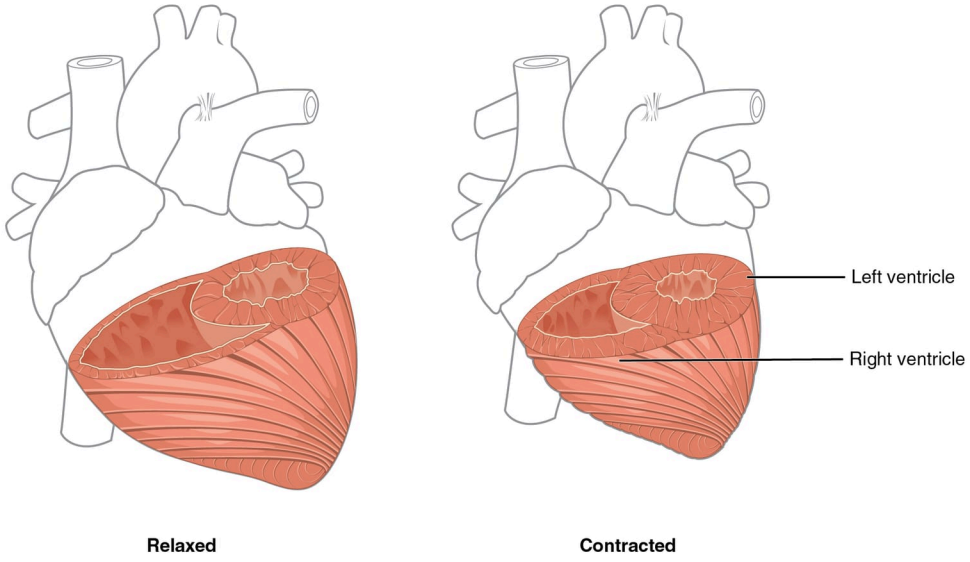

Figure 17.2.6: Differences in Ventricular Muscle Thickness. The myocardium in the left ventricle is significantly thicker than that of the right ventricle. In both relaxed and contracting states, also note the differences in the relative size of the lumens, the region inside each ventricle where the blood is contained. *(Image credit: "Ventricular Muscle Thickness" by OpenStax is licensed under CC BY 3.0.)*

The innermost layer of the heart wall, the **endocardium**, is joined to the myocardium with a thin layer of areolar connective tissue. The endocardium lines the chambers where the blood circulates and covers the heart valves. It is made of simple squamous epithelium called **endothelium**, which is continuous with the endothelial lining of the blood vessels (Figure 17.2.4).

DISORDERS OF THE...

Heart: Cardiac Tamponade

If excess fluid builds within the pericardial space, it can lead to a condition called cardiac tamponade, or pericardial tamponade. With each contraction of the heart, more fluid—in most instances, blood—accumulates within the pericardial cavity. In order to fill with blood for the next contraction, the heart must relax. However, the excess fluid in the pericardial cavity puts pressure on the heart and prevents full relaxation, so the chambers within the heart contain slightly less blood as they begin each heart cycle. Over time, less and less blood is ejected from the heart. If the fluid builds up slowly, as in hypothyroidism, the pericardial cavity may be able to expand gradually to accommodate this extra volume. Some cases of fluid in excess of one liter within the pericardial cavity have been reported. Rapid accumulation of as little as 100 mL of fluid following trauma may trigger cardiac tamponade. Other common causes include myocardial rupture, pericarditis, cancer, or even cardiac surgery. Removal of this excess fluid requires insertion of drainage tubes into the pericardial cavity. Premature removal of these drainage tubes, for example, following cardiac surgery, or clot formation within these tubes are causes of this condition. Untreated, cardiac tamponade can lead to death.

Surface Features of the Heart

The heart is composed of four hollow chambers: two atria and two ventricles. The thin walled **right and left atria** are the two superior chambers. While both atria are visible from the anterior, the majority of the left atrium is seen on the posterior aspect ((Figure 17.2.7). Each atrium has a superficial flap-like extension called an **auricle** because its shape resembles the external ear of a human (Figure 17.2.8). You may also hear them referred to as atrial appendages. The auricles can increase the atrial capacity at times of exertion by filling with blood and, thus, relieving high atrial pressure. The two ventricles are inferior to the atria and they form the largest portion of the heart. Their walls are significantly thicker than those of the atria as a large amount of muscle

mass is needed to push the blood into the arteries. The **right ventricle** makes up the right side and much of the anterior portion of the heart, while the **left ventricle** makes up the left side and much of the posterior portion of the heart (Figure 17.2.6).

Also prominent along the superficial surfaces of the heart is a series of fat-filled grooves, each of which is known as a **sulcus** (plural = sulci), containing major coronary blood vessels. The deepest is the **coronary sulcus,** which encircles the heart between the atria and ventricles. Located between the left and right ventricles are two shallower sulci: the **anterior interventricular sulcus** is visible on the anterior surface of the heart (Figure 17.2.8.A), whereas the **posterior interventricular sulcus** is visible on the posterior surface of the heart (Figure 17.2.8.B).

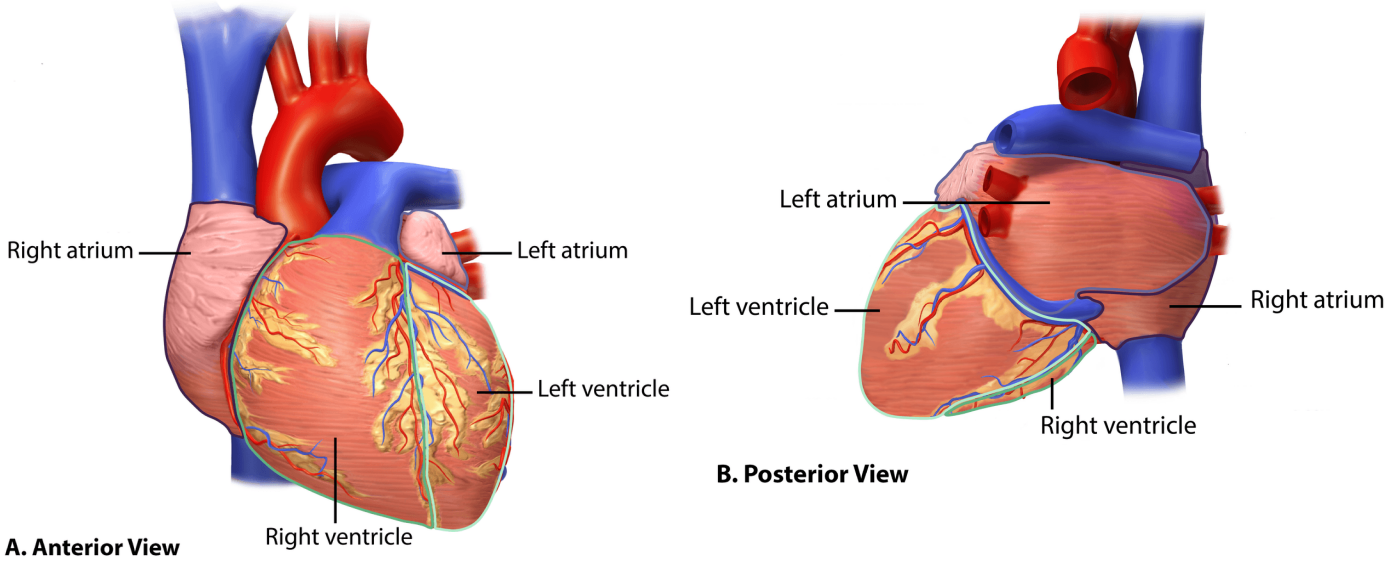

Figure 17.2.7: Superficial Heart Anatomy. Inside the pericardium, the surface features of the heart are visible. (Caption from OpenStax) *(Image credits: "Heart Chambers Anterior View" by Jennifer Lange is licensed under CC BY-NC-SA 4.0, modification of original "Blausen 0451 - Anterior view of the heart - English labels" by Blausen Medical Communications, Inc.; "Heart Chambers Posterior View" by Jennifer Lange is licensed under under CC BY-NC-SA 4.0, modification of original "Blausen 0456 Heart Posterior" by Blausen Medical Communications, Inc.)*

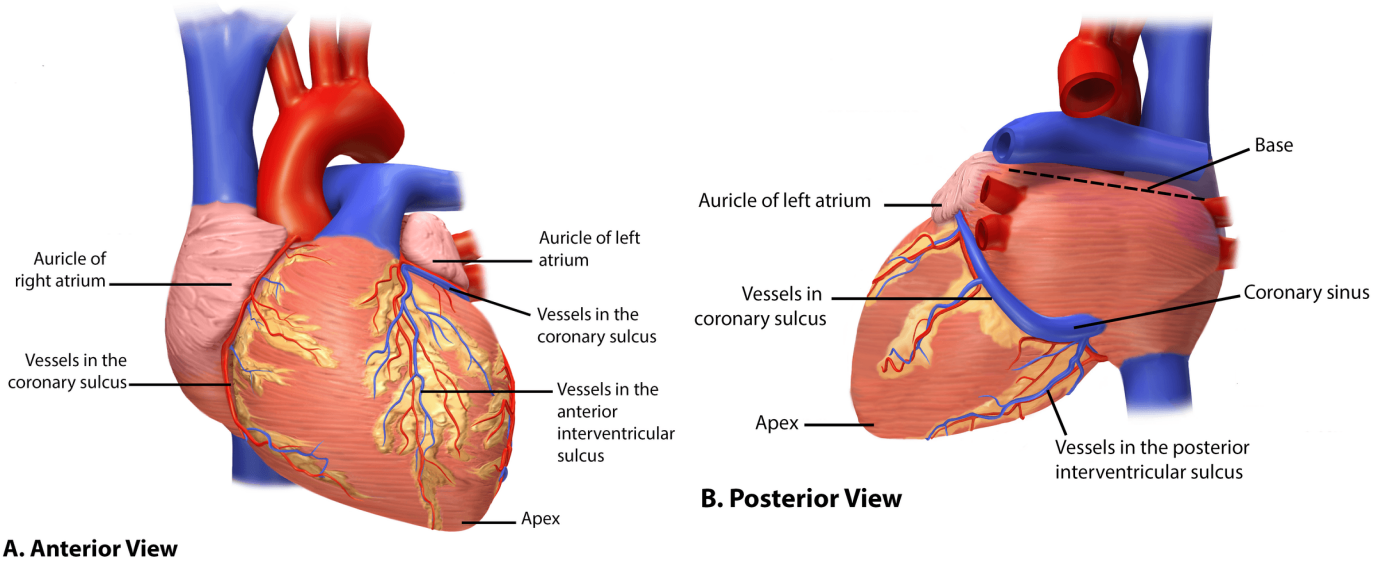

Figure 17.2.8: Superficial Heart Anatomy. Inside the pericardium, the surface features of the heart are visible. (Caption from OpenStax) *(Image credits: "Superficial Heart Anatomy Anterior View" by Jennifer Lange is licensed under CC BY-NC-SA 4.0, modification of original "Blausen 0451 - Anterior view of the heart - English labels" by Blausen Medical Communications, Inc.; "Superficial Heart Anatomy - Posterior View" by Jennifer Lange is licensed under under CC BY-NC-SA 4.0, modification of original "Blausen 0456 Heart Posterior" by Blausen Medical Communications, Inc.)*

The Great Vessels

Blood enters and exits the heart through the largest arteries and veins, respectively, in the body. Termed the great vessels, these are the large arteries and veins directly connected with the heart, the: inferior vena cava, superior vena cava, pulmonary arteries, pulmonary veins, and the aorta (Figure 17.2.9).

The **pulmonary trunk** arises from the right ventricle and then splits into the **right** and **left pulmonary arteries**, each of which carries blood to the lung on their respective side. After circulating through the smaller blood vessels of the lungs the blood, which will have a relatively high oxygenation level and a relatively low carbon dioxide level, returns to the heart in the **right** and **left pulmonary veins** and enters the left atrium and then the left ventricle. The left side of the heart gives rise to the largest and thickest artery in the body, the **aorta**. The aorta directs blood along multiple systemic circuit routes to reach all of the body's organs. The systemic circuit returns blood to the right atrium through two of the great vessels. The **inferior vena cava** carries blood from regions inferior to the heart while the **superior vena cava** collects blood from the regions superior to the heart. The structure of these vessels will be discussed in Chapter 18.

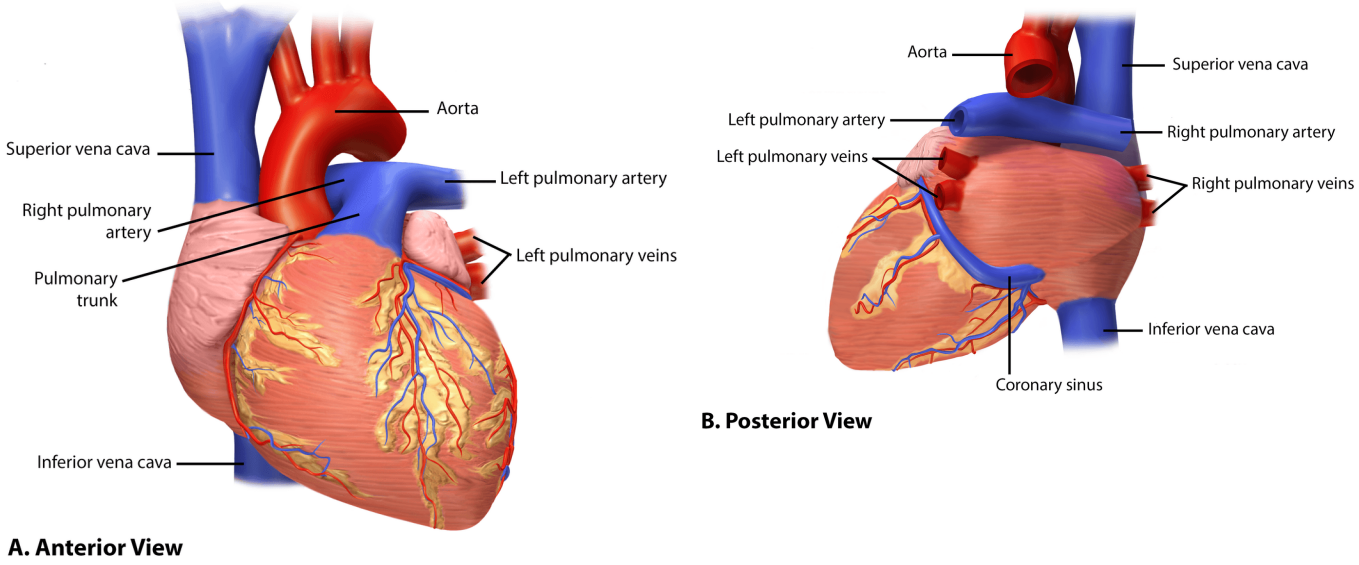

Figure 17.2.9: Great Vessels of the Heart. The base of the heart shows the location of the great vessels. Insert image caption. *(Image credits: "Great Vessels of the Heart, Anterior View" by Jennifer Lange is licensed under CC BY-NC-SA 4.0, modification of original "Blausen 0451 - Anterior view of the heart - English labels" by Blausen Medical Communications, Inc.; "Great Vessels of the Heart, Posterior View" by Jennifer Lange is licensed under under CC BY-NC-SA 4.0, modification of original "Blausen 0456 Heart Posterior" by Blausen Medical Communications, Inc.)*

Interactive Element

Explore a model of the heart in 3D:

This interactive element is not available in this format. Visit the link or scan the QR code to access it online.

View this Interactive Content online

Internal Structures of the Heart

Figure 17.2.10 shows the internal anatomy of the heart and the relative positions and features of the four chambers. Muscular septa form the walls between adjacent chambers. The word septum is derived from the Latin for “something that encloses;” in

this case, a **septum** (plural = septa) refers to a wall or partition that divides the heart into chambers. The septa are physical extensions of the myocardium lined with endocardium. Located between the two atria is the **interatrial septum**. Normally in an adult heart, the interatrial septum bears an oval-shaped depression known as the **fossa ovalis**, a remnant of an opening in the fetal heart known as the **foramen ovale**. The foramen ovale allowed blood in the fetal heart to pass directly from the right atrium to the left atrium, allowing some blood to bypass the pulmonary circuit. Within seconds after birth, a flap of tissue that previously acted as a valve closes the foramen ovale and establishes the typical cardiac circulation pattern. Between the two ventricles is a second septum known as the **interventricular septum**. Unlike the interatrial septum, the interventricular septum is normally intact after its formation during fetal development. It is substantially thicker than the interatrial septum, since the ventricles generate far greater pressure when they contract.

The septum between the atria and ventricles is known as the **atrioventricular septum**. It is marked by the presence of four openings that allow blood to move from the atria into the ventricles and from the ventricles into the pulmonary trunk and aorta. Located in each of these openings between the atria and ventricles is a **valve**, a specialized structure that ensures one-way flow of blood. The valves between the atria and ventricles are known generically as **atrioventricular valves**. Each flap of an atrioventricular valve is attached to strong strands of connective tissue, the **chordae tendineae**, literally "tendinous cords," or sometimes more poetically referred to as "heart strings" (Figure 17.2.11). There are several chordae tendineae associated with each of the valve flaps that are composed of approximately 80 percent collagenous fibers with the remainder consisting of elastic fibers and endothelium. They connect each of the flaps to a **papillary muscle**. The valves at the openings that lead to the pulmonary trunk and aorta are known generically as **semilunar valves**. The semilunar valves are both comprised of three small flaps of endothelium reinforced with dense connective tissue.

Right Atrium

The **right atrium** serves as the receiving chamber for blood returning to the heart from the systemic circulation. The two major systemic veins, the superior and inferior venae cavae, and the large coronary vein called the **coronary sinus** empty into the right atrium. The superior vena cava drains blood from regions superior to the diaphragm: the head, neck, upper limbs, and the thoracic region. It empties into the superior and posterior portions of the right atrium. The inferior vena cava drains blood from areas inferior to the diaphragm: the lower limbs and abdominopelvic region of the body. It, too, empties into the posterior portion of the atria, but inferior to the opening of the superior vena cava. Immediately superior and slightly medial to the opening of the inferior vena cava on the posterior surface of the atrium is the opening of the coronary sinus. This thin-walled vessel drains most of the coronary veins that return systemic blood from the heart into the right atrium. The majority of the internal heart structures discussed in this and subsequent sections are illustrated in Figure 17.2.10.

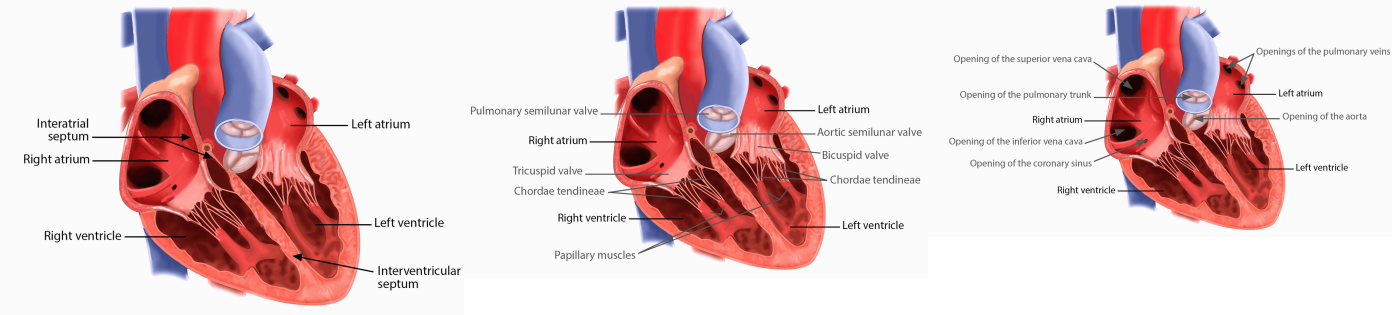

Figure 17.2.10: Interior Structures of the Heart. This anterior view of the heart shows the four chambers, the major vessels and their early branches, as well as the valves. The presence of the pulmonary trunk and aorta covers the interatrial septum, and the atrioventricular septum is cut away to show the atrioventricular valves. (Caption from OpenStax) *(Image credits: "Interior Structures of the Heart - illustration with multiple label sets" by Jennifer Lange is licensed under CC BY-NC-SA 4.0, modification of original "Slagter - Drawing Anatomy of the heart and large vessels - no labels" by Ron Slagter, license: CC BY-NC-SA.)*

While the bulk of the internal surface of the right atrium is smooth, the depression of the fossa ovalis is medial, and the anterior surface demonstrates prominent ridges of muscle called the **pectinate muscles** (see Figure 17.2.11), which are thought to help spread the electrical signals to contract and strengthen the contraction of the atria. The right auricle also has pectinate muscles. The left atrium does not have pectinate muscles except in the auricle.

The atria receive venous blood on a nearly continuous basis, allowing the heart to continue to receive blood even while the ventricles are contracting. While most ventricular filling occurs while the atria are relaxed, they do demonstrate a contractile phase and actively pump blood into the ventricles just prior to ventricular contraction. The opening between the right atrium and right ventricle is guarded by the **tricuspid valve**.

Right Ventricle

The right ventricle receives blood from the right atrium through the tricuspid valve (also called the right atrioventricular valve). There are three papillary muscles in the right ventricle which correspond to the three flaps of the valve. (The third valve flap and papillary muscle would be on the anterior portion of the heart, which has been removed in this illustration.) When the myocardium of the ventricle contracts, pressure within the ventricular chamber rises. Blood, like any fluid, flows from higher pressure to lower pressure areas, in this case, toward the pulmonary trunk and the atrium. To prevent any potential backflow, the flaps of the tricuspid valve are pushed closed during ventricular contraction. The papillary muscles contract with the ventricular myocardium, generating tension on the chordae tendineae. This prevents the flaps of the valves from being forced into the atria and regurgitation of the blood back into the atria during ventricular contraction. Figure 17.2.11 shows papillary muscles and chordae tendineae attached to the bicuspid valve.

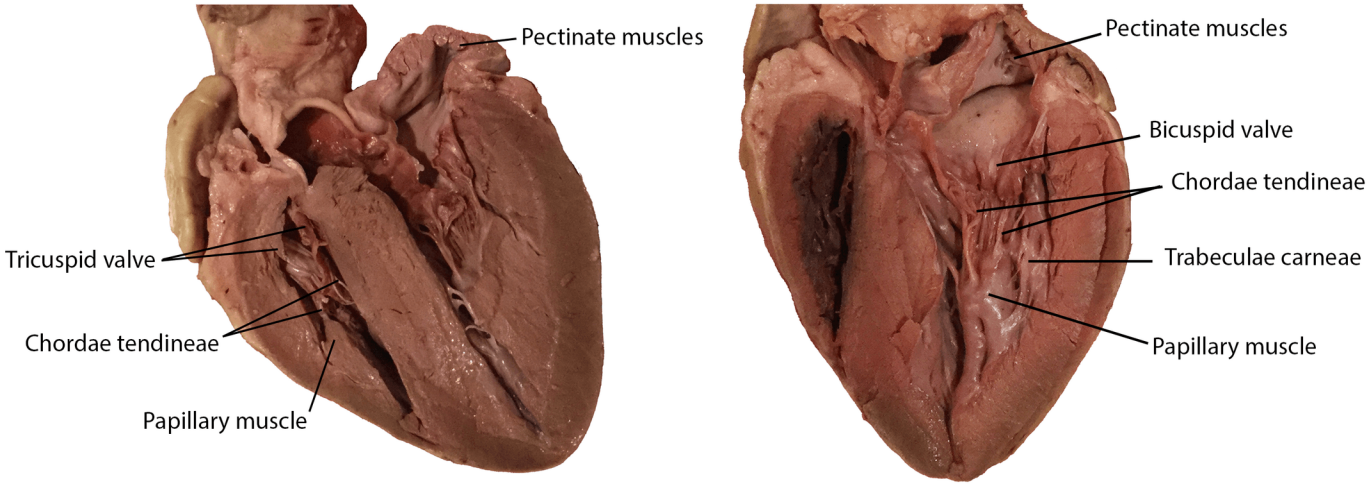

Figure 17.2.11: Interior of the Heart Chambers - Dissection. In these frontal sections, within in the ventricles you can see a papillary muscle attached to the atriventricular valve the via chordae tendineae as well as the trabeculae carneae ridges on the walls. Within the left atrium a few of the pectinate muscles are visible. *(Image credit: "Heart Dissection - Interior Features" by Jennifer Lange is licensed under CC BY-NC-SA 4.0.)*

The walls of the ventricle are lined with **trabeculae carneae**, ridges of cardiac muscle covered by endocardium (Figure 17.2.11) that increase the surface area of the ventricular wall.

When the right ventricle contracts, it ejects blood into the pulmonary trunk, which branches into the left and right pulmonary arteries that carry deoxygenated blood to each lung. The superior surface of the right ventricle begins to taper as it approaches the pulmonary trunk. At the base of the pulmonary trunk is the pulmonary semilunar valve that prevents backflow from the pulmonary trunk when the ventricle relaxes.

Left Atrium

After exchange of gases in the pulmonary capillaries, freshly oxygenated blood returns to the left atrium via one of the four pulmonary veins. The left atrium does not contain pectinate muscles so its walls are smoother than in the right atrium, but it does have an auricle that includes pectinate ridges. Blood flows nearly continuously from the pulmonary veins back into the atrium, which acts as the receiving chamber, and from here through an open bicuspid valve, also known as the mitral valve or the left atrioventricular valve, into the left ventricle. Most blood flows passively into the heart while both the atria and ventricles are relaxed, but toward the end of the ventricular relaxation period, the left atrium will contract, pumping blood into the ventricle. This atrial contraction accounts for approximately 20 percent of ventricular filling.

Left Ventricle

Recall that, although both sides of the heart will pump the same amount of blood, the muscular layer is much thicker in the left ventricle compared to the right (see Figure 17.2.7). The left ventricle is the major pumping chamber for the systemic circuit; it ejects blood into the aorta through the aortic semilunar valve. The primary driver of the myocardial thickness of the left ventricle is the need to push blood into the head to ensure the brain has a constant supply - this requires more force because of the larger

distance and the resistance of gravity.

The left ventricle also has trabeculae carneae, and they are more prominent here than in the right ventricle. The flaps of the bicuspid valve are connected to papillary muscles via chordae tendineae. There are two papillary muscles in the left ventricle—the anterior and posterior—as opposed to three in the right ventricle.

Heart Valve Function

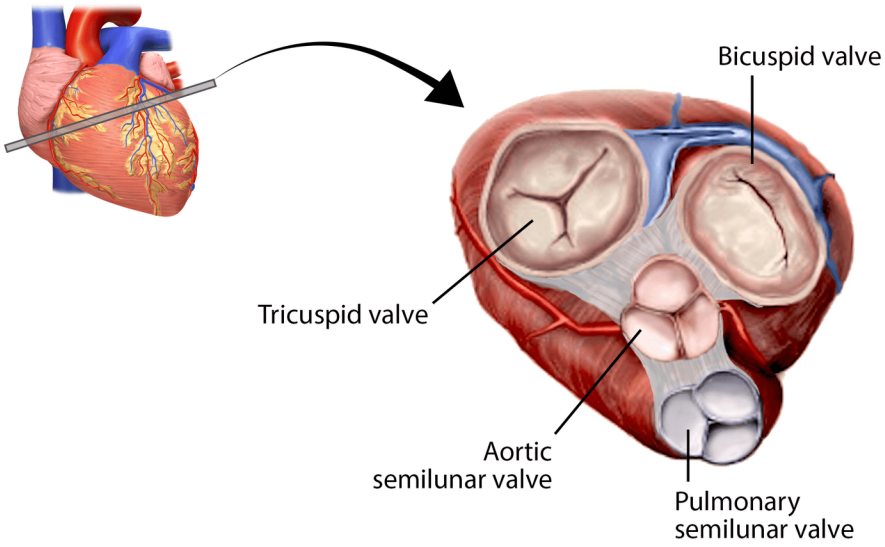

Figure 17.2.12: Valves and Cardiac Skeleton. With the atria and major vessels removed, all four valves are clearly visible. (Caption from OpenStax) *(Image credit: "Valves and the Cardiac Skeleton" by Jennifer Lange is licensed under CC BY-NC-SA 4.0, modification of originals "Blausen 0451 - Anterior view of the heart - English labels" by Blausen Medical Communications, Inc. and OLI - Drawing Valves of the heart from anterior and cross-section - English labels" by Open Learning Initiative.)*

A transverse section through the heart slightly above the level of the atrioventricular septum reveals all four heart valves along the same plane (Figure 17.2.12). The valves ensure unidirectional blood flow through the heart. Between the right atrium and the right ventricle is the **right atrioventricular valve**, or **tricuspid valve**. It typically consists of three flaps, or leaflets, made of endocardium reinforced with additional dense connective tissue. Each flap is connected by several chordae tendineae to a papillary muscle that protrudes from the ventricular wall.

Located at the opening between the left atrium and left ventricle is the **mitral valve**, also called the **bicuspid valve** or the **left atrioventricular valve**. In a clinical setting, the valve is referred to as the mitral valve, rather than the bicuspid valve, as the actual number of cusps has been found to vary greatly among individuals (Gunnal *et al*, 2012). The cusps of the mitral valve are attached by chordae tendineae to two papillary muscles that project from the trabeculae carneae of the wall of the ventricle.

When the ventricles begin to contract, pressure within the ventricles rises and blood flows toward the area of lowest pressure, which is initially in the atria. This movement of blood causes the cusps of the tricuspid and mitral valves to close. As the myocardium of the ventricle contracts, so do the papillary muscles. This creates tension on the chordae tendineae (see Figure 17.2.13 - ventricular systole), helping to hold the cusps of the atrioventricular valves in place and preventing them from everting into the atria. During the relaxation phase of the cardiac cycle, the papillary muscles are also relaxed and the tension on the chordae tendineae is slight.

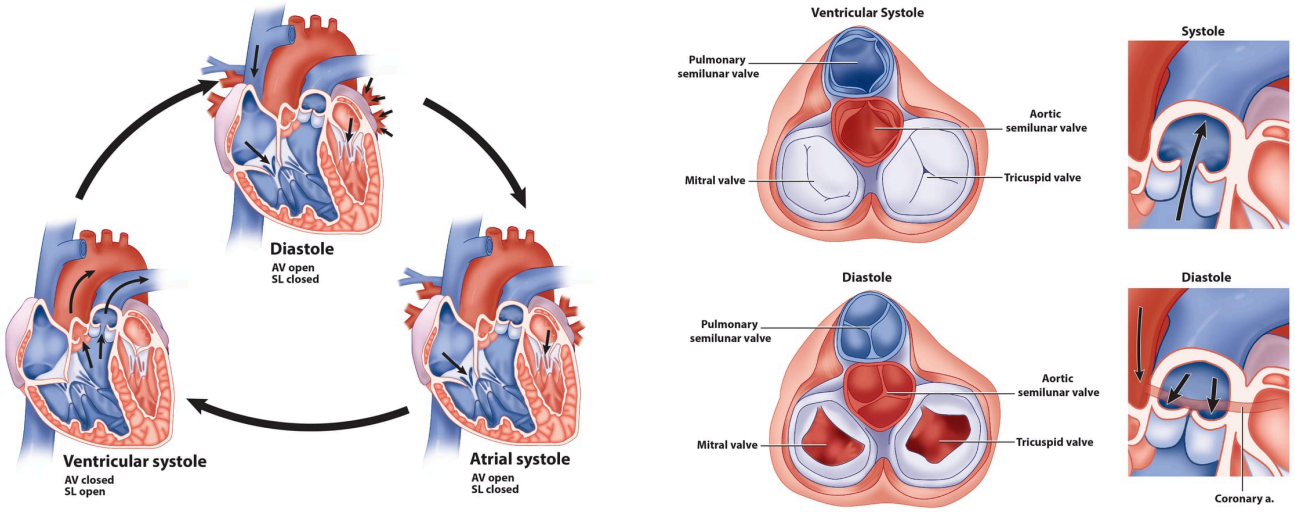

Figure 17.2.13: Bood Flow Through the Heart Valves and Chambers. During diastole, the blood will flow through the AV valves from the artia into the ventricles. During systole, the blood will flow through. the semilunar valves from the ventricles to the pulmonary and systemic circuit. *(Image credits: "Heart Cardiac Cycle" and "Heart Aortic Valve Action" by BlueLink are licensed under CC BY-NC 4.0 with notification of the original authors.)*

Emerging from the right ventricle at the base of the pulmonary trunk is the pulmonary semilunar valve, or the **pulmonary valve**; it is also known as the pulmonic valve. At the base of the aorta that emerges from the left ventricle is the aortic semilunar valve, or the **aortic valve**. The semilunar valves are both comprised of three small flaps of endothelium reinforced with dense connective tissue.

When the ventricle relaxes, the pressure differential causes blood to flow back towards the ventricle within the pulmonary trunk and aorta. This flow of blood fills the pocket-like flaps of each semilunar valve, causing the valve to close, disrupting the backflow of blood and producing an audible sound. Unlike the atrioventricular valves, there are no papillary muscles or chordae tendineae associated with the semilunar valves.

Since these openings and valves structurally weaken the atrioventricular septum, the remaining tissue is heavily reinforced with dense irregular connective tissue of the **cardiac skeleton**, or skeleton of the heart. It includes four rings that surround the openings between the atria and ventricles, and the openings to the pulmonary trunk and aorta, and serve as the point of attachment for the heart valves. The cardiac skeleton also provides the structural framework against which the cardiac muscle contracts and forms an important insulating boundary in the heart's electrical conducting system.

INTERACTIVE LINK

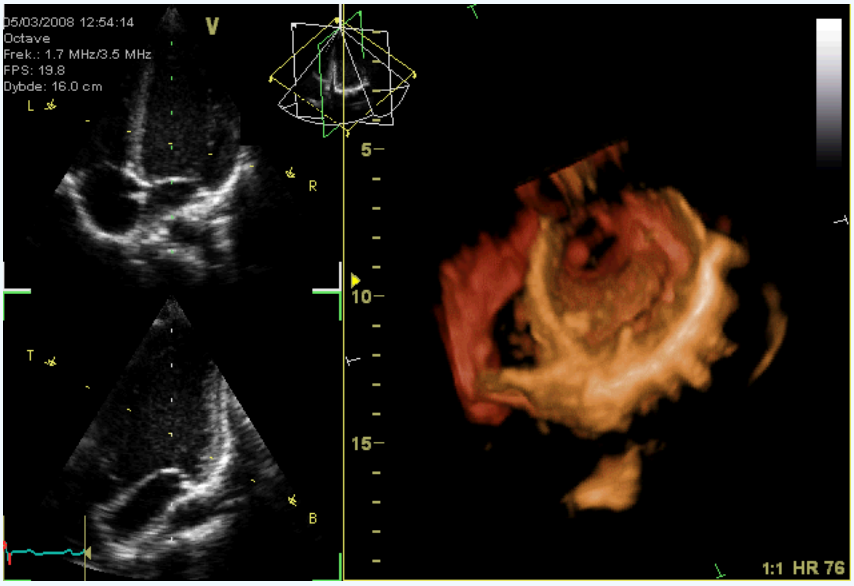

Figure 17.2.14: Echocardiogram of Heart Valves Opening and Closing. GIF-animation showing a moving echocardiogram; a 3D-loop of a heart viewed from the apex, with the apical part of the ventricles removed and the mitral valve clearly visible. Due to missing data the leaflet of the tricuspid and aortic valve is not clearly visible, but the openings are. To the left are two standard two-dimensional views taken from the 3D dataset. If not animated above, visit this site to observe an echocardiogram of actual heart valves opening and closing. (Image and caption credit: "Apikal4D" by Kjetil Lenes is licensed under CC BY-SA 3.0)

Query 17.2.1

This interactive element is not available in this format. Visit the link or scan the QR code to access it online.

View this Interactive Content online

Valves and Heart Sounds

In a normal, healthy heart, there are primarily two audible **heart sounds**: S_1 and S_2. S_1 is the sound created by the closing of the atrioventricular valves during ventricular contraction and is normally described as a “lub,” or first heart sound. The second heart sound, S_2, is the sound of the closing of the semilunar valves during ventricular diastole and is described as a “dub”. In both cases, as the valves close, the openings within the atrioventricular septum guarded by the valves will become reduced, and blood flow through the opening will become more turbulent until the valves are fully closed. There is a third heart sound, S_3, but it is rarely heard in healthy individuals.

The term **murmur** is used to describe an unusual sound coming from the heart that is caused by the turbulent flow of blood. Murmurs are graded on a scale of 1 to 6, with 1 being the most common, the most difficult sound to detect, and the least serious. Placement of the stethoscope in four distinct locations enables optimal ausculation (listening with a stethoscope) of each valve: near transition of the ascending aorta to the aortic arch for the aortic valve, near the bifurcation of the pulmonary trunk for the pulmonary valve, near the superior portion of the right ventricle for the tricuspid valve, and near the apex of the heart for the bicuspid valve. Figure 17.2.15 indicates proper placement of the bell of the stethoscope to facilitate auscultation.

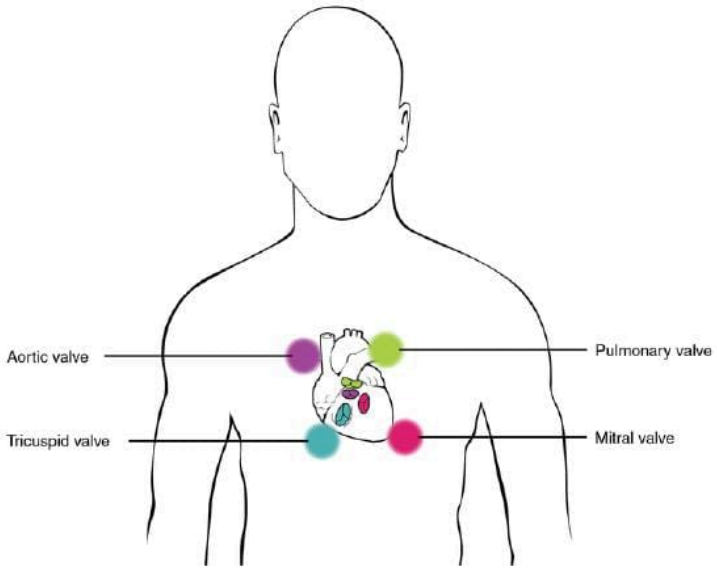

Figure 17.2.15: Stethoscope Placement for Auscultation. Proper placement of the bell of the stethoscope facilitates auscultation. At each of the four locations on the chest, a different valve can be heard. (Image credit: "Stethoscope Placement" by OpenStax is licensed under CC BY 3.0)

DISORDERS OF THE...

Heart Valves

When heart valves do not function properly, they are often described as incompetent and result in valvular heart disease, which can range from benign to lethal. Some of these conditions are congenital, that is, the individual was born with the defect, whereas others may be attributed to disease processes or trauma. Some malfunctions are treated with medications, others require surgery, and still others may be mild enough that the condition is merely monitored since treatment might trigger more serious consequences.

Valvular disorders are often caused by carditis, or inflammation of the heart. One common trigger for this inflammation is rheumatic fever, or scarlet fever, an autoimmune response to the presence of a bacterium, Streptococcus pyogenes, normally a disease of childhood.

While any of the heart valves may be involved in valve disorders, bicuspid regurgitation is the most common, detected in approximately 2 percent of the population, and the pulmonary semilunar valve is the least frequently involved. When a valve malfunctions, the flow of blood to a region will often be disrupted. The resulting inadequate flow of blood to this region will be described in general terms as an insufficiency. The specific type of insufficiency is named for the valve involved: aortic insufficiency, mitral insufficiency, tricuspid insufficiency, or pulmonary insufficiency.

If one of the cusps of the valve is forced backward by the force of the blood, the condition is referred to as a prolapsed valve. Prolapse may occur if the chordae tendineae are damaged or broken, causing the closure mechanism to fail. The failure of the valve to close properly disrupts the normal one-way flow of blood and results in regurgitation, when the blood flows backward from its normal path. Using a stethoscope, the disruption to the normal flow of blood produces a heart murmur.

Stenosis is a condition in which the heart valves become rigid and may calcify over time. The loss of flexibility of the valve interferes with normal function and may cause the heart to work harder to propel blood through the valve, which eventually weakens the heart. Aortic stenosis affects approximately 2 percent of the population over 65 years of age, and the percentage increases to approximately 4 percent in individuals over 85 years. Occasionally, one or more of the chordae tendineae will tear or the papillary muscle itself may die as a component of a myocardial infarction (heart attack). In this case, the patient's condition will deteriorate dramatically and rapidly, and immediate surgical intervention may be required.

Auscultation, or listening to a patient's heart sounds, is one of the most useful diagnostic tools, since it is proven, safe, and inexpensive. The term auscultation is derived from the Latin for "to listen," and the technique has been used for diagnostic purposes as far back as the ancient Egyptians. Valve and septal disorders will trigger abnormal heart sounds. If a valvular disorder is detected or suspected, a test called an echocardiogram, or simply an "echo," may be ordered. Echocardiograms are sonograms of the heart and can help in the diagnosis of valve disorders as well as a wide variety of heart pathologies.

Circulation Through the Heart

The right ventricle pumps **deoxygenated blood** into the **pulmonary trunk**, which ascends across the anterior surfaces of the ascending aorta and left atrium toward a bifurcation into the left and right **pulmonary arteries**. The right pulmonary artery passes under the aortic arch and delivers blood to the right lung. The left pulmonary artery delivers blood to the left lung. These arteries in turn branch many times in each lung before reaching the **pulmonary capillaries**, where gas exchange occurs: carbon dioxide exits the blood and oxygen enters. The pulmonary trunk, arteries, and their branches are the only arteries in the post-natal body that carry relatively deoxygenated blood. Highly oxygenated blood returning from the pulmonary capillaries in the lungs passes through a series of vessels that join together to form the **pulmonary veins**—the only post-natal veins in the body that carry highly oxygenated blood. The pulmonary veins conduct blood into the right and left sides of the left atrium posteriorly, which pumps the blood into the left ventricle, which in turn pumps oxygenated blood into the aorta, which ascends out of the left ventricle posterior to the pulmonary trunk, arches over the top of the heart and descends posterior to the heart. The aorta branches to deliver oxygenated blood throughout the body via the systemic circuit. Eventually, blood reaches systemic capillaries, where exchange with the tissue fluid and cells of the body occurs. In this case, oxygen and nutrients exit the systemic capillaries to be used by the cells in their metabolic processes, and carbon dioxide and waste products will enter the blood.

The blood exiting the systemic capillaries is lower in oxygen concentration than when it entered. The capillaries will ultimately unite to form venules, joining to form ever-larger veins, eventually flowing into the two major systemic veins, the **superior vena cava** and the **inferior vena cava**, which return blood into the right atrium. The blood in the superior and inferior venae cavae flows into the right atrium, which pumps blood into the right ventricle (Figure 17.2.4).

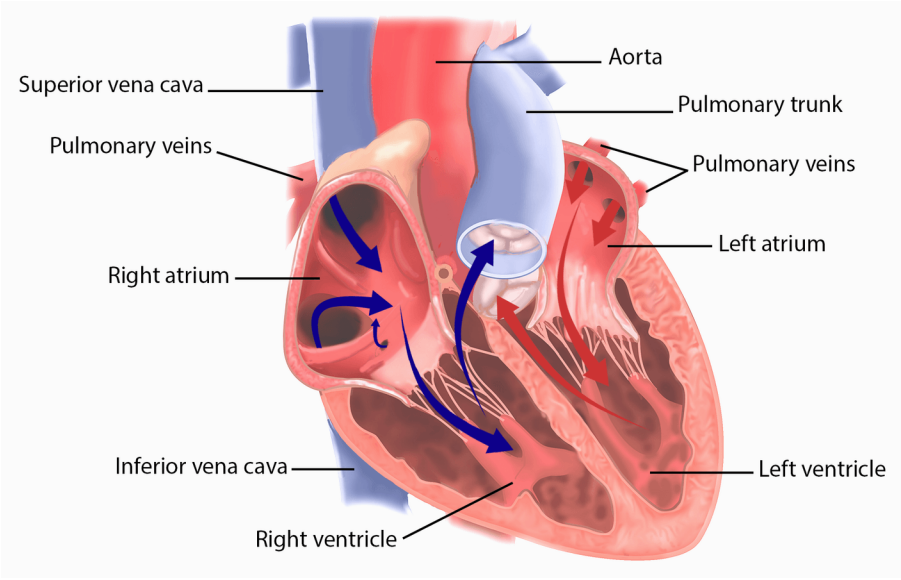

Figure 17.2.16: Circulation Through the Heart. Blood flows from the atria (right and left) to the ventricles (right and left), where it is pumped into the pulmonary circuit (from right ventricle) and systemic circuit (from left ventricle). *(Image credits: "Circulation Through the Heart" by Jennifer Lange is licensed under CC BY-NC-SA 4.0, modification of original "Slagter - Drawing Anatomy of the heart and large vessels - no labels" by Ron Slagter, license: CC BY-NC-SA.)*

CAREER CONNECTION

Cardiovascular Technologist/Technician

Cardiovascular technologists/technicians are trained professionals who perform a variety of imaging techniques, such as sonograms or echocardiograms, used by physicians to diagnose and treat diseases of the heart. Nearly all of these positions require an associate degree, and these technicians earn a median salary of $68,750 as of 2019. Growth within the field is fast, projected at 12 percent from 2019 - 2029, according to the U.S. Bureau of Labor Statistics.

QR Code representing
a URL

Visit this site for more information on cardiovascular technologists/technicians [statistics retrieved 10 Dec 2020].

There is a considerable overlap and complementary skills between cardiac technicians and vascular technicians, and so the term cardiovascular technician is often used. Special certifications within the field require documenting appropriate experience and completing additional and often expensive certification examinations. These subspecialties include Certified Rhythm Analysis Technician (CRAT), Certified Cardiographic Technician (CCT), Registered Congenital Cardiac Sonographer (RCCS), Registered Cardiac Electrophysiology Specialist (RCES), Registered Cardiovascular Invasive Specialist (RCIS), Registered Cardiac Sonographer (RCS), Registered Vascular Specialist (RVS), and Registered Phlebology Sonographer (RPhS).

Concept Review

The heart resides within the pericardial sac and is located in the mediastinal space within the thoracic cavity. The pericardial sac consists of two fused layers: an outer fibrous layer and an inner parietal pericardial serous membrane. Between the pericardial sac and the heart is the pericardial cavity, which is filled with lubricating serous fluid. The walls of the heart are composed of an outer epicardium, a thick myocardium, and an inner lining layer of endocardium. The human heart consists of a pair of atria, which receive blood and pump it into a pair of ventricles, which pump blood into the vessels. The right atrium receives systemic blood relatively low in oxygen and pumps it into the right ventricle, which pumps it into the pulmonary circuit. Exchange of oxygen and carbon dioxide occurs in the lungs, and blood high in oxygen returns to the left atrium, which pumps blood into the left ventricle, which in turn pumps blood into the aorta and the remainder of the systemic circuit. The septa are the partitions that separate the chambers of the heart. They include the interatrial septum, the interventricular septum, and the atrioventricular septum. Two of these openings are guarded by the atrioventricular valves, the right tricuspid valve and the left mitral valve, which prevent the backflow of blood. Each is attached to chordae tendineae that extend to the papillary muscles, which are extensions of the myocardium, to prevent the valves from being blown back into the atria. The pulmonary semilunar valve is located at the base of the pulmonary trunk, and the aortic semilunar valve is located at the base of the aorta.

Review Questions

Query 17.2.2

This interactive element is not available in this format. Visit the link or scan the QR code to access it online.

View this Interactive Content online

Critical Thinking Questions

Query 17.2.3

This interactive element is not available in this format. Visit the link or scan the QR code to access it online.

View this Interactive Content online

References

Axel L. "Papillary muscles do not attach directly to the solid heart wall." *Circulation*. 2004 Jun 29;109(25):3145-8. doi: 10.1161/01.CIR.0000134276.06719.F3 [accessed 3 April 2021].

Gunnal, S A *et al.* "Study of mitral valve in human cadaveric hearts." *Heart views: the official journal of the Gulf Heart Association* vol. 13,4 (2012): 132-5. doi:10.4103/1995-705X.105729 [accessed 3 April 2021].

Popa-Fotea, Nicoleta Monica *et al.* "Exploring the Continuum of Hypertrophic Cardiomyopathy-From DNA to Clinical Expression." *Medicina (Kaunas, Lithuania)* vol. 55,6 299. 23 Jun. 2019, doi:10.3390/medicina55060299 [accessed 2 April 2021].

Glossary

Query 17.2.4

This interactive element is not available in this format. Visit the link or scan the QR code to access it online.

View this Interactive Content online

Contributors and Attributions

- OpenStax Anatomy & Physiology (CC BY 4.0). Access for free at https://openstax.org/books/anatomy-and-physiology

This page titled 17.2: Heart Anatomy is shared under a CC BY-NC-SA 4.0 license and was authored, remixed, and/or curated by Jennifer Lange et al..

- 17.2: Heart Anatomy by Whitney Menefee, Julie Jenks, Chiara Mazzasette, and Kim-Leiloni Nguyen is licensed CC BY 4.0.

17.3: Cardiac Muscle and Electrical Activity

By the end of this section, you will be able to:

- Describe the structure of cardiac muscle tissue and cells
- Identify and describe the components of the conducting system that distributes electrical impulses through the heart

Recall that cardiac muscle shares a few characteristics with both skeletal muscle and smooth muscle, but it has some unique properties of its own. Not the least of these exceptional properties is its ability to initiate an electrical potential at a fixed rate that spreads rapidly from cell to cell to trigger the contractile mechanism. This property is known as **autorhythmicity**. Skeletal muscle can not do this. Even though cardiac muscle has autorhythmicity, heart rate is modulated by the endocrine and nervous systems.

Structure of Cardiac Muscle Tissue and Cells

Compared to the giant cylinders of skeletal muscle, cardiac muscle cells, or cardiomyocytes, are considerably shorter with much smaller diameters. Cardiac muscle also demonstrates striations, the alternating pattern of dark A bands and light I bands attributed to the precise arrangement of the myofilaments and fibrils that are organized in sarcomeres along the length of the cell (Figure 17.3.1.a). These contractile elements are virtually identical to skeletal muscle. T (transverse) tubules penetrate from the surface plasma membrane, the sarcolemma, to the interior of the cell, allowing the electrical impulse to reach the interior. The T tubules are only found at the Z discs, whereas in skeletal muscle, they are found at the junction of the A and I bands. Therefore, there are one-half as many T tubules in cardiac muscle as in skeletal muscle. In addition, the sarcoplasmic reticulum of cardiomyocytes stores few calcium ions, so most of the calcium ions must come from outside the cells. The result is a slower onset of contraction. Mitochondria are plentiful, providing energy for the cross-bridge cycling responsible for contractions of the heart. Typically, cardiomyocytes have a single, central nucleus, but two or more nuclei may be found in some cells. Cardiac muscle undergoes aerobic respiration patterns, primarily metabolizing lipids and carbohydrates. Myoglobin, lipids, and glycogen are all stored within the cytoplasm.

Cardiac muscle cells branch freely. A junction between two adjoining cells is marked by a critical structure called an **intercalated disc**, which helps support the synchronized contraction of the muscle and structurally links the cells together (Figure 17.3.1). Intercalated discs are formed by regions of sarcolemma with specialized integral membrane proteins. These form desmosomes, fasciae adherens, and large numbers of gap junctions. Desmosomes and fasciae adherens anchor the cells together. Fasciae adherens also anchor actin filaments of the sarcomere directly to the sarcolemma. Gap junctions allow the passage of ions from cell-to-cell through their sarcoplasm, a feature essential to producing synchronized contractions (Figure 17.3.1). Intercellular connective tissue also helps to bind the cells together. The importance of strongly binding these cells together is necessitated by the forces exerted by contraction; unlike skeletal muscle in which cells are the length of the organ to pull collectively on a bone via collagenous connective tissue attachments, smaller cardiac muscle cells pull on each other and ultimately on the dense connective tissue of the cardiac skeleton when they contract.

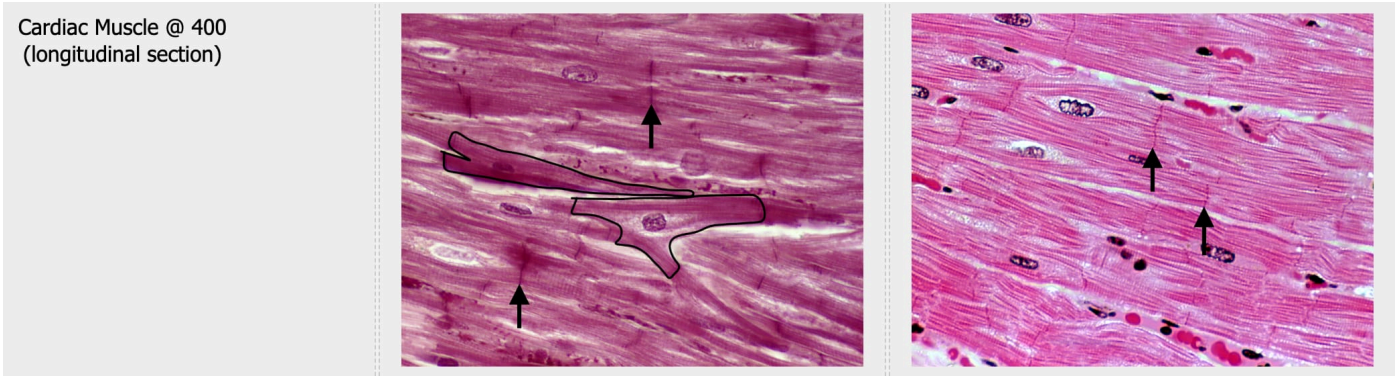

Figure 17.3.1:The cardiac muscle showing the intercalated discs (arrrows). *(Image credits: Types of Muscle Tissue by Jennifer Lange are licensed under CC-BY-SA-NC 4.0. Micrographs A1, A2, and C1 provided by the Regents of University of Michigan Medical School, micrographs B1, B2, and C2 provided by Virginia Commonwealth University.)*

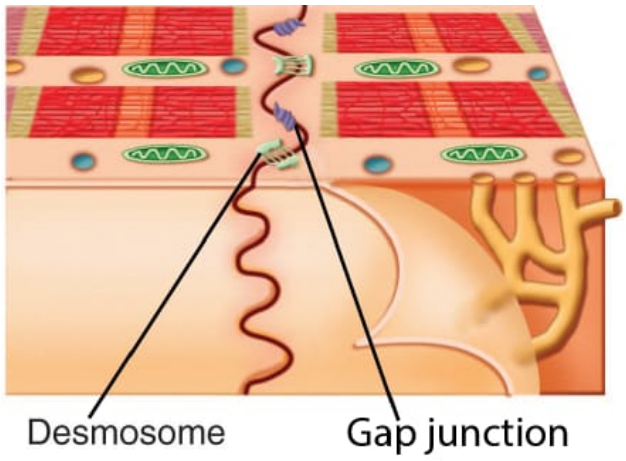

Figure 17.3.2: Intercalated discs are specialized cell junctions unique to cardiac muscle tissue that contain gap junctions and desmosomes. *(Image credit: "Intercalated Disc" by Jennifer Lange is licensed under CC-BY-SA-NC 4.0, modification of original work by Cenveo.)*

There are two major types of cardiac muscle cells: myocardial contractile cells and myocardial conducting cells. The **myocardial contractile cells** constitute the bulk (99 percent) of the cells in the myocardium of the atria and ventricles. Myocardial contractile cells are autorhythmic, but they are primarily responsible for the strong, synchronized contractions necessary to pump blood through the body. The **myocardial conducting cells** (1 percent of the cells) are generally much smaller than the contractile cells and have fewer myofibrils for contraction. Myocardial conducting cells are specialized to initiate and propagate the electrical activity that travels throughout the heart and triggers the contractions of the myocardial contractile cells that propel the blood.

EVERYDAY CONNECTION

Repair and Replacement of Cardiac Muscle

Damaged cardiac muscle cells have extremely limited abilities to repair themselves or to replace dead cells via mitosis. Recent evidence indicates that at least some stem cells remain within the heart that continue to divide and at least potentially replace these dead cells. However, newly formed or repaired cells are rarely as functional as the original cells, and cardiac function is reduced. In the event of a heart attack or myocardial infarction (MI), dead cells are often replaced by patches of scar tissue in a process called fibrosis. Autopsies performed on individuals who had successfully received heart transplants show some proliferation of original cells. If researchers can unlock the mechanism that generates new cells and restore full mitotic capabilities to heart muscle, the prognosis for heart attack survivors will be greatly enhanced. To date, myocardial cells produced within the patient (*in situ*) by cardiac stem cells seem to be nonfunctional, although those grown in Petri dishes (*in vitro*) do beat. Perhaps soon this mystery will be solved, and new advances in treatment will be commonplace.

Conducting System of the Heart

The myocardial conducting cells are concentrated in specific areas of the heart that make up the Conducting System. The components of the cardiac conducting system include the sinoatrial node, the atrioventricular node, the atrioventricular bundle, the atrioventricular bundle branches, and the Purkinje fibers (Figure 17.3.3).

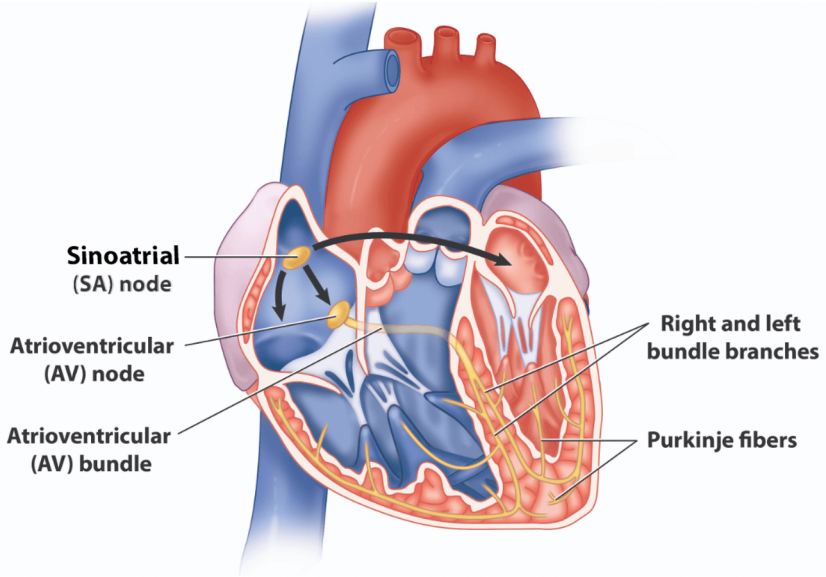

Figure 17.3.3: Conducting System of the Heart. Specialized conducting components of the heart include the sinoatrial node, the atrioventricular node, the atrioventricular bundle, the right and left bundle branches, and the Purkinje fibers. *(Image credit: "Conducting System of the Heart" by BlueLink is licensed under CC BY-NC 4.0 with notification of the original authors.)*

Normal cardiac rhythm is established by the **sinoatrial (SA) node**, a specialized clump of myocardial conducting cells located in the posterosuperior walls of the right atrium in close proximity to the orifice of the superior vena cava. The myocardial conducting cells of the SA node have the highest inherent rate of electrical signal initiation, so the SA node is known as the **pacemaker** of the heart. This impulse spreads from its initiation in the SA node throughout the atria and to the atrioventricular node. The **atrioventricular (AV) node** is a second clump of specialized myocardial conducting cells, located in the inferior portion of the right atrium within the atrioventricular septum.

Arising from the AV node, the **atrioventricular bundle**, or **bundle of His**, proceeds into the interventricular septum before dividing into two **atrioventricular bundle branches**, commonly called the left and right bundle branches. The left bundle branch supplies the left ventricle, and the right bundle branch the right ventricle. Both descend and reach the apex of the heart where they connect with the **Purkinje fibers** (see Figure 17.3.3), which then spread the impulse to the myocardial contractile cells in the ventricles. They extend throughout the myocardium from the apex of the heart toward the atrioventricular septum and the base of the heart at the top of the ventricles. Figure 17.3.4 show the spread of the electrical wave through these structures and the myocardial contractile cells.

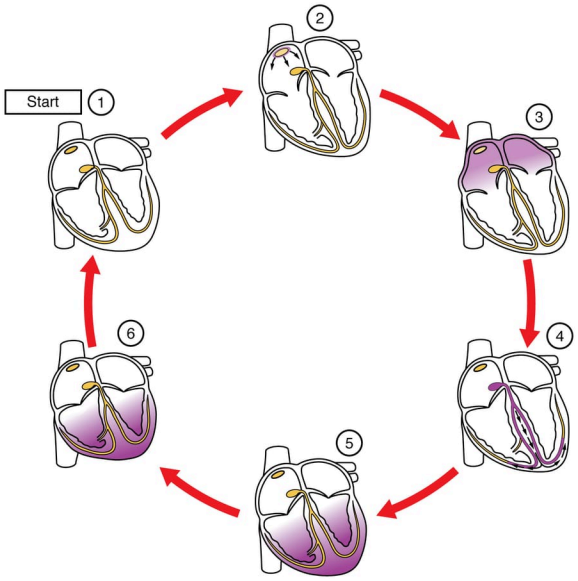

Figure 17.3.4: Cardiac Conduction. (1) The sinoatrial (SA) node and the remainder of the conducting system are at rest. (2) The SA node initiates the electrical wave, which sweeps across the atria. (3) After reaching the atrioventricular node the impulse is transmitted to the atrioventricular bundle. (4) The impulse travels through the atrioventricular bundle and bundle branches to the Purkinje fibers. (5) The impulse spreads to the contractile fibers of the ventricle. (6) Ventricular contraction begins. *(Image credit: "Cardiac Conduction" by OpenStax is licensed under CC BY 3.0.)*

DISORDERS OF THE...

Cardiovascular System: Conduction Block

A **heart block** refers to an interruption in the normal conduction pathway. The nomenclature for these is very straightforward:

- SA nodal blocks occur within the SA node.
- AV nodal blocks occur within the AV node.
- Infra-Hisian blocks involve the bundle of His.
- Bundle branch blocks occur within either the left or right atrioventricular bundle branches.

Clinically, the most common types are the AV nodal and infra-Hisian blocks.

When arrhythmias become a chronic problem, the heart maintains the rhythm of the AV node. In order to speed up the heart rate and restore full sinus rhythm, a cardiologist can implant an **artificial pacemaker**, which delivers electrical impulses to the heart muscle to ensure that the heart continues to contract and pump blood effectively.

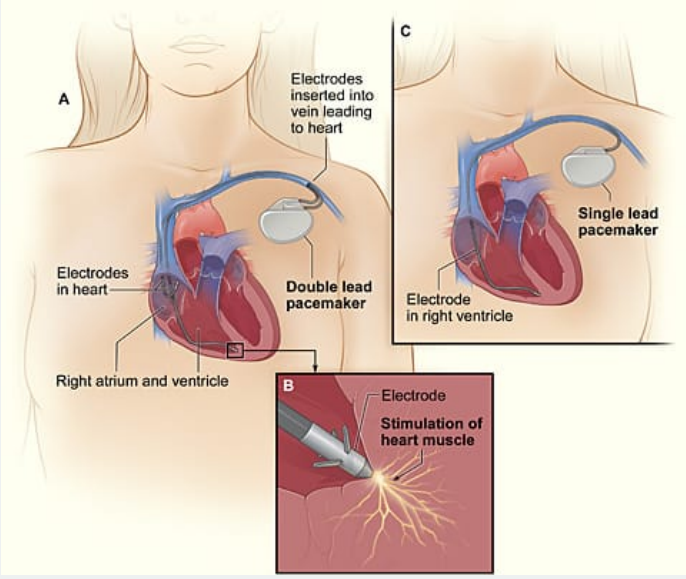

Figure 17.3.5: The image shows a cross-section of a chest and heart with a traditional pacemaker, which has wires (leads). Figure A shows a double-lead pacemaker (also called a double-chamber pacemaker) in the upper chest. Figure B shows an electrode using electrical signals to activate the heart muscle. Figure C shows a single lead pacemaker (also called a single-chamber pacemaker) in the upper chest. Wireless pacemakers (not pictured) are placed inside the right ventricle. *(Image credit: "Pacemaker NIH" by the National Heart Lung and Blood Institute (NIH) is in the Public domain, via Wikimedia Commons.)*

A traditional pacemaker generator is placed outside of the heart, either in the chest or abdomen. It connects via wires to electrodes inside one to three heart chambers: single- and double-lead pacemakers send pulses to the right side of the heart and biventricular pacemakers sends pulses to both ventricles and an atrium. Wireless, or leadless, pacemakers are smaller than traditional types because the pulse generator and electrodes are all in one device. This type of pacemaker is placed inside the heart from where it then sends pulses to the right ventricle.

Concept Review

The heart is regulated by both neural and endocrine control, yet it initiates its own electrical impulse at an intrinsic rate followed by muscular contraction. The myocardial conducting cells within the heart establish the heart rate and transmit it through the myocardium. The myocardial contractile cells contract and propel the blood. The normal path of transmission for the conductive cells is the sinoatrial (SA) node, atrioventricular (AV) node, atrioventricular (AV) bundle, bundle branches, and Purkinje fibers.

Review Questions

Query 17.3.1

This interactive element is not available in this format. Visit the link or scan the QR code to access it online.

View this Interactive Content online

Critical Thinking Questions

Query 17.3.2

This interactive element is not available in this format. Visit the link or scan the QR code to access it online.

View this Interactive Content online

Glossary

Query 17.3.3

This interactive element is not available in this format. Visit the link or scan the QR code to access it online.

View this Interactive Content online

Contributors and Attributions

- OpenStax Anatomy & Physiology (CC BY 4.0). Access for free at https://openstax.org/books/anatomy-and-physiology

This page titled 17.3: Cardiac Muscle and Electrical Activity is shared under a CC BY-NC-SA 4.0 license and was authored, remixed, and/or curated by Jennifer Lange et al..

- 17.3: Cardiac Muscle and Electrical Activity by Whitney Menefee, Julie Jenks, Chiara Mazzasette, and Kim-Leiloni Nguyen is licensed CC BY 4.0.
- 18.2: Structure and Function of Blood Vessels by Whitney Menefee, Julie Jenks, Chiara Mazzasette, and Kim-Leiloni Nguyen is licensed CC BY 4.0.

17.4: Coronary Circulation

By the end of this section, you will be able to:

- Identify the veins and arteries of the coronary circulation system
- Describe how atherosclerosis impacts blood flow in coronary arteries and can cause a heart attack

You will recall that the heart is a remarkable pump composed largely of cardiac muscle cells that are incredibly active throughout life. Like all other cells, a **cardiomyocyte** requires a reliable supply of oxygen and nutrients, and a way to remove wastes, so it needs a dedicated, complex, and extensive coronary circulation. And because of the critical and nearly ceaseless activity of the heart throughout life, this need for a blood supply is even greater than for a typical cell. However, coronary circulation is not continuous; rather, it cycles, reaching a peak when the heart muscle is relaxed and nearly ceasing while it is contracting.

Coronary Arteries

Coronary arteries supply blood to the myocardium and other components of the heart. Immediately after the aorta emerges from the left ventricle it gives rise to the right and left coronary arteries.

The **left coronary artery** distributes blood to the left side of the heart, the left atrium and ventricle, and the interventricular septum. It runs posterior to the pulmonary trunk and almost immediately branches into two vessels: the circumflex and anterior interventricular arteries. The **circumflex artery** follows the coronary sulcus to the left and eventually fuses with the small branches of the right coronary artery. The larger **anterior interventricular artery**, also known as the left anterior descending artery (LAD), follows the anterior interventricular sulcus toward the apex of the heart. Along the way it gives rise to numerous smaller branches that interconnect with the branches of the posterior interventricular artery, forming anastomoses. An **anastomosis** is an area where vessels unite to form interconnections that normally allow blood to circulate to a region even if there may be partial blockage in another branch. The anastomoses in the heart are very small. Therefore, this ability is somewhat restricted in the heart so a coronary artery blockage often results in death of the cells (myocardial infarction) supplied by the particular vessel.

The **right coronary artery** proceeds along the coronary sulcus and distributes blood to the right atrium, portions of both ventricles, and the cardiac conducting system. On the posterior surface of the heart, the right coronary artery abruptly dips inferiorly and becomes the **posterior interventricular artery**, also known as the posterior descending artery. It runs along the posterior portion of the interventricular sulcus toward the apex of the heart, giving rise to branches that supply the posterior aspects of the interventricular septum and portions of both ventricles. Figure 17.4.1 presents the major vessels of coronary circulation from both the anterior and posterior views.

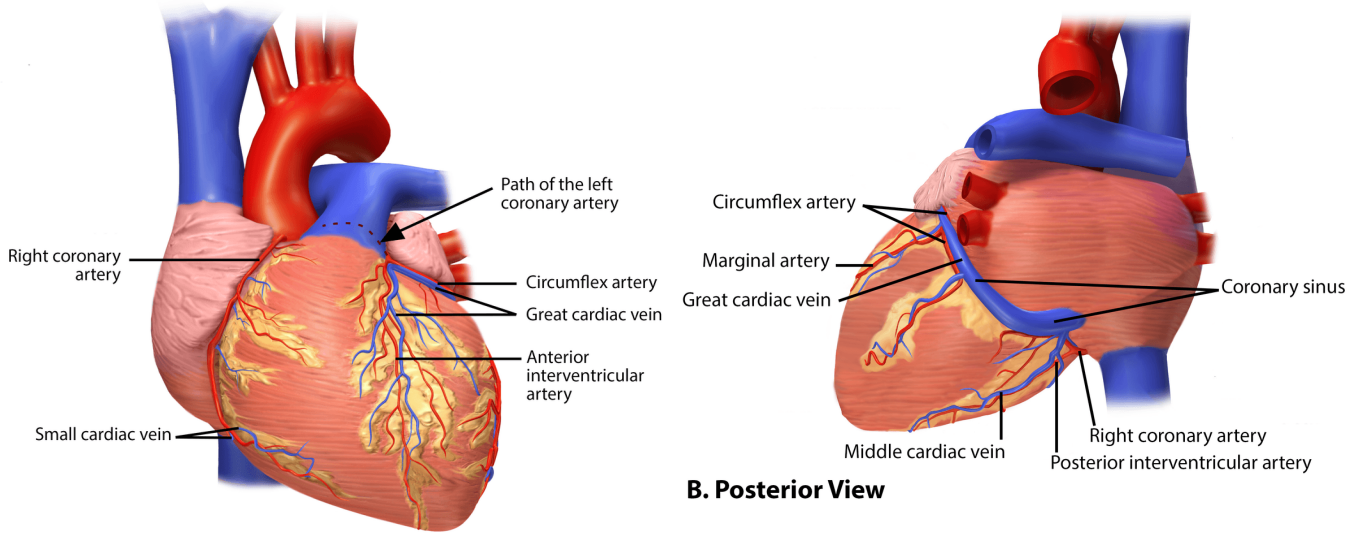

Figure 17.4.1: Coronary Arteries and Veins. The major coronary vessels shown in and anterior (A) and posterior (B) heart illustration. *(Image credits: "Coronary Vessels, Anterior View" by Jennifer Lange is licensed under CC BY-NC-SA 4.0, modification of original "Blausen 0451 - Anterior view of the heart - English labels" by Blausen Medical Communications, Inc.; "Coronary Vessels, Posterior View" by Jennifer Lange is licensed under under CC BY-NC-SA 4.0, modification of original "Blausen 0456 Heart Posterior" by Blausen Medical Communications, Inc.)*

DISORDERS OF THE...

Heart: Coronary Artery Disease

Coronary artery disease is the leading cause of death worldwide. It occurs when the buildup of plaque—a fatty material including cholesterol, connective tissue, white blood cells, and some smooth muscle cells—within the walls of the arteries obstructs the flow of blood and decreases the flexibility or compliance of the vessels. This condition is called atherosclerosis, a hardening of the arteries in which the accumulation of plaque increasingly narrows the diameter of the blood vessel. As the coronary blood vessels become occluded, the flow of blood to the tissues will be restricted, a condition called ischemia that causes the cells to receive insufficient amounts of oxygen, called hypoxia. Figure 17.4.2 shows the blockage of coronary arteries highlighted by the injection of dye. Some individuals with coronary artery disease report pain radiating from the chest called angina pectoris, but others remain asymptomatic. If untreated, coronary artery disease can lead to MI or a heart attack.

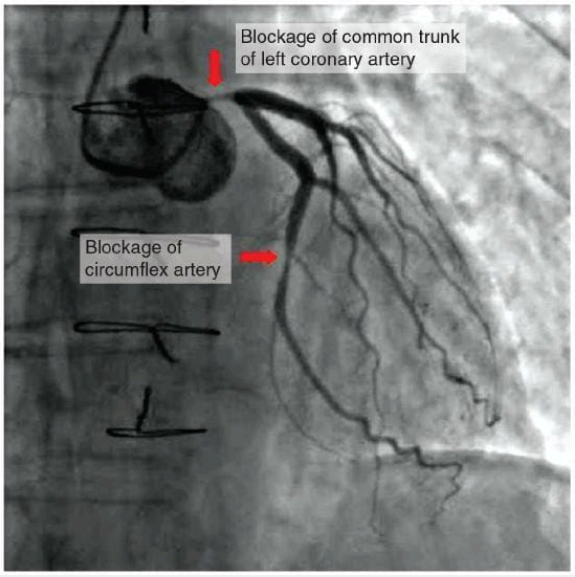

Figure 17.4.2: Atherosclerotic Coronary Arteries. In this coronary angiogram (X-ray), the dye makes visible two occluded coronary arteries, with noticeable narrowing pointed out in the circumflex artery and the common trunk of the left coronary artery. Such blockages can lead to decreased blood flow (ischemia) and insufficient oxygen (hypoxia) delivered to the cardiac tissues. If uncorrected, this can lead to cardiac muscle death (myocardial infarction). *(Image credit: "Occluded Coronay Arteries [sic]" by OpenStax is licensed under CC BY 3.0.)*

The disease progresses slowly and often begins in children and can be seen as fatty “streaks” in the vessels. It then gradually progresses throughout life. Well-documented risk factors include smoking, family history, hypertension, obesity, diabetes, high alcohol consumption, lack of exercise, stress, and hyperlipidemia or high circulating levels of lipids in the blood. Treatments may include medication, changes to diet and exercise, angioplasty with a balloon catheter, insertion of a stent, or coronary bypass procedure.

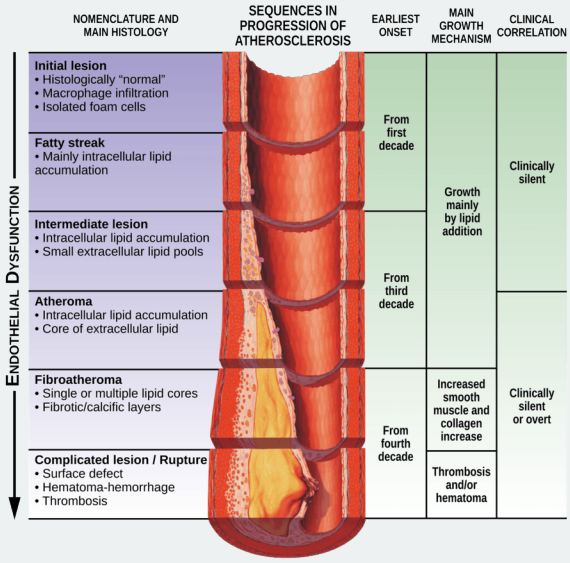

Figure 17.4.3: Atherosclerosis. Atherosclerosis is a progressive disease that narrow the diameter of an artery and restricts blood flow. *(Image credit: "Atherosclerosis Timeline - endothelial dysfunction" by YitzhakNat is licensed under CC BY-SA 4.0, via Wikimedia Commons.)*

Angioplasty is a procedure in which the occlusion is mechanically widened with a balloon (Figure 17.4.3). A specialized catheter with an expandable tip is inserted into a superficial vessel, normally in the leg, and then directed to the site of the occlusion. At this point, the balloon is inflated to compress the plaque material and to open the vessel to increase blood flow. Then, the balloon is deflated and retracted. A stent consisting of a specialized mesh is typically inserted at the site of occlusion to reinforce the weakened and damaged walls.

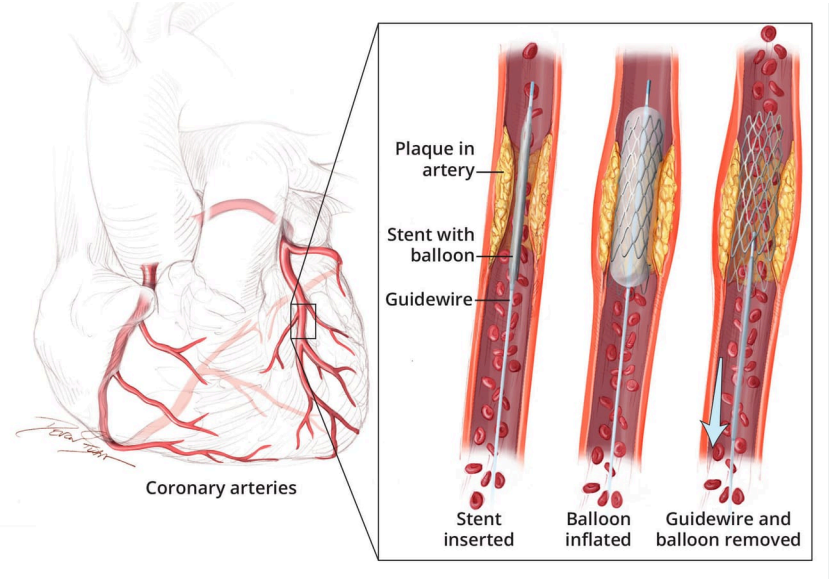

Figure 17.4.3: Angioplasty. To place a stent in a coronary artery narrowed by plaque, a catheter is inserted with an empty balloon and a stent attached at the end. The balloon is inflated to push the artery open and open the stent. Finally, the catheter and deflated balloon are removed, leaving the stent in place. (*Source: National Heart, Lung, and Blood Institute; National Institutes of Health; U.S. Department of Health and Human Services.*)

Coronary bypass surgery may also be performed. This surgical procedure grafts a replacement vessel obtained from another, less vital portion of the body to bypass the occluded area. This procedure is clearly effective in treating patients experiencing a MI, but overall does not increase longevity. Nor does it seem advisable in patients with stable although diminished cardiac capacity since frequently loss of mental acuity occurs following the procedure. Long-term changes to behavior, emphasizing diet and exercise plus a medicine regime tailored to lower blood pressure, lower cholesterol and lipids, and reduce clotting are equally as effective.

DISORDERS OF THE...

Heart: Myocardial Infarction

Myocardial infarction (MI) is the formal term for what is commonly referred to as a heart attack. It normally results from a lack of blood flow (ischemia) and oxygen (hypoxia) to a region of the heart, resulting in death of the cardiac muscle cells. An MI often occurs when a coronary artery is blocked by the buildup of atherosclerotic plaque consisting of lipids, cholesterol and fatty acids, and white blood cells, primarily macrophages. It can also occur when a portion of an unstable atherosclerotic plaque travels through the coronary arterial system and lodges in one of the smaller vessels. The resulting blockage restricts the flow of blood and oxygen to the myocardium and causes death of the tissue (Figure 17.4.4). MIs may be triggered by excessive exercise, in which the partially occluded artery is no longer able to pass sufficient quantities of blood, or severe stress, which may induce spasm of the smooth muscle in the walls of the vessel.

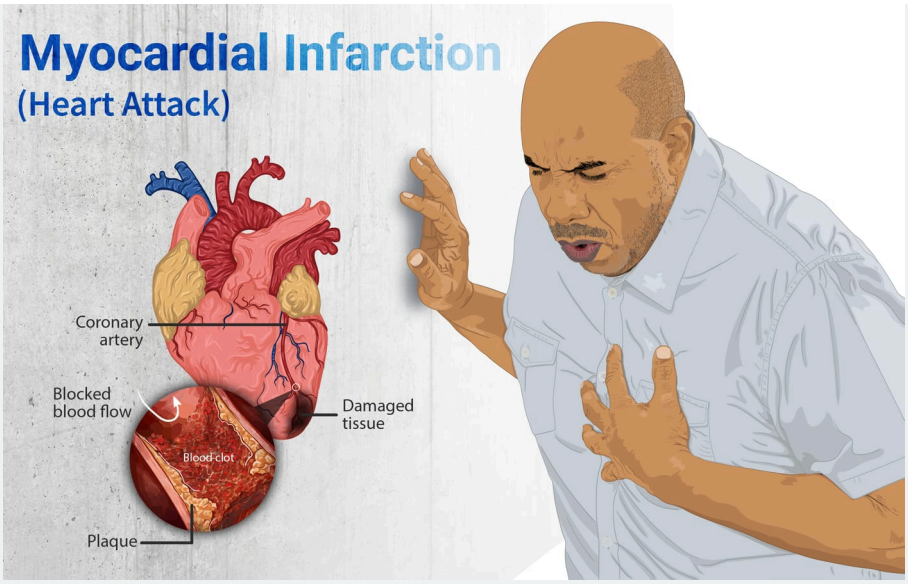

Figure \(\

PageIndex

{4}\): Myocardial Infarction. Blockage of a coronary artery results in the death of myocardium in distal regions. In men, this typically presents as a chest pain that radiates into the left arm. This pain may not be present in women. *("Depection of a person suffering from a heart attack, by https://www.myupchar.com/en is licensed under CC BY-SA 4.0, via Wikimedia Commons.)*

In the case of acute MI, there is often sudden pain beneath the sternum (retrosternal pain) called angina pectoris, often radiating down the left arm in males but not in female patients. Until this anomaly between the sexes was discovered, many female patients suffering MIs were misdiagnosed and sent home. According to the American Heart Association, the symptoms of a heart attack are:

Symptoms in Women	**Symptoms in Men**
• Chest pain, but not always • Pain or pressure in the lower chest or upper abdomen • Jaw, neck or upper back pain • Nausea or vomiting • Shortness of breath • Fainting • Indigestion • Extreme fatigue	• Squeezing chest pressure or pain • Jaw, neck or back pain • Nausea or vomiting • Shortness of breath

Many of the symptoms are shared with other medical conditions, including anxiety attacks and simple indigestion, so differential diagnosis is critical. It is estimated that between 22 and 64 percent of MIs present without any symptoms.

An MI can be confirmed by examining the patient's ECG. In addition, echocardiography or cardiac magnetic resonance imaging may be employed. Common blood tests indicating an MI include elevated levels of creatine kinase MB (an enzyme that catalyzes the conversion of creatine to phosphocreatine, consuming ATP) and cardiac troponin (the regulatory protein for muscle contraction), both of which are released by damaged cardiac muscle cells.

Important risk factors for MI include cardiovascular disease, age, smoking, high blood levels of the low-density lipoprotein (LDL, often referred to as "bad" cholesterol), low levels of high-density lipoprotein (HDL, or "good" cholesterol), hypertension, diabetes mellitus, obesity, lack of physical exercise, chronic kidney disease, excessive alcohol consumption, and use of illegal drugs.

Coronary Veins

Coronary veins drain the heart and generally parallel the large surface arteries (see Figure 17.4.1). The **great cardiac vein** can be seen initially on the anterior surface of the heart following the interventricular sulcus running parallel to the anterior interventricular artery. Upon reaching the coronary sulcus it runs between the left atrium and left ventricle with the circumflex artery. The **middle cardiac vein** parallels and drains the areas supplied by the posterior interventricular artery. The **small cardiac vein** originates on the lateral side of the right ventricle then parallels the right coronary artery in the coronary sulcus. It drains the blood from the posterior surfaces of the right atrium and ventricle. All three of these coronary veins merge with the coronary sinus - a large, thin-walled vein on the posterior surface of the heart lying within the atrioventricular sulcus and emptying directly into the right atrium. The **anterior cardiac veins** drain the anterior surface of the right ventricle but, unlike these other cardiac veins, it bypasses the coronary sinus and drains directly into the right atrium.

Concept Review

The right and left coronary arteries are the first to branch off the aorta and arise from two of the three sinuses located near the base of the aorta and are generally located in the sulci. Cardiac veins parallel the small cardiac arteries and generally drain into the coronary sinus. Coronary artery disease is caused by the build up of plaque in the walls of coronary arteries that causes ischemia and hypoxia in downstream tissues.

Review Questions

Query 17.4.1

This interactive element is not available in this format. Visit the link or scan the QR code to access it online.

View this Interactive Content online

Critical Thinking Questions

Query 17.4.2

This interactive element is not available in this format. Visit the link or scan the QR code to access it online.

View this Interactive Content online

Glossary

Query 17.4.3

This interactive element is not available in this format. Visit the link or scan the QR code to access it online.

View this Interactive Content online

Contributors and Attributions

- OpenStax Anatomy & Physiology (CC BY 4.0). Access for free at https://openstax.org/books/anatomy-and-physiology

This page titled 17.4: Coronary Circulation is shared under a CC BY-NC-SA 4.0 license and was authored, remixed, and/or curated by Jennifer Lange et al..

- 17.4: Coronary Circulation by Whitney Menefee, Julie Jenks, Chiara Mazzasette, and Kim-Leiloni Nguyen is licensed CC BY 4.0.

17.5: Development of the Heart

By the end of this section, you will be able to:

- Describe the embryological development of heart structures
- Identify five regions of the fetal heart
- Relate fetal heart structures to adult counterparts

The human heart is the first functional organ to develop. It begins beating and pumping blood around day 21 or 22, a mere three weeks after fertilization. This emphasizes the critical nature of the heart in distributing blood through the vessels and the vital exchange of nutrients, oxygen, and wastes both to and from the developing baby. The critical early development of the heart is reflected by the prominent **heart bulge** that appears on the anterior surface of the embryo.

The heart forms from an embryonic tissue called **mesoderm** around 18 to 19 days after fertilization. Mesoderm is one of the three primary germ layers that differentiates early in development that collectively gives rise to all subsequent tissues and organs. The heart begins to develop near the head of the embryo in a region known as the **cardiogenic area**. Following chemical signals called factors from the underlying endoderm (another of the three primary germ layers), the cardiogenic area begins to form two strands called the **cardiogenic cords** (Figure 17.5.1). As the cardiogenic cords develop, a lumen rapidly develops within them. At this point, they are referred to as **endocardial tubes**. The two tubes migrate together and fuse to form a single **primitive heart tube**. The primitive heart tube quickly forms five distinct regions. From head to tail, these include the truncus arteriosus, bulbus cordis, primitive ventricle, primitive atrium, and the sinus venosus. Initially, all venous blood flows into the sinus venosus, and contractions propel the blood from tail to head, or from the sinus venosus to the truncus arteriosus. This is a very different pattern from that of an adult.

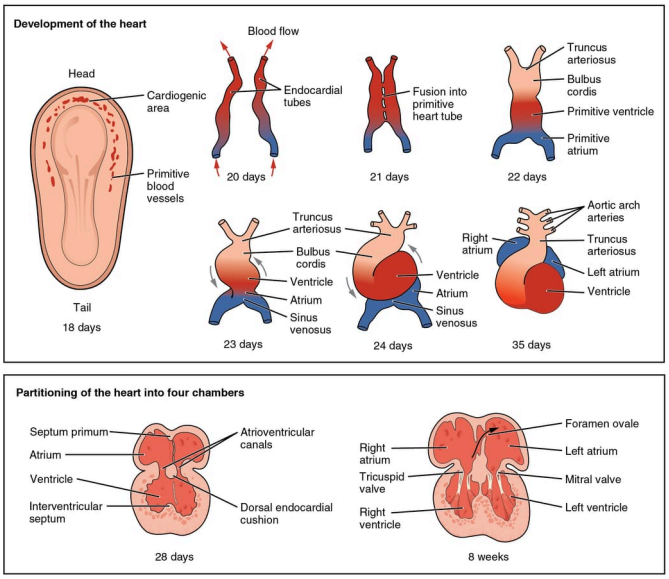

Figure 17.5.1: Development of the Human Heart. This diagram outlines the embryological development of the human heart during the first eight weeks and the subsequent formation of the four heart chambers. (Image credit: "Embryonic Development of Heart" by OpenStax is licensed under CC BY 3.0)

The five regions of the primitive heart tube develop into recognizable structures in a fully developed heart. The **truncus arteriosus** will eventually divide and give rise to the ascending aorta and pulmonary trunk. The **bulbus cordis** develops into the right ventricle. The **primitive ventricle** forms the left ventricle. The **primitive atrium** becomes the anterior portions of both the right and left atria, and the two auricles. The **sinus venosus** develops into the posterior portion of the right atrium, the SA node, and the coronary sinus.

As the primitive heart tube elongates, it begins to fold within the pericardium, eventually forming an S shape, which places the chambers and major vessels into an alignment similar to the adult heart. This process occurs between days 23 and 28. The

remainder of the cardiac development pattern includes development of septa and valves, and remodeling of the actual chambers. Partitioning of the atria and ventricles by the interatrial septum, interventricular septum, and atrioventricular septum is complete by the end of the fifth week, although the fetal blood shunts remain until birth or shortly after. The atrioventricular valves form between weeks five and eight, and the semilunar valves form between weeks five and nine.

Concept Review

The heart is the first organ to form and become functional, emphasizing the importance of transport of material to and from the developing infant. It originates about day 18 or 19 from the mesoderm and begins beating and pumping blood about day 21 or 22. It forms from the cardiogenic region near the head and is visible as a prominent heart bulge on the surface of the embryo. Originally, it consists of a pair of strands called cardiogenic cords that quickly form hollow lumens and are referred to as endocardial tubes. These then fuse into a single heart tube and differentiate into the truncus arteriosus, bulbus cordis, primitive ventricle, primitive atrium, and sinus venosus, starting about day 22. The primitive heart begins to form an S shape within the pericardium between days 23 and 28. The internal septa begin to form about day 28, separating the heart into the atria and ventricles, although the foramen ovale persists until shortly after birth. Between weeks five and eight, the atrioventricular valves form. The semilunar valves form between weeks five and nine.

Review Questions

Query 17.5.1

This interactive element is not available in this format. Visit the link or scan the QR code to access it online.

View this Interactive Content online

Critical Thinking Questions

Query 17.5.2

This interactive element is not available in this format. Visit the link or scan the QR code to access it online.

View this Interactive Content online

Query 17.5.3

This interactive element is not available in this format. Visit the link or scan the QR code to access it online.

View this Interactive Content online

Glossary

Query 17.5.4

This interactive element is not available in this format. Visit the link or scan the QR code to access it online.

View this Interactive Content online

Contributors and Attributions

- OpenStax Anatomy & Physiology (CC BY 4.0). Access for free at https://openstax.org/books/anatomy-and-physiology

This page titled 17.5: Development of the Heart is shared under a CC BY-NC-SA 4.0 license and was authored, remixed, and/or curated by Jennifer Lange et al..

- 17.5: Development of the Heart by Whitney Menefee, Julie Jenks, Chiara Mazzasette, and Kim-Leiloni Nguyen is licensed CC BY 4.0.

17.6: Anatomical Atlas - Heart

A compendium of anatomical images: slides, models, and/or cadavers.

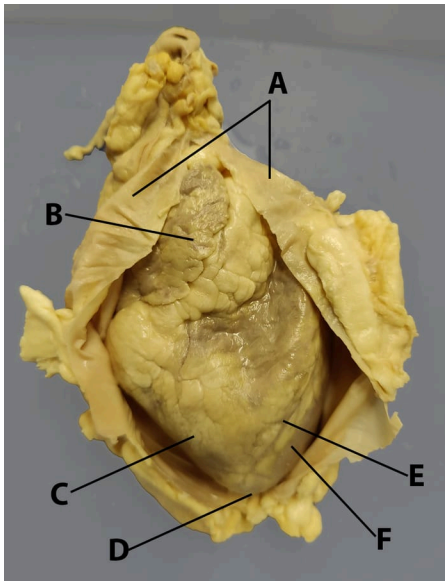

Image Credit

"Heart with Pericardium (sheep) - atlas" by Jennifer Lange is licensed under CC BY-NC-SA 4.0.

Answer Key (click to show/hide answers)

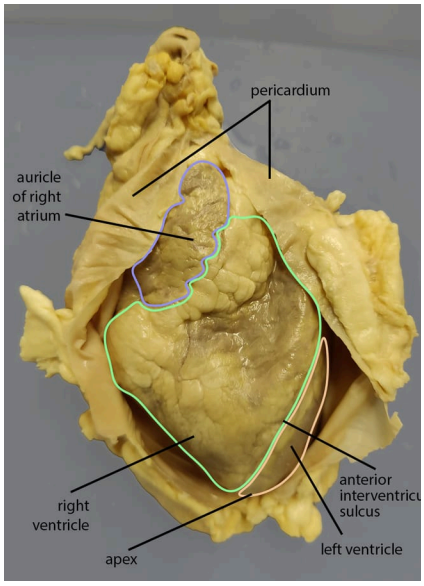

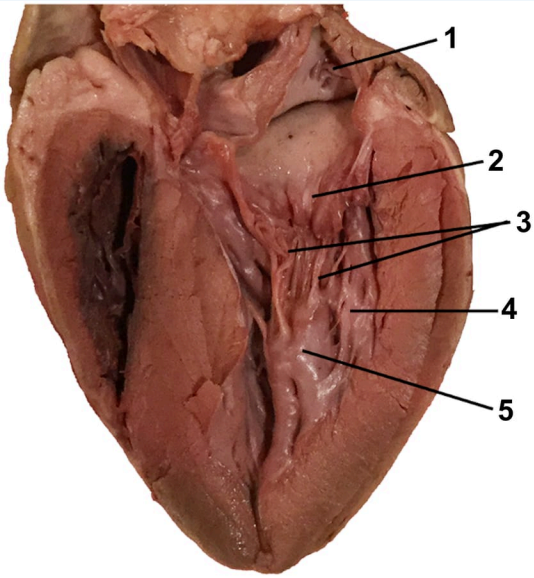

Image Credit

"Heart Dissection - Interior Features" by Jennifer Lange is licensed under CC BY-NC-SA 4.0.

Answer Key (click to show/hide answers)

Heart Internal Structures (sheep):

1 - Pectinate muscles

2 - Bicuspid valve

3 - Chordae tendineae

4 - Trabeculae carneae

5 - Papillary muscle

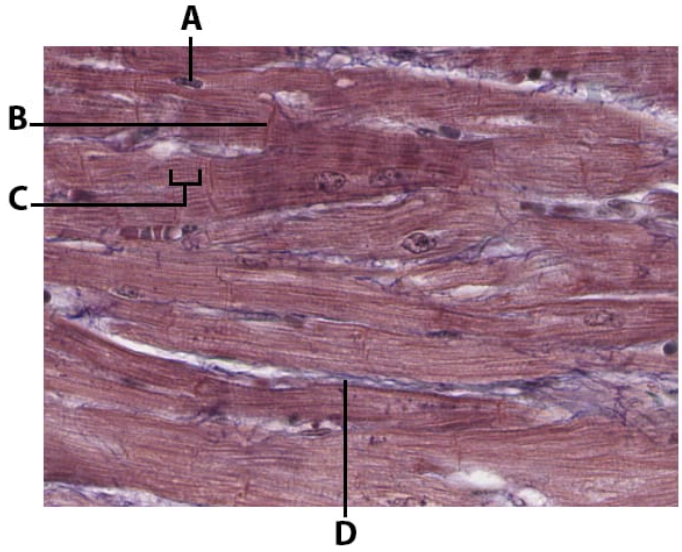

Image Credit

"Cardiac Muscle Histology" by Jennifer Lange is licensed under CC BY-NC-SA 4.0, micrographs provided by Virginia Commonwealth University under CC BY-NC-SA 4.0)

Answer Key (click to show/hide answers)

Cardiac Muscle:

A - nucleus of cardiac myofiber

B - intercalated disc

C - striations

D - endomysium

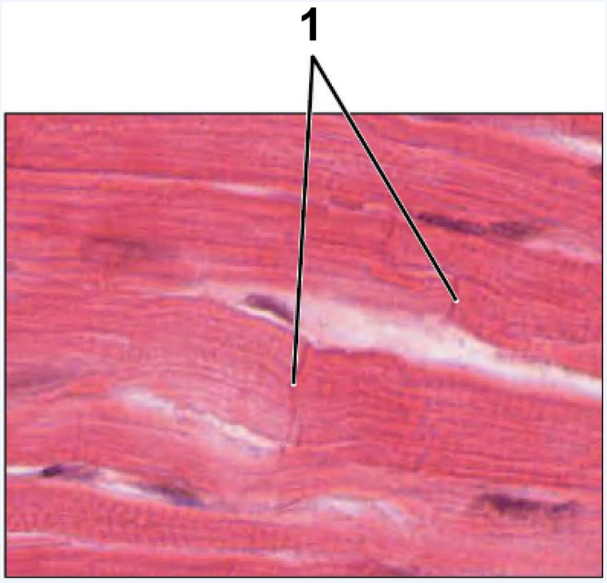

Image Credit

Answer Key (click to show/hide answers)

Heart Intercalated Disc

1 - Intercalated disc

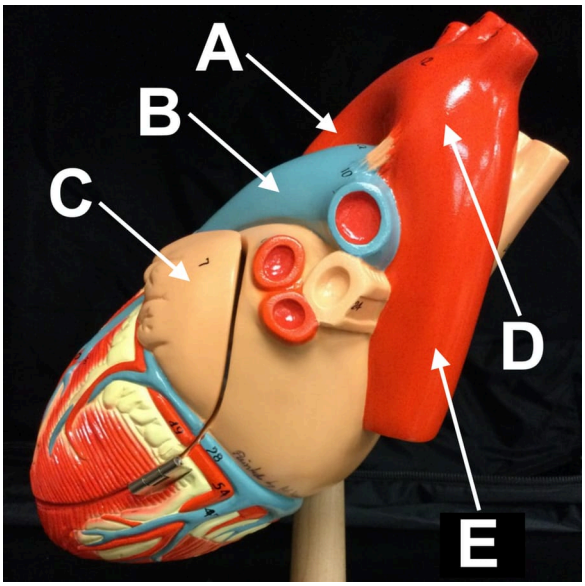

Image Credit

"Heart Model 1" by Jennifer Lange is licensed under CC BY-NC-SA 4.0.

Answer Key (click to show/hide answers)

Heart External Structures (Great Vessels):

A - Ascending part of the aorta

B - Pulmonary trunk

C - Auricle (left)

D - Arch of the aorta

E - Descending part of the aorta

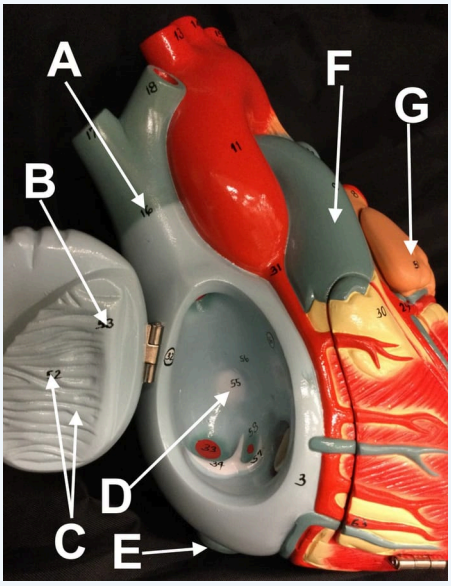

Image Credit

"Heart Model 2" by Jennifer Lange is licensed under CC BY-NC-SA 4.0.

Answer Key (click to show/hide answers)

Heart Structures and Vessels:

A - Superior Vena Cava (SVC)

B - Terminal crest

C - Pectinate muscles

D - Fossa ovalis

E - Inferior Vena Cava (IVC)

F - Pulmonary trunk

G - Auricle (left)

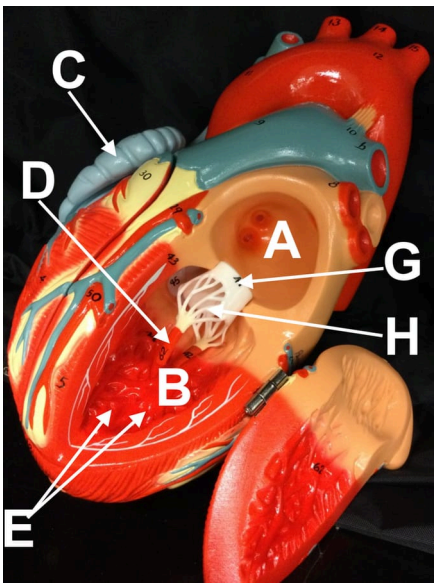

Image Credit

"Heart Model 3" by Jennifer Lange is licensed under CC BY-NC-SA 4.0.

Answer Key (click to show/hide answers)

Heart Internal Structures:

A - Atrium (left)

B - Ventricle (left)

C - Auricle (right)

D - Papillary muscle

E - Trabeculae carneae

G - Bicuspid/ Mitral/Left AV valve

H - Chordae tendineae

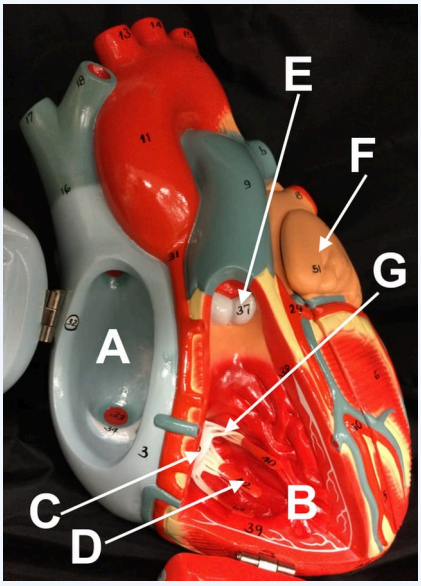

Image Credit

"Heart Model 4" by Jennifer Lange is licensed under CC BY-NC-SA 4.0.

Answer Key (click to show/hide answers)

Heart Internal Structures:

A - Atrium (right)

B - Ventricle (right)

C - Tricuspid/Right AV valve

D - Pectinate muscle

E - Pulmonary semilunar valve

F - Auricle (left)

G - Chordae tendineae

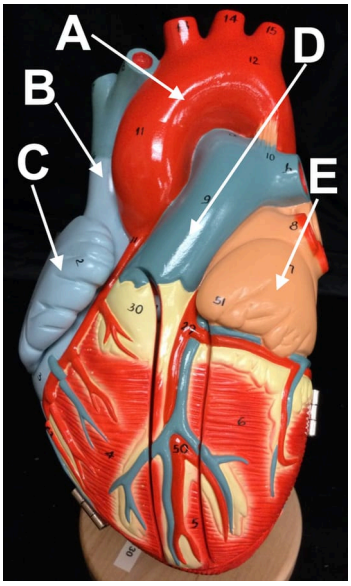

Image Credit

"Heart Model 5" by Jennifer Lange is licensed under CC BY-NC-SA 4.0.

Answer Key (click to show/hide answers)

Cardiac External Structures:

A - Aorta

B - Superior Vena Cava (SVC)

C - Auricle (right)

D - Pulmonary trunk

E - Auricle (left)

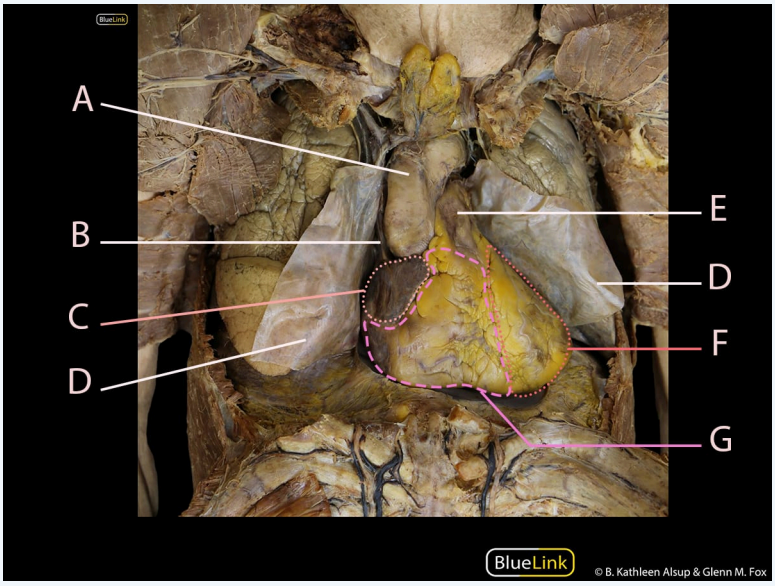

Image Credit

"UL Heart 2" by BlueLink is licensed under CC BY-NC 4.0 with notification of the original authors. Labeling by Jennifer Lange.

Answer Key (click to show/hide answers)

A - Aorta

B - Superior Vena Cava (SVC)

C - Right Atrium

D - Pericardium

E - Pulmonary Trunk

F - Left Ventricle

G - Right Ventricle

This page titled 17.6: Anatomical Atlas - Heart is shared under a CC BY-NC-SA 4.0 license and was authored, remixed, and/or curated by Jennifer Lange et al..

17.7: Practice Practical- Heart

Please answer the following questions by writing your answer on the space provided.

Query 17.7.1

This interactive element is not available in this format. Visit the link or scan the QR code to access it online.

View this Interactive Content online

Query 17.7.1

This interactive element is not available in this format. Visit the link or scan the QR code to access it online.

View this Interactive Content online

Query 17.7.1

This interactive element is not available in this format. Visit the link or scan the QR code to access it online.

View this Interactive Content online

Query 17.7.1

This interactive element is not available in this format. Visit the link or scan the QR code to access it online.

View this Interactive Content online

Query 17.7.1

This interactive element is not available in this format. Visit the link or scan the QR code to access it online.

View this Interactive Content online

Query 17.7.1

This interactive element is not available in this format. Visit the link or scan the QR code to access it online.

View this Interactive Content online

Query 17.7.1

This interactive element is not available in this format. Visit the link or scan the QR code to access it online.

View this Interactive Content online

Query 17.7.1

This interactive element is not available in this format. Visit the link or scan the QR code to access it online.

View this Interactive Content online

Query 17.7.1

This interactive element is not available in this format. Visit the link or scan the QR code to access it online.

View this Interactive Content online

Query 17.7.1

This interactive element is not available in this format. Visit the link or scan the QR code to access it online.

View this Interactive Content online

Query 17.7.1

This interactive element is not available in this format. Visit the link or scan the QR code to access it online.

View this Interactive Content online

Query 17.7.1

This interactive element is not available in this format. Visit the link or scan the QR code to access it online.

View this Interactive Content online

This page titled 17.7: Practice Practical- Heart is shared under a CC BY-NC-SA 4.0 license and was authored, remixed, and/or curated by Jennifer Lange et al..

18: CARDIOVASCULAR SYSTEM - BLOOD VESSELS

18.1: Introduction to Blood Vessels and Circulation
18.2: Structure and Function of Blood Vessels
18.3: Circulatory Pathways
18.4: Development of Blood Vessels and Fetal Circulation
18.5: Anatomical Atlas - Blood Vessels and Circulation
18.6: Practice Practical- Blood Vessels and Circulation

This page titled 18: Cardiovascular System - Blood Vessels is shared under a CC BY-NC-SA 4.0 license and was authored, remixed, and/or curated by Jennifer Lange et al..

18.1: Introduction to Blood Vessels and Circulation

Chapter Learning Objectives:

After studying this chapter, you will be able to:

- Compare and contrast the anatomical structure of arteries, arterioles, capillaries, venules, and veins
- Describe how blood flow, blood pressure, and resistance interrelate
- Describe the interaction of the cardiovascular system with other body systems
- Label the major blood vessels of the pulmonary and systemic circulations
- Identify and describe the hepatic portal system
- Describe the development of blood vessels and fetal circulation
- Compare fetal circulation to that of an individual after birth

Figure 18.1.1: Blood Vessels. While most blood vessels are located deep from the surface and are not visible, the superficial veins of the upper limb provide an indication of the extent, prominence, and importance of these structures to the body. In some individuals, contraction of the forearm muscles by squeezing a fist may cause the larger superficial veins to distend such that they are more prominent and easily located. (Image credit: "Arm veins" by Colin Davis is licensed under CC BY 2.0)

In this chapter, you will learn about the vascular part of the cardiovascular system, that is, the vessels that transport blood throughout the body and provide the physical site where gases, nutrients, and other substances are exchanged with body cells. When vessel functioning is reduced, blood-borne substances do not circulate effectively throughout the body. As a result, tissue injury occurs, metabolism is impaired, and the functions of every body system are threatened.

Contributors and Attributions

- OpenStax Anatomy & Physiology (CC BY 4.0). Access for free at https://openstax.org/books/anatomy-and-physiology

This page titled 18.1: Introduction to Blood Vessels and Circulation is shared under a CC BY-NC-SA 4.0 license and was authored, remixed, and/or curated by Jennifer Lange et al..

- 18.1: Introduction to Blood Vessels and Circulation by Whitney Menefee, Julie Jenks, Chiara Mazzasette, and Kim-Leiloni Nguyen is licensed CC BY 4.0.

18.2: Structure and Function of Blood Vessels

By the end of this section, you will be able to:

- Compare and contrast the three tunics that make up the walls of most blood vessels
- Distinguish between elastic arteries, muscular arteries, and arterioles on the basis of structure, location, and function
- Compare and contrast the three types of capillaries on the basis of structure, location, and function
- Describe the basic structure of a capillary bed, from the supplying metarteriole to the venule into which it drains
- Compare and contrast veins and venules on the basis of structure, location, and function
- Discuss factors affecting blood flow in the venous system

Blood is carried through the body via blood vessels. An artery is a blood vessel that carries blood away from the heart, where it branches into ever-smaller vessels. Eventually, the smallest arteries, vessels called arterioles, further branch into tiny capillaries, where nutrients and wastes are exchanged, and then combine with other vessels that exit capillaries to form venules, small blood vessels that carry blood to a vein, a larger blood vessel that returns blood to the heart.

Blood flow is the movement of blood through a vessel, tissue, or organ. The slowing or blocking of blood flow is called resistance. **Blood pressure** is the force that blood exerts upon the walls of the blood vessels or chambers of the heart. The components of blood pressure include systolic pressure, which results from ventricular contraction, and diastolic pressure, which results from ventricular relaxation. Pulse, the expansion and recoiling of an artery, reflects the heartbeat. In the arterial system, vasodilation and vasoconstriction of the arterioles is a significant factor in systemic blood pressure: slight vasodilation greatly decreases resistance and increases flow, whereas slight vasoconstriction greatly increases resistance and decreases flow. In the arterial system, as resistance increases, blood pressure increases and flow decreases. In the venous system, constriction increases blood pressure as it does in arteries; the increasing pressure helps to return blood to the heart. In addition, constriction causes the vessel lumen to become more rounded, decreasing resistance and increasing blood flow.

Arteries and veins transport blood in two distinct circuits: the systemic circuit and the pulmonary circuit (Figure 18.2.1). The systemic circuit begins in the left atrium of the heart and ends in the venae cavae and coronary sinus that drain into the right atrium. Systemic arteries provide blood rich in oxygen to the body's tissues; this blood is often referred to as oxygenated blood. The blood returned to the heart through systemic veins has less oxygen, since much of the oxygen carried by the arteries has been delivered to the cells; this blood is often referred to as deoxygenated blood. In contrast, the pulmonary circuit begins in the right atrium and ends in the pulmonary veins that drain into the left atrium. Pulmonary arteries carry blood low in oxygen exclusively to the lungs for gas exchange. Pulmonary veins then return freshly oxygenated blood from the lungs to the heart to be pumped back out into systemic circulation. Although arteries and veins differ structurally and functionally, they share certain features.

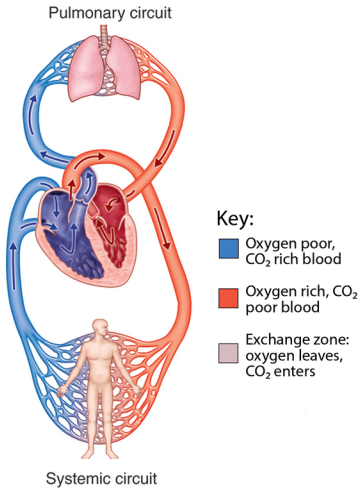

Figure 18.2.1: Cardiovascular Circulation in Pulmonary and Systemic Circuits. The pulmonary circuit moves blood from the heart to the lungs and back to the heart. The systemic circuit moves blood from the heart to the body and returns it to the heart. Within the lungs and the body regions are capillary beds where oxygen and carbon dioxide are exchanged. *(Image Credit: "Systemic and Pulmonary Circuits" by Jennifer Lange is licensed under CC BY-NC-SA 4.0, modification of original by Open Learning Initiative.)*

Structural Characteristics of Blood Vessels

Blood Vessel Tunics

Different types of blood vessels vary slightly in their structures, but they share the same general features. Arteries and arterioles have thicker walls than veins and venules because they are closer to the heart and receive blood that is surging at a far greater pressure (Figure 18.2.2). Each type of vessel has a **lumen**—a hollow passageway through which blood flows. Arteries have smaller lumens than veins, a characteristic that helps to maintain the pressure of blood moving through the system. Together, their thicker walls and smaller diameters give arterial lumens a more rounded appearance in cross section than the lumens of veins.

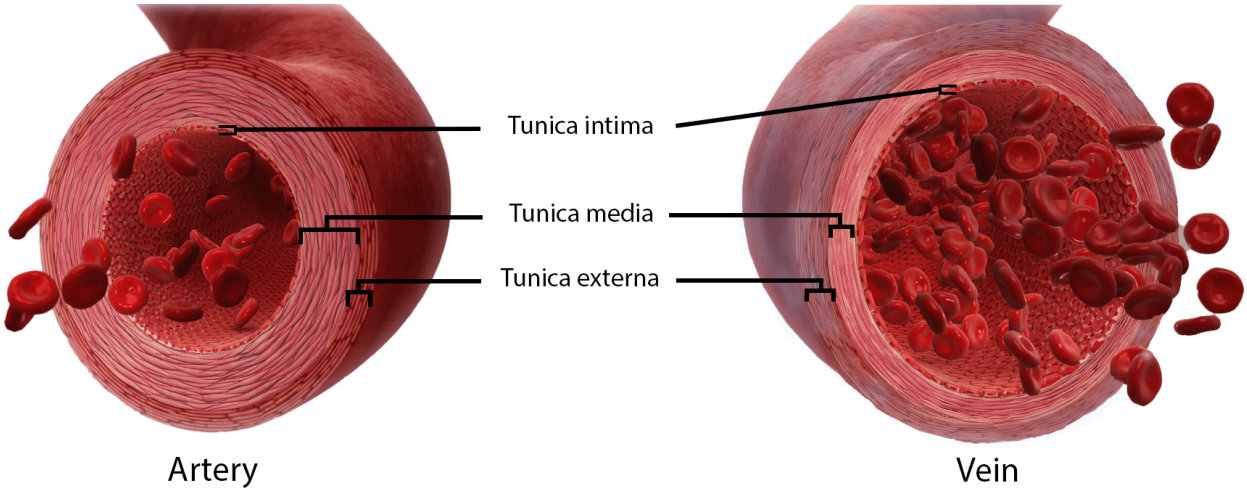

Figure 18.2.2: Structure of Blood Vessels. The walls of arteries and veins share the same general features, but the muscular layer of arteries is much thicker because of the higher pressure of the blood that flows through them. *(Image Credit: "Tunics of Arteries and Veins" by Jennifer Lange is licensed under CC BY-NC-SA 4.0, modification of original by Scientific Animations.)*

By the time blood has passed through capillaries and entered venules, the pressure initially exerted upon it by heart contractions has diminished. In other words, in comparison to arteries, venules and veins withstand a much lower pressure from the blood that flows through them. Their walls are considerably thinner and their lumens are correspondingly larger in diameter, allowing more

blood to flow with less vessel resistance. In addition, many veins of the body, particularly those of the limbs, contain valves that assist the unidirectional flow of blood toward the heart. This is critical because blood flow becomes sluggish in the extremities, as a result of the lower pressure and the effects of gravity.

Both arteries and veins have the same three distinct tissue layers, called tunics (from the Latin term tunica, for the garments first worn by ancient Romans). From the most interior layer to the outer, these tunics are the **tunica intima**, the **tunica media**, and the **tunica externa** (see Figure 18.2.2 and Figure 18.2.3). Table 18.2.1 compares and contrasts the tunics of the arteries and veins.

Table** 18.2.1**: Comparison of Tunics in Arteries and Veins

Tunic (Layer)	Arteries	Veins
General Appearance	• Thick walls with small lumens • Generally appear rounded	• Thin walls with large lumens • Generally appear flattened
Tunica Intima	• Endothelium usually appears wavy due to constriction of smooth muscle • Internal elastic membrane present in larger vessels	• Endothelium appears smooth • Internal elastic membrane absent
Tunica Media	• Normally the thickest layer in arteries • Smooth muscle cells and elastic fibers predominate (the proportions of these vary with distance from the heart) • Nervi vasorum and vasa vasorum present • External elastic membrane present in larger vessels	• Normally thinner than the tunica externa • Smooth muscle cells with elastic and collagen fibers • Nervi vasorum and vasa vasorum present • External elastic membrane absent
Tunica Externa	• Normally thinner than the tunica media in all but the largest arteries • Collagen and elastic fibers • Nervi vasorum and vasa vasorum present	• Normally the thickest layer in veins • Collagen and smooth fibers predominate • Some smooth muscle fibers • Nervi vasorum and vasa vasorum present

Tunica Intima

The **tunica intima** (also called the tunica interna) is composed of epithelial and connective tissue layers. Lining the tunica intima is the specialized simple squamous epithelium called the endothelium, which is continuous throughout the entire vascular system, including the lining of the chambers of the heart. Damage to this endothelial lining and exposure of blood to the collagen fibers beneath is one of the primary causes of clot formation. Until recently, the endothelium was viewed simply as the boundary between the blood in the lumen and the walls of the vessels. Recent studies, however, have shown that it is physiologically critical to such activities as helping to regulate capillary exchange and altering blood flow.

Next to the endothelium is the basement membrane, or basal lamina, that effectively binds the endothelium to the connective tissue. The basement membrane provides strength while maintaining flexibility, and it is permeable, allowing materials to pass through it. The thin outer layer of the tunica intima contains a small amount of areolar connective tissue that consists primarily of elastic fibers to provide the vessel with additional flexibility; it also contains some collagen fibers to provide additional strength.

In larger arteries, there is also a thick, distinct layer of elastic connective tissue known as the **internal elastic lamina** (also called the internal elastic membrane) at the boundary with the tunica media. Like the other components of the tunica intima, the internal

elastic membrane provides structure while allowing the vessel to stretch. It is permeated with small openings that allow exchange of materials between the tunics. The internal elastic membrane is not apparent in veins. In addition, many veins, particularly in the lower limbs, contain one-way valves formed by sections of thickened endothelium that are reinforced with connective tissue, extending into the lumen.

Under the microscope, the lumen and the entire tunica intima of a vein will appear smooth, whereas those of an artery will normally appear wavy because of the partial constriction of the smooth muscle in the tunica media, the next layer of blood vessel walls (Figure 18.2.3).

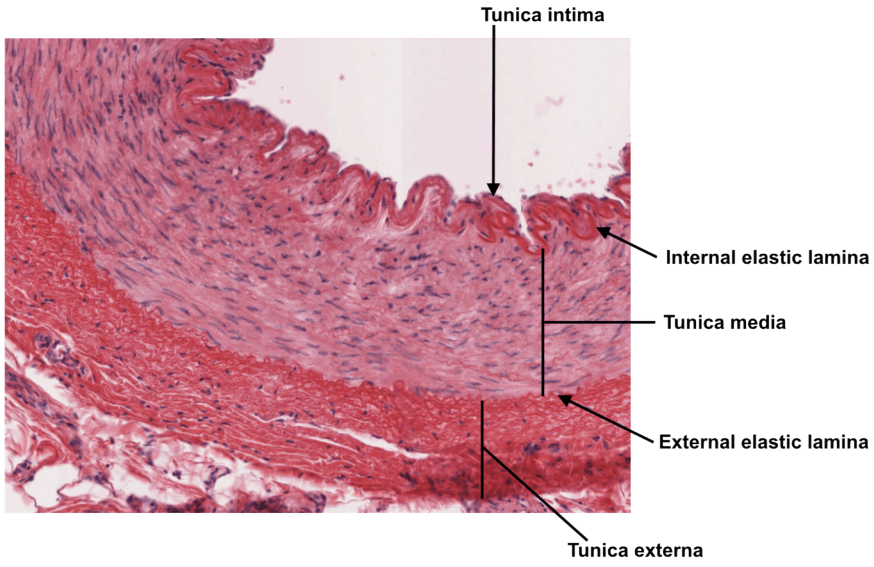

Figure 18.2.3: Histology of Blood Vessel Tunics: Artery. This vessel can be identified as an artery because it has a thick tunica media and the tunica intima appears wavy. *(Image credit: "Blood Vessel Tunics Histology" by Jennifer Lange is licensed under CC BY-NC-SA 4.0, slide provided by the Regents of the University of Michigan Medical School.)*

Tunica Media

The **tunica media** is the substantial middle layer of the vessel wall (see Figure 18.2.2 and Figure 18.2.3). It is generally the thickest layer in arteries, and it is much thicker in arteries than it is in veins. The tunica media consists of layers of circular smooth muscle supported by elastic fibers and collagen fibers. Contraction and relaxation of the circular muscles decrease and increase the diameter of the vessel lumen, respectively. Specifically in arteries, **vasoconstriction** decreases blood flow as the smooth muscle in the walls of the tunica media contracts, making the lumen narrower and increasing blood pressure. Similarly, **vasodilation** increases blood flow as the smooth muscle relaxes, allowing the lumen to widen and blood pressure to drop. Both vasoconstriction and vasodilation are regulated in part by small nerves that run within the walls of blood vessels. Neural and chemical mechanisms reduce or increase blood flow in response to changing body conditions, from exercise to hydration.

In some arteries a second elastic connective tissue layer, in addition to the internal elastic lamina, is present at the junction of the tunica media and tunica externa. This is the **external elastic lamina**.

Tunica Externa

The outer tunic, the **tunica externa** (also called the tunica adventitia), is a substantial sheath of dense irregular connective tissue with varying amounts of elastic and collagen fibers (see Figure 18.2.2 and Figure 18.2.2). The fibers are densely packed close to the tunica media, but become more spread out toward the periphery of the vessel. The outer layers of the tunica externa are not distinct but rather blend with the surrounding connective tissue outside the vessel, helping to hold the vessel in relative position. This is normally the thickest tunic in veins and may be thicker than the tunica media in some larger arteries. If you are able to palpate some of the superficial veins on your upper limbs and try to move them, you will find that the tunica externa prevents this. If the tunica externa did not hold the vessel in place, any movement would likely result in disruption of blood flow.

Arterial Structure

An **artery** is a blood vessel that conducts blood away from the heart. All arteries have relatively thick walls that can withstand the high pressure of blood ejected from the heart. However, those close to the heart have the thickest walls, containing a high percentage of elastic fibers in all three of their tunics. This type of artery is known as an **elastic artery** (Figure 18.2.4). Vessels larger than 10 mm in diameter are typically elastic. Their abundant elastic fibers allow them to expand, as blood pumped from the ventricles passes through them, and then to recoil after the surge has passed. If artery walls were rigid and unable to expand and recoil, their resistance to blood flow would greatly increase and blood pressure would rise to even higher levels, which would in turn require the heart to pump harder to increase the volume of blood expelled by each pump and maintain adequate pressure and flow. Artery walls would have to become even thicker in response to this increased pressure. The elastic recoil of the vascular wall helps to maintain the pressure gradient that drives the blood through the arterial system. An elastic artery is also known as a conducting artery, because the large diameter of the lumen gives it a low resistance and enables it to accept a large volume of blood from the heart which is conducted to smaller branches within regions of the body.

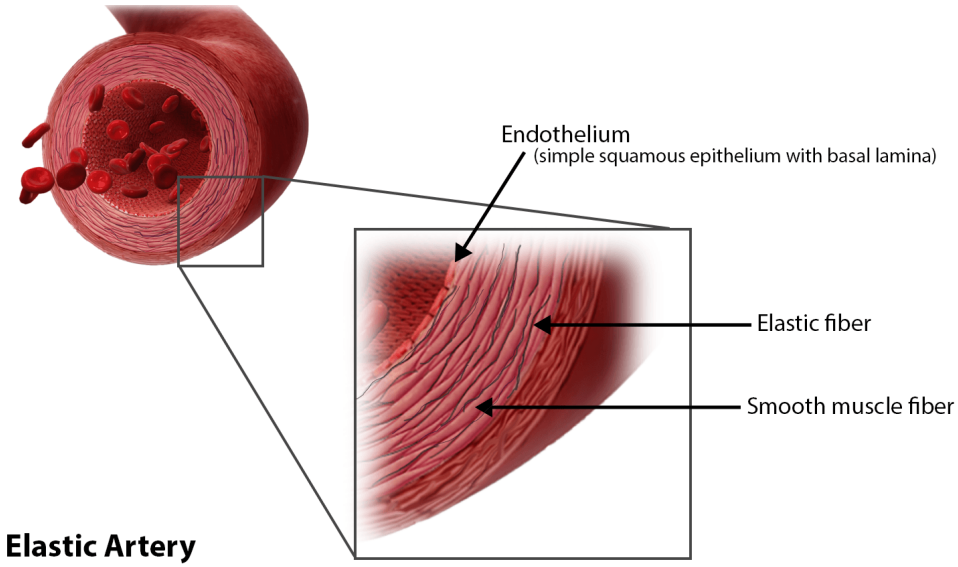

Figure 18.2.4: Elastic Artery. Elastic arteries have elastic fibers throughout their tunica media. *(Image Credit: "Elastic Artery" by Jennifer Lange is licensed under CC BY-NC-SA 4.0, modification of original by Scientific Animations.)*

Farther from the heart, where the surge of blood has dampened, the percentage of elastic fibers in an artery's tunica media decreases and becomes restricted to two thin bands, one on each side of the tunic. The layer between the tunica intima and tunica media is the **internal elastic lamina** while the layer between the tunica media and tunica externa is the **external elastic lamina**. The artery at this point is described as a **muscular artery** (Figure 18.2.5). The diameter of muscular arteries typically ranges from 0.1 mm to 10 mm. Their thick tunica media allows muscular arteries to play a leading role in vasoconstriction which controls blood flow to individual organs. In contrast, their decreased quantity of elastic fibers limits their ability to expand. Fortunately, because the blood pressure has eased by the time it reaches these more distant vessels, elasticity has become less important.

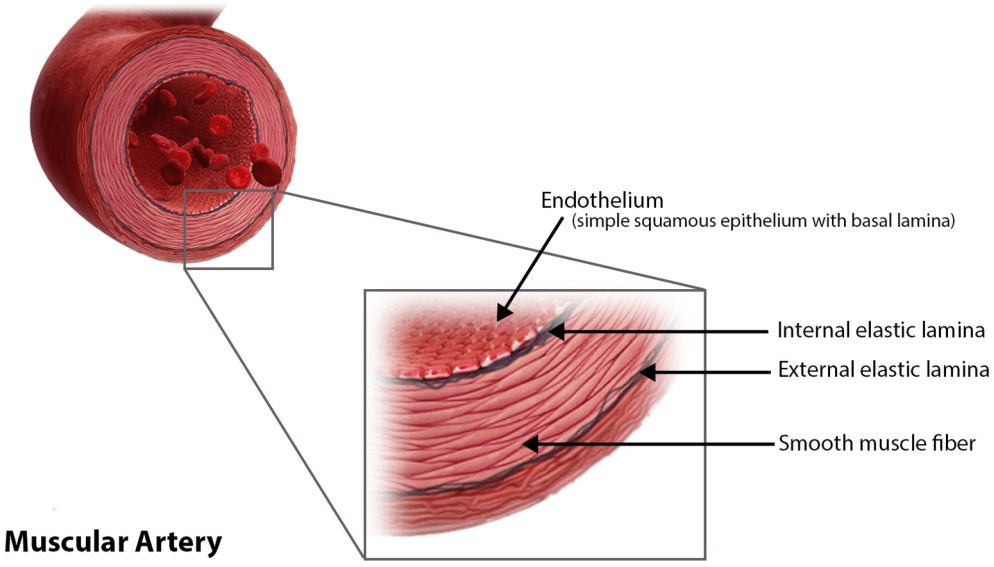

Figure 18.2.5: Muscular Artery. Muscular arteries have elastic fibers in two elastic laminae, one on each side of the tunica media. *(Image Credit: "Muscular Artery" by Jennifer Lange is licensed under CC BY-NC-SA 4.0, modification of original by Scientific Animations.)*

Notice that although the distinctions between elastic and muscular arteries are important, there is no "line of demarcation" where an elastic artery suddenly becomes muscular. Rather, there is a gradual transition as the vascular tree repeatedly branches. In turn, muscular arteries branch to distribute blood to the vast network of arterioles that deliver blood to capillaries within specific organs and tissues. For this reason, a muscular artery is also known as a distributing artery.

Arteriole Structure

An **arteriole** is a very small artery that leads to a capillary. Arterioles have the same three tunics as the larger vessels, but the thickness of each is greatly diminished. The critical endothelial lining of the tunica intima is intact. The tunica media is restricted to one or two smooth muscle cell layers in thickness. The tunica externa remains but is very thin as arterioles are supported and held in place by their positioning within organs and tissues (see Figure 18.2.6). At the distal end of arterioles the tunica externa may be absent.

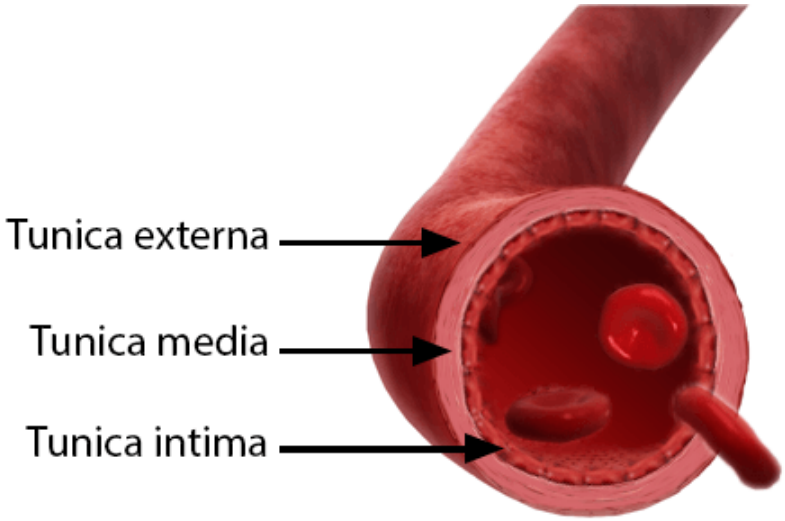

Figure 18.2.6: Arteriole. Arterioles have a much thinner wall and almost no tunica externa. *(Image Credit: "Arteriole" by Jennifer Lange is licensed under CC BY-NC-SA 4.0, modification of original by Scientific Animations.)*

With a lumen averaging 30 micrometers or less in diameter, arterioles are critical in slowing down—or resisting—blood flow and,

thus, causing a substantial drop in blood pressure. Because of this, you may see them referred to as resistance vessels. The muscle fibers in arterioles are normally slightly contracted, causing arterioles to maintain a consistent muscle tone—in this case referred to as vascular tone—in a similar manner to the muscular tone of skeletal muscle. In reality, all blood vessels exhibit vascular tone due to the partial contraction of smooth muscle. The importance of the arterioles is that they will be the primary site of both resistance and regulation of blood pressure. The precise diameter of the lumen of an arteriole at any given moment is determined by neural and chemical controls, and vasoconstriction and vasodilation in the arterioles are the primary mechanisms for distribution of blood flow to capillary beds as well as regulation of systemic blood pressure.

DISORDERS OF THE...

Cardiovascular System: Arteriosclerosis

Compliance allows an artery to expand when blood is pumped through it from the heart, and then to recoil after the surge has passed. This helps promote blood flow. In arteriosclerosis, compliance is reduced, and pressure and resistance within the vessel increase. This is a leading cause of hypertension and coronary heart disease, as it causes the heart to work harder to generate a pressure great enough to overcome the resistance.

Arteriosclerosis begins with injury to the endothelium of an artery, which may be caused by irritation from high blood glucose, infection, tobacco use, excessive blood lipids, and other factors. Artery walls that are constantly stressed by blood flowing at high pressure are also more likely to be injured—which means that hypertension can promote arteriosclerosis, as well as result from it.

Recall that tissue injury causes inflammation. As inflammation spreads into the artery wall, it weakens and scars it, leaving it stiff (sclerotic). As a result, compliance is reduced. Moreover, circulating triglycerides and cholesterol can seep between the damaged lining cells and become trapped within the artery wall, where they are frequently joined by leukocytes, calcium, and cellular debris. Eventually, this buildup, called plaque, can narrow arteries enough to impair blood flow. The term for this condition, atherosclerosis (athero- = “porridge”) describes the mealy deposits (Figure 18.2.7).

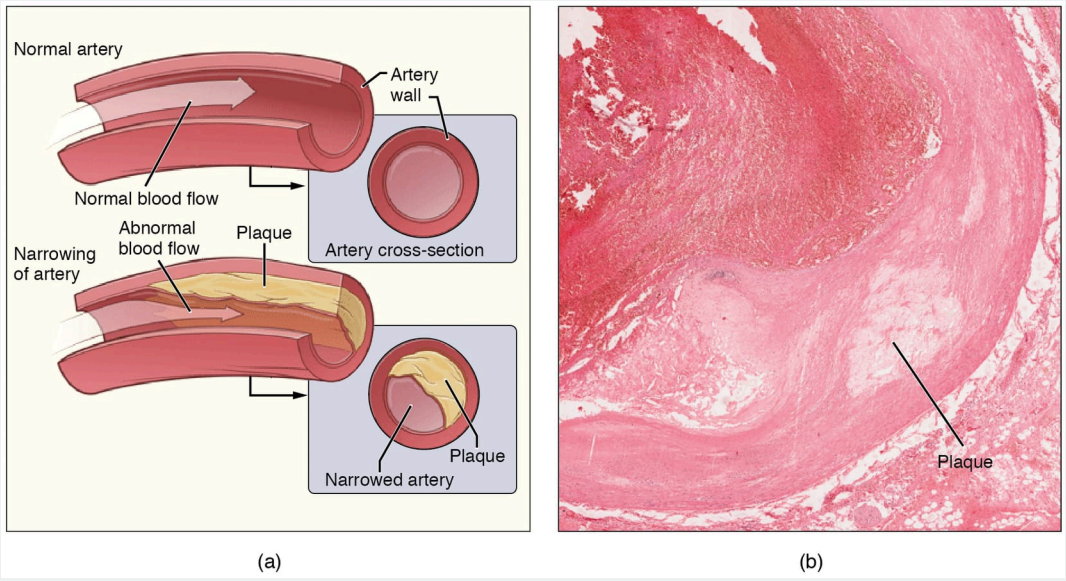

Figure 18.2.7: Atherosclerosis. (a) Atherosclerosis can result from plaques formed by the buildup of fatty, calcified deposits in an artery. (b) Plaques can also take other forms, as shown in this micrograph of a coronary artery that has a buildup of connective tissue within the artery wall. LM × 40. (Image credit: "Atherosclerosis" by OpenStax is licensed under CC BY 3.0; Micrograph provided by the Regents of University of Michigan Medical School © 2012)

Sometimes a plaque can rupture, causing microscopic tears in the artery wall that allow blood to leak into the tissue on the other side. When this happens, platelets rush to the site to clot the blood. This clot can further obstruct the artery and—if it occurs in a coronary or cerebral artery—cause a sudden heart attack or stroke. Alternatively, plaque can break off and travel through the bloodstream as an embolus until it blocks a more distant, smaller artery.

Even without total blockage, vessel narrowing leads to ischemia—reduced blood flow—to the tissue region “downstream” of the narrowed vessel. Ischemia in turn leads to hypoxia—decreased supply of oxygen to the tissues. Hypoxia involving cardiac muscle or brain tissue can lead to cell death and severe impairment of brain or heart function.

A major risk factor for both arteriosclerosis and atherosclerosis is advanced age, as the conditions tend to progress over time. Arteriosclerosis is normally defined as the more generalized loss of compliance, “hardening of the arteries,” whereas atherosclerosis is a more specific term for the build-up of plaque in the walls of the vessel and is a specific type of arteriosclerosis. There is also a distinct genetic component, and pre-existing hypertension and/or diabetes also greatly increase the risk. However, obesity, poor nutrition, lack of physical activity, and tobacco use all are major risk factors.

Treatment includes lifestyle changes, such as weight loss, smoking cessation, regular exercise, and adoption of a diet low in sodium and saturated fats. Medications to reduce cholesterol and blood pressure may be prescribed. For blocked coronary arteries, surgery is warranted. In angioplasty, a catheter is inserted into the vessel at the point of narrowing, and a second catheter with a balloon-like tip is inflated to widen the opening. To prevent subsequent collapse of the vessel, a small mesh tube called a stent is often inserted. In an endarterectomy, plaque is surgically removed from the walls of a vessel. This operation is typically performed on the carotid arteries of the neck, which are a prime source of oxygenated blood for the brain. In a coronary bypass procedure, a non-vital superficial vessel from another part of the body (often the great saphenous vein) or a synthetic vessel is inserted to create a path around the blocked area of a coronary artery.

Capillary Structure

A **capillary** is a microscopic channel that supplies blood to the tissues, through a process called **perfusion**. Exchange of gases and other substances occurs in the capillaries between the blood and the surrounding cells and their tissue fluid (interstitial fluid). The diameter of a capillary lumen ranges from 5–10 micrometers; the smallest are just barely wide enough for an erythrocyte to squeeze through. Flow through capillaries is often described as **microcirculation**.

The wall of a capillary consists of the endothelial layer surrounded by a basement membrane with occasional smooth muscle fibers. Some variation in wall structure is seen depending on the size of the capillary. In a large capillary, several endothelial cells bordering each other may line the lumen, while in a small capillary, there may be only a single cell layer that wraps around to contact itself.

For capillaries to function, their walls must be leaky, or **permeable**, allowing some substances to pass through. There are three major types of capillaries, which differ according to their degree of permeability: continuous, fenestrated, and sinusoid capillaries (Figure 18.2.8).

Continuous Capillaries

The most common type of capillary, the **continuous capillary**, is found in almost all vascularized tissues. Continuous capillaries are characterized by a complete endothelial lining with tight junctions between endothelial cells. Although a tight junction is usually impermeable and only allows for the passage of water and ions, they are often incomplete in capillaries, leaving intercellular clefts that allow for exchange of water and other very small molecules between the blood plasma and the interstitial fluid. Substances that can pass between cells include metabolic products, such as glucose, water, and small hydrophobic molecules like gases and hormones, as well as various leukocytes. Continuous capillaries not associated with the brain are rich in transport vesicles, contributing to either endocytosis or exocytosis. Those in the brain are part of the blood-brain barrier. Here, there are tight junctions and no intercellular clefts, plus a thick basement membrane and astrocyte extensions called end feet; these structures combine to prevent the movement of nearly all substances.

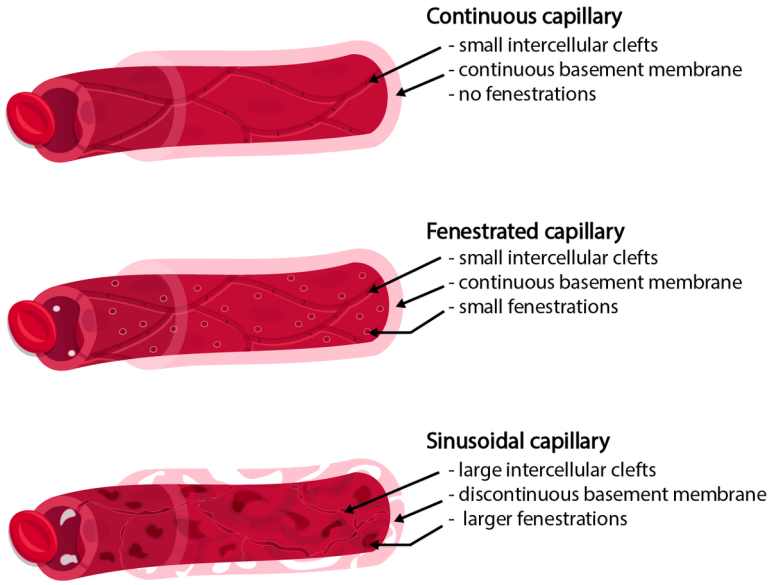

Figure 18.2.8: *Structure of different capillaries. The walls of different capillaries are compared. (Image Credit: "Types of Capillaries" by Jennifer Lange is licensed under CC BY-NC-SA 4.0, modification of original by Kelvinsong, CC BY-SA 3.0, via Wikimedia Commons.)*

Fenestrated Capillaries

A **fenestrated capillary** is one that has pores (or fenestrations) in addition to tight junctions in the endothelial lining. These make the capillary permeable to larger molecules. The number of fenestrations and their degree of permeability vary according to their location. Fenestrated capillaries are common in the small intestine, which is the primary site of nutrient absorption, as well as in the kidneys, which filter the blood. They are also found in the choroid plexus of the brain and many endocrine structures, including the hypothalamus, pituitary, pineal, and thyroid glands.

Sinusoid Capillaries

A **sinusoid capillary** (or sinusoid) is the least common type of capillary and the most permeable. Sinusoid capillaries are flattened, and they have extensive intercellular gaps and incomplete basement membranes, in addition to intercellular clefts and fenestrations. This gives them an appearance similar to Swiss cheese. These very large openings allow for the passage of the largest molecules, including plasma proteins and even cells. Blood flow through sinusoids is very slow, allowing more time for exchange of gases, nutrients, and wastes. Sinusoids are found in the liver and spleen, bone marrow, lymph nodes (where they carry lymph, not blood), and many endocrine glands including the pituitary and adrenal glands. Without these specialized capillaries, these organs would not be able to provide their myriad functions. For example, when bone marrow forms new blood cells, the cells must enter the blood supply and can only do so through the large openings of a sinusoid capillary; they cannot pass through the small openings of continuous or fenestrated capillaries. The liver also requires extensive specialized sinusoid capillaries in order to process the materials brought to it by the hepatic portal vein from both the digestive tract and spleen, and to release plasma proteins into circulation.

Metarterioles and Capillary Beds

A **metarteriole** is a type of vessel that has structural characteristics of both an arteriole and a capillary. Slightly larger than the typical capillary, the smooth muscle of the tunica media of the metarteriole is not continuous but forms rings of smooth muscle (sphincters) prior to the entrance of the capillaries. Each metarteriole arises from a terminal arteriole and branches to supply blood to a **capillary bed** that may consist of 10–100 capillaries depending on the metabolic needs of the surrounding tissues.

The **precapillary sphincters**, circular smooth muscle cells that surround the capillary at its origin with the metarteriole, tightly regulate the flow of blood from a metarteriole to the capillaries it supplies. Their function is critical: If all of the capillary beds in the body were to open simultaneously, they would collectively hold every drop of blood in the body and there would be none in the arteries, arterioles, venules, veins, or the heart itself. Normally, the precapillary sphincters are closed. When the surrounding tissues need oxygen and have excess waste products, the precapillary sphincters open, allowing blood to flow through and

exchange to occur before closing once more (Figure 18.2.9). If all of the precapillary sphincters in a capillary bed are closed, blood will flow from the metarteriole directly into a **thoroughfare channel** and then into the venous circulation, bypassing the capillary bed entirely. In addition, some regions contain one or more **arteriovenous anastomoses**, which can be opened to bypass the capillary bed, skipping perfusion and leading directly to the venous system.

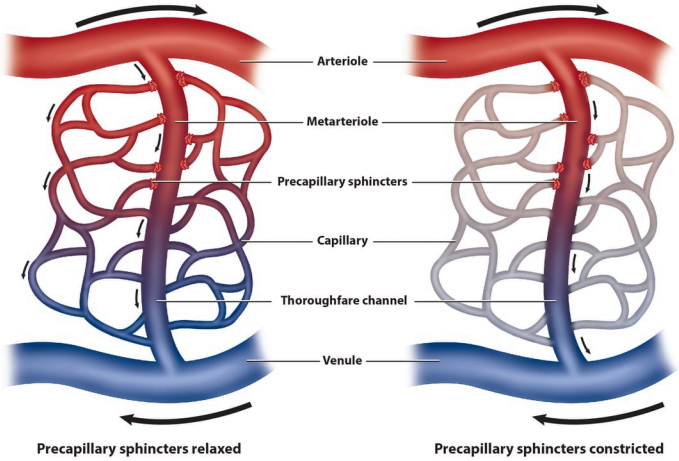

Figure 18.2.9: *Capillary network. Capillaries deliver blood to organs, these capillaries lie between arterioles (via metarterioles) and venules. (Image credit: "Microcirculation" by BlueLink is licensed under CC BY-NC 4.0 with notification of the original authors.)*

Venous System

The venous system is the system of veins in the systemic and pulmonary circulations that return blood from the tissues to the heart. In the systemic circuit the venous return is of deoxygenated blood from the organs and tissues of the body. All of the systemic veins are tributaries of the two largest veins, the superior and inferior vena cavae, that empty the oxygen-depleted blood into the right atrium of the heart. In the pulmonary circuit the pulmonary veins return oxygenated blood from the lungs to the heart.

The whole of the venous system is a large volume, low pressure system. The thin walls of the veins and their larger cross-sectional area (total luminal diameter) allow them to hold a large volume of blood, giving them the term of capacitance vessels. Veins do not have a consistent pressure generator equivalent to the heart that propels the blood in a single direction. While the blood in some veins can rely on gravity to cause movement, most work against gravity and their structure is specialized to prevent backflow and to allow for fluctuations in blood volume.

Veins vary in size from the smallest post-capillary venules, to larger venules, small veins, medium veins, and large veins. The thickness of the walls of the veins varies according to their location – in the legs the vein walls are much thicker than those in the arms - as does the number of valves present.

Venules

A **venule** is an extremely small vein, generally 8–100 micrometers in diameter. Postcapillary venules drain multiple capillaries exiting from a capillary bed. Multiple venules join to form veins. The walls of venules consist of endothelium, a thin or non-existent middle layer with a few smooth muscle cells and elastic fibers, plus an outer layer of connective tissue fibers that constitute a thin tunica externa (Figure 18.2.10). Venules as well as capillaries are the primary sites of emigration or diapedesis, in which the white blood cells adhere to the endothelial lining of the vessels and then squeeze between adjacent cells to enter the tissue fluid.

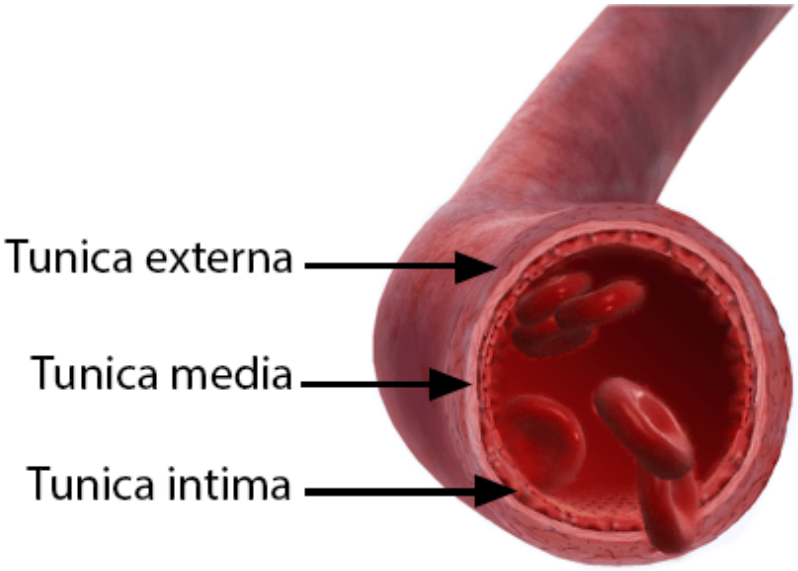

Figure 18.2.10: Venule. The wall of venules is also thin, with the tunica externa being thicker than the tunica media. *(Image Credit: "Venule" by Jennifer Lange is licensed under CC BY-NC-SA 4.0, modification of original by Scientific Animations.)*

Veins

A **vein** is a larger blood vessel that conducts blood toward the heart. Compared to arteries, veins are thin-walled vessels with large and irregular lumens (see Figure 18.2.12). Because they are low-pressure vessels, larger veins are commonly equipped with valves that promote the unidirectional flow of blood toward the heart and prevent backflow toward the capillaries caused by the inherent low blood pressure in veins as well as the pull of gravity (Figure 18.2.11).

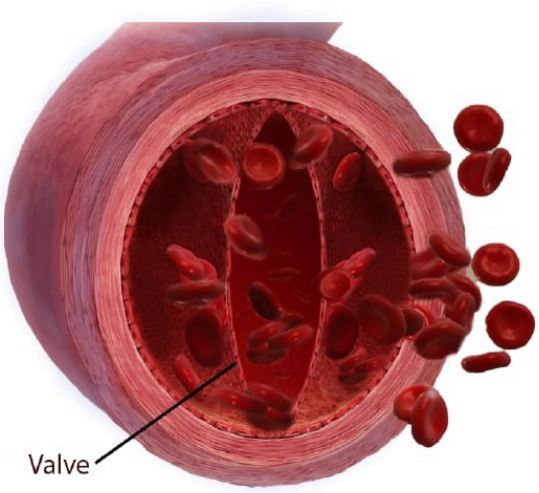

Figure 18.2.11: Vein with Valve. When pressure distal to the valve is higher than the pressure proximal to the valve the valve cusps will open and allow blood to flow toward the heart. When blood begins to flow in reverse, it will build up in the cusp pockets and cause the valve to close. This prevents further backflow. *(Image Credit: "Vein with Valve" by Jennifer Lange is licensed under CC BY-NC-SA 4.0, modification of original by Scientific Animations.)*

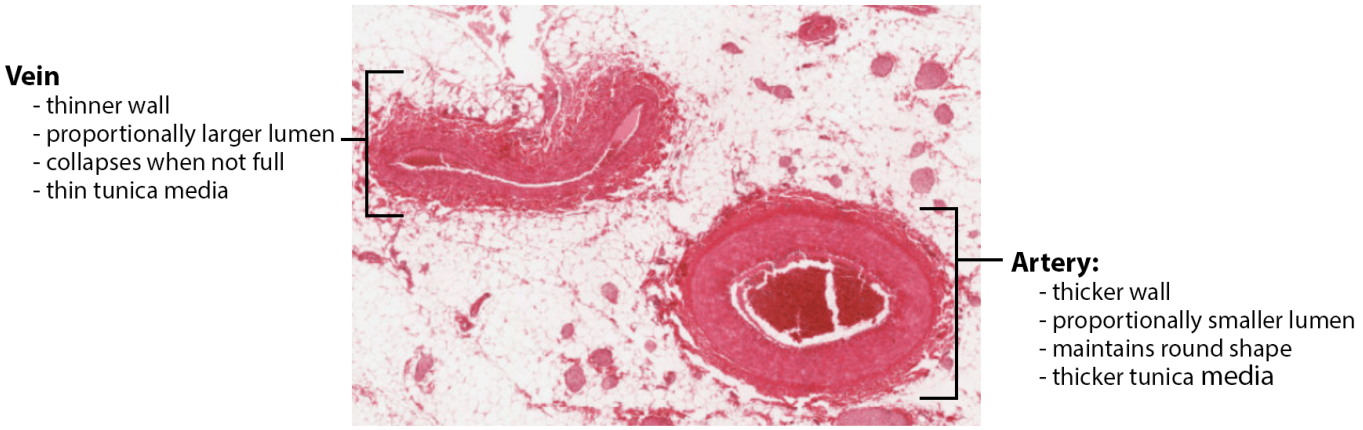

Figure 18.2.12: Small Artery and Vein. Small arteries and veins clearly demonstrate the histological differences between the two vessel types. Small veins have a thicker tunica externa and a very thin tunic media whereas small arteries have a thick tunica media and a relatively thinner tunica externa. *(Image credit: "Artery and Vein Histological Comparison" by Jennifer Lange is licensed under CC BY-NC-SA 4.0, slide provided by the Regents of the University of Michigan Medical School © 2022.)*

Skeletal Muscle Pump

The pumping action of the heart propels the blood into the arteries, from an area of higher pressure toward an area of lower pressure. If blood is to flow from the veins back into the heart, the pressure in the veins must be greater than the pressure in the atria of the heart. Two factors help maintain this pressure gradient between the veins and the heart. First, the pressure in the atria during diastole is very low, often approaching zero when the atria are relaxed (atrial diastole). Second, two physiologic "pumps" increase pressure in the venous system. The use of the term "pump" implies a physical device that speeds flow. These physiological pumps are less obvious.

In many body regions, the pressure within the veins can be increased by the contraction of the surrounding skeletal muscle. This mechanism, known as the **skeletal muscle pump** (Figure 18.2.13), helps the lower-pressure veins counteract the force of gravity, increasing pressure to move blood back to the heart. As leg muscles contract, for example during walking or running, they exert pressure on nearby veins with their numerous one-way valves. This increased pressure causes blood to flow upward, opening valves superior to the contracting muscles so blood flows through. Simultaneously, valves inferior to the contracting muscles close; thus, blood should not seep back downward toward the feet. Military recruits are trained to flex their legs slightly while standing at attention for prolonged periods. Failure to do so may allow blood to pool in the lower limbs rather than returning to the heart. Consequently, the brain will not receive enough oxygenated blood, and the individual may lose consciousness.

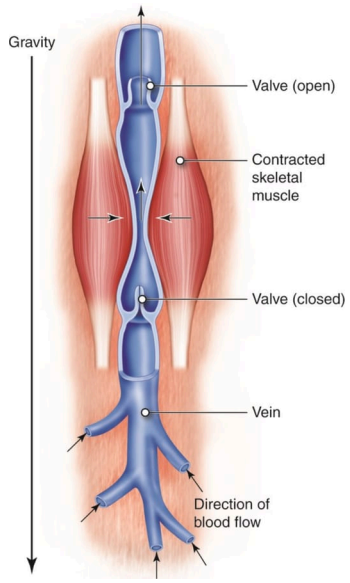

Figure 18.2.13: *Venous blood flow due to muscle contraction. Some veins are located in between muscles (e.g. in the lower extremity). When the muscles contract the pressure increases. Therefore valves will open so that blood will flow towards the heart.* (Image Credit: "KnowledgeWorks - Drawing Venous blood flow due to muscle contraction - English labels" by KnowledgeWorks Global Ltd., license: CC BY)

Respiratory Pump

The **respiratory pump** aids blood flow through the veins of the thorax and abdomen. During inhalation, the volume of the thorax increases, largely through the contraction of the diaphragm, which moves downward and compresses the abdominal cavity. The elevation of the chest caused by the contraction of the external intercostal muscles also contributes to the increased volume of the thorax. The volume increase causes air pressure within the thorax to decrease, allowing us to inhale. Additionally, as air pressure within the thorax drops, blood pressure in the thoracic veins also decreases, falling below the pressure in the abdominal veins. This causes blood to flow along its pressure gradient from veins outside the thorax, where pressure is higher, into the thoracic region, where pressure is now lower. This in turn promotes the return of blood from the thoracic veins to the atria. During exhalation, when air pressure increases within the thoracic cavity, pressure in the thoracic veins increases, speeding blood flow into the heart while valves in the veins prevent blood from flowing backward from the thoracic and abdominal veins.

DISORDERS OF THE...

Cardiovascular System: Edema and Varicose Veins

Despite the presence of valves and the contributions of other anatomical and physiological adaptations we will cover shortly, over the course of a day, some blood will inevitably pool, especially in the lower limbs, due to the pull of gravity. Any blood that accumulates in a vein will increase the pressure within it, which can then be reflected back into the smaller veins, venules, and eventually even the capillaries. Increased pressure will promote the flow of fluids out of the capillaries and into the interstitial fluid. The presence of excess tissue fluid around the cells leads to a condition called edema.

Most people experience a daily accumulation of tissue fluid, especially if they spend much of their work life on their feet (like most health professionals). However, clinical edema goes beyond normal swelling and requires medical treatment. Edema has many potential causes, including hypertension and heart failure, severe protein deficiency, renal failure, and many others. In order to treat edema, which is a sign rather than a discrete disorder, the underlying cause must be diagnosed and alleviated.

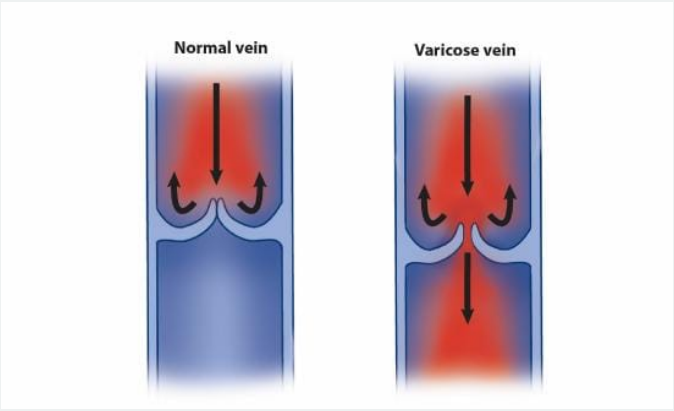

Figure 18.2.14: Varicose Veins. Varicose veins are commonly found in the superficial veins of the lower limbs. Defective valves cause localized pooling of blood in the veins that can lead to distention and deformity of the vessel appearing as lumps under the surface of the skin. *(Image credits: "Left Calf and Varicose Veins" by Thomas Kriese is licensed under CC BY 2.0; "Varicose Veins and Valves" by BlueLink is licensed under CC BY-NC 4.0 with notification of the original authors.)*

Edema may be accompanied by varicose veins, especially in the superficial veins of the legs (Figure 18.2.14). This disorder arises when defective valves allow blood to accumulate within the veins, causing them to distend, twist, and become visible on the surface of the integument. Varicose veins may occur in both sexes, but are more common in women and are often related to pregnancy. More than simple cosmetic blemishes, varicose veins are often painful and sometimes itchy or throbbing. Without treatment, they tend to grow worse over time. The use of support hose, as well as elevating the feet and legs whenever possible, may be helpful in alleviating this condition. Laser surgery and interventional radiologic procedures can reduce the size and severity of varicose veins. Severe cases may require conventional surgery to remove the damaged vessels. As there are typically redundant circulation patterns, that is, anastomoses, for the smaller and more superficial veins, removal does not typically impair the circulation. There is evidence that patients with varicose veins suffer a greater risk of developing a thrombus or clot.

Veins as Blood Reservoirs

In addition to their primary function of returning blood to the heart, veins may be considered blood reservoirs, since systemic veins contain approximately 64 percent of the blood volume at any given time (Figure 18.2.15, Table 18.2.2). Their ability to hold this much blood is due to their high **capacitance**, that is, their capacity to distend (expand) readily to store a high volume of blood, even at a low pressure. The large lumens and relatively thin walls of veins make them far more distensible than arteries; thus, they are said to be **capacitance vessels**.

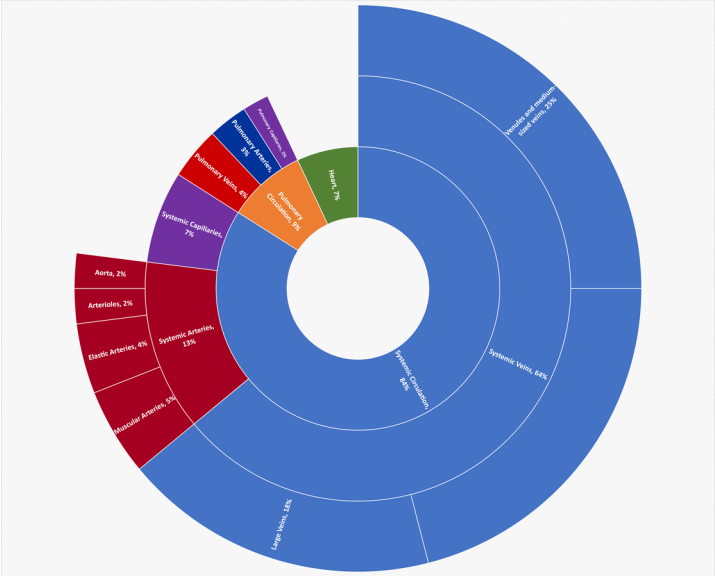

Figure 18.2.15: Graphical View of Distribution of Blood. Blood spends a higher proportion of time in systemic veins than in any other part of the cardiovascular system. This chart shows the hierarchical percentages of blood flow found within each circuit of blood flow (inner ring), within the arteries, capillaries, and veins of each circuit (middle ring), and within each specific type of systemic vessel (outer ring). The same data used to create this graphic are given in Table 18.2.2. *(Image credit: "Distribution of Blood Flow" by Julie Jenks is licensed under CC BY 4.0.)*

Table 18.2.2: Distribution of Blood

Circuit of Blood Flow	Vessel Category	Specific Vessel Type	Percentage of Blood
Systemic Circulation, 84%	Systemic Arteries, 13%	Aorta	2%
		Elastic Arteries	4%
		Muscular Arteries	5%
		Arterioles	2%
	Systemic Capillaries		7%
	Systemic Veins, 64%	Large Veins	18%
		Large venous network (liver, bone marrow, integument)	21%
		Venules and medium-sized veins	25%
Pulmonary Circulation, 9%		Pulmonary Arteries	3%
		Pulmonary Capillaries	2%
		Pulmonary Veins	4%
Heart			7%

Concept Review

Blood pumped by the heart flows through a series of vessels known as arteries, arterioles, capillaries, venules, and veins before returning to the heart. Arteries transport blood away from the heart and branch into smaller vessels, forming arterioles. Arterioles distribute blood to capillary beds, the sites of exchange with the body tissues. Capillaries lead back to small vessels known as venules that flow into the larger veins and eventually back to the heart.

Vessel Type	Diam of Ve and Thick
Elastic Artery	Diam 1.5 cn Thick 1.0 m
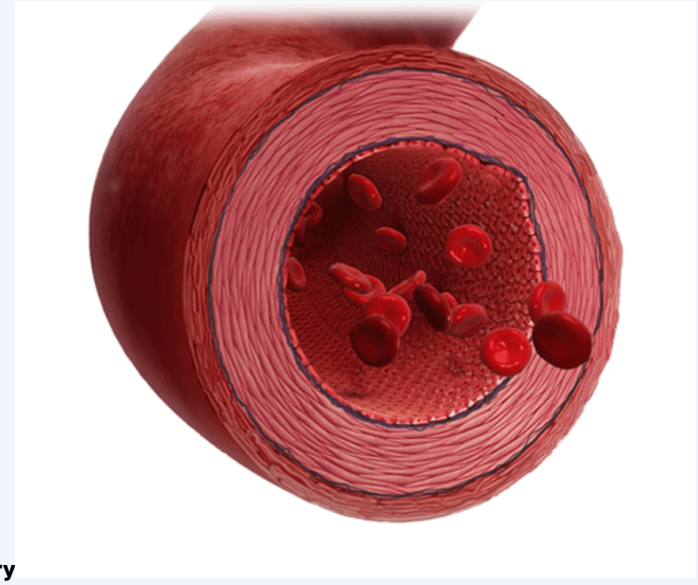 **Muscular Artery**	Diam 6.0 m Thick 1.0 m

Vessel Type	Diam of Ve and Thick
Arteriole	Diam 37.0 u Thick 1.0 ur
Capillary	Diam 9.0 ur Thick 0.5 ur

Vessel Type	Diam of Ve and Thick
Venule	Diam 20.0 Thick 1.0 ur
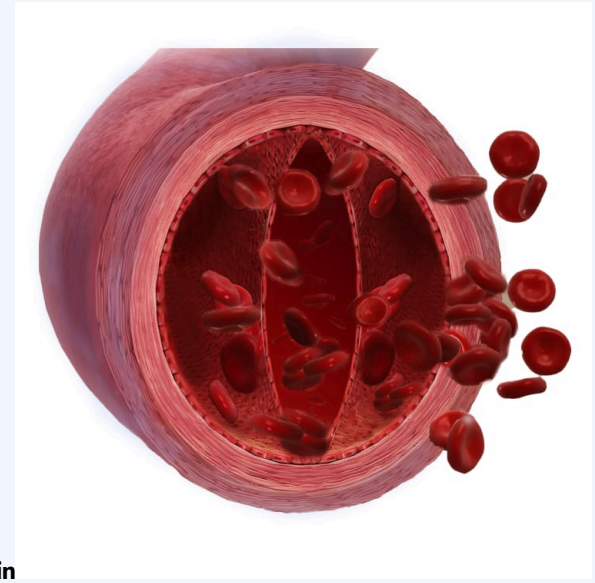 **Vein**	Diam 5.0 m Thick 0.5 m

Figure 18.2.16: Comparison of Blood Vessel Composition. A comparison of the lumen diameter (D), wall thickness (T) and structure (relative tissue makeup) of blood vessels types. *(Image Credit: Vessel images by Jennifer Lange are licensed under CC BY-NC-SA 4.0, modification of original by Scientific Animations. Graphs by Open Learning Initiative are licensed under CC BY-NC-SA.)*

Table 18.2.3: Comparison of General Features of Arteries and Veins

	Arteries	Veins
Direction of blood flow	Conducts blood away from the heart	Conducts blood toward the heart

	Arteries	Veins
General appearance	Rounded	Irregular, often collapsed
Pressure	High	Low
Wall thickness	Thick	Thin
Relative oxygen concentration	Higher in systemic arteries Lower in pulmonary arteries	Lower in systemic veins Higher in pulmonary veins
Valves	Not present	Present most commonly in limbs and in veins inferior to the heart

Arteries, arterioles, venules, and veins are composed of three tunics known as the tunica intima, tunica media, and tunica externa. The tunica intima is a thin layer composed of a simple squamous epithelium known as endothelium and a small amount of connective tissue. The tunica media is a thicker area composed of variable amounts of smooth muscle and connective tissue. It is the thickest layer in all but the largest arteries. The tunica externa is primarily a layer of connective tissue, although in veins, it also contains some smooth muscle. Blood flow through vessels can be dramatically increased or decreased by vasoconstriction and vasodilation. The arterial system is a relatively high-pressure system, so arteries have thick walls that appear round in cross section. The venous system is a lower-pressure system, containing veins that have larger lumens and thinner walls. They often appear flattened. Capillaries have only a tunica intima layer.

Review Questions

Query 18.2.1

This interactive element is not available in this format. Visit the link or scan the QR code to access it online.

View this Interactive Content online

Critical Thinking Questions

Query 18.2.2

This interactive element is not available in this format. Visit the link or scan the QR code to access it online.

View this Interactive Content online

Query 18.2.3

This interactive element is not available in this format. Visit the link or scan the QR code to access it online.

View this Interactive Content online

Glossary

Query 18.2.4

This interactive element is not available in this format. Visit the link or scan the QR code to access it online.

View this Interactive Content online

Contributors and Attributions

- OpenStax Anatomy & Physiology (CC BY 4.0). Access for free at https://openstax.org/books/anatomy-and-physiology

This page titled 18.2: Structure and Function of Blood Vessels is shared under a CC BY-NC-SA 4.0 license and was authored, remixed, and/or curated by Jennifer Lange et al..

- 18.2: Structure and Function of Blood Vessels by Whitney Menefee, Julie Jenks, Chiara Mazzasette, and Kim-Leiloni Nguyen is licensed CC BY 4.0.

18.3: Circulatory Pathways

By the end of this section, you will be able to:

- Identify the vessels through which blood travels within the pulmonary circuit, beginning from the right atrium of the heart and ending at the pulmonary vein
- Create a flow chart showing the major systemic arteries through which blood travels from the aorta and its major branches, to the most significant arteries feeding into the right and left upper and lower limbs
- Create a flow chart showing the major systemic veins through which blood travels from the feet to the right atrium of the heart

Virtually every cell, tissue, organ, and system in the body is impacted by the circulatory system. This includes the generalized and more specialized functions of transport of materials, capillary exchange, maintaining health by transporting white blood cells and various immunoglobulins (antibodies), hemostasis, regulation of body temperature, and helping to maintain acid-base balance. In addition to these shared functions, many systems enjoy a unique relationship with the circulatory system, for example blood carries the hormones for the endocrine system and both the nervous system and the skeletal system produce filtrates of the blood to make CSF and synovial fluid, respectively.

As you learn about the vessels of the systemic and pulmonary circuits, notice that many arteries and veins share the same names (Figure 18.3.1). Those with the name name run parallel to one another and are very similar on the right and left sides of the body. Where differences occur in branching patterns or when vessels are singular, this will be indicated. For example, you will find a pair of femoral arteries and a pair of femoral veins, with one vessel on each side of the body. In contrast, some vessels closer to the midline of the body, such as the aorta, are unique. Moreover, some superficial veins, such as the great saphenous vein in the femoral region, have no arterial counterpart. Another phenomenon that can make the study of vessels challenging is that names of vessels can change with location. Like a street that changes name as it passes through an intersection, an artery or vein can change names as it passes an anatomical landmark. For example, the left subclavian artery becomes the axillary artery as it passes through the body wall and into the axillary region, and then becomes the brachial artery as it flows from the axillary region into the upper arm (or brachium). You will also find examples of anastomoses where two blood vessels that previously branched reconnect. Anastomoses are especially common in veins, where they help maintain blood flow even when one vessel is blocked or narrowed, although there are some important ones in the arteries supplying the brain.

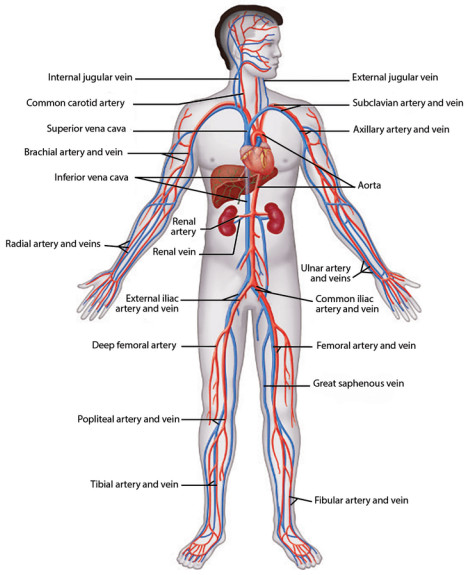

Figure 18.3.1: Large Arteries and Veins. The largest arteries and vessels in the body are depicted here. Branches of these vessels are showing in later images in this section. *(Image Credit: "C_M3_26.jpg" by Cenveo is licensed under CC BY 3.0, image from the OLI Repository, modifications by Jennifer Lange.)*

As you read about circular pathways, notice that there is an occasional, very large artery referred to as a **trunk**, a term indicating

that the vessel gives rise to several smaller arteries. For example, the celiac trunk gives rise to the left gastric, common hepatic, and splenic arteries.

As you study this section, imagine you are on a “Voyage of Discovery” similar to Lewis and Clark’s expedition in 1804–1806, which followed rivers and streams through unfamiliar territory, seeking a water route from the Atlantic to the Pacific Ocean. You might envision being inside a miniature boat, exploring the various branches of the circulatory system. This simple approach has proven effective for many students in mastering these major circulatory patterns. Another approach that works well for many students is to create simple line drawings similar to the ones provided, labeling each of the major vessels. It is beyond the scope of this text to name every vessel in the body. However, we will attempt to discuss the major pathways for blood and acquaint you with the major named arteries and veins in the body. Also, please keep in mind that individual variations in circulation patterns are not uncommon.

Pulmonary Circulation

Recall that blood returning from the systemic circuit enters the right atrium (Figure 18.3.2) via the superior and inferior venae cavae and the coronary sinus, which drains the blood supply of the heart muscle. These vessels will be described more fully later in this section. This blood is relatively low in oxygen and relatively high in carbon dioxide, since much of the oxygen has been extracted for use by the tissues and the waste gas carbon dioxide was picked up to be transported to the lungs for elimination. From the right atrium, blood moves into the right ventricle, which pumps it to the lungs for gas exchange. This system of vessels is referred to as the **pulmonary circuit**.

The single vessel exiting the right ventricle is the **pulmonary trunk**. At the base of the pulmonary trunk is the pulmonary semilunar valve, which prevents backflow of blood into the right ventricle during ventricular diastole. As the pulmonary trunk reaches the superior surface of the heart, it curves posteriorly and rapidly bifurcates (divides) into two branches, a left and a right **pulmonary artery**. To prevent confusion between these vessels, it is important to refer to the vessel exiting the heart as the pulmonary trunk, rather than also calling it a pulmonary artery. The pulmonary arteries in turn branch many times within the lung, forming a series of smaller arteries and arterioles that eventually lead to the pulmonary capillaries. The pulmonary capillaries surround lung structures known as alveoli that are the sites of oxygen and carbon dioxide exchange.

Once gas exchange is completed, oxygenated blood flows from the pulmonary capillaries into a series of pulmonary venules that eventually lead to a series of larger **pulmonary veins**. Four pulmonary veins, two on the left and two on the right, return blood to the left atrium. At this point, the pulmonary circuit is complete. Table 18.3.1 defines the major arteries and veins of the pulmonary circuit discussed in the text.

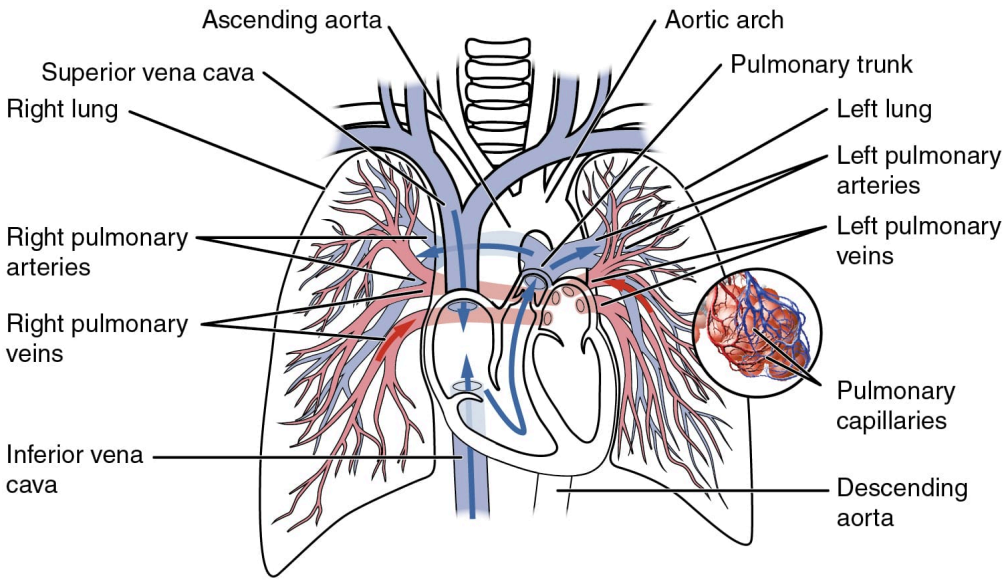

Figure 18.3.2: Pulmonary Circuit. Blood exiting from the right ventricle flows into the pulmonary trunk, which bifurcates into the two pulmonary arteries. These vessels branch to supply blood to the pulmonary capillaries, where gas exchange occurs within the lung alveoli. Blood returns via the pulmonary veins to the left atrium. (Image credit: "Pulmonary Circuit" by OpenStax is licensed under CC BY 3.0)

Table 18.3.1: Pulmonary Arteries and Veins

Vessel	Description
Pulmonary trunk	Single large vessel exiting the right ventricle that divides to form the right and left pulmonary arteries
Pulmonary arteries	Left and right vessels that form from the pulmonary trunk and lead to smaller arterioles and eventually to the pulmonary capillaries
Pulmonary veins	Two sets of paired vessels—one pair on each side—that are formed from the small venules, leading away from the pulmonary capillaries to flow into the left atrium

Overview of Systemic Arteries

Blood relatively high in oxygen concentration is returned from the pulmonary circuit to the left atrium via the four pulmonary veins. From the left atrium, blood moves into the left ventricle, which pumps blood into the aorta. The aorta and its branches—the systemic arteries—send blood to virtually every organ of the body.

The Aorta

The **aorta** is the largest artery in the body (Figure 18.3.3). It arises from the left ventricle and eventually descends to the abdominal region, where it bifurcates at the level of the fourth lumbar vertebra into the two common iliac arteries. The aorta consists of the ascending aorta, the aortic arch, and the descending aorta, which passes through the diaphragm and a landmark that divides into the superior thoracic and inferior abdominal components. Arteries originating from the aorta ultimately distribute blood to virtually all tissues of the body. At the base of the aorta is the aortic semilunar valve that prevents backflow of blood into the left ventricle while the heart is relaxing. After exiting the heart, the **ascending aorta** moves in a superior direction for approximately 5 cm and ends at the sternal angle. Following this ascent, it reverses direction, forming a graceful arc to the left, called the **aortic arch**. The aortic arch descends toward the inferior portions of the body and ends at the level of the intervertebral disk between the fourth and fifth thoracic vertebrae. Beyond this point, the **descending aorta** continues close to the bodies of the vertebrae and passes through an opening in the diaphragm known as the **aortic hiatus**. Superior to the diaphragm, the aorta is called the **thoracic aorta**, and inferior to the diaphragm, it is called the **abdominal aorta**. The abdominal aorta terminates when it bifurcates into the two common iliac arteries at the level of the fourth lumbar vertebra. See Figure 18.3.3 for an illustration of the ascending aorta, the aortic arch, and the initial segment of the descending aorta plus major branches; Table 18.3.2 summarizes the structures of the aorta.

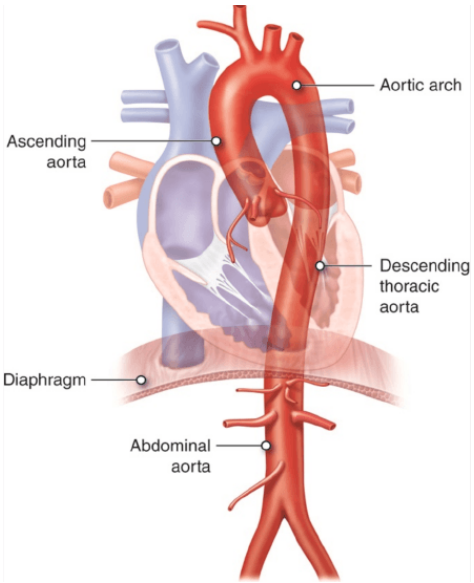

Figure 18.3.3: Parts of aorta in relation to heart and diaphragm. The ascending aorta, aortic arch, descending (thoracic) and abdominal aorta are shown. *(Image Credit: "OLI - Drawing Parts of aorta in relation to heart and diaphragm - English labels" by Open Learning Initiative, license: CC BY-NC-SA)*

Table 18.3.2: Components of the Aorta

Vessel	Description
Aorta	Largest artery in the body, originating from the left ventricle and descending to the abdominal region, where it bifurcates into the common iliac arteries at the level of the fourth lumbar vertebra; arteries originating from the aorta distribute blood to virtually all tissues of the body
Ascending aorta	Initial portion of the aorta, rising superiorly from the left ventricle for a distance of approximately 5 cm
Aortic arch	Graceful arc to the left that connects the ascending aorta to the descending aorta; ends at the intervertebral disk between the fourth and fifth thoracic vertebrae
Descending aorta	Portion of the aorta that continues inferiorly past the end of the aortic arch; subdivided into the thoracic aorta and the abdominal aorta
Thoracic aorta	Portion of the descending aorta superior to the aortic hiatus
Abdominal aorta	Portion of the aorta inferior to the aortic hiatus and superior to the common iliac arteries

Coronary Circulation

The coronary arteries and coronary veins encircle the heart, forming a "crown" of vessels that supply blood to the heart tissues. The first vessels that branch from the ascending aorta are the paired right and left coronary arteries (see Figure 18.3.4 and Figure 18.3.5), which arise from the ascending aorta just superior to the aortic semilunar valve.

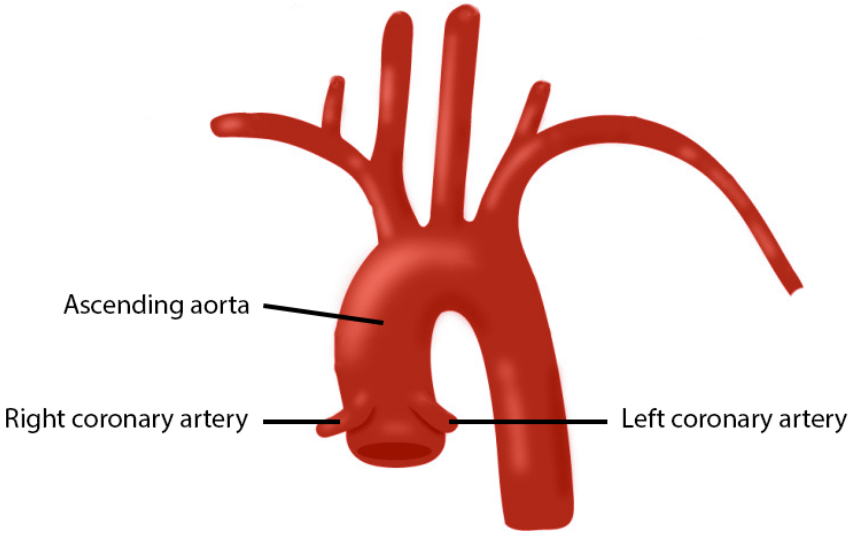

Figure 18.3.4: Aorta and Coronary Arteries. The first two arteries to branch off the the aorta are the right and left coronary arteries. The aortic arch gives rise to three large branches: the brachiocephalic artery (or trunk), the left common carotid artery, and the left subclavian artery. *(Image Credit: "Aorta and Coronary Arteries" by Jennifer Lange is licensed under CC BY-NC-SA 4.0, modification of "Palmer - Drawing Aortic arch - English labels" by Beckie Palmer, © StatPearls Publishing LLC, license: CC BY.)*

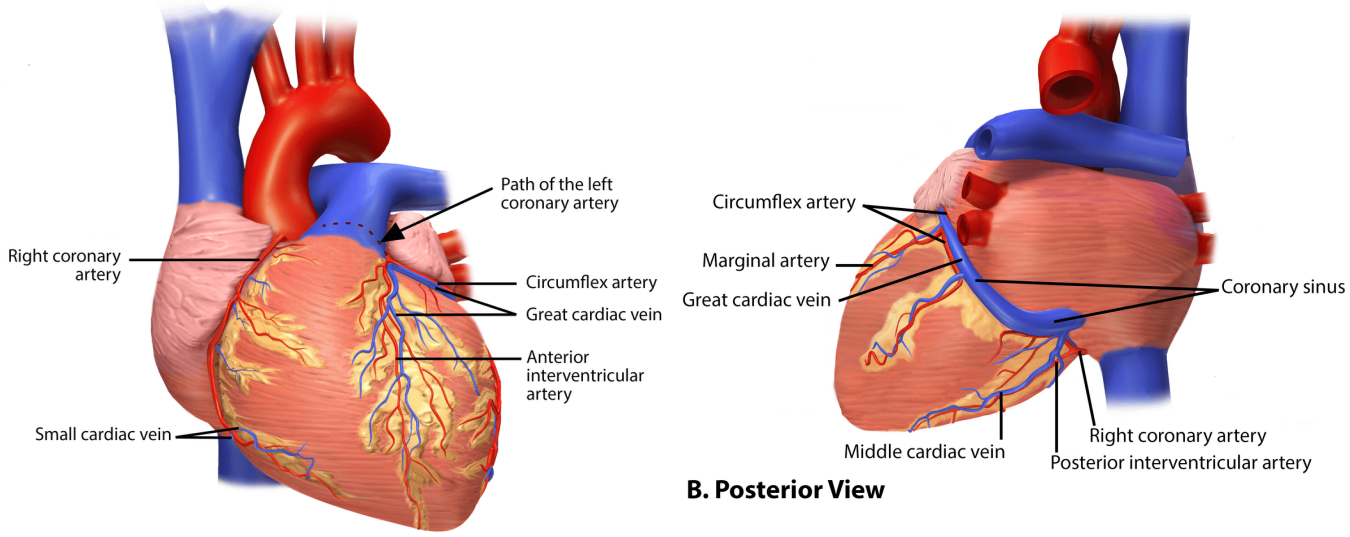

Figure 18.3.5: Coronary Circulation. The coronary vessels encircle the heart, forming a ring-like structure that divides into the next level of branches that supplies blood to the heart tissues. *(Image credit: "Coronary Vessels Anterior View" by Jennifer Lange is licensed under CC BY-NC-SA 4.0, modification of original "Blausen 0451 - Anterior view of the heart - English labels" by Blausen Medical Communications, Inc.; "Coronary Vessels Posterior View" by Jennifer Lange is licensed under under CC BY-NC-SA 4.0, modification of original "Blausen 0456 Heart Posterior" by Blausen Medical Communications, Inc.)*

The **left coronary artery** is short. It passes posterior to the pulmonary trunk and, upon emergence, splits into the **anterior interventricular artery** and the **circumflex artery**. The anterior interventricular artery travels toward the inferior margin of the heart in the anterior interventricular sulcus. The circumflex artery travels in the left atrioventricular sulcus to the posterior side of the heart. Along the way it gives off the **left marginal artery** to the lateral side of the left ventricle. The **great cardiac vein** travels first with the anterior interventricular artery and then with the circumflex artery. On the posterior surface it joins with other branches and becomes the **coronary sinus**.

The **right coronary artery** travels in the right atrioventricular sulcus to the posterior side of the heart, near the inferior vena cava. At this point it branches to give off the **posterior interventricular artery**, which travels with the **middle cardiac vein** in the posterior interventricular sulcus. The **small cardiac vein** also travels in the right atrioventricular sulcus, starting from the right margin of the right ventricle and ending at the coronary sinus.

Table 18.3.3: Coronary Circulation

Vessel	Description
Left coronary artery	It passes behind the pulmonary trunk and splits into anterior interventricular artery and circumflex artery.
Anterior interventricular artery	It travels in the anterior ventricular sulcus down to the inferior margin of the heart.
Circumflex artery	It travels in the atrioventricular sulcus to the posterior side of the heart.
Left marginal artery	A branch of artery from the circumflex artery going to the lateral side of the left ventricle
Great cardiac vein	Travels with the anterior interventricular artery and then with the circumflex artery.
Coronary sinus	Formed on the posterior surface of the heart from the joining of the great cardiac vein and other branches.
Right Coronary Artery	Goes to the posterior part of the heart via right anterior ventricular sulcus where it gives off the posterior interventricular artery.
Posterior interventricular artery	It travels with the middle cardiac vein int eh posterior interventricular sulcus.

Vessel	Description
Small cardiac vein	It travels in the right atrioventricular sulcus, from the right margin of the right ventricle to the coronary sinus.

Aortic Arch Branches

There are three major branches of the aortic arch: the brachiocephalic artery, the left common carotid artery, and the left subclavian (literally “under the clavicle”) artery. As you would expect based upon proximity to the heart, each of these vessels is classified as an elastic artery.

The **brachiocephalic artery (or trunk)** is located only on the right side of the body; there is no corresponding artery on the left. The brachiocephalic artery branches into the **right subclavian artery** and the **right common carotid artery**. The **left subclavian** and **left common carotid arteries** arise independently from the aortic arch but otherwise follow a similar pattern and distribution to the corresponding arteries on the right side (see Figure 18.3.6). Each **subclavian artery** supplies blood to the arms, chest, shoulders, back, and central nervous system.

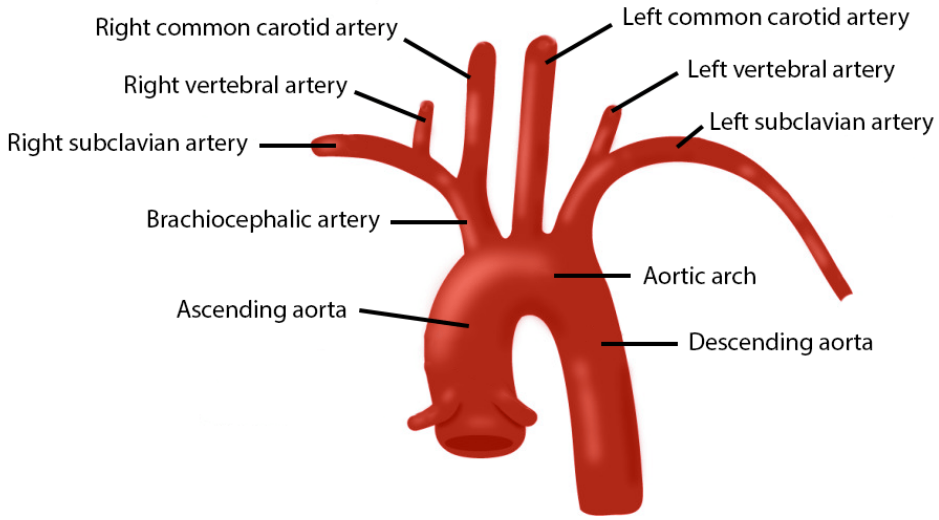

Figure 18.3.6: Branches of the Aortic Arch. The aortic arch gives rise to three large branches: the brachiocephalic artery (or trunk), the left common carotid artery, and the left subclavian artery. *(Image Credit: "Aortic Arch and Main Branches" by Jennifer Lange is licensed under CC BY-NC-SA 4.0*, modification of *"Palmer - Drawing Aortic arch - English labels" by Beckie Palmer, © StatPearls Publishing LLC, license: CC BY.)*

In the superior cervical region the **common carotid arteries** divides into internal and external carotid arteries (Figure 18.3.7). The right common carotid artery arises from the brachiocephalic artery and the left common carotid artery arises directly from the aortic arch. The **external carotid artery** supplies blood to numerous structures within the face, lower jaw, neck, esophagus, and larynx. The **internal carotid artery** initially forms an expansion known as the **carotid sinus**, containing the carotid baroreceptors and chemoreceptors. The information provided by these receptors is critical to maintaining cardiovascular homeostasis.

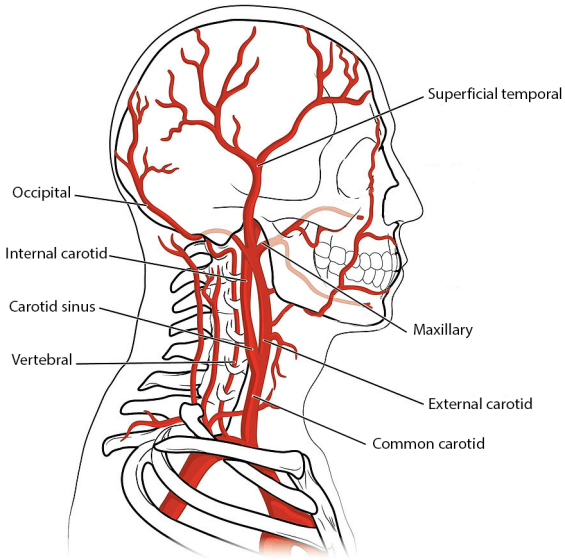

Figure 18.3.7: Branches of the Common Carotid Artery. The common carotid artery splits into an internal carotid and an external carotid branch. The internal carotid supplies blood to structures within the cranial cavity while the external carotid supplies structures on the exterior of the cranium and the face. *(Image Credit: "Common Carotid Artery" by OpenStax is licensed under CC BY 3.0, modifications by Jennifer Lange.)*

The internal carotid arteries along with the vertebral arteries are the two primary suppliers of blood to the human brain. Both the internal carotid and vertebral arteries branch once they enter the cranial cavity, and some of these branches form a structure known as the cerebral arterial circle (or circle of Willis), an anastomosis that is remarkably like a traffic circle that sends off branches (in this case, arterial branches to the brain). The internal carotid artery continues through the carotid canal of the temporal bone and enters the base of the brain through the carotid canal where it gives rise to several branches (Figure 18.3.8). One of these branches is the anterior cerebral artery that supplies blood to the frontal lobe of the cerebrum. Another branch, the middle cerebral artery, supplies blood to the temporal and parietal lobes, which are the most common sites of CVAs. The right and left anterior cerebral arteries join together to form an anastomosis called the anterior communicating artery. The initial segments of the anterior cerebral arteries and the anterior communicating artery form the anterior portion of the arterial circle. The posterior portion of the arterial circle is formed by a left and a right posterior communicating artery that branch from the posterior cerebral artery, which arises from the basilar artery. It provides blood to the posterior portion of the cerebrum and brainstem. The basilar artery is an anastomosis that begins at the junction of the two vertebral arteries and sends branches to the cerebellum and brainstem. It flows into the posterior cerebral arteries. Table 18.3.4 summarizes the aortic arch branches, including the major branches supplying the brain.

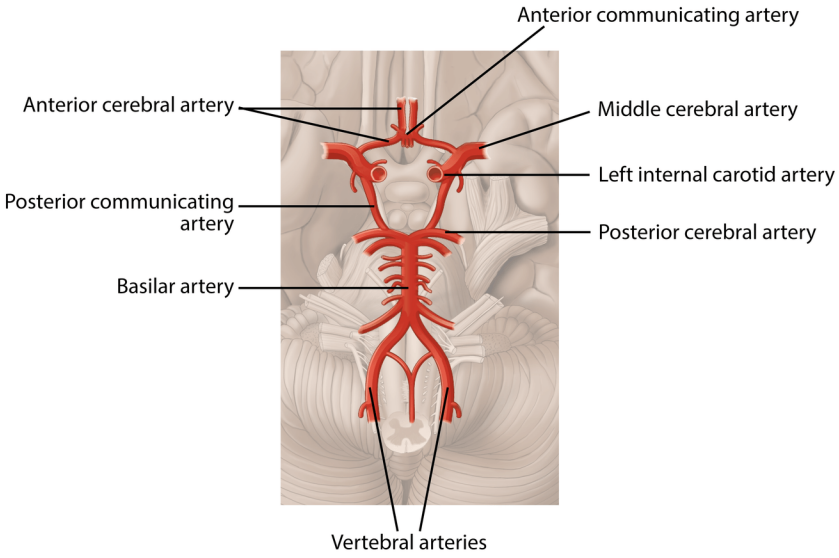

Figure 18.3.8: Cerebral Arterial Circle. This inferior view shows the arteries of the brain. This circular structure with its communicating branches is called the cerebral arterial circle, also called the circle of Willis. *(Image credit: "Cerebral Arteries" by Jennifer Lange using brain image by Justin Greene is licensed under CC-BY-NC-SA 4.0, Circle of Willis original image from OpenStax.)*

Table 18.3.4: Aortic Arch Branches and Brain Circulation

Vessel	Description	Image
Brachiocephalic artery	Single vessel located on the right side of the body; the first vessel branching from the aortic arch; gives rise to the right subclavian artery and the right common carotid artery; supplies blood to the head, neck, upper limb, and wall of the thoracic region	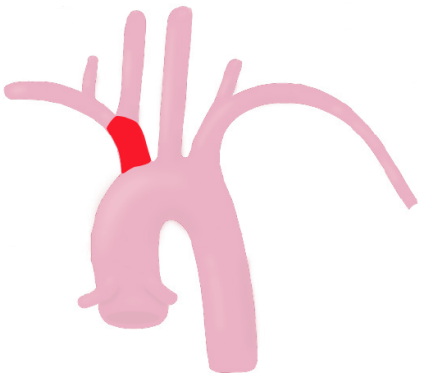

Vessel	Description	Image
Subclavian artery	The right side branches from the brachiocephalic artery while the left side branches from the aortic arch. Becomes the axillary artery at the lateral border of the first rib; supplies blood to the head, neck, upper thorax, and upper limb.	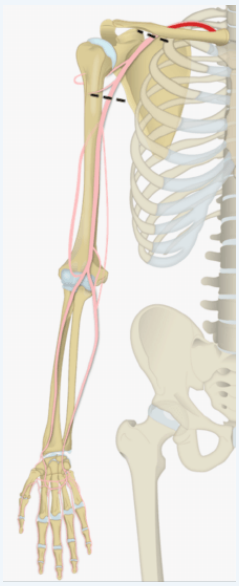 **Image Credit** *University of British Columbia Clinical Anatomy*, *CC BY-NC-SA 4.0*
Vertebral artery	Arises from the subclavian artery and passes through the vertebral foramen through the foramen magnum to the brain; joins with the internal carotid artery to form the arterial circle; supplies blood to the brain and spinal cord	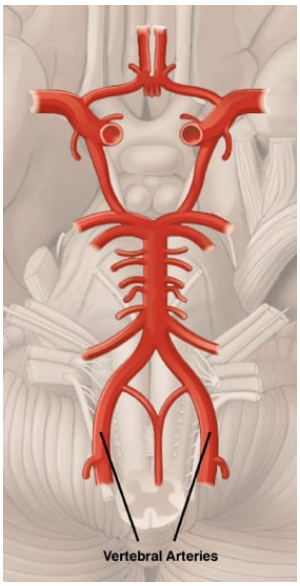 **Image Credit** *"Cerebral Arteries" by Jennifer Lange using brain image by Justin Greene is licensed under CC-BY-NC-SA 4.0, Circle of Willis original image from OpenStax*

Vessel	Description	Image
Common carotid artery	The right common carotid artery arises from the brachiocephalic artery and the left common carotid artery arises from the aortic arch; each gives rise to the external and internal carotid arteries; supplies the respective sides of the head and neck	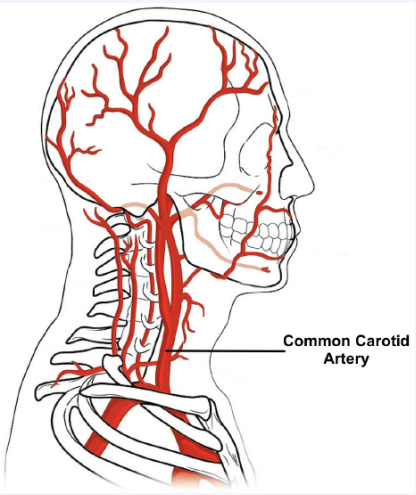 **Image Credit** *"Common Carotid Artery" by OpenStax is licensed under CC BY 3.0, modifications by Jennifer Lange*
External carotid artery	Arises from the common carotid artery; supplies blood to numerous structures within the face, lower jaw, neck, esophagus, and larynx	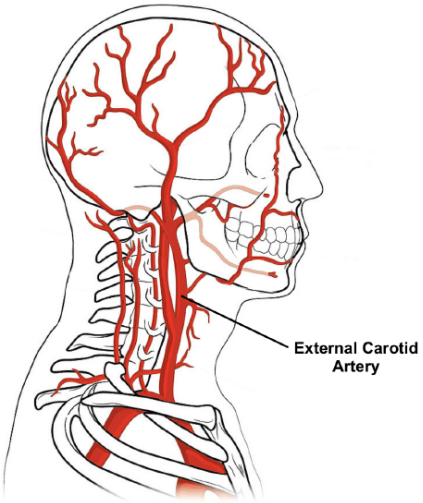 **Image Credit** *"Common Carotid Artery" by OpenStax is licensed under CC BY 3.0, modifications by Jennifer Lange*

Vessel	Description	Image
Internal carotid artery	Arises from the common carotid artery and begins with the carotid sinus; goes through the carotid canal of the temporal bone to the base of the brain; combines with the branches of the vertebral artery, forming the arterial circle; supplies blood to the brain	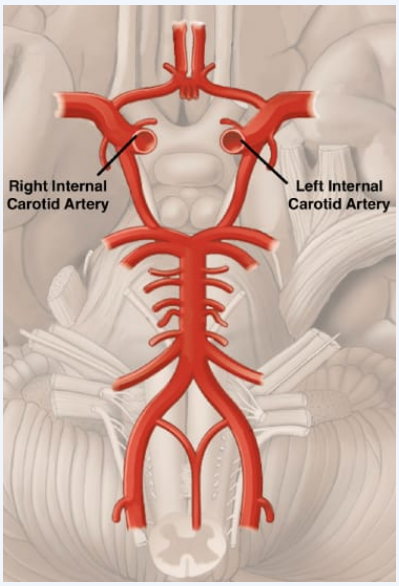 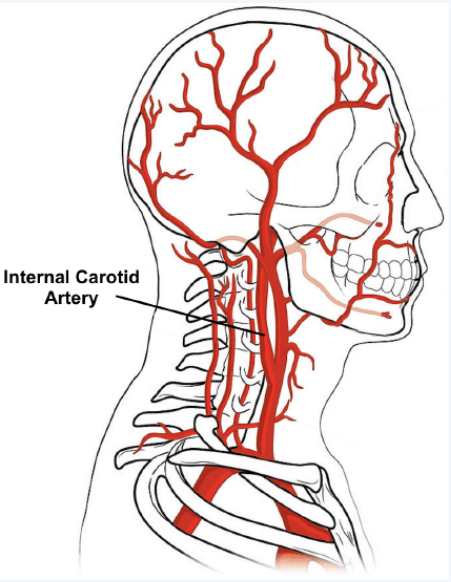 A B **Image Credit** *A."Cerebral Arteries" by Jennifer Lange using brain image by Justin Greene is licensed under CC-BY-NC-SA 4.0, Circle of Willis original image from OpenStax. B. "Common Carotid Artery" by OpenStax is licensed under CC BY 3.0, modifications by Jennifer Lange*

Vessel	Description	Image
Cerebral arterial circle or circle of Willis	An anastomosis located at the base of the brain that ensures continual blood supply; formed from the branches of the internal carotid and vertebral arteries; supplies blood to the brain	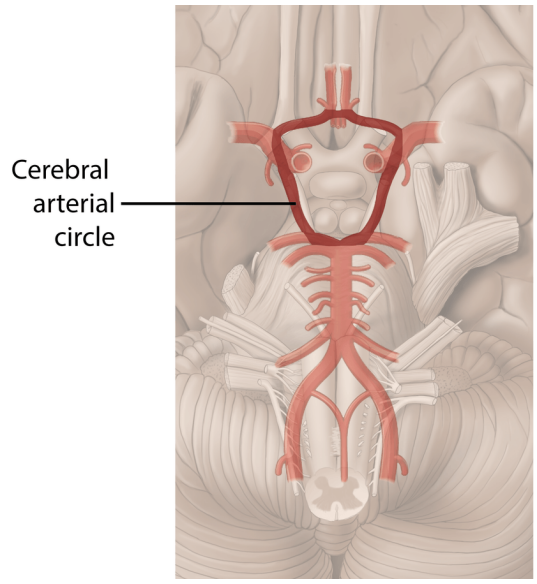 **Image Credit** *"Cerebral Arterial Circle" by Jennifer Lange using brain image by Justin Greene is licensed under CC-BY-NC-SA 4.0, Circle of Willis original image from OpenStax*

Vessel	Description	Image
Anterior cerebral artery	Arises from the internal carotid artery; supplies blood to the frontal lobe of the cerebrum	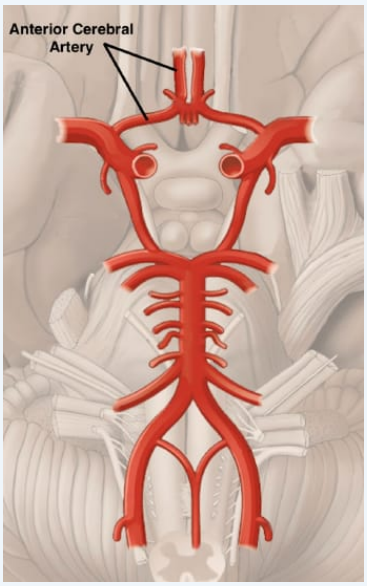 **Image Credit** *"Cerebral Arteries" by Jennifer Lange using brain image by Justin Greene is licensed under CC-BY-NC-SA 4.0, Circle of Willis original image from OpenStax*
Middle cerebral artery	Another branch of the internal carotid artery; supplies blood to the temporal and parietal lobes of the cerebrum	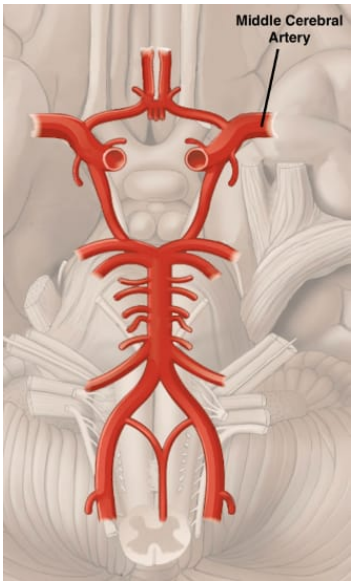 **Image Credit** *"Cerebral Arteries" by Jennifer Lange using brain image by Justin Greene is licensed under CC-BY-NC-SA 4.0, Circle of Willis original image from OpenStax*

Vessel	Description	Image
Anterior communicating artery	An anastomosis of the right and left internal carotid arteries; supplies blood to the brain	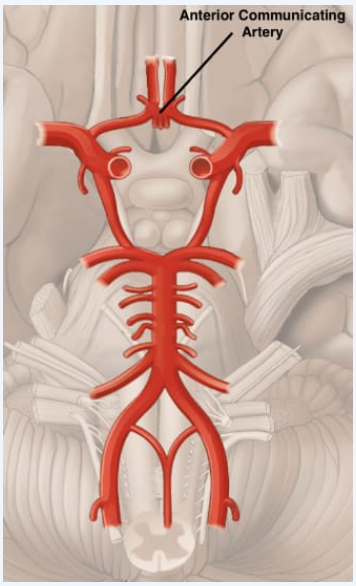 **Image Credit** *"Cerebral Arteries" by Jennifer Lange using brain image by Justin Greene is licensed under CC-BY-NC-SA 4.0, Circle of Willis original image from OpenStax*
Posterior communicating artery	Branches of the posterior cerebral artery that form part of the posterior portion of the arterial circle; supplies blood to the brain	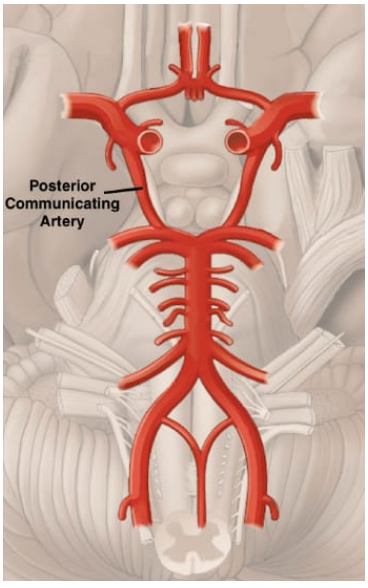 **Image Credit** *"Cerebral Arteries" by Jennifer Lange using brain image by Justin Greene is licensed under CC-BY-NC-SA 4.0, Circle of Willis original image from OpenStax*

Vessel	Description	Image
Posterior cerebral artery	Branch of the basilar artery that forms a portion of the posterior segment of the arterial circle of Willis; supplies blood to the posterior portion of the cerebrum and brain stem	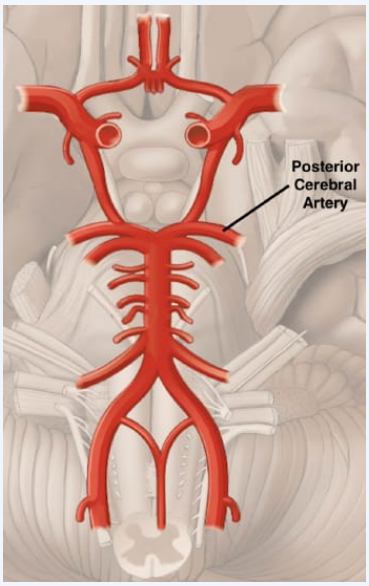 **Image Credit** *"Cerebral Arteries" by Jennifer Lange using brain image by Justin Greene is licensed under CC-BY-NC-SA 4.0, Circle of Willis original image from OpenStax*
Basilar artery	Formed from the fusion of the two vertebral arteries; sends branches to the cerebellum, brain stem, and the posterior cerebral arteries; the main blood supply to the brain stem	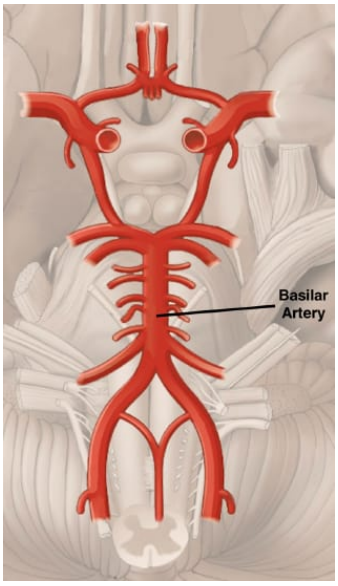 **Image Credit** *"Cerebral Arteries" by Jennifer Lange using brain image by Justin Greene is licensed under CC-BY-NC-SA 4.0, Circle of Willis original image from OpenStax*

Thoracic Aorta and Major Branches

The thoracic aorta begins at the level of vertebra T5 and continues through to the diaphragm at the level of T12, initially traveling within the mediastinum to the left of the vertebral column. As it passes through the thoracic region, the thoracic aorta gives rise to several branches. These branches include each **intercostal artery** that provides blood to the muscles of the thoracic cavity and vertebral column and the **superior phrenic artery** that provides blood to the superior surface of the diaphragm.

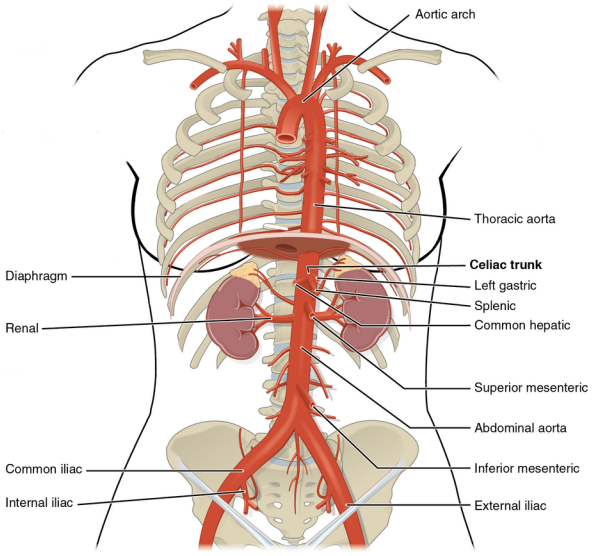

Figure 18.3.9: Arteries of the Thoracic and Abdominal Regions. The thoracic aorta gives rise to the arteries of the visceral and parietal branches. *(Image credit: "Thoracic Abdominal Arteries" by OpenStax is licensed under CC BY 3.0, modifications by Jennifer Lange.)*

Abdominal Aorta and Major Branches

After crossing through the diaphragm, the thoracic aorta is called the abdominal aorta (see Figure 18.3.7). This vessel remains to the left of the vertebral column and is embedded in adipose tissue behind the peritoneal cavity. It formally ends at approximately the level of vertebra L4, where it bifurcates to form the **common iliac arteries**. Before this division, the abdominal aorta gives rise to several important branches:

- a single **celiac trunk** (artery) emerges and divides into the
  - **left gastric artery** to supply blood to the stomach and esophagus,
  - **splenic artery** to supply blood to the spleen, and
  - the **common hepatic artery**, which in turn gives rise to the hepatic artery proper to supply blood to the liver.
- The **superior mesenteric artery** arises approximately inferior to the celiac trunk and branches into several major vessels that supply blood to the small intestine (duodenum, jejunum, and ileum), the pancreas, and a majority of the large intestine.
- The **inferior mesenteric artery** arises approximately 5 cm superior to the common iliac arteries and supplies blood to the distal segment of the large intestine, including the rectum.
- Each **inferior phrenic artery** is a counterpart of a superior phrenic artery and supplies blood to the inferior surface of the diaphragm.
- The **adrenal artery** supplies blood to the adrenal (suprarenal) glands and arises near the superior mesenteric artery.
- Each **renal artery** branches inferior to the superior mesenteric arteries and supplies a kidney. The right renal artery is longer than the left since the aorta lies to the left of the vertebral column and the vessel must travel a greater distance to reach its target. Renal arteries branch repeatedly to supply blood to the kidneys.

The aorta divides at approximately the level of vertebra L4 into a left and a right **common iliac artery**. The common iliac arteries provide blood to the pelvic region and ultimately to the lower limbs. They split into external and internal iliac arteries approximately at the level of the lumbar-sacral articulation. Each **internal iliac artery** sends branches to the urinary bladder, the walls of the pelvis, and the external genitalia. In females, they also provide blood to the uterus and vagina. The much larger **external iliac artery** supplies blood to each of the lower limbs. Figure 18.3.8 shows the distribution of the major branches of the aorta into the thoracic and abdominal regions. Figure 18.3.9 shows the distribution of the major branches of the common iliac arteries. Table 18.3.6 summarizes the major branches of the abdominal aorta.

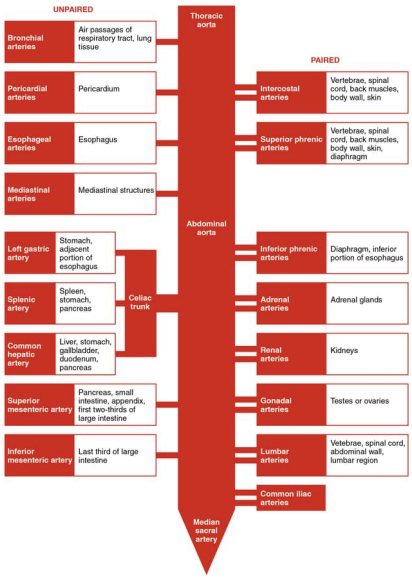

Figure 18.3.10: Major Branches of the Descending Aorta. The flow chart summarizes the distribution of the major branches of the aorta into the thoracic and abdominal regions. (Image credit: "Thoracic Abdominal Arteries" by OpenStax is licensed under CC BY 3.0)

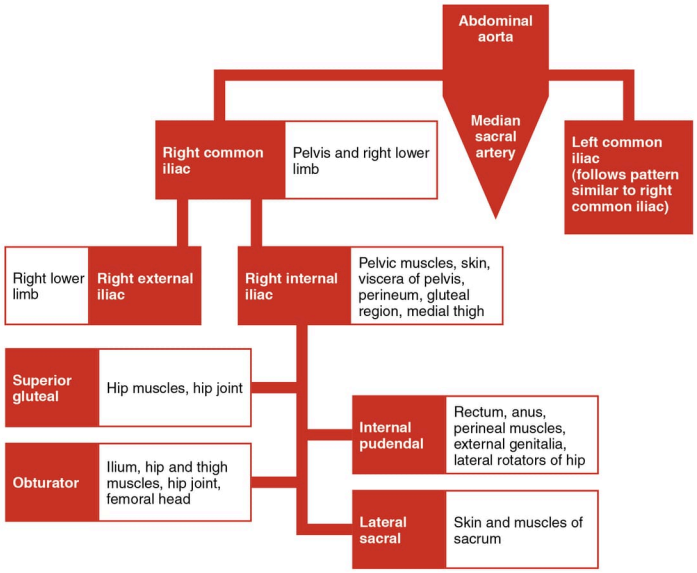

Figure 18.3.11: Major Branches of the Iliac Arteries. The flow chart summarizes the distribution of the major branches of the common iliac arteries into the pelvis and lower limbs. The left side follows a similar pattern to the right. (Image credit: "Iliac Artery Branches Chart" by OpenStax is licensed under CC BY 3.0)

Table* 18.3.6*: Arteries Branching from the Abdominal Aorta

Vessel	Description	Image
Celiac trunk	Also called the celiac artery; a major branch of the abdominal aorta; gives rise to the left gastric artery, the splenic artery, and the common hepatic artery that forms the hepatic artery to the liver, the right gastric artery to the stomach, and the cystic artery to the gall bladder	
Left gastric artery	Branch of the celiac trunk; supplies blood to the stomach	
Splenic artery	Branch of the celiac trunk; supplies blood to the spleen	

Vessel	Description	Image
Common hepatic artery	Branch of the celiac trunk that forms the hepatic artery, the right gastric artery, and the cystic artery	
Hepatic artery proper	Branch of the common hepatic artery; supplies systemic blood to the liver	
Superior mesenteric artery	Branch of the abdominal aorta; supplies blood to the small intestine (duodenum, jejunum, and ileum), the pancreas, and a majority of the large intestine	
Inferior mesenteric artery	Branch of the abdominal aorta; supplies blood to the distal segment of the large intestine and rectum	
Inferior phrenic arteries	Branches of the abdominal aorta; supply blood to the inferior surface of the diaphragm	
Adrenal artery	Branch of the abdominal aorta; supplies blood to the adrenal (suprarenal) glands	
Renal artery	Branch of the abdominal aorta; supplies each kidney	
Common iliac artery	Branch of the aorta that leads to the internal and external iliac arteries	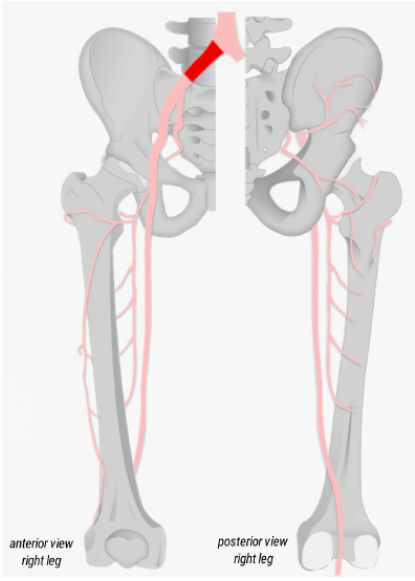 **Image Credit** *University of British Columbia Clinical Anatomy*, *CC BY-NC-SA 4.0*

Vessel	Description	Image
Internal iliac artery	Branch from the common iliac arteries; supplies blood to the urinary bladder, walls of the pelvis, external genitalia, and the medial portion of the femoral region; in females, also provides blood to the uterus and vagina	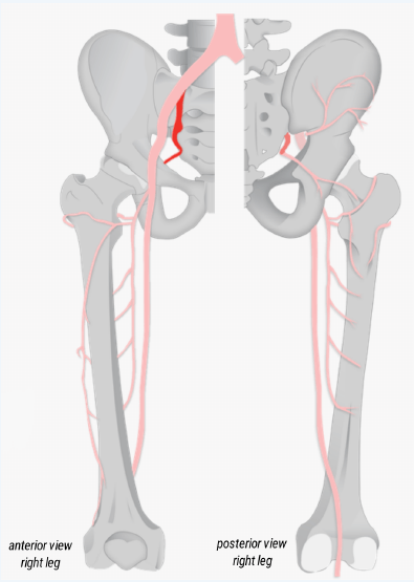 **Image Credit** *University of British Columbia Clinical Anatomy*, *CC BY-NC-SA 4.0*
External iliac artery	Branch of the common iliac artery that leaves the body cavity and becomes a femoral artery; supplies blood to the lower limbs	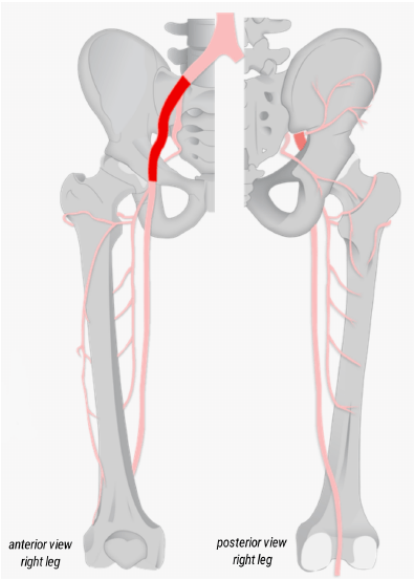 **Image Credit** *University of British Columbia Clinical Anatomy*, *CC BY-NC-SA 4.0*

Arteries Serving the Upper Limbs

As the subclavian artery exits the thorax into the axillary region, it is renamed the **axillary artery**. Although it does branch and supply blood to the region near the head of the humerus (via the humeral circumflex arteries), the majority of the vessel continues into the upper arm, or brachium, and becomes the brachial artery (Figure 18.3.10). The **brachial artery** supplies blood to much of the brachial region and divides at the elbow into several smaller branches, including the deep brachial arteries, which provide blood to the posterior surface of the arm, and the ulnar collateral arteries, which supply blood to the region of the elbow. As the brachial artery approaches the coronoid fossa, it bifurcates into the radial and ulnar arteries, which continue into the forearm, or antebrachium. The **radial artery** and **ulnar artery** parallel their namesake bones, giving off smaller branches until they reach the wrist, or carpal region. At this level, they fuse to form the superficial and deep **palmar arches** that supply blood to the hand, as well as the **digital arteries** that supply blood to the digits. Figure 18.3.11 shows the distribution of systemic arteries from the heart into the upper limb. Table 18.3.7 summarizes the arteries serving the upper limbs.

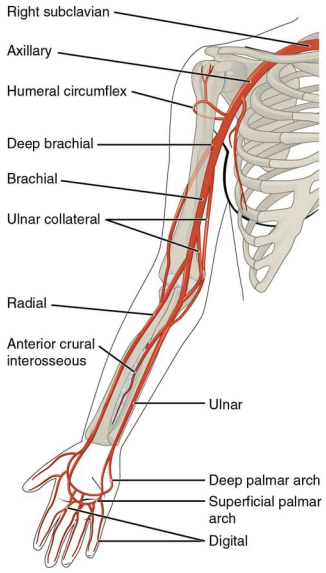

Figure 18.3.12: Major Arteries Serving the Upper Limb. The arteries that supply blood to the arms and hands are extensions of the subclavian arteries. (Image credit: "Thoracic Upper Limb Arteries" by OpenStax is licensed under CC BY 3.0)

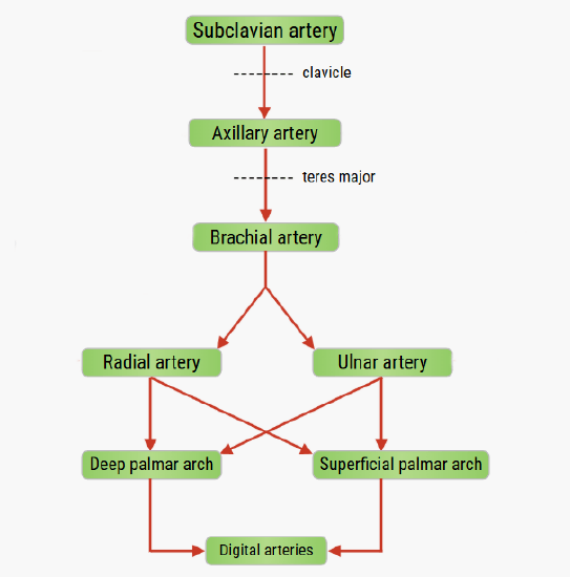

Figure 18.3.13: Major Arteries of the Upper Limb. The flow chart summarizes the distribution of the major arteries from the heart into the neck and upper limb. *(Image credit: University of British Columbia Clinical Anatomy, is licensed under CC BY-NC-SA 4.0, modified by Jennifer Lange)*

Table** 18.3.7**: Arteries Serving the Upper Limbs

Vessel	Description	Image
Subclavian artery	The right side branches from the brachiocephalic artery while the left side branches from the aortic arch. Becomes the axillary artery at the lateral border of the first rib; supplies blood to the head, neck, upper thorax, and upper limb.	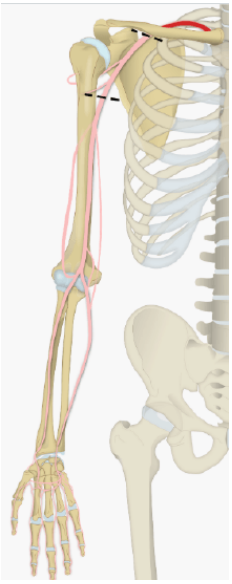 **Image Credit** *University of British Columbia Clinical Anatomy*, *CC BY-NC-SA 4.0*

Vessel	Description	Image
Axillary artery	Continuation of the subclavian artery as it penetrates the body wall and enters the axillary region; supplies blood to the region near the head of the humerus; the majority of the vessel continues into the brachium and becomes the brachial artery	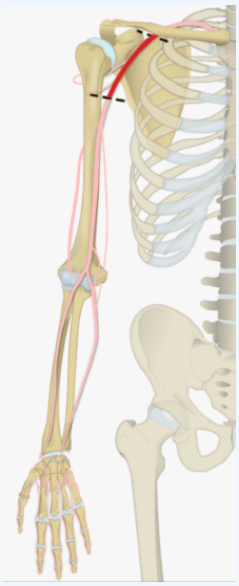 **Image Credit** *University of British Columbia Clinical Anatomy*, *CC BY-NC-SA 4.0*

Vessel	Description	Image
Brachial artery	Continuation of the axillary artery in the brachium; supplies blood to much of the brachial region; gives off several smaller branches that provide blood to the posterior surface of the arm in the region of the elbow; bifurcates into the radial and ulnar arteries at the coronoid fossa	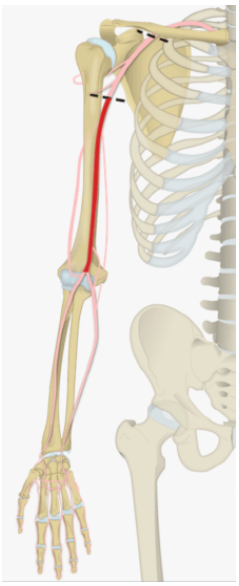 **Image Credit** *University of British Columbia Clinical Anatomy*, *CC BY-NC-SA 4.0*

Vessel	Description	Image
Radial artery	Formed at the bifurcation of the brachial artery; parallels the radius; gives off smaller branches until it reaches the carpal region where it fuses with the ulnar artery to form the palmar arches of the hand; supplies blood to the lower arm and carpal region	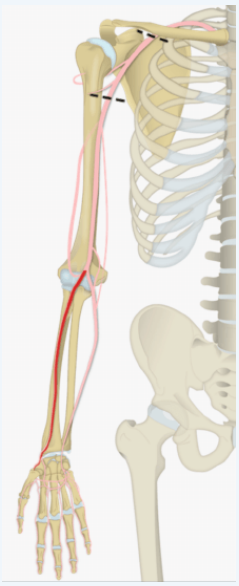 **Image Credit** *University of British Columbia Clinical Anatomy*, *CC BY-NC-SA 4.0*

Vessel	Description	Image
Ulnar artery	Formed at the bifurcation of the brachial artery; parallels the ulna; gives off smaller branches until it reaches the carpal region where it fuses with the radial artery to form the palmar arches of the hand; supplies blood to the lower arm and carpal region	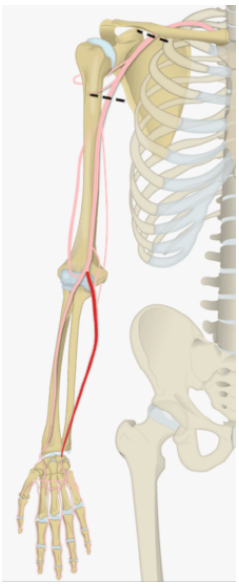 **Image Credit** *University of British Columbia Clinical Anatomy*, *CC BY-NC-SA 4.0*

Arteries Serving the Lower Limbs

The external iliac artery exits the body cavity and enters the femoral region of the lower leg (Figure 18.3.12). As it passes through the body wall, it is renamed the **femoral artery**. It gives off several smaller branches as well as the lateral **deep femoral artery** that in turn gives rise to a **lateral circumflex artery**. These arteries supply blood to the deep muscles of the thigh as well as ventral and lateral regions of the integument. The femoral artery also gives rise to the **genicular artery**, which provides blood to the region of the knee. As the femoral artery passes posterior to the knee near the popliteal fossa, it is called the popliteal artery. The **popliteal artery** branches into the anterior and posterior tibial arteries.

The **anterior tibial artery** is located between the tibia and fibula, and supplies blood to the muscles and integument of the anterior tibial region. Upon reaching the tarsal region, it becomes the **dorsalis pedis artery**, which branches repeatedly and provides blood to the tarsal and dorsal regions of the foot. The **posterior tibial artery** provides blood to the muscles and integument on the posterior surface of the tibial region. The fibular or peroneal artery branches from the posterior tibial artery. It bifurcates and becomes the **medial plantar artery** and **lateral plantar artery**, providing blood to the plantar surfaces. There is an anastomosis with the dorsalis pedis artery, and the medial and lateral plantar arteries form two arches called the **dorsal arch** (also called the arcuate arch) and the **plantar arch**, which provide blood to the remainder of the foot and toes. Figure 18.3.13 shows the distribution of the major systemic arteries in the lower limb. Table 18.3.8 summarizes the major systemic arteries discussed in the text.

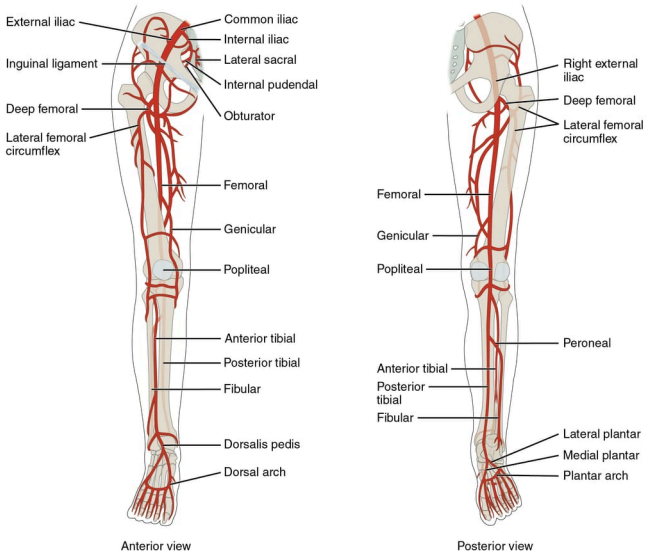

Figure 18.3.14: Major Arteries Serving the Lower Limb. Major arteries serving the lower limb are shown in anterior and posterior views. (Image credit: "Lower Limb Arteries" by OpenStax is licensed under CC BY 3.0)

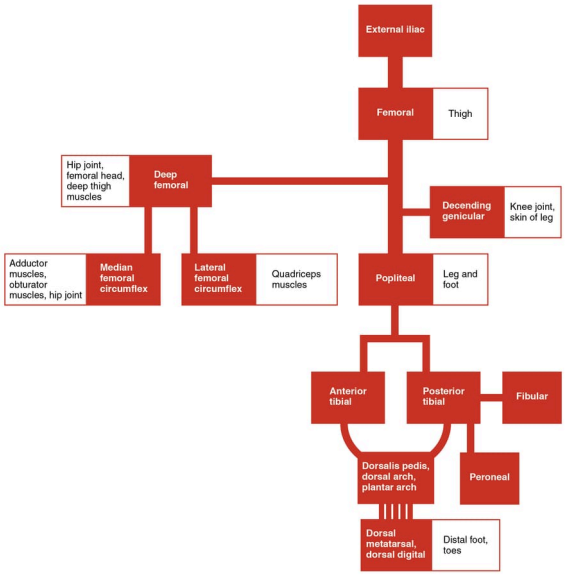

Figure 18.3.15: Systemic Arteries of the Lower Limb. The flow chart summarizes the distribution of the systemic arteries from the external iliac artery into the lower limb. (Image credit: "Lower Limb Arteries Chart" by OpenStax is licensed under CC BY 3.0)

Table** 18.3.8**: Arteries Serving the Lower Limbs

Vessel	Description	Image
Femoral artery	Continuation of the external iliac artery after it passes through the body cavity; divides into several smaller branches, the lateral deep femoral artery, and the genicular artery; becomes the popliteal artery as it passes posterior to the knee	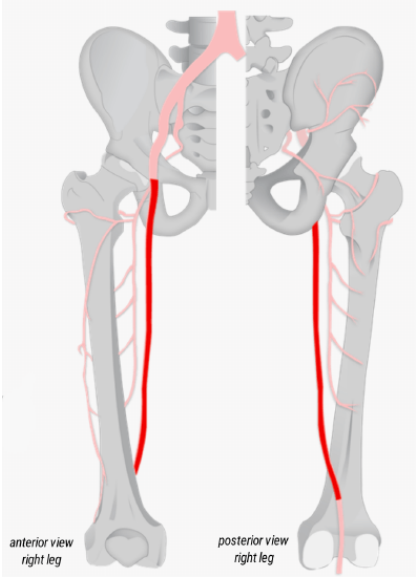 **Image Credit** *University of British Columbia Clinical Anatomy*, *CC BY-NC-SA 4.0*

Vessel	Description	Image
Deep femoral artery	Branch of the femoral artery; gives rise to the lateral circumflex arteries	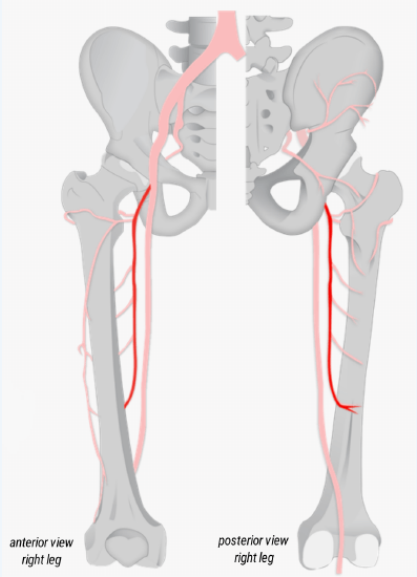 **Image Credit** *University of British Columbia Clinical Anatomy*, *CC BY-NC-SA 4.0*
Popliteal artery	Continuation of the femoral artery posterior to the knee; branches into the anterior and posterior tibial arteries	**Image Credit** *University of British Columbia Clinical Anatomy*, *CC BY-NC-SA 4.0*

Vessel	Description	Image
Anterior tibial artery	Branches from the popliteal artery; supplies blood to the anterior tibial region	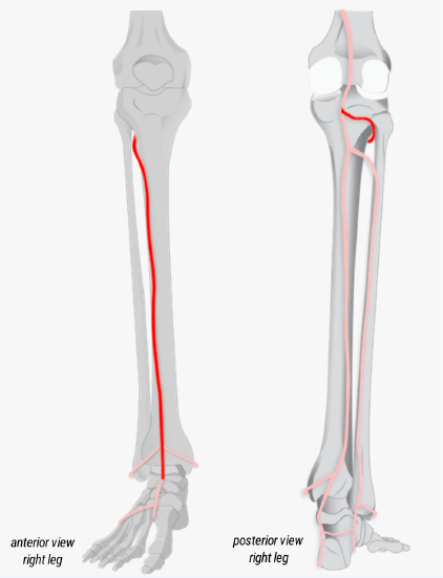 **Image Credit** *University of British Columbia Clinical Anatomy*, *CC BY-NC-SA 4.0*
Posterior tibial artery	Branches from the popliteal artery and gives rise to the fibular or peroneal artery; supplies blood to the posterior tibial region	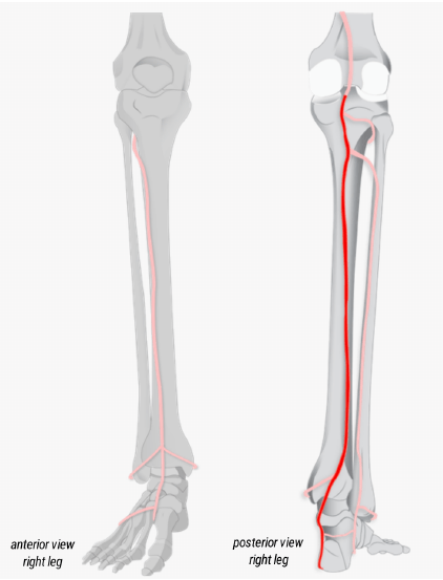 **Image Credit** *University of British Columbia Clinical Anatomy*, *CC BY-NC-SA 4.0*

Vessel	Description	Image
Fibular artery	Branches from the posterior tibial artery; supplies the posterior and lateral compartments of the leg.	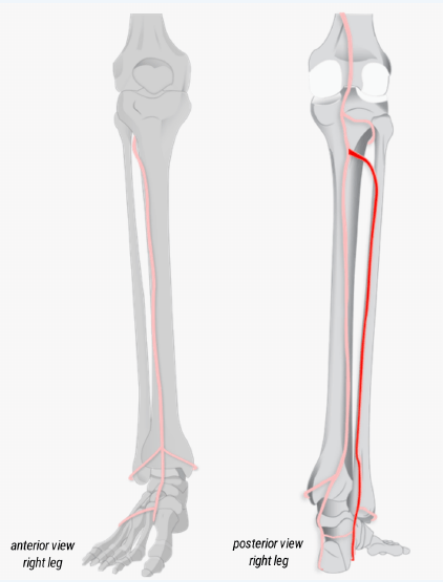 **Image Credit** *University of British Columbia Clinical Anatomy*, *CC BY-NC-SA 4.0*

Overview of Systemic Veins

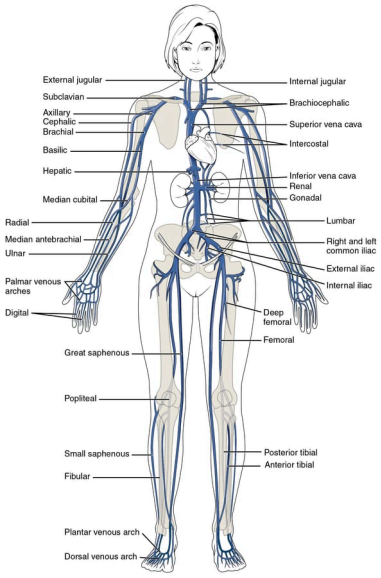

Figure 18.3.16: Major Systemic Veins of the Body. The major systemic veins of the body are shown here in an anterior view. (Image credit: "Major Systemic Veins" by OpenStax is licensed under CC BY 3.0)

The right atrium receives all of the systemic venous return. Most of the blood flows into either the superior vena cava or inferior vena cava. If you draw an imaginary line at the level of the diaphragm, systemic venous circulation from above that line will generally flow into the superior vena cava; this includes blood from the head, neck, chest, shoulders, and upper limbs. The

exception to this is that most venous blood flow from the coronary veins flows directly into the coronary sinus and from there directly into the right atrium. Beneath the diaphragm, systemic venous flow enters the inferior vena cava, that is, blood from the abdominal and pelvic regions and the lower limbs.

The Superior Vena Cava

The **superior vena cava** drains most of the body superior to the diaphragm (Figure 18.3.14). On both the left and right sides, the **subclavian vein** forms when the axillary vein passes through the body wall from the axillary region. It fuses with the external and internal jugular veins from the head and neck to form the **brachiocephalic vein**. Each **vertebral vein** also flows into the brachiocephalic vein close to this fusion. These veins arise from the base of the brain and the cervical region of the spinal cord, and flow largely through the intervertebral foramina in the cervical vertebrae. They are the counterparts of the vertebral arteries. Each **internal thoracic vein**, also known as an internal mammary vein, drains the anterior surface of the chest wall and flows into the brachiocephalic vein.

The remainder of the blood supply from the thorax drains into the azygos vein. Each **intercostal vein** drains muscles of the thoracic wall, each **esophageal vein** delivers blood from the inferior portions of the esophagus, each **bronchial vein** drains the systemic circulation from the lungs, and several smaller veins drain the mediastinal region. Bronchial veins carry approximately 13 percent of the blood that flows into the bronchial arteries; the remainder intermingles with the pulmonary circulation and returns to the heart via the pulmonary veins. These veins flow into the **azygos vein**, and with the smaller **hemiazygos vein** (hemi- = “half”) on the left of the vertebral column, drain blood from the thoracic region. The hemiazygos vein does not drain directly into the superior vena cava but enters the brachiocephalic vein via the superior intercostal vein.

The azygos vein passes through the diaphragm from the thoracic cavity on the right side of the vertebral column and begins in the lumbar region of the thoracic cavity. It flows into the superior vena cava at approximately the level of T2, making a significant contribution to the flow of blood. It combines with the two large left and right brachiocephalic veins to form the superior vena cava.

Table 18.3.9 summarizes the veins of the thoracic region that flow into the superior vena cava.

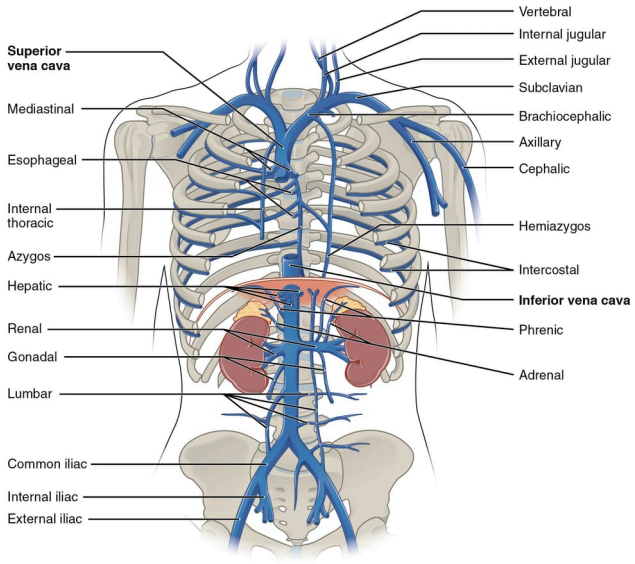

Figure 18.3.17: Veins of the Thoracic and Abdominal Regions. Veins of the thoracic and abdominal regions drain blood from the area above the diaphragm, returning it to the right atrium via the superior vena cava. (Image credit: "Thoracic Abdominal Veins" by OpenStax is licensed under CC BY 3.0)

Table** 18.3.9**: Veins of the Thoracic Region

Vessel	Description	Image
Superior vena cava	Large systemic vein; drains blood from most areas superior to the diaphragm; empties into the right atrium	

Vessel	Description	Image
Subclavian vein	Located deep in the thoracic cavity; formed by the axillary vein as it enters the thoracic cavity from the axillary region; drains the axillary and smaller local veins near the scapular region and leads to the brachiocephalic vein	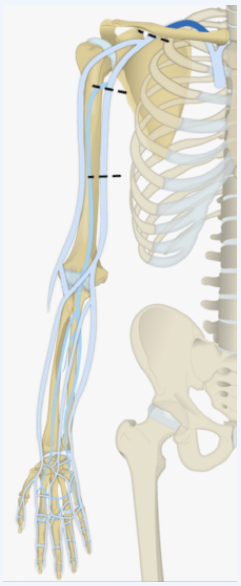 **Image Credit** *University of British Columbia Clinical Anatomy*, *CC BY-NC-SA 4.0*
Brachiocephalic veins	Pair of veins that form from a fusion of the external and internal jugular veins and the subclavian vein; subclavian, external and internal jugulars, vertebral, and internal thoracic veins flow into it; drain the upper thoracic region and lead to the superior vena cava	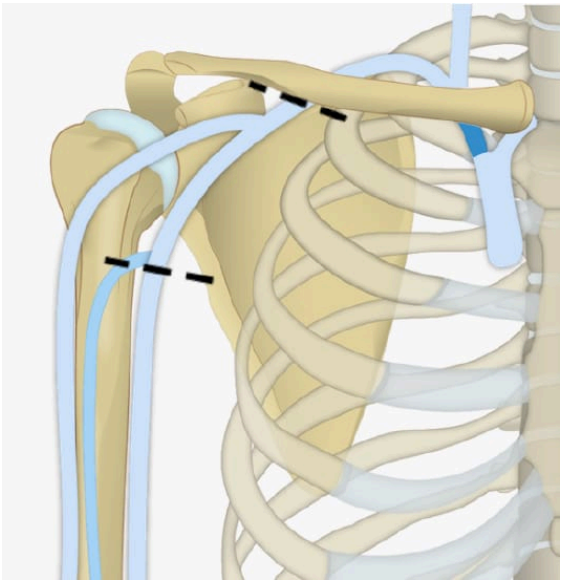 **Image Credit** *University of British Columbia Clinical Anatomy*, *CC BY-NC-SA 4.0*, modified by Jennifer Lange.

Vessel	Description	Image
Vertebral vein	Arises from the base of the brain and the cervical region of the spinal cord; passes through the intervertebral foramina in the cervical vertebrae; drains smaller veins from the cranium, spinal cord, and vertebrae, and leads to the brachiocephalic vein; counterpart of the vertebral artery	

Veins of the Head and Neck

Blood from the brain and the superficial facial vein flow into each **internal jugular vein** (Figure 18.3.15). Blood from the more superficial portions of the head, scalp, and cranial regions, including the **temporal vein** and **maxillary vein**, flow into each **external jugular vein**. Although the external and internal jugular veins are separate vessels, there are anastomoses between them close to the thoracic region. Blood from the external jugular vein empties into the subclavian vein. Table 18.3.10 summarizes the major veins of the head and neck.

Table* 18.3.10*. Major Veins of the Head and Neck

Vessel	Description
Internal jugular vein	Parallel to the common carotid artery, which is more or less its counterpart, and passes through the jugular foramen and canal; primarily drains blood from the brain, receives the superficial facial vein, and empties into the subclavian vein
External jugular vein	Drains blood from the more superficial portions of the head, scalp, and cranial regions, and leads to the subclavian vein

Venous Drainage of the Brain

Circulation to the brain is both critical and complex (see Figure 18.3.15). Many smaller veins of the brain stem and the superficial veins of the cerebrum lead to larger vessels referred to as intracranial sinuses. These include the superior and inferior sagittal sinuses, straight sinus, cavernous sinuses, left and right sinuses, the petrosal sinuses, and the occipital sinuses. Ultimately, sinuses will lead back to either the inferior jugular vein or vertebral vein.

Most of the veins on the superior surface of the cerebrum flow into the largest of the sinuses, the **superior sagittal sinus**. It is located midsagittally between the meningeal and periosteal layers of the dura mater within the falx cerebri and, at first glance in images or models, can be mistaken for the subarachnoid space. Most reabsorption of cerebrospinal fluid occurs via the chorionic villi (arachnoid granulations) into the superior sagittal sinus. Blood from most of the smaller vessels originating from the inferior cerebral veins flows into the **great cerebral vein** and into the **straight sinus**. Other cerebral veins and those from the eye socket flow into the **cavernous sinus**, which flows into the **petrosal sinus** and then into the internal jugular vein. The **occipital sinus**, sagittal sinus, and straight sinuses all flow into the left and right **transverse sinuses** near the lambdoid suture. The transverse sinuses in turn flow into the **sigmoid sinuses** that pass through the jugular foramen and into the internal jugular vein. The internal jugular vein flows parallel to the common carotid artery and is more or less its counterpart. It empties into the brachiocephalic vein. The veins draining the cervical vertebrae and the posterior surface of the skull, including some blood from the occipital sinus, flow into the vertebral veins. These parallel the vertebral arteries and travel through the transverse foramina of the cervical vertebrae. The vertebral veins also flow into the brachiocephalic veins. Table 18.3.11 summarizes the major veins of the brain.

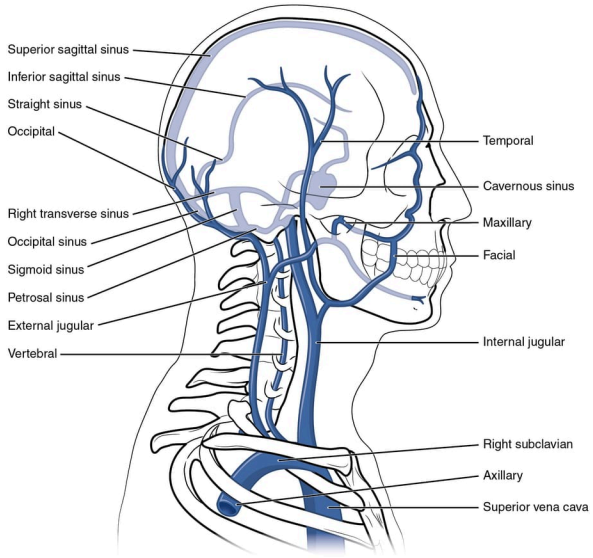

Figure 18.3.18: Veins of the Head and Neck. This left lateral view shows the veins of the head and neck, including the intercranial sinuses. (Image credit: "Head and Neck Veins" by OpenStax is licensed under CC BY 3.0)

Table* 18.3.11. *Major Veins of the Brain

Vessel	Description
Superior sagittal sinus	Enlarged vein located midsagittally between the meningeal and periosteal layers of the dura mater within the falx cerebri; receives most of the blood drained from the superior surface of the cerebrum and leads to the inferior jugular vein and the vertebral vein
Straight sinus	Enlarged vein that drains blood from the brain; receives most of the blood from the great cerebral vein and leads to the left or right transverse sinus
Occipital sinus	Enlarged vein that drains the occipital region near the falx cerebelli and leads to the left and right transverse sinuses, and also the vertebral veins
Transverse sinuses	Pair of enlarged veins near the lambdoid suture that drains the occipital, sagittal, and straight sinuses, and leads to the sigmoid sinuses
Sigmoid sinuses	Enlarged vein that receives blood from the transverse sinuses and leads through the jugular foramen to the internal jugular vein

Veins Draining the Upper Limbs

The **digital veins** in the fingers come together in the hand to form the **palmar venous arches** (Figure 18.3.16). From here, the veins come together to form the radial vein, the ulnar vein, and the median antebrachial vein. The **radial vein** and the **ulnar vein** parallel the bones of the forearm and join together at the antebrachium to form the **brachial vein**, a deep vein that flows into the axillary vein in the brachium.

The **median antebrachial vein** parallels the ulnar vein, is more medial in location, and joins the **basilic vein** in the forearm. As the basilic vein reaches the antecubital region, it gives off a branch called the **median cubital vein** that crosses at an angle to join the cephalic vein. The median cubital vein is the most common site for drawing venous blood in humans. The basilic vein continues through the arm medially and superficially to the axillary vein.

The **cephalic vein** begins in the antebrachium and drains blood from the superficial surface of the arm into the axillary vein. It is extremely superficial and easily seen along the surface of the biceps brachii muscle in individuals with good muscle tone and in those without excessive subcutaneous adipose tissue in the arms.

The **subscapular vein** drains blood from the subscapular region and joins the cephalic vein to form the **axillary vein**. As it passes through the body wall and enters the thorax, the axillary vein becomes the subclavian vein.

Many of the larger veins of the thoracic and abdominal region and upper limb are further represented in the flow chart in Figure 18.3.17. Table 18.3.12 summarizes the veins of the upper limbs.

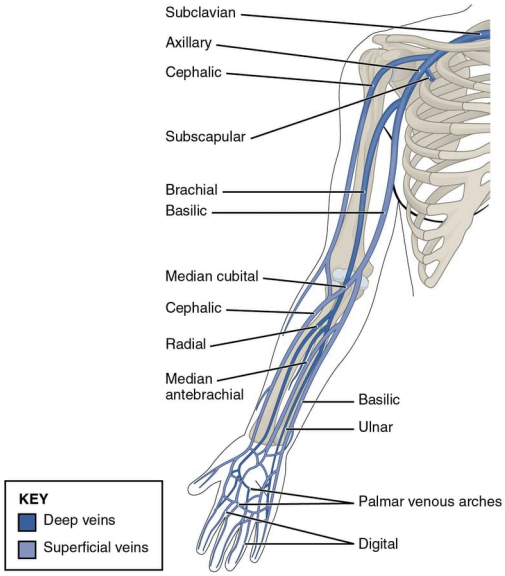

Figure 18.3.19: Veins of the Upper Limb. This anterior view shows the veins that drain the upper limb. (Image credit: "Thoracic Upper Limb Veins" by OpenStax is licensed under CC BY 3.0)

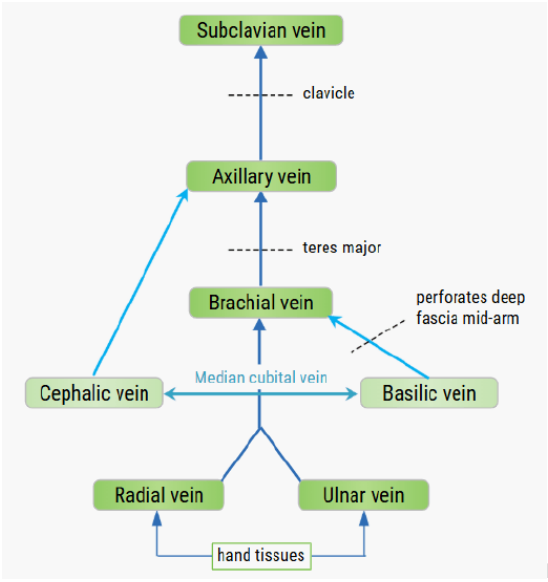

Figure 18.3.20: Veins of the Upper Limb. The flow chart summarizes the distribution of the deep and superficial veins of the upper limb. *(Image credit: Veins of the Upper Limb, University of British Columbia Clinical Anatomy, is licensed under CC BY-NC-SA 4.0.)*

Table** 18.3.12**: Veins of the Upper Limbs

Vessel	Description	Image
Radial vein	Vein that parallels the radius and radial artery; arises from the palmar venous arches and leads to the brachial vein	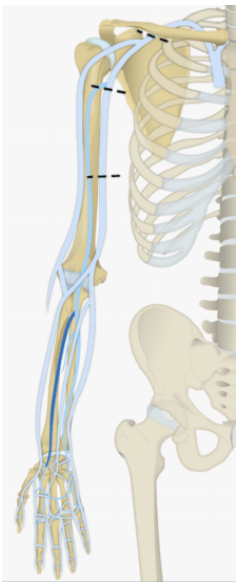 **Image Credit** *University of British Columbia Clinical Anatomy*, *CC BY-NC-SA 4.0*

Vessel	Description	Image
Ulnar vein	Vein that parallels the ulna and ulnar artery; arises from the palmar venous arches and leads to the brachial vein	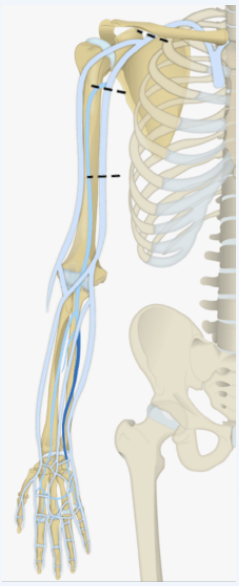 **Image Credit** *University of British Columbia Clinical Anatomy*, *CC BY-NC-SA 4.0*

Vessel	Description	Image
Brachial vein	Deeper vein of the arm that forms from the radial and ulnar veins in the lower arm; leads to the axillary vein	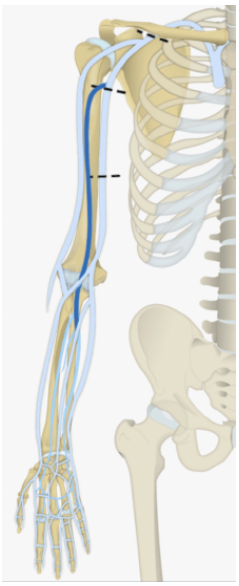 **Image Credit** *University of British Columbia Clinical Anatomy*, *CC BY-NC-SA 4.0*

Vessel	Description	Image
Basilic vein	Superficial vein of the arm that arises in the medial carpal region, intersects with the median cubital vein, parallels the ulnar vein, and continues into the upper arm; along with the brachial vein, it leads to the axillary vein	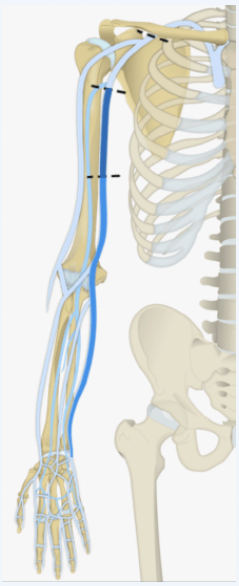 **Image Credit** *University of British Columbia Clinical Anatomy*, *CC BY-NC-SA 4.0*

Vessel	Description	Image
Median cubital vein	Superficial vessel located in the antecubital region that links the cephalic vein to the basilic vein in the form of a v; a frequent site from which to draw blood	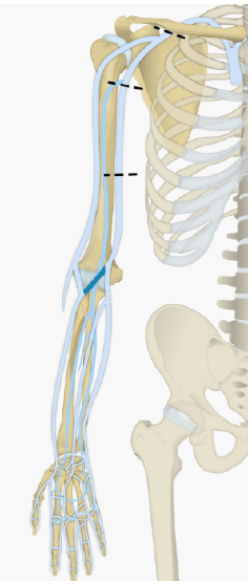 **Image Credit** *University of British Columbia Clinical Anatomy*, *CC BY-NC-SA 4.0*

Vessel	Description	Image
Cephalic vein	Superficial vessel in the lateral upper arm; leads to the axillary vein	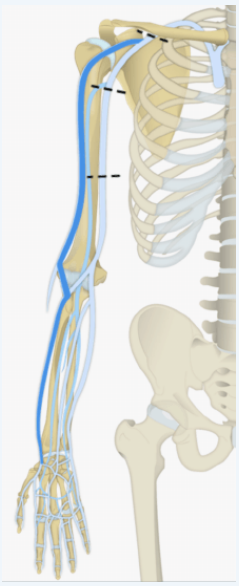 **Image Credit** *University of British Columbia Clinical Anatomy*, *CC BY-NC-SA 4.0*

Vessel	Description	Image
Axillary vein	The major vein in the axillary region; drains the upper limb and becomes the subclavian vein	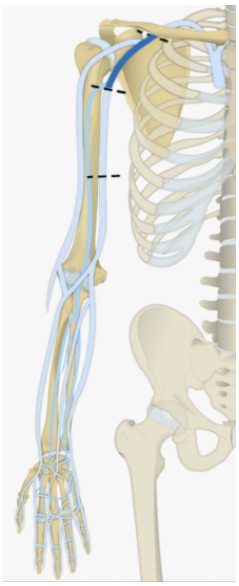 **Image Credit** *University of British Columbia Clinical Anatomy*, *CC BY-NC-SA 4.0*

The Inferior Vena Cava

Other than the small amount of blood drained by the azygos and hemiazygos veins, most of the blood inferior to the diaphragm drains into the inferior vena cava before it is returned to the heart (see Figure 18.3.14). Lying just beneath the parietal peritoneum in the abdominal cavity, the **inferior vena cava** parallels the abdominal aorta, where it can receive blood from abdominal veins. The lumbar portions of the abdominal wall and spinal cord are drained by a series of **lumbar veins**, usually four on each side. The ascending lumbar veins drain into either the azygos vein on the right or the hemiazygos vein on the left, and return to the superior vena cava. The remaining lumbar veins drain directly into the inferior vena cava.

Blood supply from the kidneys flows into each **renal vein**, normally the largest veins entering the inferior vena cava. A number of other, smaller veins empty into the left renal vein. Each **adrenal vein** drains the adrenal or suprarenal glands located immediately superior to the kidneys. The right adrenal vein enters the inferior vena cava directly, whereas the left adrenal vein enters the left renal vein.

From the male reproductive organs, each **testicular vein** flows from the scrotum, forming a portion of the spermatic cord. Each **ovarian vein** drains an ovary in females. Each of these veins is generically called a **gonadal vein**. The right gonadal vein empties directly into the inferior vena cava, and the left gonadal vein empties into the left renal vein.

Each side of the diaphragm drains into a **phrenic vein**; the right phrenic vein empties directly into the inferior vena cava, whereas the left phrenic vein empties into the left renal vein. Blood supply from the liver drains into each **hepatic vein** and directly into the inferior vena cava. Since the inferior vena cava lies primarily to the right of the vertebral column and aorta, the left renal vein is longer, as are the left phrenic, adrenal, and gonadal veins. The longer length of the left renal vein makes the left kidney the primary target of surgeons removing this organ for donation. Figure 18.3.18 provides a flow chart of the veins flowing into the inferior vena cava. Table 18.3.13 summarizes the major veins of the abdominal region.

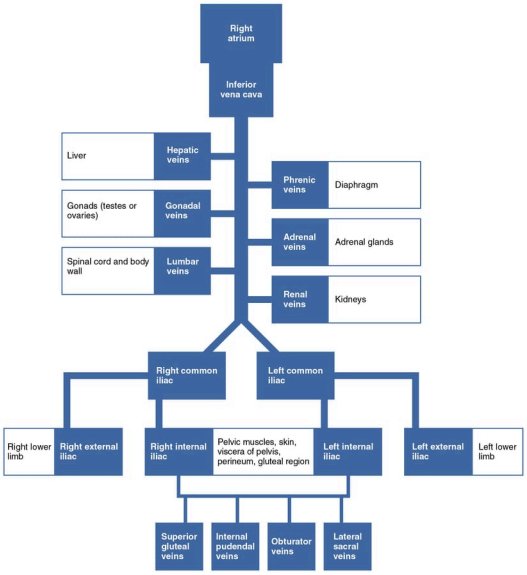

Figure 18.3.21: Venous Flow into Inferior Vena Cava. The flow chart summarizes veins that deliver blood to the inferior vena cava. (Image credit: "FlowChart Veins into VenaCava" by OpenStax is licensed under CC BY 3.0)

Table 18.3.13: Major Veins of the Abdominal Region

Vessel	Description
Inferior vena cava	Large systemic vein that drains blood from areas largely inferior to the diaphragm; empties into the right atrium
Lumbar veins	Series of veins that drain the lumbar portion of the abdominal wall and spinal cord; the ascending lumbar veins drain into the azygos vein on the right or the hemiazygos vein on the left; the remaining lumbar veins drain directly into the inferior vena cava
Renal vein	Largest vein entering the inferior vena cava; drains the kidneys and flows into the inferior vena cava
Adrenal vein	Drains the adrenal or suprarenal; the right adrenal vein enters the inferior vena cava directly and the left adrenal vein enters the left renal vein
Testicular vein	Drains the testes and forms part of the spermatic cord; the right testicular vein empties directly into the inferior vena cava and the left testicular vein empties into the left renal vein
Ovarian vein	Drains the ovary; the right ovarian vein empties directly into the inferior vena cava and the left ovarian vein empties into the left renal vein
Gonadal vein	Generic term for a vein draining a reproductive organ; may be either an ovarian vein or a testicular vein, depending on the sex of the individual
Phrenic vein	Drains the diaphragm; the right phrenic vein flows into the inferior vena cava and the left phrenic vein empties into the left renal vein
Hepatic vein	Drains systemic blood from the liver and flows into the inferior vena cava

Veins Draining the Lower Limbs

The superior surface of the foot drains into the digital veins, and the inferior surface drains into the **plantar veins**, which flow into a complex series of anastomoses in the feet and ankles, including the **dorsal venous arch** and the **plantar venous arch** (Figure 18.3.19). From the dorsal venous arch, blood supply drains into the anterior and posterior tibial veins. The **anterior tibial vein** drains the area near the tibialis anterior muscle and combines with the posterior tibial vein and the fibular vein to form the popliteal vein. The **posterior tibial vein** drains the posterior surface of the tibia and joins the popliteal vein. The **fibular vein** drains the muscles and integument in proximity to the fibula and joins the posterior tibial vein. The **small saphenous vein**

located on the lateral surface of the leg drains blood from the superficial regions of the lower leg and foot, and flows into to the **popliteal vein**. As the popliteal vein passes behind the knee in the popliteal region, it becomes the femoral vein. It is palpable in patients without excessive adipose tissue.

Close to the body wall, the great saphenous vein, the deep femoral vein, and the femoral circumflex vein drain into the femoral vein. The **great saphenous vein** is a prominent surface vessel located on the medial surface of the leg and thigh that collects blood from the superficial portions of these areas. The **deep femoral vein**, as the name suggests, drains blood from the deeper portions of the thigh. The **femoral circumflex vein** forms a loop around the femur just inferior to the trochanters and drains blood from the areas in proximity to the head and neck of the femur.

As the **femoral vein** penetrates the body wall from the femoral portion of the lower limb, it becomes the **external iliac vein**, a large vein that drains blood from the leg to the common iliac vein. The pelvic organs and integument drain into the **internal iliac vein**, which forms from several smaller veins in the region, including the umbilical veins that run on either side of the bladder. The external and internal iliac veins combine near the inferior portion of the sacroiliac joint to form the common iliac vein. In addition to blood supply from the external and internal iliac veins, the **middle sacral vein** drains the sacral region into the **common iliac vein**. Similar to the common iliac arteries, the common iliac veins come together at the level of L5 to form the inferior vena cava.

Figure 18.3.20 is a flow chart of veins flowing into the lower limb. Table 18.3.14 summarizes the major veins of the lower limbs.

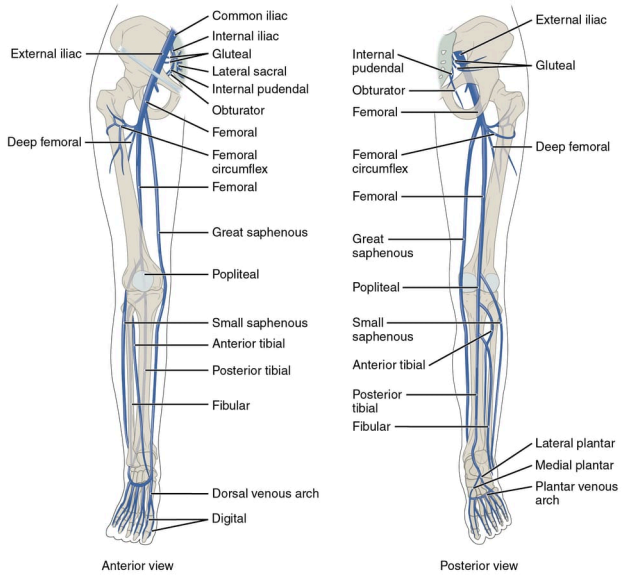

Figure 18.3.22: Major Veins Serving the Lower Limbs. Anterior and posterior views show the major veins that drain the lower limb into the inferior vena cava. (Image credit: "Lower Limb Veins Anterior Posterior" by OpenStax is licensed under CC BY 3.0)

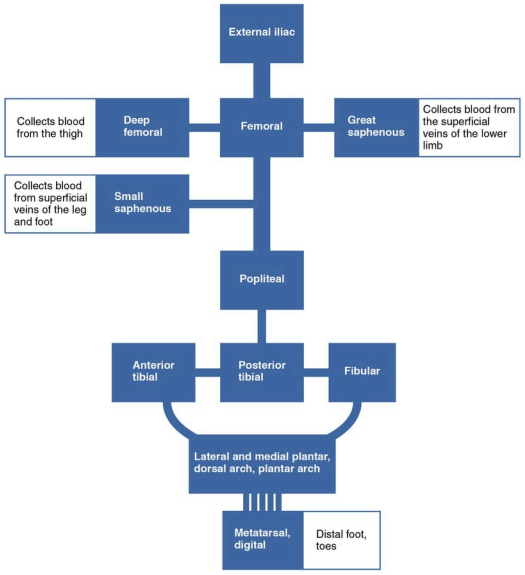

Figure 18.3.23: Major Veins of the Lower Limb. The flow chart summarizes venous flow from the lower limb. (Image credit: "Lower Limb Veins Chart" by OpenStax is licensed under CC BY 3.0)

Table* 18.3.14*: Veins of the Lower Limbs

Vessel	Description	Image
Anterior tibial vein	Formed from the dorsal venous arch; drains the area near the tibialis anterior muscle and flows into the popliteal vein	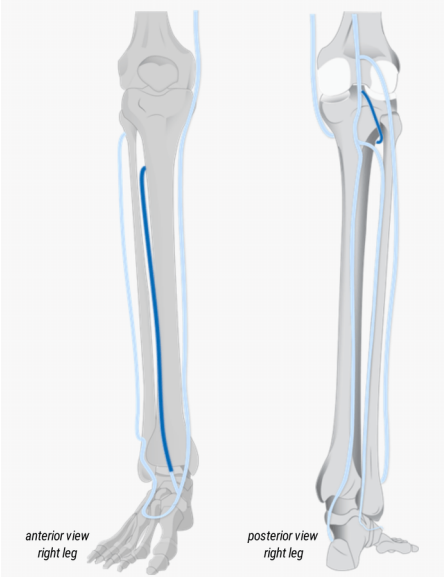 **Image Credit** *University of British Columbia Clinical Anatomy*, *CC BY-NC-SA 4.0*

Vessel	Description	Image
Posterior tibial vein	Formed from the dorsal venous arch; drains the area near the posterior surface of the tibia and flows into the popliteal vein	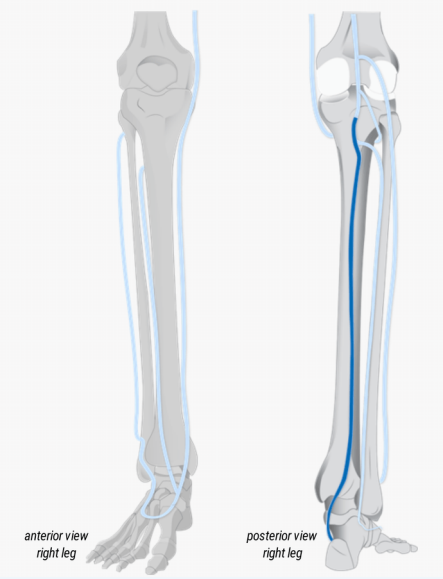 **Image Credit** *University of British Columbia Clinical Anatomy*, *CC BY-NC-SA 4.0*
Fibular vein	Drains the muscles and integument near the fibula and flows into the posterior tibial vein	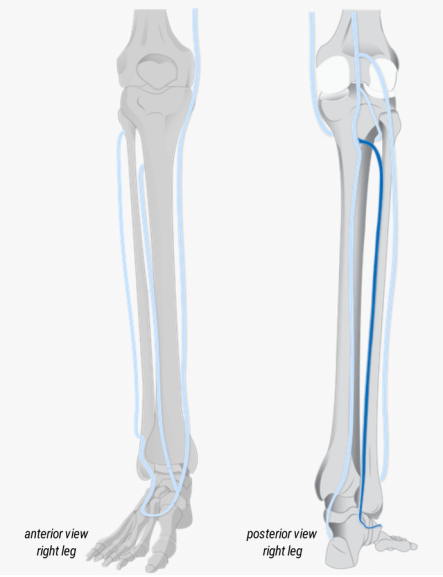 **Image Credit** *University of British Columbia Clinical Anatomy*, *CC BY-NC-SA 4.0*

Vessel	Description	Image
Small saphenous vein	Located on the lateral surface of the leg; drains blood from the superficial regions of the lower leg and foot, and flows into the popliteal vein	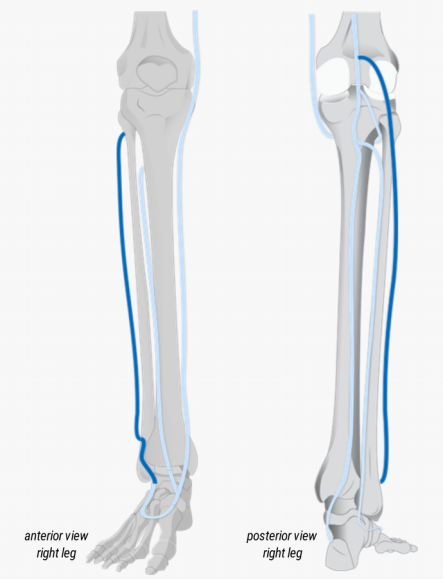 **Image Credit** *University of British Columbia Clinical Anatomy*, *CC BY-NC-SA 4.0*
Popliteal vein	Drains the region behind the knee and forms from the fusion of the fibular, anterior, and posterior tibial veins; flows into the femoral vein	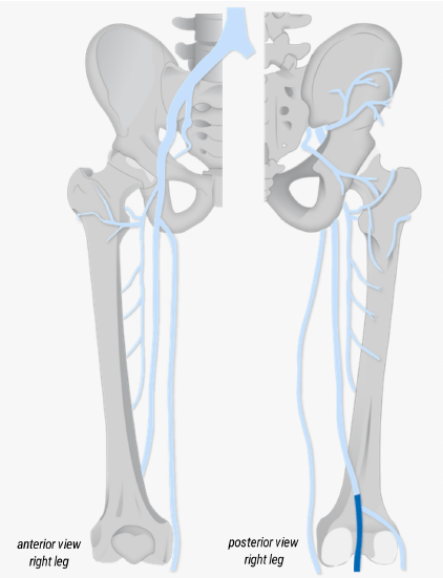 **Image Credit** *University of British Columbia Clinical Anatomy*, *CC BY-NC-SA 4.0*

Vessel	Description	Image
Great saphenous vein	Prominent surface vessel located on the medial surface of the leg and thigh; drains the superficial portions of these areas and flows into the femoral vein	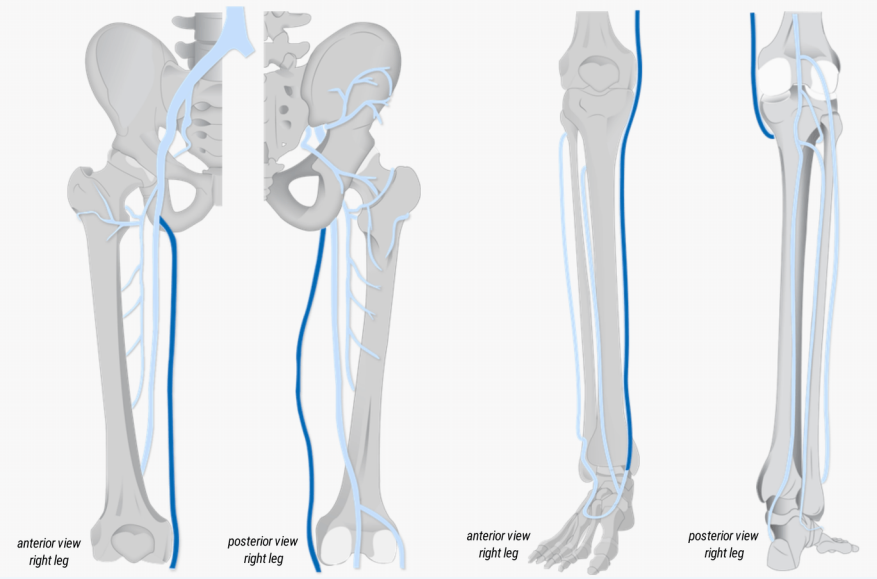 **Image Credit** *University of British Columbia Clinical Anatomy*, *CC BY-NC-SA 4.0*
Deep femoral vein	Drains blood from the deeper portions of the thigh and flows into the femoral vein	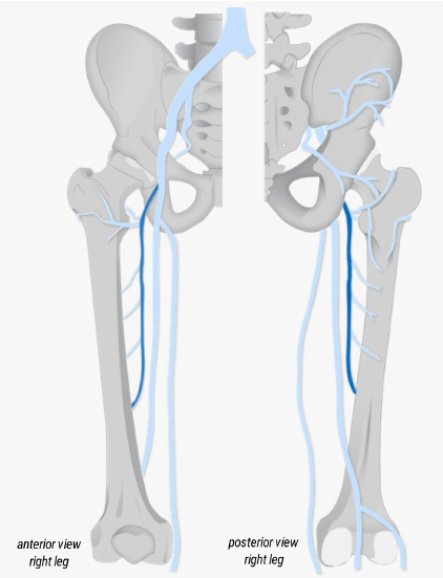 **Image Credit** *University of British Columbia Clinical Anatomy*, *CC BY-NC-SA 4.0*

Vessel	Description	Image
Femoral vein	Drains the upper leg; receives blood from the great saphenous vein, the deep femoral vein, and the femoral circumflex vein; becomes the external iliac vein when it crosses the body wall	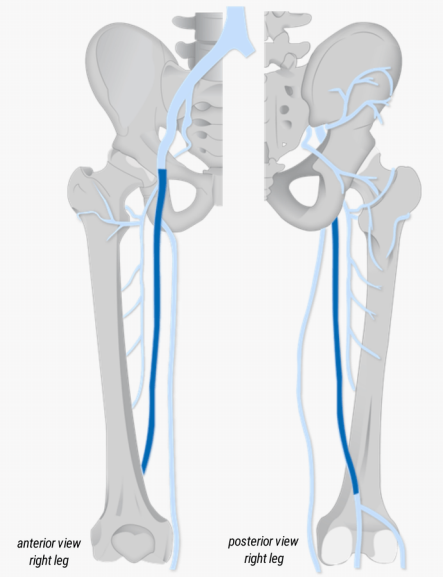 **Image Credit** *University of British Columbia Clinical Anatomy*, *CC BY-NC-SA 4.0*
External iliac vein	Formed when the femoral vein passes into the body cavity; drains the legs and flows into the common iliac vein	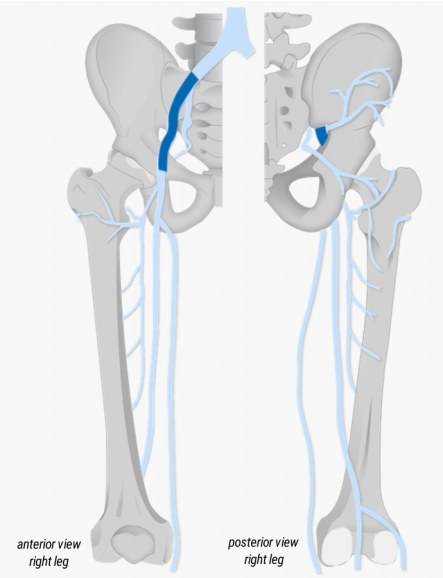 **Image Credit** *University of British Columbia Clinical Anatomy*, *CC BY-NC-SA 4.0*

Vessel	Description	Image
Internal iliac vein	Drains the pelvic organs and integument; formed from several smaller veins in the region; flows into the common iliac vein	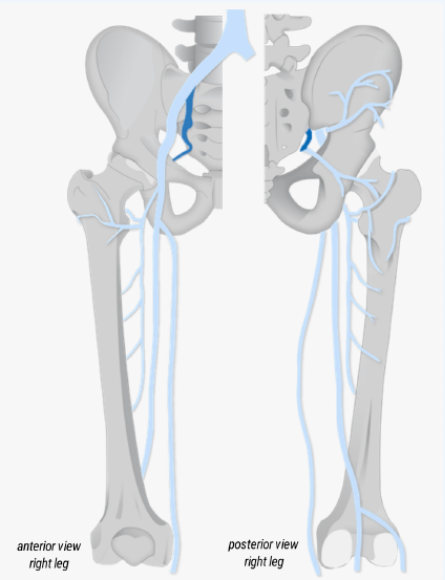 **Image Credit** *University of British Columbia Clinical Anatomy*, *CC BY-NC-SA 4.0*
Common iliac vein	Flows into the inferior vena cava at the level of L5; the left common iliac vein drains the sacral region; formed from the union of the external and internal iliac veins near the inferior portion of the sacroiliac joint	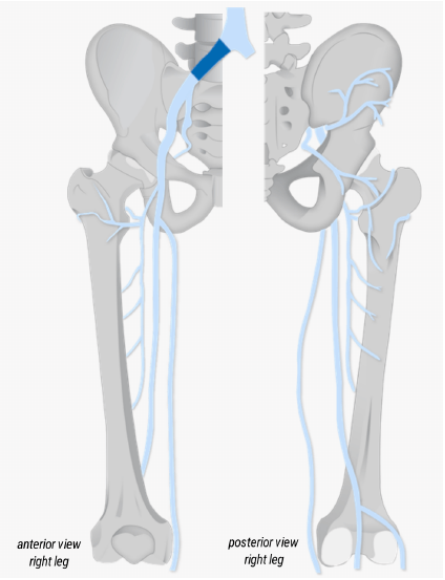 **Image Credit** *University of British Columbia Clinical Anatomy*, *CC BY-NC-SA 4.0*

Hepatic Portal System

The liver is a complex biochemical processing plant. It packages nutrients absorbed by the digestive system; produces plasma proteins, clotting factors, and bile; and disposes of worn-out cell components and waste products. Instead of entering the

circulation directly, absorbed nutrients and certain wastes (for example, materials produced by the spleen) travel to the liver for processing. They do so via the **hepatic portal system** (Figure 18.3.21). Portal systems begin and end in capillaries (two capillary beds are found in series between the arterial and venous sides of the circuit). In this case, the initial capillaries from the stomach, small intestine, large intestine, and spleen lead to the hepatic portal vein and end in specialized capillaries within the liver, the hepatic sinusoids. The hypothalamic-hypophyseal portal system is covered in the endocrine chapter.

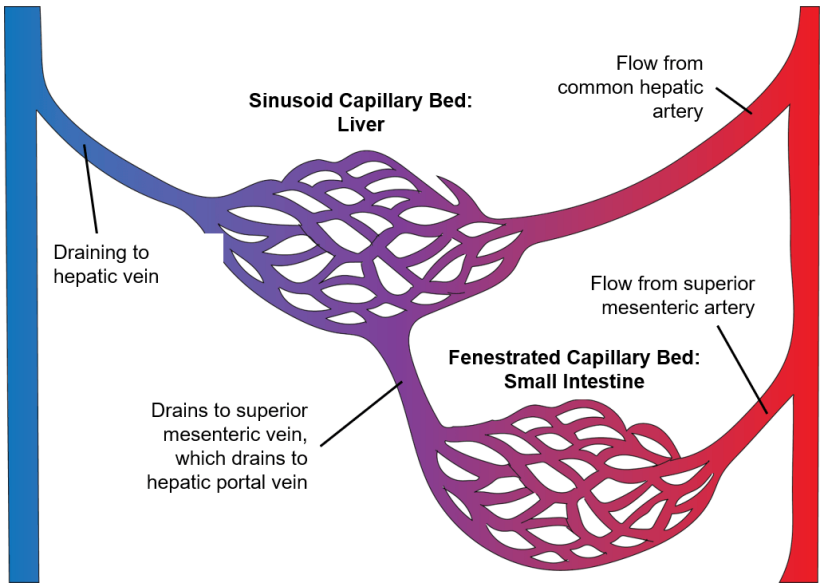

Figure 18.3.24: Hepatic Portal System. The liver receives blood from normal systemic circulation via the hepatic artery. It also receives and processes blood from other organs, delivered via the veins of the hepatic portal system. All blood exits the liver via the hepatic vein, which delivers the blood to the inferior vena cava. ("Hepatic Portal System" by Julie Jenks is a derivative of the original work by Daniel Donnelly and is licensed under CC BY 4.0)

The hepatic portal system consists of the hepatic portal vein and the veins that drain into it (Figure 18.3.22, Table 18.3.15). The hepatic portal vein itself is relatively short, beginning at the level of L2 with the confluence of the superior mesenteric and splenic veins. It also receives branches from the inferior mesenteric vein, plus the splenic veins and all their tributaries. The superior mesenteric vein receives blood from the small intestine, two-thirds of the large intestine, and the stomach. The inferior mesenteric vein drains the distal third of the large intestine, including the descending colon, the sigmoid colon, and the rectum. The splenic vein is formed from branches from the spleen, pancreas, and portions of the stomach, and the inferior mesenteric vein. After its formation, the hepatic portal vein also receives branches from the gastric veins of the stomach and cystic veins from the gall bladder. The hepatic portal vein delivers materials from these digestive and circulatory organs directly to the liver for processing.

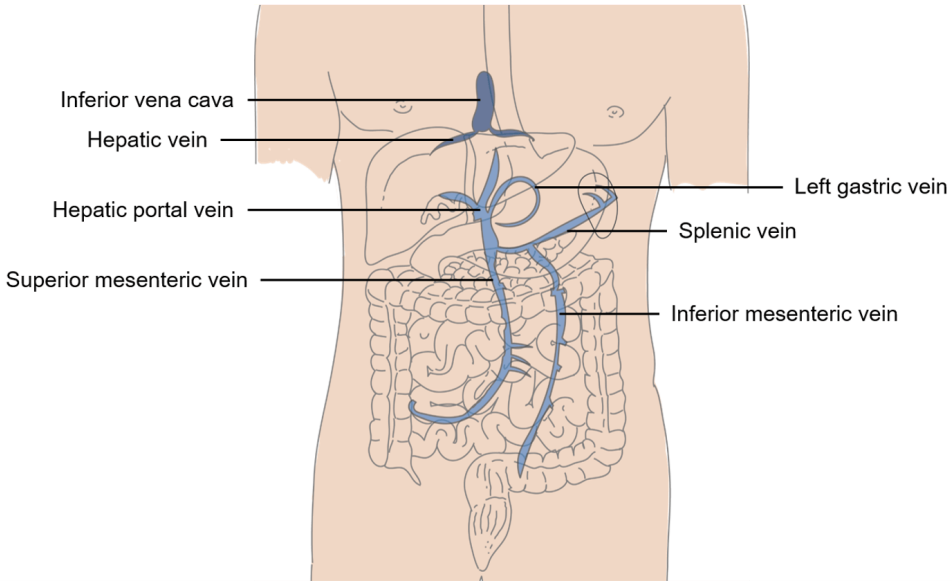

Figure 18.3.25: Veins Draining to and from Hepatic Portal System. The liver receives venous blood from many major veins draining from organs of the digestive system and the spleen. The superior mesenteric and left gastric veins drain into the hepatic portal vein. The inferior mesenteric vein drains into the splenic vein which drains into the hepatic portal vein. Venous blood drains from the liver via the hepatic veins into the inferior vena cava. ("Veins Draining to and from Hepatic Portal System" by Julie Jenks is a derivative of the original work by Daniel Donnelly and is licensed under CC BY 4.0)

Table 18.3.15 Veins of the Hepatic Portal System

Vessel	Description
Splenic vein	Drains blood from the spleen, stomach, and pancreas into the hepatic portal vein
Left gastric vein	Drains blood from the stomach into the hepatic portal vein
Inferior mesenteric vein	Drains blood from the distal part of large intestine into splenic vein
Superior mesenteric vein	Drains blood from the small intestine and proximal part of the large intestine into the hepatic portal vein
Hepatic portal vein	Drains blood from splenic vein, left gastric vein, and superior mesenteric vein into the sinusoid capillaries in the lobules of the liver

Because of the hepatic portal system, the liver receives its blood supply from two different sources: from normal systemic circulation via the hepatic artery and from the hepatic portal vein. The liver processes the blood from the portal system to remove certain wastes and excess nutrients, which are stored for later use. This processed blood, as well as the systemic blood that came from the hepatic artery, exits the liver via the right, left, and middle hepatic veins, and flows into the inferior vena cava. Overall systemic blood composition remains relatively stable, since the liver is able to metabolize the absorbed digestive components.

Concept Review

The right ventricle pumps oxygen-depleted blood into the pulmonary trunk and right and left pulmonary arteries, which carry it to the right and left lungs for gas exchange. Oxygen-rich blood is transported by pulmonary veins to the left atrium. The left ventricle pumps this blood into the aorta. The main regions of the aorta are the ascending aorta, aortic arch, and descending aorta, which is further divided into the thoracic and abdominal aorta. The coronary arteries branch from the ascending aorta. After oxygenating tissues in the capillaries, systemic blood is returned to the right atrium from the venous system via the superior vena cava, which drains most of the veins superior to the diaphragm, the inferior vena cava, which drains most of the veins inferior to the diaphragm, and the coronary veins via the coronary sinus. The hepatic portal system carries blood to the liver for processing before it enters circulation. Review the figures provided in this section for circulation of blood through the blood vessels.

Review Questions

Query 18.3.1

This interactive element is not available in this format. Visit the link or scan the QR code to access it online.

View this Interactive Content online

Critical Thinking Questions

Query 18.3.2

This interactive element is not available in this format. Visit the link or scan the QR code to access it online.

View this Interactive Content online

Query 18.3.3

This interactive element is not available in this format. Visit the link or scan the QR code to access it online.

View this Interactive Content online

Query 18.3.4

This interactive element is not available in this format. Visit the link or scan the QR code to access it online.

View this Interactive Content online

Glossary

Query 18.3.5

This interactive element is not available in this format. Visit the link or scan the QR code to access it online.

View this Interactive Content online

Contributors and Attributions

- OpenStax Anatomy & Physiology (CC BY 4.0). Access for free at https://openstax.org/books/anatomy-and-physiology

This page titled 18.3: Circulatory Pathways is shared under a CC BY-NC-SA 4.0 license and was authored, remixed, and/or curated by Jennifer Lange et al..

- 18.3: Circulatory Pathways by Whitney Menefee, Julie Jenks, Chiara Mazzasette, and Kim-Leiloni Nguyen is licensed CC BY 4.0.

18.4: Development of Blood Vessels and Fetal Circulation

By the end of this section, you will be able to:

- Describe the development of blood vessels
- Distinguish fetal circulation from newborn circulation

In a developing embryo, the heart has developed enough by day 21 post-fertilization to begin beating. Circulation patterns are clearly established by the fourth week of embryonic life. It is critical to the survival of the developing human that the circulatory system forms early to supply the growing tissue with nutrients and gases, and to remove waste products. Blood cells and vessel production in structures outside the embryo proper called the yolk sac, chorion, and connecting stalk begin about 15 to 16 days following fertilization. Development of these circulatory elements within the embryo itself begins approximately 2 days later. During those first few weeks, blood vessels begin to form from the embryonic mesoderm. The precursor cells are known as **hemangioblasts**. These in turn differentiate into **angioblasts**, which give rise to the blood vessels and pluripotent stem cells, which differentiate into the formed elements of blood. Together, these cells form masses known as **blood islands** scattered throughout the embryonic disc. Spaces appear on the blood islands that develop into vessel lumens. The endothelial lining of the vessels arise from the angioblasts within these islands. Surrounding mesenchymal cells give rise to the smooth muscle and connective tissue layers of the vessels. While the vessels are developing, the pluripotent stem cells begin to form the blood.

Vascular tubes also develop on the blood islands, and they eventually connect to one another as well as to the developing, tubular heart. Thus, the developmental pattern, rather than beginning from the formation of one central vessel and spreading outward, occurs in many regions simultaneously with vessels later joining together. This **angiogenesis**—the creation of new blood vessels from existing ones—continues as needed throughout life as we grow and develop.

Blood vessel development often follows the same pattern as nerve development. This occurs because the many factors directing growth of nerves also stimulate blood vessels to grow near the nerves in the same area. Whether a given vessel develops into an artery or a vein is dependent upon local concentrations of signaling proteins.

As the embryo grows within the mother's uterus, its requirements for nutrients and gas exchange also grow. The placenta—a circulatory organ unique to pregnancy—develops jointly from the embryo and uterine wall structures to fill this need. Emerging from the placenta is the **umbilical vein**, which carries oxygen-rich blood from the mother to the fetal inferior vena cava via the ductus venosus to the heart that pumps it into fetal circulation. Two **umbilical arteries** carry oxygen-depleted fetal blood, including wastes and carbon dioxide, to the placenta. Remnants of the umbilical arteries remain in the adult as the medial umbilical ligaments.

There are three major shunts—alternate paths for blood flow—found in the circulatory system of the fetus. Two of these shunts divert blood from the pulmonary to the systemic circuit, whereas the third connects the umbilical vein to the inferior vena cava. The first two shunts are critical during fetal life, when the lungs are compressed, filled with amniotic fluid, and nonfunctional, and gas exchange is provided by the placenta. These shunts close shortly after birth, however, when the newborn begins to breathe. The third shunt persists a bit longer but becomes nonfunctional once the umbilical cord is severed. The three shunts are as follows (Figure 18.4.1):

- The **foramen ovale** is an opening in the interatrial septum that allows blood to flow from the right atrium to the left atrium. A valve associated with this opening prevents backflow of blood during the fetal period. As the newborn begins to breathe and blood pressure in the atria increases, this shunt closes. The fossa ovalis remains in the interatrial septum after birth, marking the location of the former foramen ovale.
- The **ductus arteriosus** is a short, muscular vessel that connects the pulmonary trunk to the aorta. Most of the blood pumped from the right ventricle into the pulmonary trunk is thereby diverted into the aorta. Only enough blood reaches the fetal lungs to maintain the developing lung tissue. When the newborn takes the first breath, pressure within the lungs drops dramatically, and both the lungs and the pulmonary vessels expand. As the amount of oxygen increases, the smooth muscles in the wall of the ductus arteriosus constrict, sealing off the passage. Eventually, the muscular and endothelial components of the ductus arteriosus degenerate, leaving only the connective tissue component of the ligamentum arteriosum.
- The **ductus venosus** is a temporary blood vessel that branches from the umbilical vein, allowing much of the freshly oxygenated blood from the placenta—the organ of gas exchange between the mother and fetus—to bypass the fetal liver and go directly to the fetal heart. The ductus venosus closes slowly during the first weeks of infancy and degenerates to become

the ligamentum venosum.

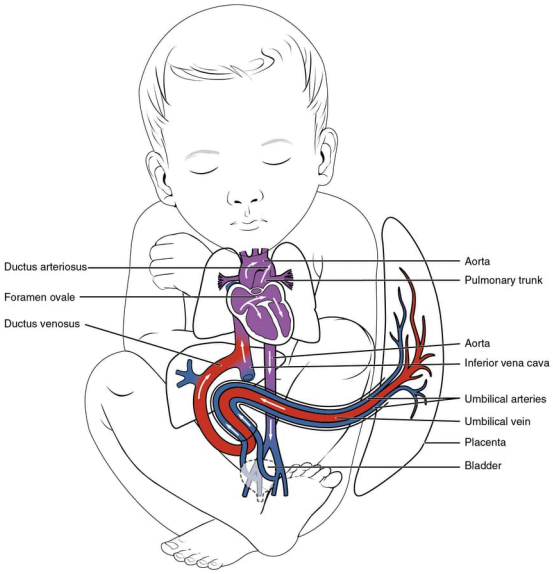

Figure 18.4.1: Fetal Shunts. The foramen ovale in the interatrial septum allows blood to flow from the right atrium to the left atrium. The ductus arteriosus is a temporary vessel, connecting the aorta to the pulmonary trunk. The ductus venosus links the umbilical vein to the inferior vena cava largely through the liver. (Image credit: "Fetal Circulation" by OpenStax is licensed under CC BY 3.0)

Concept Review

Blood vessels begin to form from the embryonic mesoderm. The precursor hemangioblasts differentiate into angioblasts, which give rise to the blood vessels and pluripotent stem cells that differentiate into the formed elements of the blood. Together, these cells form blood islands scattered throughout the embryo. Extensions known as vascular tubes eventually connect the vascular network. As the embryo grows within the mother's womb, the placenta develops to supply blood rich in oxygen and nutrients via the umbilical vein and to remove wastes in oxygen-depleted blood via the umbilical arteries. Three major shunts found in the fetus are the foramen ovale and ductus arteriosus, which divert blood from the pulmonary to the systemic circuit, and the ductus venosus, which carries freshly oxygenated blood high in nutrients from the placenta to the fetal heart.

Review Questions

Query 18.4.1

This interactive element is not available in this format. Visit the link or scan the QR code to access it online.

View this Interactive Content online

Critical Thinking Questions

Query 18.4.2

This interactive element is not available in this format. Visit the link or scan the QR code to access it online.

View this Interactive Content online

Query 18.4.3

This interactive element is not available in this format. Visit the link or scan the QR code to access it online.

View this Interactive Content online

Query 18.4.4

This interactive element is not available in this format. Visit the link or scan the QR code to access it online.

View this Interactive Content online

Glossary

Query 18.4.5

This interactive element is not available in this format. Visit the link or scan the QR code to access it online.

View this Interactive Content online

Contributors and Attributions

- OpenStax Anatomy & Physiology (CC BY 4.0). Access for free at https://openstax.org/books/anatomy-and-physiology

---

This page titled 18.4: Development of Blood Vessels and Fetal Circulation is shared under a CC BY-NC-SA 4.0 license and was authored, remixed, and/or curated by Jennifer Lange et al..

- 18.4: Development of Blood Vessels and Fetal Circulation by Whitney Menefee, Julie Jenks, Chiara Mazzasette, and Kim-Leiloni Nguyen is licensed CC BY 4.0.

18.5: Anatomical Atlas - Blood Vessels and Circulation

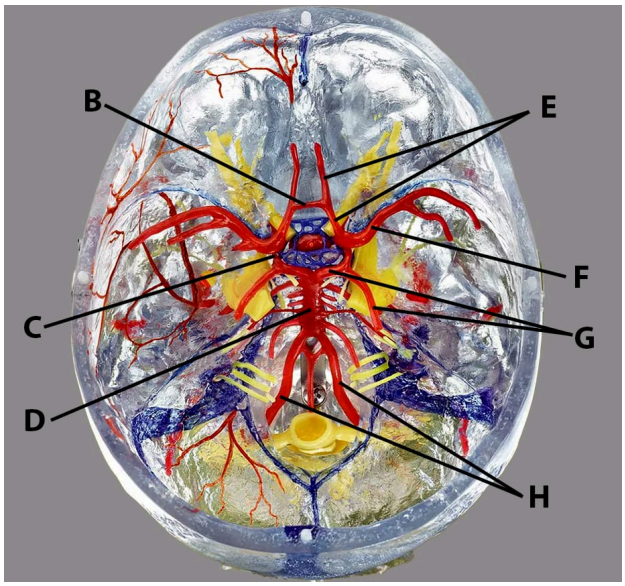

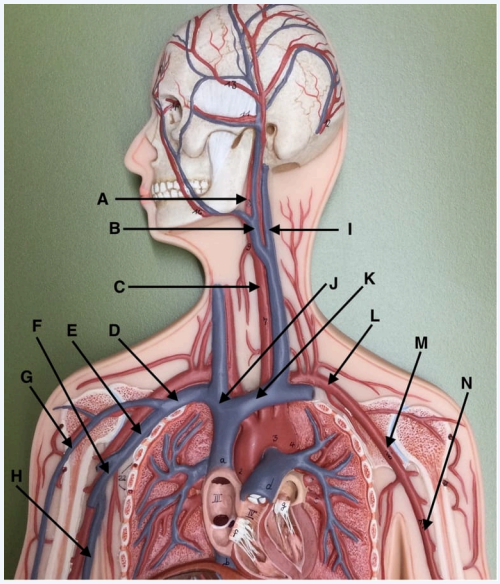

Image Credit

"Blood Vessels - Flat Model - Atlas 1" by Jennifer Lange is licensed under CC BY-NC-SA 4.0.

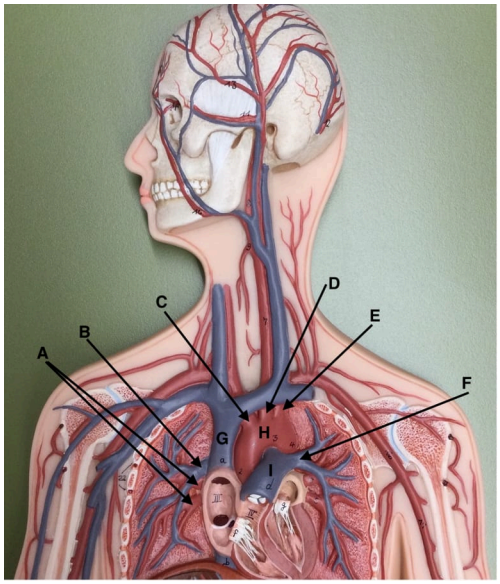

Image Credit

"Blood Vessels - Flat Model - Atlas 2" by Jennifer Lange is licensed under CC BY-NC-SA 4.0.

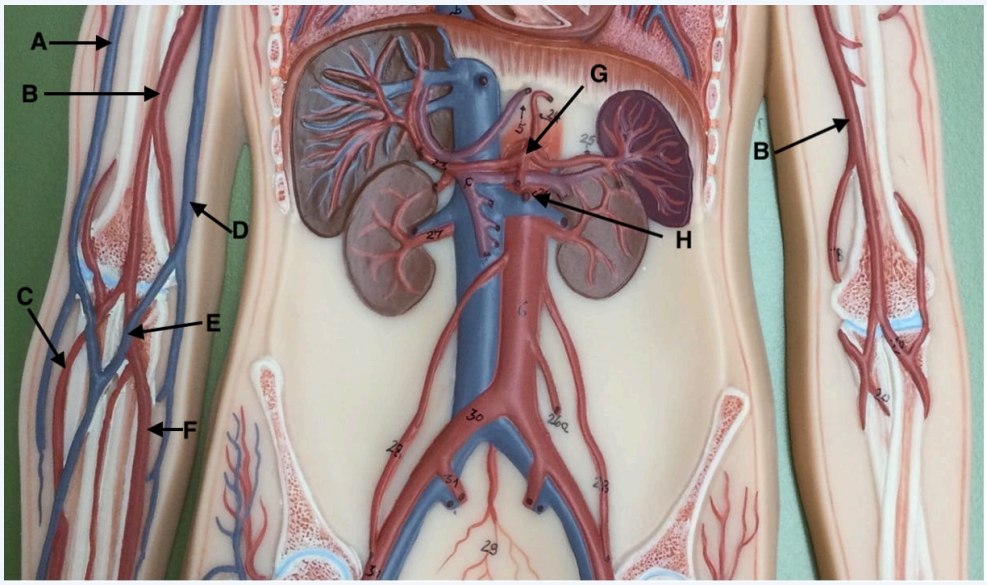

Image Credit

"Blood Vessels - Flat Model - Atlas 3" by Jennifer Lange is licensed under CC BY-NC-SA 4.0.

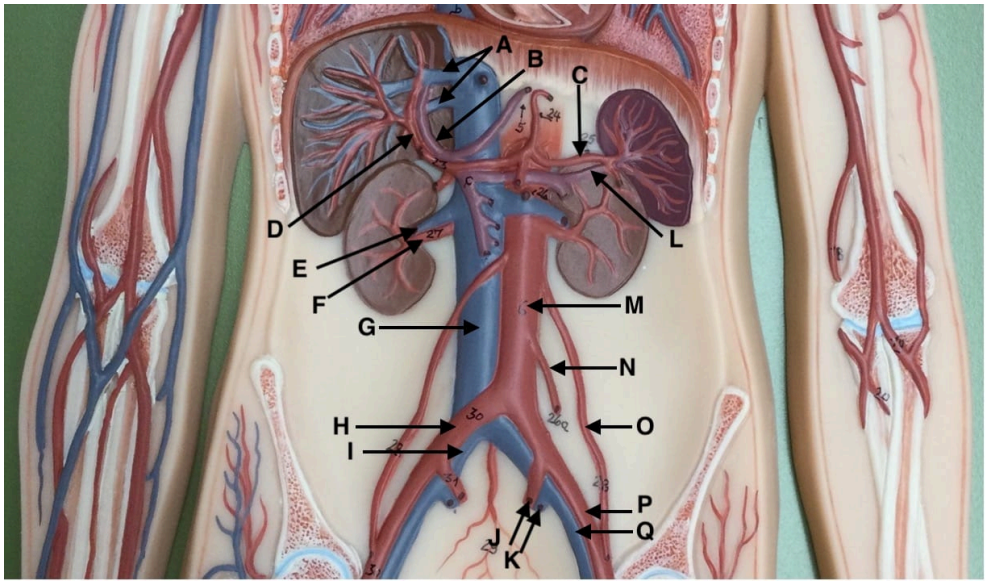

Image Credit

"Blood Vessels - Flat Model - Atlas 4" by Jennifer Lange is licensed under CC BY-NC-SA 4.0.

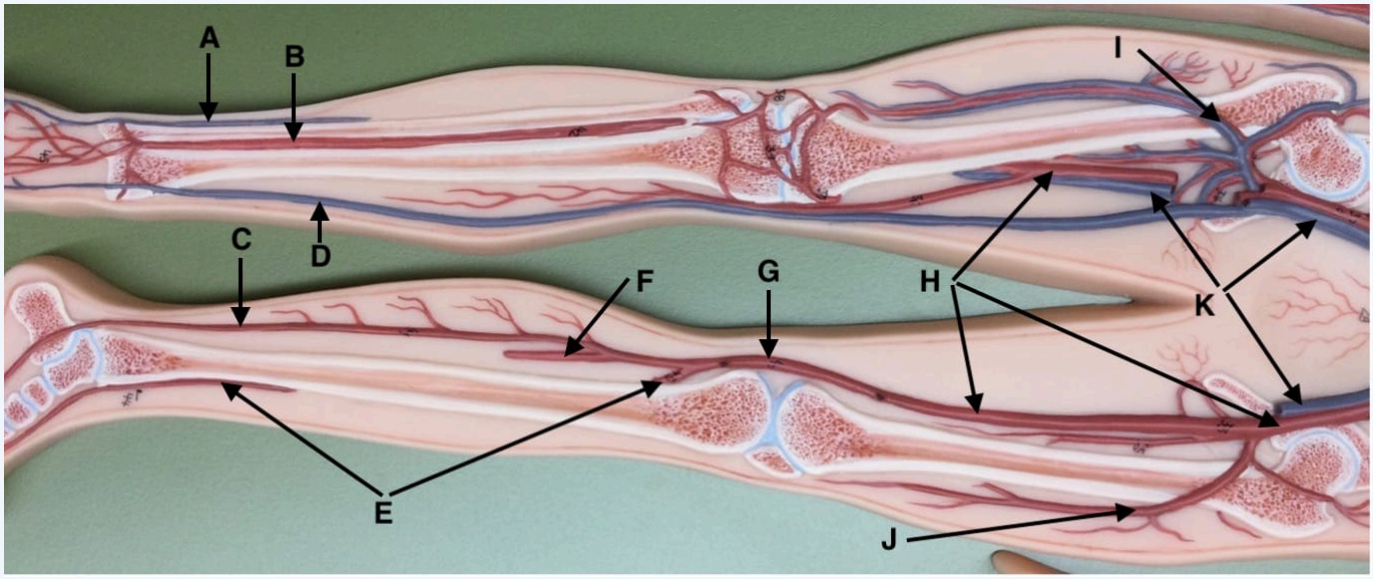

Image Credit

"Blood Vessels - Flat Model - Atlas 5" by Jennifer Lange is licensed under CC BY-NC-SA 4.0.

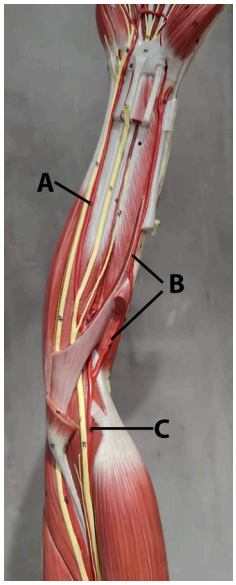

Image Credit

"Arteries of the Upper Limb - Atlas" by Jennifer Lange is licensed under CC BY-NC-SA 4.0.

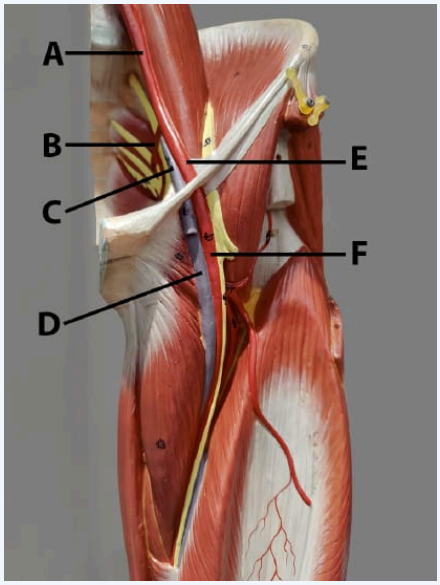

Image Credit

"Blood Vessels of the Pelvis and Thigh, Anterior View - Atlas" by Jennifer Lange is licensed under CC BY-NC-SA 4.0.

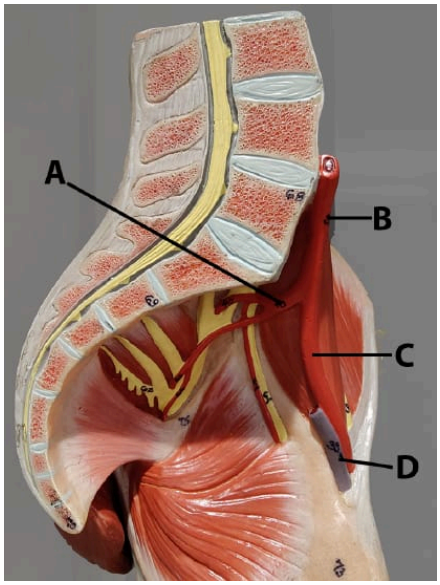

Image Credit

"Blood Vessels Pelvis, Medial View - Atlas" by Jennifer Lange is licensed under CC BY-NC-SA 4.0.

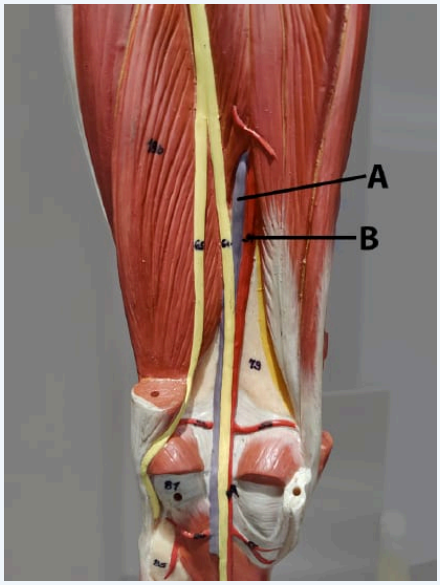

Image Credit

"Blood Vessels Posterior Knee - Atlas by Jennifer Lange is licensed under CC BY-NC-SA 4.0.

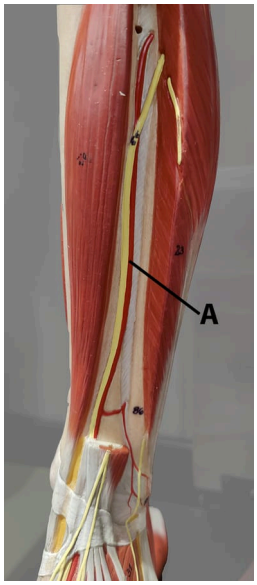

Image Credit

"Blood Vessels of Anterior Leg" by Jennifer Lange is licensed under CC BY-NC-SA 4.0.

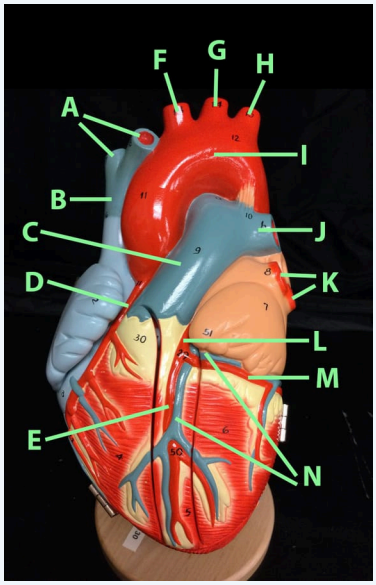

Image Credit

"Blood Vessels on Heart Model" by Jennifer Lange is licensed under CC BY-NC-SA 4.0.

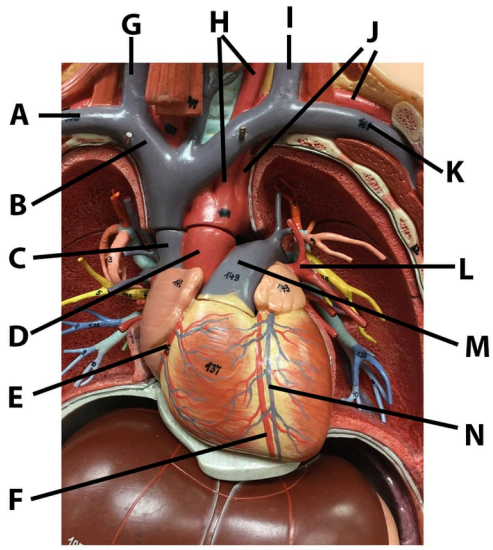

Image Credit

"Blood Vessels of Torso Model Thorax - Atlas" by Jennifer Lange is licensed under CC BY-NC-SA 4.0.

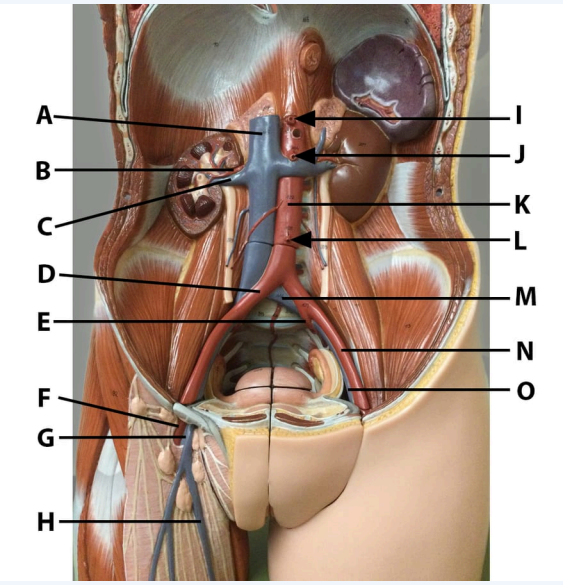

Image Credit

"Blood Vessels of Torso Model Abdominopelvic - Atlas" by Jennifer Lange is licensed under CC BY-NC-SA 4.0.

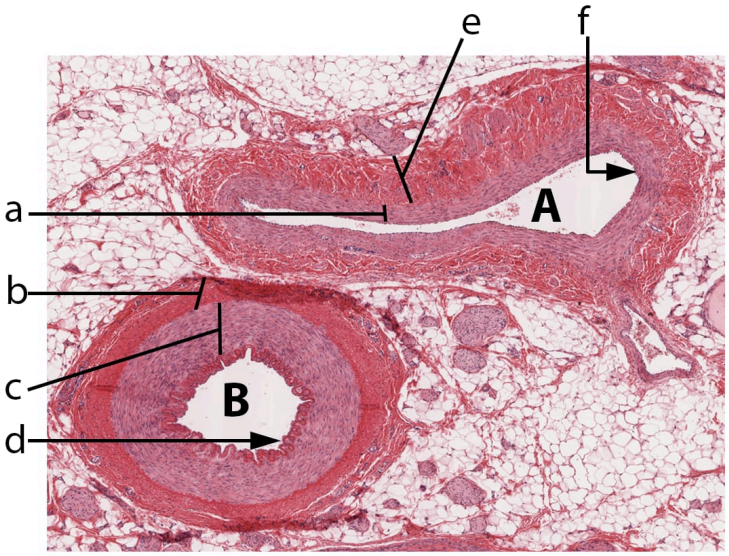

Image Credit

"Histology of Artery and Vein @ 100x - Atlas" by Jennifer Lange is licensed under CC BY-NC-SA 4.0, slide provided by the Regents of the University of Michigan Medical School © 2022.

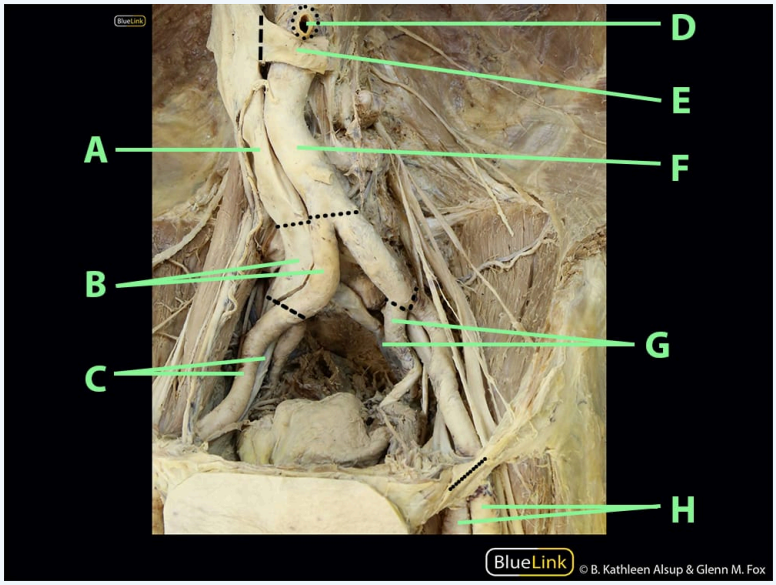

Image Credit

"Blood Vessels of the Pelvis - Atlas" by BlueLink is licensed under CC BY-NC 4.0 with notification of the original authors, labeling by Jennifer Lange.)

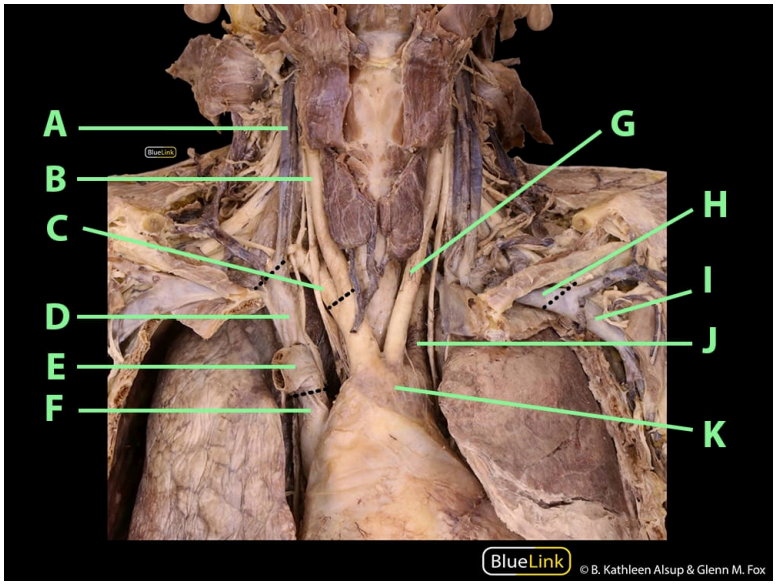

Image Credit

"Blood Vessels of Mediastinum and Root of the Neck - Atlas" by BlueLink is licensed under CC BY-NC 4.0 with notification of the original authors, labeling by Jennifer Lange.)

This page titled 18.5: Anatomical Atlas - Blood Vessels and Circulation is shared under a CC BY-NC-SA 4.0 license and was authored, remixed, and/or curated by Jennifer Lange et al..

18.6: Practice Practical- Blood Vessels and Circulation

Answer the following questions by writing your answer on the space provided.

Query 18.6.1

This interactive element is not available in this format. Visit the link or scan the QR code to access it online.

View this Interactive Content online

Query 18.6.1

This interactive element is not available in this format. Visit the link or scan the QR code to access it online.

View this Interactive Content online

Query 18.6.1

This interactive element is not available in this format. Visit the link or scan the QR code to access it online.

View this Interactive Content online

Query 18.6.1

This interactive element is not available in this format. Visit the link or scan the QR code to access it online.

View this Interactive Content online

Query 18.6.1

This interactive element is not available in this format. Visit the link or scan the QR code to access it online.

View this Interactive Content online

Query 18.6.1

This interactive element is not available in this format. Visit the link or scan the QR code to access it online.

View this Interactive Content online

Query 18.6.1

This interactive element is not available in this format. Visit the link or scan the QR code to access it online.

View this Interactive Content online



Query 18.6.1

This interactive element is not available in this format. Visit the link or scan the QR code to access it online.

View this Interactive Content online

Query 18.6.1

This interactive element is not available in this format. Visit the link or scan the QR code to access it online.

View this Interactive Content online

Query 18.6.1

This interactive element is not available in this format. Visit the link or scan the QR code to access it online.

View this Interactive Content online

This page titled 18.6: Practice Practical- Blood Vessels and Circulation is shared under a CC BY-NC-SA 4.0 license and was authored, remixed, and/or curated by Jennifer Lange et al..

19: LYMPHATIC SYSTEM

19.1: Introduction to the Lymphatic System
19.2: Functions of the Lymphatic System
19.3: Anatomy of Lymphatic Vessels
19.4: Anatomy of Lymphatic Organs and Tissues
19.5: Anatomical Atlas - Lymphatic System
19.6: Practice Practical- Lymphatic System

This page titled 19: Lymphatic System is shared under a CC BY-NC-SA 4.0 license and was authored, remixed, and/or curated by Jennifer Lange et al..

- 19: Lymphatic and Immune System by Whitney Menefee, Julie Jenks, Chiara Mazzasette, and Kim-Leiloni Nguyen is licensed CC BY 4.0.

19.1: Introduction to the Lymphatic System

Chapter Learning Objectives:

After studying this chapter, you will be able to:

- Explain the location, structure, and function of the components of the lymphatic system
- Discuss the integration of the lymphatic system with other body systems
- Explain how the structure and organization of lymphatic vessels and lymph nodes are suited to their functions

The lymphatic system is integrated within each of the body's systems through a network of vessels that carry fluid, called lymph, from the body tissues to the blood to assist in maintaining fluid homeostasis. These vessels also provide a means by which fats absorbed by the intestines eventually enter the blood. Along these vessels are nodes containing white blood cells that filter the lymph fluid to detect and mount an immune response to infections. Other organs and tissues of the lymphatic system, such as the spleen, the thymus gland, and the tonsils carry out immune functions as well.

Contributors and Attributions

- OpenStax Anatomy & Physiology (CC BY 4.0). Access for free at https://openstax.org/books/anatomy-and-physiology

This page titled 19.1: Introduction to the Lymphatic System is shared under a CC BY-NC-SA 4.0 license and was authored, remixed, and/or curated by Jennifer Lange et al..

- 19.1: Introduction to the Lymphatic and Immune Systems by Whitney Menefee, Julie Jenks, Chiara Mazzasette, and Kim-Leiloni Nguyen is licensed CC BY 4.0.

19.2: Functions of the Lymphatic System

By the end of this section, you will be able to:

- Explain the overall functions of the lymphatic system

Functions of the Lymphatic System

The functions of the lymphatic system are integral to the immune system because structures of the lymphatic system function to produce, develop, house and distribute leukocytes, but the lymphatic system also supports other body systems in a couple of ways. A network of lymphatic vessels provide a one-way route to return excess fluid from tissues back to the bloodstream to maintain blood volume and also distribute leukocytes throughout the body. Along the way, the fluid is filtered for pathogens and debris as it passes through lymph nodes. Lymphatic capillaries serving the small intestine also collect lipid products of digestion that are too large to enter blood capillaries. These lipids are transported to the bloodstream via the lymphatic vessels. Lymph is the watery fluid connective tissue found in lymphatic vessels whose cellular components include primarily lymphocytes along with phagocytic macrophages and other specialized leukocytes. The watery matrix of lymph is similar to the plasma of blood; it contains dissolved nutrients, waste products, and plasma proteins.

Lymphoid tissues and organs are so-called because they contain fluid that resembles lymph, and they support lymphocyte production, development, storage, and functions in a variety of locations in the body. Dense collections of leukocytes suspended in reticular connective tissue that remove debris and fight infection within organs of other body systems constitute lymphoid tissues such as the tonsils and mucosa-associated lymphoid tissues (MALT). The lymphatic system also includes distinct organs that support the immune system including the thymus, spleen, and red bone marrow. The vessels, tissues, and organs of the lymphatic system are summarized in Figure 19.2.1 and Table 19.2.1 and will be covered in more detail in subsequent sections of this chapter.

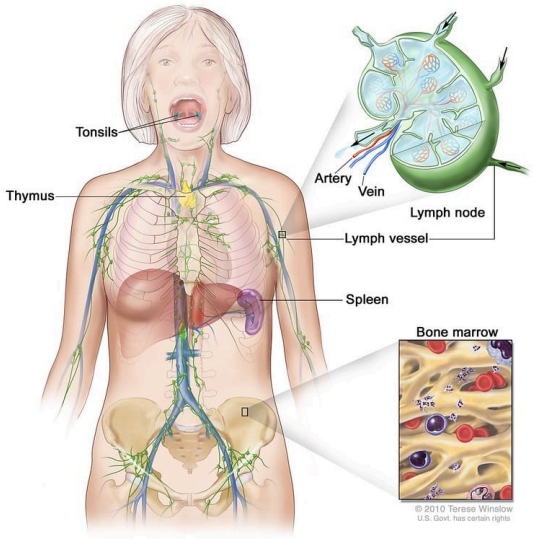

Figure 19.2.1: Lymphatic System. Lymphatic vessels, with lymph nodes along their length, as well as the tonsils, thymus, spleen, and red bone marrow are all organs of the lymphatic system. (Image credit: "Lymphatic System" by Terese Winslow, commissioned by NIH National Cancer Institute, is licensed under CC-BY-NC 2.0.)

Table 19.2.1. Structures of the Lymphatic System

Structure	Examples	Functions
Lymphatic Vessels	Lymphatic capillaries, vessels, trunks, and ducts containing lymph	• Return excess fluid from tissues to the bloodstream • Distribute lymphocytes and other leukocytes throughout the body • Transport lipid products of digestion to the bloodstream
Lymphoid Tissues	Tonsils, Mucosa-Associated Lymphoid Tissue (MALT)	• Support lymphocyte production, storage, and distribution
Lymphoid Organs	Lymph Nodes, Thymus, Red Bone Marrow, Spleen	• Support lymphocyte production, storage, and distribution • Filter blood and lymph of debris, abnormal cells, and pathogens

Concept Review

Structures of the lymphatic system support immune system function, but also carry out other specific functions. Lymphatic structures include vessels, tissues, and distinct organs.

Review Questions

Query 19.2.1

This interactive element is not available in this format. Visit the link or scan the QR code to access it online.

View this Interactive Content online

Critical Thinking Questions

Query 19.2.2

This interactive element is not available in this format. Visit the link or scan the QR code to access it online.

View this Interactive Content online

Glossary

Query 19.2.3

This interactive element is not available in this format. Visit the link or scan the QR code to access it online.

View this Interactive Content online

Contributors and Attributions

- OpenStax Anatomy & Physiology (CC BY 4.0). Access for free at https://openstax.org/books/anatomy-and-physiology

This page titled 19.2: Functions of the Lymphatic System is shared under a CC BY-NC-SA 4.0 license and was authored, remixed, and/or curated by Jennifer Lange et al..

- 19.2: Functions of the Lymphatic and Immune Systems by Whitney Menefee, Julie Jenks, Chiara Mazzasette, and Kim-Leiloni Nguyen is licensed CC BY 4.0.

19.3: Anatomy of Lymphatic Vessels

By the end of this section, you will be able to:

- Explain the structure and function of the lymphatic vessels
- Describe the asymmetrical pattern of lymphatic drainage into the bloodstream

A significant portion of the lymphatic system is comprised of a network of lymphatic vessels routed near the blood vessels of the cardiovascular system. The lymphatic vessels function to collect and transport fluid from the tissues of the body back to the bloodstream to help maintain a consistent blood volume. They also function to collect and transport dietary lipids and some lipid-soluble vitamins from the small intestine to the bloodstream and to distribute leukocytes throughout the body for housekeeping and immune defense.

Lymphatic Vessels

The **lymphatic vessels** begin as open-ended capillaries, which feed into larger and larger lymphatic vessels, and eventually empty into the bloodstream by a series of ducts. The fluid contained within lymphatic vessels is called **lymph** (lympha means "clear water"), a watery fluid that contains lymphocytes and other types of white blood cells, as well as proteins and lipids.

Blood pressure causes leakage of fluid from the blood capillaries, resulting in the accumulation of fluid in the interstitial space—that is, spaces between individual cells in the tissues. In humans, 20 liters of plasma is released into the interstitial space of the tissues each day due to capillary filtration. Once this filtrate is out of the bloodstream and in the tissue spaces, it is referred to as interstitial fluid. Of this, 17 liters is reabsorbed directly by the blood vessels. But what happens to the remaining three liters? Lymphatic capillaries drain the excess fluid away from the tissues and carry it back to the bloodstream via the network of lymphatic vessels. Lymph is the term used to describe interstitial fluid once it has entered the lymphatic system.

This cycle of fluids from blood plasma to interstitial fluid to lymph aids in oxygen and nutrient delivery to tissues as well as waste and pathogen removal away from tissues: it ensures that the body's cells are constantly exposed to fresh fluid.

Lymphatic Capillaries

Lymphatic capillaries, also called the terminal lymphatics, are vessels where interstitial fluid enters the lymphatic system to become lymph fluid. Located in almost every tissue in the body, these vessels are typically interlaced among the blood capillaries of the circulatory system in the soft connective tissues of the body (Figure 19.3.1). Exceptions are the red bone marrow, bones, teeth, and the cornea of the eye, which do not contain lymphatic vessels.

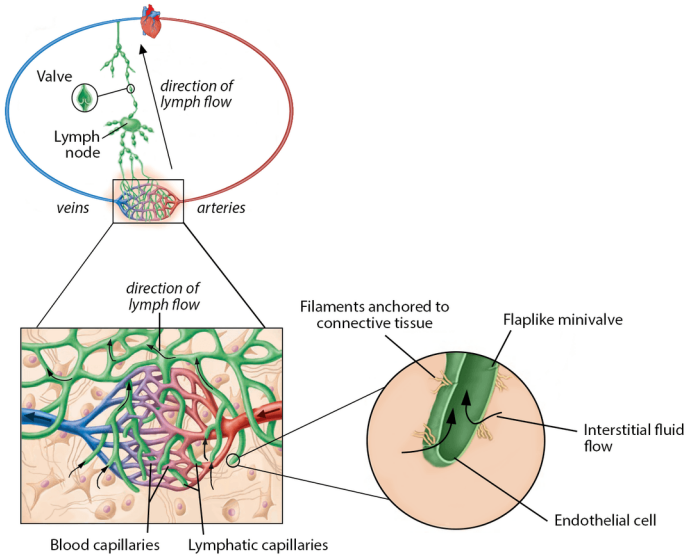

Figure 19.3.1: Lymphatic Capillaries. Lymphatic capillaries collect interstitial fluid from the body tissues, which is then returned to the venous circulation. Hydrostatic pressure allows the interstitial fluid to slip through the minivalves between the overlapping endothelial cells of the lymphatic capillary. The lymphatic capillaries are interlaced with the arterioles, blood capillaries, and venules of the cardiovascular system. Collagen fibers anchor a lymphatic capillary in the surrounding connective tissue. *(Image credit: "Lymphatic Capillaries and Vessels" by Jennifer Lange is licensed under CC BY-NC-SA 4.0, modification of original "OLI - Drawing Relationship of blood capillaries and lymphatic capillaries - English labels" by Open Learning Initiative. Heart icon from University of British Columbia Clinical Anatomy.)*

Lymphatic capillaries are formed by one simple layer of endothelial cells and represent the open end of the system, allowing interstitial fluid to flow into them via overlapping endothelial cells that form "flaps" that function like valves (see Figure 19.3.1). When interstitial fluid pressure is low, the endothelial flaps close to prevent backflow of fluid from the capillary into the tissue. As interstitial pressure increases due to an increase in excess fluid, the spaces between the endothelial cells open up, allowing the fluid to enter the lymphatic capillary. Entry of fluid into lymphatic capillaries is also enabled by the collagen fibers that anchor the capillaries to surrounding structures. As interstitial pressure increases, the fibers pull on the endothelial cell flaps, opening them further to allow easy entry of fluid.

In the small intestine, lymphatic capillaries called **lacteals** are critical for the transport of dietary lipids and lipid-soluble vitamins to the bloodstream. In the small intestine, dietary triglycerides combine with other lipids and proteins, and enter the lacteals to form a milky fluid called **chyle**. The chyle then travels through the lymphatic vessels, and drains into the bloodstream.

Larger Lymphatic Vessels, Trunks, and Ducts

Larger lymphatic vessels are similar to veins in terms of their three-tunic structure and the presence of one-way valves to prevent backflow. These one-way valves are located fairly close to one another, and each one causes a bulge in the lymphatic vessel, giving the vessels a beaded appearance (see Figure 19.3.1). A major distinction between the lymphatic and cardiovascular systems in humans is that lymph is not actively pumped by the heart, but is pulled into the lymphatic capillaries by a pressure gradient (capillary action) and is forced through the vessels by similar mechanisms that help venous blood return to the heart: the contraction of skeletal muscles during body movements and the pressure gradients created by breathing. The one-way valves in lymphatic vessels keep the lymph from flowing backwards as it moves toward its destination.

Lymph is filtered for debris and pathogens in **lymph nodes** as it drains through lymphatic vessels. Humans have about 500–600 lymph nodes positioned at regular intervals along the length of lymphatic vessels throughout the body and clustered in some regions of the body. Examples of clustered lymph nodes include the axillary nodes near the armpit and the inguinal nodes near the groin (Figure 19.3.2). Lymph nodes are covered in more detail in the next section.

In general, lymphatic vessels of the subcutaneous tissues of the skin, that is, the superficial lymphatics, follow the same routes as veins, whereas the deep lymphatic vessels of the viscera generally follow the paths of arteries. The superficial and deep lymphatics eventually merge to form larger lymphatic vessels known as **lymphatic trunks**. There are four pairs of lymphatic trunks, each collecting lymph from a region of either the left or right side of the body, as well as a single **intestinal trunk**. Lymph from the head and neck drains into the **jugular trunks**. Lymph from the superficial thorax and the upper limb drains into the **subclavian trunks**. Lymph from the deep thorax drains into the **bronchomediastinal trunks**. Lymph from the lower limbs and

pelvis drains into the **lumbar trunks**.

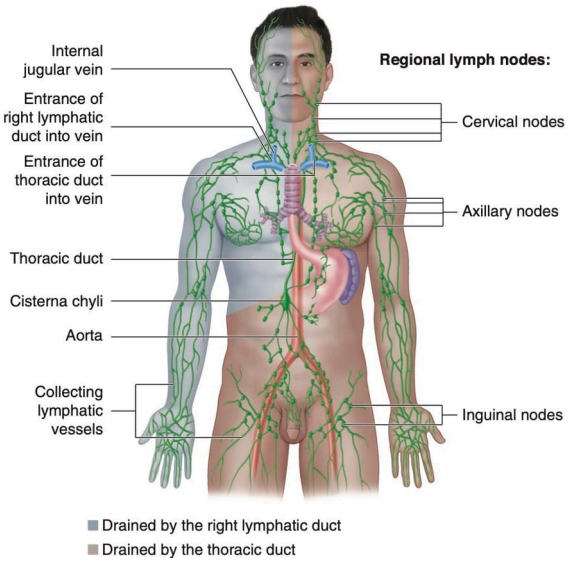

Figure 19.3.2: Lymphatic Vessel Drainage. Lymphatic vessels drain into lymphatic trunks. Lymphatic trunks drain into the right lymphatic duct from the upper portion of the right side of the body and into the larger thoracic duct from the upper portion of the left side of the body and both sides of the lower portion of the body. *(Image Credit: "OLI - Drawing Lymphatic drainage by thoracic duct and right lymphatic duct - English labels" by Open Learning Initiative, license: CC BY-NC-SA.)*

The largest lymphatic vessels that drain into the bloodstream are the **lymphatic ducts**. The overall drainage of fluid into the bloodstream via the lymphatic ducts is asymmetrical. The **right lymphatic duct** receives lymph from only the upper right portion of the body via the right jugular, subclavian, and bronchomediastinal trunks. The right lymphatic duct drains into the right subclavian vein lateral to its junction with the right internal jugular vein. The lymph from the rest of the body drains into the **thoracic duct** via all the remaining lymphatic trunks. The thoracic duct itself begins just beneath the diaphragm in the **cisterna chyli**, a sac-like chamber that receives lymph from the lower abdomen, pelvis, and lower limbs by way of the left and right lumbar trunks and the intestinal trunk. The left jugular, subclavian, and bronchomediastinal trunks drain into the thoracic duct near its entrance into the left subclavian vein, which is lateral to the junction of the left subclavian vein and left internal jugular vein.

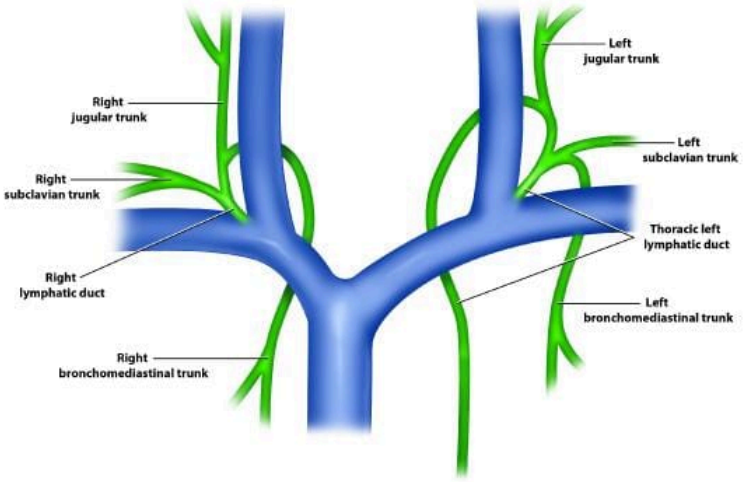

Figure 19.3.3: Lymphatic Trunks and Ducts. The most common pattern for the larger lymphatic vessels is that the right lymphatic duct and the thoracic (left) lymphatic duct merge with the venous system at the junction of the subclavian veins and the internal jugular veins. *(Image credit: "Lymph - Thoracic Duct" by BlueLink is licensed under CC BY-NC 4.0 with notification of the original authors.)*

DISORDERS OF THE....

Lymphatic System: Lymphedema

Edema is the term for localized swelling in the body, caused by fluid becoming trapped in the tissues. Lymphedema is caused by damage in the vasculature of the lymphatic system, such as by being blocked by cancer cells or destroyed by injury. When the fluid cannot flow properly to drain away from an area and be returned to the bloodstream, protein-rich interstitial fluid accumulates in the tissue spaces upstream of the damage. Figure 19.3.3 compares the degree of visible swelling in the left extremity impacted by each of 4 potential stages of lymphedema severity. Lymphedema may lead to serious medical consequences.

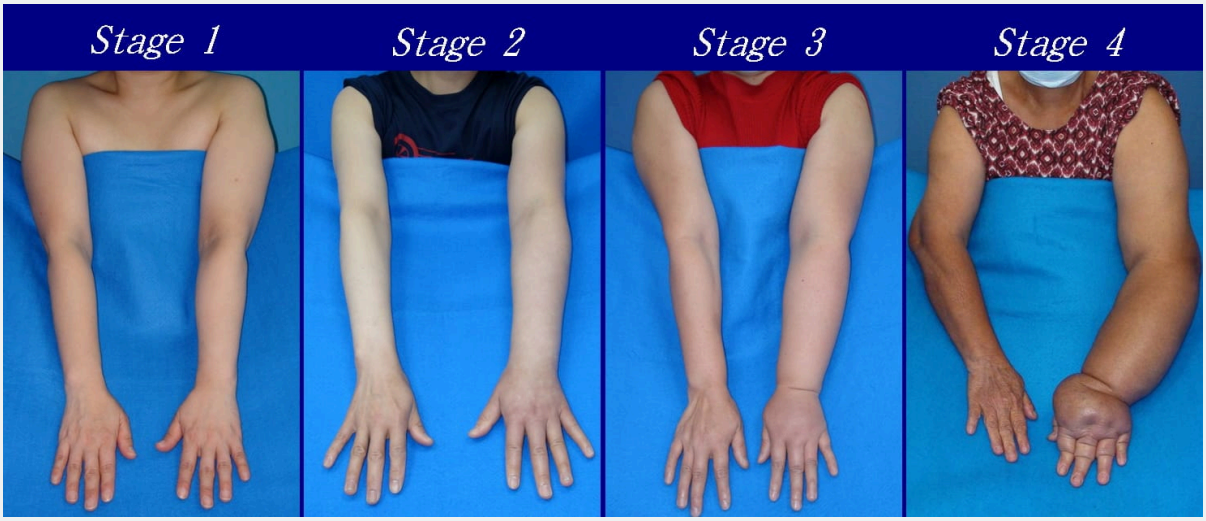

Figure 19.3.3: Lymphedema. When lymphatic vessels are unable to adequately return fluid to the bloodstream, the excess interstitial fluid can build up in a region of the body, typically one extremity. The resulting swelling is called lymphedema, which can be categorized into stages according to its severity. (Image credit: "Upper Limb Lymphedema" by DocHealer is licensed under CC BY-SA 4.0)

RECENT DISCOVERIES IN ANATOMY

Lymphatic Vessels near the Brain

Prior to the 2015 discovery of lymphatic vessels in the dura mater surrounding the brain, maps of lymphatic vessels would depict an unexpected absence of lymphatic vessels around the brain (Figure \({19{.}3{.}\eatSpaces{4} \endSpaces}\.a)). We now understand there are lymphatic vessels embedded alongside the venous sinuses in the dura mater meningeal layer surrounding the brain (Figure \({19{.}3{.}\eatSpaces{4} \endSpaces}\.b)).

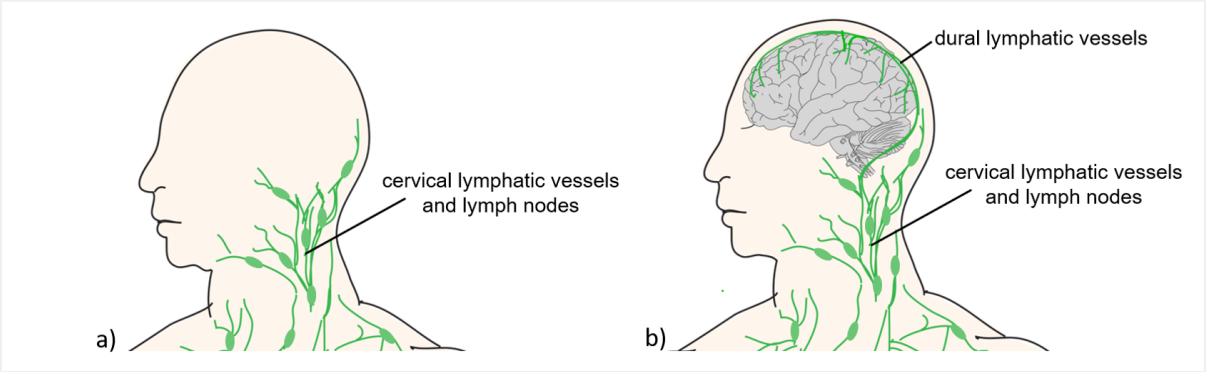

Figure 19.3.4: Dural Lymphatic Vessels. a) map of lymphatic vessels in the head and neck prior to 2015 showed only the cervical lymphatic vessels and lymph nodes. b) map of lymphatic vessels in the head and neck after the discovery of dural lymphatic vessels published in 2015 with the addition of the dural lymphatic vessels. (Image credit: “Dural Lymphatic Vessels" by Julie Jenks is a derivative of the original work by Daniel Donnelly and is licensed under CC BY 4.0)

The discovery of dural lymphatic vessels adds to the understanding of several mechanisms involved in draining cerebrospinal fluid (CSF) away from the subarachnoid space around the brain. Cerebrospinal fluid supplies nervous tissue with nutrients and also collects waste products from it, so CSF is constantly secreted into spaces within and surrounding the brain and spinal cord and it is also drained away at the same rate. It has long been understood that cerebrospinal fluid drains into the dural sinuses of the bloodstream. CSF fluid can also drain into dural lymphatic vessels. Yet another mechanism of draining CSF away from the brain was described in 2012. The mechanism was dubbed the glymphatic system because while lymphatic vessels are not found deep to the dura mater around the brain, there is evidence that fluid flows along the surface of blood vessels in perivascular channels formed by astrocytes toward drainage sites (Figure 19.3.5).

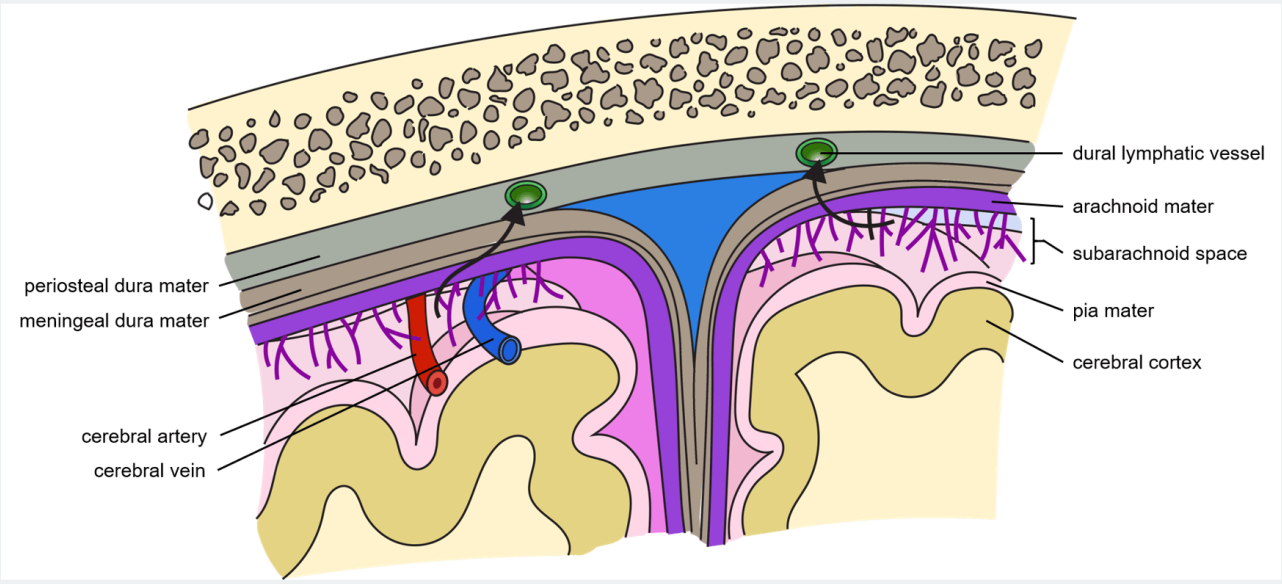

Figure 19.3.5: Glymphatics and Dural Lymphatic Vessels. The lymphatic system plays two key roles in the drainage of waste-containing cerebrospinal fluid from around the brain: glymphatic mechanisms (the perivascular countercurrent movement of fluid along the surface of veins and venules rather than within additional lymphatic vessels) and drainage directly into dural lymphatic vessels. (Image credit: "Glymphatics and Dural Lymphatic Vessels" by Julie Jenks is a derivative of the original work by Daniel Donnelly and is licensed under CC BY 4.0)

At the time the discovery of the glymphatic mechanism was published in 2012, it was thought that it worked to drain fluid away from the brain in the absence of nearby lymphatic vessels, but now a more dynamic picture illustrates multiple mechanisms for draining fluid away from the very metabolically active brain. The physiology of the glymphatic system mechanism of drainage is still not fully understood.

INTERACTIVE LINK

Query 19.3.1

This interactive element is not available in this format. Visit the link or scan the QR code to access it online.

View this Interactive Content online

Concept Review

The lymphatic vessels include a network of capillaries, vessels, trunks, and ducts that remove interstitial fluid from the tissues and return it the blood filtered of debris and pathogens by passage through lymph nodes. The lymphatics are also used to transport

dietary lipids and distribute cells of the immune system.

Review Questions

Query 19.3.2

This interactive element is not available in this format. Visit the link or scan the QR code to access it online.

View this Interactive Content online

Critical Thinking Questions

Query 19.3.3

This interactive element is not available in this format. Visit the link or scan the QR code to access it online.

View this Interactive Content online

Glossary

Query 19.3.4

This interactive element is not available in this format. Visit the link or scan the QR code to access it online.

View this Interactive Content online

References

Abbott, N.J., Pizzo, M.E., Preston, J.E. *et al*. The role of brain barriers in fluid movement in the CNS: is there a 'glymphatic' system?. *Acta Neuropathol* 135, 387–407 (2018). [Accessed 17 Apr 2021]

Iliff JJ, Wang M, Liao Y, Plogg BA, Peng W, Gundersen GA, Benveniste H, Vates GE, Deane R, Goldman SA, Nagelhus EA, Nedergaard M. A paravascular pathway facilitates CSF flow through the brain parenchyma and the clearance of interstitial solutes, including amyloid β. Sci Transl Med. 2012 Aug 15;4(147):147ra111. doi: 10.1126/scitranslmed.3003748. PMID: 22896675; PMCID: PMC3551275. [Accessed 18 Jan 2021]

Louveau A, Smirnov I, Keyes TJ, Eccles JD, Rouhani SJ, Peske JD, Derecki NC, Castle D, Mandell JW, Lee KS, Harris TH, Kipnis J. Structural and functional features of central nervous system lymphatic vessels. Nature. 2015 Jul 16;523(7560):337-41. doi: 10.1038/nature14432. Epub 2015 Jun 1. Erratum in: Nature. 2016 May 12;533(7602):278. PMID: 26030524; PMCID: PMC4506234. [Accessed 18 Jan 2021]

Contributors and Attributions

- OpenStax Anatomy & Physiology (CC BY 4.0). Access for free at https://openstax.org/books/anatomy-and-physiology

This page titled 19.3: Anatomy of Lymphatic Vessels is shared under a CC BY-NC-SA 4.0 license and was authored, remixed, and/or curated by Jennifer Lange et al..

- 19.3: Anatomy of Lymphatic Vessels by Whitney Menefee, Julie Jenks, Chiara Mazzasette, and Kim-Leiloni Nguyen is licensed CC BY 4.0.

19.4: Anatomy of Lymphatic Organs and Tissues

By the end of this section, you will be able to:

- Describe the structure and function of the primary and secondary lymphatic organs
- Describe the structure, function, and location of lymphoid tissues

Lymphoid organs are distinct structures consisting of multiple tissue types. The category can be further subdivided into primary lymphoid organs, which support lymphocyte production and development, and secondary lymphoid organs, which support lymphocyte storage and function. Lymphoid tissues are concentrations of lymphocytes and other immune cells within other organs of the body.

Primary Lymphoid Organs and Lymphocyte Development

The differentiation and development of B and T cells is critical to the adaptive immune response. When the body is exposed to a new pathogen, lymphocytes of the adaptive immune response must "learn" the new antigen associated with the pathogen, mount an effective response to eradicate the pathogen, and "remember" the antigen in case the body is exposed again in the future by forming memory cells. It is also through this process that the body (ideally) learns to destroy only pathogens and leaves the body's own cells relatively intact. The **primary lymphoid organs** are the bone marrow and thymus gland. The lymphoid organs are where lymphocytes proliferate and mature.

Bone Marrow

Red bone marrow is a loose collection of cells where hematopoiesis (blood cell formation) occurs surrounding a framework of reticular connective tissue. Red bone marrow is primarily located surrounding the trabeculae of spongy bone (Figure 19.4.1).

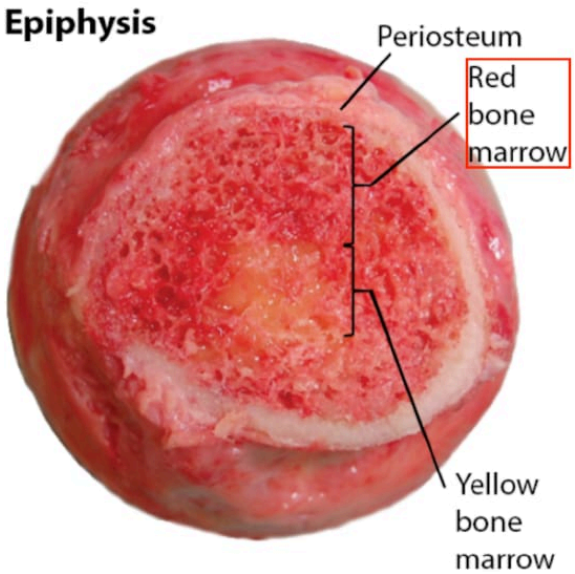

Figure 19.4.1: Red and Yellow Bone Marrow. The epiphysis of the femur contains both yellow marrow (stores fat) and red marrow (responsible for hematopoiesis. *(Image credits: "Bone Marrow - Epiphysis" by Jennifer Lange is licensed under CC BY-NC-SA 4.0, modification of original by OpenStax)*

Hematopoiesis is summarized in Figure 19.4.2 and was covered in more detail in the blood chapter. In the embryo, blood cells are made in the yolk sac. As development proceeds, this function is taken over by the spleen, lymph nodes, and liver. Later, the red bone marrow takes over most hematopoietic functions, although the final stages of the differentiation of some cells may take place in other organs. The B cell undergoes nearly all of its development in the red bone marrow, whereas the immature T cell,

called a **thymocyte**, leaves the bone marrow and matures largely in the thymus gland.

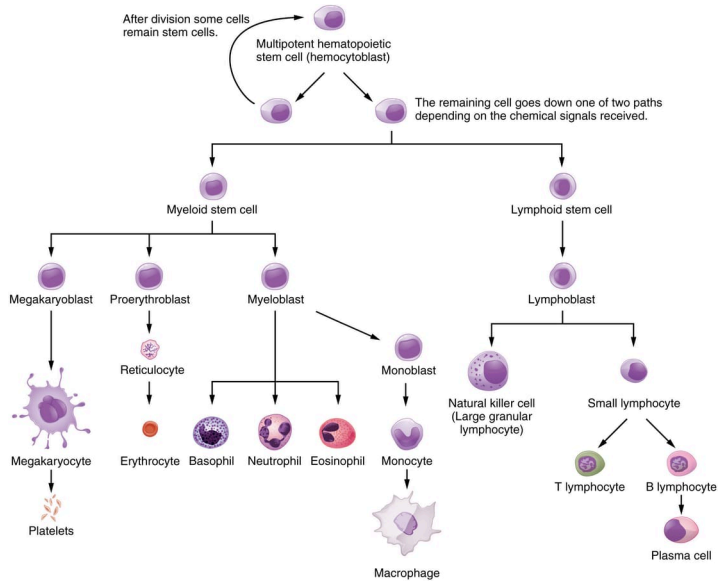

Figure 19.4.2: Hematopoietic System of Bone Marrow. Hematopoiesis is the proliferation and differentiation of the formed elements of blood. *(Image credit: "Hematopoietic System of the Bone Marrow" by Julie Jenks is licensed under CC BY 4.0 / A derivative from the original work)*

Thymus

The **thymus** gland is a bilobed organ found in the space between the sternum and the aorta of the heart (Figure 19.4.3) that serves as a specialized structure in which T lymphocytes mature. The thymus is most active early in life as you are exposed to and build immunity to many pathogens. After puberty, the thymus slowly but continuously decreases in activity and size as its tissue is replaced with a mix of fibrous and adipose connective tissues.

In the thymus, the maturation of T lymphocytes begins with thymocytes. Thymocytes travel through the bloodstream from the red bone marrow to the thymus. Thymocytes are precursors to T lymphocytes that lack the surface proteins mature T lymphocytes use to recognize an antigen and coordinate an adaptive immune response. There is a multi-step physiological process by which T lymphocytes mature into naïve T lymphocytes ready to be activated for an adaptive immune response.

Dense irregular connective tissue holds the lobes of the thymus closely together but also separates them and forms a fibrous capsule. The fibrous capsule further divides the thymus into lobules via extensions called trabeculae. Blood vessels and nerves are routed within the trabeculae. The outer region of each lobule is known as the cortex and here the structure of the thymus forms a **blood-thymus barrier** to prevent the thymocytes from being exposed to antigens from the bloodstream before they mature. The densely packed thymocytes in the cortex stain more intensely than the rest of the thymus (see Figure 19.4.3). The medulla contains a less dense collection of thymocytes, epithelial cells, macrophages, and dendritic cells, so it appears more lightly stained in the micrograph. Thymocytes move from the cortex to the medulla as they mature where the lack of the blood-thymus barrier allows them to enter the bloodstream and travel to other lymphatic structures to await activation for an adaptive immune response.

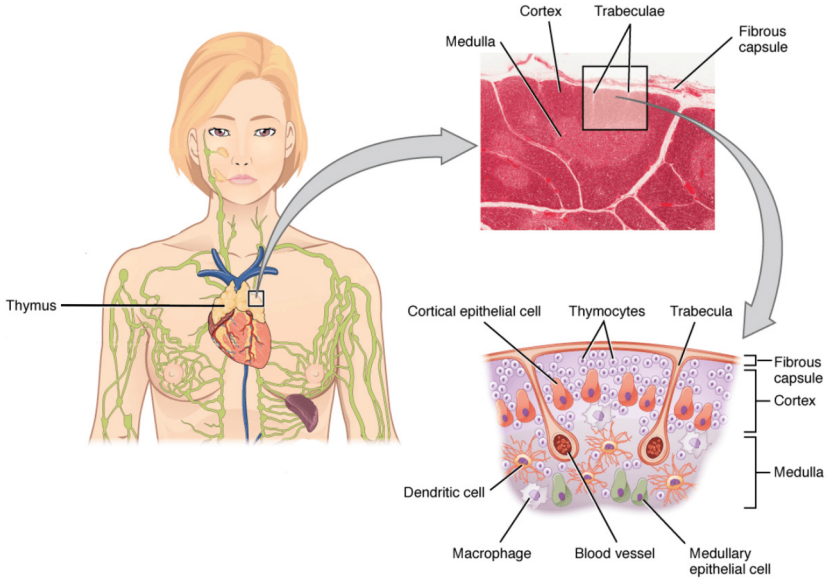

Figure 19.4.3: Location, Structure, and Histology of the Thymus. The thymus lies above the heart. The trabeculae and lobules, including the darkly staining cortex and the lighter staining medulla of each lobule, are clearly visible in the light micrograph of the thymus of a newborn. LM × 100. *(Image credit: "The Location Structure and Histology of the Thymus" by Yancy Aquinois licensed under CC BY-NC-SA 4.0, modification of original by OpenStax)/ Micrograph provided by the Regents of the University of Michigan Medical School © 2012)*

AGING AND THE...

Immune System

By the year 2050, 25 percent of the population of the United States will be 60 years of age or older. The CDC estimates that 80 percent of those 60 years and older have one or more chronic diseases associated with deficiencies of the immune systems. This loss of immune function with age is called immunosenescence. To treat this growing population, medical professionals must better understand the aging process. One major cause of age-related immune deficiencies is thymic involution, the shrinking of the thymus gland that begins after puberty, at a rate of about three percent tissue loss per year, and continues until 35–45 years of age, when the rate declines to about one percent loss per year for the rest of one's life. At that pace, the total loss of thymic epithelial tissue and thymocytes would occur at about 120 years of age. Thus, this age is a theoretical limit to a healthy human lifespan.

Thymic involution has been observed in all vertebrate species that have a thymus gland. Animal studies have shown that transplanted thymic grafts between inbred strains of mice involuted according to the age of the donor and not of the recipient, implying the process is genetically programmed. There is evidence that the thymic microenvironment, so vital to the development of naïve T cells, loses thymic epithelial cells according to the decreasing expression of the FOXN1 gene with age.

It is also known that thymic involution can be altered by hormone levels. Sex hormones such as estrogen and testosterone enhance involution, and the hormonal changes in pregnant women cause a temporary thymic involution that reverses itself, when the size of the thymus and its hormone levels return to normal, usually after lactation ceases. What does all this tell us? Can we reverse immunosenescence, or at least slow it down? The potential is there for using thymic transplants from younger donors to keep thymic output of naïve T cells high. Gene therapies that target gene expression are also seen as future possibilities. The more we learn through immunosenescence research, the more opportunities there will be to develop therapies, even though these therapies will likely take decades to develop. The ultimate goal is for everyone to live and be healthy longer, but there may be limits to immortality imposed by our genes and hormones.

Secondary Lymphoid Organs and their Roles in Immune Responses

Lymphocytes develop and mature in the primary lymphoid organs, but they mount immune responses from the **secondary lymphoid organs**. A **naïve lymphocyte** is one that has left the primary organ and entered a secondary lymphoid organ. Naïve

lymphocytes are fully functional immunologically, sometimes referred to as immunocompetency, but have yet to encounter an antigen to which to respond. In addition to circulating in the blood and lymph, lymphocytes concentrate in secondary lymphoid organs, which include the lymph nodes, spleen, and lymphoid tissues associated with several organs in the body. All of these tissues have many features in common, including the following:

- An internal structure of reticular connective tissue with associated fixed macrophages
- The presence of **lymphoid nodules**, collections of lymphocytes, with specific B cell-rich and T cell-rich areas
- **Germinal centers**, which are the sites of activated (rapidly dividing) B lymphocytes and plasma cells in lymphoid nodules, with the exception of the spleen
- Specialized post-capillary vessels known as **high endothelial venules**; the cells lining these venules are thicker and more columnar than normal endothelial cells, which allow cells from the blood to directly enter these tissues

Lymph Nodes

As described in the previous section, lymph nodes are positioned at regular intervals along the length of lymphatic vessels. Lymph nodes function to remove debris and pathogens from the lymph, and are thus sometimes referred to as the “filters of the lymph” (Figure 19.4.5). Any bacteria that infect the interstitial fluid are taken up by the lymphatic capillaries and transported to a regional lymph node. Dendritic cells and macrophages within this organ internalize and kill many of the pathogens and debris that pass through, thereby removing them from the body. The lymph node is the most common site of activation of adaptive immune responses mediated by T cells, B cells, and accessory cells of the adaptive immune system. This is why swollen lymph nodes can be a sign of infection.

Like the thymus, the bean-shaped lymph nodes are surrounded by a tough capsule of dense connective tissue and are separated into compartments by trabeculae, extensions of the capsule. In addition to the structure provided by the capsule and trabeculae, the structural support of the lymph node is provided by a series of reticular fibers laid down by fibroblasts of its reticular connective tissue framework. Several afferent lymphatic vessels deliver lymph into the convex side of a lymph node and a one-way valve in each vessel near where it connects with the lymph node prevents back-flow of lymph. One or two efferent lymphatic vessels allow lymph to flow out of the concave hilum of the lymph node. The tissue inside the lymph node consists of two generalized regions: the cortex and the medulla. The cortex is nearest the convex side of the node and contains lymphoid nodules where activated lymphocytes proliferate. The medulla, nearest the hilum of each node, is rich with lymphocytes (T cells, B cells, and plasma cells), as well as macrophages and dendritic cells.

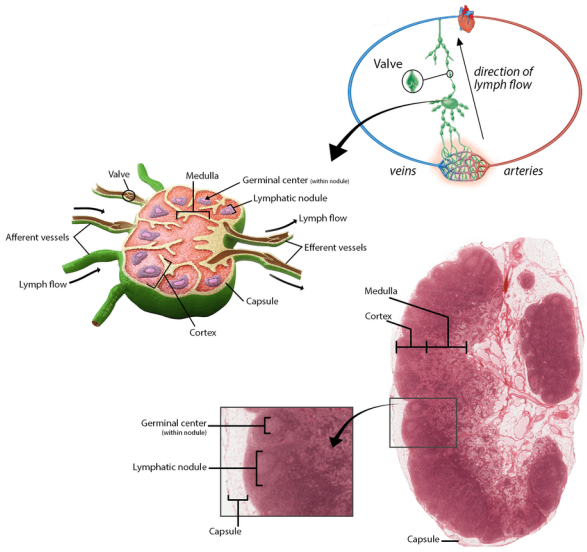

Figure 19.4.5: Lymph Node. Lymph flows into a lymph node via afferent vessels through the open cusps of one-way valves that prevent lymph from flowing in the wrong direction. Within the lymph node, lymph flows past densely packed immune cells that remove debris and pathogens (including B and T cells, macrophages, and plasma cells), and then out of the node through more back-flow preventing one-way valves into efferent vessels. Histological views of lymph node sections show the capsule, cortex, and medulla. Within the cortex several lymphoid nodules as densely packed dark-staining cells, often with a lighter germinal center. *(Image credit: "Lymph Node - Illustration and Histology" by Jennifer Lange is licensed under CC BY-NC-SA 4.0. Modification of originals: "OLI - Drawing Relationship of blood capillaries and lymphatic capillaries - English labels" by Open Learning Initiative and "Lymph node" illustration by Scientific Animations. Heart icon from University of British Columbia Clinical Anatomy. Slide images provided by the Regents of the University of Michigan Medical School © 2022.)*

Spleen

The spleen is located inferior and medial to the curve of the diaphragm and lateral to the stomach in the upper left quadrant of the abdomen (Figure 19.4.6). It is built on a framework of reticular connective tissue and surrounded by a capsule of dense irregular connective tissue that invaginates into trabeculae to divide the spleen into nodules (Figure 19.4.7). Upon entering the spleen, the splenic artery splits into several arterioles and eventually into sinusoid capillaries. Blood from the capillaries subsequently collects in venules that drain into the splenic vein.

Within each splenic nodule is a large area of **red pulp** surrounding the sinusoid capillaries that is so-called because it consists mainly of erythrocytes. The red pulp consists of reticular fibers with fixed macrophages attached, free macrophages, and other formed elements of the blood, including some lymphocytes. The red pulp primarily functions in phagocytosis of worn-out erythrocytes and bloodborne pathogens. Aside from the blood vessels, the remaining tissue of each nodule is called the **white pulp**, so-called because it lacks the erythrocytes found in the red pulp. The white pulp surrounds the arteriole and resembles the lymphoid nodules of the lymph nodes. It consists of germinal centers of dividing B cells surrounded by T cells and accessory cells, including macrophages and dendritic cells. Germinal centers function as a site of T cell and B cell activation. The marginal zone is the region where the white pulp transitions to the red pulp and their functions mix.

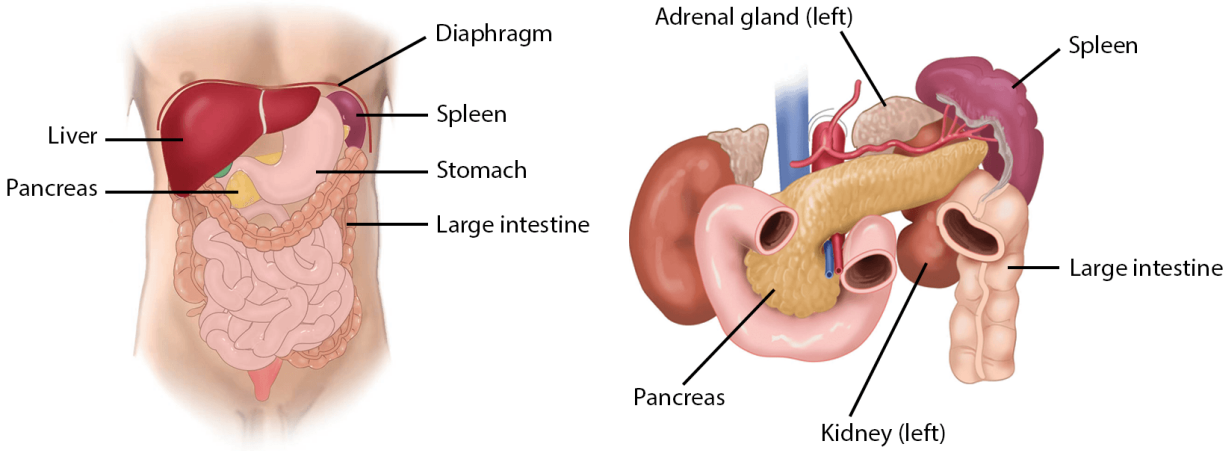

A. Organs of the abdominal region **B. Posterior upper abdominal organs**

Figure 19.4.6: Location of the Spleen. (A) The spleen is located in the upper, left quadrant of the abdomen, just inferior to the diaphragm. (B) With the stomach and regions of the intestines removed, you can see the spleen mover clearly and its location relative to the pancreas and left kidney. *(Image credit: "Spleen Location" by Jennifer Lange is licensed under CC BY-NC-SA 4.0, modification of originals A - "Slagter - Drawing Abdominal organs in situ, anterior view - no labels" by Ron Slagter and B - "Leiden - Drawing pancreas and neighbouring organs - no labels" by Ron Slagter.)*

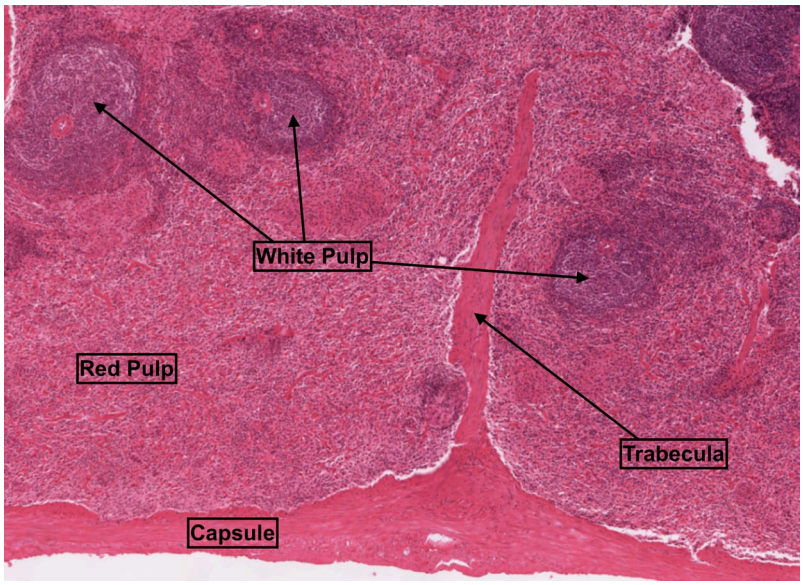

Figure 19.4.7: Histology of the Spleen. A micrograph of the spleen showing the internal structures, such as white and red pulp. (*Slide provided by the Regents of the University of Michigan Medical School under CC BY-NC-SA 4.0 © 2022.*)

Lymphoid Nodules

The other lymphoid tissues, **lymphoid nodules**, have a simpler architecture than the spleen and lymph nodes in that they consist of a dense cluster of lymphocytes on a framework of reticular connective tissue without a surrounding fibrous capsule. These nodules are associated with the mucus membranes of the respiratory and digestive tracts, areas routinely exposed to environmental pathogens.

Tonsils are lymphoid nodules located along the inner surface of the pharynx and are important in developing immunity to oral pathogens (Figure 19.4.8).

- The **pharyngeal tonsil**, sometimes referred to as the adenoid, is located in the superoposterior of the nasopharynx
- The **palatine tonsils** are in the lateral wall of the oropharynx
- The **lingual tonsil** faces the oropharynx in the wall at the posterior of the tongue

Swelling of the tonsils is an indication of an active immune response to infection. Histologically, tonsils do not contain a complete capsule, and the epithelial layer invaginates deeply into the interior of the tonsil to form tonsillar crypts. The crypts allow all sorts of materials taken into the body through eating and breathing to accumulate in the tonsils, actually “encouraging” pathogens to penetrate deep into the tonsillar tissues where T cells and B cells in the germinal centers can be activated for an adaptive immune response. This seems to be the major function of tonsils—to help children’s bodies recognize, destroy, and develop immunity to common environmental pathogens so that they will be protected in their later lives. Tonsils are often removed in those children who have recurring throat infections, especially those involving the palatine tonsils on either side of the throat, whose swelling may interfere with their breathing and/or swallowing.

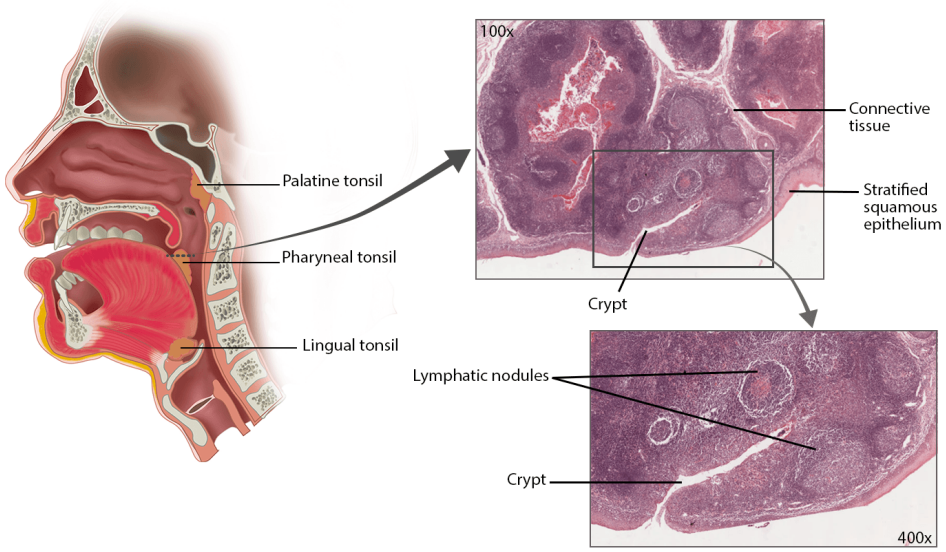

Figure 19.4.7: Locations and Histology of the Tonsils. The pharyngeal tonsil is located in the superoposterior wall of the nasopharynx, the palatine tonsils are located in the lateral wall of the oropharynx, and the lingual tonsil is located in the anterior wall of the oropharynx at the base of the tongue. Histologically the palatine tonsils show crypts lined with stratified squamous epithelium and the numerous lymphatic nodules. *(Image credit: "Tonsils" by Jennifer Lange is licensed under CC BY-NC-SA 4.0, modification of illustration "Slagter - Drawing Head and neck: sagittal section - no labels" by Ron Slagter, license: CC BY-NC-SA, slide images provided by the Regents of the University of Michigan Medical School © 2022.)*

Mucosa-associated lymphoid tissue (MALT) consists of an aggregate of lymphoid nodules directly associated with the mucous membrane epithelia. MALT makes up dome-shaped structures found underlying the mucosa of the gastrointestinal tract, breast tissue, lungs, and eyes. Peyer's patches, a type of MALT in the small intestine, are especially important for immune responses against ingested substances (Figure 19.4.9). Peyer's patches contain specialized endothelial cells called M (or microfold) cells that sample material from the intestinal lumen and transport it to nearby follicles so that adaptive immune responses to potential pathogens can be mounted.

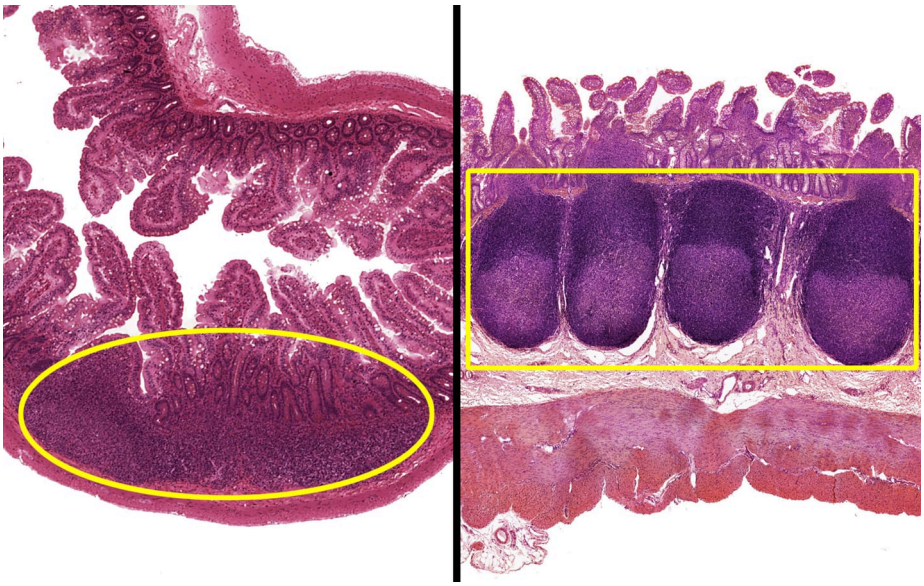

Figure 19.4.8: Mucosa-Associated Lymphoid Tissue (MALT) Nodule (Peyer's patch). The mucosa-associated lymphoid nodules in the small intestine are called Peyer's patches. *(Image credit: "Payer's patch" by Yancy Aquino; micrographs provided by Virginia Commonwealth University under CC BY-NC-SA 4.0)*

Concept Review

Lymphoid organs are comprised of multiple tissues forming a distinct structure in the body. Primary lymphoid organs include bone marrow and the thymus. Lymphocytes and other blood cells are produced in red bone marrow while lipids are stored for long-term energy in yellow bone marrow. B lymphocytes remain in red bone marrow to develop into naïve B lymphocytes. The thymus is the organ in which immature T lymphocytes are stored and develop into naïve T lymphocytes. Naïve T and B lymphocytes travel to secondary lymphoid organs, lymph nodes and the spleen, from where they can be activated for the adaptive immune response. Lymph nodes filter lymph for invaders, abnormal cells, and debris as it drains to the bloodstream through lymphatic vessels. The spleen, in the white pulp, filters the blood for invaders, abnormal cells, and debris as it circulates through the bloodstream. The red pulp of the spleen also filters the blood and serves to remove worn-out red blood cells from circulation. Concentrations of lymphocytes and other immune cells within mucus membranes of other organ systems are called lymphoid tissues or nodules. The tonsils surround the pharynx while mucosa-associated lymphoid tissue (MALT) are found in mucus membranes of the gastrointestinal tract, breast tissue, lungs, and eyes.

Review Questions

Query 19.4.1

This interactive element is not available in this format. Visit the link or scan the QR code to access it online.

View this Interactive Content online

Critical Thinking Questions

Query 19.4.2

This interactive element is not available in this format. Visit the link or scan the QR code to access it online.

View this Interactive Content online

Glossary

Query 19.4.3

This interactive element is not available in this format. Visit the link or scan the QR code to access it online.

View this Interactive Content online

Contributors and Attributions

- OpenStax Anatomy & Physiology (CC BY 4.0). Access for free at https://openstax.org/books/anatomy-and-physiology

This page titled 19.4: Anatomy of Lymphatic Organs and Tissues is shared under a CC BY-NC-SA 4.0 license and was authored, remixed, and/or curated by Jennifer Lange et al..

- 19.4: Anatomy of Lymphatic Organs and Tissues by Whitney Menefee, Julie Jenks, Chiara Mazzasette, and Kim-Leiloni Nguyen is licensed CC BY 4.0.

19.5: Anatomical Atlas - Lymphatic System

A compendium of anatomical images: slides, models, and/or cadavers.

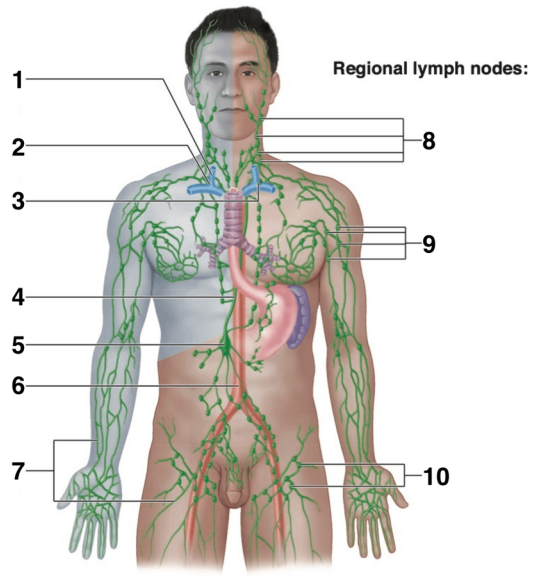

Image Credit

"OLI - Drawing Lymphatic drainage by thoracic duct and right lymphatic duct - English labels" by *Open Learning Initiative*, license: *CC BY-NC-SA*.

Answer Key (click to show/hide answers)

Lymphatic Drainage:

1 - Internal jugular vein

2 - Entrance of right lymphatic duct into vein

3 - Entrance of thoracic duct into vein

4 - Thoracic duct

5 - Cisterna chyli

6 - Aorta

7 - Collecting lymphatic vessels

8 - Cervical nodes

9 - Axillary nodes

10 - Inguinal nodes

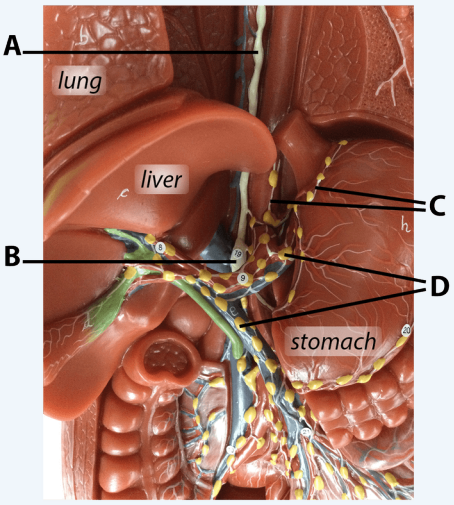

Image Credit

"Lymphatic System Model Close-up of Cysterna Chyli" by Jennifer Lange is licensed under *CC BY-NC-SA 4.0*.

Answer Key (click to show/hide answers)

A - thoracic duct

B - cysterna chyli

C - lymphatic vessels

D - lymph nodes

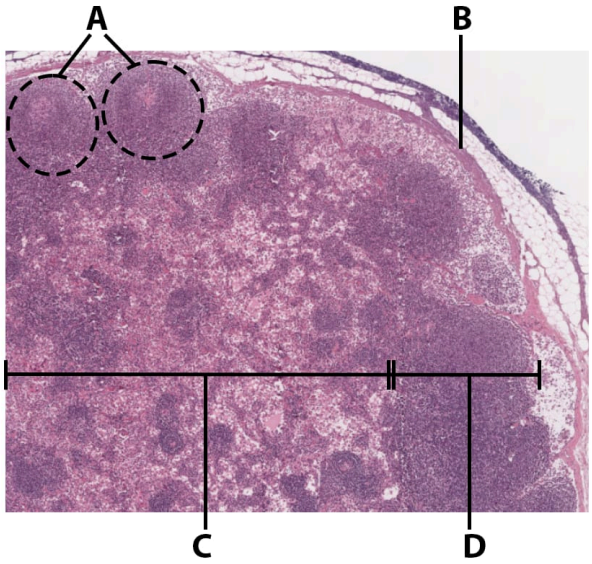

Image Credit

"Lymph Node @ 100x - atlas" by Jennifer Lange is licensed under *CC BY-NC-SA 4.0*, *slide image provided by the Regents of the University of Michigan Medical School © 2022*

Answer Key (click to show/hide answers)

Lymph Node:

A - lymphatic nodules

B - capsule

C - medulla

D - cortex

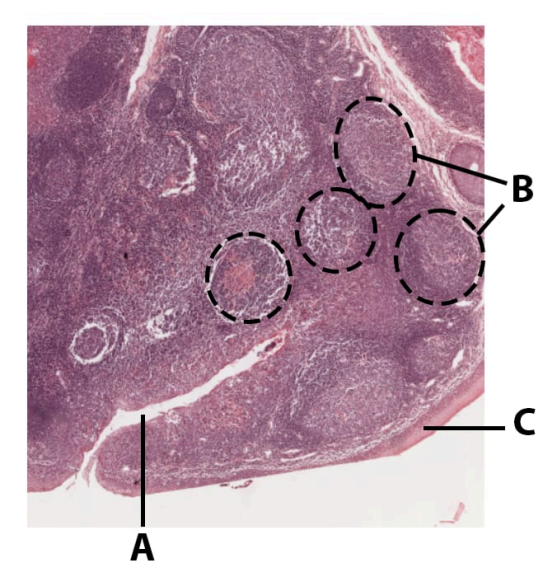

Image Credit

"Tonsil @ 100x - atlas" by Jennifer Lange is licensed under *CC BY-NC-SA 4.0*, *slide image provided by the Regents of the University of Michigan Medical School © 2022*

Answer Key (click to show/hide answers)

Tonsil:

A - tonsilar crypt

B - lymphatic nodules

C - stratified squamous epithelium

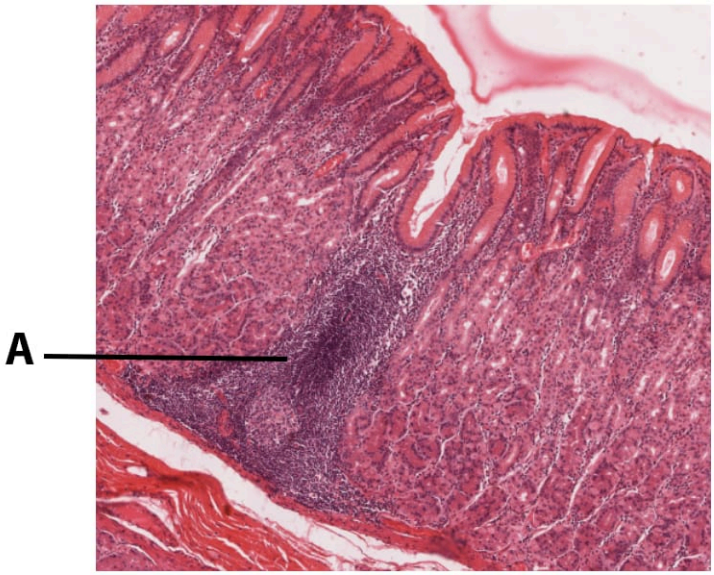

Image Credit

"Mucosa Associated Lymphoid Tissue (MALT) @ 100 x - atlas" by Jennifer Lange is licensed under *CC BY-NC-SA 4.0*, *slide image provided by the Regents of the University of Michigan Medicl School © 2022*

Answer Key (click to show/hide answers)

A - MALT (Slide of Stomach)

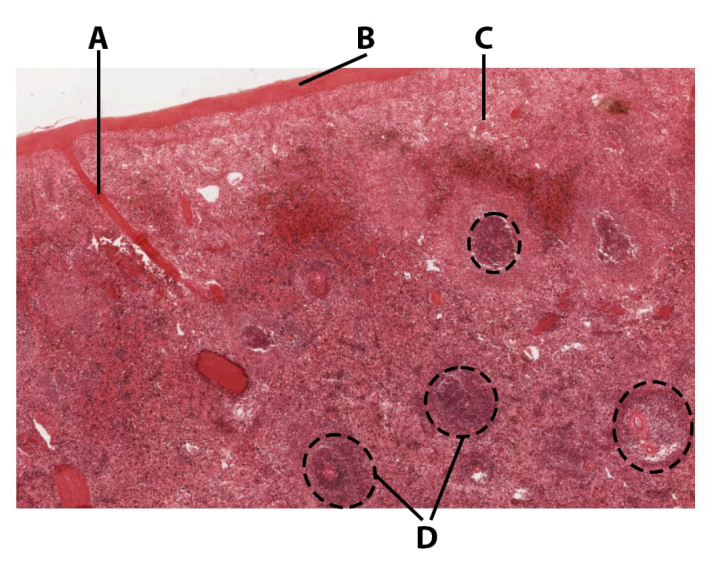

Image Credit

"Spleen @ 100x - atlas" by Jennifer Lange is licensed under *CC BY-NC-SA 4.0*, *slide image provided by the Regents of the University of Michigan Medical School © 2022*

Answer Key (click to show/hide answers)

Spleen:

A - trabecula

B - capsule

C - red pulp

D - white pulp/ lymphatic nodules

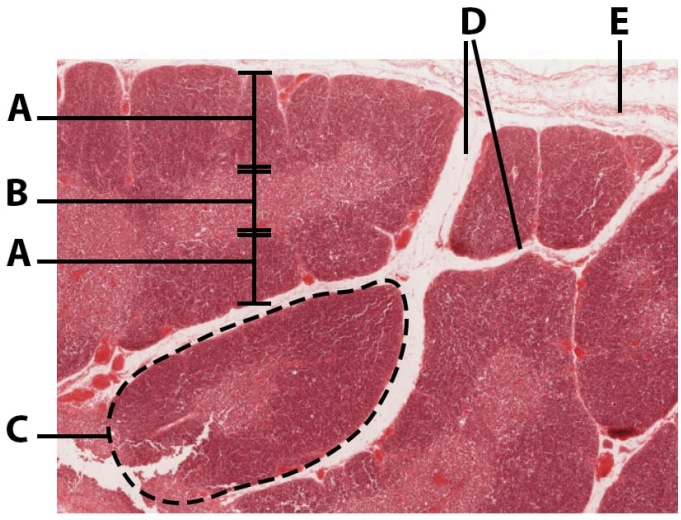

Image Credit

"Thymus @ 100x - atlas" by Jennifer Lange is licensed under *CC BY-NC-SA 4.0*, *slide image provided by the Regents of the University of Michigan Medical School © 2022*

Answer Key (click to show/hide answers)

Thymus Gland:

A - cortex

B - medulla

C - lobule

D - trabeculae

E - capsule

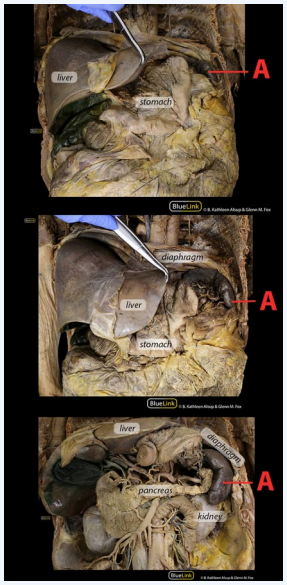

Image Credit

"Cadaver Stomach, Liver, and Spleen - atlas" by BlueLink is licensed under CC BY-NC 4.0 with notification of the original authors, labeling by Jennifer Lange.

Answer Key (click to show/hide answers)

A - spleen

This page titled 19.5: Anatomical Atlas - Lymphatic System is shared under a CC BY-NC-SA 4.0 license and was authored, remixed, and/or curated by Jennifer Lange et al..

19.6: Practice Practical- Lymphatic System

Please answer the following questions by writing your answers on the space provided.

Query 19.6.1

This interactive element is not available in this format. Visit the link or scan the QR code to access it online.

View this Interactive Content online

Query 19.6.1

This interactive element is not available in this format. Visit the link or scan the QR code to access it online.

View this Interactive Content online

Query 19.6.1

This interactive element is not available in this format. Visit the link or scan the QR code to access it online.

View this Interactive Content online

Query 19.6.1

This interactive element is not available in this format. Visit the link or scan the QR code to access it online.

View this Interactive Content online

Query 19.6.1

This interactive element is not available in this format. Visit the link or scan the QR code to access it online.

View this Interactive Content online

Query 19.6.1

This interactive element is not available in this format. Visit the link or scan the QR code to access it online.

View this Interactive Content online

Query 19.6.1

This interactive element is not available in this format. Visit the link or scan the QR code to access it online.

View this Interactive Content online

Query 19.6.1

This interactive element is not available in this format. Visit the link or scan the QR code to access it online.

View this Interactive Content online

Query 19.6.1

This interactive element is not available in this format. Visit the link or scan the QR code to access it online.

View this Interactive Content online

Query 19.6.1

This interactive element is not available in this format. Visit the link or scan the QR code to access it online.

View this Interactive Content online



This page titled 19.6: Practice Practical- Lymphatic System is shared under a CC BY-NC-SA 4.0 license and was authored, remixed, and/or curated by Jennifer Lange et al..

20: RESPIRATORY SYSTEM

The respiratory system consists of specific organs and structures designed to deliver clean and conditioned oxygenated air to the sites of gas exchange in the lungs while also functioning to excrete waste in the form of carbon dioxide. The respiratory system also follows the gases (oxygen and carbon dioxide) as they travel via specialized structures through the bloodstream to be exchanged with tissues throughout the body.

20.1: Introduction to the Respiratory System

20.2: The Lungs

20.3: Conducting Zone

20.4: Respiratory Zone

20.5: Embryonic Development of the Respiratory System

20.6: Anatomical Atlas - Respiratory System

20.7: Practice Practical - the Respiratory System

This page titled 20: Respiratory System is shared under a CC BY-NC-SA 4.0 license and was authored, remixed, and/or curated by Jennifer Lange et al..

- 20: Respiratory System by Whitney Menefee, Julie Jenks, Chiara Mazzasette, and Kim-Leiloni Nguyen is licensed CC BY 4.0.

20.1: Introduction to the Respiratory System

Chapter Learning Objectives:

After studying this chapter, you will be able to:

- List the structures of the respiratory system
- List the major functions of the respiratory system
- Outline the forces that allow for air movement into and out of the lungs
- Describe the development of the respiratory system in the embryo

Hold your breath. Really! See how long you can hold your breath as you continue reading...How long can you do it? Chances are you are feeling uncomfortable already. A typical human cannot survive without breathing for more than 3 minutes, and even if you wanted to hold your breath longer, your autonomic nervous system would take control. This is because every cell in the body needs to run the oxidative stages of cellular respiration, the process by which energy is produced in the form of adenosine triphosphate (ATP). For oxidative phosphorylation to occur, oxygen is used as a reactant and carbon dioxide is released as a waste product.

Figure 20.1.1: Mountain Climbers. The thin air at high elevations can strain the human respiratory system.

You may be surprised to learn that although oxygen is a critical need for cells, it is actually the accumulation of carbon dioxide that primarily drives your need to breathe. Carbon dioxide is exhaled and oxygen is inhaled through the respiratory system, which includes muscles to move air into and out of the lungs, passageways through which air moves, and microscopic gas exchange surfaces covered by capillaries. The circulatory system transports gases from the lungs to tissues throughout the body and vice versa. A variety of diseases can affect the respiratory system, such as asthma, emphysema, chronic obstruction pulmonary disorder (COPD), and lung cancer. All of these conditions affect the gas exchange process and result in labored breathing and other difficulties.

Contributors and Attributions

- OpenStax Anatomy & Physiology (CC BY 4.0). Access for free at https://openstax.org/books/anatomy-and-physiology

This page titled 20.1: Introduction to the Respiratory System is shared under a CC BY-NC-SA 4.0 license and was authored, remixed, and/or curated by Jennifer Lange et al..

- 20.1: Introduction to the Respiratory System by Whitney Menefee, Julie Jenks, Chiara Mazzasette, and Kim-Leiloni Nguyen is licensed CC BY 4.0.

20.2: The Lungs

By the end of this section, you will be able to:

- Describe the overall function of the lungs
- Outline the anatomy of the blood supply to the lungs
- Describe the pleurae of the lungs and their function

A major organ of the respiratory system, each **lung** houses structures of both the conducting and respiratory zones. The main function of the lungs is to perform the exchange of oxygen and carbon dioxide with air from the atmosphere. To this end, the lungs exchange respiratory gases across a very large epithelial surface area—about 70 square meters—that is highly permeable to gases.

Gross Anatomy of the Lungs

The lungs are pyramid-shaped, paired organs that are connected to the trachea by the right and left bronchi; on the inferior surface, the lungs are bordered by the diaphragm. The diaphragm is the flat, dome-shaped muscle located at the base of the lungs and thoracic cavity. The lungs are enclosed by the pleurae, which are attached to the mediastinum. The right lung is shorter and wider than the left lung, and the left lung occupies a smaller volume than the right. The **cardiac notch** is an indentation on the medial surface of the left lung that allows space for the heart (Figure 20.2.1). The apex of the lung is the superior region, whereas the base is the opposite region near the diaphragm. The costal surface of the lung borders the ribs. The mediastinal surface faces the midline. The primary bronchi enter the lungs at the **hilum**, a concave region facing the mediastinum where blood vessels, lymphatic vessels, and nerves also enter the lungs. Collectively this grouping of the bronchi, vessels, and nerves is known as the **lung root**.

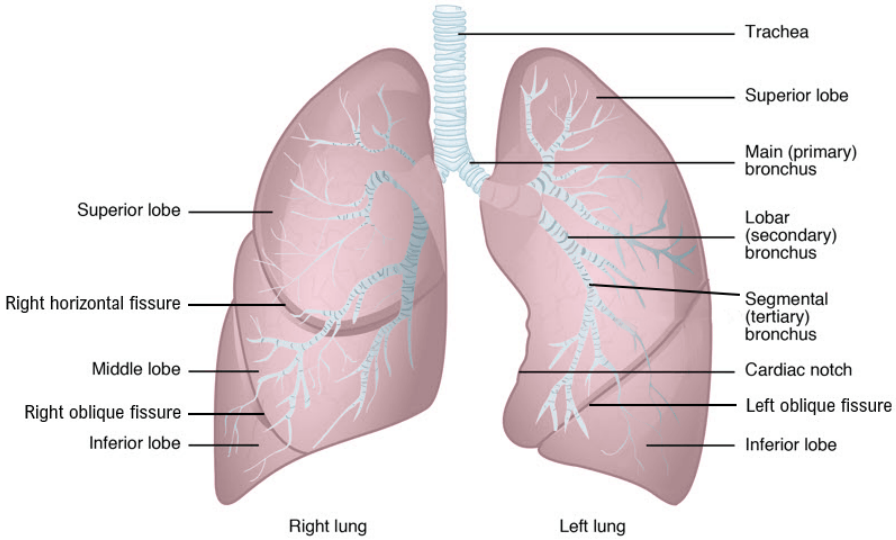

Figure 20.2.1: Gross Anatomy of the Lungs. The left lung is divided into just two lobes and has less mass due to the cardiac notch while the right lung is divided into three lobes. The right superior lobe is separated from the right middle lobe by the right horizontal fissure. The right middle lobe is separated from the right inferior lobe by the right oblique fissure. The left superior lobe is separated from the right inferior lobe by the left oblique fissure. *(Image credit: "Gross Anatomy of the Lungs" by Jennifer Lange is licensed under CC BY-NC-SA 4.0, modification of original work.)*

Each lung is composed of smaller units called **lobes**. Deep grooves called **fissures** separate these lobes from each other; the lobes are only connected near the mediastinum where connective tissue anchors the lungs in place as well as the major pulmonary arteries and veins routing into each lung. The right lung consists of three lobes: the **superior**, **middle**, and **inferior** lobes. The right **superior** and **middl**e lobes are separated by the right **horizontal fissure**, while the right **middle** and **inferior lobes** are

separated by the right **oblique fissure**. The left lung consists of two lobes: the **superior** and **inferior lobes**, separated by the left **oblique fissure**. A **bronchopulmonary segment** is a division of a lobe, and each lobe houses multiple bronchopulmonary segments. Each segment receives air from its own tertiary bronchus and is supplied with blood by its own artery. Some diseases of the lungs typically affect one or more bronchopulmonary segments, and in some cases, the diseased segments can be surgically removed with little influence on neighboring segments. A **pulmonary lobule** is a subdivision formed as the bronchi branch into bronchioles. Each lobule receives its own large bronchiole that has multiple branches. An interlobular septum is a wall, composed of connective tissue, which separates lobules from one another.

The superior tips of the superior lobe is known as the **apex** of the lungs while the broad surface of the inferior lobe is known as the **base** of the lung. The left lung is smaller due to the apex of the heart projecting into it. On the anterior surface, there is the **cardiac notch** which allows for the accomodation of the heart.

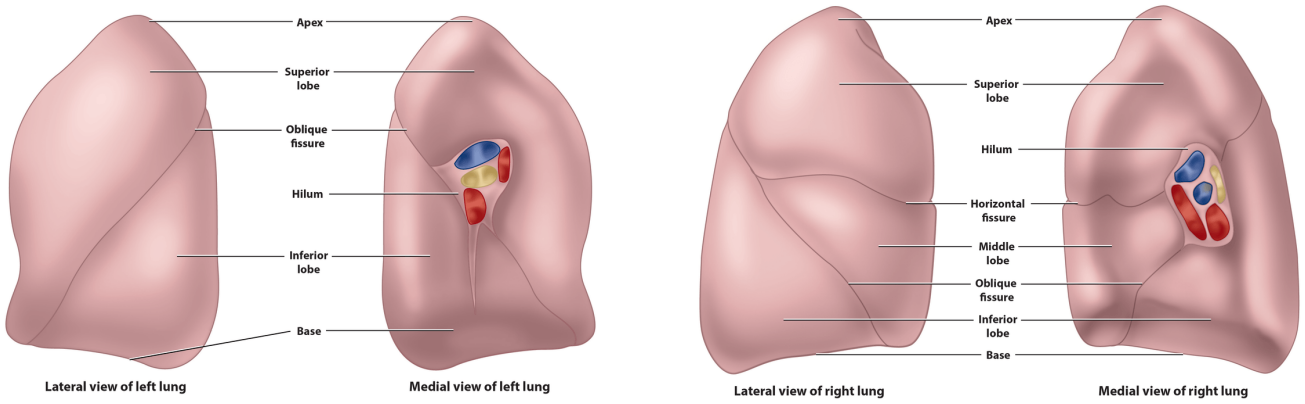

Figure 20.2.2: Lobes and fissures of lungs. The lateral and medial views of the lungs show the fissures that divide each lung into lobes. *(Image credit: "Gross Anatomy of Right and Left Lungs" by BlueLink is licensed under CC BY-NC 4.0 with notification of the original authors, modifications by Jennifer Lange.)*

Blood Supply and Nervous Innervation of the Lungs

The blood supply of the lungs plays an important role in gas exchange and serves as a transport system for gases throughout the body. In addition, innervation by both the parasympathetic and sympathetic nervous systems provides an important level of control through dilation and constriction of the airways.

Blood Supply

The major function of the lungs is to perform gas exchange, which requires blood from the pulmonary circulation. This blood supply contains deoxygenated blood and travels to the lungs where erythrocytes, also known as red blood cells, pick up oxygen to be transported to tissues throughout the body. The **pulmonary arteries** are arteries that arise from the pulmonary trunk and carry deoxygenated, arterial blood to each lung. Each pulmonary artery branches multiple times as it follows the bronchi, and each branch becomes progressively smaller in diameter. One arteriole and an accompanying venule supply and drain one pulmonary lobule. As they near the alveoli, the pulmonary arterioles become the pulmonary capillary network. The pulmonary capillary network consists of tiny vessels with very thin walls that lack smooth muscle fibers. The capillaries branch and follow the bronchioles and structure of the alveoli. It is at this point that the capillary wall meets the alveolar wall, creating the respiratory membrane. Once the blood is oxygenated, it drains from the alveoli by way of multiple pulmonary veins, which exit the lungs through the hilum.

Nervous Innervation

Dilation and constriction of the airway are achieved through nervous control by the parasympathetic and sympathetic nervous systems. The parasympathetic system causes **bronchoconstriction**, whereas the sympathetic nervous system stimulates **bronchodilation**. Reflexes such as coughing, and the ability of the lungs to regulate oxygen and carbon dioxide levels, also result

from this autonomic nervous system control. Sensory nerve fibers arise from the vagus nerve, and from the second to fifth thoracic ganglia. The **pulmonary plexus** is a region on the lung root formed by the entrance of the nerves at the hilum. The nerves then follow the bronchi in the lungs and branch to innervate muscle fibers, glands, and blood vessels.

Pleurae of the Lungs

Each lung is enclosed within a cavity that is surrounded by the pleurae. The pleura (plural = pleurae) is a serous membrane that surrounds each lung. The right and left pleurae, which enclose the right and left lungs, respectively, are separated by the mediastinum. The pleurae consist of two layers. The **visceral pleura** is the layer that is superficial to the lungs, and extends into and lines the lung fissures (Figure 20.2.3). In contrast, the **parietal pleura** is the outer layer that connects to the thoracic wall, the mediastinum, and the diaphragm. The visceral and parietal pleurae connect to each other at the hilum. The **pleural cavity** is the space between the visceral and parietal layers.

The pleurae perform two major functions: They produce pleural fluid (serous fluid) and create cavities that separate the lungs from each other and other thoracic structures. **Pleural fluid** is secreted by mesothelial cells from both pleural layers and acts to lubricate their surfaces. This lubrication reduces friction between the two layers to prevent trauma during breathing, and creates surface tension that helps maintain the position of the lungs against the thoracic wall. This adhesive characteristic of the pleural fluid causes the lungs to enlarge when the thoracic wall expands during ventilation, allowing the lungs to fill with air. The pleurae also create a division between major organs that prevents interference due to the movement of the organs, while preventing the spread of infection.

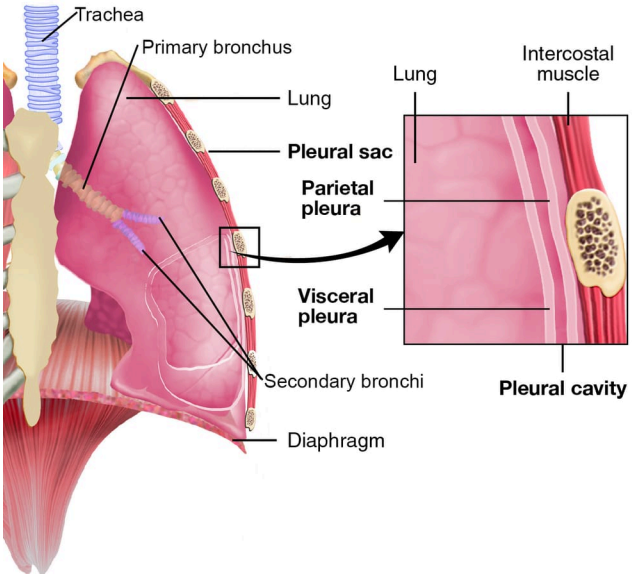

Figure 20.2.3: Parietal and Visceral Pleurae of the Lungs. The pleural sac is formed by the parietal and visceral pleura of the lungs. The parietal pleura is attached to the deep surface of the chest wall, which includes the ribs, sternum, thoracic vertebrae, connective tissue of the mediastinum, internal intercostal muscles, and the superior surface of the diaphragm. The visceral pleura covers the superficial surface of the lobes of the lungs. The pleural cavity is the potential space between the layers that is filled with lubricating serous fluid. (Image credit: "The Lung Pleurae" by OpenStax is licensed under CC BY 3.0. Image edited by Gabrielle Spurlock.)

DISORDERS OF THE...

Respiratory System: Pneumothorax

A pneumothorax is a condition in which a rupture caused by trauma or disease introduces air into the pleural cavity. The air increases pressure on the surface of the lung on the affected side, breaking the surface tension that adheres the visceral pleura to the parietal pleura throughout increases and decreases in the volume of the thoracic cavity during ventilation. With the surface tension between the pleurae broken, the lung collapses due to elastic recoil (Figure 20.2.4). Treatment may include manual aspiration of the air, along with treatment of the underlying cause of the pneumothorax.

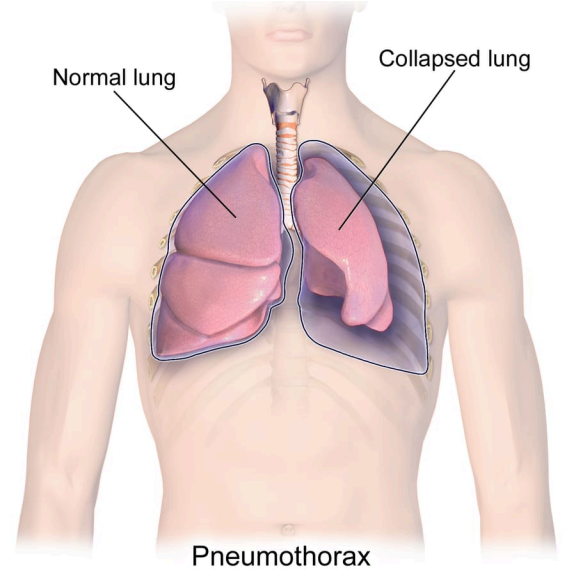

Figure 20.2.4: Pneumothorax. A pneumothorax is caused by air in the pleural cavity, which increases pressure on the lung, causing it to collapse. (Image credit: "Blausen 0742 Pneumothorax" by Bruce Blaus Blausen.com staff, Medical gallery of Blausen Medical is licensed under CC BY 3.0)

EVERYDAY CONNECTION

The Effects of Second-Hand Tobacco Smoke

The burning of a tobacco cigarette creates multiple chemical compounds that are released through mainstream smoke, which is inhaled by the smoker, and through sidestream smoke, which is the smoke that is given off by the burning cigarette. Second-hand smoke, which is a combination of sidestream smoke and the mainstream smoke that is exhaled by the smoker, has been demonstrated by numerous scientific studies to cause disease. At least 40 chemicals in sidestream smoke have been identified that negatively impact human health, leading to the development of cancer or other conditions, such as immune system dysfunction, liver toxicity, cardiac arrhythmias, pulmonary edema, and neurological dysfunction. Furthermore, second-hand smoke has been found to harbor at least 250 compounds that are known to be toxic, carcinogenic, or both. Some major classes of carcinogens in second-hand smoke are polyaromatic hydrocarbons (PAHs), N-nitrosamines, aromatic amines, formaldehyde, and acetaldehyde.

Tobacco and second-hand smoke are considered to be carcinogenic. Exposure to second-hand smoke can cause lung cancer in individuals who are not tobacco users themselves. It is estimated that the risk of developing lung cancer is increased by up to 30 percent in nonsmokers who live with an individual who smokes in the house, as compared to nonsmokers who are not regularly exposed to second-hand smoke. Children are especially affected by second-hand smoke. Children who live with an individual who smokes inside the home have a larger number of lower respiratory infections, which are associated with hospitalizations, and higher risk of sudden infant death syndrome (SIDS). Second-hand smoke in the home has also been linked to a greater number of ear infections in children, as well as worsening symptoms of asthma.

Concept Review

The lungs are the major organs of the respiratory system and are responsible for performing gas exchange. The lungs are paired and separated into lobes; The left lung consists of two lobes, whereas the right lung consists of three lobes. Blood circulation is very important, as blood is required to transport oxygen from the lungs to other tissues throughout the body and deliver carbon dioxide to the lungs for removal. The function of the pulmonary circulation is to aid in gas exchange. The pulmonary artery provides deoxygenated blood to the capillaries that form respiratory membranes with the alveoli, and the pulmonary veins return newly oxygenated blood to the heart for further transport throughout the body. The lungs are innervated by the parasympathetic and sympathetic nervous systems, which coordinate bronchodilation and bronchoconstriction of the airways. The lungs are enclosed by the pleurae, a membrane that is composed of visceral and parietal pleural layers. The space between

these two layers is called the pleural cavity. The mesothelial cells of the pleural membrane create pleural (serous) fluid, which serves as both a lubricant (to reduce friction during breathing) and as an adhesive to adhere the lungs to the thoracic wall (to facilitate movement of the lungs during ventilation).

Review Questions

Query 20.2.1

This interactive element is not available in this format. Visit the link or scan the QR code to access it online.

View this Interactive Content online

Critical Thinking Questions

Query 20.2.2

This interactive element is not available in this format. Visit the link or scan the QR code to access it online.

View this Interactive Content online

Query 20.2.3

This interactive element is not available in this format. Visit the link or scan the QR code to access it online.

View this Interactive Content online

Glossary

Query 20.2.4

This interactive element is not available in this format. Visit the link or scan the QR code to access it online.

View this Interactive Content online

References

McKnight CL, Burns B. Pneumothorax. 2020 Nov 16. In: StatPearls [Internet]. Treasure Island (FL): StatPearls Publishing; 2021 Jan–. PMID: 28722915. Licensed under CC BY 4.0. [Accessed 30 Apr 2021]

Contributors and Attributions

- OpenStax Anatomy & Physiology (CC BY 4.0). Access for free at https://openstax.org/books/anatomy-and-physiology

This page titled 20.2: The Lungs is shared under a CC BY-NC-SA 4.0 license and was authored, remixed, and/or curated by Jennifer Lange et al..

- 20.3: The Lungs by Whitney Menefee, Julie Jenks, Chiara Mazzasette, and Kim-Leiloni Nguyen is licensed CC BY 4.0.

20.3: Conducting Zone

By the end of this section, you will be able to:

- List the organs that make up the conducting zone of the respiratory system
- Describe the structure and related functions of the respiratory epithelium
- Name the cartilages of the larynx and vocal cords and explain their role in voice production
- Compare and contrast the structure of the tracheobronchial tree regions

The major organs of the respiratory system function primarily to provide oxygen to body tissues for cellular respiration, remove the waste product carbon dioxide, and help to maintain acid-base balance. Portions of the respiratory system are also used for non-vital functions, such as sensing odors, speech production, and straining, such as during childbirth or coughing (Figure 20.3.1).

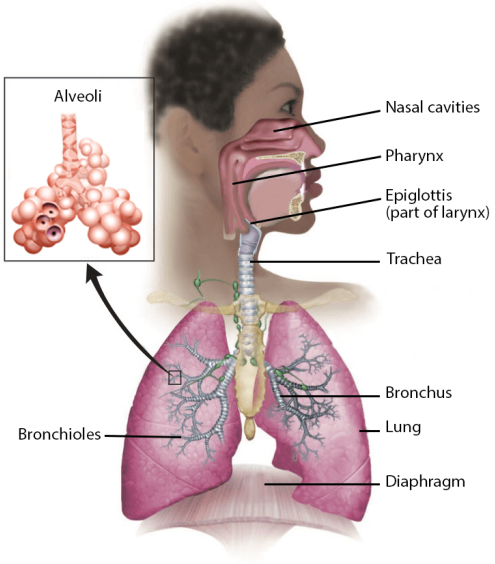

Figure 20.3.1: Respiratory System Organs. The organs of the respiratory system conduct air to the lungs for gas exchange. *(Image credit: "Respiratory System Organs" by Jennifer Lange is licensed under CC BY-NC-SA 4.0, modification of "OLI - Drawing Lower respiratory tract and detail of alveoli - English labels" by KnowledgeWorks Global Ltd..)*

Functionally, the respiratory system can be divided into a conducting zone and a respiratory zone. The **conducting zone** of the respiratory system includes the organs and structures not directly involved in gas exchange. Gas exchange occurs in the **respiratory zone**. The conducting zone delivers air to and from the respiratory zone.

Conducting Zone

The major functions of the conducting zone are to provide a route for incoming and outgoing air, remove debris and pathogens from the incoming air, and warm and humidify the incoming air. Several structures within the conducting zone perform other functions as well. The epithelium of the nasal passages, for example, is essential to sensing odors, and the larynx is our voice box.

The Nose and its Adjacent Structures

The primary entrance and exit for the respiratory system is through the nose. When discussing the nose, it is helpful to divide it into two major sections: the external nose, and the nasal cavity or internal nose.

The **external nose** consists of the surface and skeletal structures that result in the outward appearance of the nose and contribute

to its numerous functions (Figure 20.3.2).

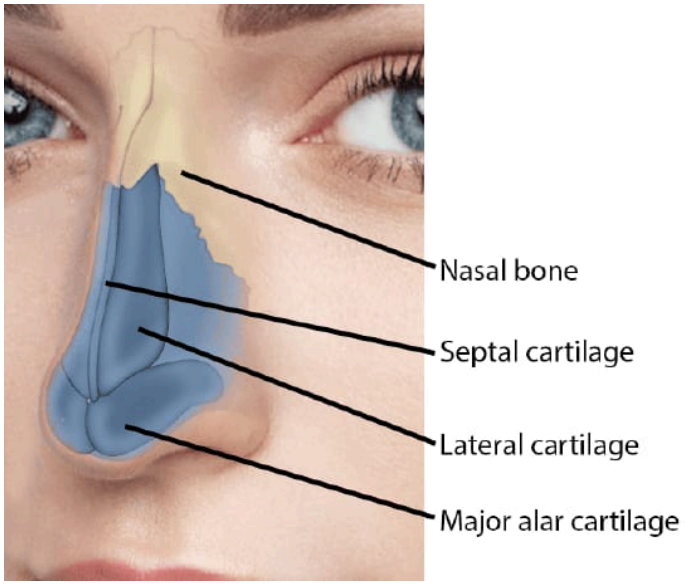

Figure 20.3.2: Nose. The major skeletal and cartilaginous features supporting the structure of the external nose. (Image credit: "Nasal Cartilages" by Jennifer Lange is licensed under *CC BY-NC-SA 4.0*, *modification of Rinoplasti by https://www.ozanbalik.com*.)

While the superior aspect of the nose consists of bone, most of the protruding portion of the nose is composed of hyaline cartilage. As a result, when looking at a skull much of the nose is missing. The **nasal bone** is one of a pair of bones that lies under the bridge of the nose. The nasal bone articulates superiorly with the frontal bone and laterally with the maxillary bones.

On either side of the midline, the **alar cartilages** and **lateral cartilages**, form the medial portion of the **external nares**, the narrow openings into each nasal cavity. The lateral portion of the external nares lack cartilage. The external nares open into the nasal cavities, which is separated into left and right sections by the nasal septum. The **nasal septum** is formed anteriorly by a portion of the **septal cartilage**, the flexible hyaline cartilage you can move with your fingers that forms the majority of the dorsum nasi, and posteriorly by the perpendicular plate of the ethmoid bone superiorly and the vomer bone inferiorly.

Each lateral wall of the nasal cavity has three bony projections, called the **superior, middle, and inferior nasal conchae** (Figure 20.3.3). The inferior nasal conchae are separate bones, whereas the superior and middle nasal conchae are portions of the ethmoid bone. Several bones that help form the walls of the nasal cavity have hollowed air-containing spaces called the paranasal sinuses. The increased surface area of both the nasal cavities and the sinuses contribute to the richness of the tone of sounds produced, as evidenced by the change in your voice when you plug your nose or are congested.

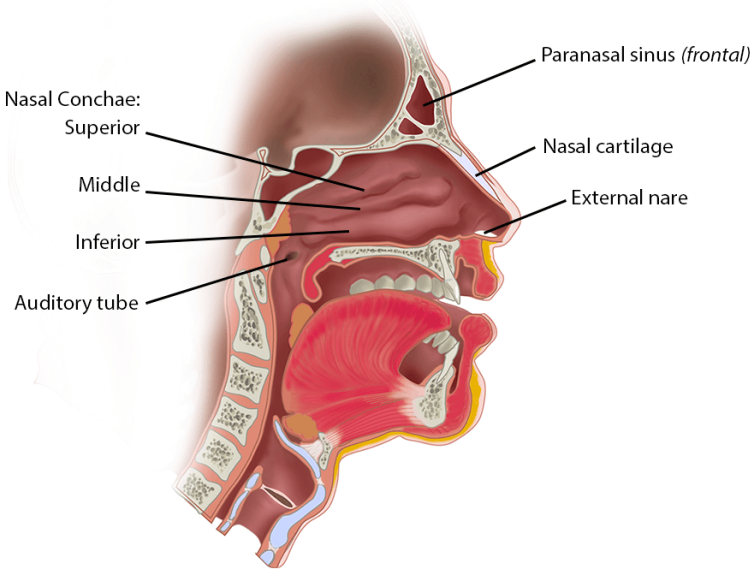

Figure 20.3.3: Nasal Passages - Sagittal Section. Air passes through the external naris and enters the nasal cavity, which has raised nasal conchae protruding into the space. *(Image credit: "Nasal Cavities" by Jennifer Lange is licensed under CC BY-NC-SA 4.0, modification of "Slagter - Drawing Head and neck: sagittal section - no labels" by Ron Slagter.)*

Each **paranasal sinus** is named for its associated bone: frontal sinus, maxillary sinus, sphenoidal sinus, and ethmoidal sinuses. The hollowed sinuses also lighten the weight of the skull.The **frontal sinus** is located just above the eyebrows, within the frontal bone (Figure 20.3.3 and Figure 20.3.4). This irregular space may be divided at the midline into bilateral spaces, or these may be fused into a single sinus space. The frontal sinus is the most anterior of the paranasal sinuses. The largest sinus is the **maxillary sinus** (Figure 20.3.4). These are paired and located within the right and left maxillary bones, where they occupy the area just below the orbits. The maxillary sinuses are most commonly involved during sinus infections. Because their connection to the nasal cavity is located high on their medial wall, they are difficult to drain. The **sphenoid sinus** is a single, midline sinus . It is located within the body of the sphenoid bone, just anterior and inferior to the sella turcica, thus making it the most posterior of the paranasal sinuses. The lateral aspects of the ethmoid bone contain multiple small spaces separated by very thin bony walls (Figure 20.3.4). Each of these spaces is called an **ethmoid air cell**. These are located on both sides of the ethmoid bone, between the upper nasal cavity and medial orbit, just behind the superior nasal conchae.

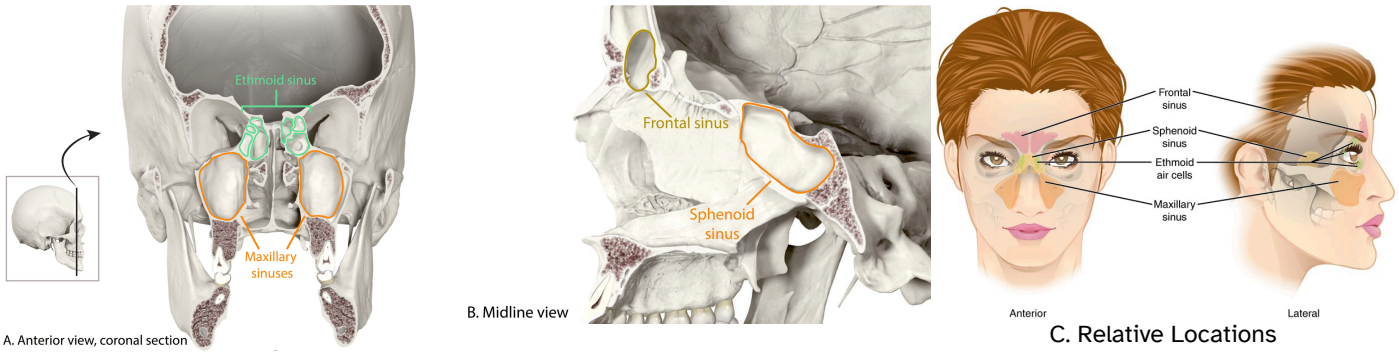

Figure 20.3.4: Paranasal Sinuses. The paranasal sinuses are hollow, air-filled spaces named for the skull bone that each occupies. The most anterior is the frontal sinus, located in the frontal bone above the eyebrows. The largest are the maxillary sinuses, located in the right and left maxillary bones below the orbits. The most posterior is the sphenoid sinus, located in the body of the sphenoid bone, under the sella turcica. The ethmoid air cells are multiple small spaces located in the right and left sides of the ethmoid bone, between the medial wall of the orbit and lateral wall of the upper nasal cavity. *(Images A and B credit: "Paranasal Sinuses" by Mark Schaeffer are licensed under CC BY-NC-SA 4.0, modification of image from Anatomy Standard under CC BY-NC 4.0. Image C credit: "Paranasal Sinuses" by OpenStax is licensed under CC BY 3.0)*

The external nares and nasal vestibule at the anterior portion of each nasal cavity are composed of skin: lined with stratified squamous epithelium and contain sebaceous glands and hair follicles embedded in the dermis that serve to prevent the passage of large debris, such as dirt, through the nasal cavity.

Respiratory Epithelium

The conchae, meatuses, and paranasal sinuses are lined by a mucous membrane or mucosa called the **respiratory epithelium** composed of ciliated pseudostratified columnar epithelium (Figure 20.3.5 shows the epithelium lining in the trachea). (Mucous spelled with an "o" is the adjective form of the word, while mucus spelled without an "o" is the noun form used to describe the secretion produced by mucous membranes.) The respiratory epithelium contains goblet cells, one of the specialized, columnar epithelial cells that produce mucus to trap debris. The cilia of the respiratory epithelium help remove the mucus and debris from the nasal cavity with a constant beating motion, sweeping materials towards the throat to be swallowed. Interestingly, cold air slows the movement of the cilia, resulting in accumulation of mucus that may in turn lead to a runny nose during cold weather.

The tissue-covered nasal conchae and meatuses within the nasal cavities create turbulent airflow and provide an increased surface area to aid in filtering, warming, and humidifying air as it enters the body. Capillaries located just beneath the nasal epithelium warm the air by convection. Immune cells that patrol the connective tissue deep to the respiratory epithelium provide additional protection.

A specialized olfactory epithelium used to detect odors (olfaction is the sense of smell) is found at the superior surface of the nasal cavity in the area of the olfactory foramina of the ethmoid bone and is covered in more detail in the chapter that includes the special senses of the nervous system.

Figure 20.3.5: Ciliated Pseudostratified Columnar Epithelium. The respiratory epithelium consists of a ciliated pseudostratified columnar epithelium featuring cilia at the apical surface facing the lumen of the airway and goblet cells that secrete mucus. Seromucous glands embedded in the dense irregular connective tissue of the submucosa provide additional lubricating mucus. LM × 680. *(Image credit: "Pseudostratified Epithelium" by OpenStax is licensed under CC BY 3.0 / Micrograph provided by the Regents of University of Michigan Medical School © 2012)*

Pharynx

Inhaled air moves deeper into the upper airway when it leaves the nasal cavities via the **internal nares**, also known as posterior nasal apertures, narrowings at the back of each nasal cavity, and moves into the pharynx. The **pharynx** is a tube formed by skeletal muscle and lined by mucous membrane that is continuous with that of the nasal cavities. The pharynx is divided into three major regions: the nasopharynx, the oropharynx, and the laryngopharynx (Figure 20.3.6).

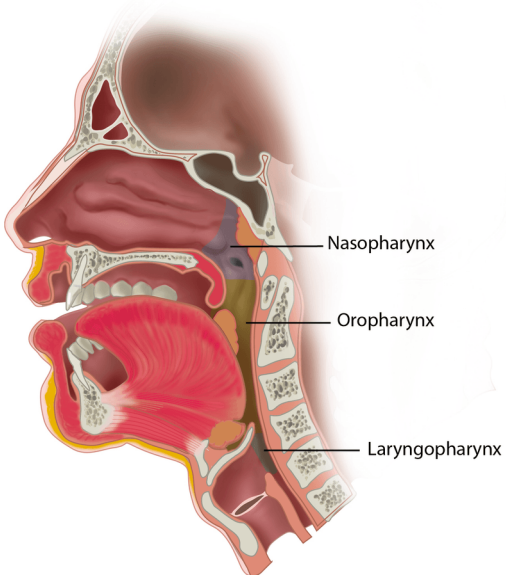

Figure 20.3.6: Divisions of the Pharynx. The pharynx a shared respiratory and digestive structure that is divided into three regions: the nasopharynx, the oropharynx, and the laryngopharynx. *(Image credit:"Regions of the Pharynx" by Jennifer Lange is licensed under CC BY-NC-SA 4.0, modification of "Slagter - Drawing Head and neck: sagittal section - no labels" by Ron Slagter.)*

The **nasopharynx** is posterior to the conchae of the nasal cavity, and it is meant to serve only as an airway. The **uvula** is a small bulbous, teardrop-shaped structure located at the apex of the soft palate. Both the uvula and soft palate move like a pendulum during swallowing, swinging upward to close off the nasopharynx to prevent ingested materials from entering the nasal cavity. In addition, auditory (Eustachian) tubes that connect to each middle ear cavity open into the nasopharynx. This connection is why colds may lead to ear infections.

Unlike the nasopharynx which is a passageway for air only, the **oropharynx** is a passageway for both air and food. The oropharynx is bordered superiorly by the nasopharynx and anteriorly by the oral cavity. As the nasopharynx becomes the oropharynx, the epithelium changes from ciliated pseudostratified columnar epithelium to a stratified squamous epithelium.

The **laryngopharynx** is inferior to the oropharynx. It continues the route for ingested material and air until its inferior end, where the digestive and respiratory systems diverge. It is posterior to the open epiglottis, allowing air to move in and out of the larynx. When you swallow ingested material, the epiglottis closes and the material moves into the esophagus. The stratified squamous epithelium of the oropharynx is continuous with the laryngopharynx.

Larynx

The **larynx** is a cartilaginous structure inferior to the laryngopharynx that connects the pharynx to the trachea and helps regulate the volume of air that enters and leaves the lungs, protects the respiratory passages from ingested materials, and produces sound (Figure 20.3.7). The structure of the larynx is formed by several pieces of cartilage. With the exception of the epiglottis, the cartilages of the larynx are comprised of hyaline cartilage. Three large cartilage pieces—the thyroid cartilage (anterior), epiglottis (superior), and cricoid cartilage (inferior)—form the major structure of the larynx, which is also known as the voice box. The **thyroid cartilage** is the largest piece of cartilage that makes up the larynx and functions to form a protective shield across the anterior of the larynx. The thyroid cartilage consists of the **laryngeal prominence**, or “Adam’s apple,” which tends to be more prominent in males. The thick **cricoid cartilage** forms a continuous ring around the larynx to hold the airway open as pressure changes during ventilation. It has a taller posterior region and a shorter anterior region inferior to the thyroid cartilage. The cricoid cartilage is connected to the thyroid cartilage by the cricothyroid ligament across the midline anteriorly and is connected to the most superior cartilage of the trachea by the cricotracheal ligament. Three smaller, paired cartilages—the arytenoids, corniculates, and cuneiforms—attach to the epiglottis and the vocal cords as well as the muscle that helps move the vocal cords to produce sound.

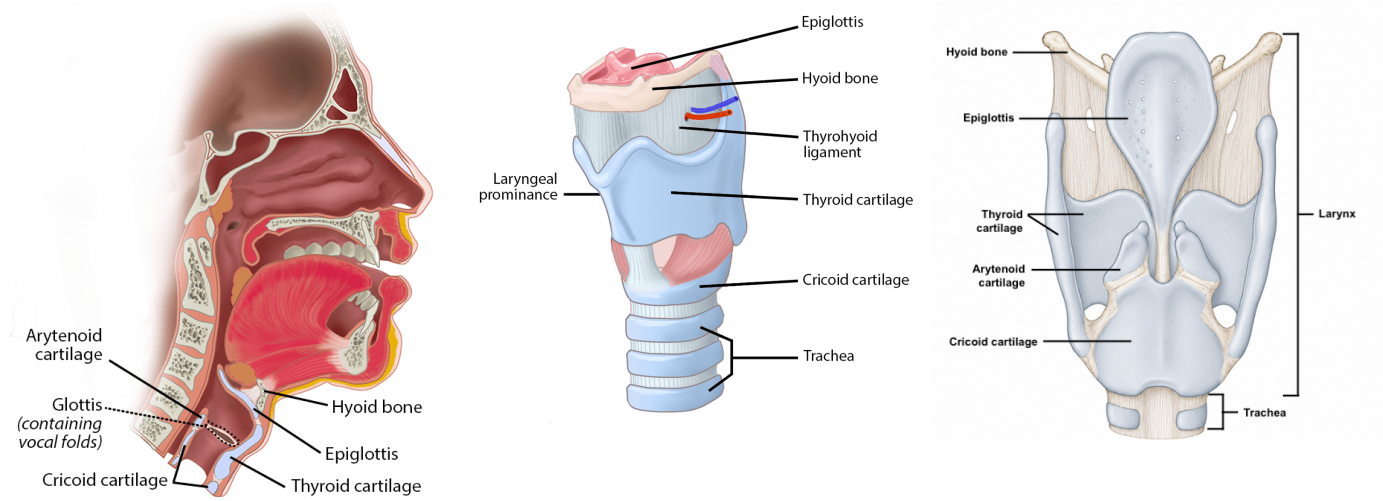

Figure 20.3.7: Larynx. The larynx is comprised of several cartilaginous structures connected by ligaments. Within the larynx the vocal folds attach anteriorly to the thyroid cartilage and posteriorly to the arytenoid cartilage. *(Image credit: "Larynx - Midsagittal View" by Jennifer Lange is licensed under CC BY-NC-SA 4.0, modification of "Slagter - Drawing Head and neck: sagittal section - no labels" by Ron Slagter. "Larynx - Anterolateral View" by Jennifer Lange and John Polos is licensed under CC BY-NC-SA 4.0, modification of "Slagter - Drawing Larynx anatomy: anterior lateral view - no labels" by Ron Slagter. "Larynx - Posterior View" by Jennifer Lange (using ChatGPT) is licensed under CC BY-NC-SA 4.0.)*

The **epiglottis**, attached to the thyroid cartilage by a ligament, is a very flexible piece of elastic cartilage that is tethered to the body of the hyoid bone and remains open unless you are swallowing. When the hyoid bone moves during swallowing, the pharynx and larynx are lifted upward, allowing the pharynx to expand and the epiglottis to swing downward to cover the glottis. These movements produce a larger area for food to pass through, while preventing ingested food and beverages from entering the trachea.

The **glottis** is composed of the vestibular folds, the true vocal cords, and the space between these folds through which air passes to and from the trachea (Figure 20.3.8). A **vestibular fold**, or false vocal cord, is one of a pair of folded sections of mucous membrane that sit superior to the vocal folds and may function to protect the vocal folds and amplify sound. A **true vocal cord (or vocal fold)** is one of the white, membranous folds attached by muscle to the thyroid and arytenoid cartilages of the larynx on their outer edges. The inner edges of the true vocal cords contain an elastic vocal ligament covered in epithelial tissue that vibrates as air moves across it to produce sound. The size of the membranous folds of the true vocal cords differs between individuals, producing voices with different pitch ranges. Folds in males tend to be larger than those in females, which create a deeper voice. Movements of the muscles attaching the folds to the thyroid and arytenoid cartilages reposition the vocal folds to adjust the pitch of sounds produced.

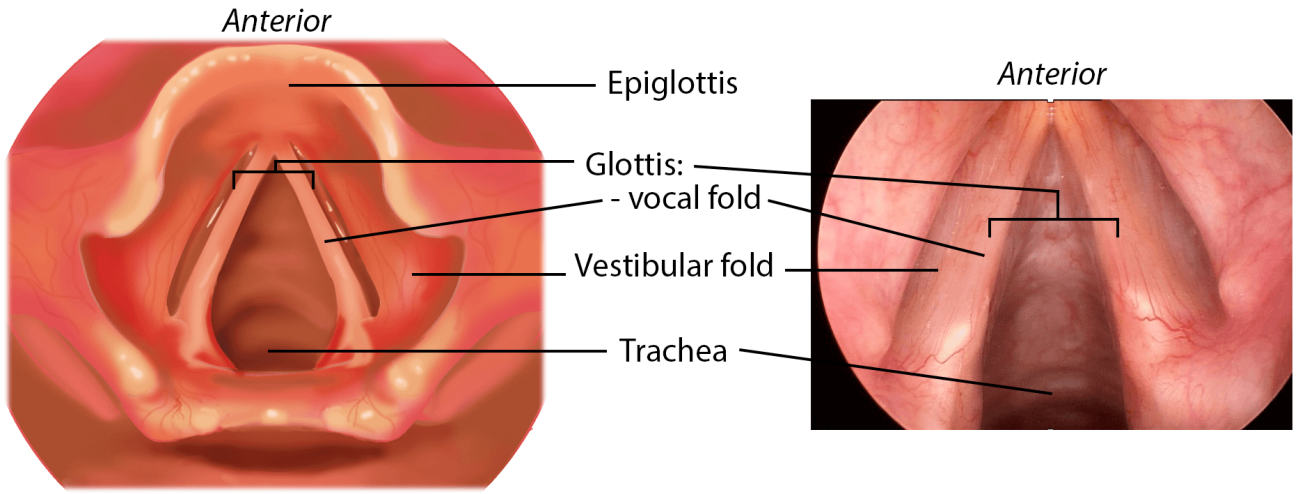

Figure 20.3.8: Glottis. The glottis inside the larynx includes the vocal folds and the open space between them. A superior view shows the open epiglottis at the anterior and the trachea inferior to the glottis, visible beyond the opening of the V-shaped vocal folds. *(Image credit: "Glottis and Vocal Cords" by Jennifer Lange is licensed under CC BY-NC-SA 4.0, based on illustration "Slagter - Drawing Larynx and vocal cords - no labels" by Ron Slagter and photo "Cuerdasvocales", via Wikimedia Commons.)*

Continuous with the laryngopharynx, the superior portion of the larynx is lined with stratified squamous epithelium, transitioning into ciliated pseudostratified columnar epithelium that contains goblet cells. Similar to the nasal cavity and nasopharynx, this specialized epithelium produces mucus to trap debris and pathogens as they enter the trachea. Beginning in this region and continuing throughout much of the conducting zone, cilia beat the mucus upward towards the laryngopharynx, where it can be swallowed down the esophagus into the acidic environment of the stomach that functions to kill pathogens trapped in the mucus. The action of the cilia moving the mucus upward to be swallowed is referred to as the mucous escalator.

Trachea

The **trachea** (windpipe) extends from the larynx toward the lungs (Figure 20.3.9). The mucosal layer of the wall of the trachea is lined with ciliated pseudostratified columnar epithelium featuring mucus-secreting goblet cells and covering a lamina propria of areolar connective tissue. The submucosa contains dense irregular connective tissue and houses seromucous glands that secrete a lubricating mucus that shares properties with serous fluid. The wall of the trachea contains 16 to 20 stacked, C-shaped pieces of hyaline cartilage that are positioned horizontally with the opening in the C at the back of the trachea. The incomplete rings of cartilage provide structural support that prevent the trachea from collapsing and protect it. The cartilages are connected to one another by dense connective tissue. The **fibroelastic membrane** consists of the **trachealis muscle**, made of smooth muscle, and elastic connective tissue. It is a flexible membrane that spans the gap across the the C-shaped cartilages at the posterior of the trachea, allowing the trachea to stretch and expand slightly during inhalation and exhalation. Its flexibility also allows the trachea to accommodate ingested materials passing through the esophagus that borders the trachea posteriorly. In addition, the smooth muscle of the trachealis muscle can be contracted to force air through the trachea during exhalation. The superficial wrapping of the trachea is an adventitia of dense irregular connective tissue.

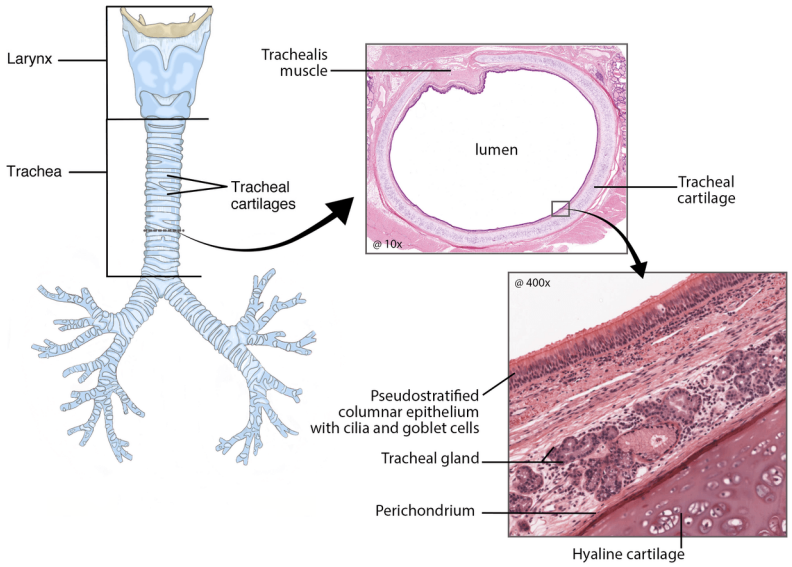

Figure 20.3.9: Trachea. The mucosa lining the hollow lumen of the trachea is comprised of ciliated pseudostratified columnar epithelium that contains goblet cells covering a lamina propria of connective tissue. The submucosa houses seromucous tracheal glands. The C-shaped rings of hyaline cartilage are positioned deep to the mucosa with the opening at the posterior, which is spanned by the trachealis muscle and connective tissue. The superficial layer of the trachea is adventitia. The esophagus is positioned posterior to the trachea. *(Image credit: "Trachea" by Jennifer Lange is licensed under CC BY-NC-SA 4.0, modification of illustration by Open Stax College, slide @ 10x provided by Virginia Commonwealth University and slide @ 400x provided by the Regents of the University of Michigan Medical School © 2022.)*

Bronchial Tree

The trachea branches into the right and left **primary (main) bronchi** (singular = bronchus) at the **carina**. The carina is a raised structure that contains specialized nervous tissue that induces violent coughing if a foreign body, such as food, is present. These bronchi are also lined by ciliated pseudostratified columnar epithelium containing mucus-producing goblet cells (Figure 20.3.10). Rings of cartilage, similar to those of the trachea, support the structure of the bronchi and prevent their collapse. The primary bronchi branch to the **secondary (lobar) bronchi** that deliver air to the individual lobes of each lung. The secondary bronchi branch to the **tertiary (segmental) bronchi** that deliver air to the bronchopulmonary segments that comprise each lobe.

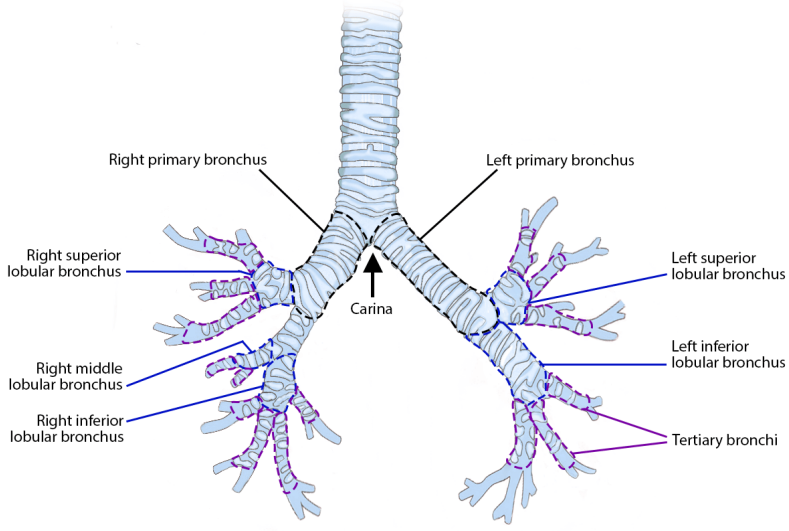

Figure 20.3.10: Bronchi. The trachea branches at the carina into the right and left primary bronchi that deliver air to each lung. The primary bronchi branch into the secondary bronchi that deliver air to the lobes of each lung. The secondary bronchi branch into the tertiary bronchi that deliver air into the bronchopulmonary segments of each lobe. *(Image credit: "Bronchi" by Jennifer Lange is licensed under CC BY-NC-SA 4.0; contains modification of original by OpenStax College.)*

The **bronchial tree** (or respiratory tree) is the collective term used for these highly branching bronchi, since they resemble branches of an upside-down tree (Figure 20.3.10 and Figure 20.3.11). The main function of the bronchi, like other conducting zone structures, is to provide a passageway for air to move into and out of each lung. In addition, the mucous membrane traps debris and pathogens, cilia continue to work as a mucous escalator moving mucus up toward the laryngopharynx to be swallowed. Hyaline cartilage is featured within the wall of all the bronchi to reinforce the airways and help them stay open through pressure changes, but its quantity decreases with each branch point. The C-shaped rings of cartilage in the trachea become irregular plates of cartilage in the bronchi that are smaller and more sporadic in the tertiary bronchi than in the primary bronchi. A layer of smooth muscle is present in the bronchi that may **bronchoconstrict**, make the lumen diameter smaller by contracting the smooth muscle, or **bronchodilate**, make the lumen diameter larger by relaxing the smooth muscle, to adjust air flow in each passage. The quantity of smooth muscle in the wall relative to the lumen diameter increases with each branch point, meaning that the capability to adjust air flow is greater in the tertiary bronchi than in the primary bronchi.

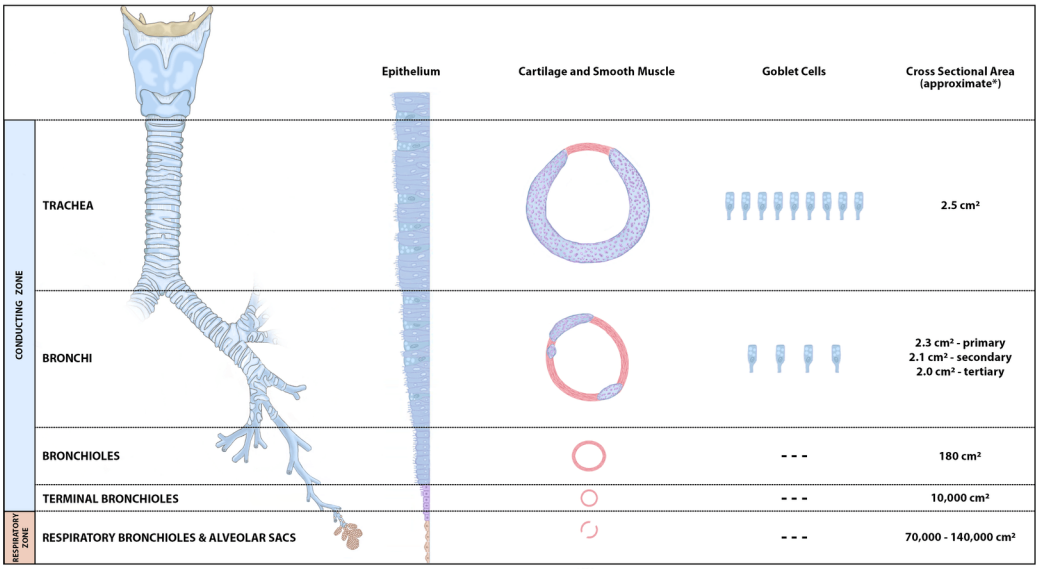

Figure 20.3.11: Tracheobronchial Tree. As the airways branch and spread out within the lungs the histological structure changes and the total cross sectional area increases logarithmically. *Values are intended to be illustrative because actual values differ based on the technique used for calculation (see Rao & Johncy, 2022). *(Image credit: "Tracheobronchial Tree" by Jennifer Lange is licensed under CC BY-NC-SA 4.0; contains modification of original by OpenStax College.)*

Bronchi continue to branch from the tertiary bronchi, getting smaller and smaller, until they become bronchioles. **Bronchioles**, which are 1 mm in diameter or less, further branch until they become the tiny terminal bronchioles, which lead to the structures of gas exchange. There are approximately 30,000 terminal bronchioles in each lung. As they branch, the epithelium of the bronchioles transitions from ciliated pseudostratified columnar epithelium to a thinner simple columnar epithelium to an even thinner simple cuboidal epithelium in the terminal bronchioles. Cilia and mucus-producing cells are sporadic in the largest bronchioles and then disappear as the bronchioles get smaller. The walls of the bronchioles do not contain cartilage like those of the bronchi, but they feature a significant layer of smooth muscle to change their diameter to adjust air flow.

DISORDERS OF THE...

Respiratory System: Asthma

Asthma is common condition that affects the lungs in both adults and children. Approximately 8.2 percent of adults (18.7 million) and 9.4 percent of children (7 million) in the United States suffer from asthma. In addition, asthma is the most frequent cause of hospitalization in children.

Asthma is a chronic disease characterized by inflammation and edema of the airway, and bronchospasms (that is, constriction of the bronchioles), which can inhibit air from entering the lungs. In addition, excessive mucus secretion can occur, which further contributes to airway occlusion (Figure 20.3.11). Cells of the immune system, such as eosinophils and macrophages, may also be involved in infiltrating the walls of the bronchi and bronchioles.

Bronchospasms occur periodically and lead to an “asthma attack.” An attack may be triggered by environmental factors such as dust, pollen, pet hair, or dander, changes in the weather, mold, tobacco smoke, and respiratory infections, or by exercise and stress.

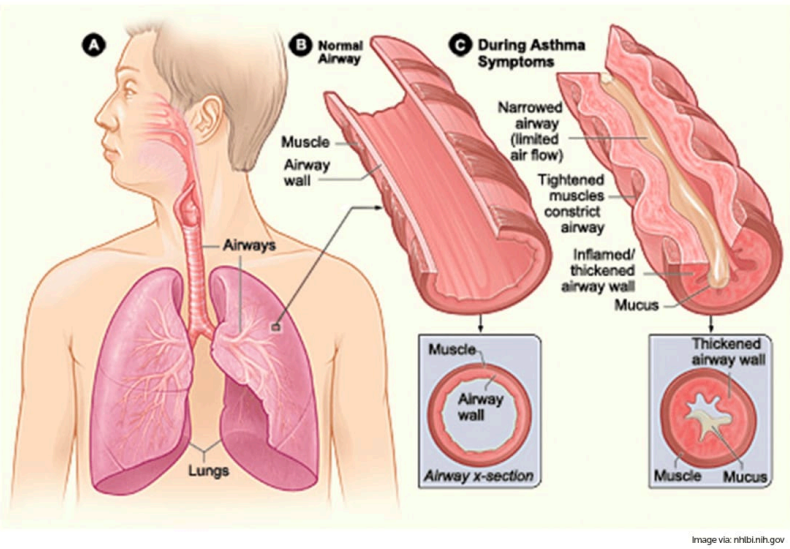

Figure 20.3.12: Normal and Asthmatic Bronchial Tissues. The picture shows a closeup of normal and asthmatic lung tissue. Normal lung tissue (B) does not have the characteristics of lung tissue during an asthma attack (C), which include thickened mucosa, increased mucus-producing goblet cells, increased numbers of macrophages and mast cells, and eosinophil infiltrates. (Image credit: "Asthma by NIH is licensed under CC BY 2.0)

Symptoms of an asthma attack involve coughing, shortness of breath, wheezing, and tightness of the chest. Symptoms of a severe asthma attack that requires immediate medical attention would include difficulty breathing that results in blue (cyanotic) lips or face, confusion, drowsiness, a rapid pulse, sweating, and severe anxiety. The severity of the condition, frequency of attacks, and identified triggers influence the type of medication that an individual may require. Longer-term treatments are used for those with more severe asthma. Short-term, fast-acting drugs that are used to treat an asthma attack are typically administered via an inhaler. For young children or individuals who have difficulty using an inhaler, asthma medications can be administered via a nebulizer.

In many cases, the underlying cause of the condition is unknown. However, recent research has demonstrated that certain viruses, such as human rhinovirus C (HRVC), and the bacteria *Mycoplasma pneumoniae* and *Chlamydia pneumoniae* that are contracted in infancy or early childhood, may contribute to the development of many cases of asthma.

Concept Review

The respiratory system is responsible for obtaining oxygen and getting rid of carbon dioxide, and aiding in speech production and in sensing odors. From a functional perspective, the respiratory system can be divided into two major areas: the conducting zone and the respiratory zone.

The conducting zone consists of all of the structures that provide passageways for air to travel into and out of the lungs:

- nasal cavities - contain the conchae and meatuses that expand the surface area of the cavity, which helps to warm and humidify incoming air, while removing debris and pathogens;
- pharynx - composed of three major sections:
  - the nasopharynx, which is continuous with the nasal cavity
  - the oropharynx, which borders the nasopharynx and the oral cavity and
  - the laryngopharynx, which connects the oropharynx to the larynx and esophagus;
- larynx - a cartilaginous structure involved in passing air to and from the trachea (while blocking food from entering) and sound production;
- trachea - long tube lined with respiratory epithelium and supported by cartilage that conducts air from the cervical region to

the thoracic region;
- bronchi - three levels of cartilage supported tubes lined with respiratory epithelium:
  - primary bronchi lead to each lung,
  - secondary bronchi lead to each lobe of the lung,
  - tertiary bronchi lead to each segment of each lobe;
- most bronchioles - conduct air to the respiratory zone.

The structure of the airway wall progressively changes as the branches go deeper into the lungs and air is distributed into smaller but more numerous tubes. Changes include:

- the diameter of the individual tubes decreases
- the amount of hyaline cartilage supporting the tube wall decreases
- the extent of the of smooth muscle surrounding the airways increases
- the epithelial tissue becomes progressively thinner.

Review Questions

Query 20.3.1

This interactive element is not available in this format. Visit the link or scan the QR code to access it online.

View this Interactive Content online

Critical Thinking Questions

Query 20.3.2

This interactive element is not available in this format. Visit the link or scan the QR code to access it online.

View this Interactive Content online

Query 20.3.3

This interactive element is not available in this format. Visit the link or scan the QR code to access it online.

View this Interactive Content online

Query 20.3.4

This interactive element is not available in this format. Visit the link or scan the QR code to access it online.

View this Interactive Content online

References

Ananda Rao, A., & Johncy, S. (2022). Tennis Courts in the Human Body: A Review of the Misleading Metaphor in Medical Literature. *Cureus*, *14*(1), e21474. https://doi.org/10.7759/cureus.21474.

Glossary

Query 20.3.5

This interactive element is not available in this format. Visit the link or scan the QR code to access it online.

View this Interactive Content online

Contributors and Attributions

- OpenStax Anatomy & Physiology (CC BY 4.0). Access for free at https://openstax.org/books/anatomy-and-physiology

This page titled 20.3: Conducting Zone is shared under a CC BY-NC-SA 4.0 license and was authored, remixed, and/or curated by Jennifer Lange et al..

- 20.2: Organs and Structures of the Respiratory System by Whitney Menefee, Julie Jenks, Chiara Mazzasette, and Kim-Leiloni Nguyen is licensed CC BY 4.0.
- 6.3: The Skull by Whitney Menefee, Julie Jenks, Chiara Mazzasette, and Kim-Leiloni Nguyen is licensed CC BY 4.0.

20.4: Respiratory Zone

By the end of this section, you will be able to:

- Name the structures of the respiratory zone and give the structure of each
- Explain how the structure of the respiratory membrane maximizes gas exchange
- Describe how the muscular system, nervous system, and respiratory system interact in ventilation

Respiratory Zone

In contrast to the conducting zone, the respiratory zone includes structures that are directly involved in gas exchange. The respiratory zone begins where a **terminal bronchiole** becomes **respiratory bronchioles**, the smallest type of **bronchiole** (Figure 20.4.1). These **respiratory bronchioles** branch into **alveolar ducts** which terminate in **alveolar sacs**, the site of gas exchange. The structure of **respiratory bronchioles** is very similar to that of terminal bronchioles; however, the lumen of respiratory bronchioles is lined with cuboidal epithelial tissue instead of while terminal bronchioles have columnar epithelial cells.

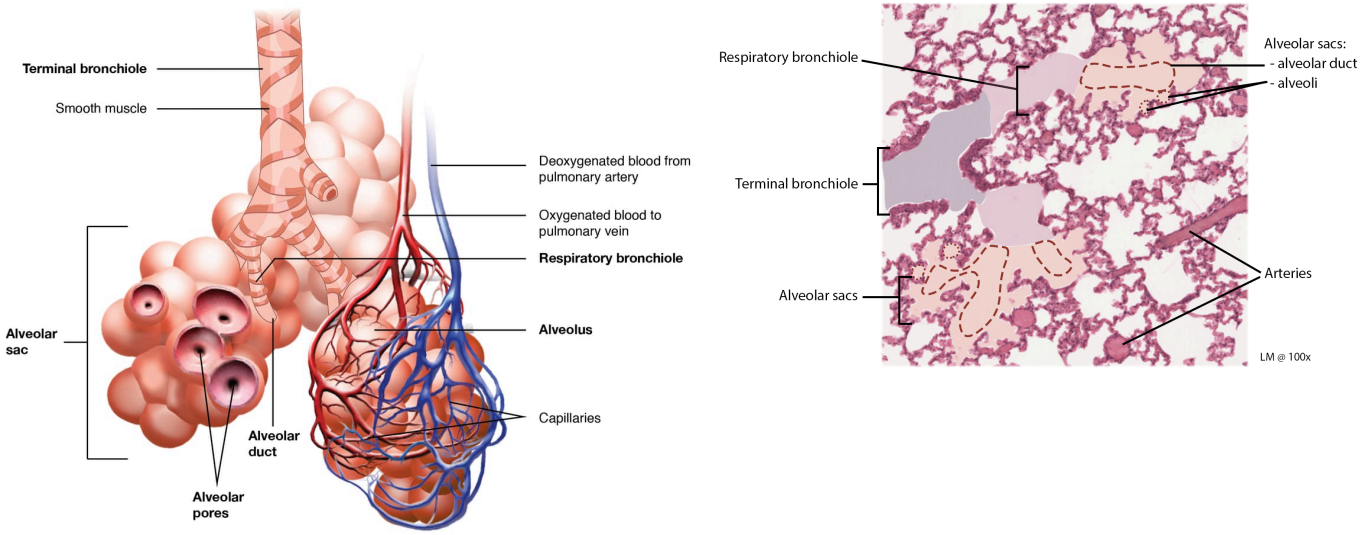

Figure 20.4.1: Respiratory Zone. Each respiratory bronchiole branches to a few alveolar ducts that connect to alveoli in the respiratory zone. *(Image credit: "Respiratory Zone Structures" by Jennifer Lange is licensed under CC BY-NC-SA 4.0, modification of The Respiratory Zone by OpenStax. "Respiratory Zone Histology" by Jennifer Lange is licensed under CC BY-NC-SA 4.0, slide provided by the Regents of the University of Michigan Medical School © 2022 under CC BY-NC-SA 3.0.)*

Alveolar Ducts and Alveoli

Respiratory bronchioles divide distally to form **alveolar ducts**. An **alveolar duct** does not have its own walls, but are channels created by the walls of the alveoli that line it. Each **alveolar duct** opens into a cluster of alveoli. An alveolar duct and all of the alveoli connected to it form a cluster called an **alveolar sac**. There are an average of 480 million **alveoli** in the lungs, yielding an incredibly large surface area for gas exchange. **Alveoli** are connected to their neighbors by **alveolar pores**, which help maintain equal air pressure throughout the alveoli and lung.

Each **alveolar sac** is surrounded by a capillary bed with a network of capillaries that distribute several capillaries to route along the outside of each **alveolus** in the **alveolar sac** (Figure 20.4.2). Deoxygenated blood is delivered to the capillary bed via an arteriole branching from the pulmonary artery and oxygenated blood is collected by a venule that drains to the pulmonary vein. An alveolus is **approximately** 200 µm in diameter with elastic walls that allow the alveolus to stretch during air intake like a balloon inflating, which greatly increases the surface area available for gas exchange, and then return to a smaller size to assist

with expiration.

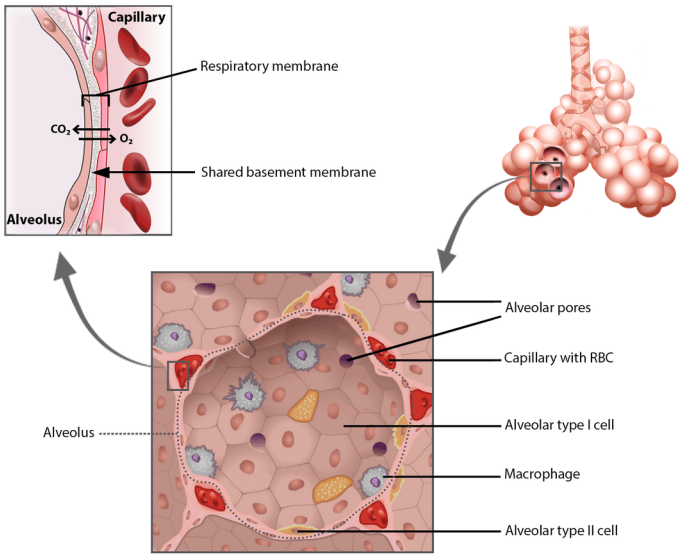

Figure 20.4.2: Respiratory Membrane. The alveolus is responsible for gas exchange with the blood in capillaries. Their areas of closest contact are is called the respiratory membrane, which is made of two layers of simple squamous epithelium with a shared basement membrane. *(Image credit: "Respiratory Membrane" by Jennifer Lange is licensed under CC BY-NC-SA 4.0, modification of The Respiratory Zone by OpenStax; includes Red blood cells by Jessica Polka.)*

The simple squamous epithelium of the alveolar wall consists of three major cell types: type I alveolar cells, type II alveolar cells, and alveolar macrophages (see Figure 20.4.2). **Type I alveolar cells** (aka type I pneumocytes or squamous alveolar cells) are squamous epithelial cells of the alveoli, which constitute up to 97 percent of the alveolar surface area. These cells are about 25 nm (there are a thousand nanometers in a millimeter!) thick and are highly permeable to gases. **Type II alveolar cells** (aka type II pneumocytes or great alveolar cells) are interspersed among the type I cells and secrete **pulmonary surfactant**, a substance that reduces the surface tension of the alveoli. **Type II alveolar cells** also play an important role in initiating repair of an alveolus is damaged. Roaming around the alveolar wall is the **alveolar macrophage**, a phagocytic cell of the immune system that removes debris and pathogens that have reached the alveoli.

The simple squamous epithelium formed by **type I alveolar cells** is attached to a thin, elastic basement membrane. Attaching to the opposite side of the same basement membrane is the endothelium of the capillaries, which is also simple squamous epithelium. Taken together, the alveoli and capillary walls form a **respiratory membrane** that is approximately 0.5 micrometers thick. The respiratory membrane allows gases to cross by simple diffusion, allowing oxygen to be picked up by the blood for transport and CO_2 to be released into the air of the alveoli to be excreted during the exhale.

Muscles of Breathing

Pulmonary ventilation is the act of breathing, which can be described as the movement of air into and out of the lungs. The lungs themselves are passive during breathing, meaning they are not involved in creating the movement that helps inspiration and expiration. This is because of the adhesive nature of the pleural fluid, which allows the lungs to be pulled outward when the thoracic wall moves during inspiration. The recoil of the thoracic wall, partly due to lung elasticity, during expiration causes compression of the lungs. When you take a deep breath, notice the expansion of your rib cage. Contraction of the diaphragm and external intercostal muscles increases the volume in the chest cavity, which in turn lowers the pressure and draws air into the lungs for **inspiration**. When these muscles stop contracting, the elastic recoil of the lungs causes them to become smaller. This increases the pressure within the thoracic cavity and air leaves the lungs (**expiration**). During exercise, additional muscles aid with ventilation. Secondary inspiratory muscles such as the scalenes, the pectoralis major and minor, and the sternocleidomastoid help to elevate the ribs even more. Conversely, the internal intercostals can pull the ribs further in than their "resting" position and the abdominal muscles can force the viscera against diaphragm. Both actions decrease the volume of the thoracic cavity, thus they are secondary expiratory muscles.

DISORDERS OF THE...

Respiratory System: Chronic Obstructive Pulmonary Disorder (COPD)

Chronic Obstructive Pulmonary Disorder (COPD) is used to describe a number of closely related respiratory conditions including **chronic bronchitis** and **emphysema**. COPD is often associated with heavy smokers, although it can affect individuals that never smoked. In chronic bronchitis, the walls of the bronchioles are chronically inflamed, reducing the volume of the lumen and marked by an over-production of mucus that can obstruct the movement of air during ventilation. In emphysema, the alveolar walls lose their elasticity and are destroyed, often by a build-up of damage and debris being cleaned up by alveolar macrophages (Figure 20.4.3). The damage leads to fibrosis in which normal tissue is replaced by scar tissue, further reducing the elasticity of the alveolar walls and perpetuating the progression fo the disease.

Patients with COPD can have shortness of breath and can have difficulty in particular with expiration, which affects the efficiency of ventilation. Coupled with alveolar damage, the result is reduced oxygen levels in the blood, which can affect the function of many systems of the body. Bronchodilators and anti-inflammatory medications are typically used to treat COPD. Eventually, in those with severe COPD, even treatment with supplemental oxygen will not be sufficient to prevent respiratory failure.

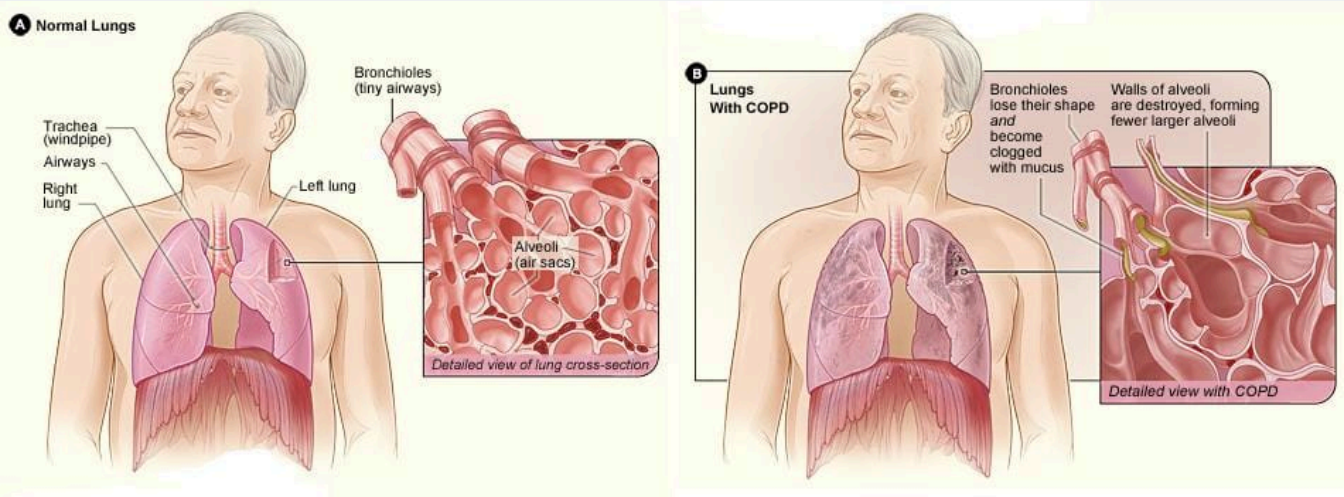

Figure 20.4.3: Chronic Obstructive Pulmonary Disorder. Lungs with COPD contain fewer alveoli after the walls between adjacent alveoli are destroyed, forming fewer, larger alveoli and reducing the surface area for gas exchange. Bronchioles lose their shape and are clogged with excessive mucus. *(Image credit: "COPD_2010Side" by National Heart Lung and Blood Institute is in the Public Domain)*

Respiratory Rate and Control of Ventilation

Breathing usually occurs without thought, although at times you can consciously control it, such as when you swim under water, sing a song, or blow bubbles. The **respiratory rate** is the total number of breaths, or respiratory cycles, that occur each minute. Respiratory rate can be an important indicator of disease, as the rate may increase or decrease during an illness or in a disease condition. The respiratory rate is controlled by the respiratory center located within the medulla oblongata (Figure 20.4.5) in the brain, which responds primarily to input received from central and peripheral chemoreceptors that sense carbon dioxide and blood pH. While blood oxygen levels are not the primary drive of respiratory rate, the respiratory center will receive input if they get dangerously low. The respiratory control centers of the medulla oblongata are further influenced by a rate control center in the pons.

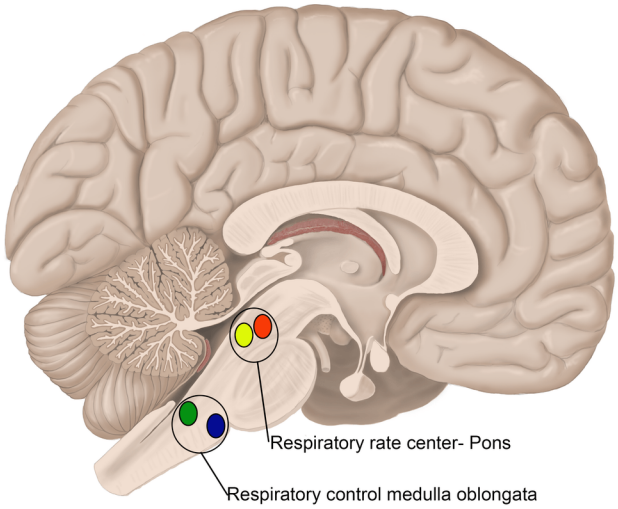

Figure 20.4.5: Inspiration and Expiration. During inspiration, the diaphragm and external intercostal muscles contract, expanding the volume in the thoracic cavity, creating a pressure gradient with lower air pressure in the lungs that draws air in. During expiration, the diaphragm and external intercostal muscles relax, reducing the volume in the thoracic cavity and reversing the pressure gradient with higher air pressure in the lungs that forces air out. *(Image credit: "Midsagittal Brain" by Justin Greene is licensed under CC BY-NC-SA 4.0.)*

The normal respiratory rate of a child decreases from birth to adolescence. A child under 1 year of age has a normal respiratory rate between 30 and 60 breaths per minute, but by the time a child is about 10 years old, the normal rate is closer to 18 to 30. By adolescence, the normal respiratory rate is similar to that of adults, 12 to 18 breaths per minute.

DISORDERS OF THE...

Respiratory System: Sleep Apnea

Sleep apnea is a chronic disorder that can occur in children or adults, and is characterized by the cessation of breathing during sleep. These episodes may last for several seconds or several minutes, and may differ in the frequency with which they are experienced. Sleep apnea leads to poor sleep, which is reflected in the symptoms of fatigue, evening napping, irritability, memory problems, and morning headaches. In addition, many individuals with sleep apnea experience a dry throat in the morning after waking from sleep, which may be due to excessive snoring.

There are two types of sleep apnea: obstructive sleep apnea and central sleep apnea. Obstructive sleep apnea is caused by an obstruction of the airway during sleep, which can occur at different points in the airway, depending on the underlying cause of the obstruction. For example, the tongue and throat muscles of some individuals with obstructive sleep apnea may relax excessively, causing the muscles to push into the airway. Another example is obesity, which is a known risk factor for sleep apnea, as excess adipose tissue in the neck region can push the soft tissues towards the lumen of the airway, causing the trachea to narrow.

In central sleep apnea, the respiratory centers of the brain do not respond properly to rising carbon dioxide levels and therefore do not stimulate the contraction of the diaphragm and intercostal muscles regularly. As a result, inspiration does not occur and breathing stops for a short period. In some cases, the cause of central sleep apnea is unknown. However, some medical conditions, such as stroke and congestive heart failure, may cause damage to the pons or medulla oblongata. In addition, some pharmacologic agents, such as morphine, can affect the respiratory centers, causing a decrease in the respiratory rate. The symptoms of central sleep apnea are similar to those of obstructive sleep apnea.

A diagnosis of sleep apnea is usually done during a sleep study, where the patient is monitored in a sleep laboratory for several nights. The patient's blood oxygen levels, heart rate, respiratory rate, and blood pressure are monitored, as are brain activity and the volume of air that is inhaled and exhaled. Treatment of sleep apnea commonly includes the use of a device called a continuous positive airway pressure (CPAP) machine during sleep (Figure 20.4.6). The CPAP machine has a mask that covers the nose, or the nose and mouth, and forces air into the airway at regular intervals. This pressurized air can help to

gently force the airway to remain open, allowing more normal ventilation to occur. Other treatments include lifestyle changes to decrease weight, eliminate alcohol and other sleep apnea–promoting drugs, and changes in sleep position. In addition to these treatments, patients with central sleep apnea may need supplemental oxygen during sleep.

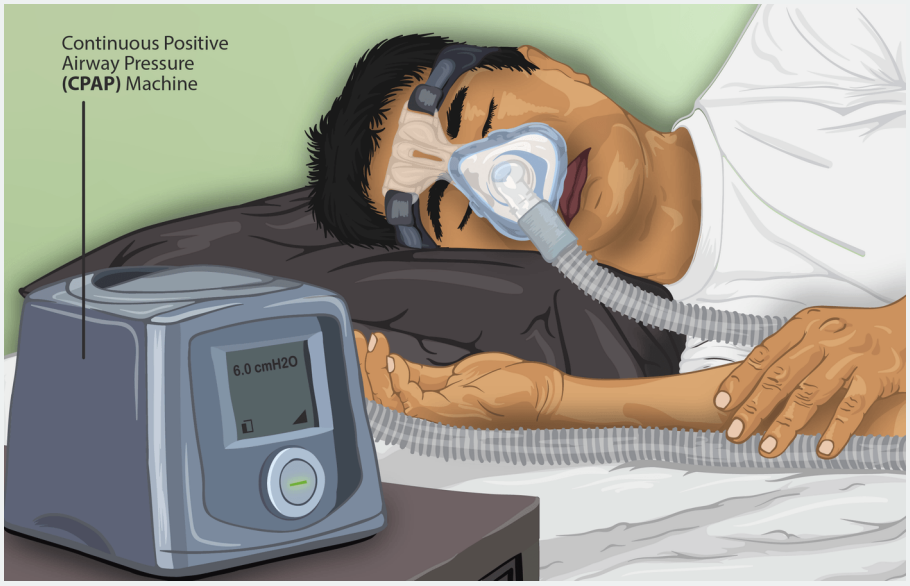

Figure 20.4.6: Sleep Apnea. Continuous positive airway pressure (CPAP) machines help keep airways open during sleep. *(Image credit: "COPD_2010Side" by National Heart Lung and Blood Institute is in the Public Domain.)*

Concept Review

The respiratory zone is the functional part of the lungs responsible for gas exchange. These structures are specialized for the diffusion of oxygen and carbon dioxide between the air and the blood. Key components of the respiratory zone:

- Respiratory Bronchioles: the smallest bronchioles, leading to alveolar ducts.
- Alveolar Ducts: narrow passageways that connect respiratory bronchioles to alveoli.
- Alveoli: tiny sacs where gas exchange takes place. They are made of simple squamous epithelial tissues are surrounded by capillaries.
- Alveolar Sac: an alveolar duct and all of the alveoli connected to it.
- Type I Alveolar Cells: simple squamous epithelial cells forming the walls of the alveoli.
- Type II Alveolar Cells: cuboidal cells that produce and secrete surfactant

The thin walls of the alveoli and capillaries allow for efficient diffusion of gases. They form the respiratory membrane, composed of two simple squamous epithelial layers connected by a shared basement membrane.

Muscles that expand the size of the thoracic cavity cause inspiration while those that decrease the size of the thoracic cavity cause expiration. The respiratory rate and depth are controlled by clusters of neurons found in the pons and medulla oblongata.

Review Questions

Query 20.4.1

This interactive element is not available in this format. Visit the link or scan the QR code to access it online.

View this Interactive Content online

Critical Thinking Questions

Query 20.4.2

This interactive element is not available in this format. Visit the link or scan the QR code to access it online.

View this Interactive Content online

Glossary

Query 20.4.3

This interactive element is not available in this format. Visit the link or scan the QR code to access it online.

View this Interactive Content online

Contributors and Attributions

OpenStax Anatomy & Physiology (CC BY 4.0). Access for free at https://openstax.org/books/anatomy-and-physiology

This page titled 20.4: Respiratory Zone is shared under a CC BY-NC-SA 4.0 license and was authored, remixed, and/or curated by Jennifer Lange et al..

- 20.4: The Processes of the Respiratory System by Whitney Menefee, Julie Jenks, Chiara Mazzasette, and Kim-Leiloni Nguyen is licensed CC BY 4.0.
- 20.2: Organs and Structures of the Respiratory System by Whitney Menefee, Julie Jenks, Chiara Mazzasette, and Kim-Leiloni Nguyen is licensed CC BY 4.0.

20.5: Embryonic Development of the Respiratory System

By the end of this section, you will be able to:

- Create a timeline of the phases of respiratory development in the fetus
- Propose reasons for fetal breathing movements
- Explain how the lungs become inflated after birth

Development of the respiratory system begins early in the fetus. It is a complex process that includes many structures, most of which arise from the endoderm. Towards the end of development, the fetus can be observed making breathing movements. Until birth, however, the mother provides all of the oxygen to the fetus as well as removes all of the fetal carbon dioxide via the placenta.

Time Line

The development of the respiratory system begins at about week 4 of gestation. By week 28, enough alveoli have matured that a baby born prematurely at this time can usually breathe on its own. The respiratory system, however, is not fully developed until early childhood, when a full complement of mature alveoli is present.

Weeks 4–7

Respiratory development in the embryo begins around week 4. Ectodermal tissue from the anterior head region invaginates posteriorly to form olfactory pits, which fuse with endodermal tissue of the developing pharynx. An **olfactory pit** is one of a pair of structures that will enlarge to become the nasal cavity. At about this same time, the lung bud forms. The **lung bud** is a dome-shaped structure composed of tissue that bulges from the foregut. The **foregut** is endoderm just inferior to the pharynx, surrounded by splanchnic mesoderm. Eventually, the epithelial tissues of the trachea, bronchi, and lungs form from the endoderm while the smooth muscle and connective tissues of the trachea, bronchi, and lungs, as well as the visceral pleura, develop from the splanchnic mesoderm. The **laryngotracheal tube** is a structure that forms from the longitudinal extension of the lung bud as development progresses. The portion of this structure nearest the pharynx becomes the trachea, whereas the distal end becomes more bulbous and bifurcates, forming bronchial buds. A **bronchial bud** is one of a pair of structures that will eventually become the bronchi and all other lower respiratory structures (Figure 20.5.1).

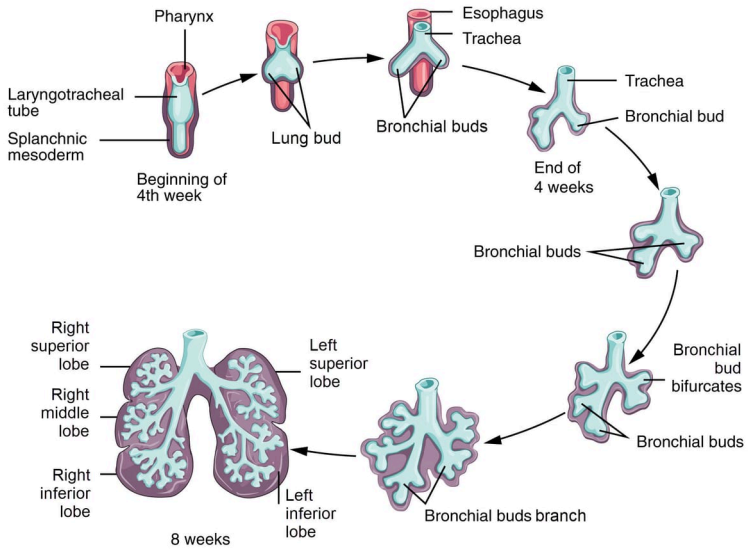

Figure 20.5.1: Development of the Lower Respiratory System. The respiratory passages begin to develop from the developing pharynx during week 4 of gestation when the laryngotracheal tube forms and then elongates, forming the trachea and bronchial buds. In the weeks that follow, the bronchial buds continue to elongate and branch further, forming the branches of the bronchial tree. Superficial tissues of the respiratory passages and the lobes of the lungs develop from splanchnic mesoderm. (Image credit: "Development of the Lower Respiratory System" by Julie Jenks is licensed under CC BY 4.0 / A derivative from the original work)

Weeks 7–16

Bronchial buds continue to branch as development progresses until all of the segmental bronchi have been formed. Beginning around week 13, the lumens of the bronchi begin to expand in diameter. By week 16, respiratory bronchioles form. The fetus now has the beginnings of all major lung structures involved in the airway.

Weeks 16–24

Once the respiratory bronchioles form, further development includes extensive vascularization, or the development of the blood vessels, as well as the formation of alveolar ducts and alveolar precursors. At about week 19, the respiratory bronchioles have formed. In addition, cells lining the respiratory structures begin to differentiate to form type I and type II alveolar cells. Once type II alveolar cells have differentiated, they begin to secrete small amounts of pulmonary surfactant. Around week 20, fetal breathing movements may begin.

Weeks 24–Term

Major growth and maturation of the respiratory system occurs from week 24 until term. More alveolar precursors develop, and larger amounts of pulmonary surfactant are produced. Surfactant levels are not generally adequate to create effective lung compliance, or a change in lung volume as the result of a change in pressure, until about the eighth month of pregnancy. The respiratory system continues to expand, and the surfaces that will form the respiratory membrane develop further. At this point, pulmonary capillaries have formed and continue to expand, creating a large surface area for gas exchange. The major milestone of respiratory development occurs at around week 28, when sufficient alveolar precursors have matured so that a baby born prematurely at this time can usually breathe on its own. However, alveoli continue to develop and mature into childhood. A full complement of functional alveoli does not form until around 8 years of age.

Fetal “Breathing”

Although the function of fetal breathing movements is not entirely clear, they can be observed starting at 20–21 weeks of development. Fetal breathing movements involve muscle contractions that cause the inhalation of amniotic fluid and exhalation of the same fluid, with pulmonary surfactant and mucus. Fetal breathing movements are not continuous and may include periods of frequent movements and periods of no movements. Maternal factors can influence the frequency of breathing movements. For

example, high blood glucose levels, called hyperglycemia, can boost the number of breathing movements. Conversely, low blood glucose levels, called hypoglycemia, can reduce the number of fetal breathing movements. Tobacco use is also known to lower fetal breathing rates. Fetal breathing may help tone the muscles in preparation for breathing movements once the fetus is born. It may also help the alveoli to form and mature. Fetal breathing movements are considered a sign of robust health.

Birth

Prior to birth, the lungs are filled with amniotic fluid, mucus, and surfactant. As the fetus is squeezed through the birth canal, the fetal thoracic cavity is compressed, expelling much of this fluid. Some fluid remains, however, but is rapidly absorbed by the body shortly after birth. The first inhalation occurs within 10 seconds after birth and not only serves as the first inspiration, but also acts to inflate the lungs. Pulmonary surfactant is critical for inflation to occur, as it reduces the surface tension of the alveoli. Preterm birth around 26 weeks frequently results in severe respiratory distress, although with current medical advancements, some babies may survive. Prior to 26 weeks, sufficient pulmonary surfactant is not produced, and the surfaces for gas exchange have not formed adequately; therefore, survival is low.

DISORDERS OF THE...

Respiratory System: Respiratory Distress Syndrome

Respiratory distress syndrome (RDS) primarily occurs in infants born prematurely. Up to 50 percent of infants born between 26 and 28 weeks and fewer than 30 percent of infants born between 30 and 31 weeks develop RDS. RDS results from insufficient production of pulmonary surfactant, thereby preventing the lungs from properly inflating at birth. A small amount of pulmonary surfactant is produced beginning at around 20 weeks; however, this is not sufficient for inflation of the lungs. As a result, dyspnea occurs and gas exchange cannot be performed properly. Blood oxygen levels are low, whereas blood carbon dioxide levels and pH are high.

The primary cause of RDS is premature birth, which may be due to a variety of known or unknown causes. Other risk factors include gestational diabetes, cesarean delivery, second-born twins, and family history of RDS. The presence of RDS can lead to other serious disorders, such as septicemia (infection of the blood) or pulmonary hemorrhage. Therefore, it is important that RDS is immediately recognized and treated to prevent death and reduce the risk of developing other disorders.

Medical advances have resulted in an improved ability to treat RDS and support the infant until proper lung development can occur. At the time of delivery, treatment may include resuscitation and intubation if the infant does not breathe on his or her own. These infants would need to be placed on a ventilator to mechanically assist with the breathing process. If spontaneous breathing occurs, application of nasal continuous positive airway pressure (CPAP) may be required. In addition, a laboratory synthesized form of pulmonary surfactant is typically administered. Death due to RDS has been reduced by 50 percent due to the introduction of pulmonary surfactant therapy. Other therapies may include corticosteroids, supplemental oxygen, and assisted ventilation. Supportive therapies, such as temperature regulation, nutritional support, and antibiotics, may be administered to the premature infant as well.

Concept Review

The development of the respiratory system in the fetus begins at about 4 weeks and continues into childhood. Ectodermal tissue in the anterior portion of the head region invaginates posteriorly, forming olfactory pits, which ultimately fuse with endodermal tissue of the early pharynx. At about this same time, a protrusion of endodermal tissue extends anteriorly from the foregut, producing a lung bud, which continues to elongate until it forms the laryngotracheal bud. The proximal portion of this structure will mature into the trachea, whereas the bulbous end will branch to form two bronchial buds. These buds then branch repeatedly, so that at about week 16, all major airway structures are present. Development progresses after week 16 as respiratory bronchioles and alveolar ducts form, and extensive vascularization occurs. Type I alveolar cells also begin to take shape. Type II alveolar cells develop and begin to produce small amounts of surfactant. As the fetus grows, the respiratory system continues to expand as more alveoli develop and more surfactant is produced. Beginning at about week 36 and lasting into childhood, alveolar precursors mature to become fully functional alveoli. At birth, compression of the thoracic cavity forces much of the fluid in the lungs to be expelled. The first inhalation inflates the lungs. Fetal breathing movements begin around week 20 or 21, and occur when contractions of the respiratory muscles cause the fetus to inhale and exhale amniotic fluid. These movements continue until birth, which may help to tone the muscles in preparation for breathing after birth, and are a sign of good health.

Review Questions

Query 20.5.1

This interactive element is not available in this format. Visit the link or scan the QR code to access it online.

View this Interactive Content online

Critical Thinking Questions

Query 20.5.2

This interactive element is not available in this format. Visit the link or scan the QR code to access it online.

View this Interactive Content online

Query 20.5.3

This interactive element is not available in this format. Visit the link or scan the QR code to access it online.

View this Interactive Content online

Glossary

Query 20.5.4

This interactive element is not available in this format. Visit the link or scan the QR code to access it online.

View this Interactive Content online

Contributors and Attributions

- OpenStax Anatomy & Physiology (CC BY 4.0). Access for free at https://openstax.org/books/anatomy-and-physiology

This page titled 20.5: Embryonic Development of the Respiratory System is shared under a CC BY-NC-SA 4.0 license and was authored, remixed, and/or curated by Jennifer Lange et al..

- 20.5: Embryonic Development of the Respiratory System by Whitney Menefee, Julie Jenks, Chiara Mazzasette, and Kim-Leiloni Nguyen is licensed CC BY 4.0.

20.6: Anatomical Atlas - Respiratory System

A compendium of anatomical images: slides, models, and/or cadavers.

Models

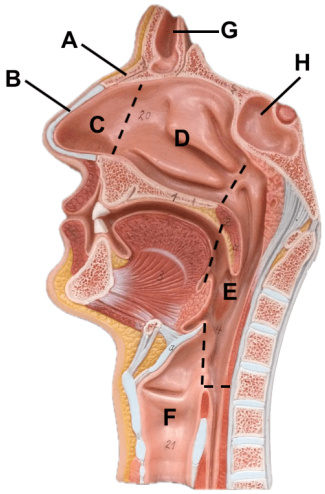

Image credit

"Upper Respiratory System Regions" by Jennifer Lange, is licensed under CC BY-NC-SA 4.0.

Answer Key (click to show/hide answers)

A - Nasal bone
B - Nasal cartilage
C - Nose/nares
D - Nasal cavity
E - Pharynx
F - Larynx
G - Frontal sinus
H - Sphenoid sinus

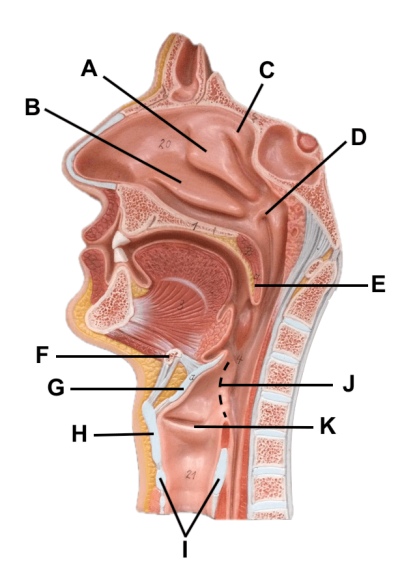

Image credit

"Upper Respiratory System Structures" by Jennifer Lange, is licensed under CC BY-NC-SA 4.0.

Answer Key (click to show/hide answers)

A - Middle nasal concha
B - Inferior nasal concha
C - Superior nasal concha
D - Opening of auditory tube
E - Uvula
F - Hyoid bone
G - Epiglottis
H -Thyroid cartilage
I - Cricoid cartilage
J - Glottis
K - vocal folds/ cords

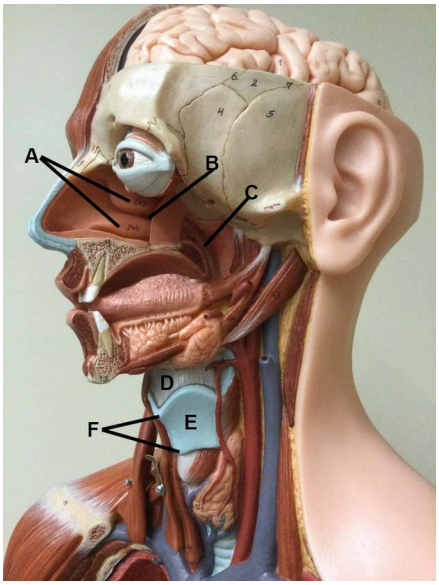

Image credit

"Head Model External - Respriatory Organs Atlas" by Jennifer Lange, is licensed under CC BY-NC-SA 4.0. Labeled by John Polos

Answer Key (click to show/hide answers)

A - Nasal concha
B - Nasal meatus
C - Pharynx
D - Thyrohyoid membrane
E - Thyroid cartilage
F - Laryngeal prominence

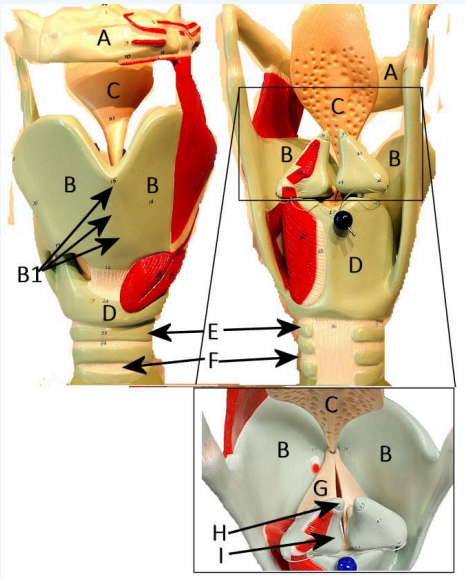

Image credit

"Larynx Model- Respiratory Organs Atlas" by John Polos, is licensed under CC BY-NC-SA 4.0.

Answer Key (click to show/hide answers)

A - Hyoid bone
B - Thyroid cartilage
B1 - Laryngeal prominence
C - Epiglottis
D - Cricoid cartilage
E - Tracheal cartilage
F - Annular ligament
G - Vocal folds
H - Corniculate cartilage
I - Arytenoid cartilage

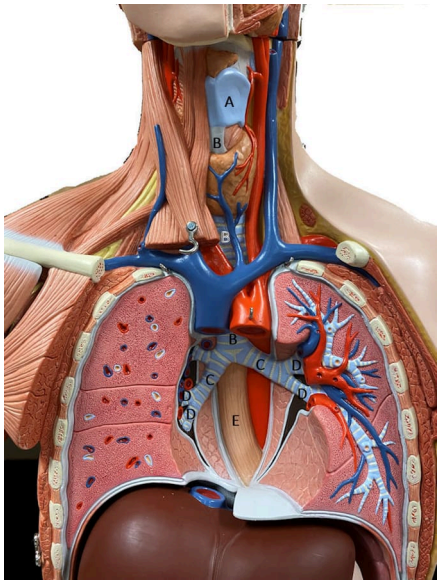

Image credit

"Torso Model - Respiratory Organs Atlas" by John Polos, is licensed under CC BY-NC-SA 4.0.

Answer Key (click to show/hide answers)

A - Larynx (thyroid cartilage)
B - Trachea
C - Primary bronchi (plural)
D - Secondary bronchi (plural)
E - Esophagus

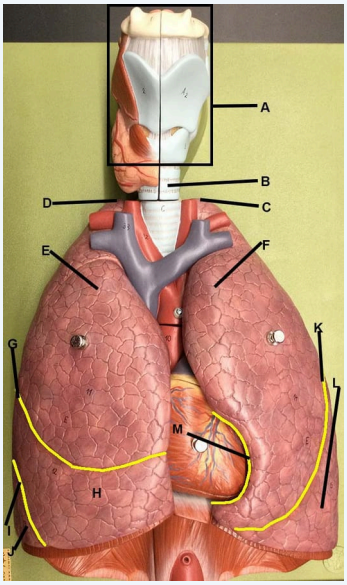

Image credit

"Lung model external - Respiratory Organs Atlas" by Jennifer Lange, is licensed under CC BY-NC-SA 4.0. Labeled by John Polos

Answer Key (click to show/hide answers)

A - Larynx
B - Trachea
C - Apex of left lung
D - Apex of right lung
E - Superior lobe of right lung
F - Superior lobe of left lung
G - Horizontal fissure of right lung
H - Middle lobe of right lung.
I - Oblique fissure of right lung
J - Inferior lobe of right lung
K - Oblique fissure of left lung
L - Inferior lobe of left lung
M - Cardiac Notch of left lung

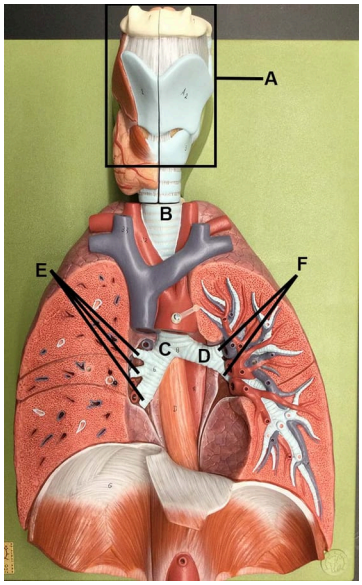

Image credit

“Lung model, deep - Respiratory Organs Atlas" by Jennifer Lange, is licensed under CC BY-NC-SA 4.0. Labeles by John Polos

Answer Key (click to show/hide answers)

A - Larynx
B - Trachea
C - Right primary bronchus
D - Left primary bronchus
E - Right secondary bronchi
F - Left secondary bronchi

Histology

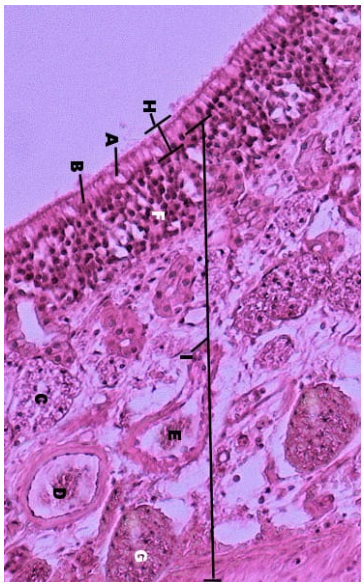

Image credit

"Nasal cavity histology - Respiratory Organs Atlas" by John Polos, is licensed under CC BY-NC-SA 4.0.

Answer Key (click to show/hide answers)

A - Goblet cell
B - Pseudostratified colum epithelium
C - Olfactory (Bowman's) g
D - Artery
E - Vein
F - Bipolar cell nuclei
G - Nerve
H - Mucosal layer
I - Submucosal layer and lamina propria

Image credit

"Trachea histology - Respiratory Organs Atlas" by Jennifer Lange, is licensed under CC BY-NC-SA 4.0.

Answer Key (click to show/hide answers)

A - Submucosal glands/ Tracheal glands
B - Mucosal layer/ Pseudostratified columnar epithelium
C - Submucosal layer and lamina propria
D - Hyaline cartilage
E - Adventitia

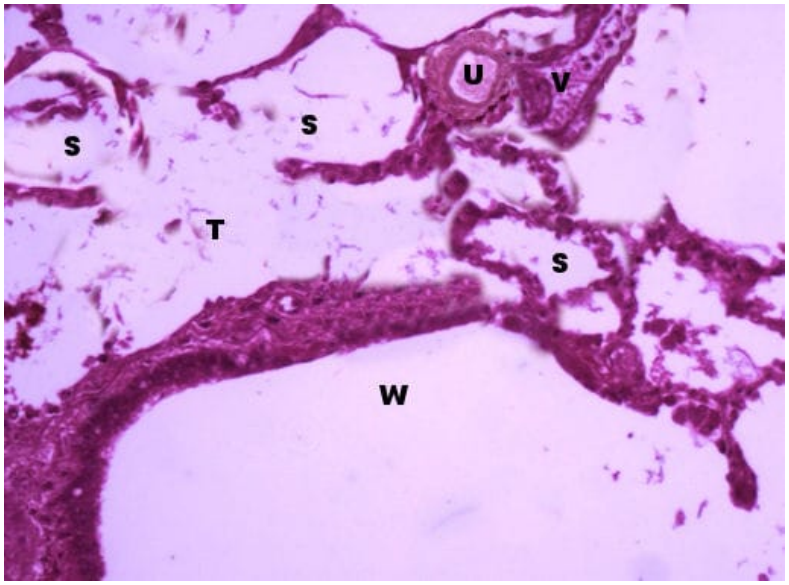

Image credit

“Lung histology - Digestive Organs Atlas" by John Polos, is licensed under CC BY-NC-SA 4.0.

Answer Key (click to show/hide answers)

S - Alveoli
T - Alveolar duct
U - Small artery
V - Small vein
W - Respiratory bronchus

Cadaver

To view a larger version, right click (PC) or command click (Mac) and click open in new tab.

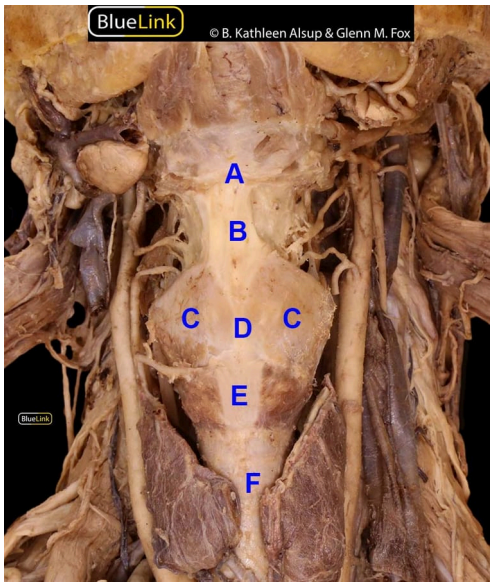

Image credit

“ Anterior Neck" provided by the regents of the University of Michigan and shared under CC 4.0 . Labeled by John Polos.

Answer Key (click to show hide answers)

A - Hyoid bone
B - Thyrohyoid membrane
C - Thyroid cartila
D - Laryngeal promin
E - Cricoid cartila
F - Trachea

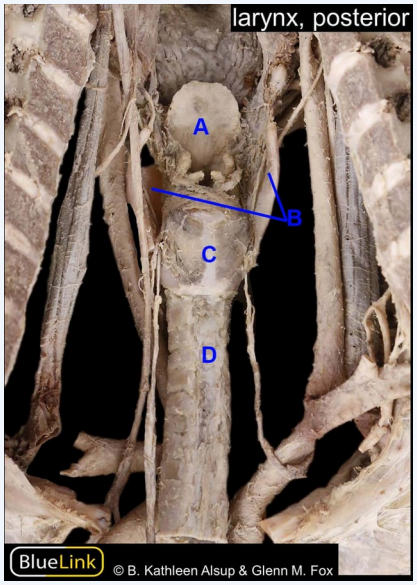

Image credit

“ Posterior larynx" provided by the regents of the University of Michigan and shared under CC 4.0 . Labeled by John Polos.

Answer Key (click to show hide answers)

A - Epiglottis
B - Thyroid cartila thyroid lamina
C - Cricoid cartila
D - Trachea

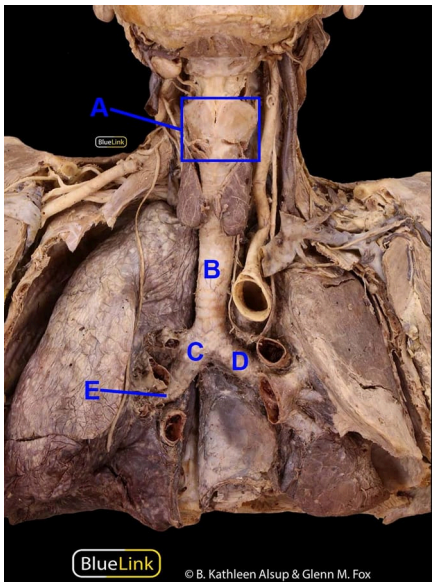

Image credit

“ Thoracic cavity" provided by the regents of the University of Michigan and shared under CC 4.0 . Labeled by John Polos.

Answer Key (click to show hide answers)

A - Larynx
B - Trachea
C - Right primary bronchus
D - Left primary bronchus
E - Right secondary bronch (inferior)

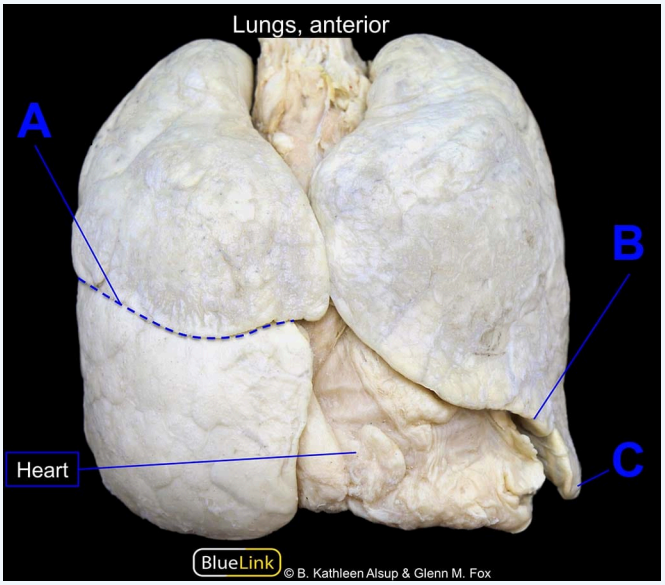

Image credit

“ Anterior lungs" provided by the regents of the University of Michigan and shared under CC 4.0 . Labeled by John Polos.

Answer Key (click to show hide answers)

A - Horizontal fiss of right lung
B - Cardiac notch left lung
C - Lingula of left

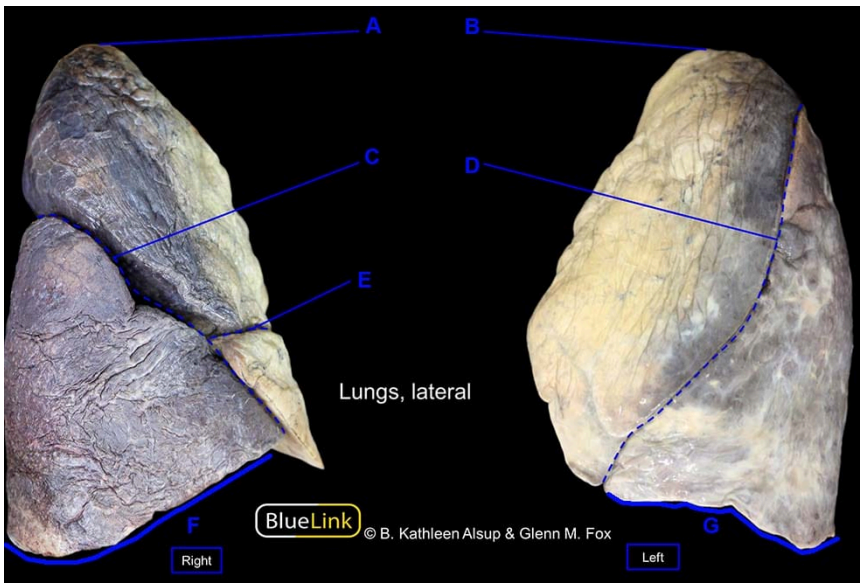

Image credit

“ Lateral Lungs" provided by the regents of the University of Michigan and shared under CC 4.0 . Labeled by John Polos.

Answer Key (click to show hide answers)

A - Apex right lun
B - Apex left lung
C - Oblique fissur right lung
D - Oblique fissur lung
E - Horizontal fiss right lung
F - Base right lun
G - Base left lung

This page titled 20.6: Anatomical Atlas - Respiratory System is shared under a CC BY-NC-SA 4.0 license and was authored, remixed, and/or curated by Jennifer Lange et al..

20.7: Practice Practical - the Respiratory System

Query 20.7.1

This interactive element is not available in this format. Visit the link or scan the QR code to access it online.

View this Interactive Content online

Interactive Content

This interactive element is not available in this format. Visit the link or scan the QR code to access it online.

View this Interactive Content online

Query 20.7.1

This interactive element is not available in this format. Visit the link or scan the QR code to access it online.

View this Interactive Content online

This page titled 20.7: Practice Practical - the Respiratory System is shared under a CC BY-NC-SA 4.0 license and was authored, remixed, and/or curated by Jennifer Lange et al..

21: DIGESTIVE SYSTEM

21.1: Introduction to the Digestive System

21.2: Organs of the Digestive System

21.3: Digestive System Processes and Regulation

21.4: Mouth, Pharynx, and Esophagus

21.5: Stomach

21.6: Small and Large Intestines

21.7: Accessory Organs - Liver, Pancreas, and Gallbladder

21.8: Anatomical Atlas - Digestive System

21.9: Practice Practical- Digestive system

This page titled 21: Digestive System is shared under a CC BY-NC-SA 4.0 license and was authored, remixed, and/or curated by Jennifer Lange et al..

- 21: Digestive System by Whitney Menefee, Julie Jenks, Chiara Mazzasette, and Kim-Leiloni Nguyen is licensed CC BY 4.0.

21.1: Introduction to the Digestive System

Chapter Learning Objectives:

After studying this chapter, you will be able to:

- Describe the gross and histological anatomy of the organs of the digestive system
- List the functions of the digestive system and the function of each organ
- Explain how the structure of each organ relates to its role in the digestive systems functions
- Outline the structural interactions between the digestive system and other systems such as the lymphatic system and the cardiovascular system

The digestive system is continually at work, yet people seldom appreciate the complex tasks it performs in a choreographed biologic symphony. Consider what happens when you eat an apple. Of course, you enjoy the apple's taste as you chew it, but in the hours that follow, unless something goes amiss and you get a stomachache, you don't notice that your digestive system is working. You may be taking a walk or studying or sleeping, having forgotten all about the apple, but your stomach and intestines are busy digesting it and absorbing its vitamins and other nutrients. By the time any waste material is excreted, the body has appropriated all it can use from the apple. In short, whether you pay attention or not, the organs of the digestive system perform their specific functions, allowing you to use the food you eat to keep you going. This chapter examines the structure of these organs, and explores the mechanics of the digestive system processes.

Figure 21.1.1: Eating Fries. Eating may be one of the simple pleasures in life, but digesting even one fry requires the coordinated work of many organs. *(Image credit: "Girl Eating Fries" by Moisés Delgado from Pexels is in the public domain.)*

Contributors and Attributions

- OpenStax Anatomy & Physiology (CC BY 4.0). Access for free at https://openstax.org/books/anatomy-and-physiology

This page titled 21.1: Introduction to the Digestive System is shared under a CC BY-NC-SA 4.0 license and was authored, remixed, and/or curated by Jennifer Lange et al..

- 21.1: Introduction to the Digestive System by Whitney Menefee, Julie Jenks, Chiara Mazzasette, and Kim-Leiloni Nguyen is licensed CC BY 4.0.

21.2: Organs of the Digestive System

By the end of the section, you will be able to:

- Identify the organs of the digestive tract from proximal to distal, and briefly state their functions
- Identify the accessory digestive organs and briefly state their primary function
- Describe the four fundamental tissue layers of the digestive tract
- Contrast the roles of the enteric and autonomic nervous systems in digestive system functioning
- Describe the structure and function of the peritoneum and mesenteries

The function of the digestive system is to break down the foods you eat by secreting enzymes to mix with food, release their nutrients, and absorb those nutrients into the body. Although the small intestine is the workhorse of the system, where the majority of digestion occurs, and where most of the released nutrients are absorbed into the blood or lymph, each of the digestive system organs makes a vital contribution to this process. Figure 21.2.1 shows all the organs of the digestive tract, a long tube that starts with the oral cavity, to the esophagus, stomach, small intestine, large intestine, and ending at the anus. The picture also shows some accessory digestive organs, such as the salivary glands, liver, gallbladder, and pancreas.

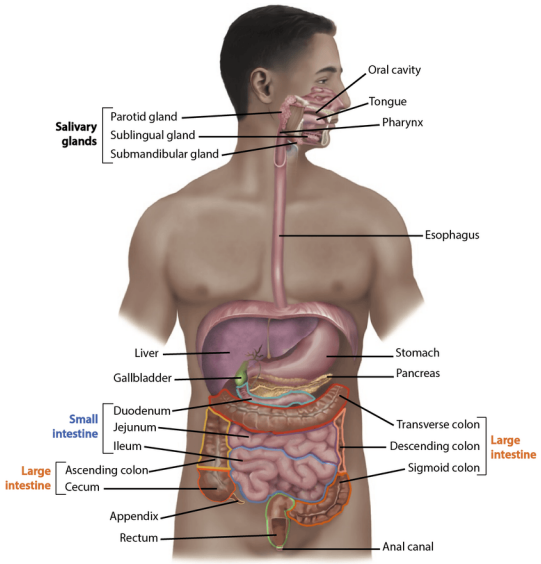

Figure 21.2.1: Organs of the Digestive System. As food moves through the organs of the digestive tract it is broken down into component molecules which are absorbed into the body. The accessory organs (salivary glands, liver, pancreas and gallbladder) secrete digestive enzymes and other substances to assist and regulate the processes. *(Image credit: "Components of the Digestive System" by Jennifer Lange and Gabrielle Spurlock is licensed under CC BY-NC-SA 4.0, modification of original by KnowledgeWorks .)*

Digestive System Organs

The easiest way to understand the digestive system is to divide its organs into two main categories. The first group is the organs that make up the digestive tract, also known as the alimentary canal or gastrointestinal (GI) tract, the long tube through which food passes. Accessory digestive organs comprise the second group and are critical for orchestrating the breakdown of food and the assimilation of its nutrients into the body by releasing exocrine secretions into the tract. Accessory digestive organs, despite their name, are critical to the function of the digestive system.

Digestive Tract Organs

The digestive tract, gastrointestinal (GI) tract or gut, is a one-way tube about 7.62 meters (25 feet) in length during life and closer to 10.67 meters (35 feet) in length when measured after death, once smooth muscle tone is lost. The main function of the organs of the tract is to nourish the body. This tube begins at the oral cavity and terminates at the anus. Between those two points, the canal is modified as the pharynx, esophagus, stomach, and small and large intestines to fit the functional needs of the body (Figure 21.2.2). In this system, relative locations closer to the oral cavity are considered “proximal” and further from the oral cavity (closer to the anus) are considered “distal”. Both the oral cavity and anus are open to the external environment; thus, food and wastes within the tract are technically considered to be outside the body. Only through the process of absorption, moving from digestive organs into the blood, do the nutrients in food enter into and nourish the body’s “inner space.” The organs of the digestive tract are summarized in (Table21.2.1.

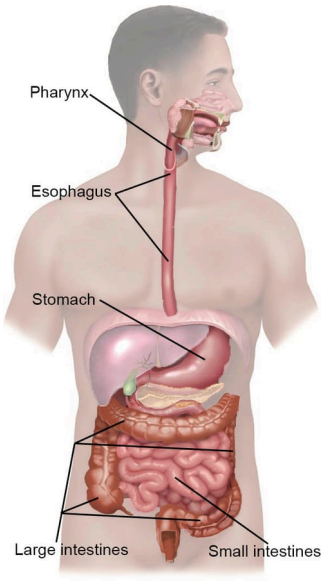

Figure 21.2.2: The digestive tract is a tube called the alimentary canal that extends from the mouth to the anus and the main digestive organs are found on that tract. Those are the pharynx, stomach, small intestines, large intestines, and rectum. *(Image credit: "Main Digestive Organs" by John Polos is licensed under CC BY-NC-SA 4.0, modification of original by KnowledgeWorks .)*

Accessory Organs

Each accessory digestive organ aids in the breakdown of food (Figure 21.2.3. Within the oral cavity, the teeth and tongue begin mechanical digestion, whereas the salivary glands begin chemical digestion. Once food products enter the small intestine, the gallbladder, liver, and pancreas release secretions—such as bile and enzymes—essential for digestion to continue. Together, these are called accessory organs because they sprout from the lining cells of the developing gut (mucosa) and augment its function; indeed, you could not live without the vital contributions from the liver and pancreas, and many significant diseases result from their malfunction. Even after development is complete, they maintain a connection to the gut by way of ducts. The accessory digestive organs are summarized in (Table21.2.1.

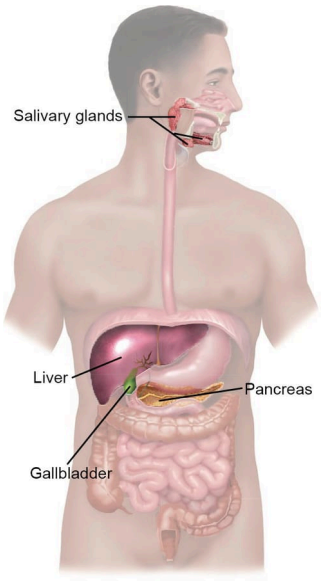

Figure 21.2.3: The accessory organs (salivary glands, liver, pancreas and gallbladder) develop off of the alimentary canal and they secrete digestive enzymes and other substances to assist and regulate the processes. *(Image credit: "Components of the Digestive System" by John Polos is licensed under CC BY-NC-SA 4.0, modification of original by KnowledgeWorks .)*

(Table 21.2.1: Organs of the Digestive System

Tract Organ	Accessory Organ
Oral Cavity- Ingestion. Site of mechanical digestion; start of chemical digestion.	**Salivary Glands**- Produce saliva; empty into oral cavity through ducts. The three pairs of salivary glands are: • parotid glands • submandibular glands • sublingual glands **Teeth**- Grinding, tearing, crushing of food. **Tongue**- Moves food to contact teeth; moves food into pharynx.
Esophagus- Moves food to stomach.	
Stomach- Chemical digestion of proteins and mechanical breakdown of food. Moves food to small intestine.	
Small Intestine- Finish chemical digestion and absorbs food. Moves food to large intestine. Three regions are: • Duodenum • Jejunum • Ileum	**Liver**- Produces bile that emulsifies fat. Empties into duodenum through hepatic ducts. **Gallbladder**- Stores bile. Empties into duodenum through cystic duct. **Pancreas**- Produces pancreatic juice which contains enzymes to digest lipids, proteins, and starch. Empties into duodenum through pancreatic duct(s).

Tract Organ	Accessory Organ
Large Intestine - Reabsorbs water and absorbs some vitamins and minerals; bacteria ferment soluble fiber. Five regions are: • Cecum • Ascending Colon • Transverse Colon • Descending Colon • Sigmoid Colon	
Rectum- Collects and stores fecal matter.	

Histology of the Digestive Tract Organs

Throughout its length, the digestive tract is composed of the same four tissue layers; the details of their structural arrangements vary to fit the specific functions of each organ or region. Starting from the lumen and moving outwards, these layers are the mucosa, submucosa, muscularis, and serosa (or adventitia). Figure 21.2.4 also shows the blood vessels and nerves sandwiched between the two serosal layers called the mesentery. More details about mesentery are found in upcoming paragraphs in this section.

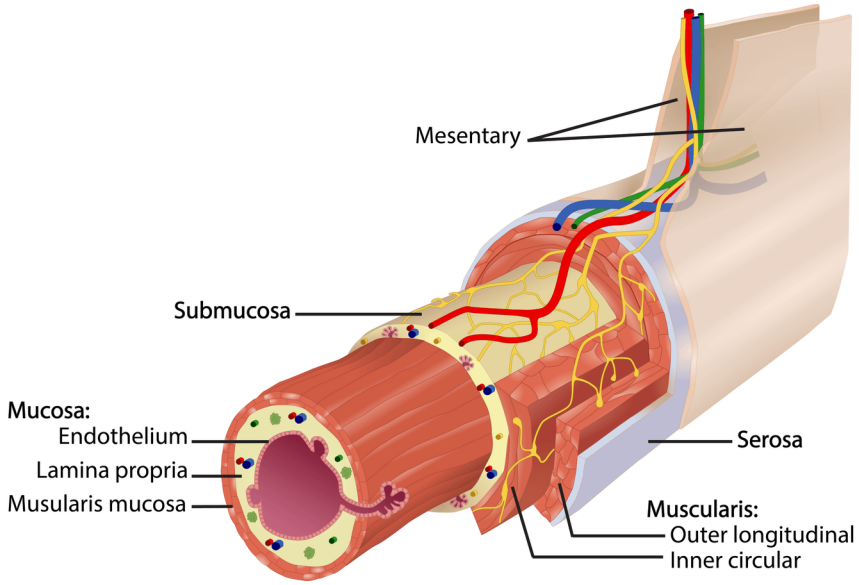

Figure 21.2.4: Layers of the Digestive Tract. From inner to outer, the wall of the digestive tract has four basic tissue layers: the mucosa, submucosa, muscularis, and serosa. Mesentery is seen with vessels and nerves sandwiched in between. *(Image credit: "Layers of the Gastrointestinal Tract" by Jennifer Lange is licensed under CC BY-NC-SA 4.0, modification of image by Goran tek-en with edits made by Collectivedogs via Wikimedia Commons.)*

Mucosa

The **mucosa** is referred to as a mucous membrane, because mucus production is a characteristic feature of gut epithelium. The membrane consists of epithelium, which is in direct contact with ingested food, and a layer of areolar connective tissue (Figure 21.2.3). In addition, the mucosa has a thin, smooth muscle layer called the muscularis mucosa (not to be confused with the muscularis layer, described below).

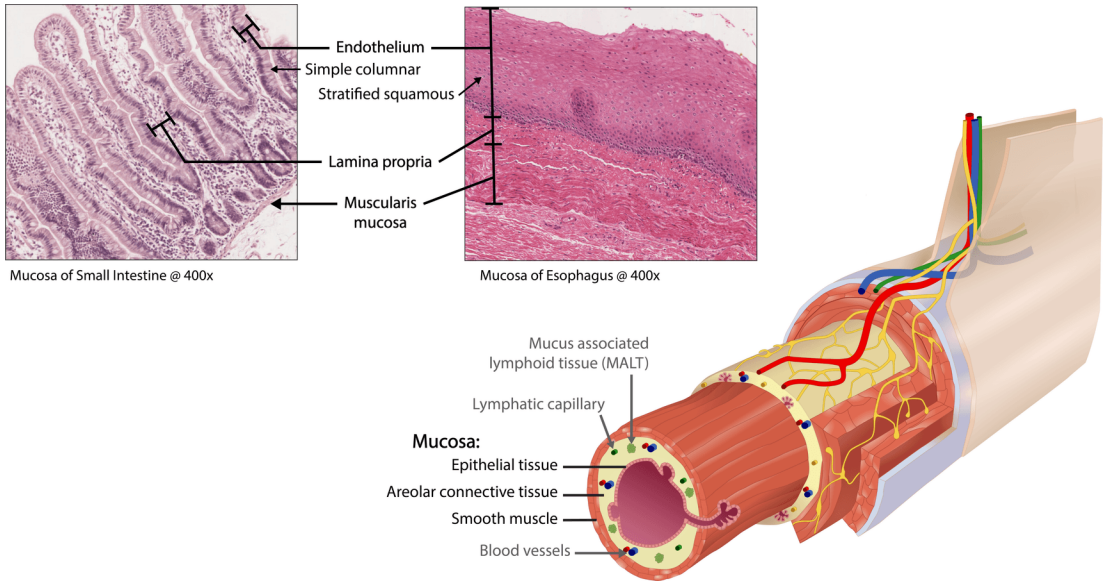

Figure 21.2.3: Mucosa of the GI Tract. The mucosa has three sublayers: an epithelial tissue, areolar connective tissue, and smooth muscle. In the small intestine the endothelium is simple columnar epithelium while in the esophagus it is stratified squamous epithelial tissue. *(Image credit: "Mucosa of the GI Tract" by Jennifer Lange is licensed under CC BY-NC-SA 4.0, incorporating illustration by Goran tek-en with edits made by Collectivedogs via Wikimedia Commons and slides provided by the Regents of the University of Michigan Medical School © 2022.)*

- **Endothelium:** In the oral cavity, pharynx, esophagus, and anal canal, the epithelium is primarily a non-keratinized, stratified squamous epithelium. In the stomach and intestines, it is a simple columnar epithelium. Notice that the epithelium is in direct contact with the lumen, the space inside the tract. Interspersed among its epithelial cells are goblet cells, which secrete mucus and fluid into the lumen, and enteroendocrine cells, which secrete hormones into the interstitial spaces between cells. Epithelial cells have a very brief lifespan, averaging from only a couple of days (in the oral cavity) to about a week (in the gut). This process of rapid renewal helps preserve the health of the tract organs, despite the wear and tear resulting from continued contact with foodstuffs.
- **Lamina propria:** In addition to areolar connective tissue, the lamina propria contains numerous blood and lymphatic vessels that transport nutrients absorbed through the tract to other parts of the body. The lamina propria also serves an immune function by housing clusters of lymphocytes, making up the mucosa-associated lymphoid tissue (MALT). These lymphocyte clusters are particularly substantial in the distal ileum where they are known as Peyer's patches. When you consider that the digestive tract organs are exposed to food borne bacteria and other foreign matter, it is not hard to appreciate why the immune system has evolved a means of defending against the pathogens encountered within it.
- **Muscularis mucosa:** This thin layer of smooth muscle is in a constant state of tension, pulling the mucosa of the stomach and small intestine into undulating folds. These folds dramatically increase the surface area available for digestion and absorption.

Submucosa

As its name implies, the **submucosa** lies immediately beneath the mucosa. A broad layer of areolar connective tissue (although some sources say it is dense irregular connective tissue) of varying thickness, it lies between the muscularis mucosa and the muscularis (Figure 21.2.5). It includes blood and lymphatic vessels (which transport absorbed nutrients), and a scattering of submucosal glands that release digestive secretions. Additionally, it serves as a conduit for a dense branching network of nerves, the submucosal plexus, which functions as described below.

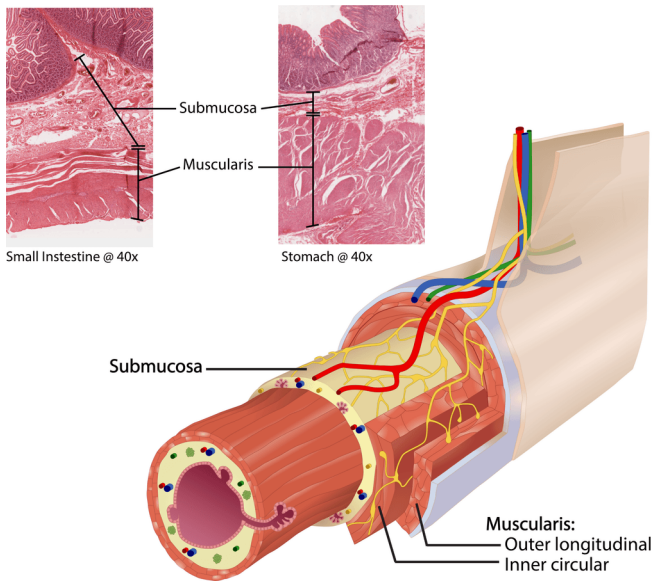

Figure 21.2.5: Submucosa and Muscularis of the GI Tract. The submucosa is a layer of areolar connective tissue between the muscularis mucosa and the muscularis. The muscularis is thicker in the stomach than in the small intestine. *(Image credit: "Submucosa and Muscularis of the GI Tract" by Jennifer Lange is licensed under CC BY-NC-SA 4.0, incorporating illustration by Goran tek-en with edits made by Collectivedogs via Wikimedia Commons and slides provided by the Regents of the University of Michigan Medical School © 2022.)*

Muscularis

The third layer of the digestive tract is the **muscularis** (also called the **muscularis externa**). The muscularis is made up of a double layer of smooth muscle: an inner circular layer, forming a ring around the tube, and an outer longitudinal layer that runs the length of the tube (Figure 21.2.4). The contractions of these layers promote mechanical digestion, expose more of the food to digestive chemicals, and move the food along the canal. In the most proximal and distal regions of the tract, including the oral cavity, pharynx, superior part of the esophagus, and external anal sphincter, the muscularis is made up of skeletal muscle to give you voluntary control over swallowing and defecation. The basic two-layer structure is modified in the stomach and large intestine. The stomach is equipped for its churning function by the addition of a third layer, the deep oblique muscle. While the large intestine has two layers, its longitudinal layer is segregated into three narrow parallel bands, the teniae coli, which make it look like a series of pouches rather than a simple tube.

Serosa or Adventitia

The **serosa** is the portion of the digestive tract superficial to the muscularis. Present only in the region of the digestive tract within the abdominal cavity, it consists of a layer of visceral peritoneum overlying a layer of loose connective tissue. Instead of serosa, the oral cavity, pharynx, and esophagus have a dense sheath of collagen fibers called the **adventitia**. These tissues serve to hold the tract organs in place near the ventral surface of the vertebral column.

Nerve Supply

As soon as food enters the oral cavity, it is detected by receptors that send impulses along the sensory neurons of cranial nerves. Without these nerves, not only would your food be without taste, but you would also be unable to feel either the food or the structures of your oral cavity. Without these nerves, you would could bite yourself as you chew, an action enabled by the motor branches of cranial nerves.

Intrinsic (within) innervation of much of the digestive tract is provided by the enteric nervous system, which runs from the esophagus to the anus, and contains approximately 100 million motor, sensory, and interneurons (unique to this system compared to all other parts of the peripheral nervous system). The enteric nervous system is the largest component of the peripheral nervous system and because it has interneurons is frequently called the "second brain"! These enteric neurons are grouped into two plexuses. The myenteric plexus (plexus of Auerbach) lies in the muscularis layer and is responsible for motility, especially the rhythm and force of the contractions of the muscularis. The submucosal plexus (plexus of Meissner) lies in the submucosal layer and is responsible for regulating digestive secretions and reacting to the presence of food (Figure 21.2.6.

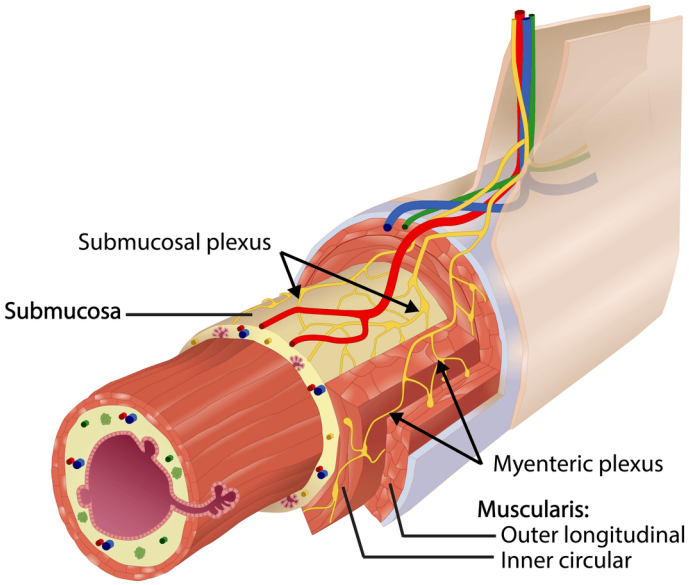

Figure 21.2.6: Enteric Nervous System. The two plexuses of the enteric nervous system are found in the submucosa and the muscularis layers. *(Image credit: "Enteric Nervous System" by Jennifer Lange is licensed under CC BY-NC-SA 4.0, modification of illustration by Goran tek-en with edits made by Collectivedogs via Wikimedia Commons.)*

Extrinsic innervations of the digestive tract are provided by the autonomic nervous system communicating with the enteric nervous system. In general, sympathetic activation (the fight-or-flight response) restricts the activity of enteric neurons, thereby decreasing GI secretion and motility. In contrast, parasympathetic activation (the rest-and-digest response) increases GI secretion and motility by stimulating neurons of the enteric nervous system.

Blood Supply

The blood vessels serving the digestive system have two functions. They transport the protein and carbohydrate nutrients absorbed by mucosal cells after food is digested in the lumen. Lipids are absorbed via lacteals, tiny structures of the lymphatic system. The blood vessels' second function is to supply the organs of the digestive tract with the nutrients and oxygen needed to drive their cellular processes.

Specifically, the more anterior parts of the digestive tract are supplied with blood by arteries branching off the aortic arch and thoracic aorta. Below this point, the digestive tract is supplied with blood by arteries branching from the abdominal aorta. The celiac trunk services the liver, stomach, and duodenum, whereas the superior and inferior mesenteric arteries supply blood to the remaining small and large intestines (Figure 21.2.7).

The veins that collect nutrient-rich blood from the small intestine (where most absorption occurs) and the spleen, empty into the hepatic portal system. This venous network takes the blood into the liver where the nutrients are either processed or stored for later use. Only then does the blood drained from the digestive tract organs and the spleen (not a digestive organ) circulate back to the heart. To appreciate just how demanding the digestive process is on the cardiovascular system, consider that while you are "resting and digesting," about one-fourth of the blood pumped with each heartbeat enters arteries serving the intestines.

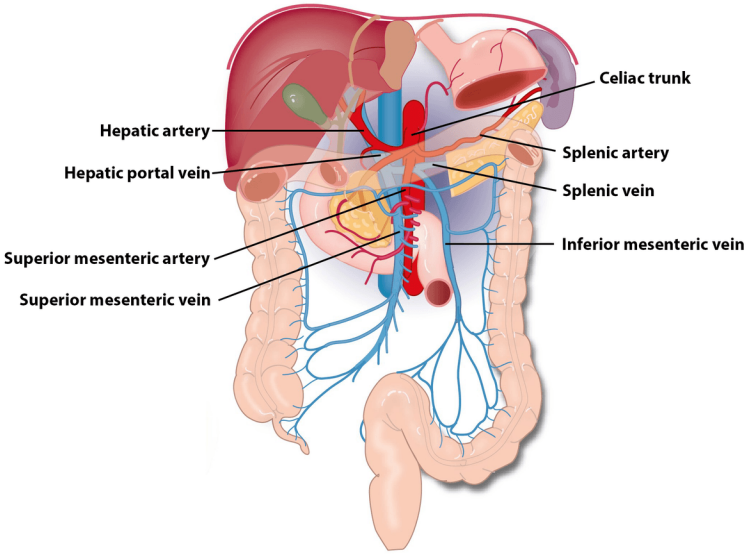

Figure 21.2.7: Blood Vessels of the Abdomen. The majority of blood going to the digestive organs is carried by one of three major branches from the abdominal aorta: the celiac trunk, superior mesenteric artery or inferior mesenteric artery (not shown). Venous blood from the intestines, stomach, pancreas, and spleen enter the hepatic portal system to flow through the liver before returning to general circulation. *(Image credit: "Blood Vessels of the Abdomen" by Jennifer Lange is licensed under CC BY-NC-SA 4.0, modification of illustration "Slagter - Drawing Portal vein - no labels" by Ron Slagter.)*

Peritoneum

The digestive organs within the abdominal cavity are held in place by the peritoneum, a broad serous membrane. It is composed of two different regions: the **parietal peritoneum**, which lines the abdominal wall (red in Figure 21.2.8 below), and the **visceral peritoneum**, which envelopes the abdominal organs (blue in Figure 21.2.8). The peritoneal cavity is the space bounded by the visceral and parietal peritoneal surfaces, filled with a few milliliters of watery fluid acting as a lubricant to minimize friction between the surfaces of the peritoneum.

The visceral peritoneum is the serosa of the organs within the peritoneal cavity. The visceral peritoneum includes multiple large folds, also called **mesenteries** (Figure 21.2.9), that connect various abdominal organs, holding them to the dorsal surface of the body (trunk) wall and in some cases, each other. General functions of the peritoneal folds are to provide routes for vessels and nerves to reach intraperitoneal (within the peritoneum) organs, hold these organs to a relative location and in some cases insulate and protect other nearby organs. The largest peritoneal fold is the **greater omentum** (Figure 21.2.9)**,** a sheet of the membrane containing adipose that lies anterior to the intestines. The greater omentum provides a small amount of protection (cushioning) in the region not protected by the skeleton.

Note that during fetal development, certain digestive structures, including the first portion of the small intestine (called the duodenum), the pancreas, and portions of the large intestine (the ascending and descending colon, and the rectum) remain completely or partially posterior to the peritoneum. Thus, the location of these organs is described as retroperitoneal.

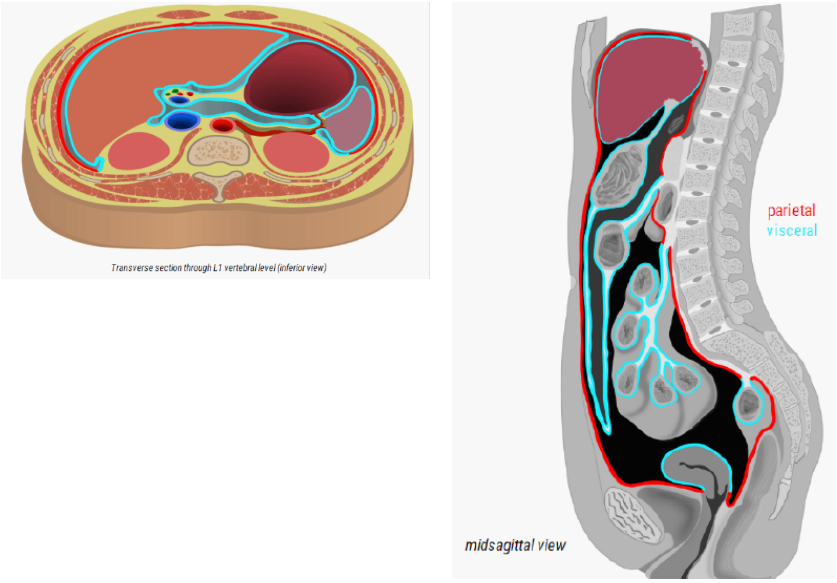

Figure 21.2.8: Parietal and Visceral Peritoneum. The peritoneal membrane has two layers: the parietal layer adheres to the walls of the abdominopelvic cavity and the visceral layer adheres to the organs. *(Image credits: "Peritoneum Sections" by University of British Columbia Clinical Anatomy are licensed under CC BY-NC-SA 4.0.)*

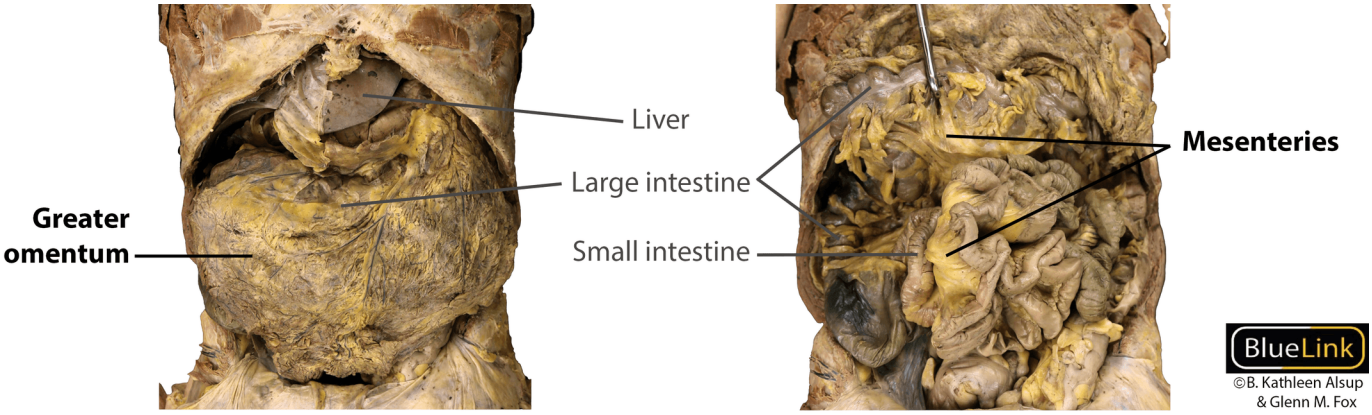

Figure \({21{.}2{.}\eatSpaces{9\): Greater Omentum and the Mesenteries. Cadaver dissections showing the greater omentum (left) and the organs underneath connected to the mesenteries (right). *(Image credit: "Greater Omentum and the Mesenteries" by Jennifer Lange is licensed under CC BY-NC 4.0, cadaver images by BlueLink are licensed under CC BY-NC 4.0 with notification of the original authors.)*

DISORDERS OF THE...

Digestive System: Peritonitis

Inflammation of the peritoneum is called peritonitis. Chemical peritonitis can develop any time the wall of the digestive tract is breached, allowing the contents of the lumen entry into the peritoneal cavity. For example, when an ulcer perforates the stomach wall, gastric juices spill into the peritoneal cavity. Hemorrhagic peritonitis occurs after a ruptured tubal pregnancy or traumatic injury to the liver or spleen fills the peritoneal cavity with blood. Even more severe peritonitis is associated with bacterial infections seen with appendicitis, colonic diverticulitis, and pelvic inflammatory disease (infection of uterine tubes, usually by sexually transmitted bacteria). Peritonitis is life threatening and often results in emergency surgery to correct the underlying problem and intensive antibiotic therapy. When your great grandparents and even your parents were young, the mortality from peritonitis was high. Aggressive surgery, improvements in anesthesia safety, the advance of critical care expertise, and antibiotics have greatly improved the mortality rate from this condition. Even so, the mortality rate for peritonitis still ranges from 30 to 40 percent.

Concept Review

The digestive system includes the organs of the digestive tract and accessory structures. The digestive tract forms a continuous tube that is open to the outside environment at both ends.

The organs of the tract are the

- oral cavity,
- pharynx,
- esophagus,
- stomach,
- small intestine
  - duodenum
  - jejunum
  - ileum
- large intestine (colon)
  - cecum
  - appendix
  - ascending colon
  - transverse colon
  - descending colon
  - sigmoid colon
- rectum
- anus

The accessory digestive structures include the

- teeth,
- tongue,
- salivary glands,
  - parotid
  - sublingual
  - submandibular
- liver,
- pancreas,
- gallbladder.

The wall of the digestive tract is composed of four basic tissue layers: mucosa, submucosa, muscularis, and serosa (or adventitia).

The enteric nervous system provides intrinsic innervation, and the autonomic nervous system provides extrinsic innervation. Organs of the digestive system receive oxygenated blood from the abdominal aorta and send deoxygenated, nutrient rich blood, to the liver through the hepatic portal vein. The peritoneum, a serous membrane, functions to anchor abdominal organs and provides routes for vessels and nerves along with insulation in specialized regions called peritoneal folds (mesenteries).

Review Questions

Query Extra close brace or missing open brace

This interactive element is not available in this format. Visit the link or scan the QR code to access it online.

View this Interactive Content online

Critical Thinking Questions

Query 21.2.2

This interactive element is not available in this format. Visit the link or scan the QR code to access it online.

View this Interactive Content online

Query 21.2.3

This interactive element is not available in this format. Visit the link or scan the QR code to access it online.

View this Interactive Content online

Glossary

Query 21.2.4

This interactive element is not available in this format. Visit the link or scan the QR code to access it online.

View this Interactive Content online

Contributors and Attributions

OpenStax Anatomy & Physiology (CC BY 4.0). Access for free at https://openstax.org/books/anatomy-and-physiology

This page titled 21.2: Organs of the Digestive System is shared under a CC BY-NC-SA 4.0 license and was authored, remixed, and/or curated by Jennifer Lange et al..

- 21.2: Organs of the Digestive System by Whitney Menefee, Julie Jenks, Chiara Mazzasette, and Kim-Leiloni Nguyen is licensed CC BY 4.0.

21.3: Digestive System Processes and Regulation

By the end of the section, you will be able to:

- Discuss seven fundamental activities of the digestive system, giving an example of each
- Describes the functions of each digestive organs
- Describe the difference between mechanical digestion and chemical digestion
- Describe the difference between peristalsis and segmentation

The digestive system uses mechanical and chemical activities to break food down into absorbable substances during its journey through the digestive system. Table 21.3.1 provides an overview of the basic functions of the digestive organs.

Table* 21.3.1*: Functions of the Digestive Organs

Organ	Major functions	Other functions
Oral Cavity	• Ingests food • Chews and mixes food • Begins chemical breakdown of carbohydrates with secretion of saliva • Moves food into the pharynx • Begins breakdown of lipids via lingual lipase	• Moistens and dissolves food, allowing you to taste it • Cleans and lubricates the teeth and oral cavity • Has some antimicrobial activity
Pharynx	• Propels food from the oral cavity to the esophagus	• Lubricates food and passageways
Esophagus	• Propels food to the stomach	• Lubricates food and passageways
Stomach	• Mixes and churns food with gastric juices secreted from epithelium to form chyme • Begins chemical breakdown of proteins • Releases food into the duodenum as chyme • Absorbs some fat-soluble substances (for example, alcohol, aspirin) • Possesses antimicrobial functions	• Stimulates protein-digesting enzymes • Secretes intrinsic factor required for vitamin B_{12} absorption in small intestine
Small intestine	• Mixes chyme with digestive juices secreted from pancreas, gallbladder, and small intestine • Propels food at a rate slow enough for digestion and absorption • Absorbs breakdown products of carbohydrates, proteins, lipids, and nucleic acids, along with vitamins, minerals, and water • Performs physical digestion via segmentation	• Provides optimal medium for enzymatic activity
Large intestine	• Reabsorbs water secreted by the stomach • Absorbs most electrolytes, and vitamins produced by enteric bacteria • Propels feces toward rectum	• Food residue is concentrated and temporarily stored prior to defecation • Mucus eases passage of feces through colon

Organ	Major functions	Other functions
Rectum	• Stores fecal matter until wall stretch triggers the defecation reflex.	• Reabsorbs water secreted by the stomach. • Absorbs electrolytes.
Anal canal	• Internal and external anal sphincters remain closed to keep feces in the tract. • Internal and external anal sphincters relax to allow passage of feces.	• Defecation reflex triggers the relaxation of the internal anal sphincter (smooth muscle). • The external anal sphincter is under voluntary control (skeletal muscle).
Accessory organs	• **Teeth**: begin ingestion through biting food; begin mechanical digestion by crushing and tearing food into smaller pieces. • **Tongue**: aids in ingestion and in mechanical digestion by bringing food into the oral cavity and moving it so that it is in position for the teeth. Gathers food into bolus and pushes it to the pharynx for swallowing. • **Salivary glands**: produce digestive enzyme amylase and mucus. Both enter oral cavity where the mucus lubricates food and the amylase breaks down starch. • **Liver**: produces bile salts, which enter the small intestine. In the small intestine, bile salts emulsify lipids, aiding their digestion and absorption. • **Gallbladder**: stores, concentrates, and releases bile. • **Pancreas**: produces digestive enzymes and bicarbonate. These are released into the small intestine where the enzymes finish chemical digestion and the bicarbonate buffers against the stomach acid.	• Bicarbonate-rich pancreatic juices help neutralize acidic chyme and provide optimal environment for enzymatic activity. • Saliva contains chemical compounds that restrict bacterial growth and help to keep your teeth and gums healthy.

Digestive Processes

The processes of digestion include seven activities: ingestion, propulsion, mechanical or physical digestion, chemical digestion, secretion, absorption, and defecation.

The first of these processes, **ingestion**, refers to the entry of food into the alimentary canal through the oral cavity. There, the food is chewed and mixed with saliva secreted by salivary glands, which contains enzymes that begin breaking down the carbohydrates in the food plus some lipid digestion via lingual lipase. Chewing increases the surface area of the food and allows an appropriately sized bolus (chunk) to be produced.

Food leaves the oral cavity when the tongue and pharyngeal muscles propel it into the esophagus. This act of swallowing, the last voluntary act until defecation, is an example of **propulsion**, which refers to the movement of food through the digestive tract. It includes both the voluntary process of swallowing and the involuntary process of peristalsis. **Peristalsis** consists of sequential, alternating waves of contraction and relaxation of of circular and longitudinal layers of the muscularis externa (alimentary wall smooth muscles), which act to propel food along (Figure 21.3.1). These waves also play a role in mixing food with digestive juices. Peristalsis is so powerful that foods and liquids you swallow enter your stomach even if you are standing on your head.

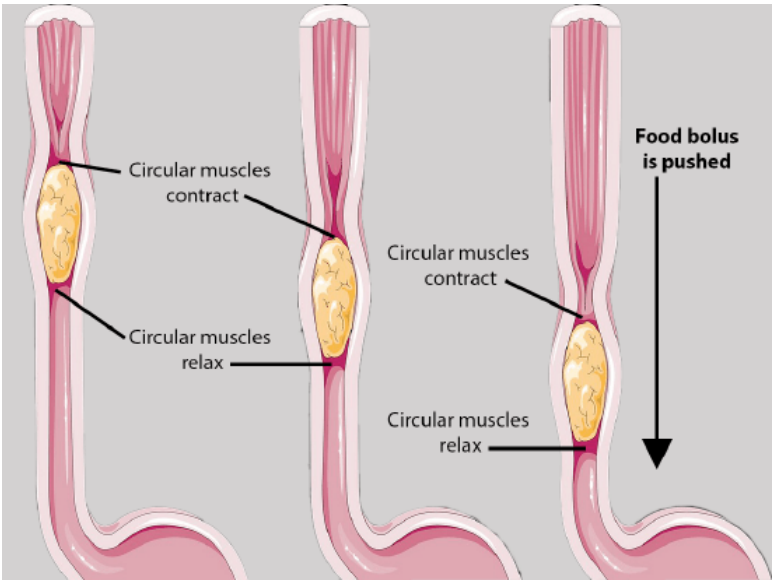

Figure 21.3.1: Peristalsis. Peristalsis moves food through the digestive tract with sliding waves of muscle contraction and relaxation. *(Image credit: "Peristalsis" by Jennifer Lange is licensed under CC BY-NC-SA 4.0, modification of originals by Servier Medical Art under CC BY 2.0.)*

Peristalysis

In the small intestine the waves of peristaltic contractions are shorter than in the esophagus, as they only move the liquified food a small distance so digestion and absorption can continue.

This interactive element is not available in this format. Visit the link or scan the QR code to access it online.

View this YouTube Video online

Digestion includes both mechanical and chemical processes. **Mechanical digestion** is a purely physical process that does not change the chemical nature of the food. Instead, it makes the food smaller to increase both surface area and mobility. It includes **mastication**, or chewing, as well as tongue movements that help break food into smaller bits and mix food with saliva. Although there may be a tendency to think that mechanical digestion is limited to the first steps of the digestive process, it occurs after the food leaves the oral cavity, as well. The mechanical churning of food in the stomach serves to further break it apart and expose more of its surface area to digestive juices, creating an acidic "soup" called **chyme**. **Segmentation**, which occurs mainly in the small intestine, consists of localized contractions of circular muscle of the muscularis layer of the alimentary canal. These contractions isolate small sections of the intestine, moving their contents back and forth while continuously subdividing, breaking up, and mixing the contents. By moving food back and forth in the intestinal lumen, segmentation mixes food with digestive juices and facilitates absorption.

Chemical digestion is aided by **secretion** of enzymes. Starting in the oral cavity, digestive secretions break down complex food molecules into their chemical building blocks (for example, proteins into separate amino acids). These secretions vary in composition, but typically contain water, various enzymes, acids, and salts. The process is completed in the small intestine.

Food that has been broken down is of no value to the body unless it enters the bloodstream and its nutrients are put to work. This occurs through the process of **absorption**, which takes place primarily within the small intestine. There, most nutrients are absorbed from the lumen of the alimentary canal into the bloodstream through the epithelial cells that make up the mucosa. Lipids are absorbed into lacteals and are transported via the lymphatic vessels to the bloodstream (the subclavian veins near the heart). The details of these processes will be discussed later.

In **defecation**, the final step in digestion, undigested materials are removed from the body as feces.

AGING AND THE...

Digestive System: From Appetite Suppression to Constipation

Age-related changes in the digestive system begin in the oral cavity and can affect virtually every aspect of the digestive system. Taste buds become less sensitive, so food isn't as appetizing as it once was. A slice of pizza is a challenge, not a treat, when you have lost teeth, your gums are diseased, and your salivary glands aren't producing enough saliva. Swallowing can be difficult, and ingested food moves slowly through the alimentary canal because of reduced strength and tone of muscular tissue. Neurosensory feedback is also dampened, slowing the transmission of messages that stimulate the release of enzymes and hormones.

Pathologies that affect the digestive organs—such as hiatal hernia, gastritis, and peptic ulcer disease—can occur at greater frequencies as you age. Problems in the small intestine may include duodenal ulcers, maldigestion, and malabsorption. Problems in the large intestine include hemorrhoids, diverticular disease, and constipation. Conditions that affect the function of accessory organs—and their abilities to deliver pancreatic enzymes and bile to the small intestine—include jaundice, acute pancreatitis, cirrhosis, and gallstones.

In some cases, a single organ is in charge of a digestive process. For example, ingestion occurs only in the oral cavity and defecation from the anus. However, most digestive processes involve the interaction of several organs and occur gradually as food moves through the alimentary canal (Figure 21.3.2). Figure 21.3.2 shows the digestive tract with the locations of propulsion, chemical digestion, mechanical digestion, and absorption in different organs.

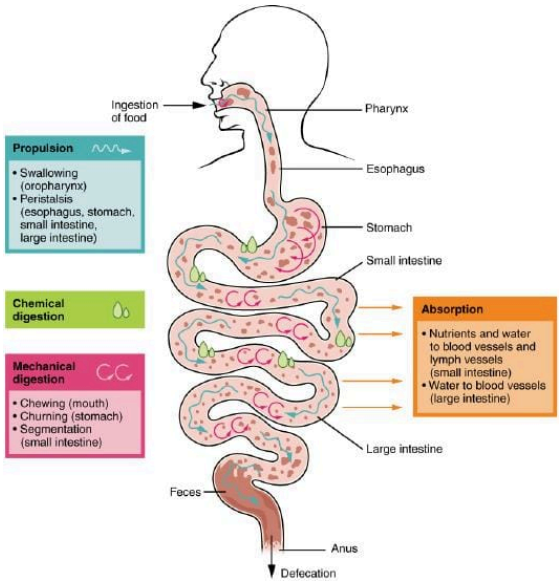

Figure 21.3.2: Digestive Processes. The digestive processes are ingestion (oral cavity), propulsion (GI tract), mechanical digestion (oral cavity, stomach, and small intestine), chemical digestion (oral cavity, stomach, and small intestine), absorption (stomach, small intestine, and large intestine), and defecation (anus). (Image credit: "Digestive Process" by OpenStax is licensed under CC BY 3.0)

While most chemical digestion occurs in the small intestine, some occurs in the oral cavity (carbohydrates and lipids) and stomach (proteins). Absorption, also largely carried out by the small intestine, some can occur in the oral cavity, stomach, and large intestine. For example, alcohol and aspirin are absorbed by the stomach and water and many ions are absorbed by the large intestine.

Regulatory Mechanisms

Neural and endocrine regulatory mechanisms work to maintain the optimal conditions in the lumen needed for digestion and absorption. These regulatory mechanisms, which stimulate digestive activity through mechanical and chemical activity, are controlled both extrinsically and intrinsically.

Neural Controls

The walls of the alimentary canal contain a variety of sensors that help regulate digestive functions. These include mechanoreceptors, chemoreceptors, and osmoreceptors, which are capable of detecting mechanical, chemical, and osmotic stimuli, respectively. For example, these receptors can sense when the presence of food has caused the stomach to expand, whether food particles have been sufficiently broken down, how much liquid is present, and the type of nutrients in the food (lipids, carbohydrates, and/or proteins). Stimulation of these receptors provokes an appropriate reflex that furthers the process of digestion. This may entail sending a message that activates the glands that secrete digestive juices into the lumen, or it may mean the stimulation of muscles within the alimentary canal, thereby activating peristalsis and segmentation that move food along the intestinal tract.

The walls of the entire alimentary canal are embedded with nerve plexuses (enteric nervous system, submucosal and myenteric plexuses) that interact with the central nervous system and other nerve plexuses—either within the same digestive organ or in different ones. These interactions prompt several types of reflexes. Extrinsic nerve plexuses orchestrate long reflexes, which involve the central and autonomic nervous systems and work in response to stimuli from outside the digestive system. Short reflexes, on the other hand, are orchestrated by intrinsic nerve plexuses within the alimentary canal wall. These two plexuses and their connections were introduced earlier as the enteric nervous system. Short reflexes regulate activities in one area of the digestive tract and may coordinate local peristaltic movements and stimulate digestive secretions. For example, the sight, smell, and taste of food initiate long reflexes that begin with a sensory neuron delivering a signal to the medulla oblongata. The response to the signal is to stimulate cells in the stomach to begin secreting digestive juices in preparation for incoming food. In contrast, food that distends the stomach initiates short reflexes that cause cells in the stomach wall to increase their secretion of digestive juices.

Hormonal Controls

A variety of hormones are involved in the digestive process. The main digestive hormone of the stomach is gastrin, which is secreted in response to the presence of food. Gastrin stimulates the secretion of gastric acid by the parietal cells of the stomach mucosa. Other GI hormones are produced and act upon the gut and its accessory organs. Hormones produced by the duodenum include secretin, which stimulates a watery secretion of bicarbonate by the pancreas; cholecystokinin (CCK), which stimulates the secretion of pancreatic enzymes and bile from the liver and release of bile from the gallbladder; and gastric inhibitory peptide, which inhibits gastric secretion and slows gastric emptying and motility. These GI hormones are secreted by specialized epithelial cells, called enteroendocrine cells, located in the mucosal epithelium of the stomach and small intestine. These hormones then enter the bloodstream, through which they can reach their target organs.

Concept Review

The digestive system ingests and digests food, absorbs released nutrients, and excretes food components that are indigestible. The six activities involved in this process are ingestion (oral cavity), motility (GI tract), mechanical digestion (oral cavity, stomach, small intestine), chemical digestion (oral cavity, stomach, small intestine), absorption (oral cavity, stomach, small and large intestines), and defecation (anus). Contractions of smooth muscles (muscularis externa) result in peristalsis to push contents along in the GI tract and segmentation to mix the content with enzymes. These processes are regulated by neural and hormonal mechanisms.

Review Questions

Query 21.3.1

This interactive element is not available in this format. Visit the link or scan the QR code to access it online.

View this Interactive Content online

Critical Thinking Questions

Query 21.3.2

This interactive element is not available in this format. Visit the link or scan the QR code to access it online.

View this Interactive Content online

Query 21.3.3

This interactive element is not available in this format. Visit the link or scan the QR code to access it online.

View this Interactive Content online

Glossary

Query 21.3.4

This interactive element is not available in this format. Visit the link or scan the QR code to access it online.

View this Interactive Content online

Contributors and Attributions

- OpenStax Anatomy & Physiology (CC BY 4.0). Access for free at https://openstax.org/books/anatomy-and-physiology

This page titled 21.3: Digestive System Processes and Regulation is shared under a CC BY-NC-SA 4.0 license and was authored, remixed, and/or curated by Jennifer Lange et al..

- 21.3: Digestive System Processes and Regulation by Whitney Menefee, Julie Jenks, Chiara Mazzasette, and Kim-Leiloni Nguyen is licensed CC BY 4.0.

21.4: Mouth, Pharynx, and Esophagus

By the end of the section, you will be able to:

- Describe the structures of the oral cavity, including its three accessory digestive organs
- Group the 32 adult teeth according to name, location, and function
- Describe the histology of the oral cavity, pharynx, and esophagus
- Trace the pathway food follows from ingestion into the oral cavity through release into the stomach

In this section, you will examine the anatomy and functions of the three main organs of the upper alimentary canal—the oral cavity, pharynx, and esophagus—as well as three associated accessory organs—the tongue, salivary glands, and teeth.

Oral Cavity

The cheeks, tongue, and palate frame the **oral cavity** (or buccal cavity). The structures of the oral cavity are illustrated in Figure 21.4.1. Teeth, hard and soft palate, fauces, arches, and uvula form the roof of the oral cavity. The floor of the oral cavity has the different types of teeth labeled, tongue, and lingual frenulum attached to the tongue. Below the tongue are openings of the ducts of submandibular glands. The image also shows the upper and lower lips attached by the upper and lower labial frenula (singular: frenulum).

At the entrance to the oral cavity are the lips, or **labia** (singular = labium). Their outer covering is skin, which transitions to a mucous membrane in the oral cavity proper. Lips are very vascular with a thin layer of keratin; hence, the reason they are "red." They have a huge representation on the cerebral cortex, which probably explains the human fascination with kissing! The lips cover the orbicularis oris muscle, which regulates what comes in and goes out of the oral cavity. The cheeks make up the oral cavity's sidewalls. While their outer covering is skin, their inner covering is mucous membrane. This membrane is made up of non-keratinized, stratified squamous epithelium. Between the skin and mucous membranes are connective tissue.

When you are chewing, you do not find it difficult to breathe simultaneously. The next time you have food in your oral cavity, notice how the arched shape of the roof of your oral cavity allows you to handle both ingestion and respiration at the same time. This arch is called the **palate**. The anterior region of the palate serves as a wall (or septum) between the oral and nasal cavities as well as a rigid shelf against which the tongue can push food. It is created by the maxillary and palatine bones of the skull and, given its bony structure, is known as the **hard palate**. If you run your tongue along the roof of your oral cavity, you'll notice that the hard palate ends in the posterior oral cavity, and the tissue becomes fleshier. This part of the palate, known as the **soft palate**, is composed mainly of skeletal muscle. You can therefore manipulate, subconsciously, the soft palate—for instance, to yawn, swallow, or sing (see Figure 21.4.1).

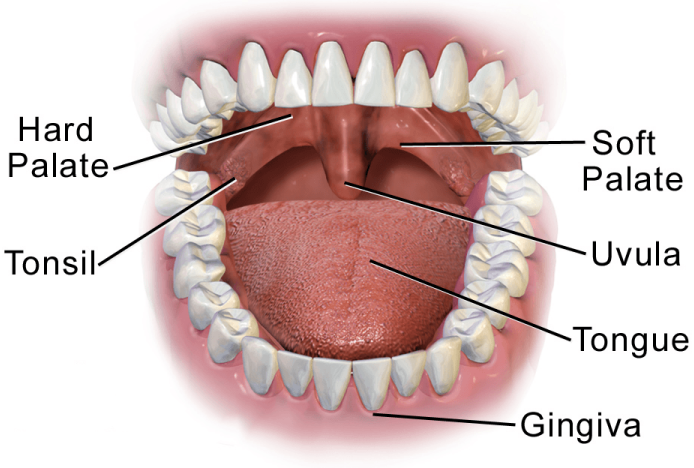

Figure 21.4.1: Oral Cavity. The oral cavity includes the lips, tongue, palate, gums, and teeth. *(Image credit: "Blausen 0653 - Anatomy of the oral cavity - English labels" by Blausen.com staff (2014), is licensed under CC BY. Modification by Jennifer Lange.)*

A fleshy bead of tissue called the uvula drops down from the center of the posterior edge of the soft palate. Although some have suggested that the uvula is a vestigial (a structure in our ancestors that has over time lost its original function) organ, it serves an important purpose. When you swallow, the soft palate and uvula move upward, helping to keep foods and liquid from entering the nasal cavity. Unfortunately, it can also contribute to the sound produced by snoring. Lateral to the uvula are the palatine tonsils, clusters of lymphoid tissue that protect the pharynx.

Tongue

Perhaps you have heard it said that the **tongue** is the strongest muscle in the body. Those who stake this claim cite its strength proportionate to its size. Although it is difficult to quantify the relative strength of different muscles, it remains indisputable that the tongue is a workhorse, facilitating ingestion, mechanical digestion, chemical digestion (lingual lipase), sensation (of taste, texture, and temperature of food), swallowing, and vocalization.

The tongue is positioned over the floor of the oral cavity (Figure 21.4.2). It attaches to the soft tissue via **frenulum** and is attached to the mandible, the styloid processes of the temporal bones, and the hyoid bone. A medial septum extends the entire length of the tongue, dividing it into symmetrical halves.

Beneath its mucous membrane covering, each half of the tongue is composed of the same number and type of intrinsic and extrinsic skeletal muscles. These allow you to change the size and shape of your tongue, as well as to stick it out, if you wish. Having such a flexible tongue facilitates both swallowing and speech.

The extrinsic muscles of the tongue originate outside the tongue and insert into connective tissues within the tongue. The mylohyoid is responsible for raising the tongue, the hyoglossus pulls it down and back, the styloglossus pulls it up and back, and the genioglossus pulls it forward. Working in concert, these muscles perform three important digestive functions in the oral cavity: (1) position food for optimal chewing, (2) gather food into a **bolus** (rounded mass), and (3) position food so it can be swallowed.

The top and sides of the tongue are studded with **papillae** (round mounds), extensions of lamina propria of the mucosa, which are covered in stratified squamous epithelium (Figure 21.4.2). **Fungiform papillae**, which are mushroom shaped, cover a large area of the tongue; they tend to be larger toward the rear of the tongue and smaller on the tip and sides. In contrast, **filiform papillae** are long and thin and they cover the majority of the superior surface. **Vallate papillae** (also called circumvallate papillae) form two rows at the posterior of the tongue. Fungiform and vallate papillae contain taste buds; filiform papillae have touch receptors that help the tongue move food around in the oral cavity.

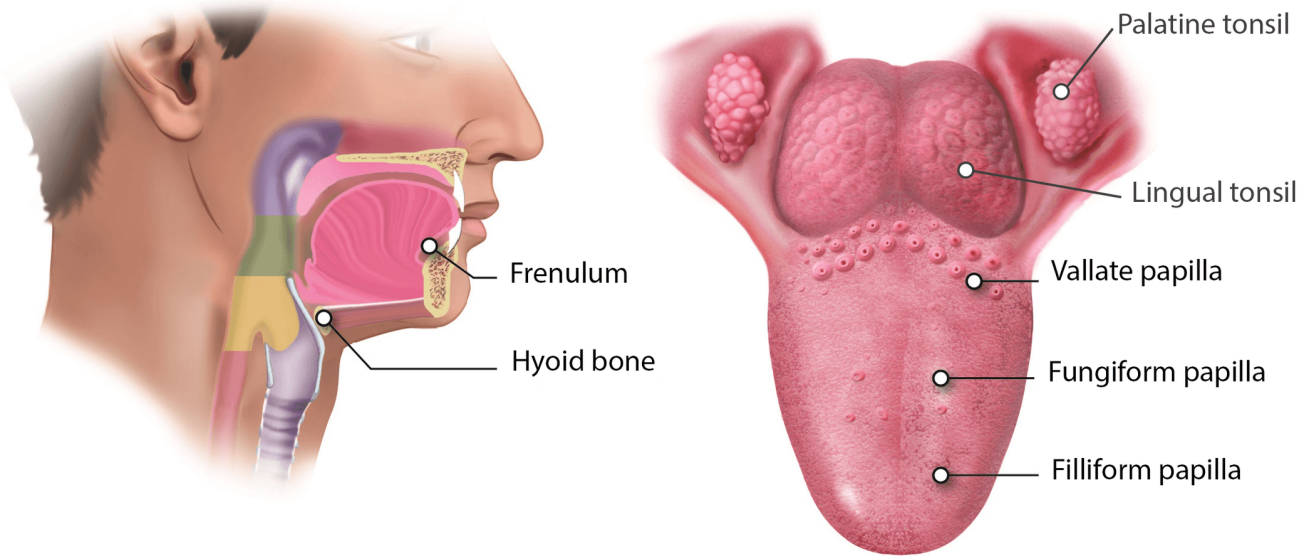

Figure 21.4.2: Tongue. This superior view of the tongue shows the locations and types of lingual papillae. *(Image credit: "KnowledgeWorks - Drawing Tongue and adjacent structures - English labels" by KnowledgeWorks Global Ltd. is licensed under CC BY; modification of labels by Jennifer Lange.)*

Salivary Glands

Many small **salivary glands** are housed within the mucous membranes of the oral cavity and tongue. These minor exocrine glands are constantly secreting saliva, either directly into the oral cavity or indirectly through ducts, even while you sleep. In fact, an average of 1 to 1.5 liters of saliva is secreted each day. Usually just enough saliva is present to moisten the oral cavity and teeth. Reflexes stimulated by presence or thoughts of food increase secretion when you eat, because saliva is essential to moisten food and initiate the chemical breakdown of carbohydrates. Small amounts of saliva are also secreted by the labial glands in the lips. In addition, the buccal glands in the cheeks, palatal glands in the palate, and lingual glands in the tongue help ensure that all areas of the oral cavity are supplied with adequate saliva.

Major Salivary Glands

Outside the oral mucosa are three pairs of major salivary glands, which secrete the majority of saliva into ducts that open into the oral cavity (Figure 21.4.3).

- The **submandibular glands**, which are in the floor of the oral cavity, secrete saliva into the oral cavity through the submandibular ducts, one on each side of the lingual frenulum.
- The **sublingual glands**, which lie below the tongue, use the multiple lesser sublingual ducts to secrete saliva into the oral cavity.
- The **parotid glands** lie between the skin and the masseter muscle, near the ears. They secrete saliva into the oral cavity through the parotid duct, which is located near the second upper molar tooth.

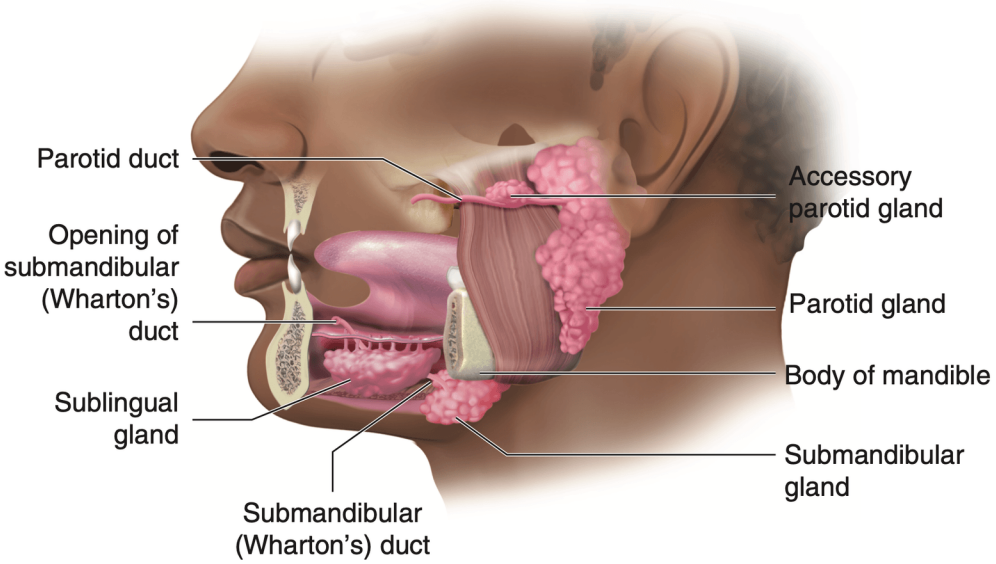

Figure 21.4.3: Salivary Glands. The major salivary glands are located outside the oral mucosa and deliver saliva into the oral cavity through ducts. *(Image credit: "KnowledgeWorks - Drawing Location of salivary glands and ducts - English labels" by KnowledgeWorks Global Ltd., is licensed under CC BY.)*

Saliva is essentially water (95.5%). The remaining 4.5 percent is a complex mixture of ions, glycoproteins, enzymes, growth factors, and waste products. Perhaps the most important ingredient in saliva from the perspective of digestion is the enzyme **salivary amylase**, which initiates the breakdown of carbohydrates. Food does not spend enough time in the oral cavity to allow all the carbohydrates to break down, but salivary amylase continues acting until it is inactivated by stomach acids. Bicarbonate and phosphate ions function as chemical buffers, maintaining saliva at a pH between 6.35 and 6.85. Salivary mucus helps lubricate food, facilitating movement in the oral cavity, bolus formation, and swallowing. Saliva contains immunoglobulin A (antibodies), which prevents microbes from penetrating the epithelium, and lysozyme, which makes saliva antimicrobial. Saliva also contains epidermal growth factor, which might have given rise to the adage "a mother's kiss can heal a wound."

Each of the major salivary glands secretes a unique formulation of saliva according to its cellular makeup. For example, the parotid glands secrete a watery solution that contains salivary amylase. The submandibular glands (Figure 21.4.3)) have cells similar to those of the parotid glands, as well as mucus-secreting cells. Therefore, saliva secreted by the submandibular glands also contains amylase but in a liquid thickened with mucus. The sublingual glands contain mostly mucous cells, and they secrete the thickest saliva with the least amount of salivary amylase.

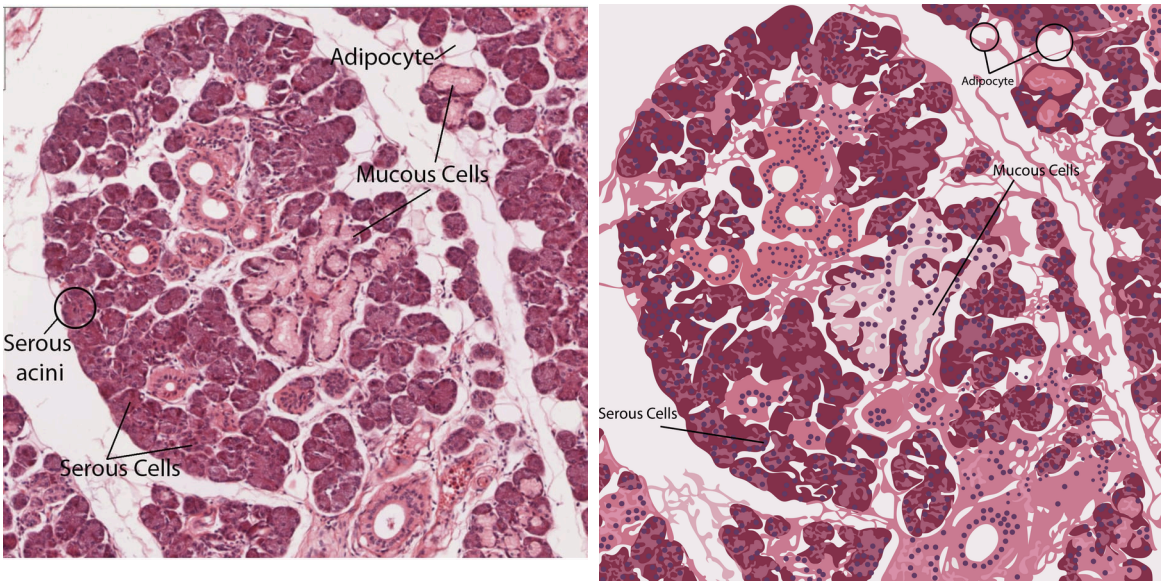

Figure 21.4.4): Histology photo and illustration of the submandibular gland. Two types cells that are visible in the **submandibular salivary glands**. **Serous cells** produce salivary amylase and lysozyme and are arranged in clusters called **serous acini**. **Mucous cells** are the other cell present and as the name implies, these cells make mucus that helps to lubricate the food. These cells tend to be larger and lighter in color. **Mucous cells** are found in **mucous acini** Secretions from both cell type drain into **salivary ducts**. These are made up of cuboidal epithelium (both simple and stratified).

Submandibular Gland histology photo image Credit:"Submandibular Gland" provided by the Regents of the University of Michigan under a BY-SA-NC Creative Commons license 4.0. Illustration of submandibular gland original work by Gabrielle Spurlock

DISORDER OF THE...

Digestive System: Mumps in Parotid Glands

Infections of the nasal passages and pharynx can attack any salivary gland. The parotid glands are the usual site of infection with the virus that causes mumps (paramyxovirus). Mumps manifests as enlargement and inflammation of the parotid glands, causing a characteristic swelling between the ears and the jaw. Symptoms include fever and throat pain, which can be severe when swallowing acidic substances such as orange juice.

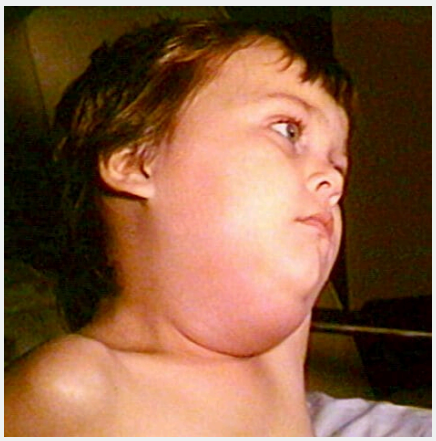

Figure 21.4.5: Child with swelling of the face and neck characteristic of a mumps infection. *(Photo Credit: Content Providers: CDC/NIP/ Barbara Rice, Public domain, via Wikimedia Commons.)*

> In about one-third of men who are past puberty, mumps also causes testicular inflammation, typically affecting only one testis and rarely resulting in sterility. With the increasing use and effectiveness of mumps vaccines, the incidence of mumps has decreased dramatically. According to the U.S. Centers for Disease Control and Prevention (CDC), the number of mumps cases dropped from more than 150,000 in 1968 to fewer than 1700 in 1993 to only 11 reported cases in 2011.

Regulation of Salivation

The autonomic nervous system regulates **salivation** (the secretion of saliva). In the absence of food, parasympathetic stimulation keeps saliva flowing at just the right level for comfort as you speak, swallow, sleep, and generally go about life. Over-salivation can occur, for example, if you are stimulated by the smell of food, but that food is not available for you to eat. Drooling is an extreme instance of the overproduction of saliva. During times of stress, such as before speaking in public, sympathetic stimulation takes over, reducing salivation and producing the symptom of dry oral cavity often associated with anxiety. When you are dehydrated, salivation is reduced, causing the oral cavity to feel dry and prompting you to take action to quench your thirst.

Salivation can be stimulated by the sight, smell, and taste of food. It can even be stimulated by thinking about food. You might notice whether reading about food and salivation right now has had any effect on your production of saliva.

How does the salivary process work while you are eating? Food contains chemicals that stimulate taste receptors on the tongue, which send impulses to the superior and inferior salivatory nuclei in the brain stem. These two nuclei then send back parasympathetic impulses through fibers in the glossopharyngeal and facial nerves, which stimulate salivation. Even after you swallow food, salivation is increased to cleanse the oral cavity and to water down and neutralize any irritating chemical remnants, such as that hot sauce in your burrito. Most saliva is swallowed along with food and is reabsorbed, so that fluid is not lost.

Teeth

The teeth, or **dentes** (singular = dens), are organs similar to bones that you use to tear, grind, and otherwise mechanically break down food.

Types of Teeth

During the course of your lifetime, you have two sets of teeth (one set of teeth is a **dentition**). Your 20 **deciduous teeth**, or baby teeth, first begin to appear at about 6 months of age. Between approximately age 6 and 12, these teeth are replaced by 32 **permanent teeth**. Figure 21.4.5 shows both the deciduous and permanent set of teeth, upper and lower, with the different types of teeth labeled and the age range in which they are seen. Moving from the center of the oral cavity toward the side, these are as follows:

- The eight **incisors**, four top and four bottom, are the sharp front teeth you use for biting into food.
- The four **cuspids** (or canines) flank the incisors and have a pointed edge (cusp) to tear up food. These fang-like teeth are superb for piercing tough or fleshy foods.
- Posterior to the cuspids are the eight **premolars** (or bicuspids), which have an overall flatter shape with two rounded cusps useful for mashing foods.
- The most posterior and largest are the 12 **molars**, which have several pointed cusps used to crush food so it is ready for swallowing. The third members of each set of three molars, top and bottom, are commonly referred to as the wisdom teeth, because their eruption is commonly delayed until early adulthood. It is not uncommon for wisdom teeth to fail to erupt; that is, they remain impacted. In these cases, the teeth are typically removed by orthodontic surgery.

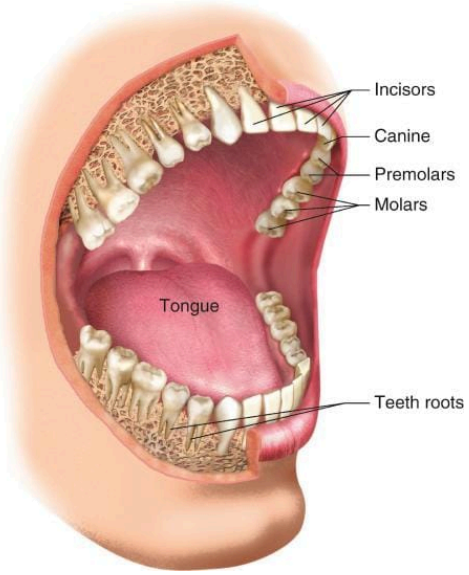

Figure 21.4.6: Permanent Teeth. This figure of human dentition shows the arrangement of teeth in the maxilla and mandible. *(Image credit: "KnowledgeWorks - Drawing Teeth and structures of the oral cavity - English labels" by KnowledgeWorks Global Ltd., is licensed under CC BY. Modification of labels by Jennifer Lange.)*

Pharynx

The **pharynx** (throat) is involved in both digestion and respiration. It receives food and air from the oral cavity, and air from the nasal cavities. When food enters the pharynx, involuntary muscle contractions close off the air passageways and the swallowing reflex is initiated by multiple cranial nerves.

A short tube of skeletal muscle lined with a mucous membrane, the pharynx runs from the posterior oral and nasal cavities to the opening of the esophagus and larynx. There are three subdivisions of the pharynx. The most superior, the **nasopharynx**, is involved only in breathing and speech. The other two subdivisions, the **oropharynx** and the **laryngopharynx**, are used for both breathing and digestion. The oropharynx begins inferior to the nasopharynx and is continuous below with the laryngopharynx (Figure 21.4.7). The oropharynx is separated from the oral cavity by the uvula. The inferior border of the laryngopharynx connects to the esophagus, whereas the anterior portion connects to the larynx, allowing air to flow into the bronchial tree. Figure 21.4.7 also shows the epiglottis and glottis to signal the beginning of the larynx.

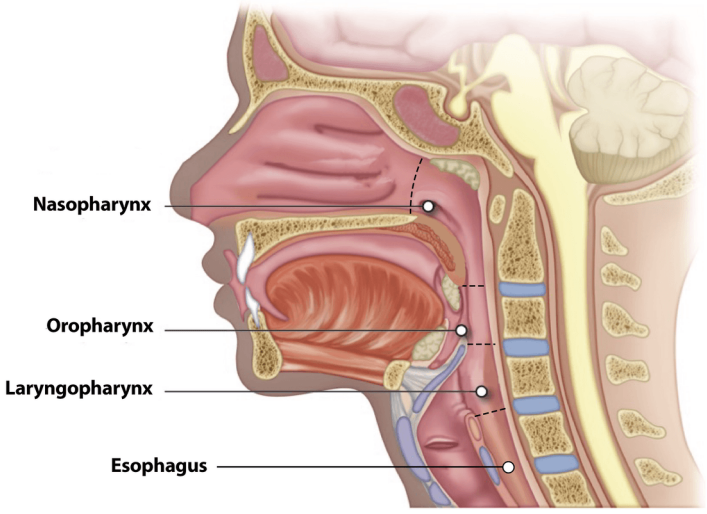

Figure 21.4.7: Pharynx. The pharynx runs from the nasal cavity to the esophagus and the larynx. The region posterior to the nasal cavity is called the nasopharynx. When you swallow, the uvula and soft plate lift to close off the nasopharynx. Inferior to the nasopharynx and posterior to the oral cavity is the oropharynx. The laryngopharynx is posterior to the larynx and superior to the esophagus. *(Image credit: "KnowledgeWorks - Drawing Parts of the pharynx - English labels" at AnatomyTOOL.org is licensed under CC BY 4.0. Modifications by Jennifer Lange.)*

Histologically, the wall of the oropharynx is similar to that of the oral cavity. The mucosa includes a stratified squamous epithelium that is endowed with mucus-producing glands. During swallowing, the elevator skeletal muscles of the pharynx contract, raising and expanding the pharynx to receive the bolus of food. Once received, these muscles relax and the constrictor muscles of the pharynx contract, forcing the bolus into the esophagus and initiating peristalsis.

Usually during swallowing, the soft palate and uvula rise reflexively to close off the entrance to the nasopharynx. At the same time, the larynx is pulled superiorly and the cartilaginous epiglottis, its most superior structure, folds inferiorly, covering the glottis (the opening to the larynx); this process effectively blocks access to the trachea and bronchi. When the food “goes down the wrong way,” it goes into the trachea. When food enters the trachea, the reaction is to cough, which usually forces the food up and out of the trachea, and back into the pharynx.

Esophagus

The **esophagus** is a muscular tube that connects the pharynx to the stomach. It is approximately 25.4 cm (10 in) in length, located posterior to the trachea, and remains in a collapsed form when not engaged in swallowing (Figure 21.4.8) The esophagus runs a mainly straight route through the mediastinum of the thorax. To enter the abdomen, the esophagus penetrates the diaphragm through an opening called the esophageal hiatus. The esophagus has two sphincters: the upper esophageal sphincter at the inferior border of the laryngopharynx and the lower esophageal sphincter by the diaphragm.

Passage of Food through the Esophagus

The **upper esophageal sphincter**, which is continuous with the inferior pharyngeal constrictor, controls the movement of food from the pharynx into the esophagus. The upper two-thirds of the esophagus consists of both smooth and skeletal muscle fibers, with the latter fading out in the bottom third of the esophagus. Rhythmic waves of peristalsis, which begin in the upper esophagus, propel the bolus of food toward the stomach. Meanwhile, secretions from the esophageal mucosa lubricate the esophagus and food. Food passes from the esophagus into the stomach at the **lower esophageal sphincter** (also called the gastroesophageal or cardiac sphincter). Recall that sphincters are muscles that surround tubes and serve as valves, closing the tube when the sphincters contract and opening it when they relax. In the alimentary canal, involuntary sphincters are created by a thickening of the circular layer of the muscularis externa. The lower esophageal sphincter relaxes to let food pass into the stomach, and then contracts to prevent stomach acids from backing up into the esophagus. Surrounding this sphincter is the muscular diaphragm (the opening is the esophageal hiatus), which helps close off the sphincter when no food is being swallowed. When the lower esophageal sphincter does not completely close, the stomach’s contents can reflux (that is, back up into the esophagus), causing

heartburn or gastroesophageal reflux disease (GERD).

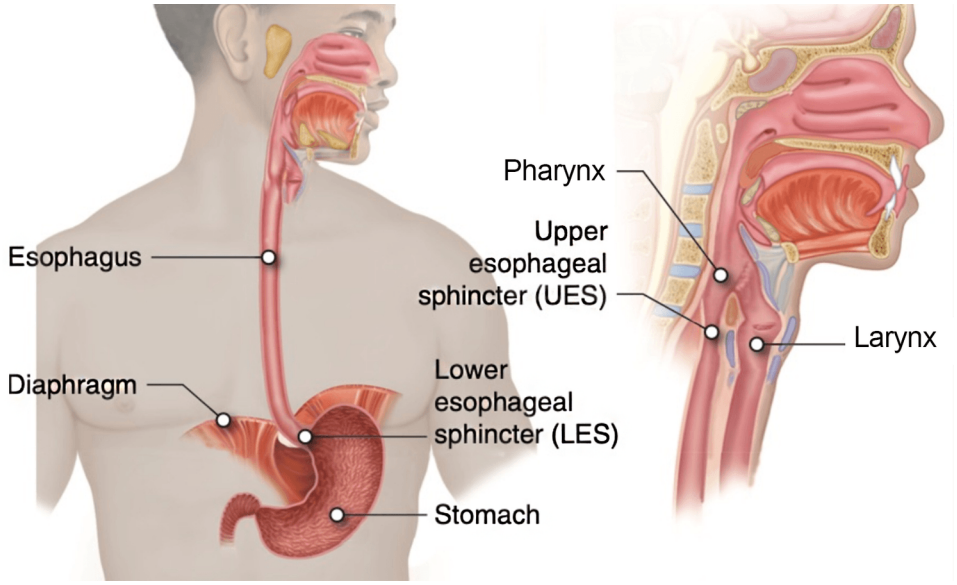

Figure 21.4.8: Esophagus. The upper esophageal sphincter controls the movement of food from the pharynx to the esophagus. The lower esophageal sphincter controls the movement of food from the esophagus to the stomach. *(Image credit: "KnowledgeWorks - Drawing Oesophagus: upper and lower oesophageal sphincters - English labels" by KnowledgeWorks Global Ltd., is licensed under CC BY 4.0. Modifications by Jennifer Lange.)*

Histology of the Esophagus

The mucosa of the esophagus is made up of an epithelial lining that contains non-keratinized, stratified squamous epithelium, with a layer of basal and parabasal cells. This epithelium protects against erosion from food particles. The mucosa's lamina propria contains mucus-secreting glands. The muscularis layer changes according to location: In the upper third of the esophagus, the muscularis is skeletal muscle. In the middle third, it is both skeletal and smooth muscle. In the lower third, it is smooth muscle. As mentioned previously, the most superficial layer of the esophagus is called the adventitia, not the serosa. In contrast to the stomach and intestines, the connective tissue of the adventitia is not covered by a fold of visceral peritoneum (Figure 21.4.9a and b).

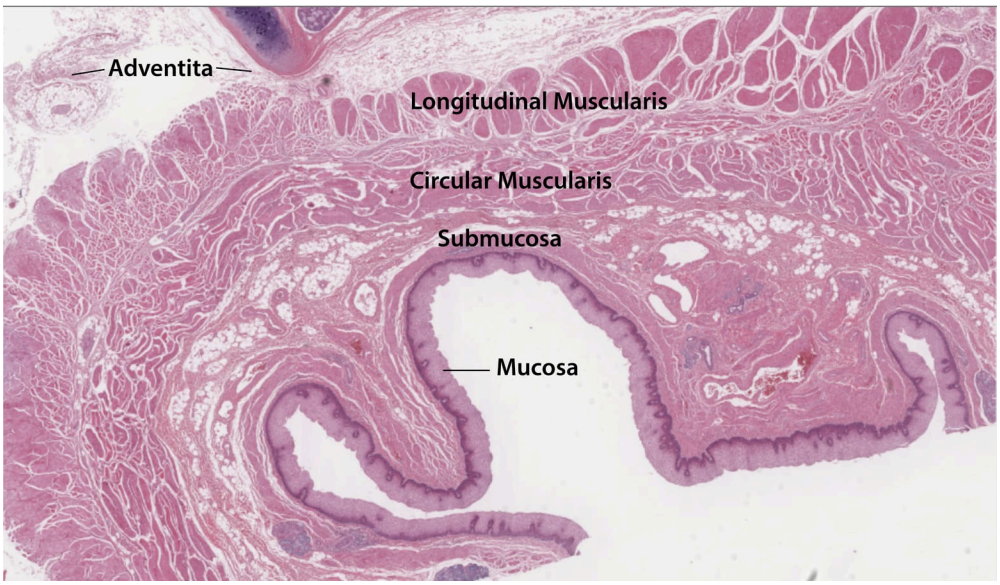

Figure 21.4.9a: Histology of the esophagus. The non-keratinized stratified squamous that makes up the **mucosal layer** is on the bottom portion of the picture and has a dark purple border with the submucosal layer. The **submucosal layer** has numerus blood vessels, nerves and glands. You can also see some adipose tissue in it. The **muscularis** has 2 layers. The **circular muscularis borders** the **submucosal layer** and the **longitudinal muscularis** is outside of this. Lastly, the **adventitia** surrounds the esophagus. *Image Credit: "Esophagus" provided by the Regents of the University of Michigan under a BY-SA-NC Creative Commons license 4.0. Labelling by Gabrielle Spurlock.*

Concept Review

In the oral cavity, the tongue and the teeth begin mechanical digestion, and saliva begins chemical digestion and helps form the bolus, and protects the oral cavity. The pharynx, which plays roles in breathing and vocalization as well as digestion, runs from the nasal and oral cavities superiorly to the esophagus inferiorly (for digestion) and to the larynx anteriorly (for respiration). During deglutition (swallowing), the soft palate rises to close off the nasopharynx, the larynx elevates, and the epiglottis folds over the glottis. The esophagus includes an upper esophageal sphincter made of skeletal muscle, which regulates the movement of food from the pharynx to the esophagus. It also has a lower esophageal sphincter, made of smooth muscle, which controls the passage of food from the esophagus to the stomach. Cells in the esophageal wall secrete mucus that eases the passage of the food bolus.

Review Questions

Query 21.4.1

This interactive element is not available in this format. Visit the link or scan the QR code to access it online.

View this Interactive Content online

Critical Thinking Questions

Query 21.4.2

This interactive element is not available in this format. Visit the link or scan the QR code to access it online.

View this Interactive Content online

Query 21.4.3

This interactive element is not available in this format. Visit the link or scan the QR code to access it online.

View this Interactive Content online

Query 21.4.4

This interactive element is not available in this format. Visit the link or scan the QR code to access it online.

View this Interactive Content online

Query 21.4.5

This interactive element is not available in this format. Visit the link or scan the QR code to access it online.

View this Interactive Content online

Query 21.4.6

This interactive element is not available in this format. Visit the link or scan the QR code to access it online.

View this Interactive Content online

References

van Loon FPL, Holmes SJ, Sirotkin B, Williams W, Cochi S, Hadler S, Lindegren ML. Morbidity and Mortality Weekly Report: Mumps

surveillance -- United States, 1988–1993 [Internet]. Atlanta, GA: Center for Disease Control; [cited 2013 Apr 3]. Available from: http://www.cdc.gov/mmwr/preview/mmwrhtml/00038546.htm.

Glossary

Query 21.4.7

This interactive element is not available in this format. Visit the link or scan the QR code to access it online.

View this Interactive Content online

Contributors and Attributions

- OpenStax Anatomy & Physiology (CC BY 4.0). Access for free at https://openstax.org/books/anatomy-and-physiology

This page titled 21.4: Mouth, Pharynx, and Esophagus is shared under a CC BY-NC-SA 4.0 license and was authored, remixed, and/or curated by Jennifer Lange et al..

- 21.4: Mouth, Pharynx, and Esophagus by Whitney Menefee, Julie Jenks, Chiara Mazzasette, and Kim-Leiloni Nguyen is licensed CC BY 4.0.

21.5: Stomach

By the end of the section, you will be able to:

- Label on a diagram the four main regions of the stomach, its curvatures, and its sphincter
- Identify the four main types of secreting cells in gastric glands, and their important products
- Explain why the stomach does not digest itself
- Describe the mechanical and chemical digestion of food entering the stomach

Although a minimal amount of carbohydrate digestion occurs in the mouth, chemical digestion really gets underway in the stomach. An expansion of the alimentary canal that lies immediately inferior to the esophagus, the stomach links the esophagus to the first part of the small intestine (the duodenum) and is relatively fixed in place at its esophageal and duodenal ends. In between, however, it can be a highly active structure, contracting and continually changing position and size. These contractions provide mechanical assistance to digestion. The empty stomach is only about the size of your fist, but can stretch to hold as much as 4 liters of food and fluid, or more than 75 times its empty volume, and then return to its resting size when empty. Although you might think that the size of a person's stomach is related to how much food that individual consumes, body weight does not correlate with stomach size. Rather, when you eat greater quantities of food—such as at holiday dinner—you stretch the stomach more than when you eat less.

Popular culture tends to refer to the stomach as the location where all digestion takes place. Of course, as you have already begun to learn, this is not true; the bulk of digestion occurs in the small intestine. An important function of the stomach is to serve as a temporary holding chamber. You can ingest a meal far more quickly than it can be digested and absorbed by the small intestine. Thus, the stomach holds food and parses only small amounts into the small intestine at a time. Foods are not processed in the order they are eaten; rather, they are mixed together with digestive juices in the stomach until they are converted into chyme, which is released into the small intestine.

As you will see in the sections that follow, the stomach plays several important roles in chemical digestion, including the continued digestion of carbohydrates and the initial digestion of proteins and triglycerides. Little,if any, nutrient absorption occurs in the stomach, with the exception of the negligible amount of nutrients in alcohol.

Structure

There are four main regions in the **stomach**: the cardia, fundus, body, and pylorus (Figure 21.5.1). It is unique with three layers of the muscularis externa: outer longitudinal layer, middle circular layer, and inner oblique layer. The **cardia** (or cardiac region) is the point where the esophagus connects to the stomach and through which food passes into the stomach. Located inferior to the diaphragm, above and to the left of the cardia, is the dome-shaped **fundus**. Below the fundus is the **body**, the main part of the stomach. The funnel-shaped **pylorus** connects the stomach to the duodenum. The wider end of the funnel, the **pyloric antrum**, connects to the body of the stomach. The narrower end is called the **pyloric canal**, which connects to the duodenum. The smooth muscle **pyloric sphincter** is located at this latter point of connection and controls stomach emptying. In the absence of food, the stomach deflates inward, and its mucosa and submucosa fall into large folds called **rugae**.

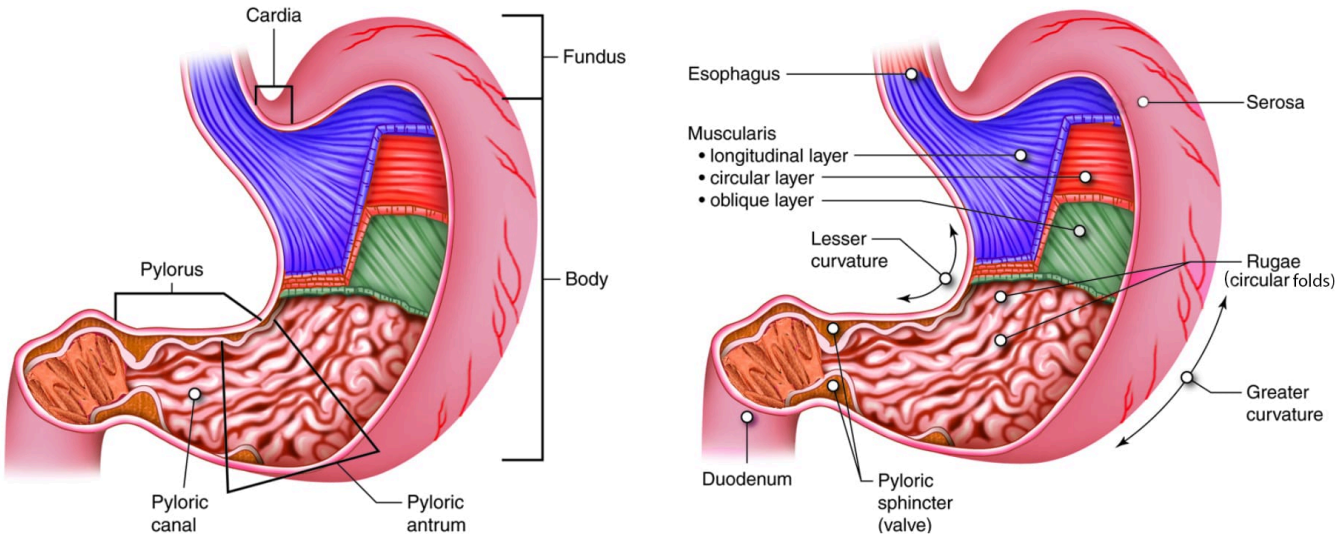

Figure 21.5.1: Stomach. The stomach has four major regions: the cardia, fundus, body, and pylorus. The addition of an inner oblique smooth muscle layer gives the muscularis the ability to vigorously churn and mix food. (Image credit: "Layers of the Stomach" by "KnowledgeWorks - Drawing Abdominal organs - no labels" by KnowledgeWorks Global Ltd. and Open Learning Initiative, license: CC BY-NC-SA. Edited by Gabrielle Spurlock)

The convex lateral surface of the stomach is called the greater curvature; the concave medial border is the lesser curvature. The stomach is held in place by the lesser omentum, which extends from the liver to the lesser curvature, and the greater omentum, which runs from the greater curvature, down the anterior abdominal cavity, forming a large, insulating fold and then connecting to the transverse colon.

Histology

The wall of the stomach is made of the same four layers as most of the rest of the alimentary canal, but with adaptations to the mucosa and muscularis for the unique functions of this organ. In addition to the typical circular and longitudinal smooth muscle layers, the muscularis has an inner oblique smooth muscle layer (Figure 21.5.2). As a result, in addition to moving food through the canal, the stomach can vigorously churn food, mechanically breaking it down into smaller particles.

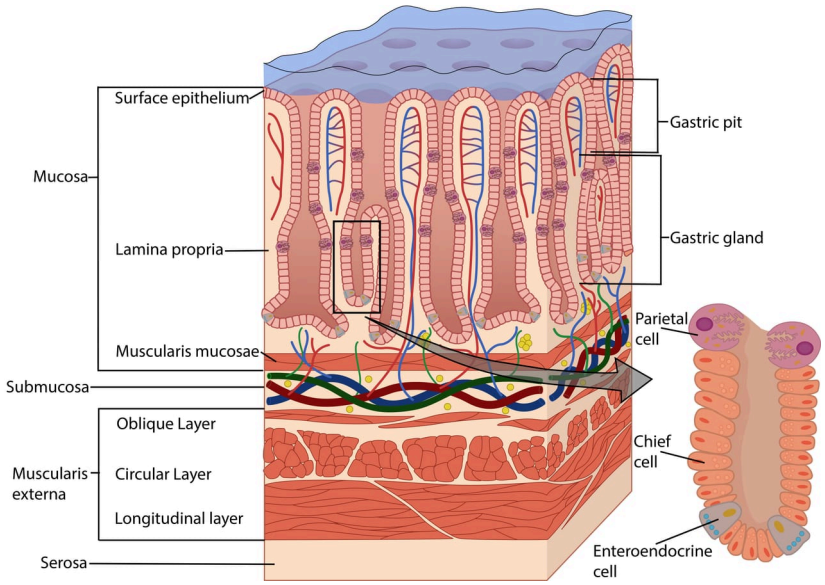

(Figure 21.5.2): Histology of the Stomach. The stomach wall is adapted for the functions of the stomach. In the epithelium, gastric pits lead to gastric glands that secrete gastric juice. The gastric glands (one gland is shown enlarged on the right) contain different types of cells that secrete a variety of enzymes, including hydrochloric acid, which activates the protein-digesting enzyme, pepsin. (Image credit: "Histology of the Stomach" by Collectivedogs is licensed under Creative Commons Attribution-Share Alike 4.0 International license. Labeled by John Polos)

(Figure 21.5.2) also shows the different types of gastric gland in the epithelial lining. The stomach mucosa's simple columnar epithelial lining consists only of surface **mucous cells**, which secrete a protective coat of alkaline mucus. A vast number of **gastric pits** dot the surface of the epithelium, giving it the appearance of a well-used pincushion, and mark the entry to deeper exocrine tubules called **gastric glands**, which secrete a complex digestive fluid referred to as gastric juice.

When viewing the histology slides on scanning power ((Figure 21.5.3) a and b), the mucosal, submucosal, muscularis, and serosal layers are very distinct. The muscularis has numerous gastric pits that are visiable ven under scanning. Similar to the esophagus, a thin lamina propria holds the basement membrane underlining tissue and it has a muscularis mucosae. Likewise, the submucosal layer of the stomach has blood vessels and nerves. As mentioned above, the muscularis has 3 brands of fibers; the inner oblique, the middle circular, and outer longitudinal. Lastly, the stomach is surrounded by the serous which forms part of a serosal membrane.

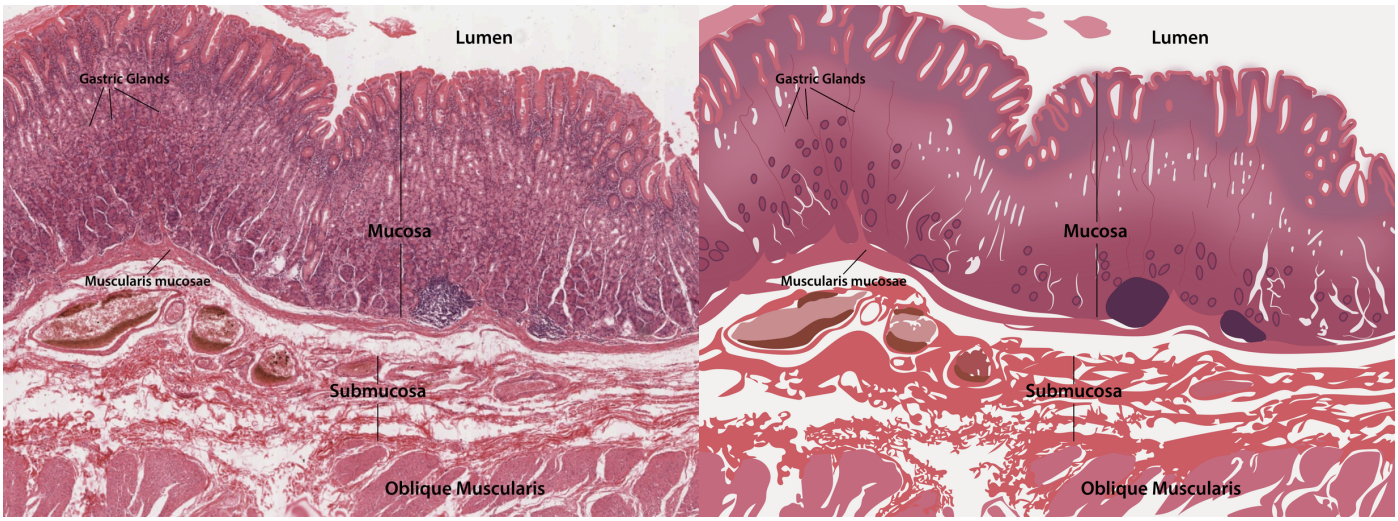

(Figure 21.5.1) Stomach histology on scanning power (40x) showing the layers. Image Credit: Histology photographs (Figure 21.5.3a)provided by the Regents of the University of Michigan under a BY-SA-NC Creative Commons license 4.0. Illustration (Figure 21.5.3b)) original by Gabrielle Spurlock.

Although the walls of the gastric pits are made up primarily of mucous cells, the gastric glands are made up of different types of cells. The glands of the cardia and pylorus are composed primarily of mucus-secreting cells. Cells that make up the pyloric antrum

secrete mucus and a number of hormones, including the majority of the stimulatory hormone, **gastrin**. The much larger glands of the fundus and body of the stomach, the site of most chemical digestion, produce most of the gastric secretions. These glands are made up of a variety of secretory cells. These include parietal cells, chief cells, mucous neck cells, and enteroendocrine cells.

- **Parietal cells**—Located primarily in the middle region of the gastric glands are **parietal cells**, which are among the most highly differentiated of the body's epithelial cells. These relatively large cells produce both **hydrochloric acid (HCl)** and **intrinsic factor**. HCl is responsible for the high acidity (pH 1.5 to 3.5) of the stomach contents and is needed to activate the protein-digesting enzyme, pepsin. The acidity also kills much of the bacteria you ingest with food and helps to denature proteins, making them more available for enzymatic digestion. Intrinsic factor is a glycoprotein necessary for the absorption of vitamin B_{12} in the small intestine.
- **Chief cells**—Located primarily in the basal regions of gastric glands are **chief cells**, which secrete **pepsinogen**, the inactive proenzyme form of pepsin. HCl is necessary for the conversion of pepsinogen to pepsin, an enzyme to digest proteins.
- **Mucous neck cells**—Gastric glands in the upper part of the stomach contain **mucous neck cells** that secrete thin, acidic mucus that is much different from the mucus secreted by the goblet cells of the surface epithelium. The role of this mucus is not currently known.
- **Enteroendocrine cells**—Finally, enteroendocrine cells found in the gastric glands secrete various hormones into the interstitial fluid of the lamina propria. These include gastrin, which is released mainly by enteroendocrine **G cells**.

The mucosa of the stomach is exposed to the highly corrosive acidity of gastric juice. Gastric enzymes that can digest protein can also digest the stomach itself. The stomach is protected from self-digestion by the **mucosal barrier**. This barrier has several components. First, the stomach wall is covered by a thick coating of bicarbonate-rich mucus. This mucus forms a physical barrier, and its bicarbonate ions neutralize acid. Second, the epithelial cells of the stomach's mucosa meet at tight junctions, which block gastric juice from penetrating the underlying tissue layers. Finally, stem cells located where gastric glands join the gastric pits quickly replace damaged epithelial mucosal cells, when the epithelial cells are shed. In fact, the surface epithelium of the stomach is completely replaced every 3 to 6 days.

Table 21.5.1: Hormones Secreted by the Stomach

Hormone	Production site	Production stimulus	Target organ	Action
Gastrin	Stomach mucosa, mainly G cells of the pyloric antrum	Presence of peptides and amino acids in stomach	Gastrointestinal Tract	1. Increases secretions. 2. Increases motility. 3. Causes mass motions of large intestines.
Ghrelin	Stomach mucosa, mainly fundus	Fasting state (levels increase just prior to meals)	Hypothalamus	Regulates food intake, primarily by stimulating hunger and satiety
Histamine	Stomach mucosa	Presence of food in the stomach	Stomach	Stimulates parietal cells to release HCl

DISORDER OF THE...

Digestive System: Ulcers in Mucosal Barrier

As effective as the mucosal barrier is, it is not a "fail-safe" mechanism. Sometimes, gastric juice eats away at the superficial lining of the stomach mucosa, creating erosions, which mostly heal on their own. Deeper and larger erosions are called ulcers.

Why does the mucosal barrier break down? A number of factors can interfere with its ability to protect the stomach lining. The majority of all ulcers are caused by either excessive intake of non-steroidal anti-inflammatory drugs (NSAIDs), including aspirin, or Helicobacter pylori infection.

Antacids help relieve symptoms of ulcers such as "burning" pain and indigestion. When ulcers are caused by NSAID use, switching to other classes of pain relievers allows healing. When caused by H. pylori infection, antibiotics are effective.

A potential complication of ulcers is perforation: Perforated ulcers create a hole in the stomach wall, resulting in peritonitis (inflammation of the peritoneum). These ulcers must be repaired surgically.

Digestive Functions of the Stomach

The stomach participates in virtually all the digestive activities with the exception of ingestion and defecation. Although almost all absorption takes place in the small intestine, the stomach does absorb some nonpolar substances, such as alcohol and aspirin.

Mechanical Digestion

Within a few moments after food after enters your stomach, mixing waves begin to occur at intervals of approximately 20 seconds. A **mixing wave** is a unique type of peristalsis that mixes and softens the food with gastric juices to create chyme. The initial mixing waves are relatively gentle, but these are followed by more intense waves, starting at the body of the stomach and increasing in force as they reach the pylorus. It is fair to say that long before your sushi exits through the pyloric sphincter, it bears little resemblance to the sushi you ate.

The pylorus, which holds around 30 mL (1 fluid ounce) of chyme, acts as a filter, permitting only liquids and small food particles to pass through the mostly, but not fully, closed pyloric sphincter. In a process called **gastric emptying**, rhythmic mixing waves force about 3 mL of chyme at a time through the pyloric sphincter and into the duodenum. Release of a greater amount of chyme at one time would overwhelm the capacity of the small intestine to handle it. The rest of the chyme is pushed back into the body of the stomach, where it continues mixing. This process is repeated when the next mixing waves force more chyme into the duodenum.

Gastric emptying is regulated by both the stomach and the duodenum. The presence of chyme in the duodenum activates receptors that inhibit gastric secretion. This prevents additional chyme from being released by the stomach before the duodenum is ready to process it.

Chemical Digestion

The fundus plays an important role, because it stores both undigested food and gases that are released during the process of chemical digestion. Food may sit in the fundus of the stomach for a while before being mixed with the chyme. While the food is in the fundus, the digestive activities of salivary amylase continue until the food begins mixing with the acidic chyme. Ultimately, mixing waves incorporate this food with the chyme, the acidity of which inactivates salivary amylase and activates lingual lipase. Lingual lipase then begins chemical digestion of lipids, breaking down triglycerides into free fatty acids, and mono- and diglycerides.

The secretion of gastric juice is controlled by both nerves and hormones. Stimuli in the brain, stomach, and small intestine activate or inhibit gastric juice production. This is why the three phases of gastric secretion are called the cephalic, gastric, and intestinal phases. However, once gastric secretion begins, all three phases can occur simultaneously.

The breakdown of protein begins in the stomach through the actions of HCl and the enzyme pepsin. During infancy, gastric glands also produce rennin, an enzyme that helps digest milk protein.

Its numerous digestive functions notwithstanding, there is only one stomach function necessary to life: the production of intrinsic factor. The intestinal absorption of vitamin B_{12}, which is necessary for both the production of mature red blood cells and normal neurological functioning, cannot occur without intrinsic factor. People who undergo total gastrectomy (stomach removal)—for life-threatening stomach cancer, for example—can survive with minimal digestive dysfunction if they receive vitamin B_{12} injections.

The contents of the stomach are completely emptied into the duodenum within 2 to 4 hours after you eat a meal. Different types of food take different amounts of time to process. Foods heavy in carbohydrates empty fastest, followed by high-protein foods. Meals with a high triglyceride content remain in the stomach the longest. Since enzymes in the small intestine digest fats slowly, food can stay in the stomach for 6 hours or longer when the duodenum is processing fatty chyme. However, note that this is still a fraction of the 24 to 72 hours that full digestion typically takes from start to finish.

Concept Review

The stomach is a curved organ that connects the esophagus to the small intestine. It has a greater curvature and lesser curvature and can expand because of rugae. There are four main regions in the stomach: the cardia, fundus, body, and pylorus. The mucosa has gastric pits that lead to gastric glands that secrete gastric juices, comprised of mucus, acid, and different proteins to aid

in digestion. The muscularis externa has an additional layer, the oblique smooth muscle layer to aid in churning of chyme. The stomach participates in all digestive activities except ingestion and defecation. The stomach begins the digestion of protein and continues the digestion of carbohydrates and fats. It stores food as chyme, and releases it gradually into the small intestine through the pyloric sphincter. It absorbs certain drugs, including aspirin and some alcohol.

Review Questions

Query 21.5.1

This interactive element is not available in this format. Visit the link or scan the QR code to access it online.

View this Interactive Content online

Critical Thinking Questions

Query 21.5.2

This interactive element is not available in this format. Visit the link or scan the QR code to access it online.

View this Interactive Content online

Query 21.5.3

This interactive element is not available in this format. Visit the link or scan the QR code to access it online.

View this Interactive Content online

Glossary

Query 21.5.4

This interactive element is not available in this format. Visit the link or scan the QR code to access it online.

View this Interactive Content online

Contributors and Attributions

- OpenStax Anatomy & Physiology (CC BY 4.0). Access for free at https://openstax.org/books/anatomy-and-physiology

This page titled 21.5: Stomach is shared under a CC BY-NC-SA 4.0 license and was authored, remixed, and/or curated by Jennifer Lange et al..

- 21.5: Stomach by Whitney Menefee, Julie Jenks, Chiara Mazzasette, and Kim-Leiloni Nguyen is licensed CC BY 4.0.

21.6: Small and Large Intestines

By the end of the section, you will be able to:

- Compare and contrast the location and gross anatomy of the small and large intestines
- Identify three main adaptations of the small intestine wall that increase its absorptive capacity
- Describe the structures responsible for the mechanical and chemical digestion of chyme upon its release into the small intestine
- List three features unique to the wall of the large intestine and identify their contributions to its function
- Identify the beneficial roles of the bacterial flora in digestive system functioning
- Trace the pathway of food waste from its point of entry into the large intestine through its exit from the body as feces

The word intestine is derived from a Latin root meaning “internal,” and indeed, the two organs together nearly fill the interior of the abdominal cavity. In addition, called the small and large bowel, or colloquially the “guts,” they constitute the greatest mass and length of the alimentary canal and, with the exception of ingestion, perform all digestive system functions.

Small Intestine

Chyme released from the stomach enters the **small intestine**, which is the primary digestive organ in the body. Not only is this where most digestion occurs, it is also where practically all absorption occurs. The longest part of the alimentary canal, the small intestine is about 3.05 meters (10 feet) long in a living person (but about twice as long in a cadaver due to the loss of muscle tone). Since this makes it about five times longer than the large intestine, you might wonder why it is called “small.” In fact, its name derives from its relatively smaller diameter of only about 2.54 cm (1 in), compared with 7.62 cm (3 in) for the large intestine. As we’ll see shortly, in addition to its length, the folds and projections of the lining of the small intestine work to give it an enormous surface area, which is approximately 200 m^2, more than 100 times the surface area of your skin. This large surface area is necessary for complex processes of digestion and absorption that occur within it.

Structure

The coiled tube of the small intestine is subdivided into three regions. From proximal (at the stomach) to distal, these are the duodenum, jejunum, and ileum (Figure 21.6.1).

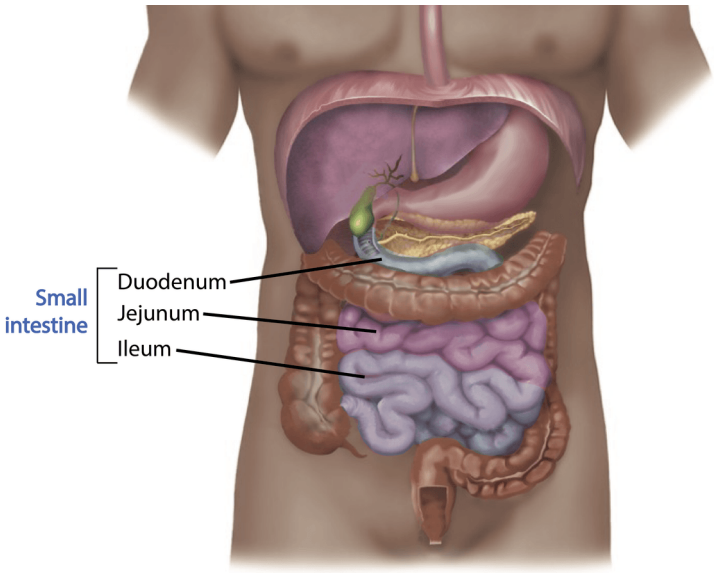

Figure 21.6.1: Small Intestine. The three regions of the small intestine are the duodenum, jejunum, and ileum. *(Image credit: "Regions of the Small Intestine" by Jennifer Lange is licensed under CC BY-NC-SA, modification of original "Drawing of Abdominal Organs" by KnowledgeWorks Global Ltd. and Open Learning Initiative.)*

The shortest region is the 25.4-cm (10-in) **duodenum** (Figure 21.6.2), which begins at the pyloric sphincter. Just past the pyloric sphincter, it bends posteriorly behind the peritoneum, becoming retroperitoneal, and then makes a C-shaped curve around the head of the pancreas before ascending anteriorly again to return to the peritoneal cavity and join the jejunum. Located in the duodenal wall, the ampulla is where the bile duct (through which bile passes from the liver) and the **main pancreatic duct**. This ampulla opens into the duodenum at the **major duodenal papilla**.

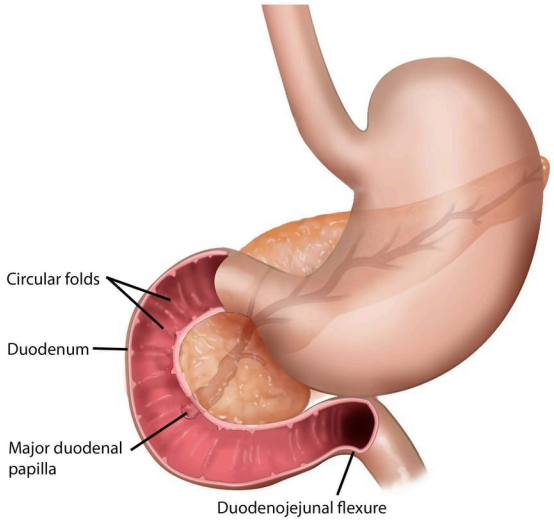

Figure 21.6.2: The Duodenum. The duodenum is the first region of the small intestine. *(Image credit: "Leiden - Drawing Stomach, duodenum, pancreas - no labels" by Ron Slagter is licensed under CC BY-NC-SA; labeled by John Polos.)*

The **jejunum** is about 0.9 meters (3 feet) long (in life) and runs from the duodenum to the ileum. Jejunum means "empty" in Latin and supposedly was so named by the ancient Greeks who noticed it was always empty at death. No clear demarcation exists between the jejunum and the final segment of the small intestine, the ileum.

The **ileum** is the longest part of the small intestine, measuring about 1.8 meters (6 feet) in length. It is thicker, more vascular, and has more developed mucosal folds than the jejunum. The ileum joins the cecum, the first portion of the large intestine, at the **ileocecal sphincter** (or valve). The jejunum and ileum are tethered to the posterior abdominal wall by the mesentery. The large intestine frames these three parts of the small intestine.

Parasympathetic fibers from the vagus nerve and sympathetic nerve fibers provide innervation to the small intestine. The superior mesenteric artery is its main arterial supply. Veins run parallel to the arteries and drain into the superior mesenteric vein. Nutrient-rich blood from the small intestine is then carried to the liver via the hepatic portal vein.

Histology

The wall of the small intestine is composed of the same four layers typically present in the digestive tract wall. However, three features of the mucosa and submucosa are unique. These features, which increase the absorptive surface area of the small intestine more than 600 times, include **circular folds** (**plicae circulares**), **villi**, and **microvilli** (Figure 21.6.3). These adaptations are most abundant in the proximal two-thirds of the small intestine, where the majority of absorption occurs.

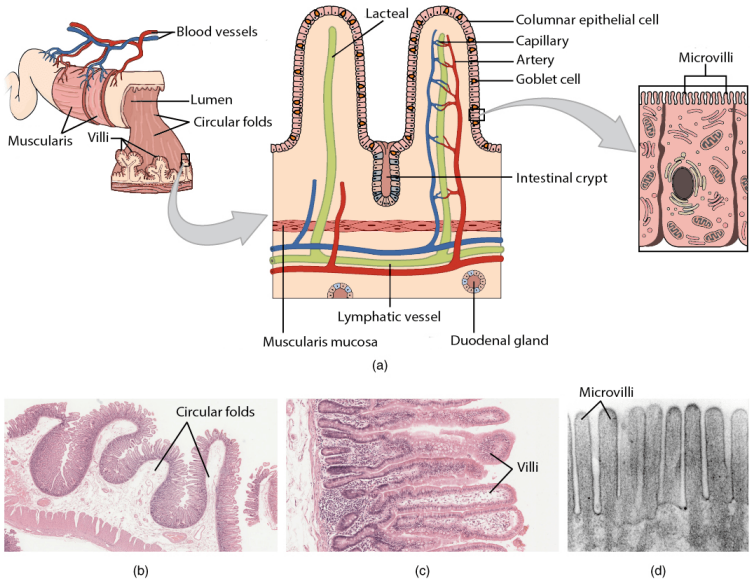

Figure 21.6.3: Histology of the Small Intestine. The absorptive surface of the small intestine is vastly enlarged by the presence of circular folds, villi, and microvilli. (b) Micrograph of the circular folds (LM @ 56x). (c) Micrograph of the villi (LM @ 504x). (d) Electron micrograph of the microvilli (EM @ 196,000x). *(Image credits: "Histology of the Small Intestine Illustration" by Jennifer Lange is licensed under CC BY-NC-SA 4.0, modification of original by OpenStax; slides b-d provided by the Regents of the University of Michigan Medical School © 2022.)*

Circular folds

Also called a plica circulare, a **circular fold** is a tall ridge in the mucosa and submucosa (Figure 21.6.3 and Figure 21.6.4). These folds form transverse ridges that can be up to 1 cm in depth and are visible to the naked eye. Beginning near the proximal part of the duodenum and ending near the middle of the ileum, these folds facilitate absorption by increasing the surface area. Additionally, their shape causes the chyme to spiral rather than move in a straight line through the small intestine. This spiraling slows the movement of chyme and provides the time needed for nutrients to be fully absorbed.

Villi

Within the circular folds are small (0.5–1 mm long) hairlike vascularized projections of the epithelium and lamina propria called **villi** (singular = villus) that give the mucosa a furry texture (Figure 21.6.3 and Figure 21.6.4). There are about 20 to 40 villi per square millimeter, increasing the surface area of the epithelium tremendously. The mucosal simple columnar epithelium, primarily composed of absorptive cells, covers the villi. In addition to muscle and connective tissue to support its structure, each villus contains a capillary bed composed of one arteriole and one venule, as well as a lymphatic capillary called a **lacteal**. The breakdown products of carbohydrates and proteins (sugars and amino acids) can enter the bloodstream directly, but lipid breakdown products are absorbed by the lacteals and transported to the bloodstream via the lymphatic system.

Microvilli

As their name suggests, **microvilli** (singular = microvillus) are much smaller (1 μm) than villi (Figure 21.6.3). They are cylindrical apical surface extensions of the plasma membrane of the mucosa's epithelial cells, and are supported by microfilaments within those cells. Although their small size makes it difficult to see each microvillus, their combined microscopic appearance suggests a mass of bristles, which is termed the **brush border**. Fixed to the surface of the microvilli membranes are enzymes that finish digesting carbohydrates and proteins and in some cases transporter proteins to aid in digestion. There are an estimated 200 million microvilli per square millimeter of small intestine, greatly expanding the surface area of the plasma membrane and thus greatly enhancing absorption.

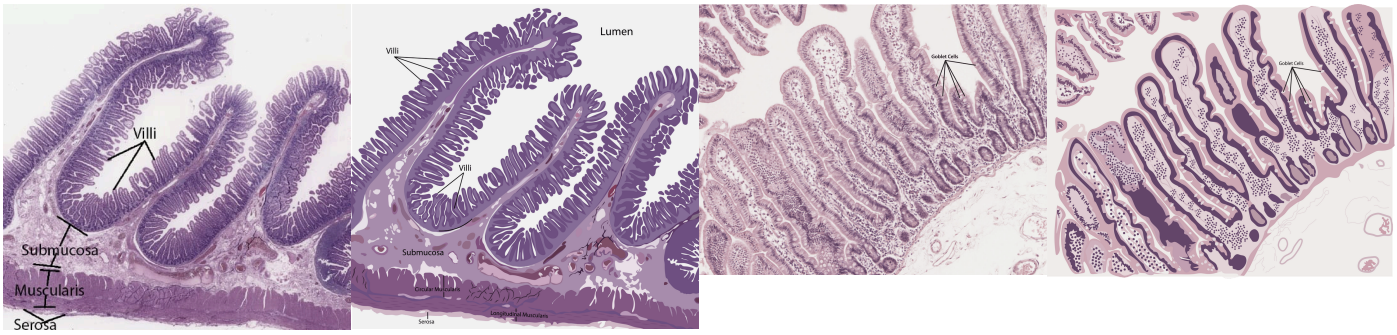

Figure 21.6.4: Jejunum histology. Under scanning power you can clearly see the layers of the wall of the jejunum and the prominent villi. When you magnify to high power you can see mucus producing goblet cells mixed in with the columnar cells of the epithelium. *(Image Credit: Histology photographs (left, top and bottom) provided by the Regents of the University of Michigan under a BY-SA-NC Creative Commons license 4.0. Illustration (right top and bottom) original work by Gabrielle Spurlock.)*

Intestinal Glands

In addition to the three specialized absorptive features just discussed, the mucosa between the villi is dotted with deep crevices that each lead into a tubular **intestinal gland** (crypt of Lieberkühn), which is formed by cells that line the crevices. These produce **intestinal juice**, a slightly alkaline (pH 7.4 to 7.8) mixture of water and mucus. Each day, about 0.95 to 1.9 liters (1 to 2 quarts) are secreted in response to the distention of the small intestine or the irritating effects of chyme on the intestinal mucosa. In addition to the exocrine glands making intestinal juice, there are enteroendocrine cells to secrete many regulatory hormones that communicate with other digestive organs including the pancreas and gallbladder.

The submucosa of the duodenum is the only site of the complex mucus-secreting **duodenal glands** (Brunner's glands), which produce a bicarbonate-rich alkaline mucus that buffers the acidic chyme as it enters from the stomach.

Lymphatic Nodules

The lamina propria of the small intestine mucosa is studded with mucosa associated lymphoid tissue (MALT). In addition to solitary lymphatic nodules, aggregations of intestinal MALT, which are typically referred to as **Peyer's patches**, are concentrated in the distal ileum where they serve to keep bacteria from entering the bloodstream. Peyer's patches are most prominent in young people and become less distinct as you age, which coincides with the general activity of our immune system (Figure 21.6.5).

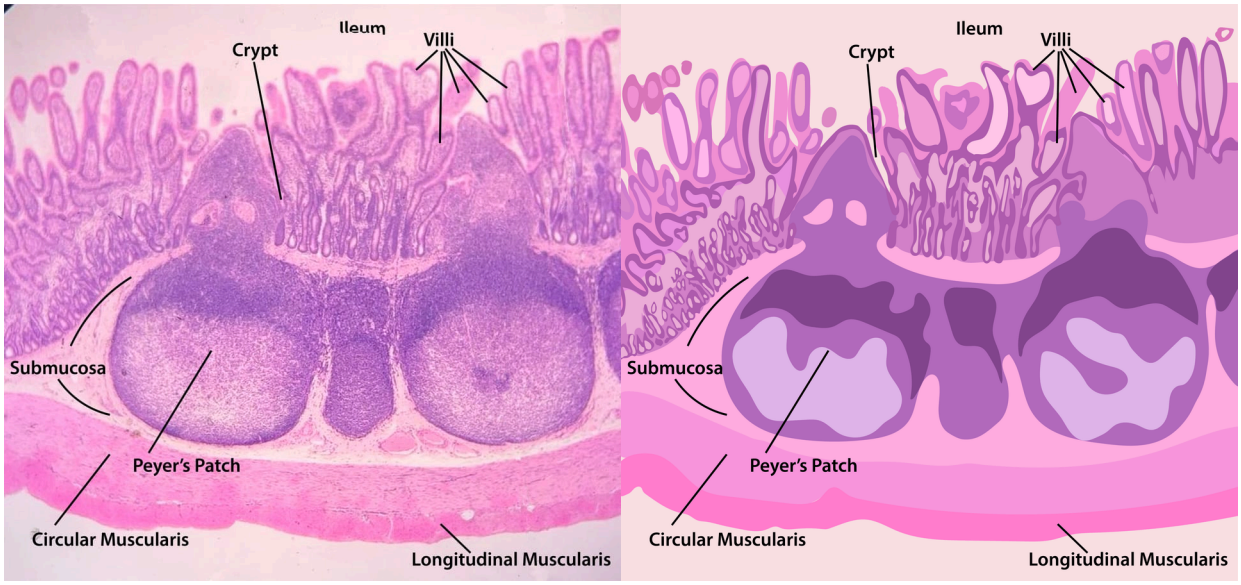

Figure 21.6.5: Histology of the Ileum. Histology photograph showing the ileum and an illustration of the ileum. **Peyer's patches** are found between the epithelial layer, which is called the **mucosa**, and the muscular layer, which is called the **muscularis**, in a layer called the **submucosal**. Similar to the **nodules** in the **lymph node**, you can see in the picture to the left the 2 different tissues within the **Peyer's patches**. The T cells are on the outside while the B cells are inside (called the **germinal center**). *Histology photo by John Polos and edited by Gabrielle Spurlock. Illustration of ileum histology original work by Gabrielle Spurlock.*

Visualizing the Intestine: Colonoscopy

This video shows a part of a colonoscopy, with normal anatomy: it starts in the terminal ileum, where the circular folds and the intestinal villi can be seen and are clearly indicated. Then the scope is gradually retracted, passing the ileocaecal junction to arrive in the caecum. In the ascending colon the semilunar folds can be seen and are indicated, one can also see the absence of villi here.

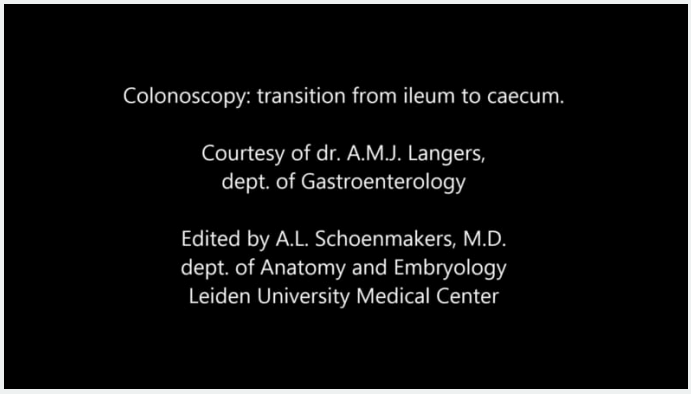

("Leiden - Video Colonoscopy: transition from ileum to caecum - English labels" by Alexandra M.J. Langers, LUMC and Alieke L. Schoenmakers, LUMC, license: CC BY-NC-SA.)

Digestive Functions of the Small Intestine

Mechanical Digestion

The movement of intestinal smooth muscles includes both segmentation and a form of peristalsis called migrating motility complexes. The kind of peristaltic mixing waves seen in the stomach are not observed here.

If you could see into the small intestine when it was going through segmentation, it would look as if the contents were being

shoved incrementally back and forth, as the rings of smooth muscle repeatedly contract and then relax. Segmentation in the small intestine does not force chyme through the tract. Instead, it combines the chyme with digestive juices and pushes food particles against the mucosa to be digested and absorbed. The duodenum is where the most rapid segmentation occurs, at a rate of about 12 times per minute. In the ileum, segmentations are only about eight times per minute. Watch these motions in the video below.

YouTube Video

This interactive element is not available in this format. Visit the link or scan the QR code to access it online.

View this YouTube Video online

When most of the chyme has been absorbed, the small intestinal wall becomes less distended. At this point, the localized segmentation process is replaced by transport movements. The duodenal mucosa secretes the hormone **motilin**, which initiates peristalsis in the form of a **migrating motility complex**. These complexes, which begin in the duodenum, force chyme through a short section of the small intestine and then stop. The next contraction begins a little bit farther down than the first, forces chyme a bit farther through the small intestine, then stops. These complexes move slowly down the small intestine, forcing chyme on the way, taking around 90 to 120 minutes to finally reach the end of the ileum. At this point, the process is repeated, starting in the duodenum.

The ileocecal valve, a sphincter, is usually in a constricted state, but when motility in the ileum increases, this sphincter relaxes, allowing food residue to enter the first portion of the large intestine, the cecum. After chyme passes through, backward pressure helps close the sphincter, preventing backflow into the ileum. Because of this reflex, your lunch is completely emptied from your stomach and small intestine by the time you eat your dinner. It takes about 3 to 5 hours for all chyme to leave the small intestine.

Chemical Digestion

For optimal chemical digestion, chyme must be delivered from the stomach slowly and in small amounts. This is because chyme from the stomach is typically hypertonic (higher concentration than the content in small intestine) and, if large quantities were forced all at once into the small intestine, the resulting osmotic water loss from the blood into the intestinal lumen to dilute the chyme would result in potentially life-threatening low blood volume. In addition, continued digestion requires an upward adjustment of the low pH of stomach chyme, along with rigorous mixing of the chyme with bile and pancreatic juices. Both processes take time, so the pumping action of the pylorus must be carefully controlled to prevent the duodenum from being overwhelmed with chyme.

The digestion of proteins and carbohydrates, which partially occurs in the stomach, is completed in the small intestine with the aid of intestinal and pancreatic secretions:

- enzymes secreted by the pancreas break the fragmented amino acid chains into peptides, which are then split into amino acids by brush border enzymes present in the plasma membrane of the epithelial cells;
- lipids arrive in the duodenum coarsely emulsified (a mixture of water and fat globules), so bile from the liver and gallbladder create a fine emulsion which allows the lipases from the pancreas to break the lipid molecules into free fatty acids and monoglycerides.

DISORDERS OF THE...

Digestive System: Lactose Intolerance

Lactose intolerance is a condition characterized by indigestion caused by dairy products. It occurs when the absorptive cells of the small intestine do not produce enough lactase, the enzyme that digests the milk sugar lactose. In most mammals, lactose intolerance increases with age. In contrast, some human populations, most notably Caucasians, are able to maintain the ability to produce lactase as adults.

In people with lactose intolerance, the lactose in chyme is not digested. Bacteria in the large intestine ferment the undigested lactose, a process that produces gas. In addition to gas, symptoms include abdominal cramps, bloating, and diarrhea. Symptom severity ranges from mild discomfort to severe pain; however, symptoms resolve once the lactose is eliminated in feces.

The hydrogen breath test is used to help diagnose lactose intolerance. Lactose-tolerant people have very little hydrogen in their breath. Those with lactose intolerance exhale hydrogen, which is one of the gases produced by the bacterial fermentation of lactose in the colon. After the hydrogen is absorbed from the intestine, it is transported through blood vessels into the lungs. There are a number of lactose-free dairy products available in grocery stores. In addition, dietary supplements are available. Taken with food, they provide lactase to help digest lactose.

Large Intestine

The **large intestine** is the terminal part of the alimentary canal. The primary function of this organ is to finish absorption of nutrients and water, synthesize certain vitamins, form feces, and eliminate feces from the body.

Structure

The large intestine runs from the appendix to the anus (Figure 21.6.6). It frames the small intestine on three sides. Despite its being about one-half as long as the small intestine, it is called large because it has a diameter that is more than twice the diameter of the small intestine, about 3 inches. The large intestine is subdivided into four main regions: the cecum, the colon, the rectum, and the anus. The ileocecal valve, located at the opening between the ileum and the large intestine, controls the flow of chyme from the small intestine to the large intestine.

Cecum

The first part of the large intestine is the **cecum**, a sac-like structure that is suspended inferior to the ileocecal valve. It is about 6 cm (2.4 in) long, receives the contents of the ileum, and continues the absorption of water and salts. The **appendix** (or vermiform appendix) is a winding, dead-end tube that attaches to the cecum. Although the 7.6-cm (3-in) long appendix contains lymphoid tissue, suggesting an immunologic function, this organ is generally considered vestigial (a structure present in our ancestors that has over time lost its original function). However, at least one recent report postulates a survival advantage conferred by the appendix: in diarrheal illness, the appendix may serve as a bacterial reservoir to repopulate the enteric bacteria for those surviving the initial phases of the illness. Moreover, its twisted anatomy provides a haven for the accumulation and multiplication of enteric bacteria.

Colon

The cecum blends seamlessly with the **colon**. The small intestine is faintly superimposed to show the location of both the large and small intestines. Upon entering the colon, the food residue first travels up the **ascending colon** on the right side of the abdomen. At the inferior surface of the liver, the colon bends to form the **right colic flexure** (hepatic flexure) and becomes the **transverse colon**. The region defined as hindgut begins with the last third of the transverse colon and continues on. Food residue passing through the transverse colon travels across to the left side of the abdomen, where the colon angles sharply immediately inferior to the spleen, at the **left colic flexure** (splenic flexure). From there, food residue passes through the **descending colon**, which runs down the left side of the posterior abdominal wall. After entering the pelvis inferiorly, it becomes the s-shaped **sigmoid colon**, which extends medially to the midline (Figure 21.6.6). The ascending and descending colon, and the rectum (discussed next) are located in the retroperitoneum.

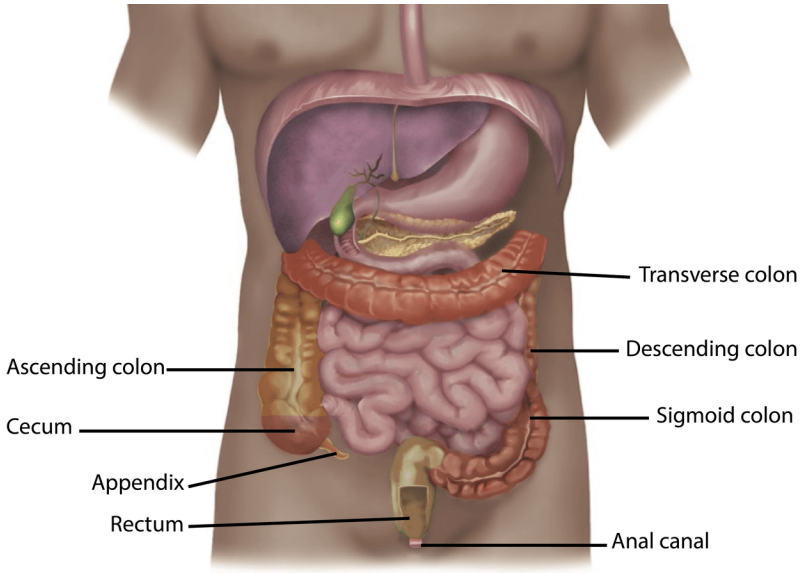

Figure 21.6.6: Large Intestine. The large intestine includes the cecum, colon, and rectum. *(Image credit: "Regions of the Large Intestine" by Jennifer Lange is licensed under CC BY-NC-SA, modification of original "Drawing of Abdominal Organs" by KnowledgeWorks Global Ltd. and Open Learning Initiative.)*

DISORDER OF THE...

Digestive System: Colorectal Cancer

Each year, approximately 140,000 Americans are diagnosed with colorectal cancer, and another 49,000 die from it, making it one of the most deadly malignancies. People with a family history of colorectal cancer are at increased risk. Smoking, excessive alcohol consumption, and a diet high in animal fat and protein also increase the risk. Despite popular opinion to the contrary, studies support the conclusion that dietary fiber and calcium do not reduce the risk of colorectal cancer.

Colorectal cancer may be signaled by constipation or diarrhea, cramping, abdominal pain, and rectal bleeding. Bleeding from the rectum may be either obvious or occult (hidden in feces). Since most colon cancers arise from benign mucosal growths called polyps, cancer prevention is focused on identifying these polyps. The colonoscopy is both diagnostic and therapeutic. Colonoscopy not only allows identification of precancerous polyps, the procedure also enables them to be removed before they become malignant. Screening for fecal occult blood tests and colonoscopy is recommended for those over 50 years of age.

Rectum

Food residue leaving the sigmoid colon enters the **rectum** in the pelvis, near the third sacral vertebra. The final 20.3 cm (8 in) of the alimentary canal, the rectum extends anterior to the sacrum and coccyx. Even though rectum is Latin for "straight," this structure follows the curved contour of the sacrum and has three lateral bends that create a trio of internal transverse folds called the **rectal valves**. These valves help separate the feces from gas to prevent the simultaneous passage of feces and gas.

Anal Canal

Finally, food residue reaches the last part of the large intestine, the **anal canal**, which is located in the perineum, completely outside of the abdominopelvic cavity. This 3.8–5 cm (1.5–2 in) long structure opens to the exterior of the body at the anus. The anal canal includes two sphincters. The **internal anal sphincter** is made of smooth muscle, and its contractions are involuntary. The **external anal sphincter** is made of skeletal muscle, which is under voluntary control. Except when defecating, both usually remain closed.

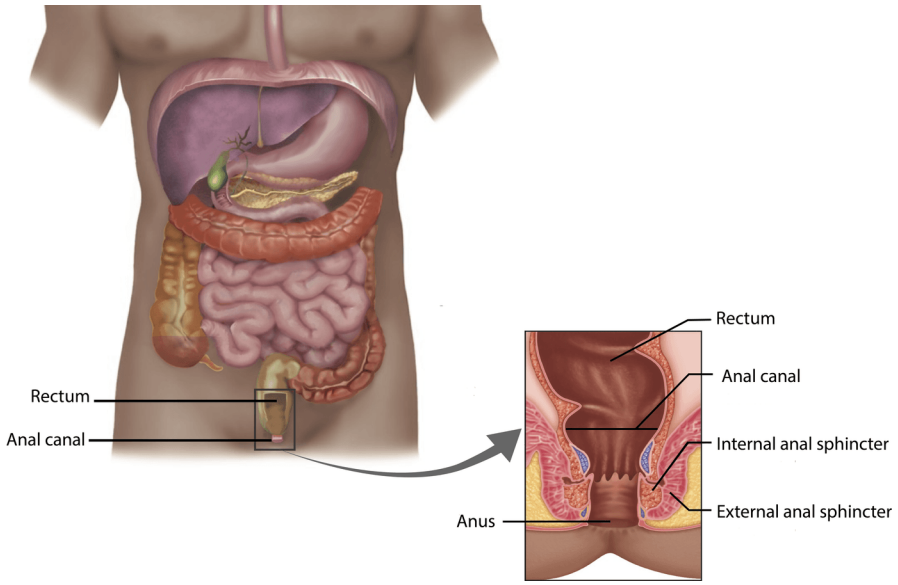

Figure 21.6.7: Anal Canal. The anal canal has two sphincters that regulate its opening. The external anal sphincter contains voluntary skeletal muscle while the internal anal sphincter contains involutatary smooth muscle. *(Image credit: "Anal Canal" by Jennifer Lange is licensed under CC BY-NC-SA, modification of original "Drawing of Abdominal Organs" by KnowledgeWorks Global Ltd. and Open Learning Initiative.)*

Histology

There are several notable differences between the walls of the large and small intestines (Figure 21.6.8 and Figure 21.6.9). For example, few enzyme-secreting cells are found in the wall of the large intestine, and there are no circular folds or villi. Other than in the anal canal, the mucosa of the colon is simple columnar epithelium made mostly of absorptive enterocytes with microvilli and goblet cells. In addition, the mucosa has far more intestinal glands, which contain a vast population of enterocytes and goblet cells. These goblet cells secrete mucus that eases the movement of feces and protects the intestine from the effects of the acids and gases produced by enteric bacteria. The enterocytes absorb water and salts as well as vitamins produced by your intestinal bacteria.

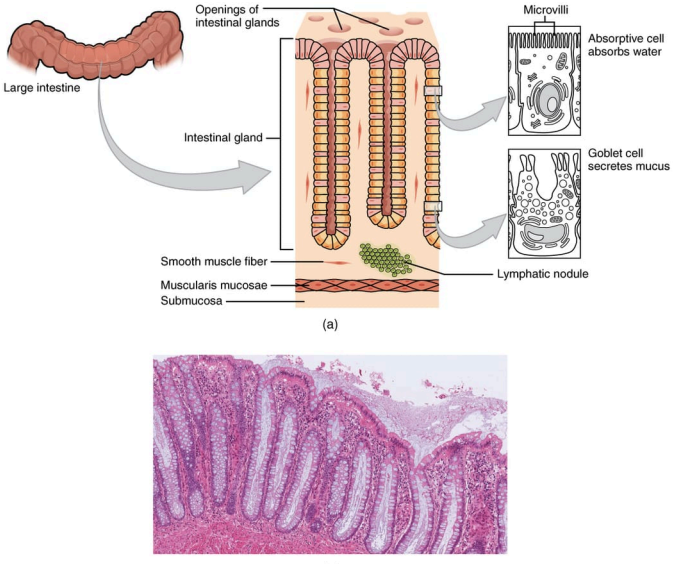

Figure 21.6.8: Histology of the large Intestine. (a) The histologies of the large intestine and small intestine (not shown) are adapted for the digestive functions of each organ. (b) This micrograph shows the colon's simple columnar epithelium and goblet cells. LM x 464. Micrograph provided by the Regents of University of Michigan Medical School © 2012. (Image credit: "Histology of Large Intestine" by OpenStax is licensed under CC BY 3.0)

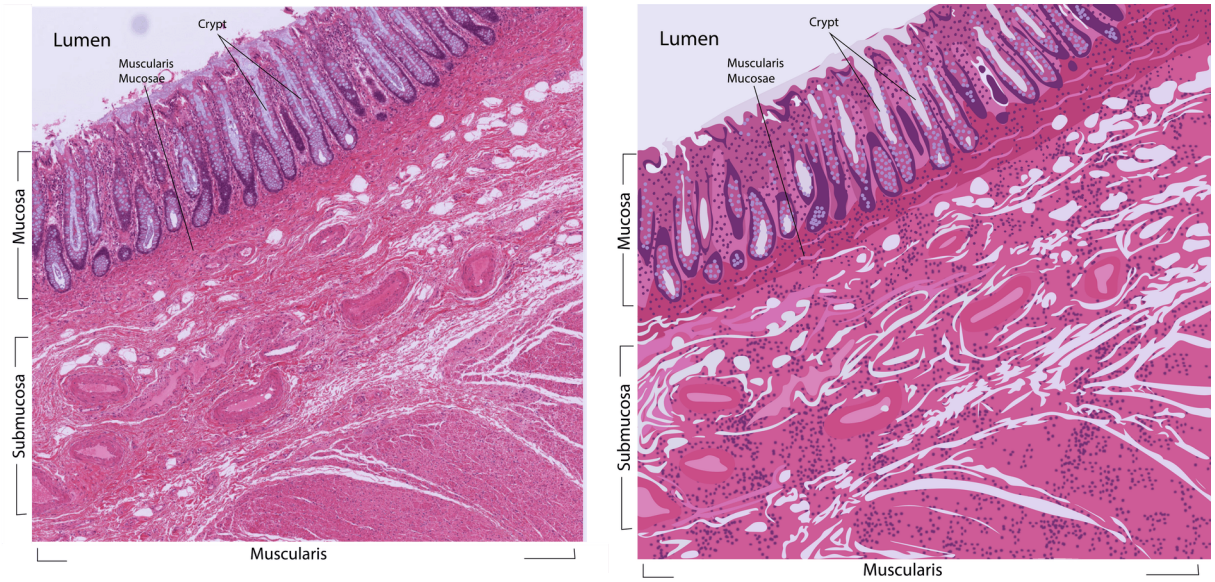

Figure 21.6.9: Low Power Histology of Large Intestine. (Left) Histology photgraph showing the colon and (right) illustration of the colon. The muscularis has deep crypts that are lined with goblet cells. The goblet cells produce a lot of mucus which help lubricate/clump the fecal matter. The crypts also have stem cells in the crypts replace cells lost due to friction from the mucosal layer. Numerous blood vessels and nerves are found in the sub mucosa. Lymph nodules can be observed in the submucosa as well. The muscularis sits below the submucosa. However, the longitudinal layer may be missing depending on where the slide was taken from. (*Micrograph provided by the Regents of University of Michigan Medical School © 2012. (Image credit: "Histology of Large Intestine" by OpenStax is licensed under CC BY 3.0. Illustration of colon histology original work by Gabrielle Spurlock.)*

Structural Features

The **teniae coli** (also spelled taenia) are three bands of smooth muscle that make up the longitudinal muscle layer of the muscularis of the large intestine, except at its terminal end (Figure 21.6.10). The bands are spaced equidistantly around the circumference of the tube. Tonic contractions of the teniae coli bunch up the colon into a succession of pouches called **haustra** (singular = hostrum), which creates the wrinkled, lumpy appearance of the colon. Attached to the teniae coli are small, fat-filled sacs of visceral peritoneum. The purpose of these is unknown. Although the rectum and anal canal have neither teniae coli nor haustra, they do have well-developed layers of muscularis that create the strong contractions needed for defecation.

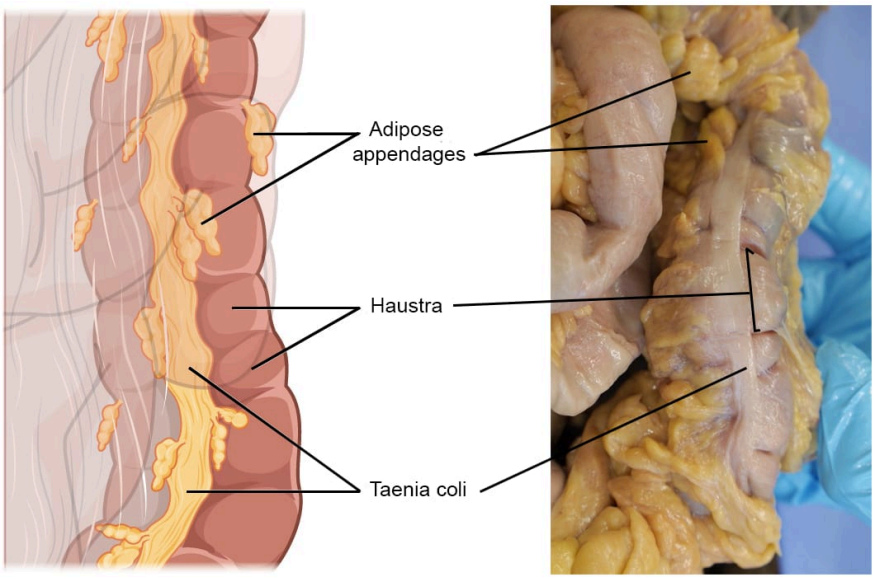

Figure 21.6.10: Structural Features of the Large Intestine. On the surface of the colon, there are fatty projections, bulges (haustra), and remnants of longitudinal smooth muscles (teniae coli). *(Image credit: "Large Intestine Structural Features by Jennifer Lange is licensed under CC BY-NC-SA 4.0 , modification of originals "Teniae Coli, Haustra, Epiploic Appendage" by OpenStax and "Leiden MOOC - Reader Anatomy on the Table - The Large Intestine" by O. Paul Gobée, LUMC.)*

The stratified squamous epithelial mucosa of the anal canal connects to the skin on the outside of the anus. This mucosa varies considerably from that of the rest of the colon to accommodate the high level of abrasion as feces pass through. Depressions within the canal's wall secrete mucus that facilitates defecation.

Bacterial Flora

Most bacteria that enter the alimentary canal are killed by lysozyme, defensins, hydrochloric acid, or protein-digesting enzymes. However, trillions of bacteria live within the large intestine and are referred to as the **bacterial flora**. Most of the more than 700 species of these bacteria are nonpathogenic commensal organisms that cause no harm as long as they stay in the gut lumen. In fact, many facilitate chemical digestion and absorption, and some synthesize certain vitamins, mainly biotin, pantothenic acid, and vitamin K. Some are linked to increased immune response. A refined system prevents these bacteria from crossing the mucosal barrier.

Digestive Functions of the Large Intestine

The residue of chyme that enters the large intestine contains few nutrients except water, which is reabsorbed as the residue lingers in the large intestine, typically for 12 to 24 hours. Thus, it may not surprise you that the large intestine can be completely removed without significantly affecting digestive functioning. For example, in severe cases of inflammatory bowel disease, the large intestine can be removed by a procedure known as a colectomy. Often, a new fecal pouch can be crafted from the small intestine and sutured to the anus, but if not, an ileostomy can be created by bringing the distal ileum through the abdominal wall, allowing the watery chyme to be collected in a bag-like adhesive appliance.

Mechanical Digestion

In the large intestine, mechanical digestion begins when chyme moves from the ileum into the cecum, an activity regulated by the ileocecal sphincter. Right after you eat, peristalsis in the ileum forces chyme into the cecum. When the cecum is distended with chyme, contractions of the ileocecal sphincter strengthen to prevent backflow. Once chyme enters the cecum, colon movements begin.

Mechanical digestion in the large intestine includes a combination of three types of movements. The presence of food residues in the colon stimulates a slow-moving **haustral contraction**. This type of movement involves sluggish segmentation, primarily in the transverse and descending colons. When a haustrum is distended with chyme, its muscle contracts, pushing the residue into the next haustrum. These contractions occur about every 30 minutes, and each last about 1 minute. These movements also mix

the food residue, which helps the large intestine absorb water. The second type of movement is peristalsis, which, in the large intestine, is slower than in the more proximal portions of the alimentary canal. The third type is a **mass movement**. These strong waves start midway through the transverse colon and quickly force the contents toward the rectum. Mass movements usually occur three or four times per day, either while you eat or immediately afterward. Distension in the stomach and the breakdown products of digestion in the small intestine provoke the **gastrocolic reflex**, which increases motility, including mass movements, in the colon. Fiber in the diet both softens the stool and increases the power of colonic contractions, optimizing the activities of the colon.

Chemical Digestion

Although the glands of the large intestine secrete mucus, they do not secrete digestive enzymes. Therefore, chemical digestion in the large intestine occurs exclusively because of bacteria in the lumen of the colon. Through the process of **saccharolytic fermentation**, bacteria break down some of the remaining carbohydrates. This results in the discharge of hydrogen, carbon dioxide, and methane gases that create **flatus** (gas) in the colon; flatulence is excessive flatus. Each day, up to 1500 mL of flatus is produced in the colon. More is produced when you eat foods such as beans, which are rich in otherwise indigestible sugars and complex carbohydrates like soluble dietary fiber.

Absorption, Feces Formation, and Defecation

The small intestine absorbs about 90 percent of the water you ingest (either as liquid or within solid food). The large intestine absorbs most of the remaining water, a process that converts the liquid chyme residue into semisolid **feces** (“stool”). Feces is composed of undigested food residues, unabsorbed digested substances, millions of bacteria, old epithelial cells from the GI mucosa, inorganic salts, other waste products, and enough water to let it pass smoothly out of the body. Of every 500 mL (17 ounces) of food residue that enters the cecum each day, about 150 mL (5 ounces) become feces.

The process of defecation begins when mass movements force feces from the colon into the rectum, stretching the rectal wall and provoking the defecation reflex, which eliminates feces from the rectum. This parasympathetic reflex is mediated by the spinal cord. It contracts the sigmoid colon and rectum, relaxes the internal anal sphincter, and initially contracts the external anal sphincter. The presence of feces in the anal canal sends a signal to the brain, which gives you the choice of voluntarily opening the external anal sphincter (defecating) or keeping it temporarily closed. If you decide to delay defecation, it takes a few seconds for the reflex contractions to stop and the rectal walls to relax. The next mass movement will trigger additional defecation reflexes until you defecate.

If defecation is delayed for an extended time, additional water is absorbed, making the feces firmer and potentially leading to constipation. On the other hand, if the waste matter moves too quickly through the intestines, not enough water is absorbed, and diarrhea can result. This can be caused by the ingestion of foodborne pathogens. In general, diet, health, and stress determine the frequency of bowel movements. The number of bowel movements varies greatly between individuals, ranging from two or three per day to three or four per week.

Concept Review

The three main regions of the small intestine are the duodenum, the jejunum, and the ileum. The small intestine is where digestion is completed and virtually all absorption occurs. These two activities are facilitated by structural adaptations that increase the mucosal surface area by 600-fold, including circular folds, villi, and microvilli. There are around 200 million microvilli per square millimeter of small intestine, which contain brush border enzymes that complete the digestion of carbohydrates and proteins. Combined with pancreatic juice, intestinal juice provides the liquid medium needed to further digest and absorb substances from chyme. The small intestine is also the site of unique mechanical digestive movements. Segmentation moves the chyme back and forth, increasing mixing and opportunities for absorption. Migrating motility complexes propel the residual chyme toward the large intestine.

The main regions of the large intestine are the cecum, the colon, and the rectum. The large intestine absorbs water and forms feces, and is responsible for defecation. Bacterial flora break down additional carbohydrate residue, and synthesize certain vitamins. The mucosa of the large intestinal wall is generously endowed with goblet cells, which secrete mucus that eases the passage of feces. The entry of feces into the rectum activates the defecation reflex.

Review Questions

Query 21.6.1

This interactive element is not available in this format. Visit the link or scan the QR code to access it online.

View this Interactive Content online

Critical Thinking Questions

Query 21.6.2

This interactive element is not available in this format. Visit the link or scan the QR code to access it online.

View this Interactive Content online

Query 21.6.3

This interactive element is not available in this format. Visit the link or scan the QR code to access it online.

View this Interactive Content online

Query 21.6.4

This interactive element is not available in this format. Visit the link or scan the QR code to access it online.

View this Interactive Content online

References

American Cancer Society (US). Cancer facts and figures: colorectal cancer: 2011–2013 [Internet]. c2013 [cited 2013 Apr 3]. Available from:http://www.cancer.org/Research/CancerFactsFigures/ColorectalCancerFactsFigures/colorectal-cancer-facts-figures-2011-2013-page.

The Nutrition Source. Fiber and colon cancer: following the scientific trail [Internet]. Boston (MA): Harvard School of Public Health; c2012 [cited 2013 Apr 3]. Available from:www.hsph.harvard.edu/nutritio...cer/index.html.

Centers for Disease Control and Prevention (US). Morbidity and mortality weekly report: notifiable diseases and mortality tables [Internet]. Atlanta (GA); [cited 2013 Apr 3]. Available from:http://www.cdc.gov/mmwr/preview/mmwrhtml/mm6101md.htm?s_cid=mm6101md_w.

Glossary

Query 21.6.5

This interactive element is not available in this format. Visit the link or scan the QR code to access it online.

View this Interactive Content online

Contributors and Attributions

- OpenStax Anatomy & Physiology (CC BY 4.0). Access for free at https://openstax.org/books/anatomy-and-physiology

This page titled 21.6: Small and Large Intestines is shared under a CC BY-NC-SA 4.0 license and was authored, remixed, and/or curated by Jennifer Lange et al..

- 21.6: Small and Large Intestines by Whitney Menefee, Julie Jenks, Chiara Mazzasette, and Kim-Leiloni Nguyen is licensed CC BY 4.0.

21.7: Accessory Organs - Liver, Pancreas, and Gallbladder

By the end of the section, you will be able to:

- State the main digestive roles, the location, and both gross and histological structure of the liver, pancreas, and gallbladder
- Explain the relative positions of the structures within a liver lobule
- Diagram the branching pattern of the bile ducts and pancreatic ducts
- Discriminate between the exocrine pancreas and the endocrine pancreas.

Chemical digestion in the small intestine relies on the activities of three accessory digestive organs: the liver, pancreas, and gallbladder (Figure 21.7.1). The digestive role of the liver is to produce bile and export it to the duodenum. The gallbladder primarily stores, concentrates, and releases bile. The pancreas produces pancreatic juice, which contains digestive enzymes and bicarbonate ions, and delivers it to the duodenum.

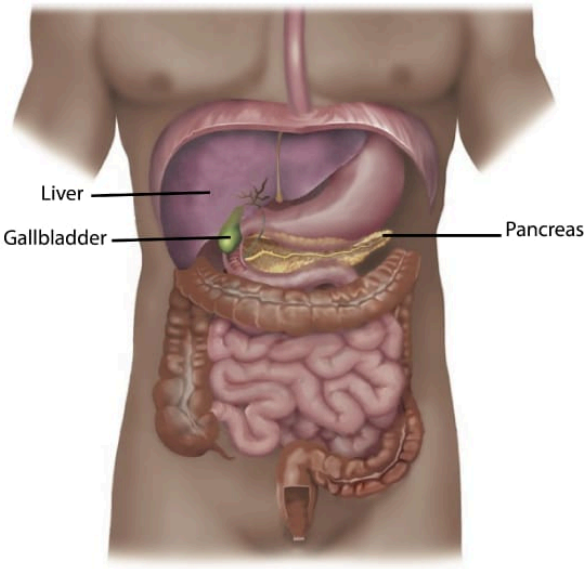

Figure 21.7.1: Accessory Organs. The liver, pancreas, and gallbladder are considered accessory digestive organs, but their roles in the digestive system are vital. *(Image credit: "Digestive System Accessory Organs" by Jennifer Lange is licensed under CC BY-NC-SA 4.0, modification of original by KnowledgeWorks.)*

Liver

The **liver** is the largest gland in the body, weighing about three pounds in an adult. It is also one of the most important organs. In addition to being an accessory digestive organ, it plays a number of roles in metabolism and regulation. The liver lies inferior to the diaphragm in the right upper quadrant of the abdominal cavity and receives protection from the surrounding ribs.

The liver is divided into two primary lobes: a large **right lobe** and a much smaller **left lobe** (Figure 21.7.2). In the right lobe, some anatomists also identify an inferior **quadrate lobe** and a posterior **caudate lobe**, which are defined by internal features. The liver is connected to the abdominal wall and diaphragm by five peritoneal folds referred to as ligaments. The lesser omentum tethers the liver to the lesser curvature of the stomach.

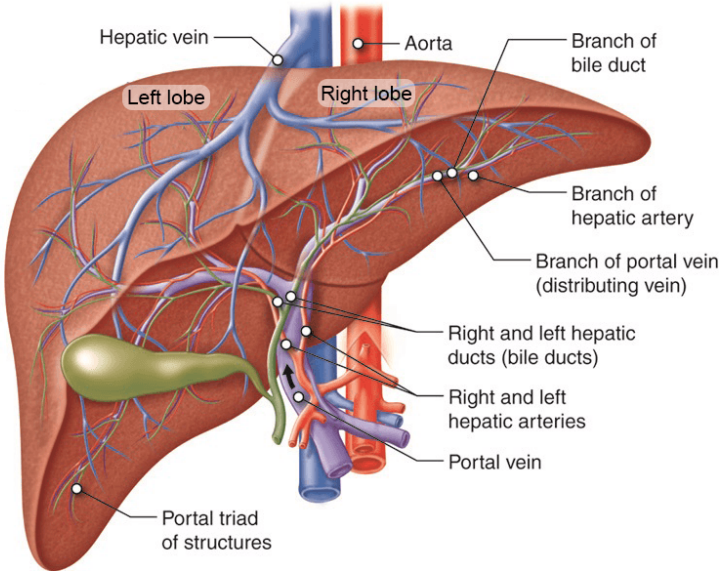

Figure 21.7.2: Inferior-anterior view of the liver. The inferior vena cava would be posterior along your spinal column. You can see the hepatic veins exiting the lobes of the liver. From this position, the left lobe is on your left hand side and the right lobe is on the right hand side. Framed between the gallbladder, porta hepatis and the ligamentum Lastly the caudate lobe is anterior to the inferior vena cava and posterior to the porta hepatis. In the porta hepatis you have the hepatic artery and hepatic portal vein entering the liver and the common hepatic duct leaving. *(Image credit: "Cenveo - Drawing Liver anatomy and vascularisation - English labels" by Cenveo, license: CC BY, modifications by Jennifer Lange.)*

The **porta hepatis** ("gate to the liver") is where the **hepatic artery** and **hepatic portal vein** enter the liver. These two vessels, along with the common hepatic duct, run behind the lateral border of the lesser omentum on the way to their destinations. As shown in (Figure 21.7.2), the hepatic artery delivers oxygenated blood from the heart to the liver. The hepatic portal vein delivers partially deoxygenated blood containing nutrients absorbed from the small intestine and actually supplies more oxygen to the liver than do the much smaller hepatic arteries. In addition to nutrients, drugs and toxins are also absorbed. After processing the blood bourne nutrients and toxins, the liver releases nutrients needed by other cells back into the blood, which drains into the central vein and then through the hepatic vein to the inferior vena cava. With this hepatic portal circulation, all blood from the alimentary canal passes through the liver. This largely explains why the liver is the most common site for the metastasis of cancers that originate in the alimentary canal.

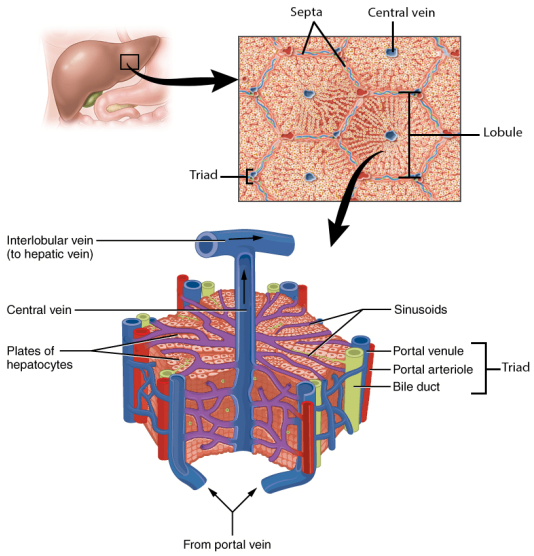

Figure 21.7.3: Microscopic Anatomy of the Liver. The liver receives oxygenated blood from the hepatic artery and nutrient-rich deoxygenated blood from the hepatic portal vein. The blood filters through the sinusoids of a liver lobule, where it comes in contact with the hepatocytes, and is collected by the central vein. Hepatocytes also produce bile, which drains through the branches of the bile duct. *(Image credit: "Microscopic Anatomy of the Liver" by Jennifer Lange is licensed under CC BY-NC-SA 4.0, modification of originals by OpenStax, BlueLink, and Cenveo.)*

Histology

The liver (Figure 21.7.4) has three main components: hepatocytes, bile canaliculi, and hepatic sinusoids. A **hepatocyte** is the liver's main cell type, accounting for around 80 percent of the liver's volume. These cells play a role in a wide variety of secretory, metabolic, and endocrine functions. Plates of hepatocytes called hepatic laminae radiate outward from the central vein in each **hepatic lobule**. The liver lobule is a hexagon shape with **portal triads** on each corner at the perimeter of the hexagon. The portal triad is a distinctive arrangement consisting of three basic structures: a bile duct, a small branch of the hepatic artery (portal arteriole) bringing in oxygenated blood and a branch of the hepatic portal vein (portal venule) delivering nutrient rich blood. The bile duct carries freshly made bile away from hepatocytes toward the gallbladder and duodenum.

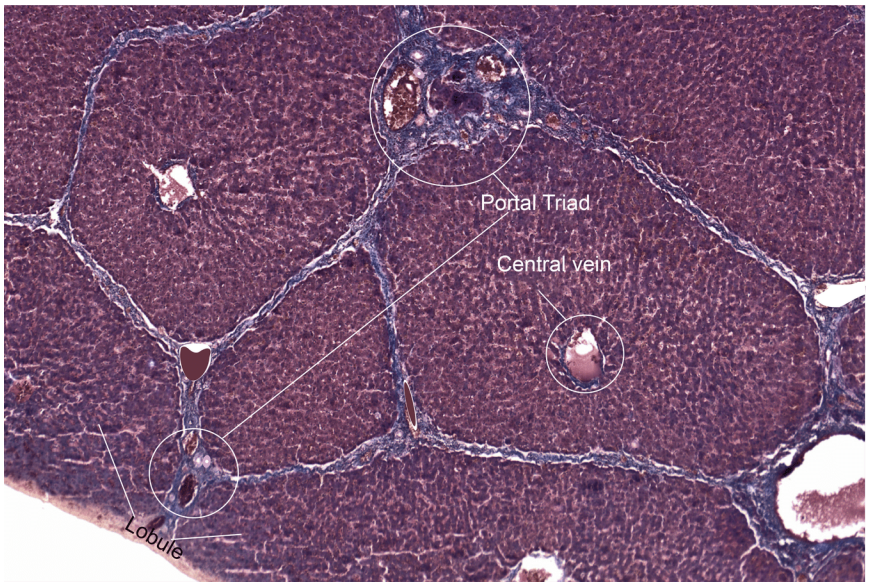

Figure 21.7.4: Liver Histology. The cells of the liver are encapsulated into hexagonal shaped lobules. At each corner of the lobule, within the connective tissue septa, is a portal triad (arteriole, venule, bile duct). An arteriole from the hepatic artery and a venule from the portal vein bring blood to the lobule. The blood drains through a series sinusoids that are lined by hepatocytes and then exists the lobule through the central vein. *(Image Credit: "Pig Liver" by Digital Histology is licensed under CC BY 4.0.)*

Between adjacent hepatocytes, grooves in the cell membranes provide room for each **bile canaliculus** (plural = canaliculi). These small ducts accumulate the bile produced by hepatocytes. From the hepatocytes, bile flows first into bile ductules and then into bile ducts. The bile ducts unite to form the larger **right** and **left hepatic ducts**, which themselves merge and exit the liver as the **common hepatic duct** (Figure 21.7.5). This duct then joins with the **cystic duct** from the gallbladder, forming the **common bile duct** through which bile flows into the small intestine.

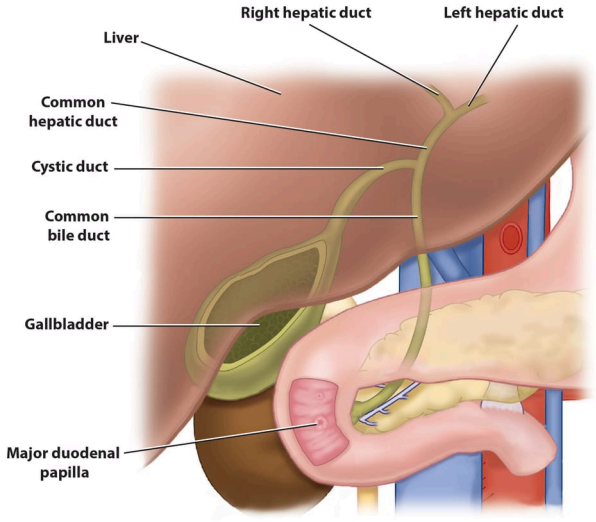

Figure 21.7.5: Bile Ducts. The ducts carrying bile from the liver and the gallbladder unite and release bile into the duodenum. *(Image credit: "Bile Ducts" by Jennifer Lange is licensed under CC BY-NC-SA 4.0, modification of original from BlueLink.)*

Recall that lipids are hydrophobic, that is, they do not dissolve in water. Thus, before they can be digested in the watery environment of the small intestine, large lipid globules must be broken down into smaller lipid globules, a process called emulsification. **Bile** is a mixture secreted by the liver to accomplish the emulsification of lipids in the small intestine.

Hepatocytes secrete about one liter of bile each day. A yellow-brown or yellow-green alkaline solution (pH 7.6 to 8.6), bile is a mixture of water, bile salts, bile pigments (including bilirubin), phospholipids (such as lecithin), electrolytes, cholesterol, and triglycerides. Some molecules in bile have regions attracted to water molecules and regions attracted to lipids. This results in the large lipid globules being pulled apart into many tiny lipid fragments of about 1 μm in diameter. This change dramatically increases the surface area available for lipid-digesting enzyme activity. This is the same way dish soap works on fats mixed with water.

Hepatocytes work non-stop, but bile production increases when fatty chyme enters the duodenum and stimulates the secretion of the gut hormone secretin. Between meals, bile is produced but conserved. The valve-like hepatopancreatic ampulla closes, allowing bile to divert to the gallbladder, where it is concentrated and stored until the next meal.

A **hepatic sinusoid** is an open, porous blood space formed by fenestrated capillaries from nutrient-rich hepatic portal veins and oxygen-rich hepatic arteries. Hepatocytes are tightly packed around the fenestrated endothelium of these spaces, giving them easy access to the blood. From their central position, hepatocytes process the nutrients, toxins, and waste materials carried by the blood. Materials such as bilirubin are processed and excreted into the bile canaliculi. Other materials including proteins, lipids, and carbohydrates are processed and secreted into the sinusoids or just stored in the cells until called upon. The hepatic sinusoids combine and send blood to a **central vein**. Blood then flows through a **hepatic vein** into the inferior vena cava. This means that blood and bile flow in opposite directions. The hepatic sinusoids also contain star-shaped **reticuloendothelial cells** (Kupffer cells), phagocytes that remove dead red and white blood cells, bacteria, and other foreign material that enter the sinusoids.

Gallbladder

Figure 21.7.5 shows the anterior view of the gallbladder, part of the liver superior to the gallbladder, and the duct connecting the liver to gallbladder, eventually becoming the common bile duct. The **gallbladder** is 8–10 cm (~3–4 in) long and is nested in a shallow area on the posterior aspect of the right lobe of the liver. This muscular sac stores, concentrates, and, when stimulated,

propels the bile into the duodenum via the common bile duct. It is divided into three regions: the fundus is the widest portion and tapers medially into the body, which in turn narrows to become the neck. The neck angles slightly superiorly as it approaches the hepatic duct. The cystic duct is 1–2 cm (less than 1 in) long and turns inferiorly as it bridges the neck and hepatic duct.

The simple columnar epithelium of the gallbladder mucosa is organized in rugae, similar to those of the stomach. There is no submucosa in the gallbladder wall. The wall's middle, muscular coat is made of smooth muscle fibers. When these fibers contract, the gallbladder's contents are ejected through the **cystic duct** and into the bile duct (Figure 21.7.5). Visceral peritoneum reflected from the liver capsule holds the gallbladder against the liver and forms the outer coat of the gallbladder. The gallbladder's mucosa absorbs water and ions from bile, concentrating it by up to 10-fold. The gallbladder can accumulate gall stones over time (Figure 21.7.6), resulting in removal of the gallbladder with the gall stones in some people.

Figure 21.7.6: Gallstones. Ultrasound image of a stone in the gallbladder. *(Image credit: "Gallstone" by © Nevit Dilmen is licensed under CC BY-SA 3.0, via Wikimedia Commons.)*

Pancreas

The soft, oblong, glandular **pancreas** lies transversely in the retroperitoneum behind the stomach. Its head is nestled into the "c-shaped" curvature of the duodenum with the body extending to the left about 15.2 cm (6 in) and ending as a tapering tail in the hilum of the spleen. It performs a curious mix of exocrine (secreting digestive enzymes) and endocrine (releasing hormones into the blood) functions (Figure 21.7.7). Histology of the pancreas reveals round clusters of acinar cells connected to the pancreatic duct and the bigger clusters of pancreatic islets.

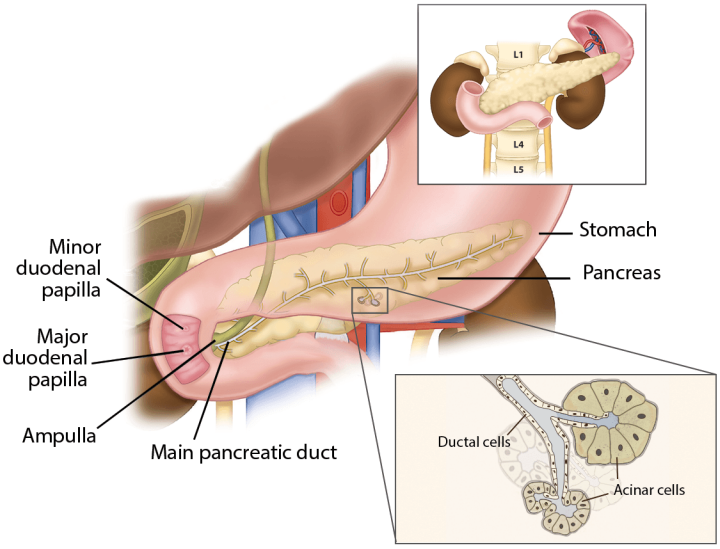

Figure 21.7.7: Exocrine Pancreas. The pancreas is located posterior to the stomach. The acinar and ductal cells secrete enzymes and bicarbonate into the pancreatic duct(s) that empty into the duodenum at the duodenal papilla(e). *(Image credit: "Exocrine Pancreas" by Jennifer Lange is licensed under CC BY-NC-SA 4.0, modification of original illustration by BlueLink.)*

The exocrine part of the pancreas arises as little grape-like cell clusters of serous cells, each called an **acinus** (plural = acini), located at the terminal ends of pancreatic ducts (Figure 21.7.7). These acinar cells secrete enzyme-rich **pancreatic juice** into tiny merging ducts that form two dominant ducts. The **main pancreatic duct** fuses with the common bile duct at the ampulla (carrying bile from the liver and gallbladder) just before entering the duodenum via a common opening (the main duodenal papilla). The smooth muscle sphincter of the hepatopancreatic ampulla controls the release of pancreatic juice and bile into the small intestine. The second and smaller pancreatic duct, the **accessory duct** (duct of Santorini), present in approximately 30% of the population, runs from the pancreas directly into the duodenum, approximately 1 inch above the hepatopancreatic ampulla. When present, it is a persistent remnant of pancreatic development.

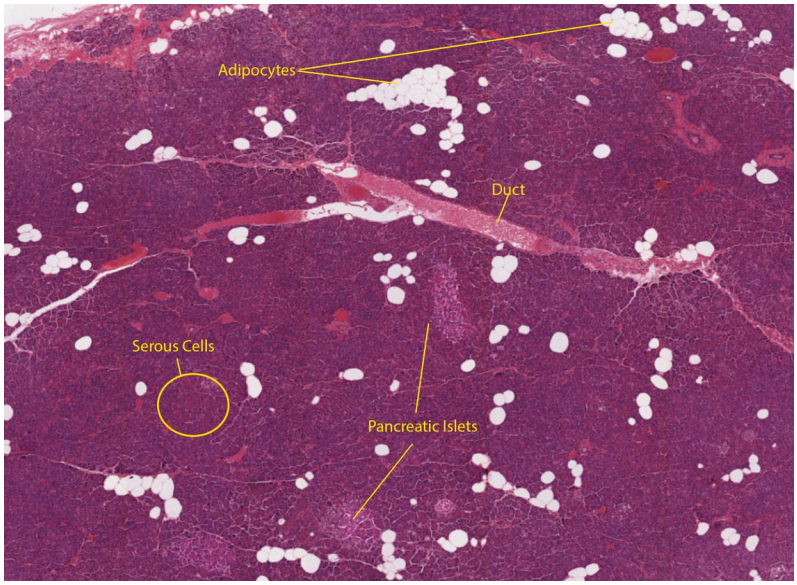

Figure 21.7.8: Pancreas Histology @ 100x. This shows that he pancreas is made up of lots of serous cells. However, at this power, you cannot see the acini. *(Image Credit: "Pancreas Histology @ 100x" micrograph provided by the Regents of University of Michigan Medical School © 2012.)*

Scattered through the sea of exocrine acini are small islands of endocrine cells, the pancreatic islets (islets of Langerhans) (Figure 21.7.8 and Figure 21.7.9). These vital cells produce the hormones pancreatic polypeptide, insulin, glucagon, and somatostatin. These hormones play roles in regulating several metabolic functions.

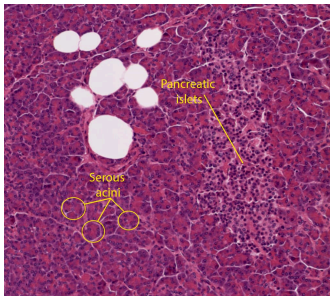

Figure 21.7.9: Pancreatic Islet Histology @ 400x. you can see the serous cells are clumped into the grape light acini. The lighter colored pancreatic islet is also more clear under this magnification. *(Image Credit :"Pancreatic Islet Histology @ 400x" micrograph provided by the Regents of University of Michigan Medical School © 2012.)*

Pancreatic Juice

The pancreas produces over a liter of pancreatic juice each day. Unlike bile, it is clear and composed mostly of water along with some salts, sodium bicarbonate, and several digestive enzymes. Sodium bicarbonate is responsible for the slight alkalinity of pancreatic juice (pH 7.1 to 8.2), which serves to buffer the acidic gastric juice in chyme, inactivate pepsin from the stomach, and create an optimal environment for the activity of pH-sensitive digestive enzymes in the small intestine. Pancreatic enzymes are active in the digestion of sugars, proteins, and fats.

The pancreas produces protein-digesting enzymes in their inactive forms. These enzymes are activated in the duodenum. If produced in an active form, they would digest the pancreas (which is exactly what occurs in the disease, pancreatitis). The intestinal brush border enzyme **enteropeptidase** stimulates the activation of an enzyme that starts the cascade of other enzymes to digest proteins.

The enzymes that digest starch (amylase), fat (lipase), and nucleic acids (nuclease) are secreted in their active forms, since they do not attack the pancreas as do the protein-digesting enzymes.

Concept Review

Chemical digestion in the small intestine cannot occur without the help of the liver and pancreas. The liver produces bile and delivers it to the common hepatic duct. Bile contains bile salts and phospholipids, which emulsify large lipid globules into tiny lipid droplets, a necessary step in lipid digestion and absorption. The gallbladder stores and concentrates bile, releasing it when it is needed by the small intestine.

The pancreas produces the enzyme- and bicarbonate-rich pancreatic juice and delivers it to the small intestine through ducts. Pancreatic juice buffers the acidic gastric juice in chyme, inactivates pepsin from the stomach, and enables the optimal functioning of digestive enzymes in the small intestine.

Review Questions

Query 21.7.1

This interactive element is not available in this format. Visit the link or scan the QR code to access it online.

View this Interactive Content online

Critical Thinking Questions

Query 21.7.2

This interactive element is not available in this format. Visit the link or scan the QR code to access it online.

View this Interactive Content online

Query 21.7.3

This interactive element is not available in this format. Visit the link or scan the QR code to access it online.

View this Interactive Content online

Glossary

Query 21.7.4

This interactive element is not available in this format. Visit the link or scan the QR code to access it online.

View this Interactive Content online

Contributors and Attributions

- OpenStax Anatomy & Physiology (CC BY 4.0). Access for free at https://openstax.org/books/anatomy-and-physiology

This page titled 21.7: Accessory Organs - Liver, Pancreas, and Gallbladder is shared under a CC BY-NC-SA 4.0 license and was authored, remixed, and/or curated by Jennifer Lange et al..

- 21.7: Accessory Organs in Digestion- Liver, Pancreas, and Gallbladder by Whitney Menefee, Julie Jenks, Chiara Mazzasette, and Kim-Leiloni Nguyen is licensed CC BY 4.0.

21.8: Anatomical Atlas - Digestive System

A compendium of anatomical images: slides, models, and/or cadavers.

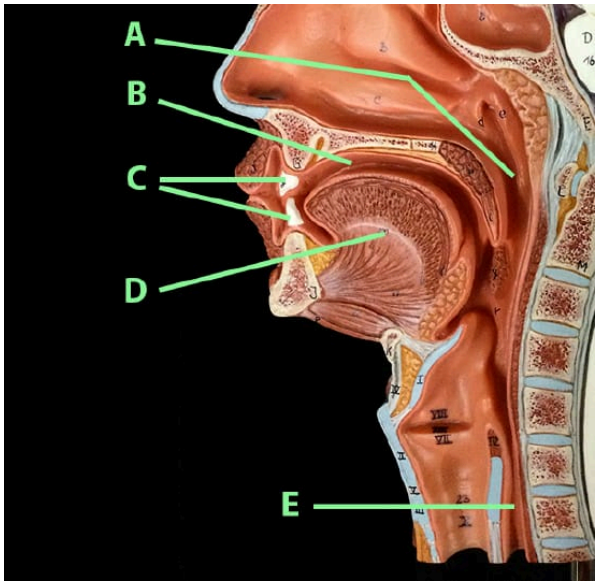

Image credit

“Head Model Midline - Digestive Organs Atlas" by Jennifer Lange, is licensed under CC BY-NC-SA 4.0.

Answer Key (click

A - pharynx

B - oral cavit

C - teeth

D - tongue

E - esophagu

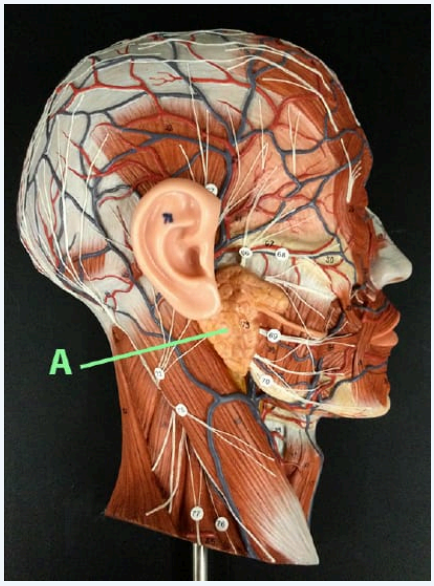

Image credit

"Head Model Lateral - Digestive Organs Atlas" by Jennifer Lange, is licensed under CC BY-NC-SA 4.0.

Answer Key (click

A - parotid g

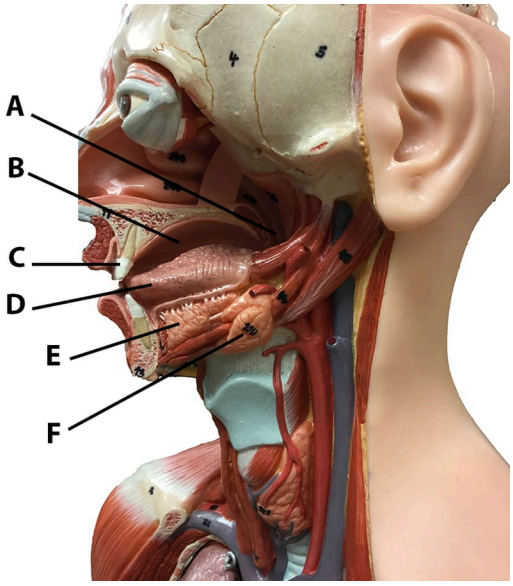

Image credit

"Torso Model Head and Neck - Digestive Organs Atlas" by Jennifer Lange, is licensed under CC BY-NC-SA 4.0.

Answer Key (click

A - pharynx

B - oral cavit

C - teeth

D - tongue

E - sublingua

F - submand

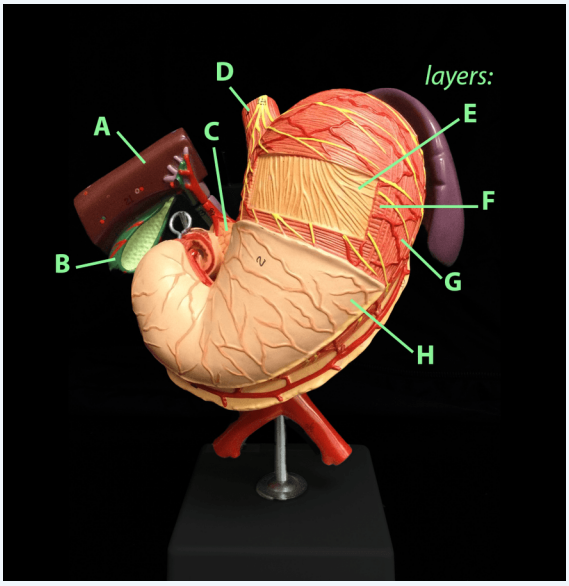

Image credit

"Stomach and Surrounding Organs Model - Atlas" by Jennifer Lange, is licensed under CC BY-NC-SA 4.0.

Answer Key (click

A - liver

B - gallbladd

C - pancreas

D - esophagu

E - inner obli

F - middle ci

G - outer lon

H - serosa

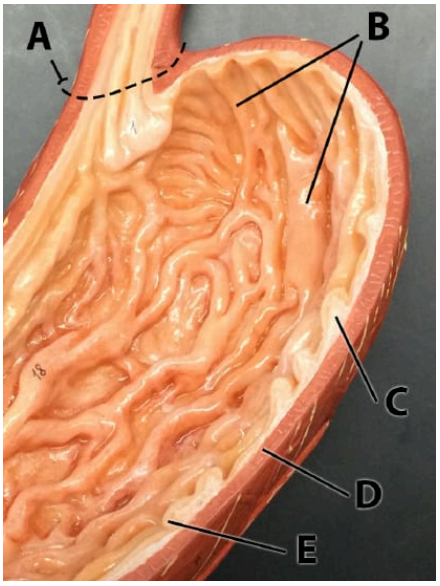

Image credit

"Stomach Model Close-up - Atlas" by Jennifer Lange, is licensed under CC BY-NC-SA 4.0.

Answer Key (click

A - lower eso

B - gastric fo

C - submuco

D - muscular

E - mucosa

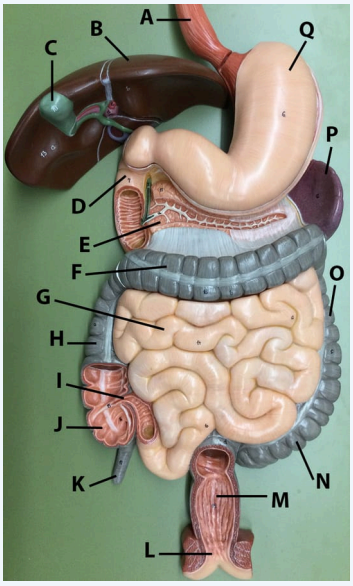

Image credit

“Flat Digestive System Model - Atlas" by Jennifer Lange, is licensed under CC BY-NC-SA 4.0.

Answer Key (click

A - esophagu

B - liver

C - gallbladd

D - duodenu

E - pancreas

F - transvers

G - small inte

H - ascendin

I - iliocecal v

J - cecum (o

K - appendix

L - anal cana

M - rectum

N - sigmoid

O - descendi

P - spleen

Q - stomach

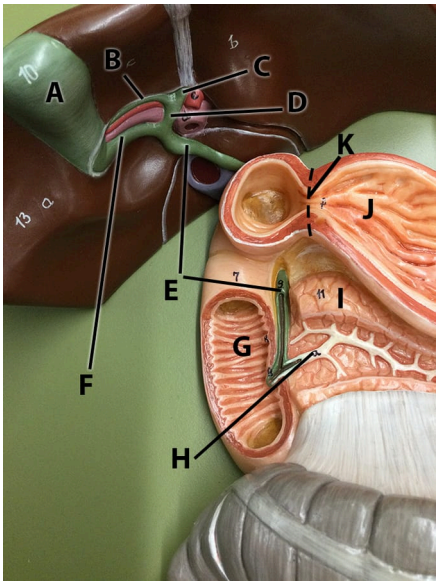

Image credit

"Flat Digestive System Model - Biliary Ducts Atlas" by Jennifer Lange, is licensed under CC BY-NC-SA 4.0.

Answer Key (click

A - gallbladd
B - right hep
C - left hepat
D - common
E - common
F - cystic duc
G - duodenu
H - pancreati
I - pancreas
J - stomach
K - pyloric sp

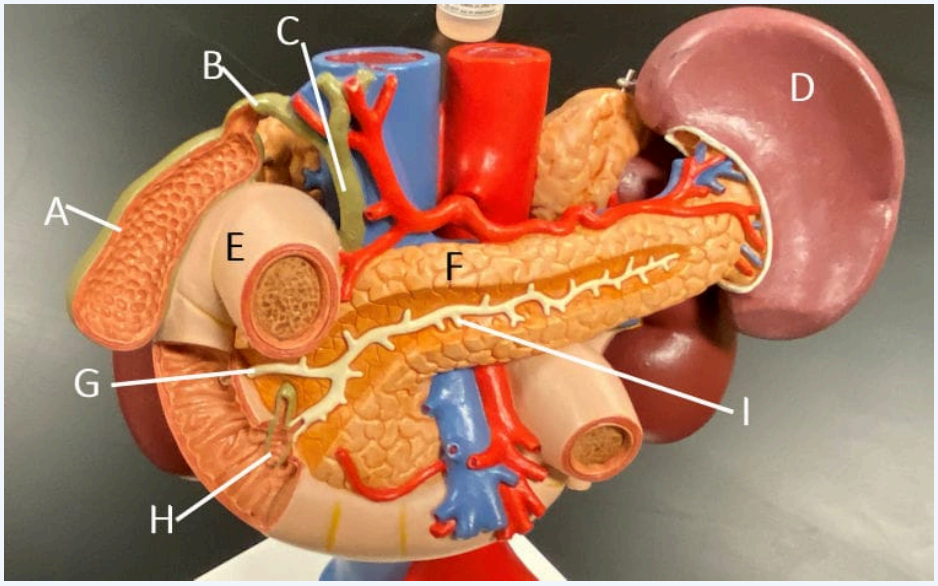

Image credit

"Upper Abdominal Organs Model - Atlas" by John Polos is licensed under CC BY-NC-SA 4.0.

Answer Key (click

A - gallbladd
B - cystic duc
C - common
D - spleen
E - duodenu
F - pancreas
G - accessor
H - ampulla
I - main pan

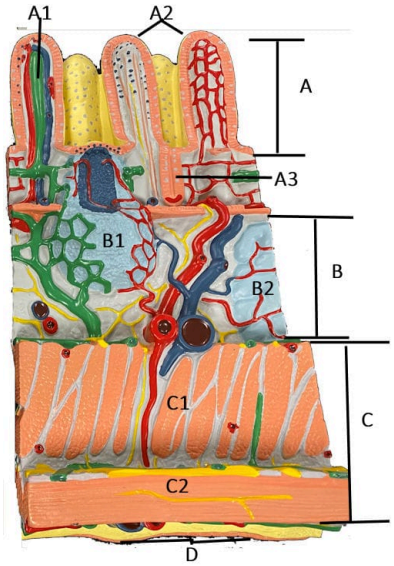

Answer Key (click

A - Mucos
A1 - Lacte
A2 - Villi
A3 - Crypt
B - Submu
B1 - Peyer
B2 - Mucu
C - Muscu
C1 - Circu
C2 - Long
D - Serosa

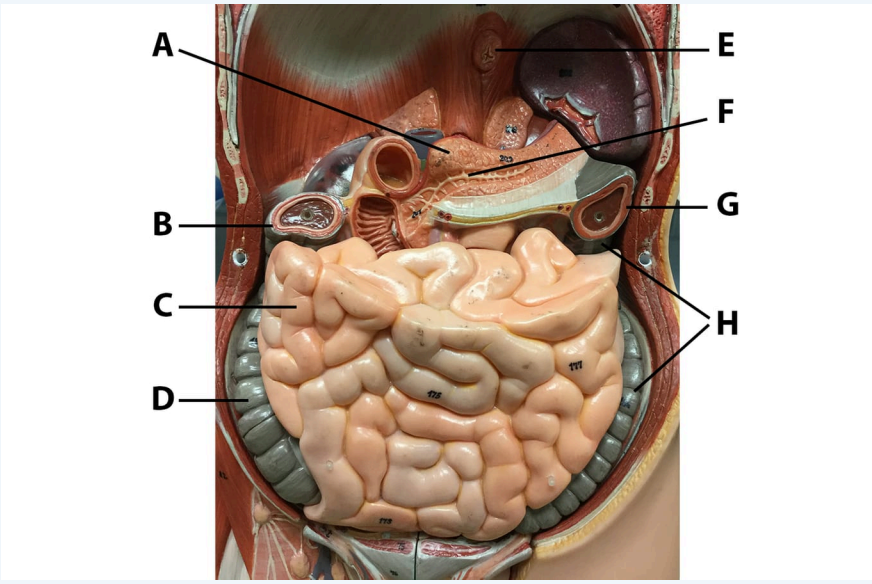

Answer Key (click

Pancre

Transve
col

Sm
intesti

Ascendi
col

Image credit

"Torso Model Abdominal Region - Digestive Organs Atlas" by Jennifer Lange, is licensed under CC BY-NC-SA 4.0.

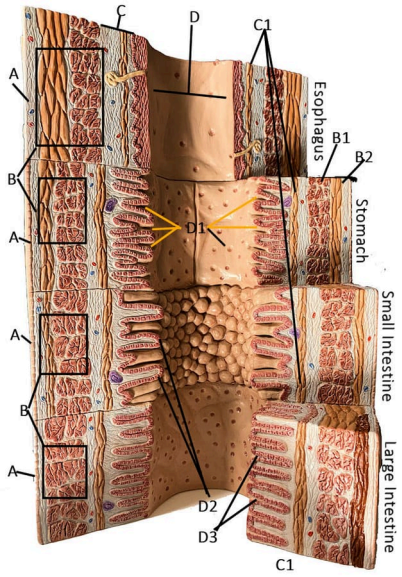

Answer Key (click

A - Serosa
B - Muscu
B1 - Circu
B2 - Long
C - Submu
C1 - Musc
D - Mucos
D1 - Gastr
D2 - Villi i
D3 - Crypt

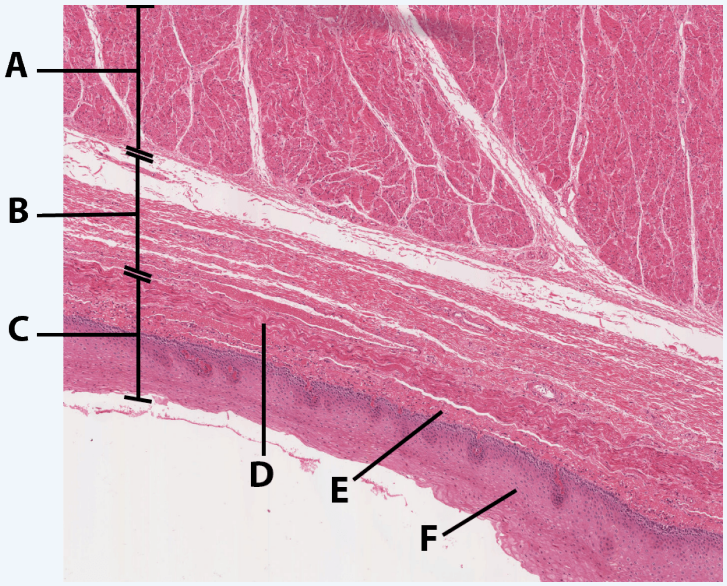

Answer Key (click

Esophagus @

A - muscular

B - submuco

C - mucosa

D - muscular

E - lamina pr

F - stratified

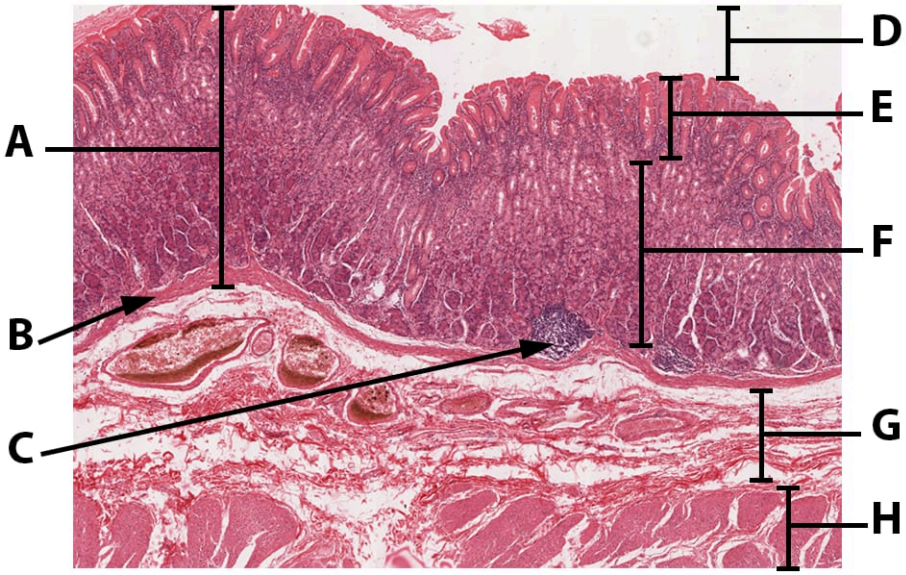

Image credit

"Stomach Histology @ 100x" slide provided by the Regents of the University of Michigan Medical School © 2022 CC BY-NC-SA 3.0, labeling by Jennifer Lange.

Answer Key (click

Stomach @ 1

A - mucosa

B - muscular

C - MALT (mu

D - lumen

E - gastric pi

F - gastric gl

G - submuco

H - muscular

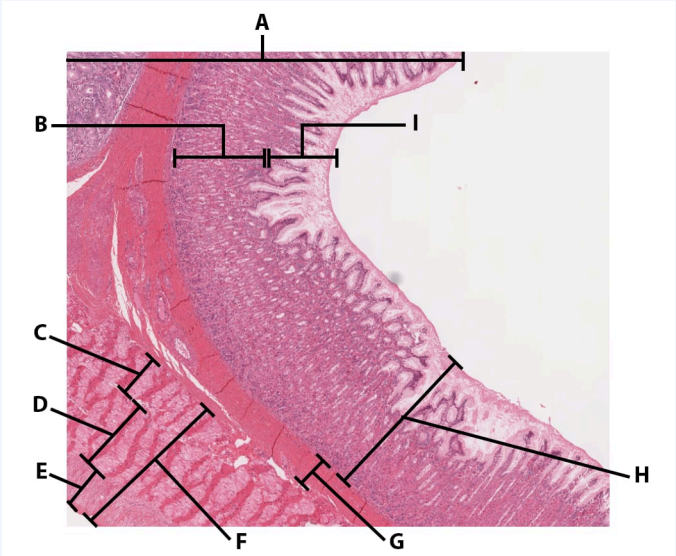

Image credit

"Stomach Histology @ 40x" slide provided by the Regents of the University of Michigan Medical School © 2022 under CC BY-NC-SA 3.0, labeling by Jennifer Lange.

Answer Key (click

Stomach @ 4

A - gastric fo

B - gastric gl

C - muscular

D - muscular

E - muscular

F - muscular

G - submuco

H - mucosa

I - gastric pit

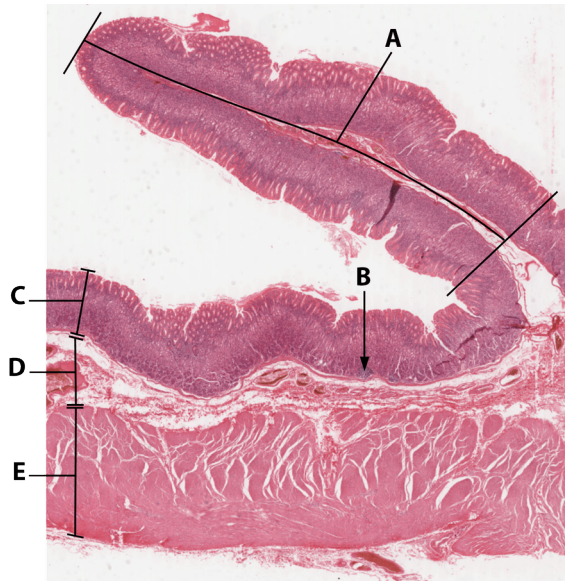

Image credit

"Stomach Histology @ 10x - atlas" slide provided by the Regents of the University of Michigan Medical School © 2022 under CC BY-NC-SA 3.0, labeling by Jennifer Lange.

Answer Key (click

Stomach @ 1

A - gastric fo

B - MALT - m

C - mucosa

D - submuco

E - muscular

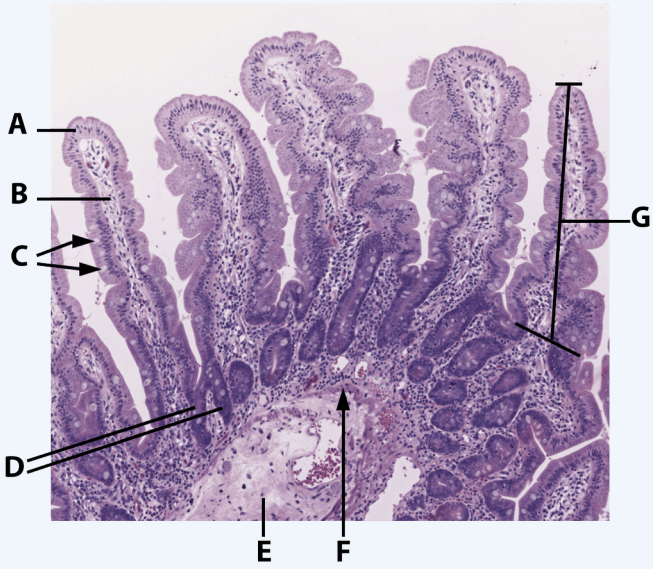

Image credit

"Small Intestine Histology @ 200x - atlas" slide provided by the Regents of the University of Michigan Medical School © 2022 under CC BY-NC-SA 3.0, labeling by Jennifer Lange.

Answer Key (click

Small intesti

A - simple co

B - lamina pr

C - goblet ce

D - intestinal

E - submucos

F - muscular

G - villus

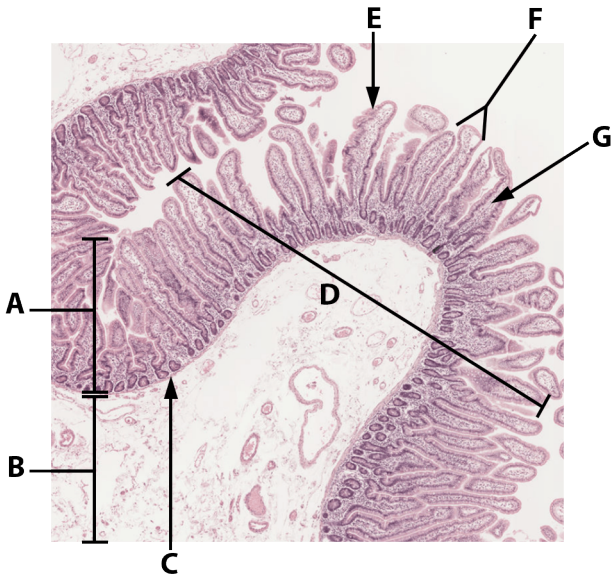

Image credit

"Small Intestine Histology @ 100x - atlas" slide provided by the Regents of the University of Michigan Medical School © 2022 under CC BY-NC-SA 3.0, labeling by Jennifer Lange.

Answer Key (click

Small intesti

A - mucosa

B - submuco

C - muscular

D - circular f

E - simple cc

F - villus

G - lamina pr

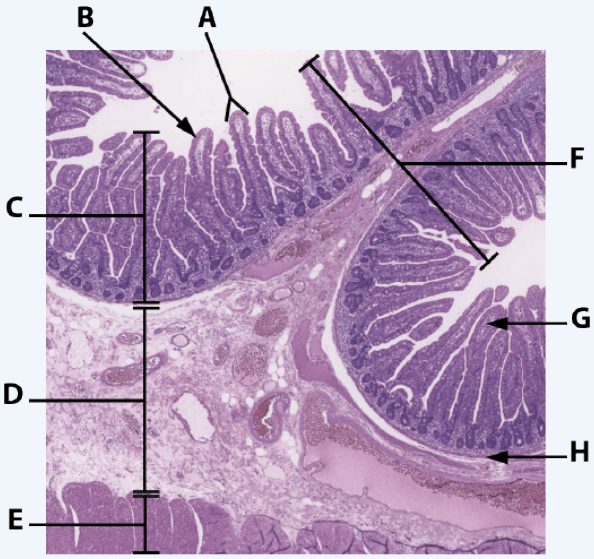

Image credit

"Small Intestine Histology @ 40x - atlas" slide provided by the Regents of the University of Michigan Medical School © 2022 under CC BY-NC-SA 3.0, labeling by Jennifer Lange.

Answer Key (click

Small Intesti

A - villus

B - simple cc

C - mucosa

D - submuco

E - muscular

F - circular f

G - lamina pr

H - muscular

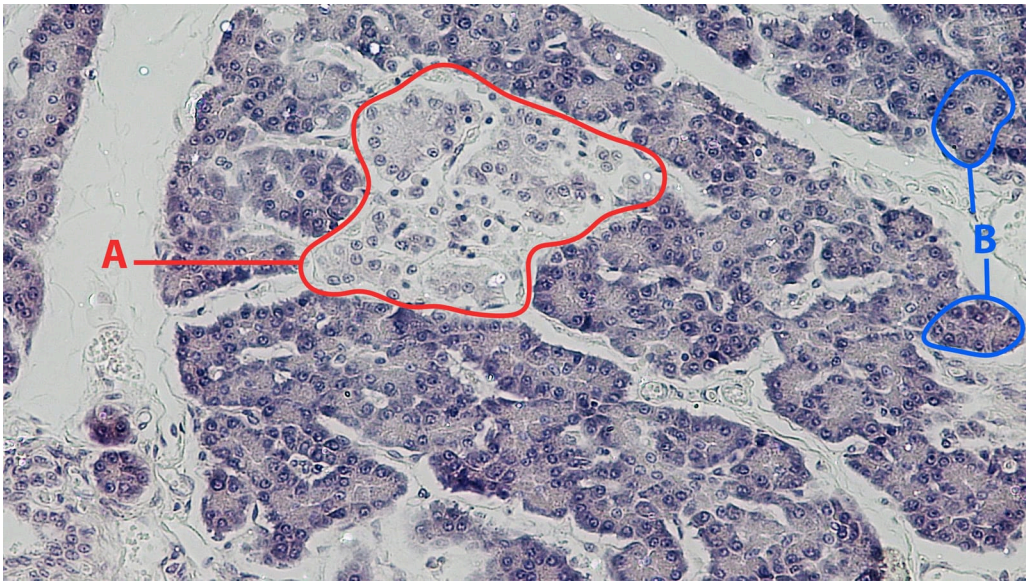

Image credit

"Pancreas Histology @ 400x - atlas" micrograph provided by Berkshire Community College Bioscience Image Library is in the Public Domain, labeling by Jennifer Lange.

Answer Key (click

Pancreas @ 4

A - pancreati

B - pancreati

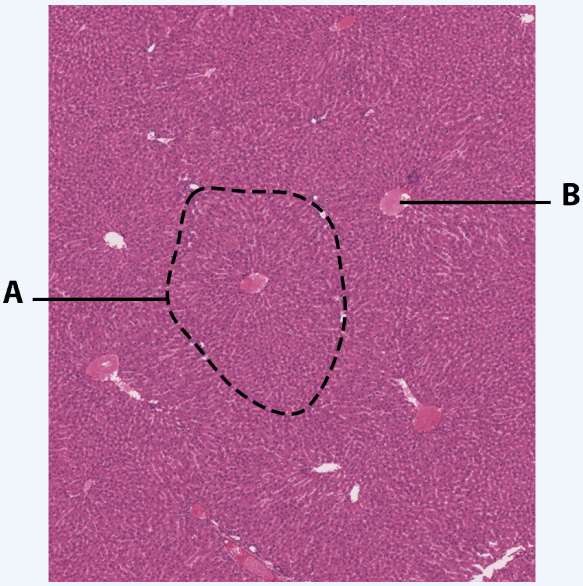

Image credit

"Liver (Human) Histology @ 100x - atlas" slide provided by the Regents of the University of Michigan Medical School © 2022 under CC BY-NC-SA 3.0, labeling by Jennifer Lange.

Answer Key (click

Liver @ 100x

A - lobule

B - central ve

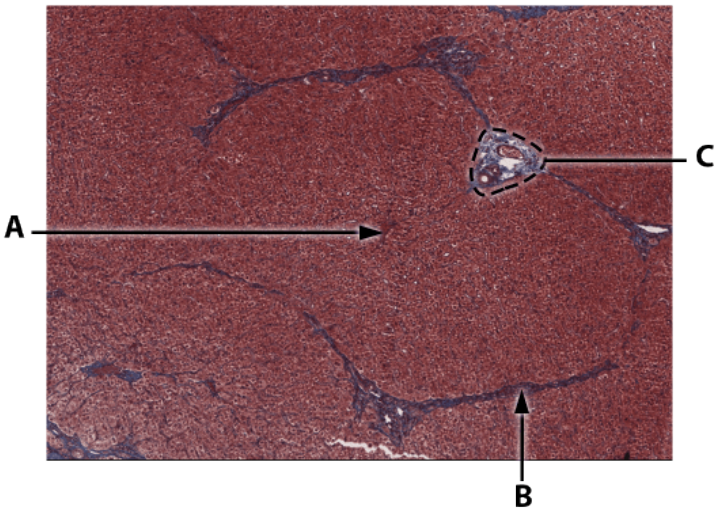

Image credit

"Liver (Human) Histology @ 400x Masson Stain - atlas" slide provided by the Regents of the University of Michigan Medical School © 2022 under CC BY-NC-SA 3.0, labeling by Jennifer Lange.

Answer Key (click

Liver @ 400›

A - central ve

B - interlobul

C - hepatic p

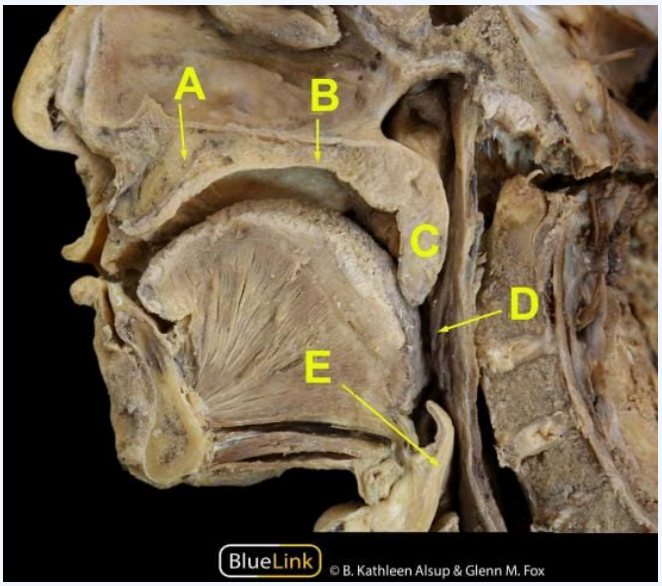

Image credit

"*Half Head*" by John Polos. All cadaver images from BlueLink at the University of Michigan and are made available by the regents under CC 4.0

For larger images, right click(PC)/command click (Mac) and click open image in new window.

Answer Key (click

A - hard pala

B - soft palat

C - uvula

D - pharynx

E - epiglottis

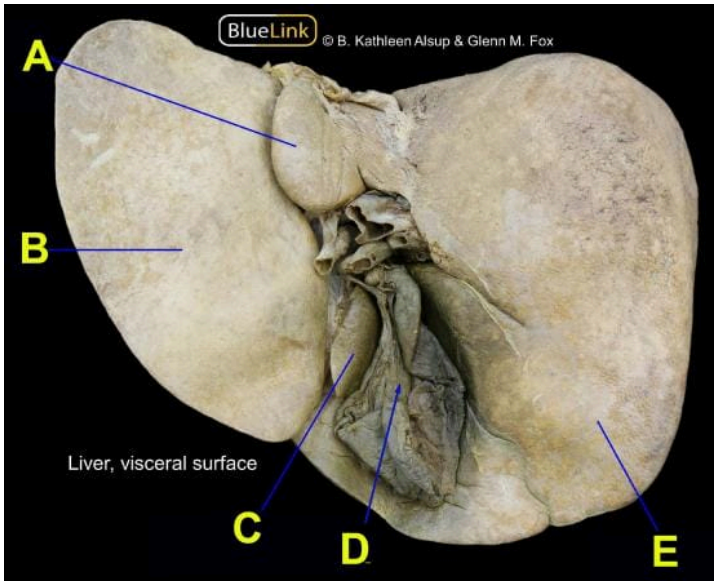

Image credit

"*Liver*" by John Polos. All cadaver images from BlueLink at the University of Michigan and are made available by the regents under CC 4.0

For larger images, right click(PC)/command click (Mac) and click open image in new window.

Answer Key (click

A - caudate l

B - right lobe

C - quadrate

D - gallbladd

E - left lobe

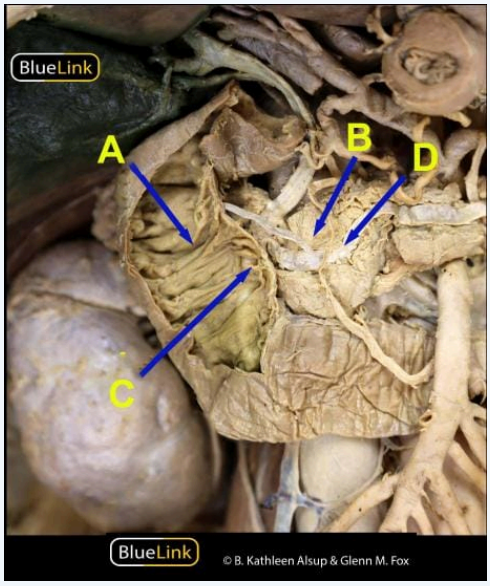

Image credit

"*Abdominal* organs" by John Polos. All cadaver images from BlueLink at the University of Michigan and are made available by the regents under CC 4.0

For larger images, right click(PC)/command click (Mac) and click open image in new window.

Answer Key (click

A - duodenur

B - pancreas

C - ampulla

D - main pan

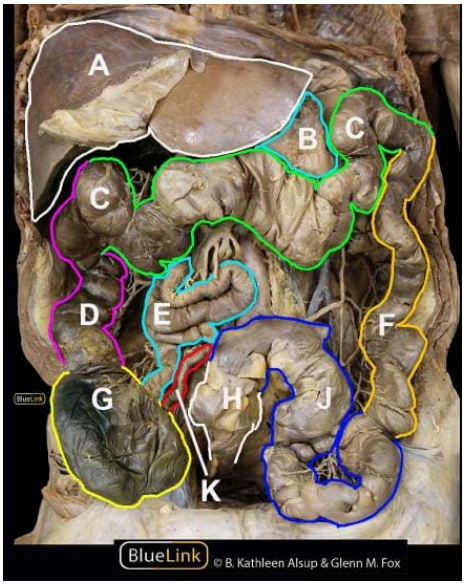

Image credit

"*Abdominal cavity*" by John Polos. All cadaver images from BlueLink at the University of Michigan and are made available by the regents under CC 4.0

For larger images, right click(PC)/command click (Mac) and click open image in new window.

Answer Key (click

A - liver

B - stomach

C - transvers

D - ascendin

E - small inte

F - descendi

G -cecum (of

H -rectum

J -sigmoid c

K -appendix

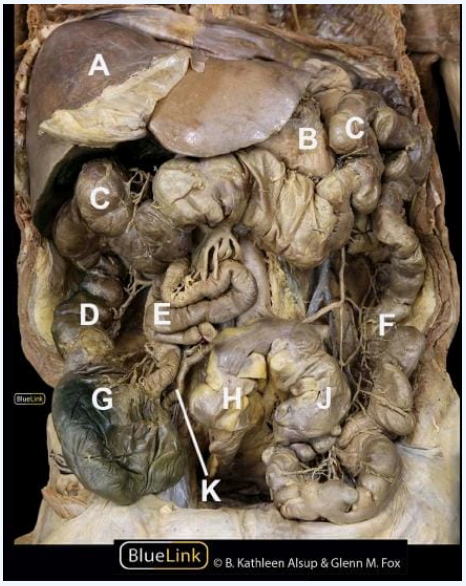

Image credit

"*Abdominal cavity*" by John Polos. All cadaver images from BlueLink at the University of Michigan and are made available by the regents under CC 4.0

For larger images, right click(PC)/command click (Mac) and click open image in new window.

Answer Key (click

A - liver

B - stomach

C - transvers

D - ascendin

E - small inte

F - descendi

G -cecum (of

H -rectum

J -sigmoid c

K -appendix

This page titled 21.8: Anatomical Atlas - Digestive System is shared under a CC BY-NC-SA 4.0 license and was authored, remixed, and/or curated by Jennifer Lange et al..

21.9: Practice Practical- Digestive system

Answer each of the following questions by typing your answer into the box(es).

Query 21.9.1

This interactive element is not available in this format. Visit the link or scan the QR code to access it online.

View this Interactive Content online

Query 21.9.2

This interactive element is not available in this format. Visit the link or scan the QR code to access it online.

View this Interactive Content online

Query 21.9.3

This interactive element is not available in this format. Visit the link or scan the QR code to access it online.

View this Interactive Content online

Query 21.9.4

This interactive element is not available in this format. Visit the link or scan the QR code to access it online.

View this Interactive Content online

This page titled 21.9: Practice Practical- Digestive system is shared under a CC BY-NC-SA 4.0 license and was authored, remixed, and/or curated by Jennifer Lange et al..

22: URINARY SYSTEM

22.1: Introduction to the Urinary System
22.2: Overview of the Kidney
22.3: Microscopic Anatomy of the Kidney
22.4: Urinary Tract
22.5: Anatomical Atlas - Urinary System
22.6: Practice Practical- Urinary System

This page titled 22: Urinary System is shared under a CC BY-NC-SA 4.0 license and was authored, remixed, and/or curated by Jennifer Lange et al..

- 22: Urinary System by Whitney Menefee, Julie Jenks, Chiara Mazzasette, and Kim-Leiloni Nguyen is licensed CC BY 4.0.

22.1: Introduction to the Urinary System

Chapter Learning Objectives

- Name the organs of the urinary system
- Explain the major function(s) of each organ of the urinary system
- Describe the macroscopic and microscopic structures of the kidney
- Trace the flow of blood and urine through the kidney
- Trace the flow of urine through the urinary tract

This chapter will help you to understand the anatomy of the urinary system: kidneys, ureters, urinary bladder, and urethra. You will trace the blood flow through the kidney; think of the kidney as a regulator of plasma makeup rather than simply a urine producer. Knowing the anatomy will help you to understand how the urinary system maintains homeostasis and affects all the other systems of the body when you take physiology.

The Urinary or Renal System consists of two kidneys and the pathway, two ureters, urinary bladder, and one urethra, for urine to exit the body. The kidneys' primary function is to make urine by first filtering out many of the electrolytes, solutes, and water in the blood, forming the filtrate. As the filtrate passes through microscopic units called nephrons, certain solutes and water molecules are reabsorbed back to the blood because they are too precious to waste and other molecules are secreted because the body does not want them. As the filtrate becomes more concentrated, because water has been reabsorbed back to the blood, as it moves through the nephron, the end product is urine containing the waste products that the body can spare. Another perspective on the function of the kidneys is to monitor the level of certain solutes in the blood to maintain homeostasis. The kidneys' secondary function is to make hormones. Please review the Endocrine chapter for details.

The two ureters will carry urine from the kidneys down to the urinary bladder by peristalsis for storage. As the urinary bladder fills with urine, nerve endings will detect the stretched bladder to signal emptying. With sphincters relaxing, urine will flow out of the urinary bladder through the urethra to be expelled.

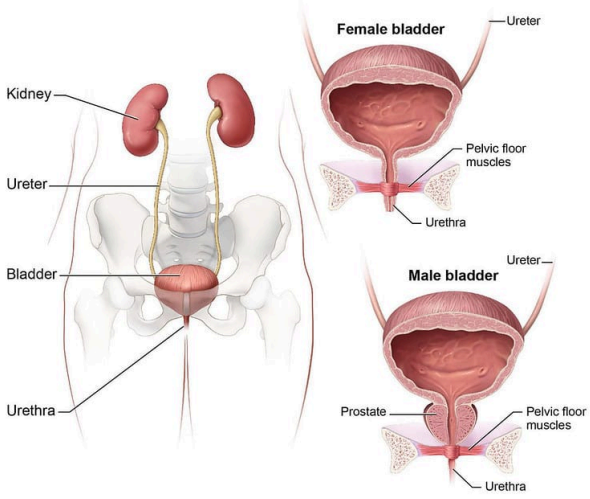

Figure 22.1.1: Organs of the Urinary System. The male and female human urinary system, including kidneys, bladder, ureter and urethra, pelvic floor muscles and the prostate. *(Image credit: "Organs of the Urinary System" by NIH Medial Arts is licensed under CC-BY-NC 2.0.)*

Contributors and Attributions

- OpenStax Anatomy & Physiology (CC BY 4.0). Access for free at https://openstax.org/books/anatomy-and-physiology

This page titled 22.1: Introduction to the Urinary System is shared under a CC BY-NC-SA 4.0 license and was authored, remixed, and/or curated by Jennifer Lange et al..

- 22.1: Introduction to the Urinary System by Whitney Menefee, Julie Jenks, Chiara Mazzasette, and Kim-Leiloni Nguyen is licensed CC BY 4.0.

22.2: Overview of the Kidney

By the end of the section, you will be able to:

- Describe the external structure and the locations of the kidney
- Identify the major internal divisions and structures of the kidney
- Identify the major blood vessels associated with the kidney and trace the path of blood through the kidney
- Name the regions in a nephron
- Trace the flow of fluid from blood through the kidney tubules

The kidneys lie laterally to the spine in the retroperitoneal space between the parietal peritoneum and the posterior abdominal wall, well protected by muscle, fat, and ribs. Each kidney weighs about 125–175 g in males and 115–155 g in females. They are about 11–14 cm in length, 6 cm wide, and 4 cm thick. This makes them roughly the size of your fist, with the male kidney typically a bit larger than the female kidney. The kidneys are well vascularized, receiving about 25 percent of the cardiac output at rest.

External Anatomy

The left kidney is located at about the level of the T12 to L3 vertebrae, whereas the right is slightly lower due to slight displacement by the liver. Superior portions of the kidneys are somewhat protected by the eleventh and twelfth ribs (Figure 22.2.1). They are directly covered by a **fibrous capsule,** composed of dense irregular connective tissue that helps to hold their shape, and are surrounded by a shock-absorbing layer of adipose tissue called the **renal fat pad.** This adipose tissues is, in turn, encompassed by a tough **renal fascia**. The fascia and, to a lesser extent, the overlying peritoneum serve to firmly anchor the kidneys to the posterior abdominal wall.

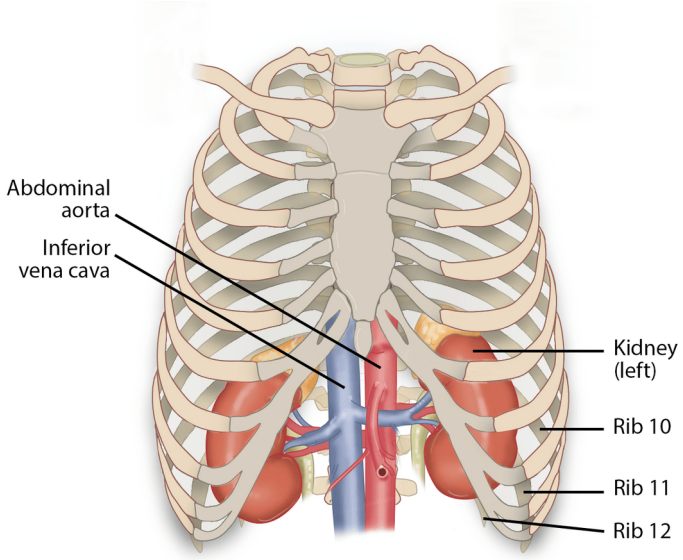

Figure 22.2.1: Kidney Position. The kidneys are located deep to the floating ribs, which provide protection for the kidneys. *(Image credit: "Kidney Position Relative to the Thoracic Cage" by Jennifer Lange is licensed under CC BY-NC-SA 4.0; modification of "Slagter - Drawing and Chest X-ray of the ribs and clavicula - no labels" by Ron Slagter, and "Slagter - Drawing Anatomy of the kidney, adrenal glands and bladder - no labels" by Ron Slagter.)*

Renal Hilum

The **renal hilum** (Figure 22.2.2A) is the medial-facing, concave entry and exit site for structures servicing the kidneys: blood vessels, nerves, lymphatics, and **ureters**. The **renal arteries** branch directly from the abdominal aorta, whereas the **renal veins** return blood directly to the inferior vena cava. The vein, artery, and ureter are arranged in an anterior-to-posterior order.

Internal Anatomy

A frontal section through the kidney reveals a thin outer region called the **renal cortex** and an inner region called the **medulla** (Figure 22.2.2A). The **renal columns** are connective tissue extensions that pass through the medulla to separate the most characteristic features of the medulla: the **renal pyramids**. Each of the 8-18 lobes within the human kidney contain a pyramid and the cortex immediately superficial to it, and these can be delineated by following the column radiations to the surface of the kidney. The renal columns also provide a supportive framework for vessels that enter and exit the cortex.

Each renal lobe contains microscopic tubules, called **nephrons**, that filter the blood and produce urine. This urine is gathered by **collecting ducts** passing from the cortex, through the pyramid and terminating in the renal papilla. The **renal papilla** is the apex of the pyramid, located at the boundary between the renal medulla and the minor calyx of the renal collecting system (Figure 22.2.2B). A **minor calyx** surrounds the renal papilla of each pyramid and collects urine from that pyramid. Several minor calyces converge to form a major calyx and the **major calyces** merge to form the **renal pelvis**. The smooth muscle in the renal pelvis funnels urine via peristalsis out of the kidney and into the ureter.

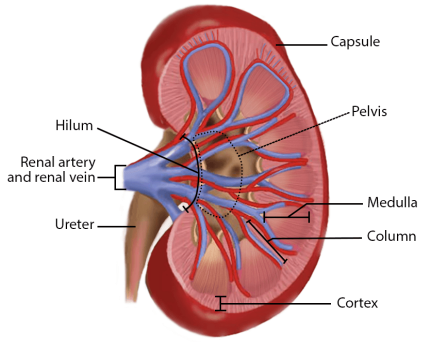

A. Major regions of the kidney

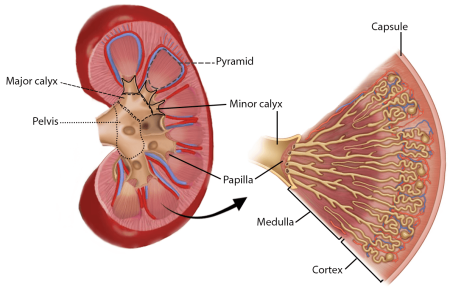

B. Urine collecting structures from each renal lobe

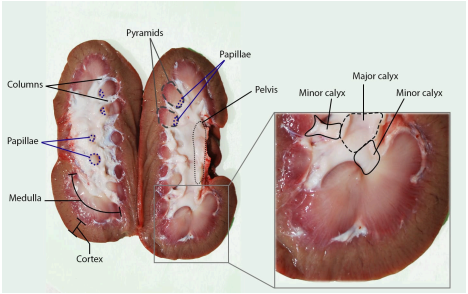

C. Dissected Pig Kidney

Figure 22.2.2: Kidney Sections. These sectional images reveals the outer cortex and inner medulla of the kidney. Located at the hilum are the renal artery, renal vein, and ureter. Urine produced within a single pyramid drains into a minor calyx. Multiple minor calyxes merge to form a major calyx and the multiple major calyces merge to form the renal pelvis. *(Image credits: A. "Kidney Regions and Major Structures" by Jennifer Lange is licensed under CC BY-NC-SA 4.0, modification of original "Slagter - Drawing Anatomy of the urinary system - no labels" by Ron Slagter. B. "Urine Collecting Structures" by Jennifer Lange is -licensed under CC BY-NC-SA 4.0, modification of originals "Slagter - Drawing Anatomy of the urinary system - no labels" by Ron Slagter and "KnowledgeWorks - Drawing Kidney anatomy and detail - English labels" by KnowledgeWorks Global Ltd.. C. "Dissected Pig Kidney" by Jennifer Lange is licensed under CC BY-NC-SA 4.0, modification of photo by John Campbell.)*

Blood Vessels

The renal artery enters the kidney medially, first divides into **segmental arteries** moving toward the medulla, followed by further branching to form **interlobar arteries** that pass through the renal columns to reach the cortex (Figure 22.2.3). The interlobar arteries, in turn, branch into **arcuate arteries** lying between the renal cortex and renal medulla. Arcuate arteries will branch further to form **interlobular** or **cortical radiate arteries** that extends into the cortex, and then branch into **afferent arterioles**. Afferent arterioles lead blood to the beginning of the nephron.

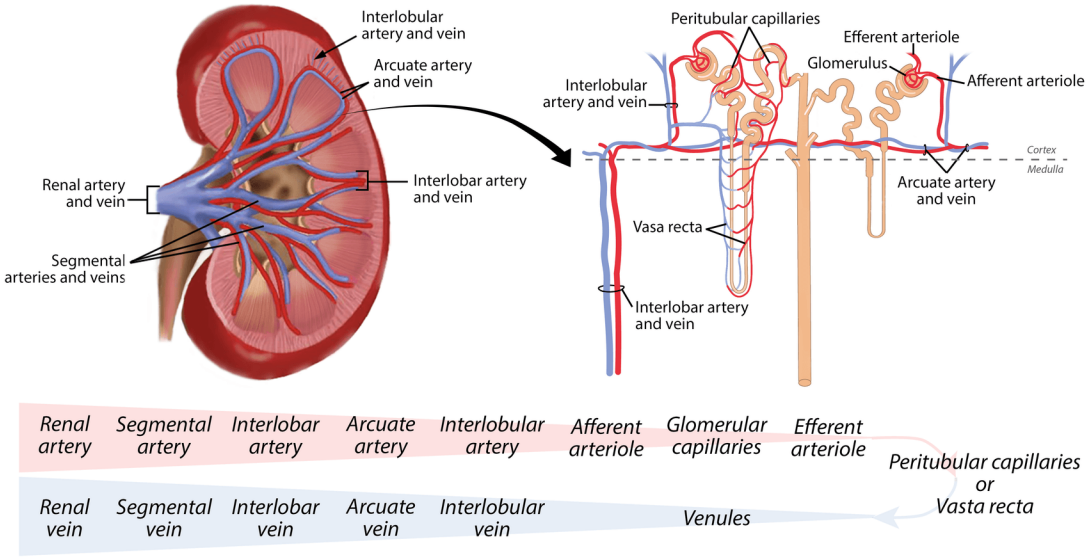

Figure 22.2.3: Blood Flow in the Kidney. Oxygenated blood with waste materials enters the kidney through the renal artery and deoxygenated blood with fewer waste materials exits the kidney in the renal vein. Renal circulation is unique because it will pass through two arterioles and two capillary beds before entering the venous system. *(Image credit: "Renal Vasculature" by Jennifer Lange is licensed under CC BY-NC-SA 4.0, modification of originals "Slagter - Drawing Anatomy of the urinary system - no labels" by Ron Slagter and "Slagter - Drawing Kidney macroscopic and microscopic anatomy - no labels" by Ron Slagter.)*

Nephrons are the "functional units" of the kidney; they cleanse the blood and balance its plasma constituents. The afferent arterioles have higher blood pressure than typical arterioles, and thus have more muscle tissue in their walls. Each afferent arteriole leads to a tuft of fenestrated capillaries about 200 µm in diameter, called the **glomerulus** (Figure 22.2.3). At their distal end the glomerular capillaries form a second arteriole, the **efferent arteriole** that will next form another capillary network around the more distal portions of the nephron tubule, the **peritubular capillaries** (in the cortex) and **vasa recta** (in the medulla). As the glomerular filtrate progresses through the nephron, these capillary networks recover most of the solutes and water and return them to the circulation. Blood from the second capillary beds then empty into venules. These merge to form **interlobular veins**, then **arcuate veins, interlobar veins,** and **segmental veins,** which finally merge to become the **renal vein**. (Figure 22.2.3).

Nephrons

Nephrons are microscopic structures to make urine, thus they are the "functional" units in the kidneys. Each kidney has over 1 million nephrons. Figure 22.2.4 and Figure 22.2.5 show two nephrons and the blood vessels running around them. Each nephron starts in the cortex with the **renal corpuscle**, which has the glomerular capsule surrounding the glomerulus (capillary bed). The glomerular capsule continues as the **proximal convoluted tubule (PCT)** which then straightens out and enters the renal medulla as the **descending limb of the nephron loop.** At various depths within the medulla the nephron loops make a U-turn to become the **ascending limb**. The nephron loop is also called the loop of Henle. The loop will enter the cortex and become the **distal convoluted tubule (DCT)**, the end of the nephron. The content inside, soon to be urine, will continue from the DCT to a collecting duct.

In a dissected kidney identifying the cortex and medulla is easy, as they have different colors and patterns (Figure 22.2.2*C*). Different parts of the nephrons are found in the two regions. All of the renal corpuscles as well as both the proximal convoluted tubules (PCTs) and distal convoluted tubules are found in the cortex. Some nephrons have a short nephron loop that does not dip much beyond the cortex. These nephrons are called **cortical nephrons**. About 15 percent of nephrons have long nephron loops that extend deep into the medulla and are called **juxtamedullary nephrons**. Figure 22.2.4 shows two types of nephrons, cortical and juxtamedullary nephrons, named according to their locations. Details of nephron structure will be discussed in the next section, Section 22.3.

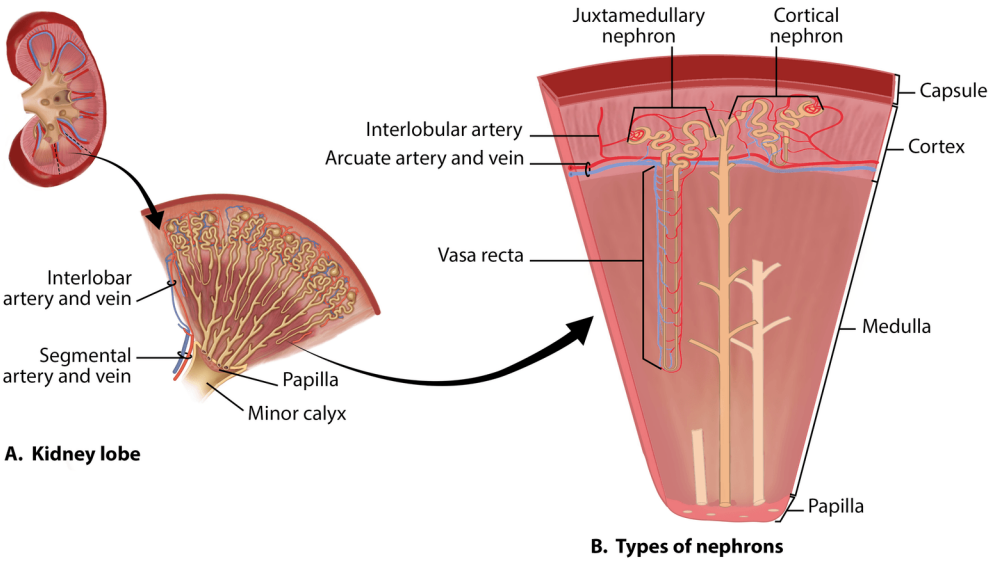

Figure 22.2.4: Renal Lobe and Nephron Types. Each minor calyx receives urine produced within the nephron of a single renal lobe. Within each lobe are thousands of nephrons with varying positions across the cortex and medulla. *(Image credit: "Renal Lobe and Nephron Types" by Jennifer Lange is licensed under CC BY-NC-SA 4.0, modification of originals A. "Slagter - Drawing Anatomy of the urinary system - no labels" by Ron Slagter and "KnowledgeWorks - Drawing Kidney anatomy and detail - English labels" by KnowledgeWorks Global Ltd.; B. "Slagter - Drawing Kidney macroscopic and microscopic anatomy - no labels" by Ron Slagter.)*

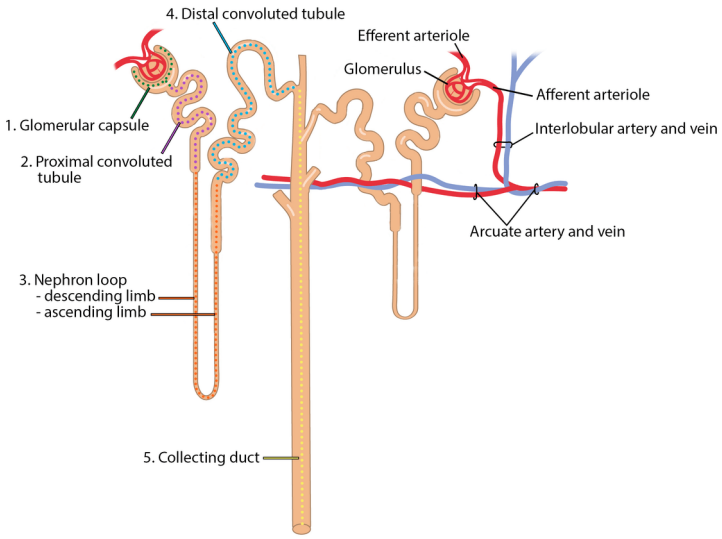

Figure 22.2.5: Nephron Structure. Blood in the glomerular capillaries is filtered into the glomerular capsule. This filtrate is modified as it flows through the nephron regions (in order - proximal convoluted tubule, nephron loop, distal convoluted tubule) and the collecting duct. *(Image credit: "Nephron Structure" by Jennifer Lange is licensed under CC BY-NC-SA 4.0, modification of original "Slagter - Drawing Kidney macroscopic and microscopic anatomy - no labels" by Ron Slagter.)*

Concept Review

As noted previously, the structure of the kidney is divided into two principle regions—the peripheral rim of cortex and the central medulla. The two kidneys receive about 25 percent of cardiac output. They are protected in the retroperitoneal space by the renal fat pad and overlying ribs and muscle. Ureters, blood vessels, lymph vessels, and nerves enter and leave at the renal hilum. The renal arteries arise directly from the aorta, and the renal veins drain directly into the inferior vena cava. Kidney function is derived from the actions of about 1.3 million nephrons per kidney; these are the “functional units.” A capillary bed, the glomerulus, filters

blood and the filtrate is captured by Bowman's capsule. A portal system is formed when the blood flows through a second capillary bed surrounding the proximal and distal convoluted tubules and the loop of Henle. Most water and solutes are recovered by this second capillary bed. This filtrate is processed and finally gathered by collecting ducts that drain into the minor calyces, which merge to form major calyces; the filtrate then proceeds to the renal pelvis and finally the ureters.

Review Questions

Query 22.2.1

This interactive element is not available in this format. Visit the link or scan the QR code to access it online.

View this Interactive Content online

Critical Thinking Questions

Query 22.2.2

This interactive element is not available in this format. Visit the link or scan the QR code to access it online.

View this Interactive Content online

Query 22.2.3

This interactive element is not available in this format. Visit the link or scan the QR code to access it online.

View this Interactive Content online

Glossary

Query 22.2.4

This interactive element is not available in this format. Visit the link or scan the QR code to access it online.

View this Interactive Content online

Contributors and Attributions

- OpenStax Anatomy & Physiology (CC BY 4.0). Access for free at https://openstax.org/books/anatomy-and-physiology

This page titled 22.2: Overview of the Kidney is shared under a CC BY-NC-SA 4.0 license and was authored, remixed, and/or curated by Jennifer Lange et al..

- 22.2: Overview of the Kidney by Whitney Menefee, Julie Jenks, Chiara Mazzasette, and Kim-Leiloni Nguyen is licensed CC BY 4.0.

22.3: Microscopic Anatomy of the Kidney

By the end of the section, you will be able to:

- Describe the structure of the filtration membrane
- Explain the major structures and subdivisions of the renal corpuscles and renal tubules
- Describe the histology of the proximal convoluted tubule, nephron loop, distal convoluted tubule, and collecting duct

The renal structures that conduct the essential work of the kidney cannot be seen by the naked eye. Only a light or electron microscope can reveal these structures. Even then, serial sections and computer reconstruction are necessary to give us a comprehensive view of the functional anatomy of the nephron and its associated blood vessels.

Nephrons: The Functional Unit

Nephrons (Figure 22.3.1) take a simple filtrate of the blood and modify it into urine. Many changes take place in the different parts of the nephron before urine is created for disposal. The term **forming urine** will be used hereafter to describe the filtrate as it is modified into true urine. The principle task of the nephron population is to balance the plasma to homeostatic set points and excrete potential toxins in the urine. They do this by accomplishing three principle functions—filtration, reabsorption, and secretion. They also have additional secondary functions that exert control in three areas: blood pressure (via production of **renin**), red blood cell production (via the hormone EPO), and calcium absorption (via conversion of calcidiol into calcitriol, the active form of vitamin D).

Different parts of the nephron are found in different regions. The renal cortex is easily distinguished from the renal medulla by the presence of renal corpuscles. These easily visualized balls contain the glomerular capillaries and the glomerular capsule. Around the corpuscles, the arrangement of the tubules in the cortex appears to be random. That is because the convoluted tubules twist, turn, and wrap around themselves and the renal corpuscles. Filtrate leaves the glomerular capillaries and enters the capsular space and then flows into the proximal convoluted tubule.

- **Proximal convoluted tubules** (PCT) are the larger tubules in the region composed of simple cuboidal epithelium. The cells of the PCT are larger and have abundant microvilli making up a brush border.
- The **distal convoluted tubule** is also composed of simple cuboidal epithelium. It has a smaller diameter and smaller cells than the PCT and the cells have few microvilli.

The renal medulla lacks renal corpuscles, so visually it only contains long tubules that run mostly parallel to each other. The two regions of the tubule found here both have two types of epithelial tissue in their walls.

The **nephron loop** is a part of the nephron that has thin and thick limbs. The thin descending nephron loop and the thin ascending nephron loop will be made up of simple squamous epithelium. The thick ascending nephron loop is made of simple cuboidal epithelium that lacks a brush border.

- The **collecting duct** (technically not part of the nephron - see below) starts as a simple cuboidal epithelium and transitions to become a simple columnar epithelium as it nears the renal papilla.

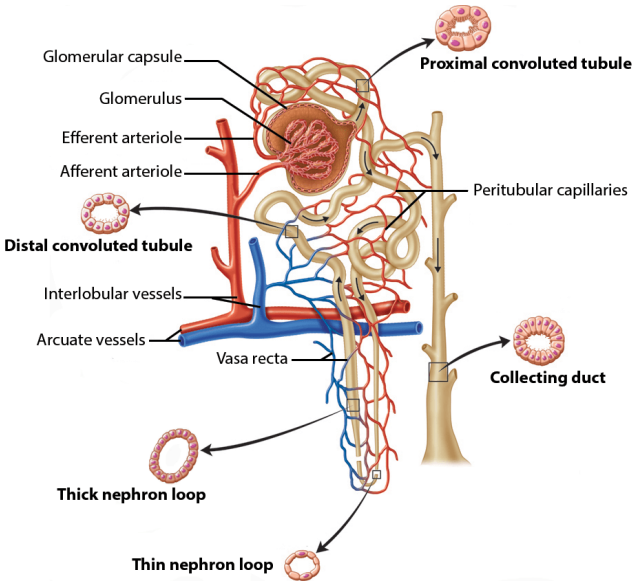

Figure 22.3.1: The Nephron. Nephrons have specialized regions for filtering the blood and then modifying that filtrate into urine. Along the nephron, each region has a slightly different epithelium that reflects the functional role of that region. *(Image credit: "Nephron Structure with Histology Illustration" by Jennifer Lange is licensed under CC BY-SA-NC 4.0, modification of original by Cenveo.)*

Renal Corpuscle

As discussed earlier, the renal corpuscle consists of a tuft of capillaries called the glomerulus that is largely surrounded by the glomerular (Bowman's) capsule. The glomerulus is a high-pressure capillary bed between afferent and efferent arterioles. The glomerular capsule surrounds the glomerulus to form a lumen, and captures and directs this filtrate to the PCT. The outermost part of the glomerular capsule, the parietal layer, is a simple squamous epithelium. It transitions onto the glomerular capillaries in an intimate embrace to form the visceral layer of the capsule. Here, the cells are not squamous, but uniquely shaped cells (**podocytes**) extending finger-like arms (**pedicels**) to cover the glomerular capillaries (Figure 22.3.2). These projections interdigitate to form **filtration slits**, leaving small gaps between the digits to form a sieve. As blood passes through the glomerulus, 10 to 20 percent of the plasma filters between these sieve-like fingers to be captured by the glomerular capsule and funneled to the PCT. Where the fenestrae (windows) in the glomerular capillaries match the spaces between the podocyte "fingers," the only thing separating the capillary lumen and the lumen of the glomerular capsule is their shared basement membrane (Figure 22.3.3). These three features (fenestrated endothelium, basement membrane, and pedicels) comprise what is known as the **filtration membrane**. This membrane permits very rapid movement of filtrate from capillary to capsule.

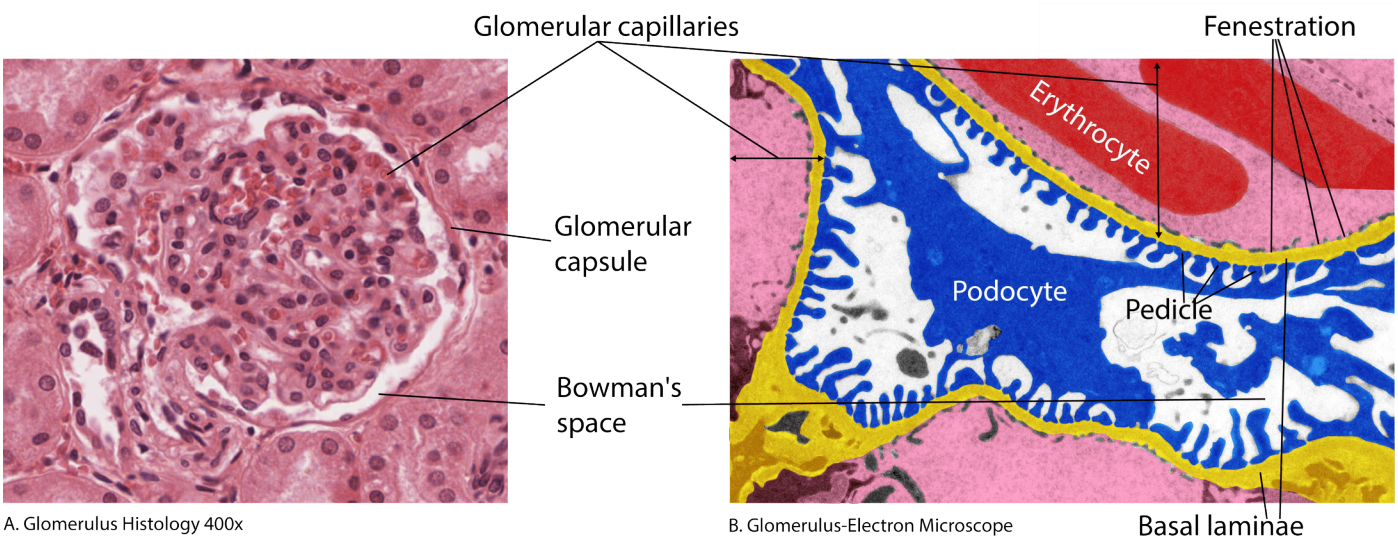

Figure 22.3.2: Renal corpuscle. Histology photograph (A) and electron microscope image (B) images comparing 400x magnification of a glomerulus with an electron microscope. In the electron microscope image you can see the podocyte in the glomerular space with its pedicles. *(Image Credit: "Renal Corpuscle" slide provided by the Regents of the University of Michigan is licensed under CC BY-SA-NC 4.0. Electron microscope from digital histology available under an Attribution-Non-Commercial-Share Alike 4.0 Creative Commons License. Images combined and labeled by Sofia Elizondo . Electron microscope image colored by Sofia Elizondo.)*

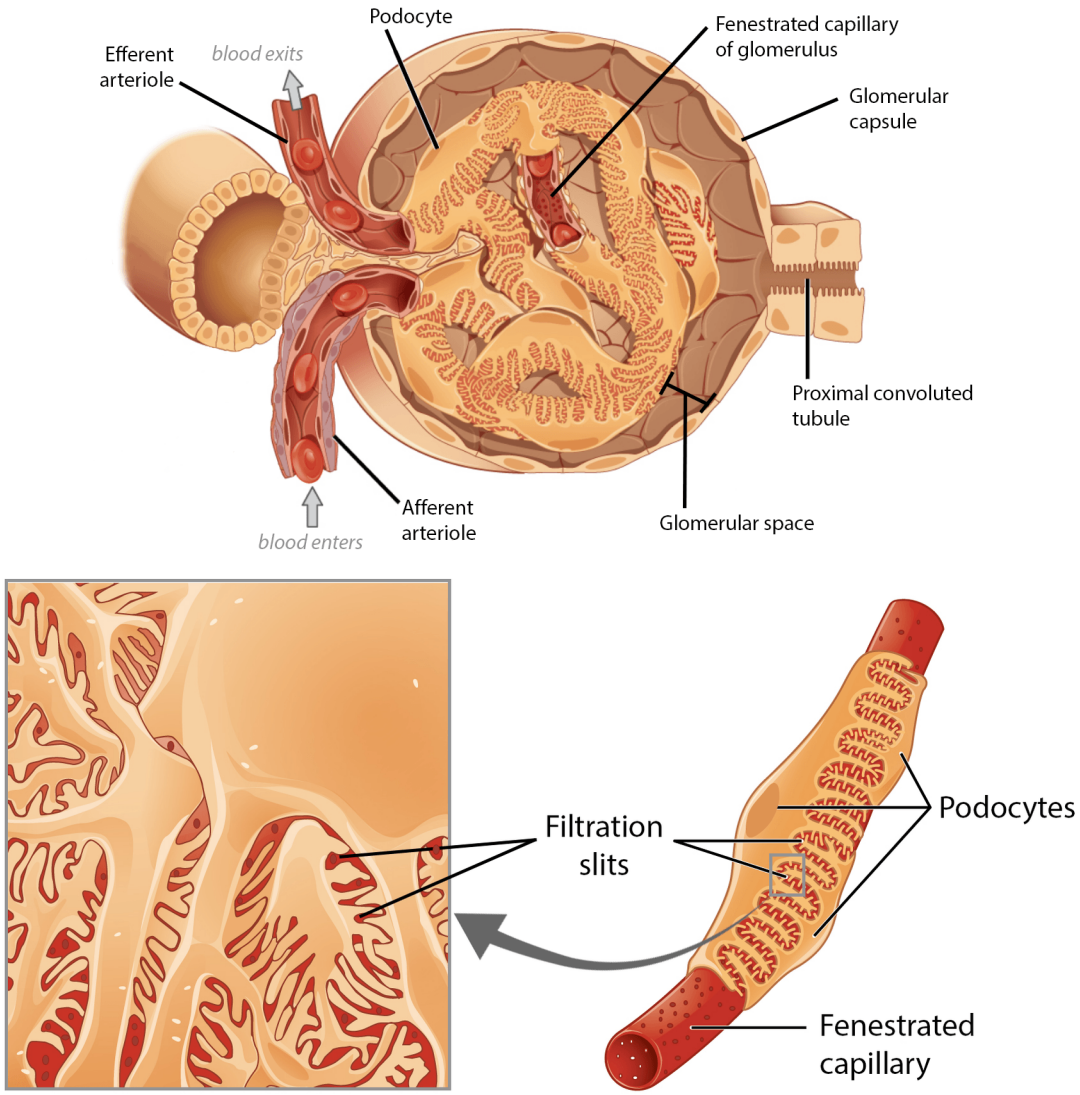

Figure 22.3.3: Filtration Membrane. Filtration of the blood occurs across the filtration membrane, consisting of the fenestrated capillaries and the filtration slits between the podocytes (the visceral layer of the glomerular capsule). Substances can diffuse from the blood into the nephron based on size and electrical charge. *(Image credit: "Filtration Membrane" by Jennifer Lange is licensed under CC BY-SA-NC 4.0, modification of originals Podocytes and Juxtaglomerular Apparatus and Glomerulus by OpenStax.)*

The **fenestrations** prevent filtration of blood cells or large proteins, but allow most other constituents through. These substances cross readily if they are less than 4 nm in size and most pass freely up to 8 nm in size. An additional factor affecting the ability of substances to cross this barrier is their electric charge. The proteins associated with these pores are negatively charged, so they tend to repel negatively charged substances and allow positively charged substances to pass more readily. The basement membrane prevents filtration of medium-to-large proteins such as globulins. Overall, filtration is regulated by fenestrations in capillary endothelial cells, podocytes with filtration slits, membrane charge, and the basement membrane between capillary cells. The result is the creation of a filtrate that does not contain cells or large proteins, and has a slight predominance of positively charged substances.

Proximal Convoluted Tubule

Filtered fluid collected by the glomerular capsule enters into the proximal convoluted tubule. It is called convoluted due to its contorted path. The simple cuboidal cells forming this tubule with prominent microvilli on the luminal surface, forming a **brush border**. These microvilli create a large surface area to maximize the reabsorption and secretion of solutes (Na^+, Cl^-, glucose, etc.), the most essential function of this portion of the nephron. These cells actively transport ions across their membranes so

they possess a large number of mitochondria in order to produce sufficient ATP and abundant rough endoplasmic reticulum (rER) and Golgi apparatus to produce the protein transporters. Because of the large number of organelles, these cells are larger than a typical cuboidal epithelial cell and their cytoplasm stains more readily (Figure 22.3.4).

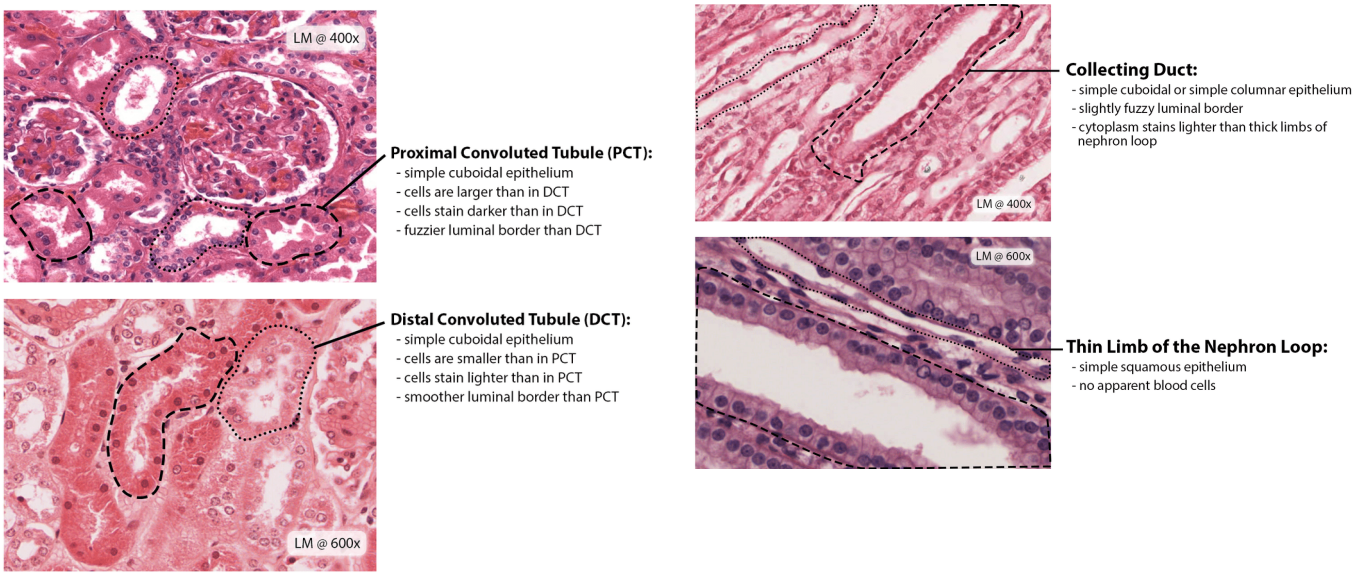

Figure 22.3.4: Histology of the Renal Cortex and Renal Medulla. In addition to the renal corpuscles, the cortex of the kidney contains the proximal and distal convoluted tubules (both simple cuboidal epithelial tissue). The deep medulla of the kidney contains the thin limbs of the nephron loop (simple squamous epithelial tissue) and the collecting ducts (simple cuboidal or columnar epithelial tissue). *(Image Credit: "Renal Cortex Histology" and "Renal Medulla Histology" by Jennifer Lange are licensed under CC BY-SA-NC 4.0, slides provided by the Regents of the University of Michigan © 2022 under CC BY-NC-SA 3.0.)*

Nephron Loop

The nephron tubule continues and becomes the descending and ascending portions of the nephron loop (of Henle). These limbs run adjacent and parallel to each other as they make a hairpin turn at the deepest point of their descent. The descending limb consists of an initial short, thick portion and long, thin portion. The ascending loop consists of an initial short, thin portion followed by a long, thick portion.

- The descending thick portion consists of simple cuboidal epithelium similar to that of the PCT.
- The descending and ascending thin portions consists of simple squamous epithelium (Figure 22.3.4).
- The ascending thick portion consists of simple cuboidal epithelium similar to the DCT.

These variations in cell type are important, since different portions of the loop have different permeabilities for solutes and water. The thin portions exchange salts and water by passive diffusion, while the thick portions utilize active transport.

Distal Convoluted Tubule

The distal convoluted tubule, like the PCT, is very contorted and formed by simple cuboidal epithelium. These cells are not as active in reabsorption and secretion as those in the PCT, thus less surface are is needed. Accordingly, the DCT is shorter than the PCT and its cells have fewer microvilli on the apical surface. However, these cells must also pump ions against their concentration gradient, so you will find of large numbers of mitochondria, rER, and Golgi apparatus, although fewer than in the PCT. The functional difference results in an alteration of the structure, which can be seen on a slide. The DCT has cuboidal epithelial cells that are smaller and lighter staining than the PCT and their luminal border is less fuzzy and cleaner appearing (Figure 22.3.4).

Collecting Duct System

Connecting tubules are the initial segment of the collecting duct system. Located in the cortex they area continuous with the nephron but not technically part of it in humans, as recent research (Sarkany & Kovacs, 2021) has determined their embryonic origin is shared with the ureters and not with the kidney proper. Each connecting tubule connects a single nephron to a collecting

duct and each collecting duct gathers filtrate from several nephrons for final modification. Collecting ducts start in the cortex and shortly enter the medulla. As they descend deeper in the medulla they merge to form about 30 terminal ducts, which empty at a papilla into the minor calyx.

Collecting ducts initially are lined with simple cuboidal epithelial cells (Figure 22.3.4) with receptors for ADH. When stimulated by ADH, these cells will insert **aquaporin** channel proteins into their membranes, which as their name suggests, allow water to pass from the duct lumen through the cells and into the interstitial spaces to be recovered by the vasa recta (Figure 22.3.1). This process allows for the recovery of large amounts of water from the filtrate back into the blood. In the absence of ADH, these channels are not inserted, resulting in the excretion of water in the form of dilute urine. Deeper in the medulla, simple columnar epithelial cells become more numerous and increase in size. These cells primarily function in acid-base balance through the reabsorption of bicarbonate (HCO_3^-) and secretion of hydrogen ions (H^+).

Juxtaglomerular Apparatus

Lying just outside the glomerular capsule and the glomerulus is the **juxtaglomerular apparatus (JGA).** At the juncture where the afferent and efferent arterioles enter and leave the glomerular capsule capsule, the initial part of the distal convoluted tubule (DCT) comes into direct contact with the arterioles. The wall of the DCT at that point forms a part of the JGA known as the **macula densa**. This cluster of cuboidal epithelial cells monitors the fluid composition of fluid flowing through the DCT (Figure 22.3.5).

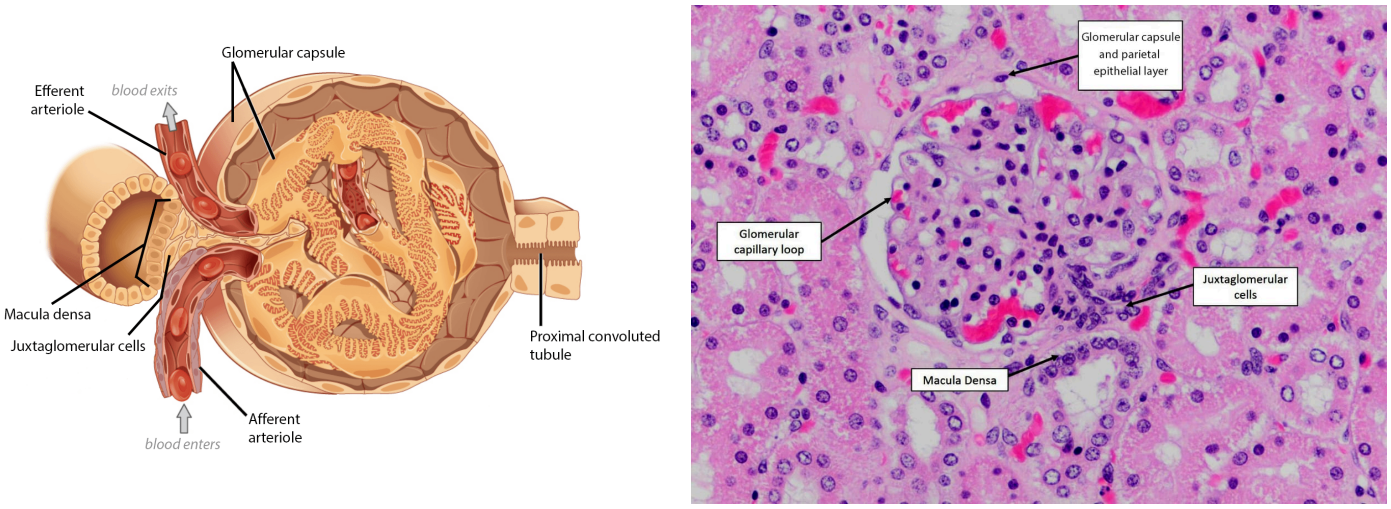

Figure 22.3.5: Juxtaglomerular Apparatus. The juxtaglomerular apparatus (JGA) controls the rate of the glomerular blood flow depending on factors such as hydration, blood volume and ion concentration. The JGA includes the macula densa (part of the DCT) and juxtaglomerular cells. *(Image credits: "Juxtaglomerular Apparatus Illustration" by Jennifer Lange is licensed under CC BY-SA-NC 4.0, modification of original Juxtaglomerular Apparatus and Glomerulus by OpenStax. "Juxtaglomerular Apparatus Histology" by Ryan Jennings and Christopher Premanandan is licensed under CC BY-NC 4.0, modifications by Jennifer Lange.)*

A second cell type in this apparatus is the **juxtaglomerular cell**. This is a modified, smooth muscle cell lining the afferent arteriole that can contract or relax in response to ATP or adenosine released by the macula densa. Such contraction and relaxation regulate blood flow to the glomerulus. A second function of the macula densa cells is to regulate **renin** release from the juxtaglomerular cells of the afferent arteriole. Renin and hormones such as **antidiuretic hormone (ADH)** and **aldosterone** regulate blood pressure by adjusting the amount of water retained by the kidneys.

Renal Medulla

The renal medulla is deep to the cortex. It contains several parallel tubular structures that are involved in the retention of water and ions. These structures, some of which were describe above (Figure 22.3.4), include:

- **Collecting ducts**. Composed of lightly stained simple cuboidal cells with clear borders.
- **Ascending thick limb of nephron loop**.Darker staining cells with a less clear border.
- **Thin segments of nephron loop**. Simple squamosal cells whose nuclei are observed to protrude into the lumen. (No observable blood cells; if blood cells are seen this is a capillary!)

- **Vasa recta**. Capillaries containing numerous blood cells. (Not highlighted on slide).

Concept Review

The functional unit of the kidney, the nephron, consists of the renal corpuscle, PCT, loop of Henle, and DCT. The glomerulus is a capillary bed that filters blood principally based on particle size. The filtrate is captured by Bowman's capsule and directed to the PCT. A filtration membrane is formed by the fused basement membranes of the podocytes and the capillary endothelial cells that they embrace. Contractile mesangial cells further perform a role in regulating the rate at which the blood is filtered. Specialized cells in the JGA produce paracrine signals to regulate blood flow and filtration rates of the glomerulus. Other JGA cells produce the enzyme renin, which plays a central role in blood pressure regulation. The filtrate enters the PCT where absorption and secretion of several substances occur. The descending and ascending limbs of the loop of Henle consist of thick and thin segments. Absorption and secretion continue in the DCT but to a lesser extent than in the PCT. Each collecting duct collects forming urine from several nephrons and responds to the posterior pituitary hormone ADH by inserting aquaporin water channels into the cell membrane to fine tune water recovery.

Review Questions

Query 22.3.1

This interactive element is not available in this format. Visit the link or scan the QR code to access it online.

View this Interactive Content online

Critical Thinking Questions

Query 22.3.2

This interactive element is not available in this format. Visit the link or scan the QR code to access it online.

View this Interactive Content online

Query 22.3.3

This interactive element is not available in this format. Visit the link or scan the QR code to access it online.

View this Interactive Content online

Glossary

Query 22.3.4

This interactive element is not available in this format. Visit the link or scan the QR code to access it online.

View this Interactive Content online

Contributors and Attributions

- Sarkany B, Kovacs G. Connecting tubules develop from the tip of the ureteric bud in the human kidney. Histochem Cell Biol. 2021 Dec;156(6):555-560. doi: 10.1007/s00418-021-02033-5. Epub 2021 Sep 23. PMID: 34554322.
- OpenStax Anatomy & Physiology (CC BY 4.0). Access for free at https://openstax.org/books/anatomy-and-physiology

This page titled 22.3: Microscopic Anatomy of the Kidney is shared under a CC BY-NC-SA 4.0 license and was authored, remixed, and/or curated by Jennifer Lange et al..

- 22.3: Microscopic Anatomy of the Kidney by Whitney Menefee, Julie Jenks, Chiara Mazzasette, and Kim-Leiloni Nguyen is licensed CC BY 4.0.

22.4: Urinary Tract

By the end of the section, you will be able to:

- Identify the ureters, urinary bladder, and urethra, as well as their location, structure, histology, and function
- Compare and contrast male and female urethras
- Name the structures involved in the micturition reflex

The urinary system has a **urinary tract ,** tubular structures through which urine passes, that includes the **ureters, urinary bladder**, and **urethra**. This section will start with urine excretion, tracing the flow of urine from the renal pelvis to ureter, urinary bladder, and urethra. Urine is a fluid of variable composition that requires specialized structures to remove it from the body safely and efficiently. Blood is filtered, and the filtrate is transformed into urine at a relatively constant rate throughout the day. This processed liquid is stored until a convenient time for excretion. All structures involved in the transport and storage of the urine are large enough to be visible to the naked eye. This transport and storage system not only stores the waste, but it protects the tissues from damage, prevents infection by foreign organisms, and for the male, provides reproductive functions.

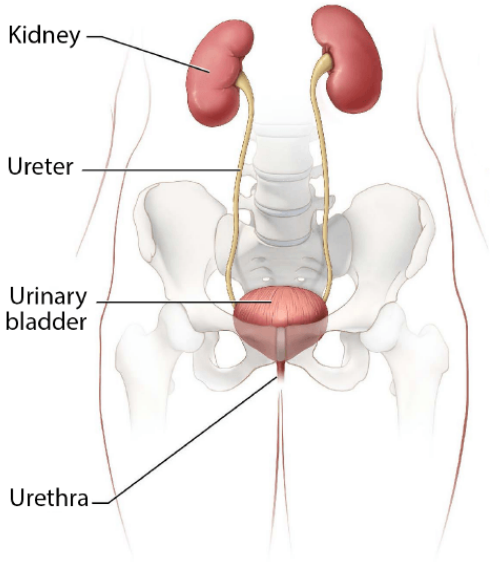

Figure 22.4.1: Urinary Tract Organs. The organs of the urinary tract transport, store, and void urine. *(Image credit: "Organs of the Urinary System" by NIH Medial Arts is licensed under CC-BY-NC 2.0.)*

Ureters

As urine is formed it drains into the calyces of the kidney, which merge to form the funnel-shaped renal pelvis in the hilum of each kidney. The pelvis narrows to become the ureter of each kidney (Figure 22.4.2B). As urine passes through the ureter, it does not passively drain into the bladder but rather is propelled by waves of peristalsis. As the ureters enter the pelvis, they sweep laterally, hugging the pelvic walls (Figure 22.4.2A). As they approach the bladder, they turn medially and pierce the bladder wall obliquely. This is important because it creates an one-way valve that allows urine into the bladder but prevents reflux of urine from the bladder back into the ureter. Children born lacking this oblique course of the ureter through the bladder wall are susceptible to "vesicoureteral reflux," which dramatically increases their risk of serious UTI. Pregnancy also increases the likelihood of reflux and UTI.

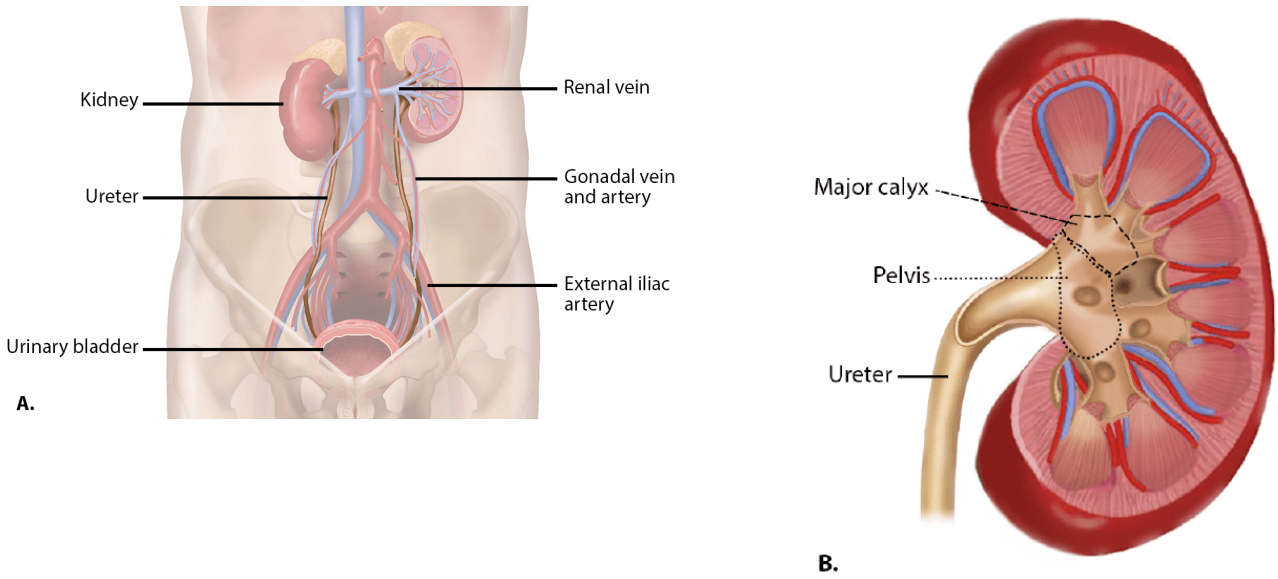

Figure 22.4.2: Ureters. The ureters emerge medially from the hilum of the kidney and travel along the posterior abdominal and pelvic walls along with several major arteries and veins (A). Each ureter is a continuation of the renal pelvis (B). *(Image credits: "Ureters and Surrounding Vessels" by Jennifer Lange is licensed under CC BY-NC-SA 4.0, modification of original by Ron Slagter; "Kidney Section with Ureter" by Jennifer Lange is licensed under CC BY-NC-SA 4.0, modification of original by Ron Slagter.)*

The ureters are approximately 30 cm long. The inner mucosa is lined with transitional epithelium containing dome (or umbrella) cells that flatten as urine passes (Figure 22.4.3). The lamina propria is loose adjacent to the epithelium and becomes denser as it approaches the muscularis externa. The muscular layer of the ureter consists of longitudinal and circular smooth muscles that create the peristaltic contractions to move the urine into the bladder without the aid of gravity. Finally, a loose adventitial layer composed of collagen and fat anchors the ureters between the parietal peritoneum and the posterior abdominal wall.

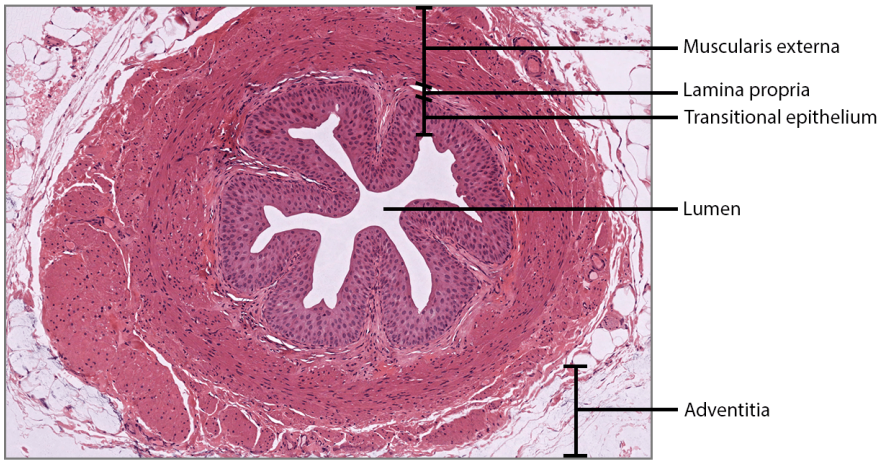

Figure 22.4.3: Ureter Histology @ 100x. The ureters are muscular tubes lined with a transitional epithelium. *(Image credit: "Ureter Histology @ 100x" by Jennifer Lange is licensed under CC BY-NC-SA 4.0, micrographs provided by Virginia Commonwealth University under CC BY-NC-SA 4.0.)*

Urinary Bladder

The urinary bladder collects urine from both ureters (Figure 22.4.4). The ureters enter on the inferior-posterior wall on either side of the urethra. The three openings form a structure called the trigone which is smooth unlike the rest of the mucosal lining of the bladder. The bladder lies anterior to the uterus in females, posterior to the pubic bone and anterior to the rectum. During

late pregnancy, its capacity is reduced due to compression by the enlarging uterus, resulting in increased frequency of urination. In males, the anatomy is similar, minus the uterus, and with the addition of the prostate inferior to the bladder. The bladder is partially **retroperitoneal** (outside the peritoneal cavity) with its peritoneal-covered "dome" projecting into the abdomen when the bladder is distended with urine.

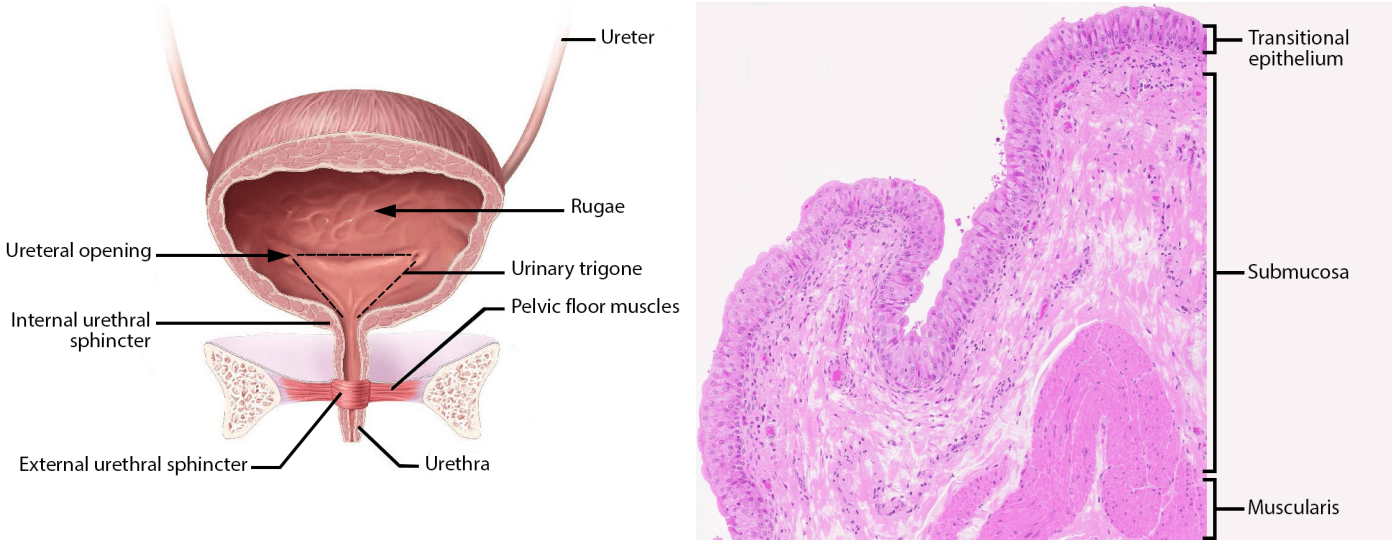

Figure 22.4.4: Urinary Bladder. The wall of the urinary bladder is structurally specialized to accommodate expansion as it fills with urine. *(Image credits: "Urinary Bladder Gross Anatomy - Female" by Jennifer Lange is licensed under CC BY-NC-SA 4.0, modification of original "Organs of the Urinary System" by NIH Medial Arts. "Urinary Bladder Histology @ 100x" by Jennifer Lange is licensed under CC BY-NC-SA 4.0,slide provided by the Regents of the University of Michigan Medical School © 2022 under CC BY-NC-SA 3.0.)*

The urinary bladder is a highly distensible organ because the middle layer is comprised of irregular crisscrossing bands of smooth muscle. The interior surface is made of transitional epithelium that is structurally suited for the large volume fluctuations of the bladder. When empty it resembles cuboidal epithelia, but when stretched it "transitions" (hence the name) to a squamous appearance (Figure 22.4.4. Similar to the stomach, most of the mucosal layer has rugae which aid in expansion. Volumes in adults can range from nearly zero to 500–600 mL. The bladder's strength diminishes with age, but voluntary contractions of abdominal skeletal muscles can increase intra-abdominal pressure to promote more forceful bladder emptying.

Urethra

The **urethra** transports urine from the bladder to the outside of the body for disposal. The urethra is the only urologic organ that shows any significant anatomic difference between males and females; all other urine transport structures are identical (Figure 22.4.5).

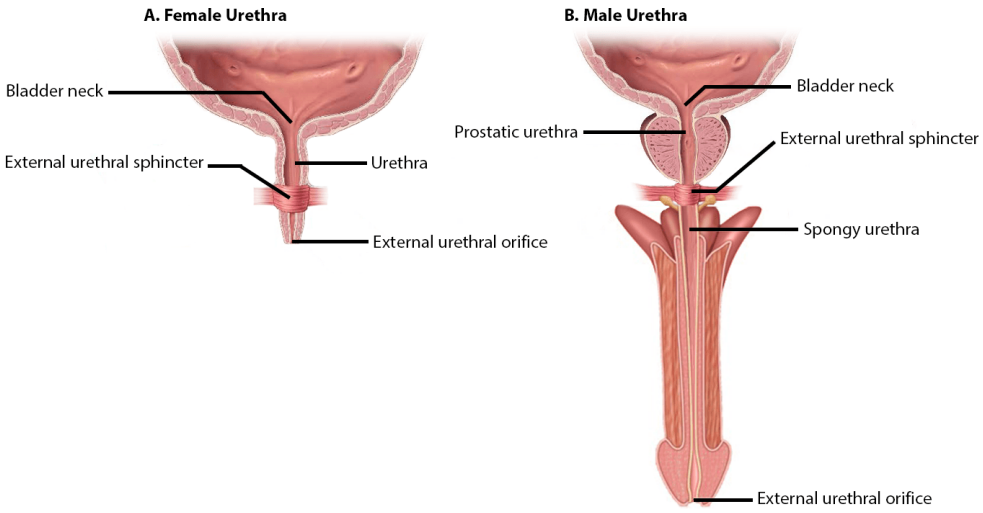

Figure 22.4.5: Comparison of the Female and Male Urethra. The urethra transports urine from the urinary bladder to the outside of the body. The female urethra (A) is short, as it only passes through the pelvic floor before reaching the external surface. The majority of the male urethra (B) is shared by the urinary and reproductive systems and, thus, is longer because it passes through both the prostate gland and the penis. *(Image credit: "Urethra Comparison - Male and Female" by Jennifer Lange is licensed under CC BY-NC-SA 4.0. Modification of originals "Organs of the Urinary System" by NIH Medial Arts and "Cenveo - Drawing Male and female urinary tract - English labels" by Cenveo.)*

The urethra in both males and females begins inferior and central to the two ureteral openings forming the three points of a triangular-shaped area at the base of the bladder called the **trigone** (Greek tri- = “triangle” and the root of the word “trigonometry”). The urethra tracks posterior and inferior to the pubic symphysis. In both males and females, the proximal urethra is lined by transitional epithelium, whereas the terminal portion is a nonkeratinized, stratified squamous epithelium. Voiding is regulated by an involuntary autonomic nervous system-controlled **internal urinary sphincter**, consisting of smooth muscle and voluntary skeletal muscle that forms the **external urinary sphincter** below it.

Female Urethra

The external urethral orifice is embedded in the anterior vaginal wall inferior to the clitoris, superior to the vaginal opening, and medial to the labia minora. Its short length, about 4 cm, is less of a barrier to fecal bacteria than the longer male urethra and the best explanation for the greater incidence of UTI in women. Voluntary control of the external urethral sphincter is a function of the pudendal nerve that arises in the sacral region of the spinal cord.

Male Urethra

The male urethra passes through the prostate gland immediately inferior to the bladder before passing below the pubic symphysis. The length of the male urethra varies between men but averages 20 cm in length. It is divided into four regions: the **preprostatic urethra**, the **prostatic urethra**, the **membranous urethra**, and the **spongy** or **penile urethra**. The preprostatic urethra is very short and incorporated into the bladder wall. The prostatic urethra passes through the prostate gland. The membranous urethra passes through the deep muscles of the perineum, where passage through is controlled by the external urethral sphincter. The spongy urethra exits at the tip (external urethral orifice) of the penis after passing through the corpus spongiosum. Mucous glands are found along much of the length of the urethra and protect the urethra from extremes of urine pH. Innervation is the same as in females.

Micturition Reflex

Micturition is a less-often used, but proper term for urination or voiding. It results from an interplay of involuntary and voluntary actions by the internal and external urethral sphincters. When bladder volume reaches about 150 mL, an urge to void is sensed

but is easily overridden. Voluntary control of urination relies on consciously preventing relaxation of the external urethral sphincter to maintain urinary continence. As the bladder fills, subsequent urges become harder to ignore. Ultimately, voluntary constraint fails with resulting **incontinence**, which will occur as bladder volume approaches 300 to 400 mL.

Normal micturition is a result of stretch receptors in the bladder wall that transmit nerve impulses to the sacral region of the spinal cord to generate a spinal reflex. The resulting parasympathetic neural outflow causes contraction of the detrusor muscle and relaxation of the involuntary internal urethral sphincter. At the same time, somatic motor neurons are inhibited, resulting in the relaxation of the skeletal muscle of the external urethral sphincter. The micturition reflex is active in infants but, with maturity, children learn to override the reflex by asserting external sphincter control, thereby delaying voiding (potty training). This reflex may be preserved even in the face of spinal cord injury that results in paraplegia or quadriplegia. However, relaxation of the external sphincter may not be possible in all cases, and therefore, periodic catheterization may be necessary for bladder emptying.

DISORDERS OF THE...

Urinary Tract

Difficulties voiding may require catheterization so that urine does not back up and cause damage to the kidneys. A urinary catheter is a flexible tube inserted into the bladder through the urethra to allow urine to drain from the bladder for collection in a bag. A health professional usually performs the procedure, but self-catheterization is also possible for those with chronic conditions. A catheter may be in place for long periods of time (indwelling catheter) or removed after each use (intermittent catheterization). The most common type of indwelling catheter is a Foley catheter that is retained in place by means of a balloon tip. The balloon is deflated for Foley catheter removal. Intermittent catheters do no have the balloon and cannot be anchored in place.

Specific reasons a urinary catheter may be used include:

- urethral obstruction because of scarring or prostate enlargement, for example
- bladder weakness or nerve damage that affects your ability to urinate
- to drain the bladder during childbirth if you have an epidural anaesthetic
- to drain the bladder before, during, and/or after some types of surgery
- a last resort treatment for urinary incontinence when other types of treatment have been unsuccessful

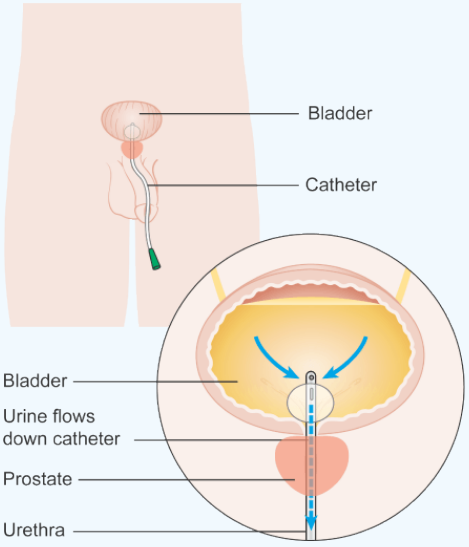

Figure 22.4.6: Foley Catheter. A urinary catheter is placed in the bladder to provide passage for urine. Foley catheters have a balloon below the intake opening that is inflated to keep the catheter in place within the urinary tract. *(Image credit: "Urinary Catheter" by Cancer Research UK is licensed under CC BY-SA 4.0, via Wikimedia Commons.)*

Concept Review

The ureters are retroperitoneal and lead from the renal pelvis of the kidney to the trigone area at the base of the bladder. A thick muscular wall consisting of longitudinal and circular smooth muscle helps move urine toward the bladder by way of peristaltic contractions.The bladder is largely retroperitoneal and can hold up to 500–600 mL urine. The urethra is the only urinary structure that differs significantly between males and females. This is due to the dual role of the male urethra in transporting both urine and semen. The urethra arises from the trigone area at the base of the bladder. Urination is controlled by an involuntary internal sphincter of smooth muscle and a voluntary external sphincter of skeletal muscle. The shorter female urethra contributes to the higher incidence of bladder infections in females. Micturition is the process of voiding the urine and involves both involuntary and voluntary actions. Loss of control of micturition is called incontinence and results in voiding when the bladder contains about 250 mL urine.

Review Questions

Query 22.4.1

This interactive element is not available in this format. Visit the link or scan the QR code to access it online.

View this Interactive Content online

Critical Thinking Questions

Query 22.4.2

This interactive element is not available in this format. Visit the link or scan the QR code to access it online.

View this Interactive Content online

Query 22.4.3

This interactive element is not available in this format. Visit the link or scan the QR code to access it online.

View this Interactive Content online

Glossary

Query 22.4.4

This interactive element is not available in this format. Visit the link or scan the QR code to access it online.

View this Interactive Content online

Contributors and Attributions

- OpenStax Anatomy & Physiology (CC BY 4.0). Access for free at https://openstax.org/books/anatomy-and-physiology

This page titled 22.4: Urinary Tract is shared under a CC BY-NC-SA 4.0 license and was authored, remixed, and/or curated by Jennifer Lange et al..

- 22.4: Urinary Tract by Whitney Menefee, Julie Jenks, Chiara Mazzasette, and Kim-Leiloni Nguyen is licensed CC BY 4.0.
- 8.7: Anatomy of Selected Synovial Joints by Whitney Menefee, Julie Jenks, Chiara Mazzasette, and Kim-Leiloni Nguyen is licensed CC BY 4.0.

22.5: Anatomical Atlas - Urinary System

Right clicking (pc)/ command clicking (mac) most of photos will give you to open them in an new tab. This will be a larger version of the photos.

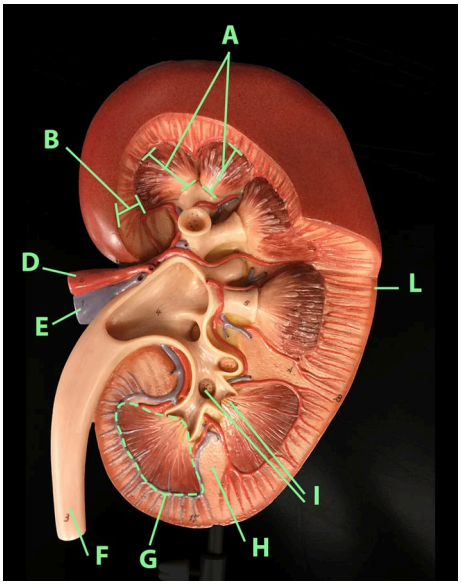

Image Credit

"Kidney Model Gross Structure - Atlas" by Jennifer Lange is licensed under CC BY-NC-SA 4.0.

Answer Key (click to show/hide answers)

A - medulla

B - cortex

D - renal artery

E - renal vein

F - ureter

G - renal pyramid

H - renal column

I - renal papillae

L - renal capsule

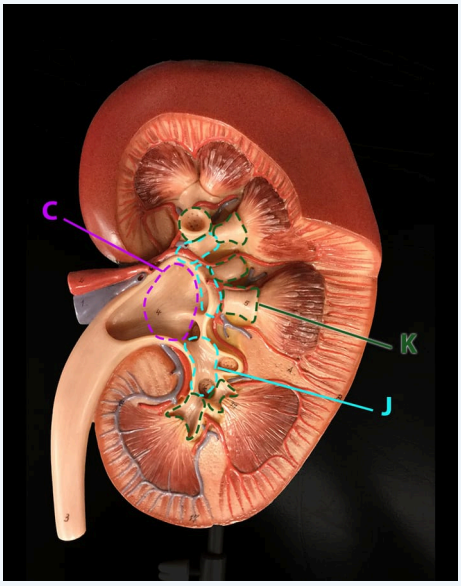

Image Credit

"Kidney Model Ducts - Atlas" by Jennifer Lange is licensed under CC BY-NC-SA 4.0.

Answer Key (click to show/hide answers)

C - renal pelvis

J - major calyces

K - minor calyces

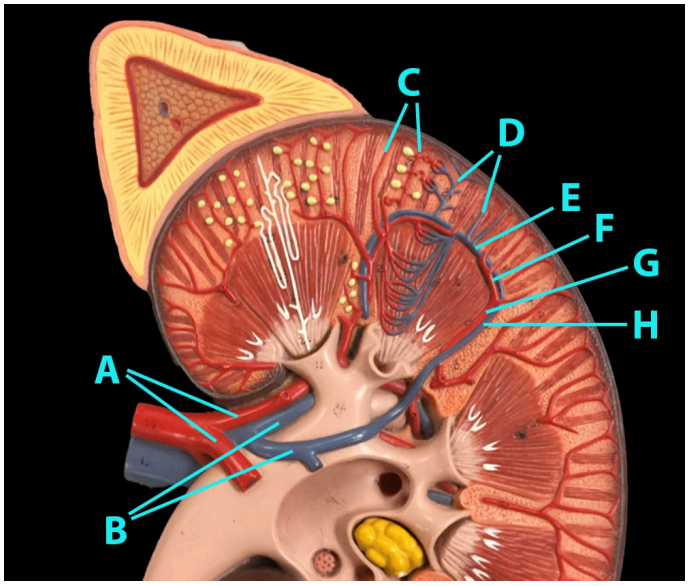

Image Credit

"Flat Kidney Model Blood Vessels- Atlas" by Jennifer Lange is licensed under CC BY-NC-SA 4.0.

Answer Key (click to show/hide answers)

A - segmental arteries

B - segmental veins

C - interlobular arteries

D - interlobular veins

E - arcuate vein

F - arcuate artery

G - interlobar artery

H - interlobar vein

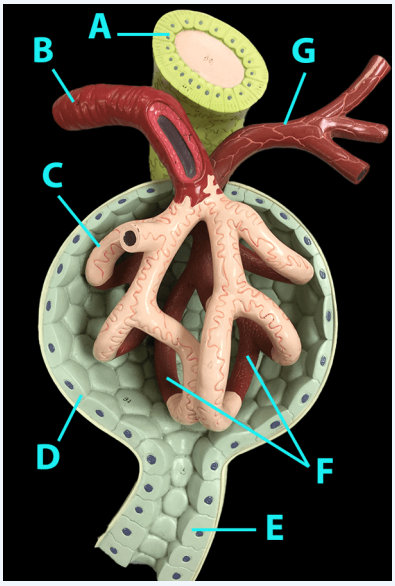

Image Credit

"Flat Kidney Model Corpuscle - Atlas" by Jennifer Lange is licensed under CC BY-NC-SA 4.0.

Answer Key (click to show/hide answers)

A - distal convoluted tubule

B - afferent arteriole

C - podocyte, visceral layer of glomerular capsule covering capillary

D - glomerular (Bowman's) capsule

E - proximal convoluted tubule

F - glomerular capillaries

G - efferent arteriole

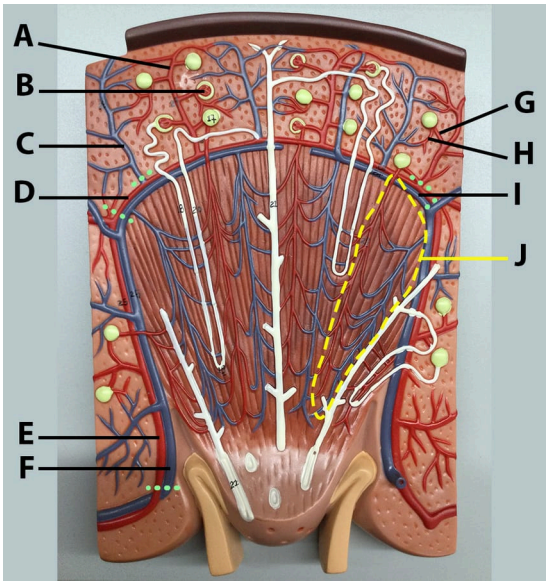

Image Credit

"Flat Kidney Model Lobe - Blood Vessels - Atlas" by Jennifer Lange is licensed under CC BY-NC-SA 4.0.

Answer Key (click to show/hide answers)

A - interlobular artery

B - glomerular capillaries/ glomerulus

C - interlobular vein

D - arcuate artery

E - interlobar artery

F - interlobar vein

G - afferent arteriole

H - efferent arteriole

I - arcuate vein

J - vasa recta

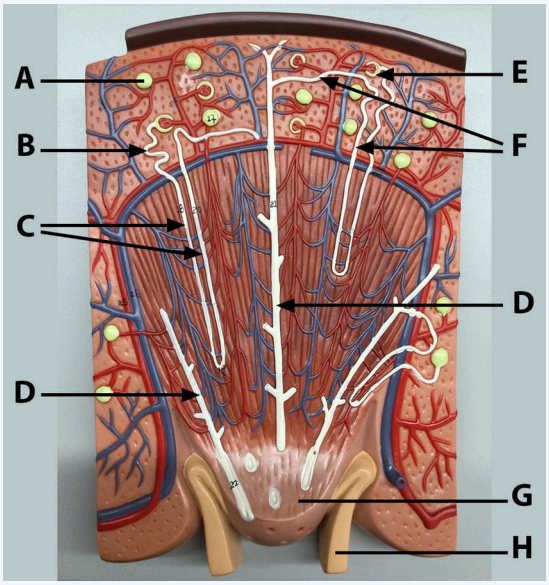

Image Credit

"Flat Kidney Model Lobe - Nephron - Atlas" by Jennifer Lange is licensed under CC BY-NC-SA 4.0.

Answer Key (click to show/hide answers)

A - corpuscle

B - proximal convoluted tubule

C - descending and ascending limbs of the nephron loop (of Henle)

D - collecting duct

E - glomerular (Bowman's) capsule

F - distal convoluted tubule

G - renal papilla

H - minor calyx

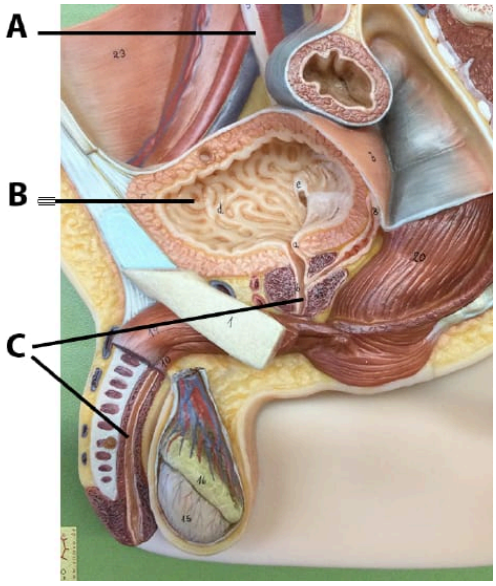

Image Credit

"Male Pelvis Model - Urinary Organs - Atlas" by Jennifer Lange is licensed under CC BY-NC-SA 4.0.

Answer Key (click to show/hide answers)

A - ureter (right)

B - urinary bladder

C - urethra

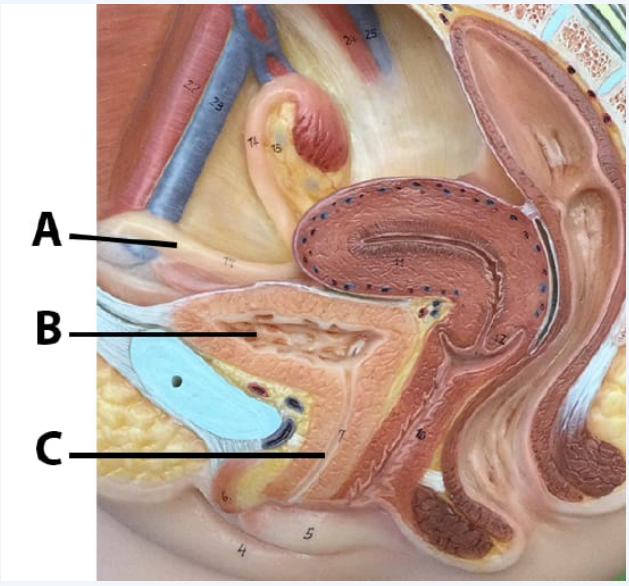

Image Credit

"Female Pelvis Model - Urinary Organs - Atlas" by Jennifer Lange is licensed under CC BY-NC-SA 4.0.

Answer Key (click to show/hide answers)

A - ureter (right)

B - urinary bladder

C - urethra

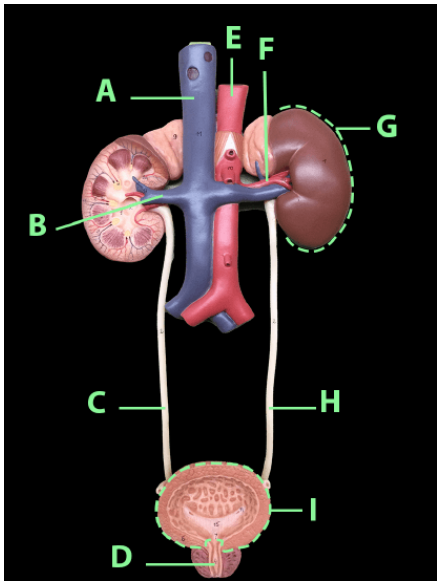

Image Credit

"Urinary System Model Organs - Atlas" by Jennifer Lange is licensed under CC BY-NC-SA 4.0.

Answer Key (click to show/hide answers)

A - inferior vena cava

B - renal vein (right)

C - ureter (right)

D - urethra

E - abdominal aorta

F - renal artery (left)

G - kidney (left)

H - ureter (left)

I - urinary bladder

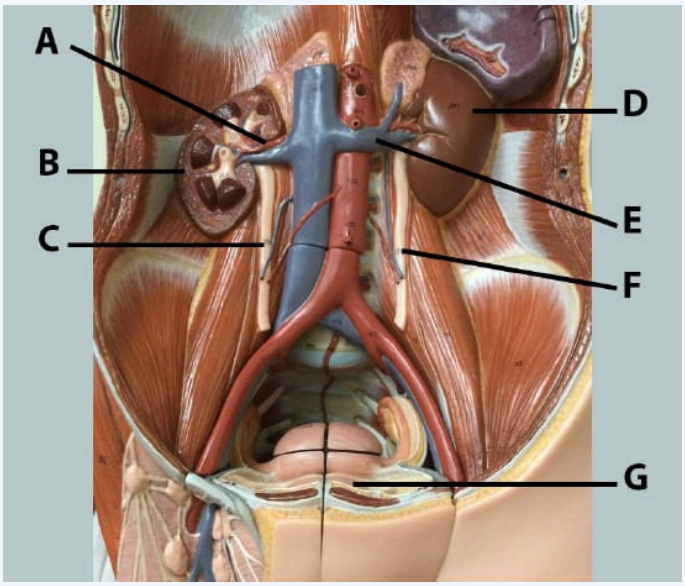

Image Credit

"Torso Model Abdomen and Pelvis - Urinary Organs - Atlas" by Jennifer Lange is licensed under CC BY-NC-SA 4.0.

Answer Key (click to show/hide answers)

A - renal artery (right)

B - kidney (right)

C - ureter (right)

D - kidney (left)

E - renal vein (left)

F - ureter (left)

G - urinary bladder

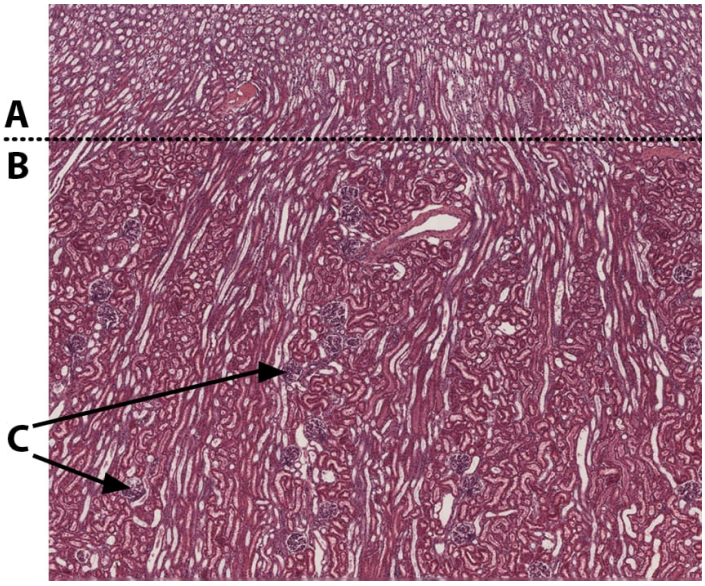

Image credit:

"Histology of the Kidney @ 40x" slide provided by the Regents of the University of Michigan Medical School under CC BY-NC-SA 4.0 © 2022, labeling by Jennifer Lange.

Answer Key (click to show/hide answers)

Kidney

A - medulla

B - cortex

C - renal corpuscles

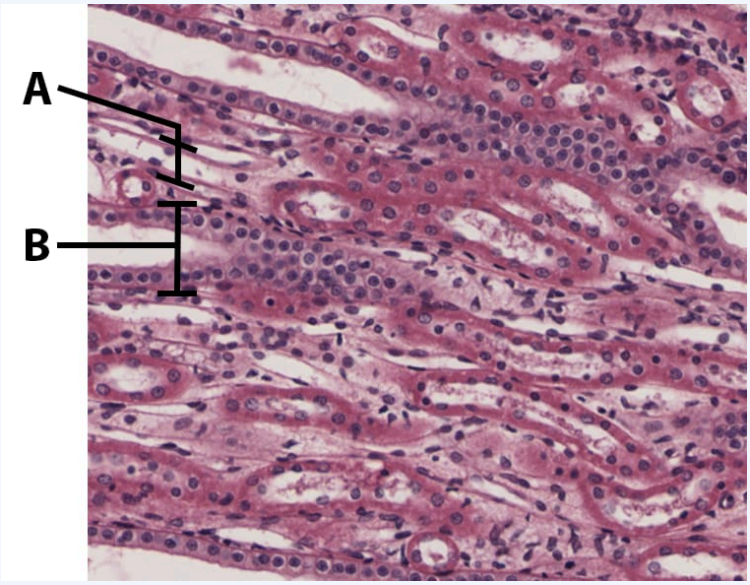

Image credit:

"Histology of the Renal Medulla @ 100x" slide provided by the Regents of the University of Michigan Medical School under CC BY-NC-SA 4.0 © 2022, labeling by Jennifer Lange.

Answer Key (click to show/hide answers)

Renal Medulla

A - thin nephron loop

B - collecting duct

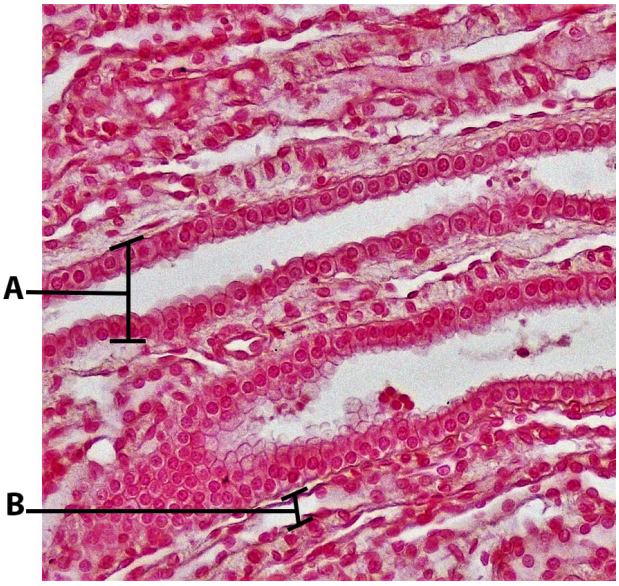

Image credit:

"Histology of the Renal Medulla" by Jennifer Lange is licensed under CC BY-NC-SA 4.0, Micrograph provided by Berkshire Community College Bioscience Image Library is in the Public Domain.

Answer Key (click to show/hide answers)

Renal Medulla

A - collecting duct

B - thin nephron loop

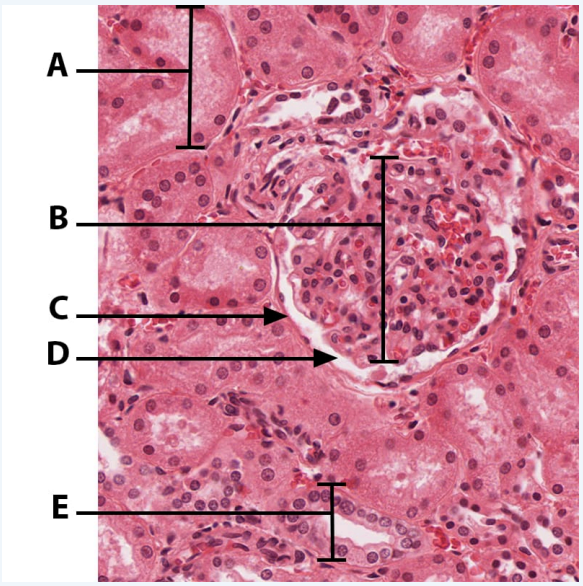

Image credit:

"Histology of the Renal Cortex @ 400x" slide provided by the Regents of the University of Michigan Medical School under CC BY-NC-SA 4.0 © 2022, labeling by Jennifer Lange.

Answer Key (click to show/hide answers)

Renal Cortex

A - proximal convoluted tubule

B - glomerulus

C - glomerular capsule

D - glomerular space

E - distal convoluted tubule

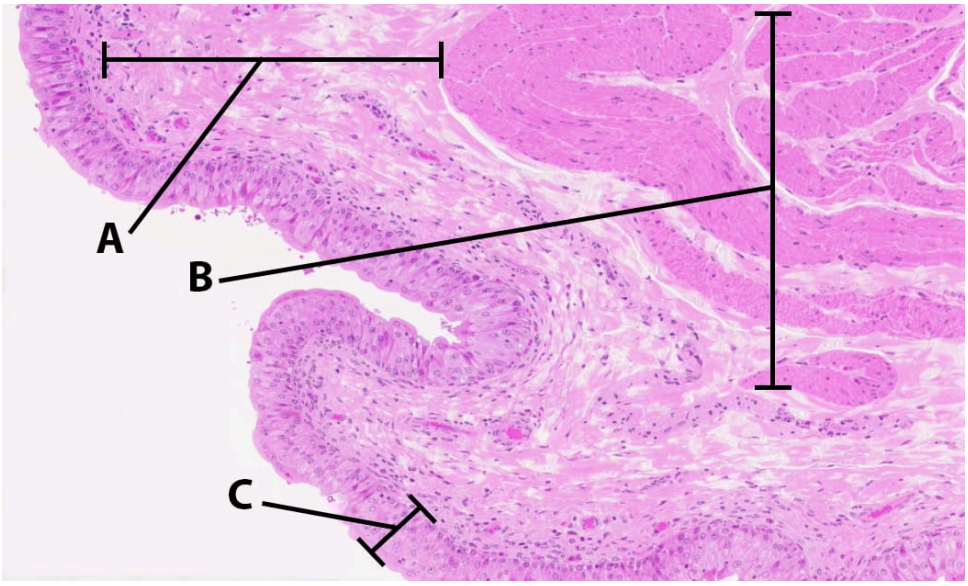

Image credit:

"Histology of the Urinary Bladder @100x" slide provided by the Regents of the University of Michigan Medical School under CC BY-NC-SA 4.0 © 2022, labeling by Jennifer Lange.

Answer Key (click to show/hide answers)

Urinary bladder

A - submucosa

B - muscularis

C - mucosa - transitional epithelium

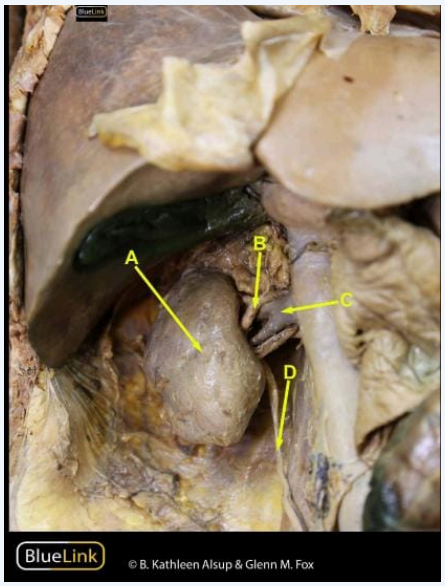

Image Credit

"Abdominal Wall" by John Polos. All cadaver images from the University of Michigan and are made available by the regents under CC 4.0

Answer Key (click to show/hide answers)

A - kidney (Right)

B - renal artery

C - renal vein

D - Ureter

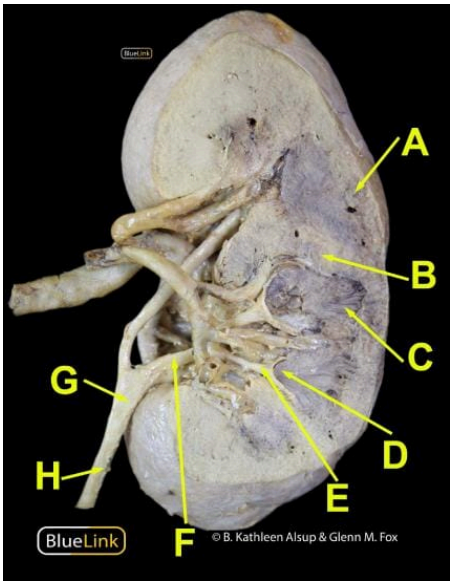

Image Credit

"Kidney" by John Polos. All cadaver images from the University of Michigan and are made available by the regents under CC 4.0.

Answer Key (click to show/hide answers)

A - renal cortex

B - renal column

C - renal medulla/ medullary pyramid

D - renal papillae

E - minor calyx

F - major calyx

G - renal pelvis

H - ureter

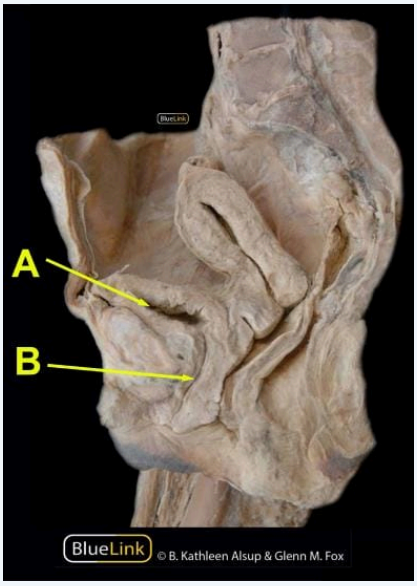

Image Credit

"Pelvic Cavity" by John Polos. All cadaver images from the University of Michigan and are made available by the regents under CC 4.0.

Answer Key (click to show/hide answers)

A - urinary bladder

B - Urethra

This page titled 22.5: Anatomical Atlas - Urinary System is shared under a CC BY-NC-SA 4.0 license and was authored, remixed, and/or curated by Jennifer Lange et al..

22.6: Practice Practical- Urinary System

Fill in the blanks with the correct word or words.

Query 22.6.1

This interactive element is not available in this format. Visit the link or scan the QR code to access it online.

View this Interactive Content online

Query 22.6.1

This interactive element is not available in this format. Visit the link or scan the QR code to access it online.

View this Interactive Content online

Query 22.6.1

This interactive element is not available in this format. Visit the link or scan the QR code to access it online.

View this Interactive Content online

Query 22.6.1

This interactive element is not available in this format. Visit the link or scan the QR code to access it online.

View this Interactive Content online

Interactive Content

This interactive element is not available in this format. Visit the link or scan the QR code to access it online.

View this Interactive Content online

Interactive Content

This interactive element is not available in this format. Visit the link or scan the QR code to access it online.

View this Interactive Content online

Interactive Content

This interactive element is not available in this format. Visit the link or scan the QR code to access it online.

View this Interactive Content online

Interactive Content

This interactive element is not available in this format. Visit the link or scan the QR code to access it online.

View this Interactive Content online

The above 9 images are by John Polos and shared under CC 4.0.

Interactive Content

This interactive element is not available in this format. Visit the link or scan the QR code to access it online.

View this Interactive Content online

Image Credit Urinary System Model Organs - Atlas" by Jennifer Lange is licensed under CC BY-NC-SA 4.0.

Interactive Content

This interactive element is not available in this format. Visit the link or scan the QR code to access it online.

View this Interactive Content online

Image credit "Torso Model Abdomen and Pelvis - Urinary Organs - Atlas" by Jennifer Lange is licensed under CC BY-NC-SA 4.0.

Interactive Content

This interactive element is not available in this format. Visit the link or scan the QR code to access it online.

View this Interactive Content online

"Histology of the Renal Cortex @ 400x" slide provided by the Regents of the University of Michigan Medical School under CC BY-NC-SA 4.0 © 2022, labeling by Jennifer Lange.

Interactive Content

This interactive element is not available in this format. Visit the link or scan the QR code to access it online.

View this Interactive Content online

Interactive Content

This interactive element is not available in this format. Visit the link or scan the QR code to access it online.

View this Interactive Content online

Interactive Content

This interactive element is not available in this format. Visit the link or scan the QR code to access it online.

View this Interactive Content online

All cadaver images from the University of Michigan and are made available by the regents under CC 4.0. Labels by John Polos.

This page titled 22.6: Practice Practical- Urinary System is shared under a CC BY-NC-SA 4.0 license and was authored, remixed, and/or curated by Jennifer Lange et al..

23: REPRODUCTIVE SYSTEMS

Note

This chapter is focused on the anatomy of the reproductive systems. A person with two X chromosomes (XX) will typically have ovaries for gonads and is genotypically classified as female. A person with one X chromosome and one Y chromosome (XY) will typically have testes for gonads and is genotypically classified as male. These two typical presentations are essentially opposite ends of a genotypic scale and differences in many genes and in epigenetics result in reproductive anatomy between these two poles. Sexual genotype and anatomy is not necessarily linked to gender identity or to sexuality.

In this chapter and in chapter 24, we will use the phrases "male", "XY", and "an individual with testes" to describe the anatomy of an individual with testes that may make sperm and who had Wolffian duct development. We will use the phrases "female", "XX", and "an individual with ovaries" to describe the anatomy of an individual with ovaries that may make ova (eggs) and who had Müllerian duct development.

23.1: Introduction to the Reproductive System

23.2: Anatomy of the Male Reproductive System

23.3: Anatomy of the Female Reproductive System

23.4: Development of the Male and Female Reproductive Systems

23.5: Practice Practical- the Reproductive System

23.6: Anatomical Atlas - Reproductive Systems

This page titled 23: Reproductive Systems is shared under a CC BY-NC-SA 4.0 license and was authored, remixed, and/or curated by Jennifer Lange et al..

- 23: Reproductive System by Whitney Menefee, Julie Jenks, Chiara Mazzasette, and Kim-Leiloni Nguyen is licensed CC BY 4.0.

23.1: Introduction to the Reproductive System

Chapter Learning Objectives:

- Describe the anatomy of the male and female reproductive systems, including their accessory structures
- Explain the role of hypothalamic and pituitary hormones in male and female reproductive function
- Trace the path of a sperm cell from its initial production through fertilization of an oocyte
- Explain the events in the ovary prior to ovulation
- Describe the development and maturation of the sex organs and the emergence of secondary sex characteristics during puberty

We do not often consider that a child's birth is proof of the healthy functioning of both the mother's and the father's reproductive systems. Moreover, the parents' endocrine systems had to secrete the appropriate regulating hormones to induce the production and release of unique male and female gametes, reproductive cells containing the parents' genetic material (one set of 23 chromosomes). The parent's reproductive behavior had to facilitate the transfer of male gametes—the sperm—to the female reproductive tract at just the right time to encounter the female gamete, an oocyte (egg). Finally, combination of the gametes (fertilization) had to occur, followed by implantation and development. In this chapter, you will explore the male and female reproductive systems, whose healthy functioning can culminate in the powerful sound of a newborn's first cry. In chapter 24 we will explore the processes of embryonic and fetal development.

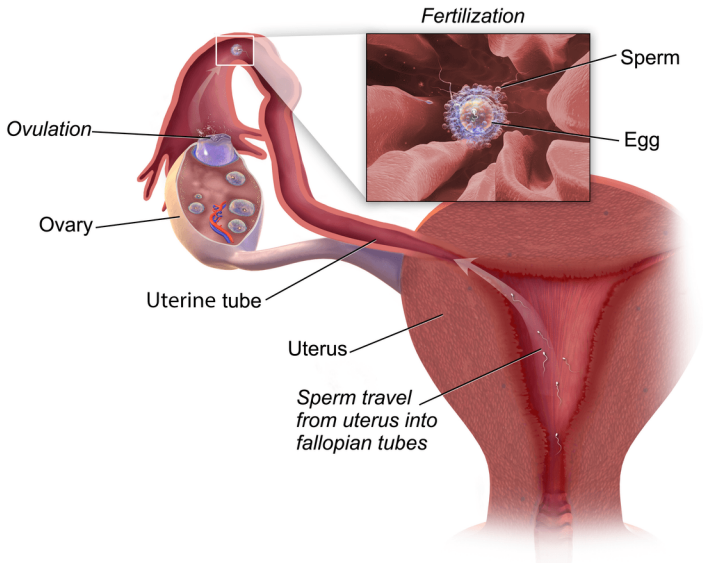

Figure 23.1.1: Ovulation. The male and female gametes meet in the uterine tube. Once fertilized the ovum will finish meiosis II. *(Image credit: "Blausen 0404 - Fertilization - English labels " by Blausen.com staff (2014), license: CC BY, modified by Jennifer Lange.)*

Brief Overview

Before diving into the details, let's cover some basic common terms. Unique for its role in human reproduction, a **gamete** is a specialized sex cell carrying 23 chromosomes—one half the number in body cells. **Gonads** are the organs that make the gametes. Once the gametes are made, they travel in tubular structures. These structures are often the site for permanent sterilization procedures because if the gametes of the opposite sex cannot meet, then fertilization will not be possible. (Table 23.1.1) Comparing the midsagittal view of the female and male pelvis, we see multiple differences (Figure 23.1.2). Discussions on the female reproductive anatomy will be covered in section 23.3. Discussions on the male reproductive anatomy will be covered in section 23.2.

Table 23.1.1 Male and Female Reproductive Systems Comparison

Term	Male	Female
Gonads	Testes	Ovaries
Gametes	Sperm	Ova (ovum, singular, also known as eggs)
Tract Organs	Ductus deferens (or vas deferens), ejaculatory duct, urethra	Uterine tubes (or Fallopian tubes), uterus, vagina
Permanent Sterilization Procedure	Vasectomy	Tubal ligation, hysterectomy
Copulatory organ	Penis	Vagina

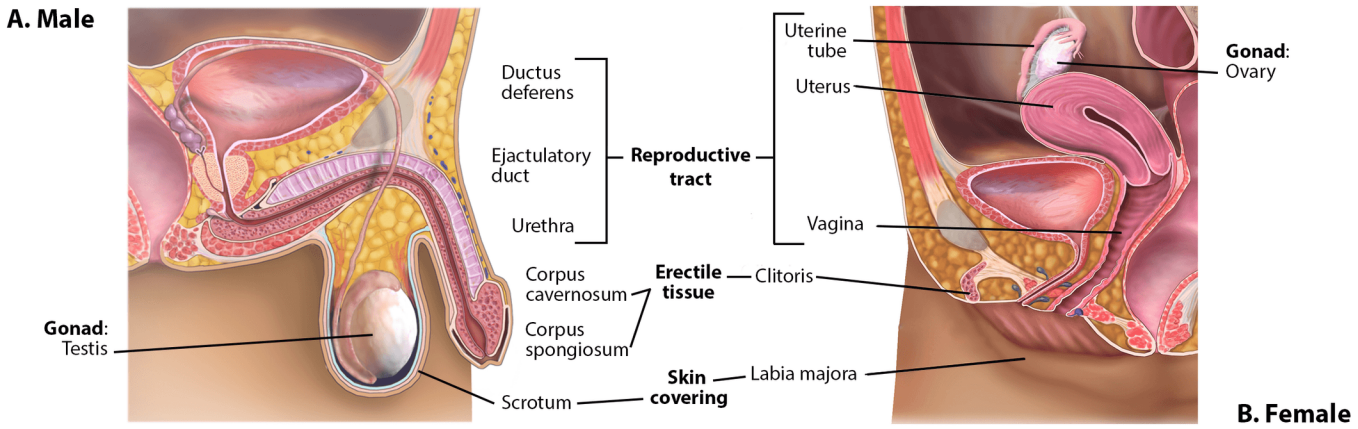

Figure 23.1.2: Reproductive System Homologues - Male and Female. Because they develop from common structures (primordial tissues) and serve a common function in adults, many of the reproductive organs are homologous between the male and the female. *(Image credit: "Reproductive System Homologues - Male and Female" by Jennifer Lange is licensed under CC BY-NC-SA 4.0, modification of "Varicocele" by BruceBlaus and of "Female Reproductive System - Midsagittal" by Blausen.com staff (2014), from the Medical gallery of Blausen Medical 2014, WikiJournal of Medicine.)*

Contributors and Attributions

- OpenStax Anatomy & Physiology (CC BY 4.0). Access for free at https://openstax.org/books/anatomy-and-physiology

This page titled 23.1: Introduction to the Reproductive System is shared under a CC BY-NC-SA 4.0 license and was authored, remixed, and/or curated by Jennifer Lange et al..

- 23.1: Introduction to the Reproductive System by Whitney Menefee, Julie Jenks, Chiara Mazzasette, and Kim-Leiloni Nguyen is licensed CC BY 4.0.

23.2: Anatomy of the Male Reproductive System

By the end of the section, you will be able to:

- Describe the structure and function of the organs of the male reproductive system
- Describe the structure and function of the sperm cell
- Explain the events during spermatogenesis that produce haploid sperm from diploid cells
- Identify the importance of testosterone in male reproductive function

Unique for its role in human reproduction, a **gamete** is a specialized sex cell carrying 23 chromosomes—one half the number in body cells. At fertilization, the chromosomes in one male gamete, called a **sperm** (or spermatozoon), combine with the chromosomes in one female gamete, called an oocyte. The function of the male reproductive system is to produce sperm and transfer them to the female reproductive tract. The structures of the male reproductive system include the testes, the epididymides, the penis, and the ducts and glands that produce and carry semen (Figure 23.2.1). Sperm exit the scrotum through the ductus deferens, which is bundled in the spermatic cord. The spermatic cord is comprised of the ductus deferens, testicular artery, autonomic nerve, lymphatic vessel, and plexus of testicular veins. The seminal vesicles and prostate gland add fluids to the sperm to create semen. The paired testes are a crucial component in this process, as they produce both sperm and androgens, the hormones that support male reproductive physiology. In humans, the most important male androgen is testosterone. Several accessory organs and ducts aid the process of sperm maturation and transport the sperm and other seminal components to the penis, which delivers sperm to the female reproductive tract. In this section, we examine each of these different structures, and discuss the process of sperm production and transport. Details about these male anatomical structures will be discussed below.

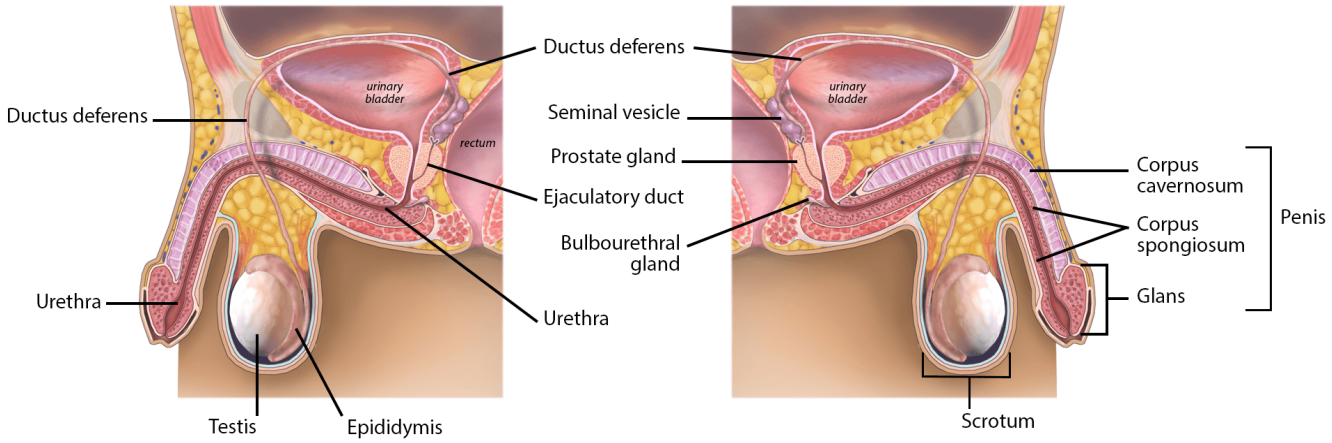

Figure 23.2.1: Male Reproductive System - Sagittal Section. Sperm produced in the testis will travel through a series of tubes and exit the penis through the urethra. Along this path the accessory glands add seminal fluid into the ejaculate. *(Image credit: "Varicocele" by BruceBlaus is licensed under CC BY-SA 4.0, modifications and labeling by Jennifer Lange.)*

Scrotum

The testes are located in a skin-covered, highly pigmented, muscular sack called the **scrotum** that extends from the body behind the penis (see Figure 23.2.1). This location is important in sperm production, which occurs within the testes, and proceeds more efficiently when the testes are kept 2 to 4°C below core body temperature.

The **dartos muscle** makes up the subcutaneous muscle layer of the scrotum (Figure 23.2.2). It continues internally to make up the scrotal septum, a wall that divides the scrotum into two compartments, each housing one testis. Descending from the internal oblique muscle of the abdominal wall are the two **cremaster muscles**, which cover each testis like a muscular net. By contracting simultaneously, the dartos and cremaster muscles can elevate the testes in cold weather (or water), moving the testes closer to the body and decreasing the surface area of the scrotum to retain heat. Alternatively, as the environmental temperature increases, the scrotum relaxes, moving the testes farther from the body core and increasing scrotal surface area, which promotes heat loss.

Externally, the scrotum has a raised medial thickening on the surface called the **raphe.**

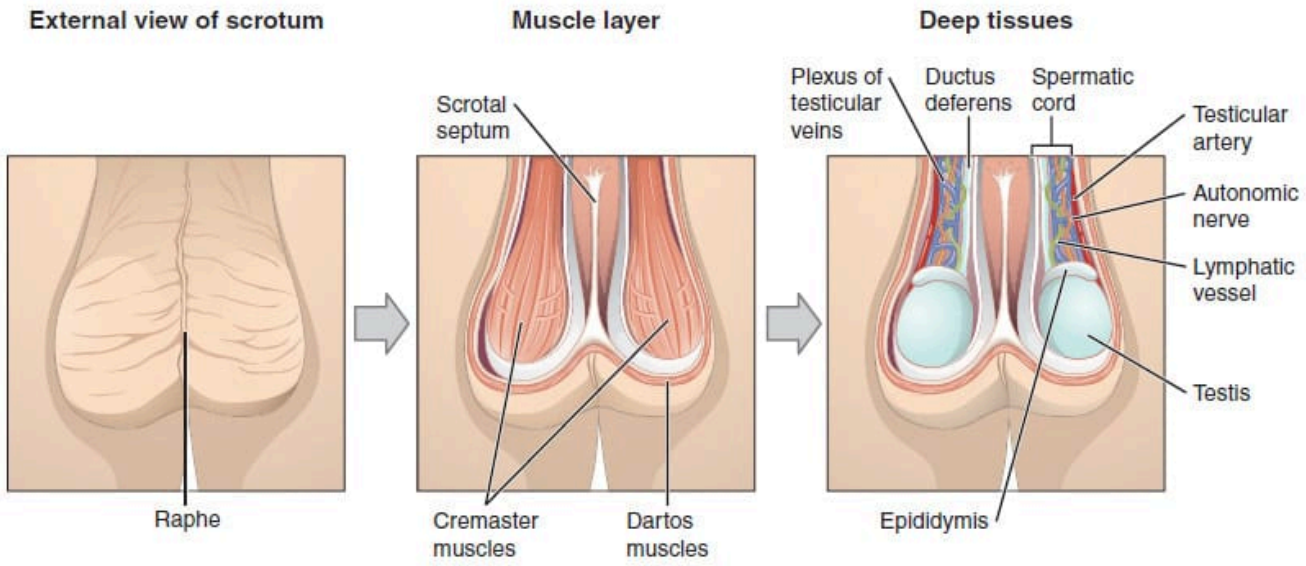

Figure 23.2.2: The Scrotum and Testes. This anterior view shows the different layers surrounding the scrotum and testes. *(Image credit: "Scrotum and Internal Structures" by OpenStax is licensed under CC BY 4.0)*

Testes

The **testes** (singular = testis) are the male gonads—that is, the male reproductive organs. They produce both sperm and androgens, such as testosterone, and are active throughout the reproductive lifespan of the male.

Paired ovals, the testes are each approximately 4 to 5 cm in length and are housed within the scrotum (see Figure 23.2.2). They are surrounded by two distinct layers of protective connective tissue. Immediately deep to the cremaster muscle is the tunica vaginalis. The outer **tunica vaginalis** is a serous membrane that has both a parietal and a thin visceral layer. Beneath the tunica vaginalis is the **tunica albuginea**, a tough, white, dense connective tissue layer covering the testis itself. Not only does the tunica albuginea cover the outside of the testis, it also invaginates to form septa that divide the testis into 300 to 400 structures called **lobules**. Within the lobules, sperm develop in structures called **seminiferous tubules** (Figure 23.2.3). During the seventh month of the developmental period of a male fetus, each testis moves through the abdominal musculature to descend into the scrotal cavity. This is called the "descent of the testis." Cryptorchidism is the clinical term used when one or both of the testes fail to descend into the scrotum prior to birth.

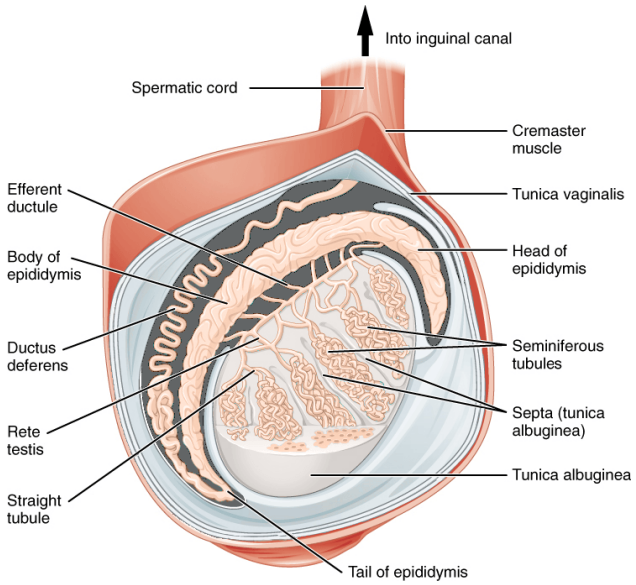

Figure \({23{.}2{.}\eatSpaces{3} \endSpaces}\: Anatomy of the Testis. Inside the scrotum is a network of small tubes called the seminiferous tubules that are the site of spermatogenesis. They are all connected from the testis to the epididymis to the ductus deferens. *(Image credit: "Anatomy of the Testis" by OpenStax is licensed under CC BY 4.0, modifications by Jennifer Lange.)*

The tightly coiled seminiferous tubules form the bulk of each testis. They are composed of developing sperm cells surrounding a lumen, the hollow center of the tubule, where formed sperm are released into the duct system of the testis. Specifically, from the lumens of the seminiferous tubules, sperm move into the **straight tubules** (or tubuli recti), and from there into a fine meshwork of tubules called the **rete testes**. Sperm leave the rete testes, and the testis itself, through the 15 to 20 **efferent ductules** that cross the tunica albuginea.

Interstitial cells (also known as **Leydig cells**) produce testosterone and are located in between the seminiferous tubules (Figure 23.2.4). Inside the seminiferous tubules are six different cell types. These include supporting cells called **sustentacular cells**, as well as five types of developing sperm cells called **germ cells**. Germ cell development progresses from the basement membrane—at the perimeter of the tubule—toward the lumen. Let's look more closely at these cell types.

Sustentacular Cells

Surrounding all stages of the developing sperm cells are elongate, branching **sustentacular cells,** also called Sertoli cells (Figure 23.2.4. Sustentacular cells secrete signaling molecules that promote sperm production and can control whether germ cells live or die. They also produce androgen-binding protein, which is needed for testosterone to actually have effects on the developing sperm, and inhibin, which feeds back to the anterior pituitary gland to regulate sperm production. They extend physically around the germ cells from the peripheral basement membrane of the seminiferous tubules to the lumen. Tight junctions between these sustentacular cells create the **blood–testis barrier**, which keeps blood borne substances from reaching the germ cells and, at the same time, keeps surface antigens on developing germ cells from escaping into the bloodstream and prompting an autoimmune response.

Germ Cells

The least mature cells, the **spermatogonia** (singular = spermatogonium), line the basement membrane inside the tubule. Spermatogonia are the stem cells of the testis, which means that they are still able to differentiate into a variety of different cell types throughout adulthood. Spermatogonia divide to produce **primary** and **secondary spermatocytes**, then **spermatids**, which finally produce formed sperm. The process that begins with spermatogonia and concludes with the production of sperm is called **spermatogenesis**.

Spermatogenesis

As just noted, spermatogenesis occurs in the seminiferous tubules that form the bulk of each testis (Figure 23.2.3. The process begins at puberty, after which time sperm are produced constantly throughout a man's life. One production cycle, from

spermatogonia through formed sperm, takes approximately 64 days. A new cycle starts approximately every 16 days, although this timing is not synchronous across the seminiferous tubules. Sperm counts—the total number of sperm a man produces—slowly decline after age 35, and some studies suggest that smoking can lower sperm counts irrespective of age.

The process of spermatogenesis begins with mitosis of the diploid spermatogonia in which one spermatogonium becomes two primary spermatocytes. Because these cells are diploid (2*n*), they each have a complete copy of the father's genetic material, or 46 chromosomes. After mitosis, the primary spermatocytes begin the two rounds of meiosis, i.e. meiosis I resulting in secondary spermatocytes, and meiosis II, resulting in spermatids. Mature gametes are haploid (1*n*), containing 23 chromosomes—meaning that daughter cells of spermatogonia must undergo a second cellular division through the process of meiosis Figure 23.2.4. These spermatids will continue with spermiogenesis to become spermatozoa, also known as sperm. A cross section of a seminiferous tubule will show the early cells of spermatogenesis at the outer edge and the more mature cells migrating toward the lumen in the center.

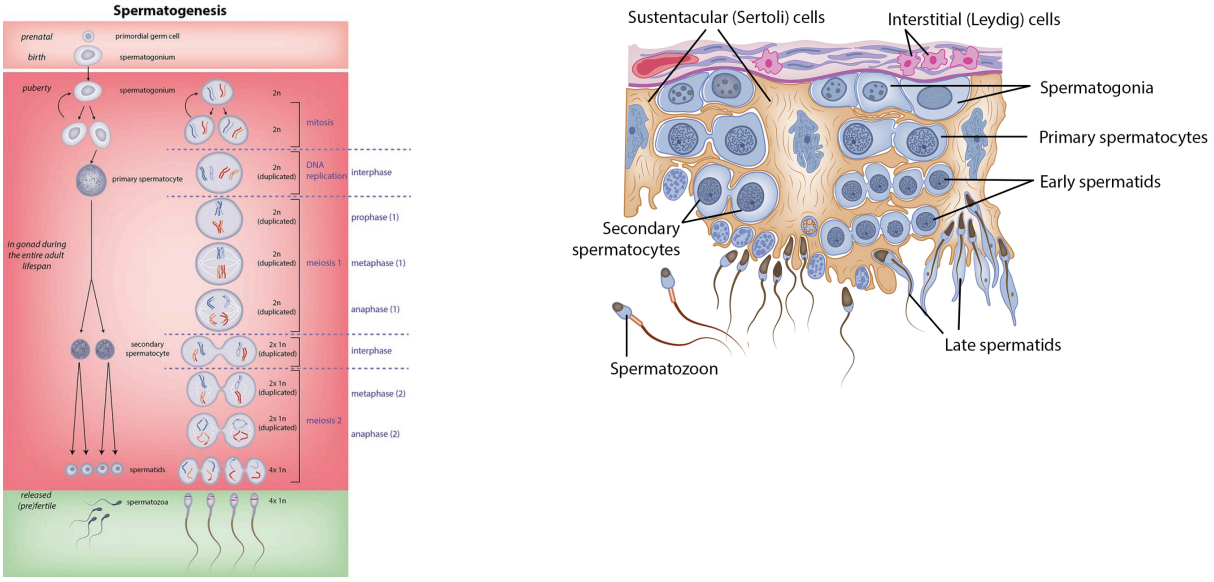

Figure 23.2.4: Spermatogenesis. Mitosis of a spermatogonium stem cell results in two identical, diploid daughter cells: a spermatogonium and a primary spermatocyte. The primary spermatocyte undergoes meiosis to produce four spermatids. The location of the spermatogonia is near the basement membrane and the spermatids are adjacent to the lumen. *(Image credits: "Slagter - Drawing Human spermatogenesis diagram - English labels" by Ron Slagter, O. Paul Gobée, LUMC, Hope Wicks, LUMC et al, license: CC BY-NC-SA. "Slagter - Drawing Spermatogenesis in seminiferous tubules of testis - no labels" by Ron Slagter, Jill P.J.M. Hikspoors, MUMC+, Hope Wicks, LUMC et al, license: CC BY-NC-SA; modified by Jennifer Lange.)*

Two identical diploid cells result from spermatogonia mitosis. One of these cells remains a spermatogonium, and the other becomes a **primary spermatocyte**, the next stage in the process of spermatogenesis. As in mitosis, DNA is replicated in a primary spermatocyte, and the cell undergoes cell division to produce two cells with identical chromosomes. Each of these is a **secondary spermatocyte**. Now a second round of cell division occurs in both of the secondary spermatocytes, separating the chromosome pairs. This second meiotic division results in a total of four cells with only half of the number of chromosomes. Each of these new cells is a **spermatid**. Although haploid, early spermatids look very similar to cells in the earlier stages of spermatogenesis, with a round shape, central nucleus, and large amount of cytoplasm. A process called **spermiogenesis** transforms these early spermatids, reducing the cytoplasm, and beginning the formation of the parts of a true sperm. The fifth stage of germ cell formation—**spermatozoa**, or formed sperm—is the end result of this process, which occurs in the portion of the tubule nearest the lumen. Eventually, the sperm are released into the lumen and are moved along a series of ducts in the testis toward a structure called the **epididymis** for the next step of sperm maturation.

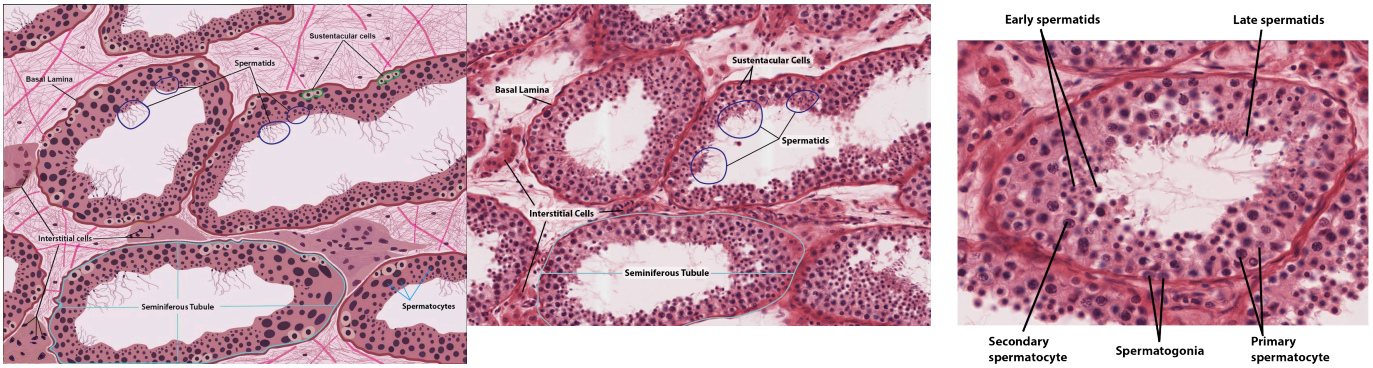

Figure \({23{.}2{.}\eatSpaces{5} \endSpaces}\: Seminiferous Tubule Histology. From these diagrams, we can see sustentacular cells and the spermatocytes in the seminiferous tubules. Also between the tubules you can observe the interstitial cells. On high power, the Sertoli cells are amorphic cells that surround the more circular spermatocytes. *(Image Credit: Histology photographs low and high power provided by the Regents of the University of Michigan under a BY-SA-NC 4.0. Illustration by Sofia Elizondo and Jennifer Lange is licensed under CC BY-NC-SA 4.0.)*

Sperm Maturation

The Epididymis

From the lumen of the seminiferous tubules, the immotile sperm are surrounded by testicular fluid and moved to the **epididymis** (plural = epididymides), a coiled tube attached to the testis where newly formed sperm continue to mature (see Figure $23.2.2$. Though the epididymis does not take up much room in its tightly coiled state, it would be approximately 6 m (20 feet) long if straightened. It takes an average of 12 days for sperm to move through the coils of the epididymis, with the shortest recorded transit time in humans being one day. Sperm enter the head of the epididymis and are moved along predominantly by the contraction of smooth muscles lining the epididymal tubes. The more mature sperm are then stored in the tail of the epididymis (the final section) until ejaculation occurs.

Sperm Structure

Sperm are smaller than most cells in the body; in fact, the volume of a sperm cell is 85,000 times less than that of the female gamete. Approximately 100 to 300 million sperm are produced each day, whereas women typically ovulate only one oocyte per month as is true for most cells in the body, the structure of sperm cells speaks to their function. The **head** of the sperm contains the extremely compact haploid nucleus with very little cytoplasm (Figure $23.2.6$. These qualities contribute to the overall small size of the sperm (the head is only 5 μm long). A structure called the **acrosome** covers most of the head of the sperm cell as a “cap” that is filled with lysosomal enzymes important for preparing sperm to participate in fertilization. Tightly packed mitochondria fill the **mid-piece** of the sperm. ATP produced by these mitochondria will power the flagellum, which extends from the neck and the mid-piece through the **tail** of the sperm, enabling it to move the entire sperm cell. The central strand of the flagellum, the axial filament, is formed from one centriole inside the maturing sperm cell during the final stages of spermatogenesis.

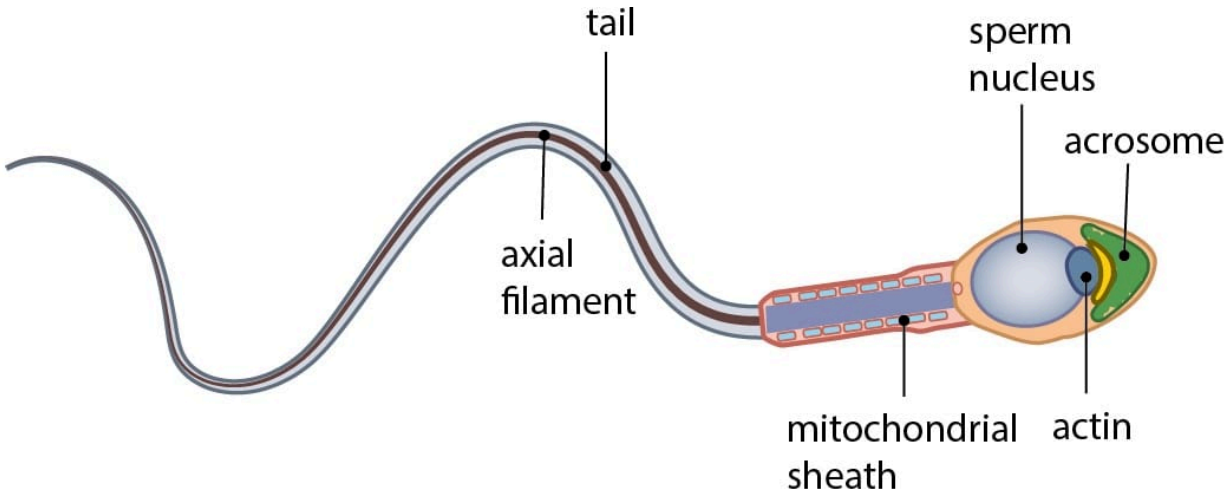

Figure \({23{.}2{.}\eatSpaces{6} \endSpaces}\: Structure of Sperm. Sperm cells are divided into a head containing the nucleus and the acrosome, a mid-piece containing mitochondria, and a tail. *(Image credit: Cropped version of "Slagter - Drawing Penetration of oocyte wall at fertilisation - English labels" by Ron Slagter, Cindy J.M. Hulsman, MUMC+, Jill P.J.M. Hikspoors, MUMC+ et al, license: CC BY-NC-SA.)*

Sperm Pathway and Seminal Fluid

To fertilize an egg, sperm must be moved from the seminiferous tubules in the testes, through the epididymis, and—later during ejaculation—along the length of the penis and out into the female reproductive tract.

Accessory Glands and Seminal Fluid Production

Sperm make up only 5 percent of the final volume of **semen**, the thick, milky fluid that the male ejaculates. The bulk of semen is produced by three critical accessory glands of the male reproductive system: the seminal vesicles, the prostate, and the bulbourethral glands (Figure 23.2.7. The secretions of these glands make up the seminal fluid.

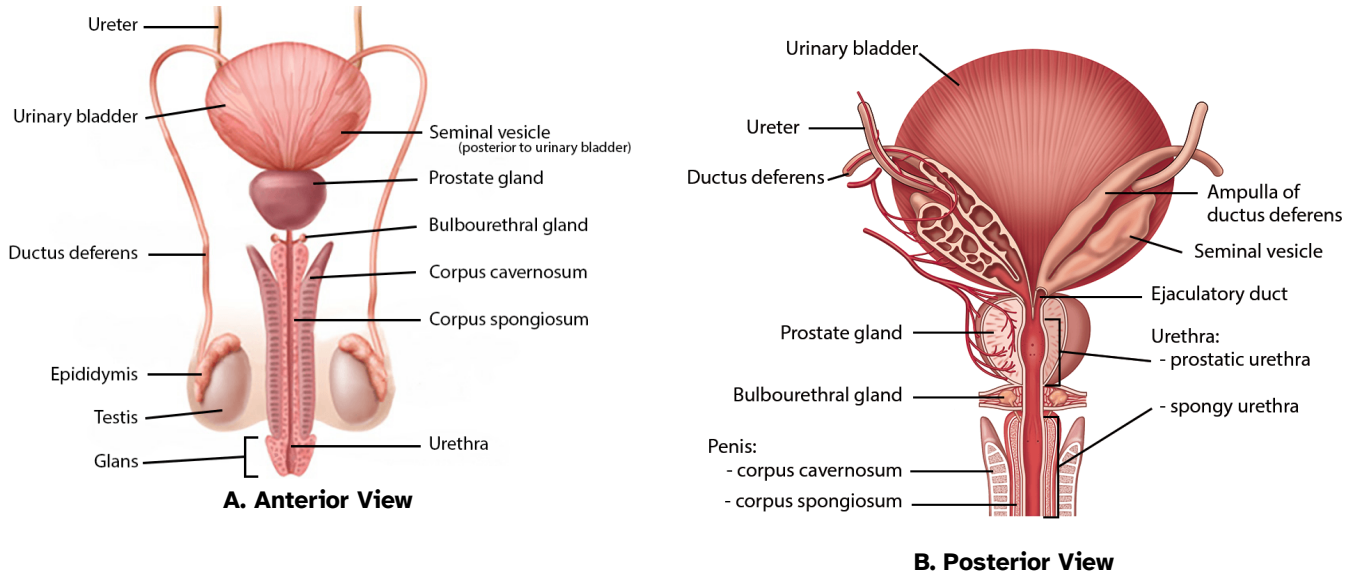

Figure 23.2.7: Semen Production. Sperm exit the scrotum in the ductus deferens, which arches posteriorly over the urinary bladder. On the posterior side of the urinary bladder a ductus deferens joins with the duct from a seminal vesicle to form an ejaculatory duct. The two ejaculatory ducts join with the urethra, which serves as a common passageway for semen and urine. Both the prostate gland and the bulbourethral glands secrete into the urethra. *(Image credits: "Male Reproductive Organs - Anterior View" by Jennifer Lange is licensed under CC BY-NC-SA 4.0, modification of original by StacyRed-Wiki via Wikimedia Commons; "Leiden - Drawing Male bladder and urethra from posterior - no labels" by Bas (S) Blankevoort, LUMC and Marco C DeRuiter, LUMC, is licensed under CC BY-NC-SA, modifications and labeling by Jennifer Lange.)*

Seminal Vesicles

As sperm pass through the ampulla of the ductus deferens at ejaculation, they mix with fluid from the associated **seminal vesicle** (see Figure 23.2.7). The paired seminal vesicles are glands that contribute approximately 60 percent of the semen volume. Seminal vesicle fluid contains large amounts of fructose, which is used by the sperm mitochondria to generate ATP to allow movement through the female reproductive tract. Sperm are immobile until mixed with secretions of the seminal glands. The seminal fluid is alkaline, which is necessary to neutralize the acidic environment of the vagina. Without this pH neutralization the sperm would not survive in the female reproductive tract. Prostaglandins are also present in the seminal vesicle's secretion. These are hormone-like molecules that cause the os of the cervix in the female reproductive tract to dilate, which facilitates sperm moving from the vagina into the uterus.

Prostate Gland

As shown in Figure 23.2.8, the centrally located **prostate gland** sits anterior to the rectum at the base of the urinary bladder surrounding the prostatic urethra (the portion of the urethra that runs within the prostate). About the size of a walnut, the prostate is formed of both muscular and glandular tissues. It excretes a milky fluid containing another sugar - citric acid - into the passing seminal fluid—now called semen—that is critical to first coagulate and then de-coagulate the semen following ejaculation. The temporary thickening of semen by mucin helps retain it within the female reproductive tract, providing time for sperm to utilize the fructose provided by seminal vesicle secretions. When the semen regains its fluid state using an enzyme called **prostate specific antigen (PSA)**, sperm can then pass farther into the female reproductive tract. Secretions from the prostate also include seminalplasmin, which serves as an antibiotic.

DISORDERS OF THE...

Prostate Gland

PSA is mostly found in semen, but small amounts of it circulate in the blood. Blood PSA levels can be tested to inform on the health of the prostate gland. This test can detect high levels of PSA that may be indicative of the presence of prostate cancer or of another conditions such as an enlarged or inflamed prostate.

The prostate normally doubles in size during puberty. At approximately age 25, it gradually begins to enlarge again. This enlargement does not usually cause problems; however, abnormal growth of the prostate, or benign prostatic hyperplasia (BPH), can cause constriction of the urethra as it passes through the middle of the prostate gland, leading to a number of lower urinary tract symptoms, such as a frequent and intense urge to urinate, a weak stream, and a sensation that the bladder has not emptied completely. By age 60, approximately 40 percent of men have some degree of BPH. By age 80, the number of affected individuals has jumped to as many as 80 percent. Treatments for BPH attempt to relieve the pressure on the urethra so that urine can flow more normally. Mild to moderate symptoms are treated with medication, whereas severe enlargement of the prostate is treated by surgery in which a portion of the prostate tissue is removed.

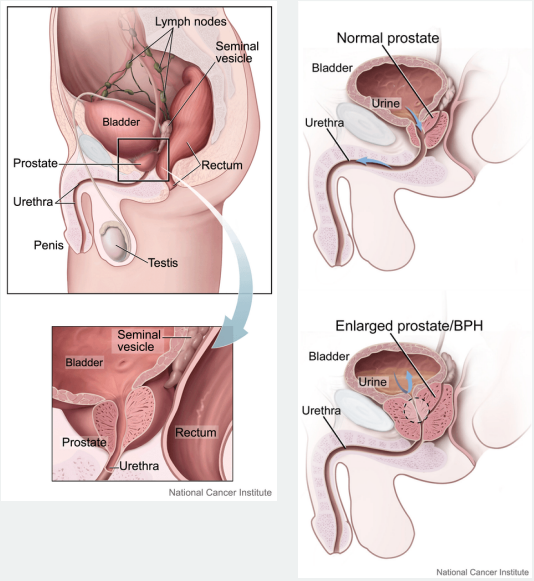

Figure 23.2.8: Prostate Gland. The prostate gland surrounds the urethra and, in a healthy state, allows for free passage of urine out of the urinary bladder. If the prostate is enlarged, due to BPH or to prostate cancer, the prostate encroaches on the urethra, narrowing its diameter and making urine passage more difficult. *(Image credits: "Prostate and Nearby Organs" by Alan Hoofring for the National Cancer Institute is in the public domain; slight modifications by Jennifer Lange. "Prostate (Normal and Enlarged)" by Alan Hoofring for the National Cancer institute is in the public domain.)*

According to the Centers for Disease Control and Prevention (CDC), prostate cancer is the second most common cancer in men. However, some forms of prostate cancer grow very slowly and thus may not ever require treatment. Aggressive forms of prostate cancer, in contrast, involve metastasis to vulnerable organs like the lymph nodes, lungs, and brain. There is no link between BPH and prostate cancer, but the symptoms are similar. Prostate cancer is detected by a medical history, a blood test, and a rectal exam that allows physicians to palpate the prostate and check for unusual masses. If a mass is detected, the cancer diagnosis is confirmed by biopsy of the cells. Treatment options for prostate cancer include active surveillance, hormone therapy, surgery, chemotherapy, and radiation therapy. For more information please visit the National Cancer Institute's page on prostate cancer.

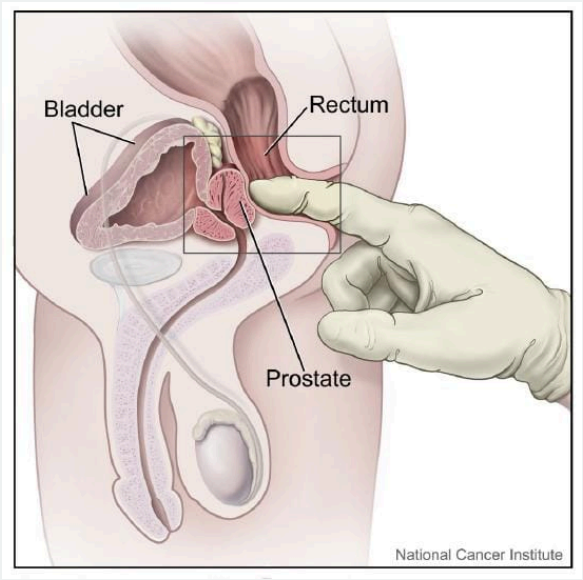

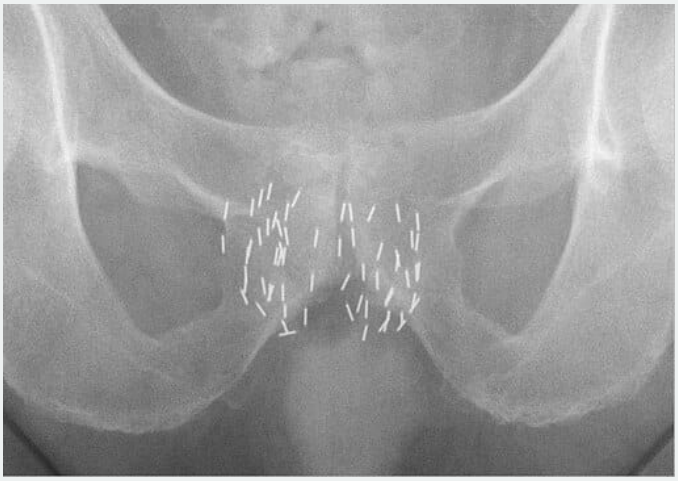

Figure 23.2.10: Prostate Cancer - Exam and Treatment. Because of the prostate gland's proximity to the rectal canal, the gland can be physically examined by performing a digital rectal exam. Surgical and radiation therapy treatment, such as implantation of the "seeds" seen here, also utilize this proximity. *(Image credits: "Exam, Digital Rectal" by the National Cancer Institute is in the public domain. "Radiation Therapy Seeds in Prostate" by Hellerhoff is licensed under CC BY-SA 4.0, via Wikimedia Commons.)*

Bulbourethral Glands

The final addition to semen is made by two **bulbourethral glands** (or Cowper's glands) that release a thick, salty mucus that lubricates the end of the urethra and the vagina, and helps to clean urine residues from the penile urethra. The fluid from these accessory glands is released after the male becomes sexually aroused, and shortly before the release of the semen. It is therefore sometimes called pre-ejaculate. It is important to note that, in addition to the lubricating proteins, it is possible for bulbourethral fluid to pick up sperm already present in the urethra, and therefore it may be able to cause pregnancy.

Ductal System

During ejaculation, sperm exit the tail of the epididymis and are pushed by smooth muscle contraction to the **ductus deferens** (also called the vas deferens). The ductus deferens is a thick, muscular tube that is bundled together inside the scrotum with connective tissue, blood vessels, and nerves into a structure called the **spermatic cord** (see Figure 23.2.2 and Figure 23.2.3). Because the ductus deferens is physically accessible within the scrotum, surgical sterilization to interrupt sperm delivery can be performed by cutting and sealing a small section of the ductus (vas) deferens. This procedure is called a **vasectomy**, and it is an effective form of male birth control. Although it may be possible to reverse a vasectomy, clinicians consider the procedure permanent, and advise men to undergo it only if they are certain they no longer wish to father children.

Interactive Element

Query 23.2.1

This interactive element is not available in this format. Visit the link or scan the QR code to access it online.

View this Interactive Content online

From each epididymis, each ductus deferens extends superiorly into the abdominal cavity through the **inguinal canal** in the abdominal wall. From here, the ductus deferens continues posteriorly to the pelvic cavity, ending posterior to the bladder where it dilates in a region called the ampulla (meaning "flask"). At this point the ductus deferens merges with the duct of the seminal vesicle and the semen to become the **ejaculatory duct**, now containing both sperm and seminal vesicle secretions. The paired ejaculatory ducts transport the seminal fluid through the prostate gland and empty into the urethra just inferior to its emergence from the inferior urinary bladder.

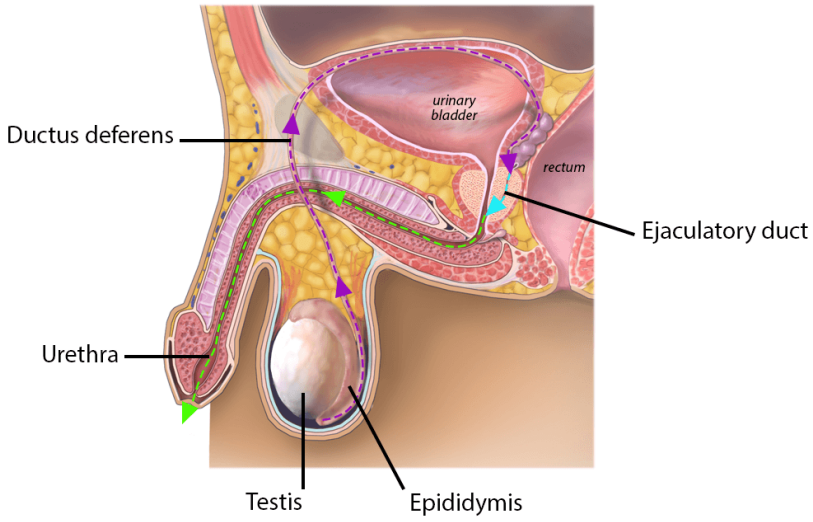

Figure 23.2.9: Male Reproductive System: Ducts. In this sagittal section of the male reproductive system we can trace the pathway of sperm from their origin in the testes to their exit from the body. When sperm are ejaculated from the epididymis they will pass through the ductus deferens, which travels from the scrotum and into the pelvic cavity. Each ductus deferens loops around the urinary bladder to join with a duct of the seminal vesicle and become the ejaculatory duct. The two ejaculatory ducts empty into the urethra, which carries the sperm to the outside. *(Image credit: "Varicocele" by BruceBlaus is licensed under CC BY-SA 4.0, modifications and labeling by Jennifer Lange.)*

The **urethra** (Figure 23.2.9transports seminal fluid from both ejaculatory ducts to the outside of the body. It is subdivided into three regions: the prostatic urethra (within the prostate gland), the membranous urethra (passing through the pelvic floor), and the spongy urethra (within the penis).

Penis

The **penis** is the male organ of copulation (sexual intercourse). It is flaccid for non-sexual actions, such as urination, and turgid and rod-like with sexual arousal. When erect, the stiffness of the organ allows it to penetrate into the vagina and deposit semen into the female reproductive tract Figure 23.2.9).

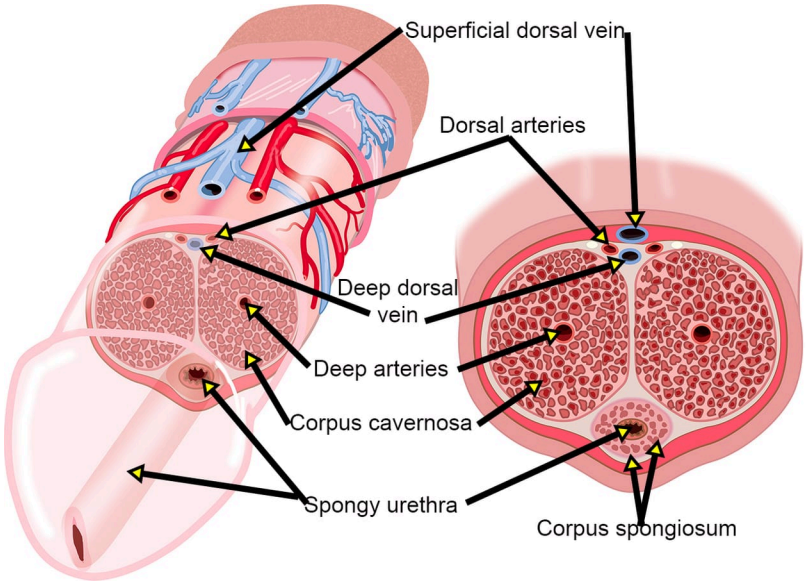

Figure \({23{.}2{.}\eatSpaces{10} \endSpaces}\: Anatomy of the Penis. The left image shows a cross-section of the penis, with the different layers and vessels on the dorsal side; the right-hand drawing shows a cross-section of the penis. *(Image credit:"Slagter - Drawing Anatomy of the penis and corpus cavernosum - no labels" by Ron Slagter and Marco C DeRuiter, LUMC, license: CC BY-NC-SA labels added by John Polos.)*

The shaft of the penis surrounds the urethra (Figure 23.2.10). The shaft is composed of three column-like chambers of erectile tissue that span the length of the shaft. Each of the two larger lateral chambers is called a **corpus cavernosum** (plural = corpora cavernosa). Together, these make up the bulk of the penis. The **corpus spongiosum**, which can be felt as a raised ridge on the erect penis, is a smaller chamber that surrounds the spongy, or penile, urethra. The end of the penis, called the **glans penis**, has a high concentration of nerve endings, resulting in very sensitive skin that influences the likelihood of ejaculation (see Figure 23.2.10). The skin from the shaft extends down over the glans and forms a collar called the **prepuce** (or foreskin). The foreskin also contains a dense concentration of nerve endings, and both lubricate and protect the sensitive skin of the glans penis. A surgical procedure called circumcision, often performed for religious or social reasons, removes the prepuce, typically within days of birth.

Both sexual arousal and REM sleep (during which dreaming occurs) can induce an erection. Penile erections are the result of vasocongestion, or engorgement of the tissues because of more arterial blood flowing into the penis than is leaving in the veins. During sexual arousal, nitric oxide (NO) is released from nerve endings near blood vessels within the corpora cavernosa and spongiosum. Release of NO activates a signaling pathway that results in relaxation of the smooth muscles that surround the penile arteries, causing them to dilate. This dilation increases the amount of blood that can enter the penis and induces the endothelial cells in the penile arterial walls to also secrete NO and perpetuate the vasodilation. The rapid increase in blood volume fills the erectile chambers, and the increased pressure of the filled chambers compresses the thin-walled penile venules, preventing venous drainage of the penis. The result of this increased blood flow to the penis and reduced blood return from the penis is erection. Depending on the flaccid dimensions of a penis, it can increase in size slightly or greatly during erection, with the average length of an erect penis measuring approximately 15 cm.

DISORDERS OF THE...

Penis

Erectile dysfunction (ED) is a condition in which a man has difficulty either initiating or maintaining an erection. The combined prevalence of minimal, moderate, and complete ED is approximately 40 percent in men at age 40, and reaches nearly 70 percent by 70 years of age. In addition to aging, ED is associated with diabetes, vascular disease, psychiatric disorders, prostate disorders, the use of some drugs such as certain antidepressants, and problems with the testes resulting in low testosterone concentrations. These physical and emotional conditions can lead to interruptions in the vasodilation pathway and result in an inability to achieve an erection.

Recall that the release of NO induces relaxation of the smooth muscles that surround the penile arteries, leading to the vasodilation necessary to achieve an erection. To reverse the process of vasodilation, an enzyme called phosphodiesterase (PDE) degrades a key component of the NO signaling pathway called cGMP. There are several different forms of this enzyme, and PDE type 5 is the type of PDE found in the tissues of the penis. Scientists discovered that inhibiting PDE5 increases blood flow, and allows vasodilation of the penis to occur.

PDEs and the vasodilation signaling pathway are found in the vasculature in other parts of the body. In the 1990's, clinical trials of a PDE5 inhibitor called sildenafil were initiated to treat hypertension and angina pectoris (chest pain caused by poor blood flow through the heart). The trial showed that the drug was not effective at treating heart conditions, but many men experienced erection and priapism (erection lasting longer than 4 hours). Because of this, a clinical trial was started to investigate the ability of sildenafil to promote erections in men suffering from ED. In 1998, the FDA approved the drug, marketed as Viagra®. Since approval of the drug, sildenafil and similar PDE inhibitors now generate over a billion dollars a year in sales, and are reported to be effective in treating approximately 70 to 85 percent of cases of ED. Importantly, men with health problems—especially those with cardiac disease taking nitrates—should avoid Viagra or talk to their physician to find out if they are a candidate for the use of this drug, as deaths have been reported for at-risk users.

Testosterone

Testosterone, an androgen, is a steroid hormone produced by **interstitial cells (of Leydig)**. These cells are located between the seminiferous tubules in the testes (Figure 23.2.5). In male embryos, testosterone is secreted by interstitial cells by the seventh week of development, with peak concentrations reached in the second trimester. This early release of testosterone results in the anatomical differentiation of the male sexual organs. In childhood, testosterone concentrations are low. They increase during puberty, activating characteristic physical changes and initiating spermatogenesis.

Functions of Testosterone

The continued presence of testosterone is necessary to keep the male reproductive system working properly, and Leydig cells produce approximately 6 to 7 mg of testosterone per day. Testicular steroidogenesis (the manufacture of androgens, including testosterone) results in testosterone concentrations that are 100 times higher in the testes than in the circulation. Maintaining these normal concentrations of testosterone promotes spermatogenesis, whereas low levels of testosterone can lead to infertility. In addition to intratesticular secretion, testosterone is also released into the systemic circulation and plays an important role in muscle development, bone growth, the development of secondary sex characteristics, and maintaining libido (sex drive) in both males and females. In females, the ovaries secrete small amounts of testosterone, although most is converted to estradiol. A small amount of testosterone is also secreted by the adrenal glands in both sexes.

Control of Testosterone

The regulation of testosterone concentrations throughout the body is critical for male reproductive function. The regulation of Leydig cell production of testosterone begins outside of the testes. The hypothalamus and the pituitary gland in the brain integrate external and internal signals to control testosterone synthesis and secretion. The regulation begins in the **hypothalamus**. Pulsatile release of a hormone called **gonadotropin-releasing hormone (GnRH)** from the hypothalamus stimulates the endocrine release of hormones from the pituitary gland. Binding of GnRH to its receptors on the **anterior pituitary** gland stimulates release of the two gonadotropins: **luteinizing hormone (LH)** and **follicle-stimulating hormone (FSH)**. These two hormones are critical for reproductive function in both men and women. In men, FSH binds predominantly to the sustentacular cells within the seminiferous tubules to promote spermatogenesis. FSH also stimulates the interstitial cells to produce hormones called inhibins, which function to inhibit FSH release from the pituitary, thus reducing testosterone secretion. These polypeptide hormones correlate directly with Sertoli cell function and sperm number; inhibin can be used as a marker of spermatogenic activity. In men, LH binds to receptors on interstitial cells in the testes and up regulates the production of testosterone. Please refer to the Endocrine System, Sections 15.3 and 15.8 for additional details.

AGING AND THE...

Male Reproductive System

Declines in Leydig cell activity can occur in men beginning at 40 to 50 years of age. The resulting reduction in circulating testosterone concentrations can lead to symptoms of andropause, also known as male menopause. While the reduction in sex steroids in men is akin to female menopause, there is no clear sign—such as a lack of a menstrual period—to denote the initiation of andropause. Instead, men report feelings of fatigue, reduced muscle mass, depression, anxiety, irritability, loss of libido, and insomnia. A reduction in spermatogenesis resulting in lowered fertility is also reported, and sexual dysfunction can also be associated with andropausal symptoms.

Whereas some researchers believe that certain aspects of andropause are difficult to tease apart from aging in general, testosterone replacement is sometimes prescribed to alleviate some symptoms. Recent studies have shown a benefit from androgen replacement therapy on the new onset of depression in elderly men; however, other studies caution against testosterone replacement for long-term treatment of andropause symptoms, showing that high doses can sharply increase the risk of both heart disease and prostate cancer.

Concept Review

Gametes are the reproductive cells that combine to form offspring. Organs called gonads produce the gametes, along with the hormones that regulate human reproduction. The male gametes are called sperm. Spermatogenesis, the production of sperm, occurs within the seminiferous tubules that make up most of the testis. The scrotum is the muscular sac that holds the testes outside of the body cavity.

Spermatogenesis begins with mitotic division of spermatogonia (stem cells) to produce primary spermatocytes that undergo the two divisions of meiosis to become secondary spermatocytes, then the haploid spermatids. During spermiogenesis, spermatids are transformed into spermatozoa (formed sperm). Upon release from the seminiferous tubules, sperm are moved to the epididymis where they continue to mature. During ejaculation, sperm exit the epididymis through the ductus deferens, a duct in the spermatic cord that leaves the scrotum. The ampulla of the ductus deferens meets the seminal vesicle, a gland that contributes fructose and proteins, at the ejaculatory duct. The fluid continues through the prostatic urethra, where secretions from the prostate are added to form semen. These secretions help sperm to travel through the urethra and into the female reproductive tract. Secretions from the bulbourethral glands protect sperm and cleanse and lubricate the penile (spongy) urethra.

Table 23.2.1 - Male Reproductive System Summary

Structure	Function	Location
Testes	Site of spermatogenesis and of testosterone secretion	Exterior to the body cavity in the scrotum
Epididymis	Site of sperm maturation	Posterior to testes
Ductus deferens (vas deferens)	Muscular tube transporting sperm from the epididymis to the ejaculatory duct	Exit testes superiorly and enter the pelvic cavity, cross the superolateral surface of the urinary bladder to its posterior aspect
Ejaculatory duct	Conducts sperm and seminal fluid to the urethra	Within the prostate gland
Seminal vesicles	Contribute majority of semen volume; contains alkaline fluid containing fructose, citric acid, and prostaglandins	Posterior to urinary bladder
Prostate gland	Secretes citric acid, seminalplasmin, mucin, prostate-specific antigen, and immunoglobulin A into ejaculatory duct.	Inferior to urinary bladder
Bulbourethral glands	Secretes an alkaline mucus into urethra	Posterolateral to the membraneous urethra
Urethra	Muscular tube transporting semen from the ejaculatory duct to the outside of the body	Travels from the urinary bladder, through the prostate gland, and through the penis.

The penis is the male organ of copulation. Columns of erectile tissue called the corpora cavernosa and corpus spongiosum fill

with blood when sexual arousal activates vasodilatation in the blood vessels of the penis. Testosterone regulates and maintains the sex organs and sex drive, and induces the physical changes of puberty. Interplay between the testes and the endocrine system precisely control the production of testosterone.

Review Questions

Query 23.2.2

This interactive element is not available in this format. Visit the link or scan the QR code to access it online.

View this Interactive Content online

Critical Thinking Questions

Query 23.2.3

This interactive element is not available in this format. Visit the link or scan the QR code to access it online.

View this Interactive Content online

Query 23.2.4

This interactive element is not available in this format. Visit the link or scan the QR code to access it online.

View this Interactive Content online

Query 23.2.5

This interactive element is not available in this format. Visit the link or scan the QR code to access it online.

View this Interactive Content online

Query 23.2.6

This interactive element is not available in this format. Visit the link or scan the QR code to access it online.

View this Interactive Content online

Glossary

Query 23.2.7

This interactive element is not available in this format. Visit the link or scan the QR code to access it online.

View this Interactive Content online

Contributors and Attributions

- OpenStax Anatomy & Physiology (CC BY 4.0). Access for free at https://openstax.org/books/anatomy-and-physiology

This page titled 23.2: Anatomy of the Male Reproductive System is shared under a CC BY-NC-SA 4.0 license and was authored, remixed, and/or curated by Jennifer Lange et al..

- 23.2: Anatomy of the Male Reproductive System by Whitney Menefee, Julie Jenks, Chiara Mazzasette, and Kim-Leiloni Nguyen is licensed CC BY 4.0.

23.3: Anatomy of the Female Reproductive System

By the end of the section, you will be able to:

- Describe the structure and function of the organs of the female reproductive system
- List the steps of oogenesis
- Trace the path of an oocyte from ovary to fertilization

The female reproductive system functions to produce gametes and reproductive hormones, just like the male reproductive system; however, it also has the additional task of supporting the developing fetus and delivering it to the outside world. Unlike its male counterpart, the female reproductive system is located primarily inside the pelvic cavity. Recall that the **ovaries** are the female gonads. The gamete they produce is called an **oocyte**. We'll discuss the production of oocytes in detail shortly. First, let's look at some of the structures of the female reproductive system (Figure 23.3.1).

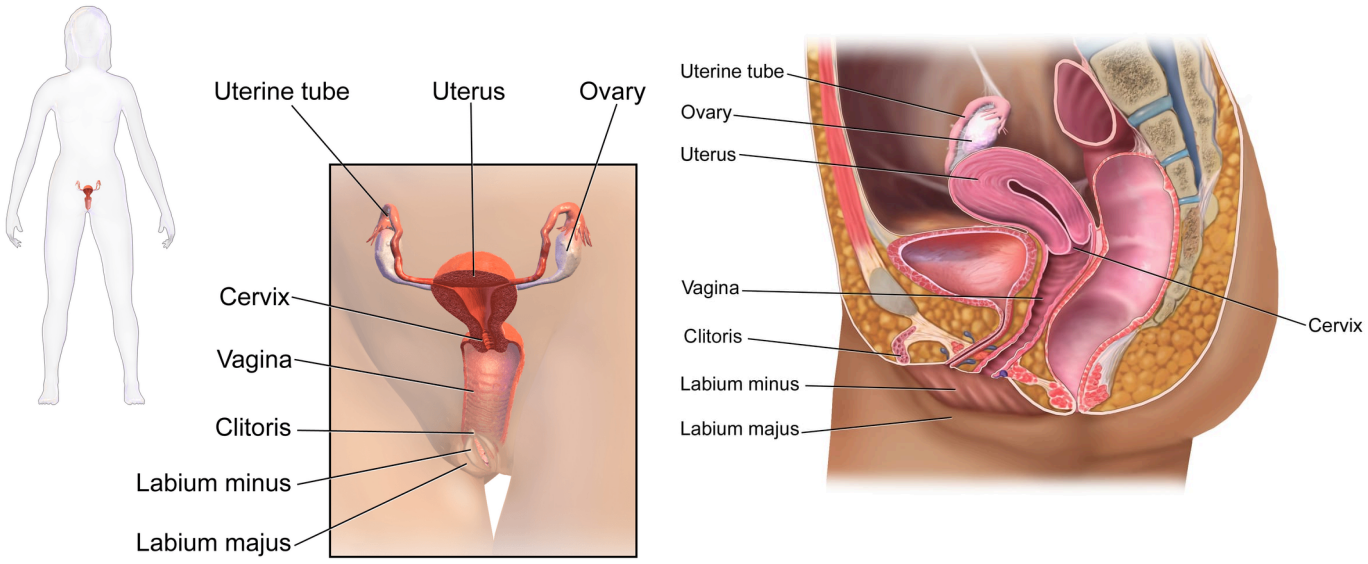

Figure 23.3.1: Female Reproductive System. The major organs of the female reproductive system are located inside the pelvic cavity. *(Image credit: "Female Reproductive System - Anterior and Midsagittal" by Blausen.com staff (2014), from the Medical gallery of Blausen Medical 2014, WikiJournal of Medicine, is licensed under CC BY 3.0. Modifications by Jennifer Lange.)*

External Female Genitals

The external female reproductive structures are referred to collectively as the vulva (Figure 23.3.2) The **mons pubis** is a pad of fat that is located at the anterior, over the pubic bone. After puberty, it becomes covered in pubic hair. The **labia majora** (labia = "lips"; majora = "larger") are folds of hair-covered skin that begin just posterior to the mons pubis. The thinner and more pigmented **labia minora** (labia = "lips"; minora = "smaller") extend medial to the labia majora. Although they naturally vary in shape and size from woman to woman, the labia minora serve to protect the female urethra and the entrance to the female reproductive tract.

The superior, anterior portions of the labia minora come together to encircle the **clitoris** (or glans clitoris), an organ that originates from the same cells as the glans penis and has abundant nerves that make it important in sexual sensation and orgasm. The **hymen** is a thin membrane that sometimes partially covers the entrance to the vagina. An intact hymen cannot be used as an indication of "virginity"; even at birth, this is only a partial membrane, as menstrual fluid and other secretions must be able to exit the body, regardless of penile–vaginal intercourse. The vaginal opening is located between the opening of the urethra and the anus. It is flanked by outlets to the **Bartholin's glands** (or greater vestibular glands) which secrete mucoid secretions to aid in vaginal and vulvar lubrication; they are the equivalent of Cowper's glands in the men. Skene's glands (or lesser vestibular glands)

flank the urethral opening and lubricate opening to the urethra; their secretions have an antimicrobial quality. Similar to male anatomy, women also have corpus cavernosum.

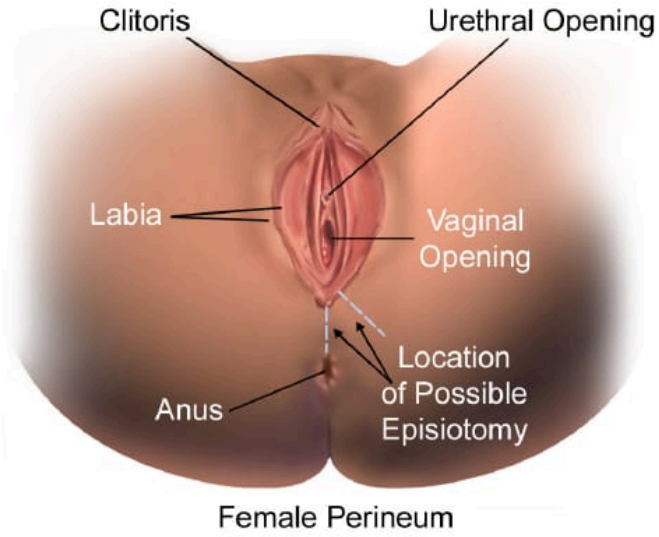

Figure 23.3.2: The Vulva. The external female genitalia are referred to collectively as the vulva. Just deep to the skin are glands and structures similar to those found in male anatomy. (Image credit: "Blausen_0355_Episiotomy" by Bruce Blaus is licensed under CC BY 3.0)

Vagina

The **vagina**, shown at the bottom of Figure 23.3.1 and Figure 23.3.2, is a muscular canal (approximately 10 cm long) that serves as the entrance to the reproductive tract. It also serves as the exit from the uterus during menses and childbirth. The outer walls of the anterior and posterior vagina are formed into longitudinal columns, or ridges, and the superior portion of the vagina—called the fornix—meets the protruding uterine cervix. The walls of the vagina are lined with an outer, fibrous adventitia; a middle layer of smooth muscle; and an inner mucous membrane with transverse folds called **rugae**. Together, the middle and inner layers allow the expansion of the vagina to accommodate intercourse and childbirth. The thin, perforated hymen can partially surround the opening to the vaginal orifice. The hymen can be ruptured with strenuous physical exercise, penile–vaginal intercourse, and childbirth. The Bartholin's glands and the lesser vestibular glands (located near the clitoris) secrete mucus, which keeps the vestibular area moist.

The vagina is home to a normal population of microorganisms that help to protect against infection by pathogenic bacteria, yeast, or other organisms that can enter the vagina. In a healthy woman, the most predominant type of vaginal bacteria is from the genus *Lactobacillus*. This family of beneficial bacterial flora secretes lactic acid, and thus protects the vagina by maintaining an acidic pH (below 4.5). Potential pathogens are less likely to survive in these acidic conditions. Lactic acid, in combination with other vaginal secretions, makes the vagina a self-cleansing organ. However, douching—or washing out the vagina with fluid—can disrupt the normal balance of healthy microorganisms, and actually increase a woman's risk for infections and irritation. Indeed, the American College of Obstetricians and Gynecologists recommend that women do not douche, and that they allow the vagina to maintain its normal healthy population of protective microbial flora.

Ovaries

The **ovaries** are the female gonads. Paired ovals, they are each about 2 to 3 cm in length, about the size of an almond (Figure 23.3.3). The ovaries are located within the pelvic cavity. The ovary is attached to the uterus via the **ovarian ligament**.

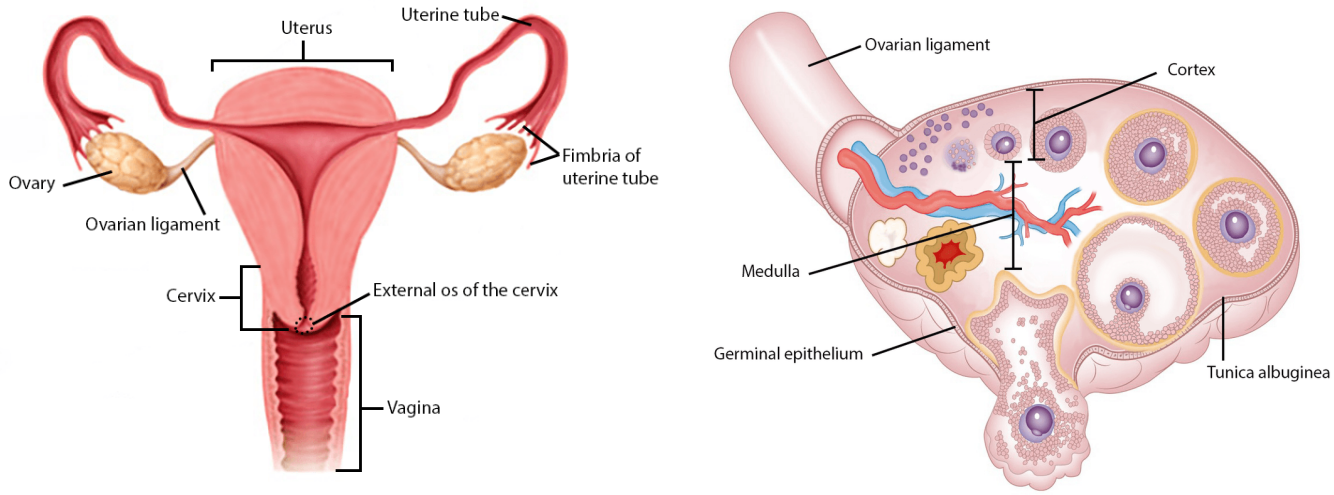

Figure 23.3.3: Ovaries. The almond shaped ovaries are located lateral to the uterus. Ovarian follicles are located in the cortex while the medulla contains connective tissue along with blood vessels. *(Image credit: "Female Reproductive Organs - Anterior View" by Jennifer Lange is licensed under CC BY-NC-SA 4.0, modification of original by StacyRed-Wiki via Wikimedia Commons. "Ovary Structure" by Jennifer Lange is licensed under CC BY-NC-SA 4.0, modification of "Slagter - Drawing Ovarium with folliculogenesis and ovulation - English labels" by Ron Slagter, Hope Wicks, LUMC, Cindy J.M. Hulsman, MUMC+ et al.)*

The ovary comprises an outer covering of cuboidal epithelium called the **germinal epithelium** that is superficial to a dense connective tissue covering called the **tunica albuginea**. Beneath the tunica albuginea is the cortex, or outer portion, of the organ. The cortex is composed of a tissue framework called the ovarian stroma that forms the bulk of the adult ovary. Oocytes develop within the outer layer of this stroma, each surrounded by supporting cells. This grouping of an oocyte and its supporting cells is called a **follicle**. The growth and development of ovarian follicles will be described shortly. Beneath the cortex lies the inner ovarian medulla, the site of blood vessels, lymph vessels, and the nerves of the ovary.

Ovarian Cycle

The **ovarian cycle** is a set of predictable changes in a female's oocytes and ovarian follicles. During a woman's reproductive years, it is a roughly 28-day cycle that can be correlated with, but is not the same as, the menstrual cycle (discussed shortly). The cycle includes two interrelated processes: **oogenesis** (the production of female gametes) and **folliculogenesis** (the growth and development of ovarian follicles).

Oogenesis

Oogenesis is the process of forming an egg or oocyte (Figure 23.3.4). The process begins with the ovarian stem cells, or **oogonia** (singular is oogonium). Oogonia are formed during fetal development, and divide via mitosis, much like spermatogonia in the testis. Unlike spermatogonia, however, oogonia form **primary oocytes** in the fetal ovary prior to birth. These primary oocytes are then arrested in this stage of meiosis I, only to resume it years later, beginning at puberty and continuing until the woman is near menopause (the cessation of a woman's reproductive functions). The number of primary oocytes present in the ovaries declines from one to two million in an infant, to approximately 400,000 at puberty, to zero by the end of menopause.

The initiation of **ovulation**—the release of an oocyte from the ovary—marks the transition from puberty into reproductive maturity for women. From then on, throughout a woman's reproductive years, ovulation occurs approximately once every 28 days. Just prior to ovulation, a surge of luteinizing hormone triggers the resumption of meiosis in a primary oocyte. This initiates the transition from primary to secondary oocyte. However, as you can see in Figure 23.3.4, this cell division does not result in two identical cells. Instead, the cytoplasm is divided unequally, and one daughter cell is much larger than the other. This larger cell, the secondary oocyte, eventually leaves the ovary during ovulation. The smaller cell, called the first **polar body**, may or may not complete meiosis and produce second polar bodies; in either case, it eventually disintegrates. Therefore, even though oogenesis produces up to four cells, only one survives.

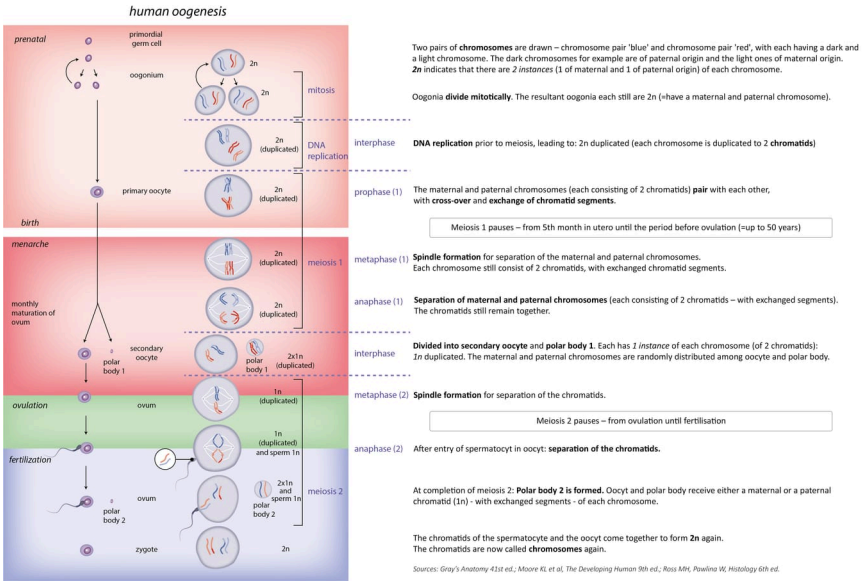

Figure 23.3.4: Oogenesis. The unequal cell division of oogenesis produces one to three polar bodies that later degrade, as well as a single haploid ovum, which is produced only if there is penetration of the secondary oocyte by a sperm cell. *(Image credit: "Slagter - Drawing Human oogenesis diagram with explanation - English labels" by Ron Slagter, O. Paul Gobée, LUMC, Hope Wicks, LUMC et al. is licensed under CC BY-NC-SA.)*

How does the diploid secondary oocyte become an **ovum**—the haploid female gamete? Meiosis of a secondary oocyte is completed only if a sperm succeeds in penetrating its barriers, which must occur within 24 hours of ovulation. Meiosis II then resumes, producing one haploid ovum that, at the instant of fertilization by a (haploid) sperm, becomes the first diploid cell of the new offspring (a **zygote**). Thus, the ovum can be thought of as a brief, transitional, haploid stage between the diploid oocyte and diploid zygote. If sperm does not penetrate, then the secondary oocyte will break down after 24 hrs.

The larger amount of cytoplasm contained in the female gamete is used to supply the developing zygote with nutrients during the period between fertilization and implantation into the uterus. Interestingly, sperm contribute only DNA at fertilization —not cytoplasm. Therefore, the cytoplasm and all of the cytoplasmic organelles in the developing embryo are of maternal origin. This includes mitochondria, which contain their own DNA. Scientific research in the 1980s determined that mitochondrial DNA was maternally inherited, meaning that you can trace your mitochondrial DNA directly to your mother, her mother, and so on back through your female ancestors.

EVERYDAY CONNECTIONS FEATURE: Mapping Human History with Mitochondrial DNA

When we talk about human DNA, we're usually referring to nuclear DNA; that is, the DNA coiled into chromosomal bundles in the nucleus of our cells. We inherit half of our nuclear DNA from our father, and half from our mother. However, mitochondrial DNA (mtDNA) comes only from the mitochondria in the cytoplasm of the fat ovum we inherit from our mother. She received her mtDNA from her mother, who got it from her mother, and so on. Each of our cells contains approximately 1700 mitochondria, with each mitochondrion packed with mtDNA containing approximately 37 genes.

Mutations (changes) in mtDNA occur spontaneously in a somewhat organized pattern at regular intervals in human history. By analyzing these mutational relationships, researchers have been able to determine that we can all trace our ancestry back to one female population who lived in Africa about 200,000 years ago. Scientists have given these women the biblical name Eve, although they are not, of course, the first Homo sapiens females. More precisely, they are our most recent common ancestor through matrilineal descent.

This doesn't mean that everyone's mtDNA today looks exactly like that of our ancestral Eve. Because of the spontaneous mutations in mtDNA that have occurred over the centuries, researchers can map different "branches" off of the "main trunk" of our mtDNA family tree. Your mtDNA might have a pattern of mutations that aligns more closely with one branch, and your neighbor's may align with another branch. Still, all branches eventually lead back to Eve.

> But what happened to the mtDNA of all of the other Homo sapiens females who were living at the time of Eve? Researchers explain that, over the centuries, their female descendants died childless or with only male children, and thus, their maternal line—and its mtDNA—ended.

Folliculogenesis

Again, ovarian follicles are oocytes and their supporting cells. They grow and develop in a process called **folliculogenesis**, which typically leads to ovulation of one follicle approximately every 28 days, along with death to multiple other follicles (Figure 23.3.5). The death of ovarian follicles is called atresia, and can occur at any point during follicular development. Recall that, a female infant at birth will have one to two million oocytes within her ovarian follicles, and that this number declines throughout life until menopause, when no follicles remain. As you'll see next, follicles progress from primordial, to primary, to secondary and tertiary stages prior to ovulation—with the oocyte inside the follicle remaining as a primary oocyte until right before ovulation.

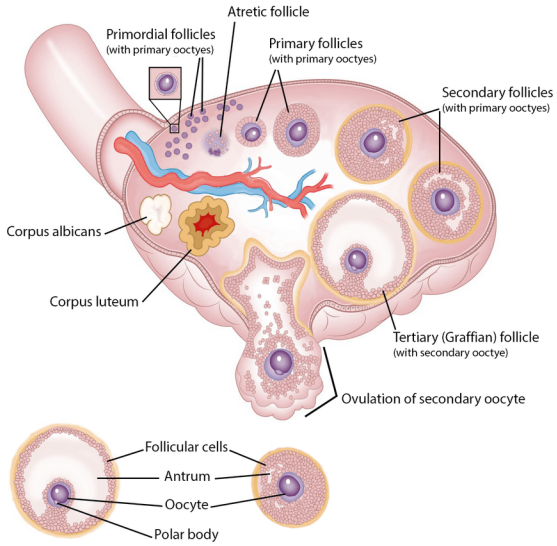

Figure 23.3.5: Folliculogenesis. The maturation of a follicle is shown in a clockwise direction proceeding from the primordial follicles to the tertiary follicles. As the follicle matures the follicular cells multiply and the antrum enlarges. Once the follicle is mature, it ruptures and releases the oocyte. Cells remaining in the follicle then develop into the corpus luteum. *(Image credit: "Ovarian Follicles" by Jennifer Lange is licensed under CC BY-NC-SA 4.0, modification of "Slagter - Drawing Ovarium with folliculogenesis and ovulation - English labels" by Ron Slagter, Hope Wicks, LUMC, Cindy J.M. Hulsman, MUMC+ et al.)*

Folliculogenesis begins with follicles in a resting state. These small **primordial follicles** are present in newborn females and are the prevailing follicle type in the adult ovary . Primordial follicles have only a single flat layer of support cells, called **granulosa cells**, that surround the oocyte, and they can stay in this resting state for years—some until right before menopause.

After puberty, a few primordial follicles will respond to a recruitment signal each day, and will join a pool of immature growing follicles called **primary follicles**. Primary follicles start with a single layer of granulosa cells, but the granulosa cells then become active and transition from a flat or squamous shape to a rounded, cuboidal shape as they increase in size and proliferate. As the granulosa cells divide, the follicles—now called **secondary follicles** (see Figure 23.3.3)—increase in diameter, adding a new outer layer of connective tissue, blood vessels, and **theca cells**—cells that work with the granulosa cells to produce estrogens.

Within the growing secondary follicle, the primary oocyte now secretes a thin acellular membrane called the zona pellucida that will play a critical role in fertilization. A thick fluid, called follicular fluid, that has formed between the granulosa cells also begins to collect into one large pool, or **antrum**. Follicles in which the antrum has become large and fully formed are considered **tertiary follicles** (or Graffian follicles). Several follicles reach the tertiary stage at the same time, and most of these will undergo atresia. The one that does not die will continue to grow and develop until ovulation, when it will expel its secondary oocyte surrounded by several layers of granulosa cells from the ovary. Keep in mind that most follicles don't make it to this point. In fact, roughly 99 percent of the follicles in the ovary will undergo atresia, which can occur at any stage of folliculogenesis.

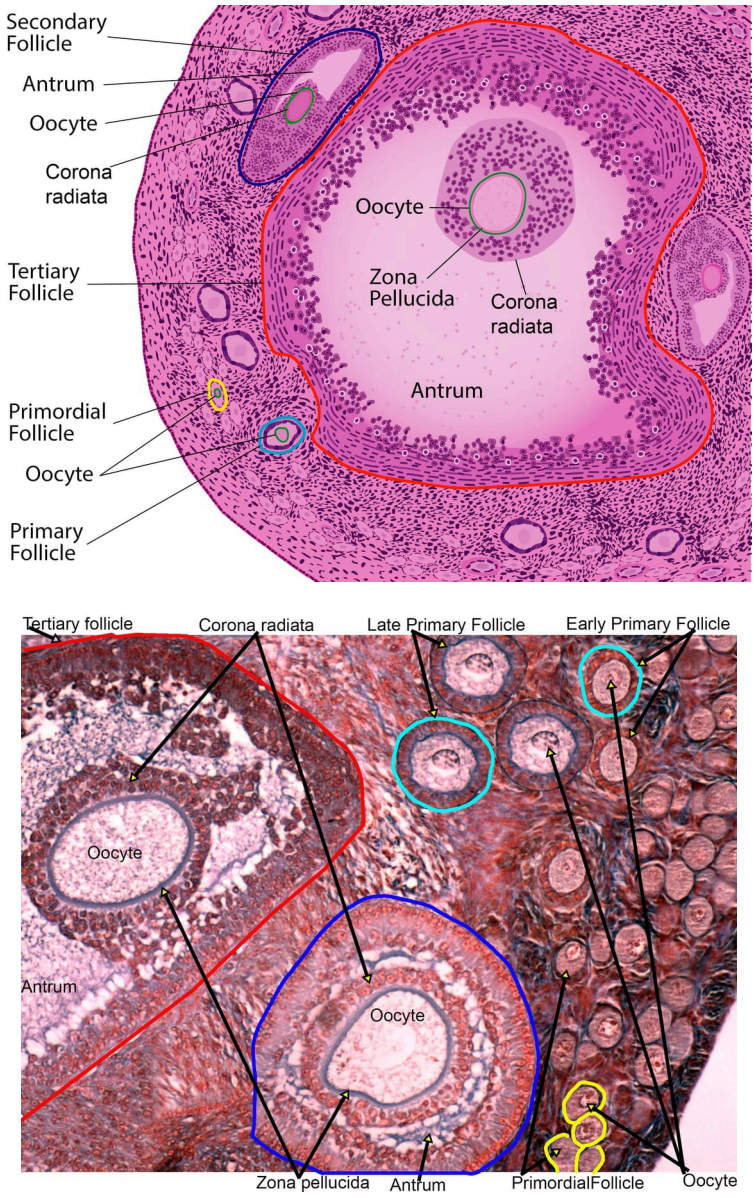

Figure 23.3.5*b*: Composite drawing of ovarian follicles in a rabbit ovary. Drawing shows the size of the different follicles to each other. (Image credit: "Ovary" by Sofia Elizondo (original work) is licensed under CC BY 3.0. Histology photograph by John Polos is licensed under CC BY 3.0)

After ovulation, a change happens in the granulosa and theca cells that remain in the follicle after the oocyte has been ovulated. This change is called luteinization , and it transforms the collapsed follicle into a new endocrine structure called the **corpus luteum**, (Figure 23.3.6) a term meaning "yellowish body". In addition to estrogen, the luteinized granulosa and theca cells of the corpus luteum begin to produce large amounts of the sex steroid hormone progesterone, a hormone that is critical for the establishment and maintenance of pregnancy.

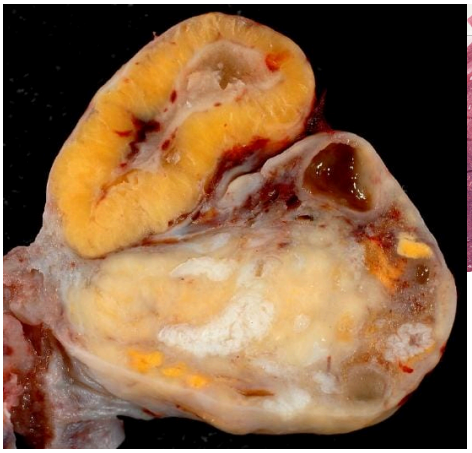

A. Gross specimen - corpus luteum and corpus albicans

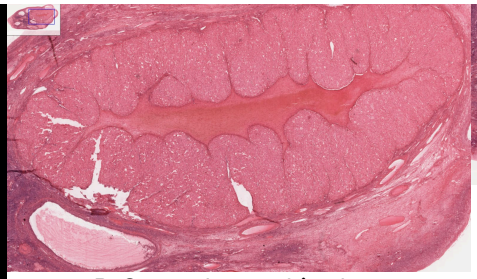

B. Corpus luteum histology

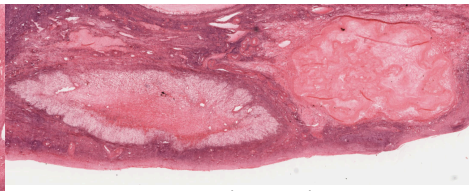

C. Corpus albicans histology

Figure 23.3.6: Corpus Luteum and Corpus Albicans. After ovulation the follicular cells remaining in the ovary secrete large amounts of progesterone, giving the cells a yellow color that give this structure the name corpus luteum (yellow body). If the oocyte is not fertilized this body will degrade and turn a whitish color - the corpus albicans. *(Image credits: "Human Ovary with Fully Developed Corpus Luteum" by Ed Ulthman is licensed under CC BY 2.0. Histology photos provided by the Regents of the University of Michigan Medical School © 2022 under a CC BY-NC-SA 3.0 license.)*

The post-ovulatory phase of progesterone secretion is known as the luteal phase of the ovarian cycle. If pregnancy does not occur within 10 to 12 days, the corpus luteum will stop secreting progesterone and degrade into the **corpus albicans** (Figure 23.3.6), a nonfunctional “whitish body” that will disintegrate in the ovary over a period of several months. During this time of reduced progesterone secretion, FSH and LH are once again stimulated, and the follicular phase begins again with a new cohort of early tertiary follicles beginning to grow and secrete estrogen.

Uterine Tubes

The **uterine tubes** (also called Fallopian tubes or oviducts) serve as the conduit of the oocyte from the ovary to the uterus (Figure 23.3.7). Each of the two uterine tubes is close to, but not directly connected to, the ovary. The wide, distal region of the tube flares out with slender, finger-like projections called **fimbriae,** which help to guide the oocyte into the tube. The middle region of the tube, is where fertilization often occurs. The inner, mucosal layer of the uterine tube contains mucus-secreting cells and ciliated columnar cells that beat in the direction of the uterus, producing a current that will be critical to move the oocyte/ovum from the distal to the proximal end and into the uterus.

Interactive Link

Query 23.3.1

This interactive element is not available in this format. Visit the link or scan the QR code to access it online.

View this Interactive Content online

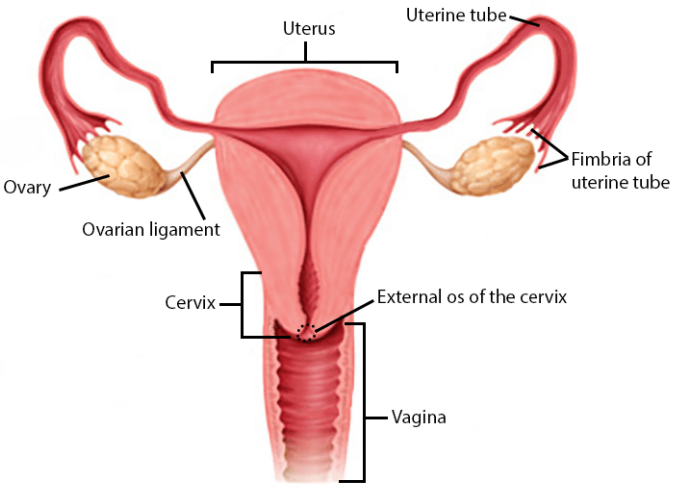

Figure 23.3.7: Female Reproductive Tract. This anterior view shows the relationship of the ovaries, uterine tubes (oviducts), and uterus. Sperm enter through the vagina, and fertilization of an ovulated oocyte usually occurs in the middle region of the uterine tube. *(Image credit: "Female Reproductive Organs - Anterior View" by Jennifer Lange is licensed under CC BY-NC-SA 4.0, modification of original by StacyRed-Wiki via Wikimedia Commons.)*

The open-ended structure of the uterine tubes can have significant health consequences if bacteria or other contagions enter through the vagina and move through the uterus, into the tubes, and then into the pelvic cavity. If this is left unchecked, a bacterial infection (sepsis) could quickly become life-threatening. The spread of an infection in this manner is of special concern when unskilled practitioners perform abortions in non-sterile conditions. Sepsis is also associated with sexually transmitted bacterial infections, especially gonorrhea and chlamydia. These increase a woman's risk for pelvic inflammatory disease (PID), infection of the uterine tubes or other reproductive organs. Even when resolved, PID can leave scar tissue in the tubes, leading to infertility.

If the oocyte is successfully fertilized, the resulting zygote will begin to divide into two cells, then four, and so on, as it makes its way through the uterine tube and into the uterus. There, it will implant and continue to grow. If the egg is not fertilized, it will simply degrade—either in the uterine tube or in the uterus, where it may be shed with the next menstrual period.

Uterus and Cervix

The **uterus** is the muscular organ that nourishes and supports the growing embryo (Figure 23.3.7). Its average size is approximately 5 cm wide by 7 cm long (approximately 2 in by 3 in) when a female is not pregnant. It has three sections. The portion of the uterus superior to the opening of the uterine tubes is called the fundus. The middle section of the uterus is called the body of uterus (or corpus). The **cervix** is the narrow inferior portion of the uterus that projects into the vagina. The cervix produces mucus secretions that become thin and stringy under the influence of high systemic plasma estrogen concentrations, and these secretions can facilitate sperm movement through the reproductive tract.

The wall of the uterus is made up of three layers (Figure 23.3.8). The most superficial layer is the serous membrane, or **perimetrium**, which consists of epithelial tissue that covers the exterior portion of the uterus. The middle layer, or **myometrium**, is a thick layer of smooth muscle responsible for uterine contractions. Most of the uterus is myometrial tissue, and the muscle

fibers run horizontally, vertically, and diagonally, allowing the powerful contractions that occur during labor and the less powerful contractions (or cramps) that help to expel menstrual blood during a woman's period. Anteriorly directed myometrial contractions also occur near the time of ovulation, and are thought to possibly facilitate the transport of sperm through the female reproductive tract.

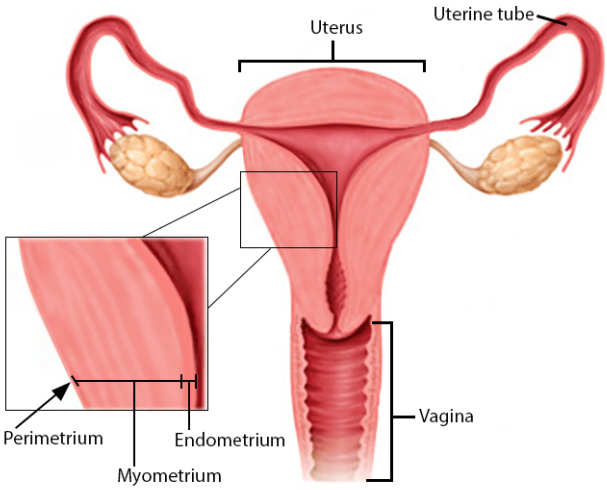

Figure 23.3.8: Uterine Wall. The wall of the uterus has three layers: perimetrium, myometrium, and endometrium. The functional layer of the endometrium sheds during mensus. *(Image credit: "Uterine Wall" by Jennifer Lange is licensed under CC BY-NC-SA 4.0, modification of original by StacyRed-Wiki via Wikimedia Commons.)*

The innermost layer of the uterus is called the **endometrium**. The endometrium contains a connective tissue lining, the lamina propria, which is covered by epithelial tissue that lines the lumen. Structurally, the endometrium consists of two layers: the **stratum basalis** and the **stratum functionalis** (the basal and functional layers). The stratum basalis layer is part of the lamina propria and is adjacent to the myometrium; this layer does not shed during menses. In contrast, the thicker stratum functionalis layer contains the glandular portion of the lamina propria and the endothelial tissue that lines the uterine lumen. It is the stratum functionalis that grows and thickens in response to increased levels of estrogen and progesterone. In the luteal phase of the menstrual cycle, special branches off of the uterine artery called spiral arteries supply the thickened stratum functionalis. This inner functional layer provides the proper site of implantation for the fertilized egg, and—should fertilization not occur—it is only the stratum functionalis layer of the endometrium that sheds during menstruation.

Recall that during the follicular phase of the ovarian cycle, the tertiary follicles are growing and secreting estrogen. At the same time, the stratum functionalis of the endometrium is thickening to prepare for a potential implantation. The post-ovulatory increase in progesterone, which characterizes the luteal phase, is key for maintaining a thick stratum functionalis. As long as a functional corpus luteum is present in the ovary, the endometrial lining is prepared for implantation. Indeed, if an embryo implants, signals are sent to the corpus luteum to continue secreting progesterone to maintain the endometrium, and thus maintain the pregnancy. If an embryo does not implant, no signal is sent to the corpus luteum and it degrades, ceasing progesterone production and ending the luteal phase. Without progesterone, the endometrium thins and, under the influence of prostaglandins, the spiral arteries of the endometrium constrict and rupture, preventing oxygenated blood from reaching the endometrial tissue. As a result, endometrial tissue dies and blood, pieces of the endometrial tissue, and white blood cells are shed through the vagina during menstruation, or the **menses**. The first menses after puberty, called **menarche**, can occur either before or after the first ovulation.

DISORDERS OF THE...

Female Reproductive System

Research over many years has confirmed that cervical cancer is most often caused by a sexually transmitted infection with human papillomavirus (HPV). There are over 100 related viruses in the HPV family, and the characteristics of each strain determine the outcome of the infection. In all cases, the virus enters body cells and uses its own genetic material to take over the host cell's metabolic machinery and produce more virus particles.

HPV infections are common in both men and women. Indeed, a recent study determined that 42.5 percent of females had HPV at the time of testing. These women ranged in age from 14 to 59 years and differed in race, ethnicity, and number of sexual partners. Of note, the prevalence of HPV infection was 53.8 percent among women aged 20 to 24 years, the age group with the highest infection rate.

Though most HPV infections do not cause disease, the disruption of normal cellular functions in the low-risk forms of HPV can cause the male or female human host to develop genital warts. Often, the body is able to clear an HPV infection by normal immune responses within 2 years. However, the more serious, high-risk infection by certain types of HPV can result in cancer of the cervix. Infection with either of the cancer-causing variants HPV 16 or HPV 18 has been linked to more than 70 percent of all cervical cancer diagnoses. Although even these high-risk HPV strains can be cleared from the body over time, infections persist in some individuals. If this happens, the HPV infection can influence the cells of the cervix to develop precancerous changes.

Risk factors for cervical cancer include having unprotected sex; having multiple sexual partners; a first sexual experience at a younger age, when the cells of the cervix are not fully mature; failure to receive the HPV vaccine; a compromised immune system; and smoking. The risk of developing cervical cancer is doubled with cigarette smoking.

The prevalence of cervical cancer in the United States is very low because of regular screening exams called pap smears. Pap smears sample cells of the cervix, allowing the detection of abnormal cells. If pre-cancerous cells are detected, there are several highly effective techniques that are currently in use to remove them before they pose a danger. However, women in developing countries often do not have access to regular pap smears. As a result, these women account for as many as 80 percent of the cases of cervical cancer worldwide.

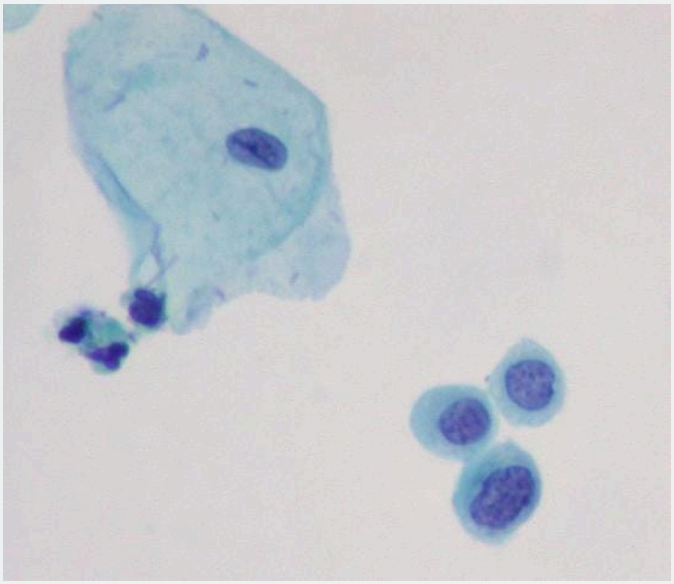

Figure 23.3.9: PAP Smear. The cell in the top, left-hand corner is a normal surface squamous epithelial cell. The three cells in the bottom, right-hand corner are examples of a high-grade squamous intraepithelial lesion (HSIL), showing a high nucleus/cytoplasm ratio variation in nuclear size, and darkly stained nuclei. Such cells often develop from an HPV infection and they may or may not become cancerous. ("PAP (ThinPrep): HSIL" by Ed Uthman is licensed under CC BY 2.0.)

In 2006, the first vaccine against the high-risk types of HPV was approved. There are now two HPV vaccines available: Gardasil® and Cervarix®. Whereas these vaccines were initially only targeted for women, because HPV is sexually transmitted, both men and women require vaccination for this approach to achieve its maximum efficacy. A recent study suggests that the HPV vaccine has cut the rates of HPV infection by the four targeted strains at least in half. Unfortunately, the high cost of manufacturing the vaccine is currently limiting access to many women worldwide.

Breasts

Whereas the breasts are located far from the other female reproductive organs, they are considered accessory organs of the female reproductive system. The function of the breasts is to supply milk to an infant in a process called lactation. The external features of the breast include a nipple surrounded by a pigmented **areola**, whose coloration may deepen during pregnancy. The areola is typically circular and can vary in size from 25 to 100 mm in diameter (Figure 23.3.10). The areolar region is characterized by small, raised areolar glands that secrete lubricating fluid during lactation to protect the nipple from chafing. When a baby nurses, or draws milk from the breast, the entire areolar region is taken into the mouth.

Breast milk is produced by the **mammary glands**, which are modified sweat glands. The milk itself exits the breast through the nipple via 15 to 20 **lactiferous ducts** that open on the surface of the nipple. These lactiferous ducts each extend to a **lactiferous sinus** that connects to a glandular lobe within the breast itself that contains groups of milk-secreting cells in clusters called **alveoli** (see Figure 23.3.10). The clusters can change in size depending on the amount of milk in the alveolar lumen. Once milk is made in the alveoli, stimulated myoepithelial cells that surround the alveoli contract to push the milk to the lactiferous sinuses. From here, the baby can draw milk through the lactiferous ducts by suckling. The lobes themselves are surrounded by fat tissue, which determines the size of the breast; breast size differs between individuals and does not affect the amount of milk produced. Supporting the breasts are multiple bands of connective tissue called **suspensory ligaments** that connect the breast tissue to the dermis of the overlying skin.

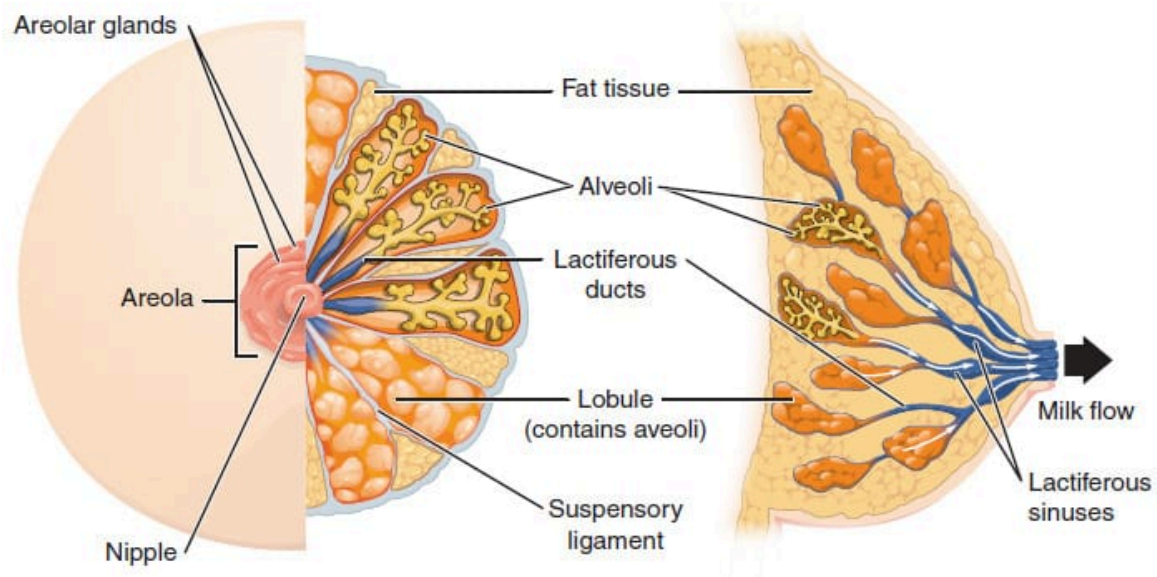

Figure 23.3.10: Anatomy of the Breast. During lactation, milk moves from the alveoli through the lactiferous ducts to the nipple. (Image credit: "Anatomy of the Breast" by OpenStax is licensed under CC BY 3.0)

During the normal hormonal fluctuations in the menstrual cycle, breast tissue responds to changing levels of estrogen and progesterone, which can lead to swelling and breast tenderness in some individuals, especially during the secretory phase. If pregnancy occurs, the increase in hormones leads to further development of the mammary tissue and enlargement of the breasts.

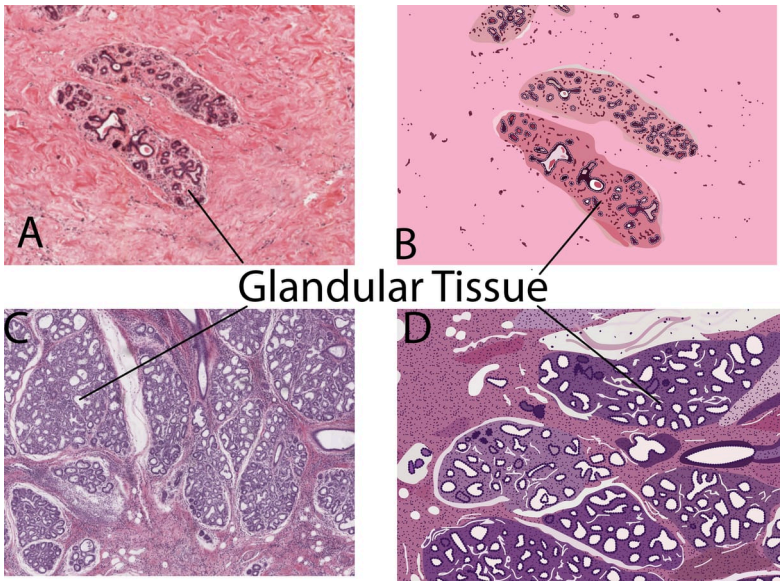

Figure 23.3.11: Non lactation (A and B) and lactating (C and D) breasts. These 4 images contrast a non lactating breast (A and B) showing very little glandular tissue with a lactating breast (C and D) with well developed glandular tissue. (Non lactating (A) and lactating (C) histology images provided by Histology slide provided by the Regents of the University of Michigan under a BY-SA-NC Creative Commons license 4.0. Illustrations of "non lactating breast" (B) and “Lactating breast" (D) by Sofia Elizondo (original work) OpenStax is licensed under CC BY 3.0)

AGING AND THE...

Female Reproductive System

Female fertility (the ability to conceive) peaks when women are in their twenties, and is slowly reduced until a women reaches 35 years of age. After that time, fertility declines more rapidly, until it ends completely at the end of menopause. Menopause is the cessation of the menstrual cycle that occurs as a result of the loss of ovarian follicles and the hormones that they produce. A woman is considered to have completed menopause if she has not menstruated in a full year. After that point, she is considered postmenopausal. The average age for this change is consistent worldwide at between 50 and 52 years of age, but it can normally occur in a woman’s forties, or later in her fifties. Poor health, including smoking, can lead to earlier loss of fertility and earlier menopause.

As a woman reaches the age of menopause, depletion of the number of viable follicles in the ovaries due to atresia affects the hormonal regulation of the menstrual cycle. During the years leading up to menopause, there is a decrease in the levels of the hormone inhibin, which normally participates in a negative feedback loop to the pituitary to control the production of FSH. The menopausal decrease in inhibin leads to an increase in FSH. The presence of FSH stimulates more follicles to grow and secrete estrogen. Because small, secondary follicles also respond to increases in FSH levels, larger numbers of follicles are stimulated to grow; however, most undergo atresia and die. Eventually, this process leads to the depletion of all follicles in the ovaries, and the production of estrogen falls off dramatically. It is primarily the lack of estrogens that leads to the symptoms of menopause.

The earliest changes occur during the menopausal transition, often referred to as peri-menopause, when a women’s cycle becomes irregular but does not stop entirely. Although the levels of estrogen are still nearly the same as before the transition, the level of progesterone produced by the corpus luteum is reduced. This decline in progesterone can lead to abnormal growth, or hyperplasia, of the endometrium. This condition is a concern because it increases the risk of developing endometrial cancer. Two harmless conditions that can develop during the transition are uterine fibroids, which are benign masses of cells, and irregular bleeding. As estrogen levels change, other symptoms that occur are hot flashes and night sweats, trouble sleeping, vaginal dryness, mood swings, difficulty focusing, and thinning of hair on the head along with the growth of more hair on the face. Depending on the individual, these symptoms can be entirely absent, moderate, or severe.

After menopause, lower amounts of estrogens can lead to other changes. Cardiovascular disease becomes as prevalent in women as in men, possibly because estrogens reduce the amount of cholesterol in the blood vessels. When estrogen is lacking, many women find that they suddenly have problems with high cholesterol and the cardiovascular issues that accompany it. Osteoporosis is another problem because bone density decreases rapidly in the first years after menopause. The reduction in bone density leads to a higher incidence of fractures.

Hormone therapy (HT), which employs medication (synthetic estrogens and progestins) to increase estrogen and progestin levels, can alleviate some of the symptoms of menopause. In 2002, the Women's Health Initiative began a study to observe women for the long-term outcomes of hormone replacement therapy over 8.5 years. However, the study was prematurely terminated after 5.2 years because of evidence of a higher than normal risk of breast cancer in patients taking estrogen-only HT. The potential positive effects on cardiovascular disease were also not realized in the estrogen-only patients. The results of other hormone replacement studies over the last 50 years, including a 2012 study that followed over 1,000 menopausal women for 10 years, have shown cardiovascular benefits from estrogen and no increased risk for cancer. Some researchers believe that the age group tested in the 2002 trial may have been too old to benefit from the therapy, thus skewing the results. In the meantime, intense debate and study of the benefits and risks of replacement therapy is ongoing. Current guidelines approve HT for the reduction of hot flashes or flushes, but this treatment is generally only considered when women first start showing signs of menopausal changes, is used in the lowest dose possible for the shortest time possible (5 years or less), and it is suggested that women on HT have regular pelvic and breast exams.

Concept Review

The external female genitalia are collectively called the vulva. The vagina is the pathway into and out of the uterus. The man's penis is inserted into the vagina to deliver sperm, and the baby exits the uterus through the vagina during childbirth.

The ovaries produce oocytes, the female gametes, in a process called oogenesis. As with spermatogenesis, meiosis produces the haploid gamete (in this case, an ovum); however, it is completed only in an oocyte that has been penetrated by a sperm. In the ovary, an oocyte surrounded by supporting cells is called a follicle. In folliculogenesis, primordial follicles develop into primary, secondary, and tertiary follicles. Early tertiary follicles with their fluid-filled antrum will be stimulated by an increase in FSH, a gonadotropin produced by the anterior pituitary, to grow in the 28-day ovarian cycle. Supporting granulosa and theca cells in the growing follicles produce estrogens, until the level of estrogen in the bloodstream is high enough that it triggers negative feedback at the hypothalamus and pituitary. This results in a reduction of FSH and LH, and most tertiary follicles in the ovary undergo atresia (they die). One follicle, usually the one with the most FSH receptors, survives this period and is now called the dominant follicle. The dominant follicle produces more estrogen, triggering positive feedback and the LH surge that will induce ovulation. Following ovulation, the granulosa cells of the empty follicle luteinize and transform into the progesterone-producing corpus luteum. The ovulated oocyte with its surrounding granulosa cells is picked up by the infundibulum of the uterine tube, and beating cilia help to transport it through the tube toward the uterus. Fertilization occurs within the uterine tube, and the final stage of meiosis is completed.

The uterus has three regions: the fundus, the body, and the cervix. It has three layers: the outer perimetrium, the muscular myometrium, and the inner endometrium. The endometrium responds to estrogen released by the follicles during the menstrual cycle and grows thicker with an increase in blood vessels in preparation for pregnancy. If the egg is not fertilized, no signal is sent to extend the life of the corpus luteum, and it degrades, stopping progesterone production. This decline in progesterone results in the sloughing of the inner portion of the endometrium in a process called menses, or menstruation.

The breasts are accessory sexual organs that are utilized after the birth of a child to produce milk in a process called lactation. Birth control pills provide constant levels of estrogen and progesterone to negatively feed back on the hypothalamus and pituitary, and suppress the release of FSH and LH, which inhibits ovulation and prevents pregnancy.

Review Questions

Query 23.3.1

This interactive element is not available in this format. Visit the link or scan the QR code to access it online.

View this Interactive Content online

Critical Thinking Questions

Query 23.3.1

This interactive element is not available in this format. Visit the link or scan the QR code to access it online.

View this Interactive Content online

Query 23.3.1

This interactive element is not available in this format. Visit the link or scan the QR code to access it online.

View this Interactive Content online

Query 23.3.1

This interactive element is not available in this format. Visit the link or scan the QR code to access it online.

View this Interactive Content online

Glossary

Query 23.3.1

This interactive element is not available in this format. Visit the link or scan the QR code to access it online.

View this Interactive Content online

Contributors and Attributions

- OpenStax Anatomy & Physiology (CC BY 4.0). Access for free at https://openstax.org/books/anatomy-and-physiology

This page titled 23.3: Anatomy of the Female Reproductive System is shared under a CC BY-NC-SA 4.0 license and was authored, remixed, and/or curated by Jennifer Lange et al..

- 23.3: Anatomy of the Female Reproductive System by Whitney Menefee, Julie Jenks, Chiara Mazzasette, and Kim-Leiloni Nguyen is licensed CC BY 4.0.

23.4: Development of the Male and Female Reproductive Systems

By the end of the section, you will be able to:

- Explain how bipotential tissues are directed to develop into male or female sex organs
- Name the rudimentary duct systems in the embryo that are precursors to male or female internal sex organs
- Describe the hormonal changes that bring about puberty, and the secondary sex characteristics of men and women

The sperm has 24 hrs after ovulation to fertilize the ovum. Fertilization is defined as the combining of the 23 chromosomes from the sperm with the 23 chromosomes from the ovum. The fertilized egg, called a **zygote**, will undergo many rounds of cell division while the cilia inside the fallopian tube push it along. As the zygote divides, it is becomes a solid ball of 16 cells called a **morula**. The morula will continue dividing while hollowing out with a space in the center. This hollow ball of cells is now a **blastocyst** and will implant in the uterus. The development of the reproductive systems begins soon after fertilization of the egg, with primordial gonads beginning to develop approximately one month after conception. Reproductive development continues in utero, but there is little change in the reproductive system between infancy and puberty.Development of the Sexual Organs in the Embryo and Fetus

Females are considered the “fundamental” sex—that is, without much chemical prompting, all fertilized eggs would develop into females. To become a male, an individual must be exposed to the cascade of factors initiated by a single gene on the male Y chromosome. This is called the SRY (Sex-determining *R*egion of the *Y* chromosome). Because females do not have a Y chromosome, they do not have the *SRY* gene. Without a functional *SRY* gene, an individual will be female.

In both male and female embryos, the same group of cells has the potential to develop into either the male or female gonads; this tissue is considered bipotential. The *SRY* gene actively recruits other genes that begin to develop the testes, and suppresses genes that are important in female development. As part of this *SRY*-prompted cascade, germ cells in the bipotential gonads differentiate into spermatogonia. Without *SRY*, different genes are expressed, oogonia form, and primordial follicles develop in the primitive ovary (Figure 23.4.1).

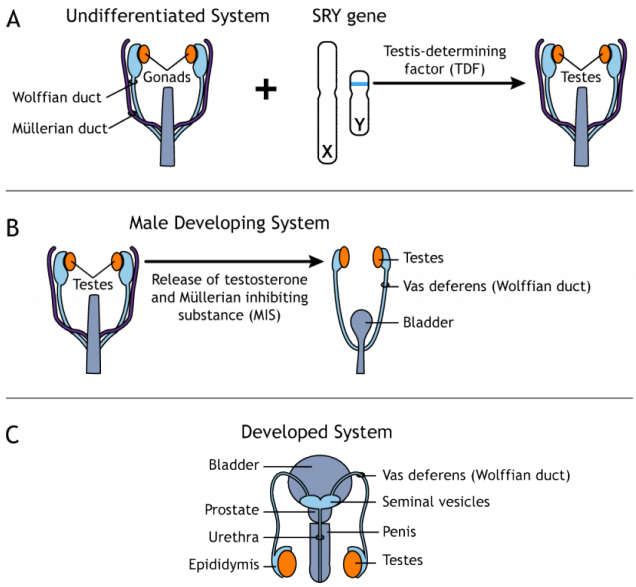

Figure 23.4.1: Male Reproductive System Development. The undifferentiated gonadal system is the same for both sexes. In males, the SRY gene is activated during development causing production of testis-determining factor, which results in a cascade of gene activation. The gonads become testes, the Wolffian ducts become the vas deferens, seminal vesicles, and epididymis. The presence of testosterone also causes the development of the penis and prostate gland in the fully developed system. *(Image credit: "Male Gonad Differentiation" by Casey Henley is licensed under a Creative Commons Attribution Non-Commercial Share-Alike (CC BY-NC-SA) 4.0 International License.)*

Soon after the formation of the testis, the Leydig cells begin to secrete testosterone. Testosterone can influence tissues that are bipotential to become male reproductive structures. For example, with exposure to testosterone, cells that could become either the glans penis or the glans clitoris form the glans penis. Without testosterone, these same cells differentiate into the clitoris. Not all tissues in the reproductive tract are bipotential. The internal reproductive structures (for example the uterus, uterine tubes, and part of the vagina in females; and the epididymis, ductus deferens, and seminal vesicles in males) form from one of two rudimentary duct systems in the embryo. For proper reproductive function in the adult, one set of these ducts must develop properly, and the other must degrade. In males, secretions from sustentacular cells trigger a degradation of the female duct, called the **Müllerian duct**. At the same time, testosterone secretion stimulates growth of the male tract, the **Wolffian duct**. Without such sustentacular cell secretion, the Müllerian duct will develop; without testosterone, the Wolffian duct will degrade. Thus, the developing offspring will be female (Figure 23.4.2)

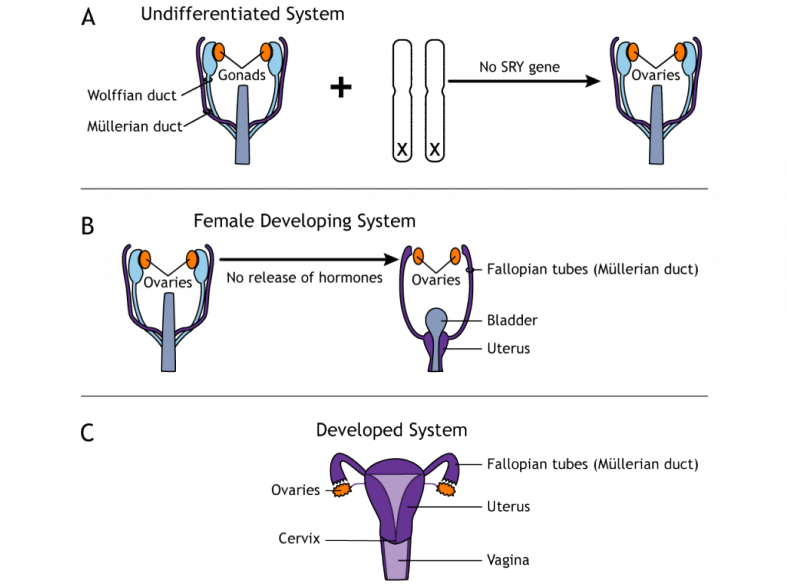

Figure 23.4.2: Female Reproductive System Development. The undifferentiated gonadal system is the same for both sexes. In the absence of the SRY gene during the 6th to 12th week of gestation, the gonads become the ovaries. B. The ovaries do not produce any hormones during development which causes the Müllerian ducts to become the fallopian tubes, uterus, and vagina, and the Wolffian ducts degenerate. C. In the fully developed system, the cervix is the lower part of the uterus, which separates the uterus from the vagina. *(Image credit: "Female Gonad Differentiation" bu Casey Henley is licensed under a Creative Commons Attribution Non-Commercial Share-Alike (CC BY-NC-SA) 4.0 International License.)*

Further Sexual Development Occurs at Puberty

Puberty is the stage of development at which individuals become sexually mature. Though the outcomes of puberty for boys and girls are very different, the hormonal control of the process is very similar. In addition, though the timing of these events varies between individuals, the sequence of changes that occur is predictable for male and female adolescents. As shown in Figure 23.4.3, a concerted release of hormones from the hypothalamus (GnRH), the anterior pituitary (LH and FSH), and the gonads (either testosterone or estrogen) is responsible for the maturation of the reproductive systems and the development of **secondary sex characteristics**, which are physical changes that serve auxiliary roles in reproduction.

In addition to age, multiple factors can affect the age of onset of puberty, including genetics, environment, and psychological stress. One of the more important influences may be nutrition; historical data demonstrate the effect of better and more consistent nutrition on the age of menarche in girls in the United States, which decreased from an average age of approximately 17 years of age in 1860, to the age of approximately 12.75 years in 1960, and to 12.4 years today. Some studies indicate a link between puberty onset and the amount of stored fat in an individual. This effect is more pronounced in girls, but has been documented in both sexes. Body fat, corresponding with secretion of the hormone leptin by adipose cells, appears to have a strong role in determining menarche. This may reflect to some extent the high metabolic costs of gestation and lactation. In girls who are lean and highly active, such as gymnasts, there is often a delay in the onset of puberty.

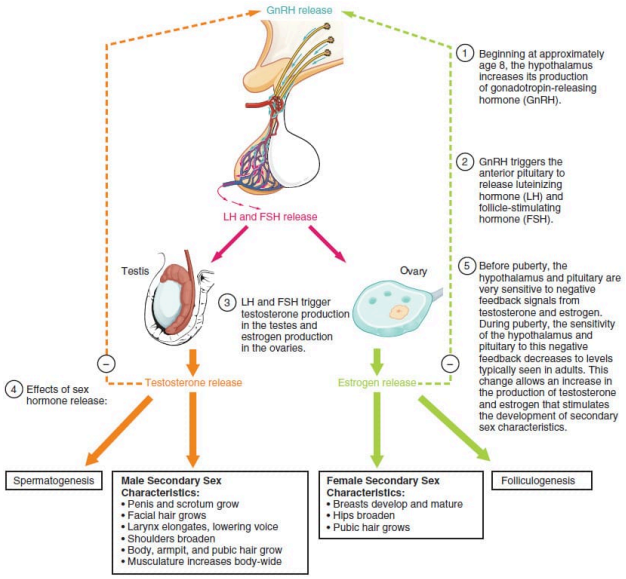

Figure 23.4.3: Hormones of Puberty. During puberty, the release of LH and FSH from the anterior pituitary stimulates the gonads to produce sex hormones in both male and female adolescents. (Image credit: "Hormones at Puberty" by OpenStax is licensed under CC BY 3.0)

Signs of Puberty

Different sex steroid hormone concentrations between the sexes also contribute to the development and function of secondary sexual characteristics. Examples of secondary sexual characteristics are listed in Table 23.4.1.

Table 23.4.1: Development of the Secondary Sexual Characteristics

Male	Female
Increased larynx size and deepening of the voice	Deposition of fat, predominantly in breasts and hips
Increased muscular development	Breast development
Growth of facial, axillary, and pubic hair, and increased growth of body hair	Broadening of the pelvis and growth of axillary and pubic hair

As a girl reaches puberty, typically the first change that is visible is the development of the breast tissue. This is followed by the growth of axillary and pubic hair. A growth spurt normally starts at approximately age 9 to 11, and may last two years or more. During this time, a girl's height can increase 3 inches a year. The next step in puberty is menarche, the start of menstruation.

In boys, the growth of the testes is typically the first physical sign of the beginning of puberty, which is followed by growth and pigmentation of the scrotum and growth of the penis. The next step is the growth of hair, including armpit, pubic, chest, and facial hair. Testosterone stimulates the growth of the larynx and thickening and lengthening of the vocal folds, which causes the voice to drop in pitch. The first fertile ejaculations typically appear at approximately 15 years of age, but this age can vary widely across individual boys. Unlike the early growth spurt observed in females, the male growth spurt occurs toward the end of puberty, at approximately age 11 to 13, and a boy's height can increase as much as 4 inches a year. In some males, pubertal development can continue through the early 20s.

Concept Review

The reproductive systems of males and females begin to develop soon after conception. A gene on the male's Y chromosome called *SRY* is critical in stimulating a cascade of events that simultaneously stimulate testis development and repress the development of female structures. Testosterone produced by Leydig cells in the embryonic testis stimulates the development of male sexual organs. If testosterone is not present, female sexual organs will develop.

Whereas the gonads and some other reproductive tissues are considered bipotential, the tissue that forms the internal reproductive structures stems from ducts that will develop into only male (Wolffian) or female (Müllerian) structures. To be able to

reproduce as an adult, one of these systems must develop properly and the other must degrade.

Further development of the reproductive systems occurs at puberty. The increase in sex steroid hormones leads to maturation of the gonads and other reproductive organs. The initiation of spermatogenesis begins in boys, and girls begin ovulating and menstruating. Increases in sex steroid hormones also lead to the development of secondary sex characteristics such as breast development in girls and facial hair and larynx growth in boys.

Review Questions

Query 23.4.3

This interactive element is not available in this format. Visit the link or scan the QR code to access it online.

View this Interactive Content online

Critical Thinking Questions

Query 23.4.4

This interactive element is not available in this format. Visit the link or scan the QR code to access it online.

View this Interactive Content online

Query 23.4.5

This interactive element is not available in this format. Visit the link or scan the QR code to access it online.

View this Interactive Content online

Glossary

Query 23.4.6

This interactive element is not available in this format. Visit the link or scan the QR code to access it online.

View this Interactive Content online

Contributors and Attributions

- OpenStax Anatomy & Physiology (CC BY 4.0). Access for free at https://openstax.org/books/anatomy-and-physiology

This page titled 23.4: Development of the Male and Female Reproductive Systems is shared under a CC BY-NC-SA 4.0 license and was authored, remixed, and/or curated by Jennifer Lange et al..

- 23.4: Development of the Male and Female Reproductive Systems by Whitney Menefee, Julie Jenks, Chiara Mazzasette, and Kim-Leiloni Nguyen is licensed CC BY 4.0.

23.5: Practice Practical- the Reproductive System

Fill in the blank with the correct word or words.

Query 23.5.1

This interactive element is not available in this format. Visit the link or scan the QR code to access it online.

View this Interactive Content online

Query 23.5.1

This interactive element is not available in this format. Visit the link or scan the QR code to access it online.

View this Interactive Content online

Query 23.5.1

This interactive element is not available in this format. Visit the link or scan the QR code to access it online.

View this Interactive Content online

Query 23.5.1

This interactive element is not available in this format. Visit the link or scan the QR code to access it online.

View this Interactive Content online

This page titled 23.5: Practice Practical- the Reproductive System is shared under a CC BY-NC-SA 4.0 license and was authored, remixed, and/or curated by Jennifer Lange et al..

23.6: Anatomical Atlas - Reproductive Systems

A compendium of anatomical images: slides, models, and/or cadavers.

Models

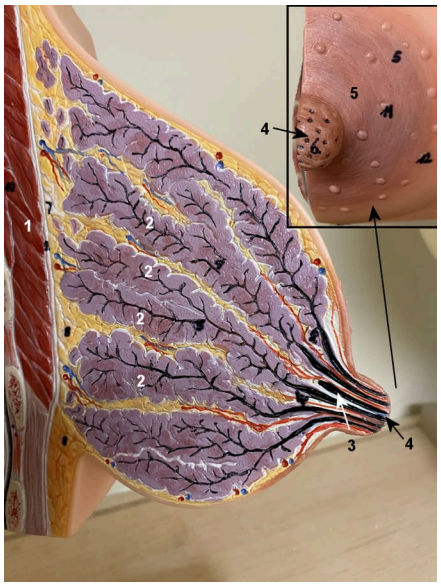

Image Credit

"*Breast Model*" by John Polos and is licensed under CC 4.0

Answer Key (click to show/hide answers)

1 - Pectoralis Major
2 - Lobules
3 - Lactiferous duct
4 - Nipple
5 - Areola

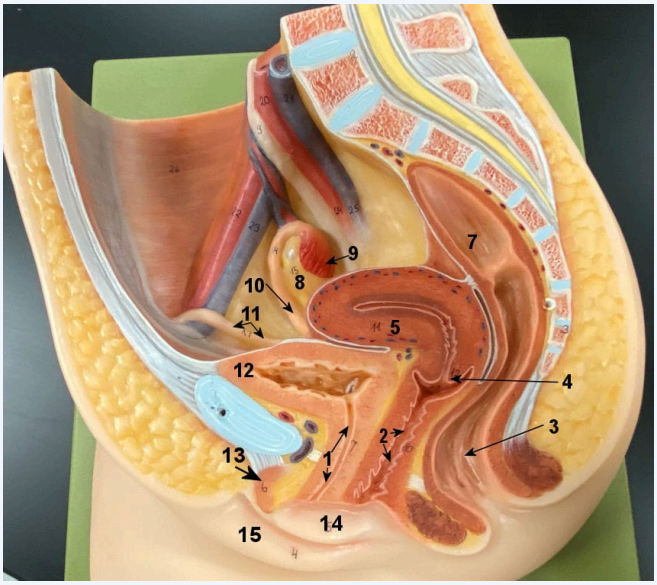

Image Credit

"*Female plate model*" by John Polos and is licensed under CC 4.0.

Answer Key (click to show/hide answers)

1 - Urethra
2 - Vagina
3 - Anus
4 - Cervix
5 - Myometrium of the Uterus
7 - Sigmoid Colon
8 - Ovary
9 - Fimbriae
10- Uterine Tube
11 - Round Ligament
12 - Urinary Bladder
13 - Clitoris
14 - Labia Minora
15 - Labia Majora

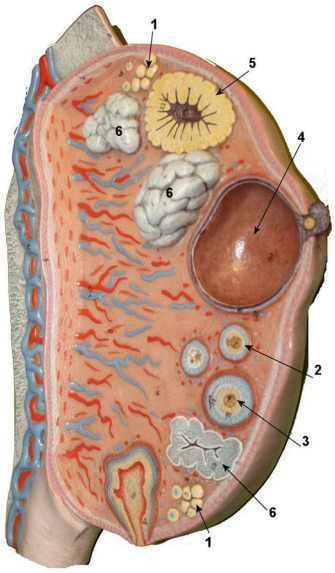

Image Credit

"*Ovary model*" by John Polos and is licensed under CC 4.0

Answer Key (click to show/hide answers)

1 - Primordial Follicle
2 - Primary Follicle
3 - Primary Follicle
4 - Tertiary Follicle at Ovulation
5 - Corpus Luteum
6 - Corpus Albicans

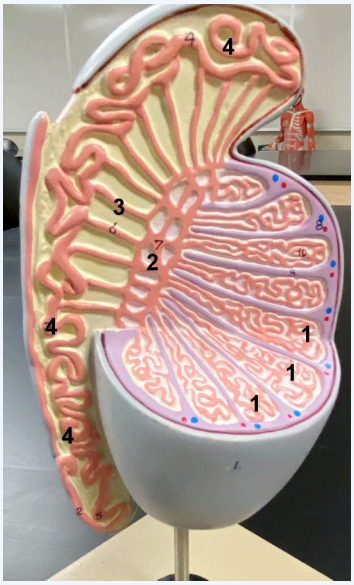

Image Credit

"*Testis model*" by John Polos and is licensed under CC 4.0

Answer Key (click to show/hide answers)

1 - Seminiferous tubules
2 - Rete Testis
3 - Efferent Ductules
4 - Epididymus

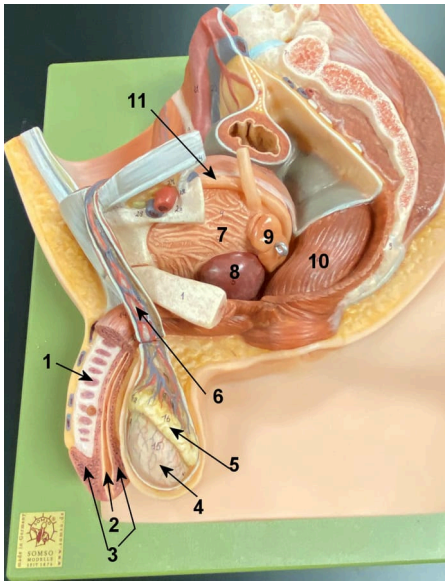

Image Credit

"*Male plate model*" by John Polos and is licensed under CC 4.0

Answer Key (click to show/hide answers)

1 - Corpus Cavernosum
2 - Urethra
3 - Corpus Spongiosum (in the Glans)
4 - Tunica albuginea of the testis
5 - Epididymus
6 - Spermatic Cord
7 - Urinary Bladder
8 - Prostate Gland
9 - Seminal Vesicle
10 - Rectum
11 - Vas Deferens (Ductus Deferens)

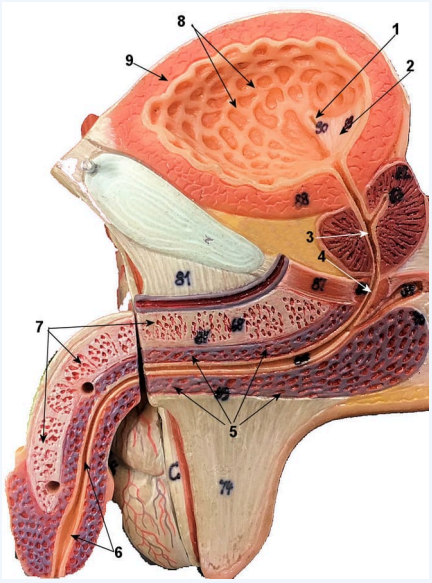

mage Credit

"*Male cross section-atlas*" by John Polos and is licensed under CC 4.0

Answer Key (click to show/hide answers)

1 - Entrance for Ureter
2 - Trigone
3 - Prostatic urethra
4 - Membranous urethra
5 - Spongy urethra
6 - Corpus spongiosum
7 - Corpus cavernosa
8 - Rugae of mucosal layer of urinary bladder
9 - Muscularis layer of urinary bladder

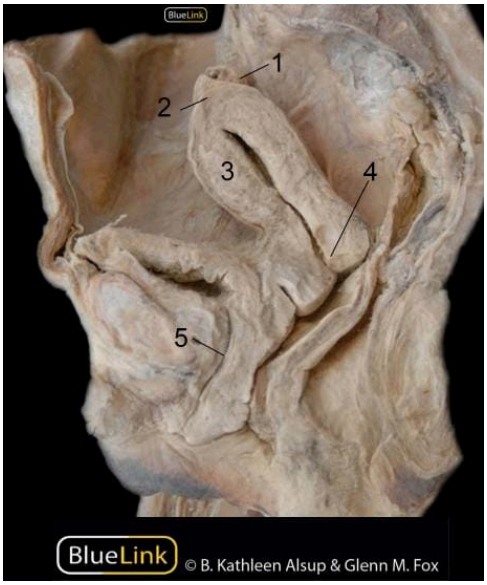

Image Credit

"*Pelvic Cavity*" by John Polos. All cadaver images from the University of Michigan and are made available by the regents under CC 4.0.

Answer Key (click to show/hide answers)

1 - Ovary

2 - Fundus of uterus

3 - Myometrium of uterus

4 - Cervix

5 - Urethra

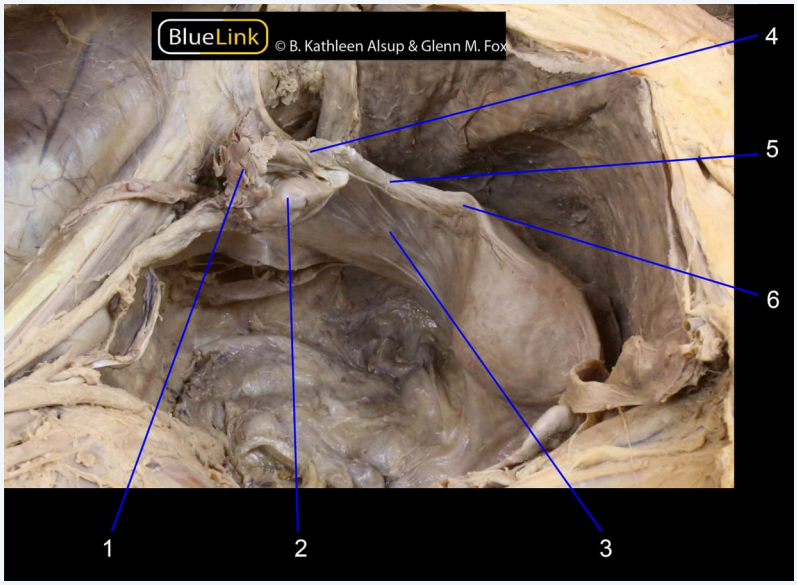

Image Credit

"*Pelvic Cavity*" by John Polos. All cadaver images from the University of Michigan and are made available by the regents under CC 4.0.

Answer Key (click to show/hide answers)

1 - Fimbriae

2 - Ovary

3 - Broad ligament of uterus

4 - Infundibulum of uterine tube

5 - Ampulla of uterine tube

6 - Isthmus of uterine tube

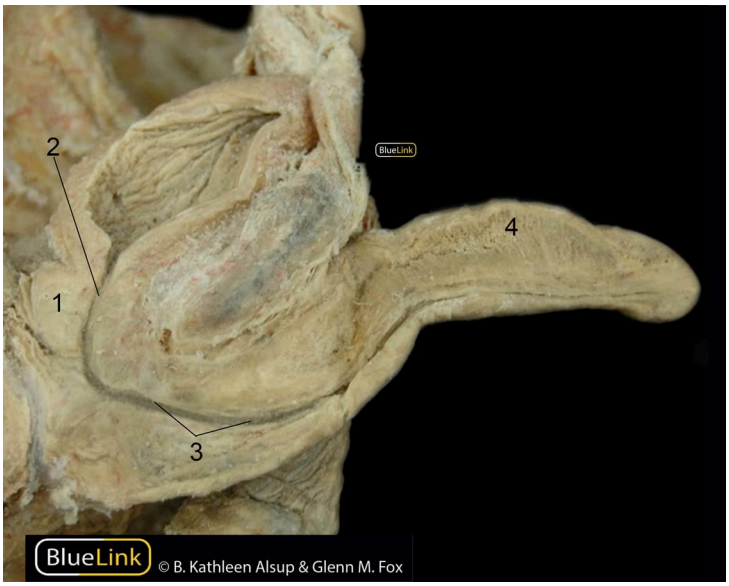

Image Credit

"*Male Pelvic Cavity*" by John Polos. All cadaver images from the University of Michigan and are made available by the regents under CC 4.0.

Answer Key (click to show/hide answers)

1 - Prostate gland

2 - Prostatic urethra

3 - Spongy urethra

4 - Corpus cavernosum

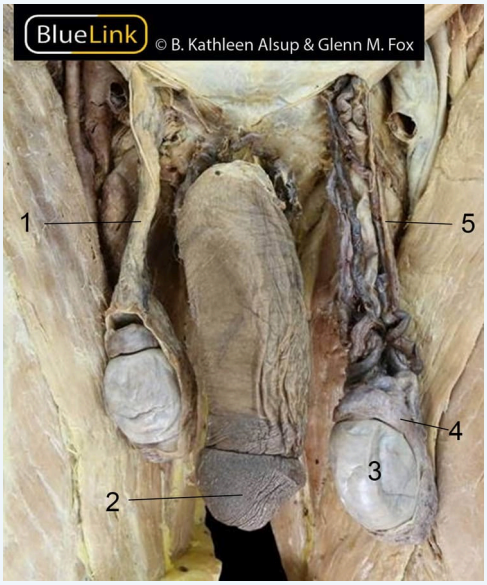

Image Credit

"*Spermatic Cord-atlas*" by John Polos. All cadaver images from the University of Michigan and are made available by the regents under CC 4.0.

Answer Key (click to show/hide answers)

1 - Spermatic Cord

2 - Glans penis

3 - Testis

4 - Epididymis

5 - Ductus (vas) deferens

Image Credit

"Corpus luteum" slide provided by the Regents of the University of Michigan Medical School under CC BY-NC-SA 4.0 © 2022, labeling by John Polos.

Answer Key (click to show/hide answers)

1 - Corpus luteum

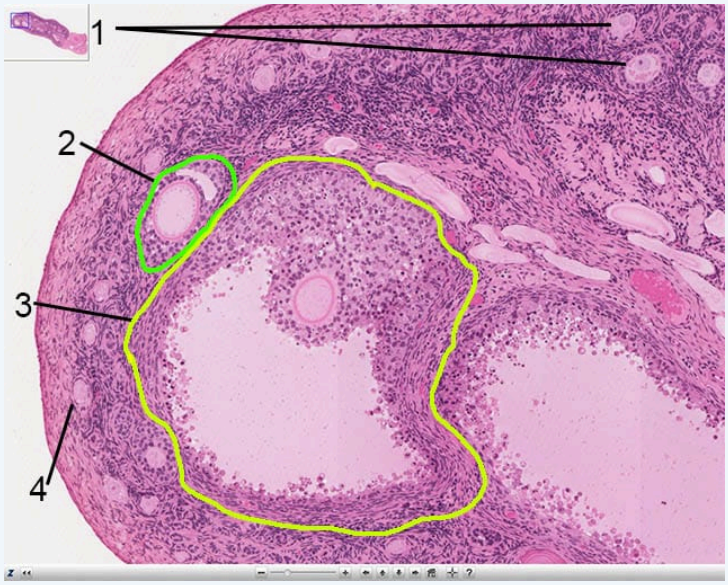

Image Credit

"Ovarian follicles - atlas" slide provided by the Regents of the University of Michigan Medical School under CC BY-NC-SA 4.0 © 2022, labeling by John Polos.

Answer Key (click to show/hide answers)

1 - Primary follicle

2 - Secondary follicle (very early)

3- Tertiary (Graafian) Follicle

4- Primordial follicle

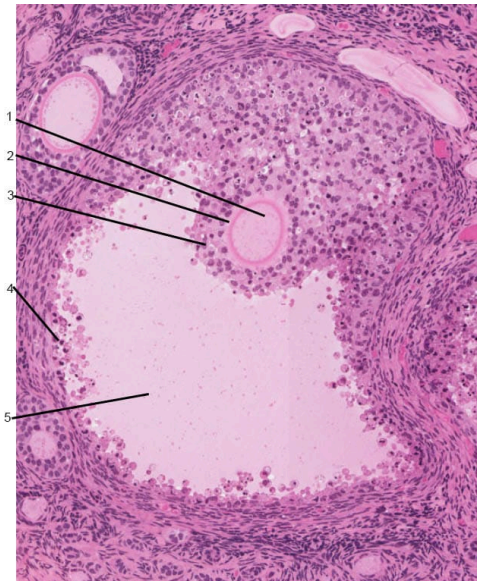

Image Credit

"Tertiary *follicle structures - atlas" slide provided by the Regents of the University of Michigan Medical School under CC BY-NC-SA 4.0 © 2022, labeling by John Polos.*

Answer Key (click to show/hide answers)

1- Oocyte

2- Corona radiata

3- Zona pellucida

4- Zona granulosa

5- Antrum

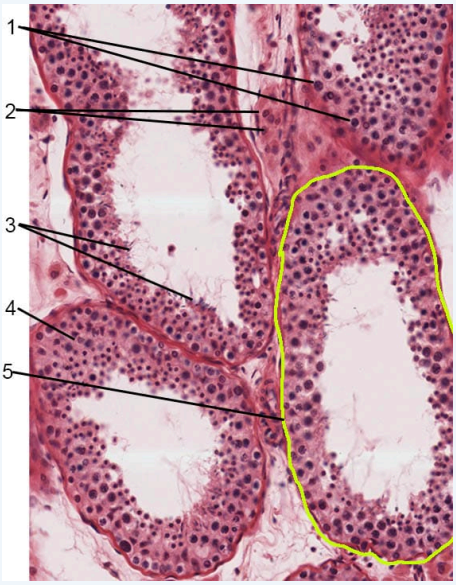

Image Credit

"Seminiferous tubule- atlas" *slide provided by the Regents of the University of Michigan Medical School under CC BY-NC-SA 4.0 © 2022, labeling by John Polos.*

Answer Key (click to show/hide answers)

1 - Spermatogonia

2 - Interstitial cells of Leydig

3- Spermatids

4 - Sertoli cell

5- Seminiferous tubule

This page titled 23.6: Anatomical Atlas - Reproductive Systems is shared under a CC BY-NC-SA 4.0 license and was authored, remixed, and/or curated by Jennifer Lange et al..

24: EMBRYOLOGY AND FETAL DEVELOPMENT

24.1: Overview of Embryology and Fetal Development

24.2: Fertilization

24.3: Embryonic Development

24.4: Fetal Development

24.5: Maternal Changes During Pregnancy, Labor, and Birth

24.6: Adjustments of the Infant at Birth and Postnatal Stages

24.7: Lactation

This page titled 24: Embryology and Fetal Development is shared under a CC BY-NC-SA 4.0 license and was authored, remixed, and/or curated by Jennifer Lange et al. via source content that was edited to the style and standards of the LibreTexts platform.

24.1: Overview of Embryology and Fetal Development

After the ovum or egg ripens and is released from the ovary, it is drawn into the fallopian tube and reaches the uterus in 3 to 4 days. When fertilized, the egg is typically fertilized in the fallopian tube and continues its journey to the uterus. At ejaculation, millions of sperm are released into the vagina, but only a few reach the egg, and typically, only one sperm fertilizes the one egg. Once a single sperm has entered the egg's wall, the wall becomes hard and prevents other sperm from entering. The tail of the sperm that is inside the egg breaks off, and the head of the sperm, containing the genetic information from the father, unites with the nucleus of the egg. As a result, a new cell is formed. This cell, including the combined genetic information from both parents, is called a zygote. A **zygote** is a new single-celled organism formed through fertilization.

The Stages of Prenatal Development

Prenatal development is divided into three stages: the germinal period, the embryonic period, and the fetal period. These stages vary in terms of length and developmental outcomes.

Germinal Stage

The pre-embryonic, or germinal, period, about **14 days in length**, is the shortest stage and lasts from conception to implantation of the blastocyst in the lining of the uterus. During this stage cell division with no significant growth produces a cluster of small cells that is the same size as the original zygote. This process is called **cleavage**. At least four initial cell divisions occur, resulting in a dense ball of at least sixteen cells called the **morula**. After the fourth doubling, differentiation of the cells also begins to occur.

About 60 percent of natural conceptions are estimated to fail to implant in the uterus (the rate is higher for in vitro conceptions). Factors contributing to implantation failure include genetic abnormalities, methylation patterns, low morphological quality, inadequate uterine lining, and missing the "window of implantation). Human embryos commonly acquire chromosomal abnormalities during mitosis that can result in DNA breakage, abnormal numbers of chromosomes in the resultant daughter cells, and errors in spindle binding.

Embryonic Stage

This period begins once the zygote is implanted in the uterine wall. It lasts from the **third through the eighth week** after conception. During this period, cells continue to differentiate and 22 days after conception the neural tube forms, beginning formation of the brain and spinal cord. Growth during prenatal development occurs in two primary directions: from head to tail (cephalocaudal development) and from the midline outward (proximodistal development). This means that those structures nearest the head develop before those nearest the feet, and those nearest the torso develop before those away from the center of the body (such as hands and fingers). The head develops in the fourth week, and the precursor to the heart begins to pulse. In the early stages of the embryonic period gills and a tail are apparent. But, by the end of this stage, these disappear and the organism takes on a more human appearance. The embryo is approximately 1 inch long and weighs about 4 grams at the end of this period. It can move and respond to touch at this time.

About 20 percent of embryos fail to develop during this stage due to gross chromosomal abnormalities. As in the case of the germinal period, often the mother does not yet know that she is pregnant. During this stage, the major structures of the body take form, making the embryonic period the time when the organism is most vulnerable to significant damage if exposed to harmful substances.

Fetal Stage

From the **ninth week until birth**, the organism is called a fetus. During this stage, the major structures are continuing to develop. By the twelfth week, the fetus has all its body parts, including external genitalia. In the following weeks, the fetus will build hair, nails, and teeth and the excretory and digestive systems will continue to develop. At the end of the twelfth week, the fetus is about 3 inches long and weighs about 28 grams.

During the fourth to sixth months the eyes become more sensitive to light and hearing develops. The respiratory system continues to grow. Reflexes such as sucking, swallowing, and hiccupping develop during the fifth month. Cycles of sleep and wakefulness are present at that time as well. The first chance of survival outside the womb, known as the age of viability, is reached at about 22 to 26 weeks. Most neurons in the brain have developed by 24 weeks, although they are still rudimentary, and the glial cells that support neurons continue to grow. At 24 weeks, the fetus can feel pain.

The fetus primarily prepares for birth between the seventh and ninth months. It is exercising its muscles; its lungs begin to expand and contract. It develops fat layers under the skin. The fetus gains about 5 pounds and 7 inches during this last trimester of pregnancy, including a layer of fat accumulated during the eighth month. This layer of fat serves as insulation and helps the baby regulate body temperature after birth.

YouTube Video

This interactive element is not available in this format. Visit the link or scan the QR code to access it online.

View this YouTube Video online

(unable to fetch text document from uri [status: 404 (NotFound)])

This page titled 24.1: Overview of Embryology and Fetal Development is shared under a CC BY-NC-SA 4.0 license and was authored, remixed, and/or curated by Jennifer Lange et al..

24.2: Fertilization

Learning Objectives

- Describe the obstacles that sperm must overcome to reach an oocyte
- Explain capacitation and its importance in fertilization
- Summarize the events that occur as a sperm fertilizes an oocyte

Fertilization occurs when a sperm and an oocyte (egg) combine and their nuclei fuse. Because each of these reproductive cells is a haploid cell containing half of the genetic material needed to form a human being, their combination forms a diploid cell. This new single cell, called a **zygote**, contains all of the genetic material needed to form a human—half from the mother and half from the father.

Transit of Sperm

Fertilization is a numbers game. During ejaculation, hundreds of millions of sperm (spermatozoa) are released into the vagina. Almost immediately, millions of these sperm are overcome by the acidity of the vagina (approximately pH 3.8), and millions more may be blocked from entering the uterus by thick cervical mucus. Of those that do enter, thousands are destroyed by phagocytic uterine leukocytes. Thus, the race into the uterine tubes, which is the most typical site for sperm to encounter the oocyte, is reduced to a few thousand contenders. Their journey—thought to be facilitated by uterine contractions—usually takes from 30 minutes to 2 hours. If the sperm do not encounter an oocyte immediately, they can survive in the uterine tubes for another 3–5 days. Thus, fertilization can still occur if intercourse takes place a few days before ovulation. In comparison, an oocyte can survive independently for only approximately 24 hours following ovulation. Intercourse more than a day after ovulation will therefore usually not result in fertilization.

During the journey, fluids in the female reproductive tract prepare the sperm for fertilization through a process called **capacitation**, or priming. The fluids improve the motility of the spermatozoa. They also deplete cholesterol molecules embedded in the membrane of the head of the sperm, thinning the membrane in such a way that will help facilitate the release of the lysosomal (digestive) enzymes needed for the sperm to penetrate the oocyte's exterior once contact is made. Sperm must undergo the process of capacitation in order to have the "capacity" to fertilize an oocyte. If they reach the oocyte before capacitation is complete, they will be unable to penetrate the oocyte's thick outer layer of cells.

Contact Between Sperm and Oocyte

Upon ovulation, the oocyte released by the ovary is swept into—and along—the uterine tube. Fertilization must occur in the distal uterine tube because an unfertilized oocyte cannot survive the 72-hour journey to the uterus. This secondary oocyte is surrounded by two protective layers. The **corona radiata** is an outer layer of follicular cells that form around a developing oocyte in the ovary and remain with it upon ovulation. The underlying **zona pellucida** (pellucid = "transparent") is a transparent, but thick, glycoprotein membrane that surrounds the cell's plasma membrane.

As it is swept along the distal uterine tube, the oocyte encounters the surviving capacitated sperm, which stream toward it in response to chemical attractants released by the cells of the corona radiata. To reach the oocyte itself, the sperm must penetrate the two protective layers. The sperm first burrow through the cells of the corona radiata. Then, upon contact, the sperm bind to receptors in the zona pellucida. This initiates a process called the **acrosomal reaction** in which the enzyme-filled "cap" of the sperm, called the **acrosome**, releases its stored digestive enzymes. These enzymes clear a path through the zona pellucida that allows sperm to reach the oocyte. Finally, a single sperm makes contact with sperm-binding receptors on the oocyte's plasma membrane (Figure 24.2.1). The plasma membrane of that sperm then fuses with the oocyte's plasma membrane, and the head and mid-piece of the "winning" sperm enter the oocyte interior.

How do sperm penetrate the corona radiata? Some sperm undergo a spontaneous acrosomal reaction, which is an acrosomal reaction not triggered by contact with the zona pellucida. The digestive enzymes released by this reaction digest the extracellular matrix of the corona radiata. As you can see, the first sperm to reach the oocyte is never the one to fertilize it. Rather, hundreds of sperm cells must undergo the acrosomal reaction, each helping to degrade the corona radiata and zona pellucida until a path

is created to allow one sperm to contact and fuse with the plasma membrane of the oocyte. If you consider the loss of millions of sperm between entry into the vagina and degradation of the zona pellucida, you can understand why a low sperm count can cause male infertility.

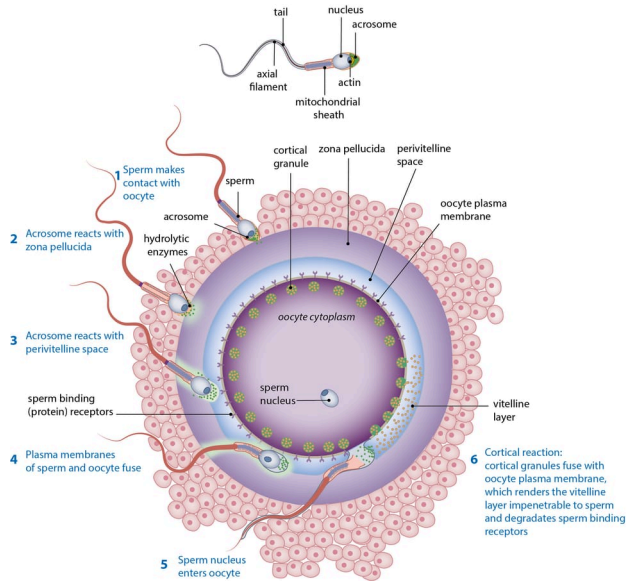

Figure 24.2.1: Sperm and the Process of Fertilization. Before fertilization, hundreds of capacitated sperm must break through the surrounding corona radiata and zona pellucida so that one can contact and fuse with the oocyte plasma membrane. *(Image credit: "Slagter - Drawing Stages of fertilisation of oocyte - English labels" by Ron Slagter, Cindy J.M. Hulsman, MUMC+, Jill P.J.M. Hikspoors, MUMC+ et al, license: CC BY-NC-SA.)*

When the first sperm fuses with the oocyte, the oocyte deploys two mechanisms to prevent **polyspermy**, which is penetration by more than one sperm. This is critical because if more than one sperm were to fertilize the oocyte, the resulting zygote would be a triploid organism with three sets of chromosomes. This is incompatible with life.

The first mechanism is the fast block, which involves a near instantaneous change in sodium ion permeability upon binding of the first sperm, depolarizing the oocyte plasma membrane and preventing the fusion of additional sperm cells. The fast block sets in almost immediately and lasts for about a minute, during which time an influx of calcium ions following sperm penetration triggers the second mechanism, the slow block. In this process, referred to as the **cortical reaction**, cortical granules sitting immediately below the oocyte plasma membrane fuse with the membrane and release zonal inhibiting proteins and mucopolysaccharides into the space between the plasma membrane and the zona pellucida. Zonal inhibiting proteins cause the release of any other attached sperm and destroy the oocyte's sperm receptors, thus preventing any more sperm from binding. The mucopolysaccharides then coat the nascent zygote in an impenetrable barrier that, together with hardened zona pellucida, is called a **fertilization membrane**.

The Zygote

Recall that at the point of fertilization, the oocyte has not yet completed meiosis: all secondary oocytes remain arrested in metaphase of meiosis II until fertilization. Only upon fertilization does the oocyte complete meiosis. The unneeded complement of genetic material that results is stored in a second polar body that is eventually ejected. At this moment, the oocyte has become an ovum, the female haploid gamete. The two haploid nuclei derived from the sperm and oocyte and contained within the egg are referred to as pronuclei. They decondense, expand, and replicate their DNA in preparation for mitosis. The pronuclei then migrate toward each other, their nuclear envelopes disintegrate, and the male- and female-derived genetic material intermingles. This step completes the process of fertilization and results in a single-celled diploid zygote with all the genetic instructions it needs to develop into a human.

Figure 24.2.2: Zygote. In this cell both the male and female pronuclei can be seen as spheres within the oocyte. The two polar bodies are still present on the outside. *(Image credit: "Zygote 1" by Nina Sesina is licensed under CC BY-SA 4.0, via Wikimedia Commons.)*

Most of the time, a woman releases a single egg during an ovulation cycle. However, in approximately 1 percent of ovulation cycles, two eggs are released and both are fertilized. Two zygotes form, implant, and develop, resulting in the birth of dizygotic (or fraternal) twins. Because dizygotic twins develop from two eggs fertilized by two sperm, they are no more identical than siblings born at different times.

Much less commonly, a zygote can divide into two separate offspring during early development. This results in the birth of monozygotic (or identical) twins. Although the zygote can split as early as the two-cell stage, splitting occurs most commonly during the early blastocyst stage, with roughly 70–100 cells present. These two scenarios are distinct from each other, in that the twin embryos that separated at the two-cell stage will have individual placentas, whereas twin embryos that form from separation at the blastocyst stage will share a placenta and a chorionic cavity.

EVERYDAY CONNECTIONS

In Vitro Fertilization

IVF, which stands for in vitro fertilization, is an assisted reproductive technology. In vitro, which in Latin translates to “in glass,” refers to a procedure that takes place outside of the body. There are many different indications for IVF. For example, a woman may produce normal eggs, but the eggs cannot reach the uterus because the uterine tubes are blocked or otherwise compromised. A man may have a low sperm count, low sperm motility, sperm with an unusually high percentage of morphological abnormalities, or sperm that are incapable of penetrating the zona pellucida of an egg.

A typical IVF procedure begins with egg collection. A normal ovulation cycle produces only one oocyte, but the number can be boosted significantly (to 10–20 oocytes) by administering a short course of gonadotropins. The course begins with follicle-stimulating hormone (FSH) analogs, which support the development of multiple follicles, and ends with a luteinizing hormone (LH) analog that triggers ovulation. Right before the ova would be released from the ovary, they are harvested using ultrasound-guided oocyte retrieval. In this procedure, ultrasound allows a physician to visualize mature follicles. The ova are aspirated (sucked out) using a syringe.

In parallel, sperm are obtained from the male partner or from a sperm bank. The sperm are prepared by washing to remove seminal fluid because seminal fluid contains a peptide, FPP (or, fertilization promoting peptide), that—in high concentrations—prevents capacitation of the sperm. The sperm sample is also concentrated, to increase the sperm count per milliliter.

Next, the eggs and sperm are mixed in a petri dish. The ideal ratio is 75,000 sperm to one egg. If there are severe problems with the sperm—for example, the count is exceedingly low, or the sperm are completely nonmotile, or incapable of binding to or penetrating the zona pellucida—a sperm can be injected into an egg (Figure 24.2.3). This is called intracytoplasmic sperm injection (ICSI).

Figure 24.2.3: Intracytoplasmic Sperm Injection. The zona pellucida is penetrated by a a fine needle so the sperm can be injected directly into the oocyte. *(Image credit: "Ooctye with Zona Pellucida" by ZEISS Microscopy is licensed under CC BY-SA 2.0.)*

The embryos are then incubated until they either reach the eight-cell stage or the blastocyst stage. In the United States, fertilized eggs are typically cultured to the blastocyst stage because this results in a higher pregnancy rate. Finally, the embryos are transferred to a woman's uterus using a plastic catheter (tube). (Figure 24.2.4) illustrates the steps involved in IVF.

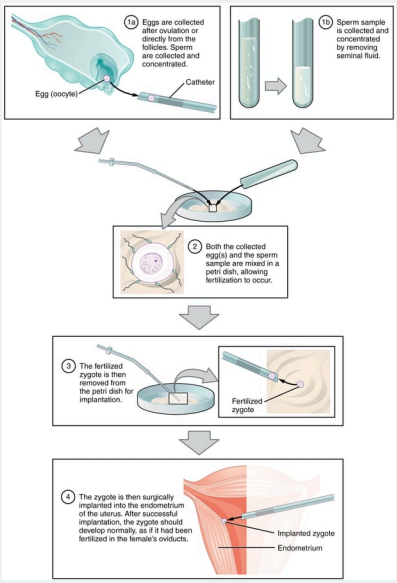

Figure 24.2.4: IVF. In vitro fertilization involves egg collection from the ovaries, fertilization in a petri dish, and the transfer of embryos into the uterus. *(Image credit: "Steps in IVF" by OpenStax College is licensed under CC BY 3.0, via Wikimedia Commons.)*

IVF is a relatively new and still evolving technology, and until recently it was necessary to transfer multiple embryos to achieve a good chance of a pregnancy. Today, however, transferred embryos are much more likely to implant successfully, so countries that regulate the IVF industry cap the number of embryos that can be transferred per cycle at two. This reduces the risk of multiple-birth pregnancies.

The rate of success for IVF is correlated with a woman's age. More than 40 percent of women under 35 succeed in giving birth following IVF, but the rate drops to a little over 10 percent in women over 40.

Chapter Review

Hundreds of millions of sperm deposited in the vagina travel toward the oocyte, but only a few hundred actually reach it. The number of sperm that reach the oocyte is greatly reduced because of conditions within the female reproductive tract. Many sperm are overcome by the acidity of the vagina, others are blocked by mucus in the cervix, whereas others are attacked by phagocytic leukocytes in the uterus. Those sperm that do survive undergo a change in response to those conditions. They go through the process of capacitation, which improves their motility and alters the membrane surrounding the acrosome, the cap-like structure in the head of a sperm that contains the digestive enzymes needed for it to attach to and penetrate the oocyte.

The oocyte that is released by ovulation is protected by a thick outer layer of granulosa cells known as the corona radiata and by the zona pellucida, a thick glycoprotein membrane that lies just outside the oocyte's plasma membrane. When capacitated sperm make contact with the oocyte, they release the digestive enzymes in the acrosome (the acrosomal reaction) and are thus able to attach to the oocyte and burrow through to the oocyte's zona pellucida. One of the sperm will then break through to the oocyte's plasma membrane and release its haploid nucleus into the oocyte. The oocyte's membrane structure changes in response (cortical reaction), preventing any further penetration by another sperm and forming a fertilization membrane. Fertilization is complete upon unification of the haploid nuclei of the two gametes, producing a diploid zygote.

Review Questions

Query 24.2.1

This interactive element is not available in this format. Visit the link or scan the QR code to access it online.

View this Interactive Content online

Critical Thinking Questions

Query 24.2.2

This interactive element is not available in this format. Visit the link or scan the QR code to access it online.

View this Interactive Content online

Query 24.2.3

This interactive element is not available in this format. Visit the link or scan the QR code to access it online.

View this Interactive Content online

Glossary

Query 24.2.4

This interactive element is not available in this format. Visit the link or scan the QR code to access it online.

View this Interactive Content online

This page titled 24.2: Fertilization is shared under a CC BY-NC-SA 4.0 license and was authored, remixed, and/or curated by Jennifer Lange et al. via source content that was edited to the style and standards of the LibreTexts platform.

- 16.3: Erythrocytes by Whitney Menefee, Julie Jenks, Chiara Mazzasette, and Kim-Leiloni Nguyen is licensed CC BY 4.0.

24.3: Embryonic Development

Learning Objectives

- Distinguish the stages of embryonic development that occur before implantation
- List and describe four embryonic membranes
- Explain gastrulation
- Describe the structure of the placenta and correlate them to its functions
- Describe the structural changes occurring as an embryo transforms from a flat disc of cells into a three-dimensional shape resembling a human
- Summarize the major events of organogenesis

Throughout this chapter, we will express embryonic and fetal ages in terms of weeks from fertilization, commonly called conception. The period of time required for full development of a fetus in utero is referred to as **gestation** (gestare = "to carry" or "to bear"). It can be subdivided into distinct gestational periods. The first 2 weeks of prenatal development are referred to as the pre-embryonic stage. A developing human is referred to as an **embryo** during weeks 3–8, and a **fetus** from the ninth week of gestation until birth. In this section, we'll cover the pre-embryonic and embryonic stages of development, which are characterized by cell division, migration, and differentiation. By the end of the embryonic period, all of the organ systems are structured in rudimentary form, although the organs themselves are either nonfunctional or only semi-functional.

Pre-implantation Embryonic Development

Following fertilization, the zygote and its associated membranes, together referred to as the **conceptus**, continue to be projected toward the uterus by peristalsis and beating cilia. During its journey to the uterus, the zygote undergoes five or six rapid mitotic cell divisions. Although each **cleavage** results in more cells, it does not increase the total volume of the conceptus (Figure 24.3.1). Each daughter cell produced by cleavage is called a **blastomere** (blastos = "germ," in the sense of a seed or sprout).

Approximately 3 days after fertilization, a 16-cell conceptus reaches the uterus. The cells that had been loosely grouped are now compacted and look more like a solid mass. The name given to this structure is the **morula** (morula = "little mulberry"). Once inside the uterus, the conceptus floats freely for several more days. It continues to divide, creating a ball of approximately 100 cells, and consuming nutritive endometrial secretions called uterine milk while the uterine lining thickens. The ball of now tightly bound cells starts to secrete fluid and organize themselves around a fluid-filled cavity, the **blastocoel**. At this developmental stage, the conceptus is referred to as a **blastocyst**. Within this structure, a group of cells forms into an **inner cell mass**, which is fated to become the embryo. The cells that form the outer shell are called **trophoblasts** (trophe = "to feed" or "to nourish"). These cells will develop into the chorionic sac and the fetal portion of the **placenta** (the organ of nutrient, waste, and gas exchange between mother and the developing offspring).

The inner mass of embryonic cells is totipotent during this stage, meaning that each cell has the potential to differentiate into any cell type in the human body. Totipotency lasts for only a few days before the cells' fates are set as being the precursors to a specific lineage of cells.

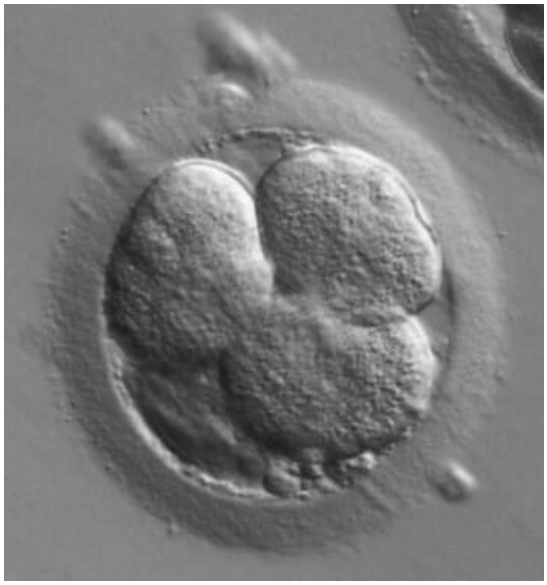

Figure 24.3.1A: **Four-Cell Stage**. *(Image credit: "Early Human Embryos" by ZEISS Microscopy is licensed under CC BY-SA 2.0.)*

Figure 24.3.1B: **Eight-Cell Stage**. *(Image credit: "Embryo 8-cells" by Ekem at English Wikipedia is in the Public domain, via Wikimedia Commons.)*

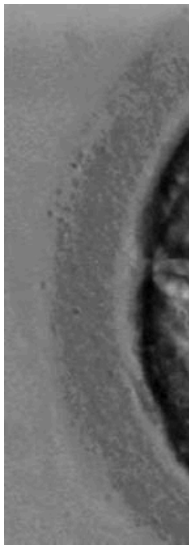

Figure 24.3.1C: **Bl**
English Wikiped

As the blastocyst forms, the trophoblast excretes enzymes that begin to degrade the zona pellucida. In a process called "hatching," the conceptus breaks free of the zona pellucida in preparation for implantation.

YouTube Video

This interactive element is not available in this format. Visit the link or scan the QR code to access it online.

View this YouTube Video online

Implantation

At the end of the first week, the blastocyst comes in contact with the uterine wall and adheres to it, embedding itself in the uterine lining via the trophoblast cells. Thus begins the process of **implantation**, which signals the end of the pre-embryonic stage of development (Figure 24.3.2). Implantation can be accompanied by minor bleeding. The blastocyst typically implants in the fundus of the uterus or on the posterior wall. However, if the endometrium is not fully developed and ready to receive the blastocyst, the blastocyst will detach and find a better spot. A significant percentage (50–75 percent) of blastocysts fail to implant; when this occurs, the blastocyst is shed with the endometrium during menses. The high rate of implantation failure is one reason why pregnancy typically requires several ovulation cycles to achieve.

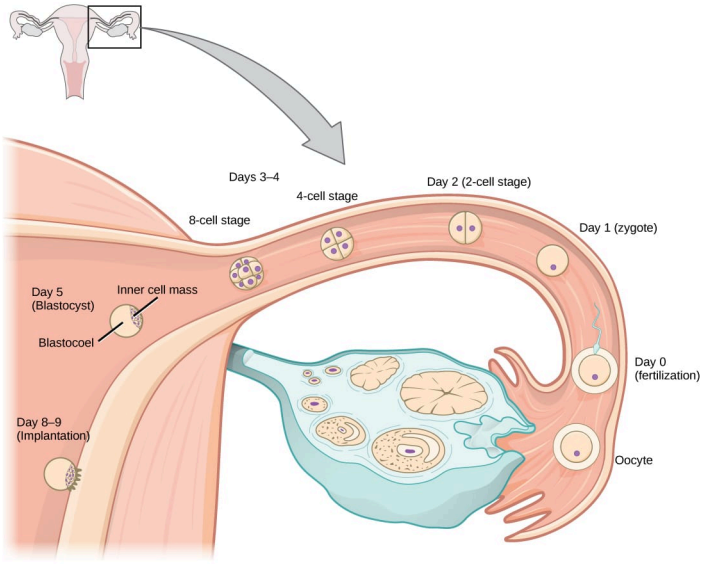

Figure 24.3.2: Pre-Embryonic Development. Ovulation, fertilization, pre-embryonic development, and implantation occur at specific locations within the female reproductive system in a time span of approximately 1 week. *(Image credit: "Figure 43 07 01" by CNX OpenStax is licensed under CC BY 4.0, via Wikimedia Commons.)*

When implantation succeeds and the blastocyst adheres to the endometrium, the superficial cells of the trophoblast fuse with each other, forming the **syncytiotrophoblast**, a multinucleated body that digests endometrial cells to firmly secure the blastocyst to the uterine wall. In response, the uterine mucosa rebuilds itself and envelops the blastocyst (Figure 24.3.3). The trophoblast secretes **human chorionic gonadotropin (hCG)**, a hormone that directs the corpus luteum to survive, enlarge, and continue producing progesterone and estrogen to suppress menses. These functions of hCG are necessary for creating an environment suitable for the developing embryo. As a result of this increased production, hCG accumulates in the maternal bloodstream and is excreted in the urine. Implantation is complete by the middle of the second week. Just a few days after implantation, the trophoblast has secreted enough hCG for an at-home urine pregnancy test to give a positive result.

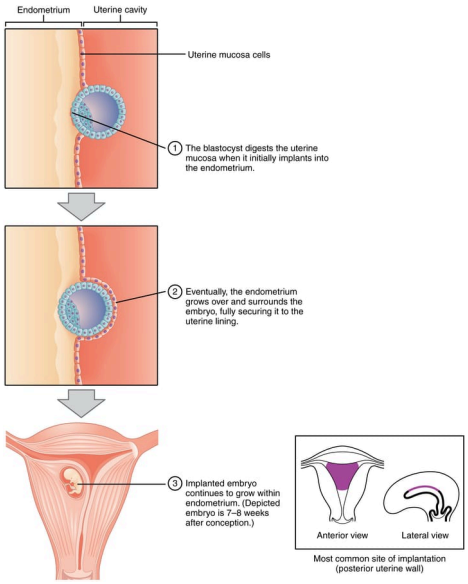

Figure 24.3.3: Implantation. During implantation, the trophoblast cells of the blastocyst adhere to the endometrium and digest endometrial cells until it is attached securely. *(Image credit: "Implantation" by OpenStax College is licensed under CC BY 3.0, via Wikimedia Commons.)*

Most of the time an embryo implants within the body of the uterus in a location that can support growth and development. However, in one to two percent of cases, the embryo implants either outside the uterus (an **ectopic pregnancy**) or in a region of uterus that can create complications for the pregnancy. If the embryo implants in the inferior portion of the uterus, the placenta can potentially grow over the opening of the cervix, a condition call **placenta previa**.

DISORDERS OF THE... Development of the Embryo

In the vast majority of ectopic pregnancies, the embryo does not complete its journey to the uterus and implants in the uterine tube, referred to as a tubal pregnancy. However, there are also ovarian ectopic pregnancies (in which the egg never left the ovary) and abdominal ectopic pregnancies (in which an egg was "lost" to the abdominal cavity during the transfer from ovary to uterine tube, or in which an embryo from a tubal pregnancy re-implanted in the abdomen). Once in the abdominal cavity, an embryo can implant into any well-vascularized structure—the rectouterine cavity (Douglas' pouch), the mesentery of the intestines, and the greater omentum are some common sites.

Tubal pregnancies can be caused by scar tissue within the tube following a sexually transmitted bacterial infection. The scar tissue impedes the progress of the embryo into the uterus—in some cases "snagging" the embryo and, in other cases, blocking the tube completely. Approximately one half of tubal pregnancies resolve spontaneously. Implantation in a uterine tube causes bleeding, which appears to stimulate smooth muscle contractions and expulsion of the embryo. In the remaining cases, medical or surgical intervention is necessary. If an ectopic pregnancy is detected early, the embryo's development can be arrested by the administration of the cytotoxic drug methotrexate, which inhibits the metabolism of folic acid. If diagnosis is late and the uterine tube is already ruptured, surgical repair is essential.

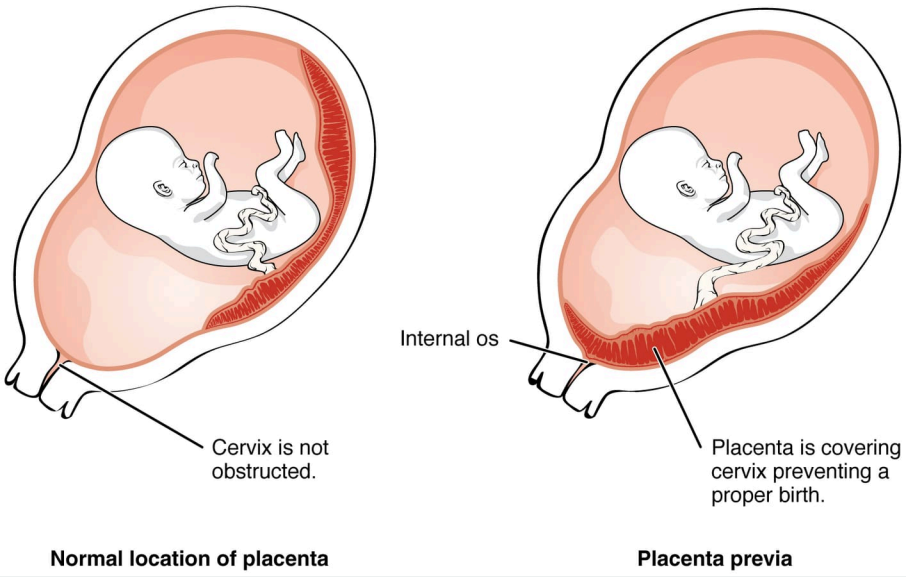

Figure 24.3.4: Placenta Previa. An embryo that implants too close to the opening of the cervix can lead to placenta previa, a condition in which the placenta partially or completely covers the cervix. *(Image credit: "Placenta Previa" by OpenStax College is licensed under CC BY 3.0, via Wikimedia Commons.)*

Even if the embryo has successfully found its way to the uterus, it does not always implant in an optimal location (the fundus or the posterior wall of the uterus). Placenta previa can result if an embryo implants close to the internal os of the uterus (the internal opening of the cervix). As the fetus grows, the placenta can partially or completely cover the opening of the cervix (Figure 24.3.4). Although it occurs in only 0.5 percent of pregnancies, placenta previa is the leading cause of antepartum hemorrhage (profuse vaginal bleeding after week 24 of pregnancy but prior to childbirth).

Embryonic Membranes

During the second week of development, with the embryo implanted in the uterus, cells within the blastocyst start to organize into layers. Some grow to form the extra-embryonic membranes needed to support and protect the growing embryo: the amnion, the yolk sac, the allantois, and the chorion.

At the beginning of the second week, the cells of the inner cell mass form into a two-layered disc of embryonic cells, and a space—the **amniotic cavity**—opens up between it and the trophoblast (Figure 24.3.5). Cells from the upper layer of the disc (the **epiblast**) extend around the amniotic cavity, creating a membranous sac that forms into the **amnion** by the end of the second week. The amnion fills with amniotic fluid and eventually grows to surround the embryo. Early in development, amniotic fluid

consists almost entirely of a filtrate of maternal plasma, but as the kidneys of the fetus begin to function at approximately the eighth week, they add urine to the volume of amniotic fluid. Floating within the amniotic fluid, the embryo—and later, the fetus—is protected from trauma and rapid temperature changes. It can move freely within the fluid and can prepare for swallowing and breathing out of the uterus.

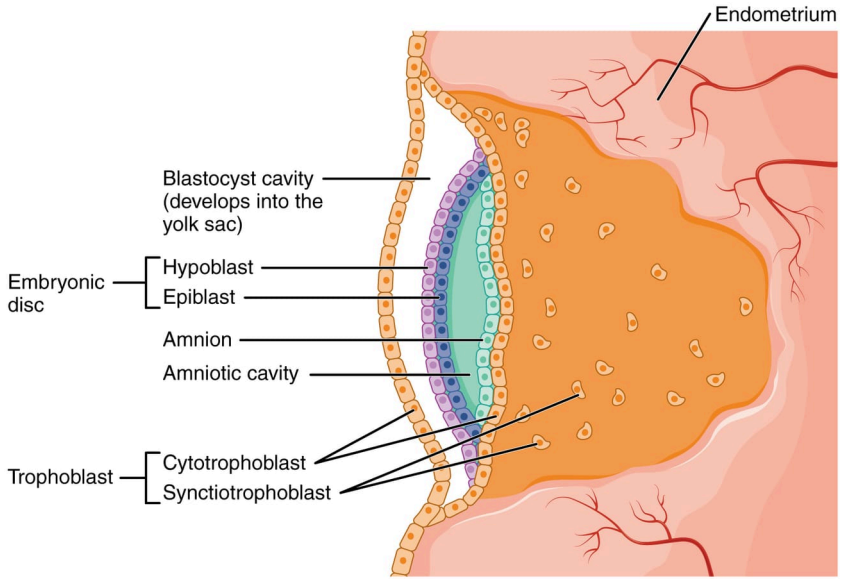

Figure 24.3.5: Development of the Embryonic Disc. Formation of the embryonic disc leaves spaces on either side that develop into the amniotic cavity and the yolk sac. *(Image credit: "Embryonic Disc, Amniotic Cavity, Yolk Sac" by OpenStax College is licensed under CC BY 3.0, via Wikimedia Commons.)*

On the ventral side of the embryonic disc, opposite the amnion, cells in the lower layer of the embryonic disk (the **hypoblast**) extend into the blastocyst cavity and form a **yolk sac**. The yolk sac supplies some nutrients absorbed from the trophoblast and also provides primitive blood circulation to the developing embryo for the second and third week of development. When the placenta takes over nourishing the embryo at approximately week 4, the yolk sac has been greatly reduced in size and its main function is to serve as the source of blood cells and germ cells (cells that will give rise to gametes). During week 3, a finger-like outpocketing of the yolk sac develops into the **allantois**, a primitive excretory duct of the embryo that will become part of the urinary bladder. Together, the stalks of the yolk sac and allantois establish the outer structure of the umbilical cord.

The last of the extra-embryonic membranes is the **chorion**, which is the one membrane that surrounds all others. The development of the chorion will be discussed in more detail shortly, as it relates to the growth and development of the placenta.

Embryogenesis

As the third week of development begins, the two-layered disc of cells becomes a three-layered disc through the process of **gastrulation**, during which the cells transition from totipotency to multipotency. The embryo, which takes the shape of an oval-shaped disc, forms an indentation called the **primitive streak** along the dorsal surface of the epiblast. A node at the caudal or “tail” end of the primitive streak emits growth factors that direct cells to multiply and migrate. Cells migrate toward and through the primitive streak and then move laterally to create two new layers of cells. The first layer is the **endoderm**, a sheet of cells that displaces the hypoblast and lies adjacent to the yolk sac. The second layer of cells fills in as the middle layer, or **mesoderm**. The cells of the epiblast that remain (not having migrated through the primitive streak) become the **ectoderm** (Figure 24.3.6).

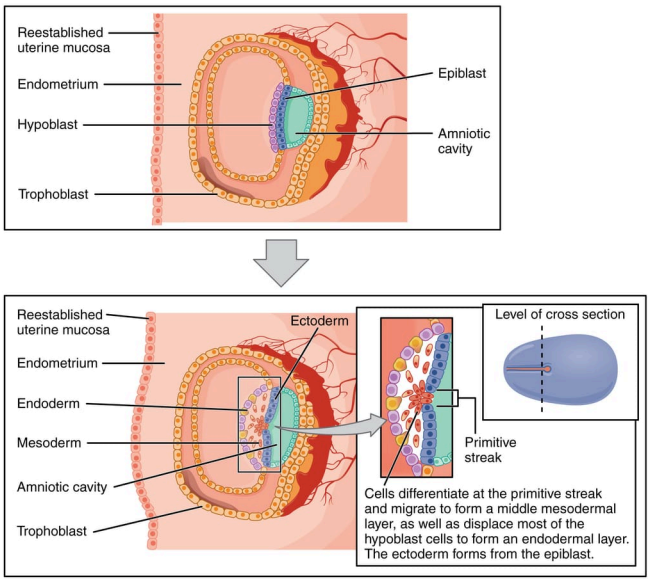

Figure 24.3.6: Germ Layers. Formation of the three primary germ layers occurs during the 3rd week of development. The embryo at this stage is only a few millimeters in length. *(Image credit: "Germ Layers" by OpenStax College is licensed under CC BY 3.0, via Wikimedia Commons.)*

Each of these germ layers will develop into specific structures in the embryo. Whereas the ectoderm and endoderm form tightly connected epithelial sheets, the mesodermal cells are less organized and exist as a loosely connected cell community. The ectoderm gives rise to cell lineages that differentiate to become the central and peripheral nervous systems, sensory organs, epidermis, hair, and nails. Mesodermal cells ultimately become the skeleton, muscles, connective tissue, heart, blood vessels, and kidneys. The endoderm goes on to form the epithelial lining of the gastrointestinal tract, liver, and pancreas, as well as the lungs (Figure 24.3.7).

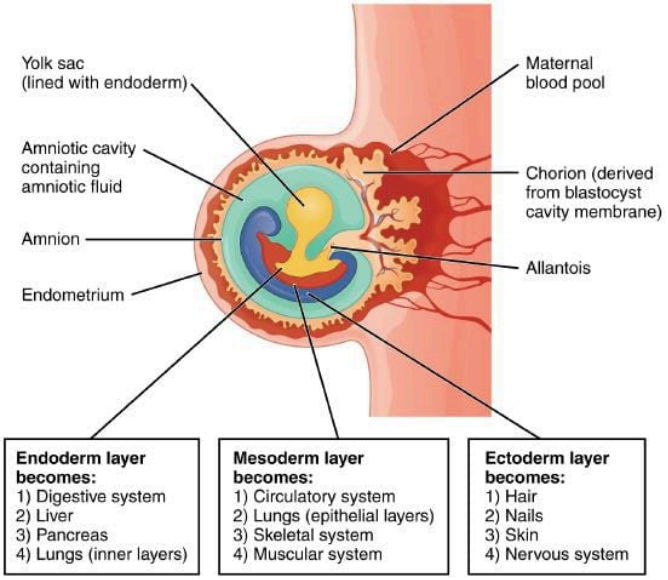

Figure 24.3.7: Fates of Germ Layers in Embryo. Following gastrulation of the embryo in the third week, embryonic cells of the ectoderm, mesoderm, and endoderm begin to migrate and differentiate into the cell lineages that will give rise to mature organs and organ systems in the infant. *(Image credit: "Fate of the Germ Layers" by Rice University is licensed under CC BY 4.0, via Wikimedia Commons.)*

Development of the Placenta

During the first several weeks of development, the cells of the endometrium—referred to as decidual cells—nourish the nascent embryo. During prenatal weeks 4–12, the developing placenta gradually takes over the role of feeding the embryo, and the decidual cells are no longer needed. The mature placenta is composed of tissues derived from the embryo, as well as maternal tissues of

the endometrium. The placenta connects to the conceptus via the **umbilical cord**, which carries deoxygenated blood and wastes from the fetus through two umbilical arteries; nutrients and oxygen are carried from the mother to the fetus through the single umbilical vein. The umbilical cord is surrounded by the amnion, and the spaces within the cord around the blood vessels are filled with Wharton's jelly, a mucous connective tissue.

The maternal portion of the placenta develops from the deepest layer of the endometrium, the decidua basalis. To form the embryonic portion of the placenta, the syncytiotrophoblast and the underlying cells of the trophoblast (cytotrophoblast cells) begin to proliferate along with a layer of extraembryonic mesoderm cells. These form the **chorionic membrane**, which envelops the entire conceptus as the chorion. The chorionic membrane forms finger-like structures called **chorionic villi** that burrow into the endometrium like tree roots, making up the fetal portion of the placenta. The cytotrophoblast cells perforate the chorionic villi, burrow farther into the endometrium, and remodel maternal blood vessels to augment maternal blood flow surrounding the villi. Meanwhile, fetal mesenchymal cells derived from the mesoderm fill the villi and differentiate into blood vessels, including the three umbilical blood vessels that connect the embryo to the developing placenta (Figure 24.3.8).

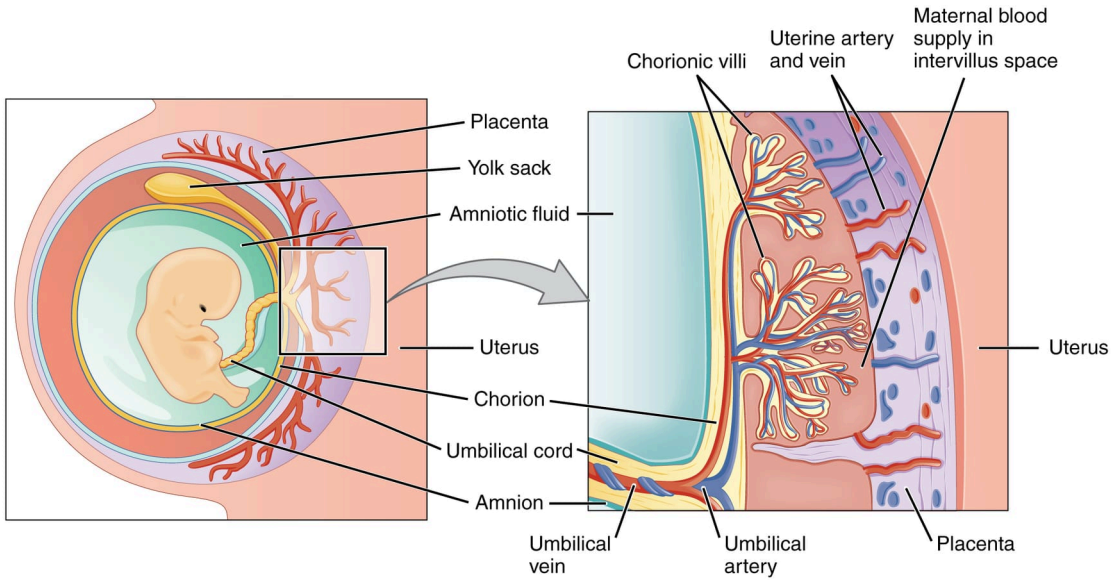

Figure 24.3.8: Cross-Section of the Placenta. In the placenta, maternal and fetal blood components are conducted through the surface of the chorionic villi, but maternal and fetal bloodstreams never mix directly. *(Image credit: "The Placenta" by OpenStax College is licensed under CC BY 3.0, via Wikimedia Commons.)*

The placenta develops throughout the embryonic period and during the first several weeks of the fetal period; **placentation** is complete by weeks 14–16. As a fully developed organ, the placenta provides nutrition and excretion, respiration, and endocrine function (Figure 24.3.9). It receives blood from the fetus through the umbilical arteries. Capillaries in the chorionic villi filter fetal wastes out of the blood and return clean, oxygenated blood to the fetus through the umbilical vein. Nutrients and oxygen are transferred from maternal blood surrounding the villi through the capillaries and into the fetal bloodstream. Some substances move across the placenta by simple diffusion. Oxygen, carbon dioxide, and any other lipid-soluble substances take this route. Other substances move across by facilitated diffusion. This includes water-soluble glucose. The fetus has a high demand for amino acids and iron, and those substances are moved across the placenta by active transport.

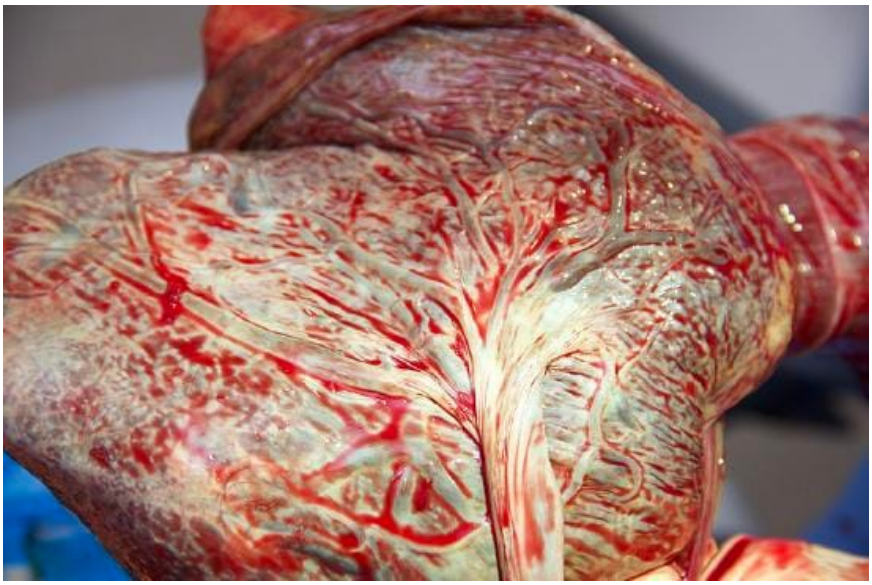

Figure 24.3.9: Fetal Side of a Freshly Delivered Placenta. The placenta is a temporary organ that should detach from the uterine wall and pass out after the baby has been born. This image shows the umbilical cord and the network of blood vessels entering it. *(Image credit: "Fetal side close up of freshly delivered placenta" by AxsDeny is licensed under CC BY-SA 4.0.)*

Maternal and fetal blood does not commingle because blood cells cannot move across the placenta. This separation prevents the mother's cytotoxic T cells from reaching and subsequently destroying the fetus, which bears "non-self" antigens. Further, it ensures the fetal red blood cells do not enter the mother's circulation and trigger antibody development (if they carry "non-self" antigens)—at least until the final stages of pregnancy or birth. This is the reason that, even in the absence of preventive treatment, an Rh^- mother doesn't develop antibodies that could cause hemolytic disease in her first Rh^+ fetus.

Although blood cells are not exchanged, the chorionic villi provide ample surface area for the two-way exchange of substances between maternal and fetal blood. The rate of exchange increases throughout gestation as the villi become thinner and increasingly branched. The placenta is permeable to lipid-soluble fetotoxic substances: alcohol, nicotine, barbiturates, antibiotics, certain pathogens, and many other substances that can be dangerous or fatal to the developing embryo or fetus. For these reasons, pregnant women should avoid fetotoxic substances. Alcohol consumption by pregnant women, for example, can result in a range of abnormalities referred to as fetal alcohol spectrum disorders (FASD). These include organ and facial malformations, as well as cognitive and behavioral disorders.

Organogenesis

Following gastrulation, rudiments of the central nervous system develop from the ectoderm in the process of **neurulation** (Figure 24.3.10). Specialized neuroectodermal tissues along the length of the embryo thicken into the **neural plate**. During the fourth week, tissues on either side of the plate fold upward into a **neural fold**. A population of cells separates from the neural folds and migrates into the periphery. These **neural crest** cells will form the nerves and ganglia of the peripheral nervous system as well as the melanocytes. The two neural folds converge to form the **neural tube**, the ends of which close at the end of the 4th week. This tube lies atop a rod-shaped, mesoderm-derived **notochord**, which eventually becomes the nucleus pulposus of intervertebral discs. Block-like structures called **somites** form on either side of the tube, eventually differentiating into the axial skeleton, skeletal muscle, and dermis. During the fourth and fifth weeks, the anterior neural tube dilates and subdivides to form vesicles that will become the brain structures.

Folate, one of the B vitamins, is important to the healthy development of the neural tube. A deficiency of maternal folate in the first weeks of pregnancy can result in neural tube defects, including spina bifida—a birth defect in which spinal tissue protrudes through the newborn's vertebral column, which has failed to completely close. A more severe neural tube defect is anencephaly, a partial or complete absence of brain tissue.

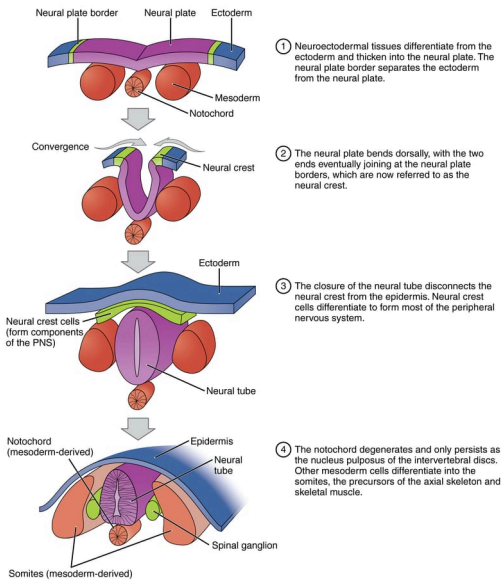

Figure 24.3.10: Neurulation. The embryonic process of neurulation establishes the rudiments of the future central nervous system and skeleton. *(Image credit: "Neurulation" by OpenStax College is licensed under CC BY 3.0, via Wikimedia Commons.)*

The embryo, which begins as a flat sheet of cells, begins to acquire a cylindrical shape through the process of **embryonic folding** (Figure 24.3.11). The embryo folds laterally and again at either end, forming a C-shape with distinct head and tail ends. The embryo envelops a portion of the yolk sac, which protrudes with the umbilical cord from what will become the abdomen. The folding essentially creates a tube, called the primitive gut, that is lined by the endoderm. The amniotic sac, which was sitting on top of the flat embryo, envelops the embryo as it folds.

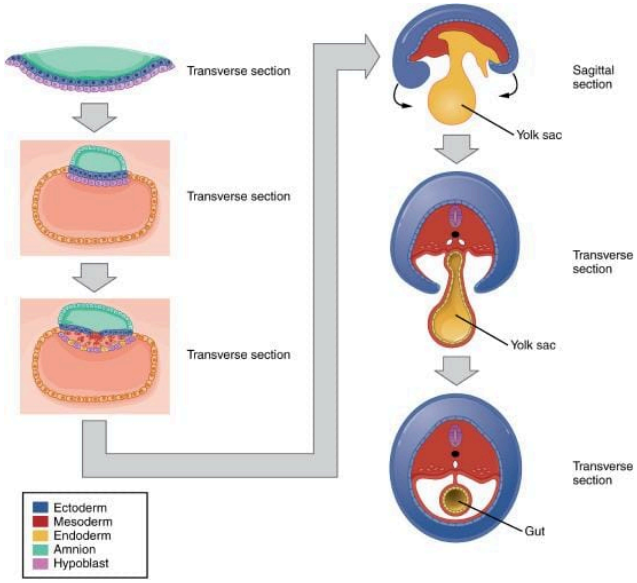

Figure 24.3.11: Embryonic Folding. Embryonic folding converts a flat sheet of cells into a hollow, tube-like structure. *(Image credit: "Embryonic Folding" by OpenStax College is licensed under CC BY 3.0, via Wikimedia Commons.)*

Within the first 8 weeks of gestation, a developing embryo establishes the rudimentary structures of all of its organs and tissues from the ectoderm, mesoderm, and endoderm. This process is called **organogenesis**.

Like the central nervous system, the heart also begins its development in the embryo as a tube-like structure, connected via capillaries to the chorionic villi. Cells of the primitive tube-shaped heart are capable of electrical conduction and contraction. The heart begins beating in the beginning of the fourth week, although it does not actually pump embryonic blood until a week later, when the oversized liver has begun producing red blood cells. (This is a temporary responsibility of the embryonic liver that the bone marrow will assume during fetal development.) During weeks 4–5, the eye pits form, limb buds become apparent, and the rudiments of the pulmonary system are formed (Figure 24.3.12).

Figure 24.3.12: Embryo at 5 Weeks. An embryo at the end of 5 weeks of development is only 10 mm in length, but its developing eyes, limb buds, and tail are already visible. *(Image credit: "Human Embryo 7th Week of Pregnancy" by Ed Uthman is licensed under CC BY 2.0.)*

During the sixth week,

- limb buds form into arms and legs and uncontrolled fetal limb movements begin to occur,
- the gastrointestinal system develops too rapidly for the embryonic abdomen to accommodate it, and the intestines temporarily loop into the umbilical cord,
- paddle-shaped hands and feet develop fingers and toes by the process of apoptosis (programmed cell death), which causes the tissues between the fingers to disintegrate,
- neurogenesis begins on day 42 and the longitudinal fissure begins to form,
- optic vesicles begin to develop on the lateral head as do the tubes that will form the ear.

By week 7, the facial structure is more complex and includes nostrils, outer ears, and lenses (Figure 24.3.13).

6 weeks

6-7 weeks

7-8 weeks

Figure 24.3.13: Embryos at 6-8 weeks from conception. During the last two weeks of the embryonic period all of the rudimentary organs will develop. Externally the limbs form with finger and toe rays and facial features become evident. Internally the cerebral hemispheres begin to take shape and the beating heart has four chambers, outflow vessels, valve flaps, and an SA node. *(Image credits: "Embryo @ 6-7 weeks", "Human Embryo: 6-7 weeks","Embryo at 7-8 weeks from conception" by lunar caustic are licensed under CC BY 2.0.)*

By the end of the eighth week (Figure 24.3.13), at the end of the embryonic period:

- the head is nearly as large as the rest of the embryo's body,
- the rudimentary structures of the brain and central nervous system are established and the major compartments of the central and peripheral nervous systems are defined,
- the external genitalia are apparent, but at this point, male and female embryos are indistinguishable,
- bone begins to replace cartilage in the embryonic skeleton through the process of ossification.

By the end of the embryonic period, the embryo is approximately 3 cm (1.2 in) from crown to rump and weighs approximately 8 g (0.25 oz).

Chapter Review

As the zygote travels toward the uterus, it undergoes numerous cleavages in which the number of cells doubles (blastomeres). Upon reaching the uterus, the conceptus has become a tightly packed sphere of cells called the morula, which then forms into a blastocyst consisting of an inner cell mass within a fluid-filled cavity surrounded by trophoblasts. The blastocyst implants in the uterine wall, the trophoblasts fuse to form a syncytiotrophoblast, and the conceptus is enveloped by the endometrium. Four embryonic membranes form to support the growing embryo: the amnion, the yolk sac, the allantois, and the chorion. The chorionic villi of the chorion extend into the endometrium to form the fetal portion of the placenta. The placenta supplies the growing embryo with oxygen and nutrients; it also removes carbon dioxide and other metabolic wastes.

Following implantation, embryonic cells undergo gastrulation, in which they differentiate and separate into an embryonic disc and establish three primary germ layers (the endoderm, mesoderm, and ectoderm). Through the process of embryonic folding, the fetus begins to take shape. Neurulation starts the process of the development of structures of the central nervous system and organogenesis establishes the basic plan for all organ systems.

Interactive Link Questions

Query 24.3.1

This interactive element is not available in this format. Visit the link or scan the QR code to access it online.

View this Interactive Content online

Video

This interactive element is not available in this format. Visit the link or scan the QR code to access it online.

View this Video online

Review Questions

Query 24.3.2

This interactive element is not available in this format. Visit the link or scan the QR code to access it online.

View this Interactive Content online

Critical Thinking Questions

Query 24.3.3

This interactive element is not available in this format. Visit the link or scan the QR code to access it online.

View this Interactive Content online

Query 24.3.4

This interactive element is not available in this format. Visit the link or scan the QR code to access it online.

View this Interactive Content online

Glossary

Query 24.3.5

This interactive element is not available in this format. Visit the link or scan the QR code to access it online.

View this Interactive Content online

Contributors and Attributions

OpenStax Anatomy & Physiology (CC BY 4.0). Access for free at https://openstax.org/books/anatomy-and-physiology

This page titled 24.3: Embryonic Development is shared under a CC BY-NC-SA 4.0 license and was authored, remixed, and/or curated by Jennifer Lange et al. via source content that was edited to the style and standards of the LibreTexts platform.

24.4: Fetal Development

Learning Objectives

- Differentiate between the embryonic period and the fetal period
- Briefly describe the process of sexual differentiation
- Describe the fetal circulatory system and explain the role of the shunts
- Trace the development of a fetus from the end of the embryonic period to birth

As you will recall, a developing human is called a fetus from the ninth week of gestation until birth. This 30-week period of development is marked by continued cell growth and differentiation, which fully develop the structures and functions of the immature organ systems formed during the embryonic period. The completion of fetal development results in a newborn who, although still immature in many ways, is capable of survival outside the womb.

Figure 24.4.1: Embryos at 9 and 10 weeks. By week 9 limbs and eye are visible and the embryo is 2 cm in length. In week 10 the 3 cm (1.2 inches) embryo begins limb movements, the eyelids develop, and the ears start to form. (These embryos were derived from ectopic or miscarried pregnancies.) *(Image credits: "Human Embryo 9th Week of Pregnancy" by Ed Uthman is licensed under CC BY 2.0. "Embryo @ approximately 8 weeks from conception, 10 weeks estimated gestational age from LMP" by lunar caustic is licensed under CC BY 2.0.)*

Sexual Differentiation

Sexual differentiation does not begin until the fetal period, during weeks 9–12. Embryonic males and females, though genetically distinguishable, are morphologically identical (Figure 24.4.1). Bipotential gonads, or gonads that can develop into male or female sexual organs, are connected to a central cavity called the cloaca via Müllerian ducts and Wolffian ducts. (The cloaca is an extension of the primitive gut.) Several events lead to sexual differentiation during this period.

During male fetal development, the SRY gene stimulates the bipotential gonads to become the testes, which start producing testosterone. Testosterone and Anti-Müllerian hormone (AMH) cause the Müllerian ducts degenerate and the Wolffian ducts to become the epididymis and vas deferens. The cloaca becomes the urethra and rectum.

During female fetal development, the bipotential gonads develop into ovaries. In the absence of testosterone and AMH, the Wolffian ducts degenerate and the Müllerian ducts become the uterine tubes and uterus. The cloaca divides and develops into a

vagina, a urethra, and a rectum.

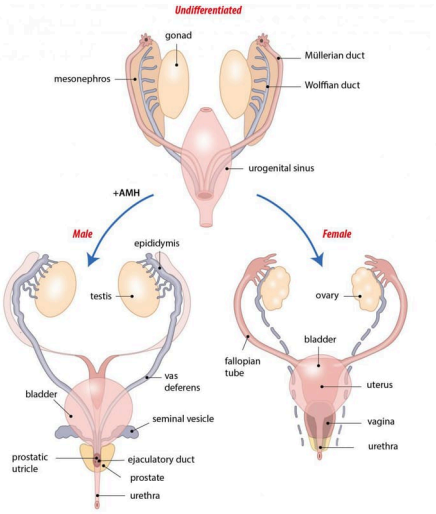

Figure 24.4.1: Genital Differentiation. Differentiation of the male and female reproductive systems does not occur until the fetal period of development. *(Image credit: "Slagter - Drawing Embryonic differentiation female and male genitals - English labels" by Ron Slagter, LUMC and Marco C. DeRuiter, LUMC, is licensed under CC BY-NC-SA.)*

The Fetal Circulatory System

During prenatal development, the fetal circulatory system is integrated with the placenta via the umbilical cord so that the fetus receives both oxygen and nutrients from the placenta. However, after childbirth, the umbilical cord is severed, and the newborn's circulatory system must be reconfigured. When the heart first forms in the embryo, it exists as two parallel tubes derived from mesoderm and lined with endothelium, which then fuse together. As the embryo develops into a fetus, the tube-shaped heart folds and further differentiates into the four chambers present in a mature heart. Unlike a mature cardiovascular system, however, the fetal cardiovascular system also includes circulatory shortcuts, or shunts. A **shunt** is an anatomical (or sometimes surgical) diversion that allows blood flow to bypass immature organs such as the lungs and liver until childbirth.

The placenta provides the fetus with necessary oxygen and nutrients via the umbilical vein. (Remember that veins carry blood toward the heart. In this case, the blood flowing to the fetal heart is oxygenated because it comes from the placenta. The respiratory system is immature and cannot yet oxygenate blood on its own.) From the umbilical vein, the oxygenated blood flows toward the inferior vena cava, all but bypassing the immature liver, via the **ductus venosus** shunt (Figure 24.4.2). The liver receives just a trickle of blood, which is all that it needs in its immature, semifunctional state. Blood flows from the inferior vena cava to the right atrium, mixing with fetal venous blood along the way.

Although the fetal liver is semifunctional, the fetal lungs are nonfunctional. The fetal circulation therefore bypasses the lungs by shifting some of the blood through the **foramen ovale**, a shunt that directly connects the right and left atria and avoids the pulmonary trunk altogether. Most of the rest of the blood is pumped to the right ventricle, and from there, into the pulmonary trunk, which splits into pulmonary arteries. However, a shunt within the pulmonary artery, the **ductus arteriosus**, diverts a portion of this blood into the aorta. This ensures that only a small volume of oxygenated blood passes through the immature pulmonary circuit, which has only minor metabolic requirements. Blood vessels of uninflated lungs have high resistance to flow, a condition that encourages blood to flow to the aorta, which presents much lower resistance. The oxygenated blood moves through the foramen ovale into the left atrium, where it mixes with the now deoxygenated blood returning from the pulmonary circuit. This blood then moves into the left ventricle, where it is pumped into the aorta. Some of this blood moves through the coronary arteries into the myocardium, and some moves through the carotid arteries to the brain.

The descending aorta carries partially oxygenated and partially deoxygenated blood into the lower regions of the body. It eventually passes into the umbilical arteries through branches of the internal iliac arteries. The deoxygenated blood collects waste as it circulates through the fetal body and returns to the umbilical cord. Thus, the two umbilical arteries carry blood low in oxygen and high in carbon dioxide and fetal wastes. This blood is filtered through the placenta, where wastes diffuse into the maternal circulation. Oxygen and nutrients from the mother diffuse into the placenta and from there into the fetal blood, and the process

repeats.

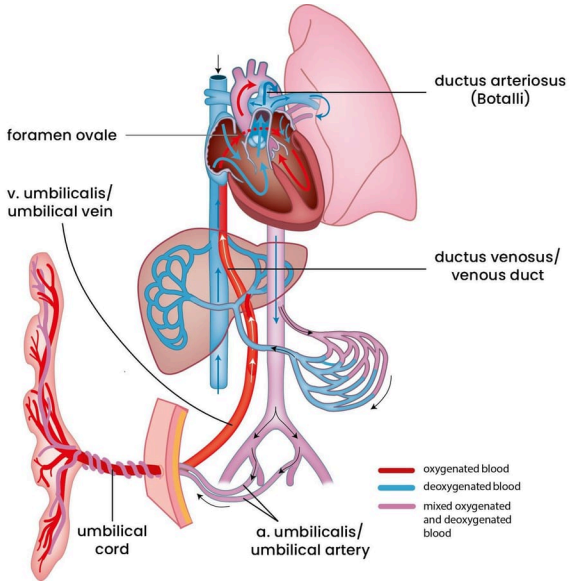

Figure 24.4.2: Fetal Circulatory System. The fetal circulatory system includes three shunts to divert blood from undeveloped and partially functioning organs, as well as blood supply to and from the placenta. *(Image credit: "Slagter - Drawing Fetal circulation - Latin and English labels" by Ron Slagter and O. Paul Gobée, LUMC is licensed under CC BY-NC-SA.)*

Brain Development

While early brain regions form in the embryo, much of brain development in the fetal period centers around the processes of neuron production, migration and differentiation.

1. The formation of neurons from stem cell precursors (neurogenesis) begins at day 42 and continues through mid gestation. By day 100 (week 13) neurons are being produced at a rate of 15 million per hour! These early neurons can generate electrical activity, but they are not connected to each other and, thus, are operating in isolation.
2. The migration of immature neurons from their birthplaces in the embryo to their final positions begins in week 10 and continues through approximately week 25.
3. The differentiation of neurons into specific types, for the majority of neurons, begins when they reach their destination by a) the outgrowth of dendrites and axons and b) the guidance of the axonic growth cone through the embryo towards postsynaptic targets.
4. The generation of synapses between axons and their postsynaptic partners begins early and then dramatically rises in week 28.
5. Gliogenesis starts with the production of immature astrocytes from neuron precursors between weeks 16-18, followed in weeks 18-20 by the formation of oligodendrocyte precursor cells. Oligodendrocytes are the last cells to begin development in the embryonic brain; myelination of axons begins in week 30.

Reflexive actions begin early, with those arising from the brainstem and cerebellum beginning during the second trimester. Most cortical gyri and sulci begin to take shape between weeks 24 and 38 of development. At birth most neurons have been born, but the brain is only around 25% of its adult weight because glial cells are only just emerging. At birth, most movements are still reflexive - controlled by the cerebellum and the brainstem. The motor cortex in the frontal lobe begins controlling conscious movements between the 3rd and 6th month after birth.

Other Organ Systems

During weeks 9–12 of fetal development the body elongates, and ossification continues. Fetal movements are frequent during this period, but are jerky and not well-controlled. The bone marrow begins to take over the process of erythrocyte production—a task that the liver performed during the embryonic period. The liver now secretes bile. The fetus circulates amniotic fluid by swallowing it and producing urine. The eyes are well-developed by this stage, but the eyelids are fused shut. The fingers and toes begin to develop nails. By the end of week 12, the fetus measures approximately 9 cm (3.5 in) from crown to rump.

Weeks 13–16 are marked by sensory organ development. The eyes move closer together; blinking motions begin, although the eyes remain sealed shut. The lips exhibit sucking motions. The ears move upward and lie flatter against the head. The scalp begins to grow hair. The excretory system is also developing: the kidneys are well-formed, and **meconium**, or fetal feces, begins to accumulate in the intestines. Meconium consists of ingested amniotic fluid, cellular debris, mucus, and bile.

During approximately weeks 16–20, as the fetus grows and limb movements become more powerful, the mother may begin to feel **quickening**, or fetal movements. However, space restrictions limit these movements and typically force the growing fetus into the "fetal position," with the arms crossed and the legs bent at the knees. Sebaceous glands coat the skin with a waxy, protective substance called **vernix caseosa** that protects and moisturizes the skin and may provide lubrication during childbirth. A silky hair called **lanugo** also covers the skin during weeks 17–20, but it is shed as the fetus continues to grow. Extremely premature infants sometimes exhibit residual lanugo.

Developmental weeks 21–30 are characterized by rapid weight gain, which is important for maintaining a stable body temperature after birth. The bone marrow completely takes over erythrocyte synthesis, and the axons of the spinal cord begin to be myelinated, or coated in the electrically insulating glial cell sheaths that are necessary for efficient nervous system functioning. (The process of myelination is not completed until adolescence.) During this period, the fetus grows eyelashes. The eyelids are no longer fused and can be opened and closed. The lungs begin producing surfactant, a substance that reduces surface tension in the lungs and assists proper lung expansion after birth. Inadequate surfactant production in premature newborns may result in respiratory distress syndrome, and as a result, the newborn may require surfactant replacement therapy, supplemental oxygen, or maintenance in a continuous positive airway pressure (CPAP) chamber during its first days or weeks of life. In male fetuses, the testes descend into the scrotum near the end of this period. The fetus at 30 weeks measures 28 cm (11 in) from crown to rump and exhibits the approximate body proportions of a full-term newborn, but still is much leaner.

The fetus continues to lay down subcutaneous fat from week 31 until birth. The added fat fills out the hypodermis, and the skin transitions from red and wrinkled to soft and pink. Lanugo is shed, and the nails grow to the tips of the fingers and toes. Immediately before birth, the average crown-to-rump length is 35.5–40.5 cm (14–16 in), and the fetus weighs approximately 2.5–4 kg (5.5–8.8 lbs). Once born, the newborn is no longer confined to the fetal position, so subsequent measurements are made from head-to-toe instead of from crown-to-rump. At birth, the average length is approximately 51 cm (20 in).

DISORDERS OF THE... Developing Fetus

Throughout the second half of gestation, the fetal intestines accumulate a tarry, greenish black meconium. The newborn's first stools consist almost entirely of meconium; they later transition to seedy yellow stools or slightly formed tan stools as meconium is cleared and replaced with digested breast milk or formula, respectively. Unlike these later stools, meconium is sterile; it is devoid of bacteria because the fetus is in a sterile environment and has not consumed any breast milk or formula. Typically, an infant does not pass meconium until after birth. However, in 5–20 percent of births, the fetus has a bowel movement in utero, which can cause major complications in the newborn.

The passage of meconium in the uterus signals fetal distress, particularly fetal hypoxia (i.e., oxygen deprivation). This may be caused by maternal drug abuse (especially tobacco or cocaine), maternal hypertension, depletion of amniotic fluid, long labor or difficult birth, or a defect in the placenta that prevents it from delivering adequate oxygen to the fetus. Meconium passage is typically a complication of full-term or post-term newborns because it is rarely passed before 34 weeks of gestation, when the gastrointestinal system has matured and is appropriately controlled by nervous system stimuli. Fetal distress can stimulate the vagus nerve to trigger gastrointestinal peristalsis and relaxation of the anal sphincter. Notably, fetal hypoxic stress also induces a gasping reflex, increasing the likelihood that meconium will be inhaled into the fetal lungs.

Although meconium is a sterile substance, it interferes with the antibiotic properties of the amniotic fluid and makes the newborn and mother more vulnerable to bacterial infections at birth and during the perinatal period. Specifically, inflammation of the fetal membranes, inflammation of the uterine lining, or neonatal sepsis (infection in the newborn) may occur. Meconium also irritates delicate fetal skin and can cause a rash.

The first sign that a fetus has passed meconium usually does not come until childbirth, when the amniotic sac ruptures. Normal amniotic fluid is clear and watery, but amniotic fluid in which meconium has been passed is stained greenish or yellowish. Antibiotics given to the mother may reduce the incidence of maternal bacterial infections, but it is critical that

meconium is aspirated from the newborn before the first breath. Under these conditions, an obstetrician will extensively aspirate the infant's airways as soon as the head is delivered, while the rest of the infant's body is still inside the birth canal.

Aspiration of meconium with the first breath can result in labored breathing, a barrel-shaped chest, or a low Apgar score. An obstetrician can identify meconium aspiration by listening to the lungs with a stethoscope for a coarse rattling sound. Blood gas tests and chest X-rays of the infant can confirm meconium aspiration. Inhaled meconium after birth could obstruct a newborn's airways leading to alveolar collapse, interfere with surfactant function by stripping it from the lungs, or cause pulmonary inflammation or hypertension. Any of these complications will make the newborn much more vulnerable to pulmonary infection, including pneumonia.

Chapter Review

The fetal period lasts from the ninth week of development until birth. During this period, male and female gonads differentiate. The fetal circulatory system becomes much more specialized and efficient than its embryonic counterpart. It includes three shunts—the ductus venosus, the foramen ovale, and the ductus arteriosus—that enable it to bypass the semifunctional liver and pulmonary circuit until after childbirth. The brain continues to grow and its structures differentiate. Facial features develop, the body elongates, and the skeleton ossifies. In the womb, the developing fetus moves, blinks, practices sucking, and circulates amniotic fluid. The fetus grows from an embryo measuring approximately 3.3 cm (1.3 in) and weighing 7 g (0.25 oz) to an infant measuring approximately 51 cm (20 in) and weighing an average of approximately 3.4 kg (7.5 lbs). Embryonic organ structures that were primitive and nonfunctional develop to the point that the newborn can survive in the outside world.

Review Questions

Query 24.4.2

This interactive element is not available in this format. Visit the link or scan the QR code to access it online.

View this Interactive Content online

Critical Thinking Questions

Query 24.4.3

This interactive element is not available in this format. Visit the link or scan the QR code to access it online.

View this Interactive Content online

Query 24.4.4

This interactive element is not available in this format. Visit the link or scan the QR code to access it online.

View this Interactive Content online

Glossary

Query 24.4.5

This interactive element is not available in this format. Visit the link or scan the QR code to access it online.

View this Interactive Content online

This page titled 24.4: Fetal Development is shared under a CC BY-NC-SA 4.0 license and was authored, remixed, and/or curated by Jennifer Lange et al. via source content that was edited to the style and standards of the LibreTexts platform.

24.5: Maternal Changes During Pregnancy, Labor, and Birth

Learning Objectives

- Connect hormonal changes in estrogen, progesterone, and hCG to physical changes in the mother during pregnancy
- List the contributors to weight gain during pregnancy
- Describe the major changes to the maternal digestive, circulatory, and integumentary systems during pregnancy
- Summarize the events leading to labor

A full-term pregnancy lasts approximately 270 days (approximately 38.5 weeks) from conception to birth. Because it is easier to remember the first day of the last menstrual period (LMP) than to estimate the date of conception, obstetricians set the due date as 284 days (approximately 40.5 weeks) from the LMP. This assumes that conception occurred on day 14 of the woman's cycle, which is usually a good approximation. The 40 weeks of an average pregnancy are usually discussed in terms of three **trimesters**, each approximately 13 weeks. During the second and third trimesters, the pre-pregnancy uterus—about the size of a fist—grows dramatically to contain the fetus, causing a number of anatomical changes in the mother (Figure 24.5.1).

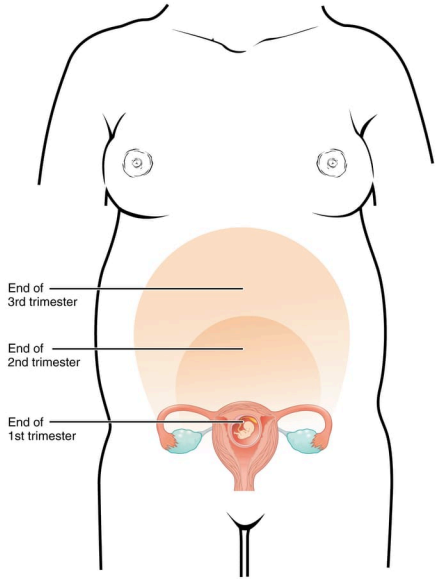

Figure 24.5.1: Size of Uterus Throughout Pregnancy. The uterus grows throughout pregnancy to accommodate the fetus. *(Image credit: "OpenStax AnatPhys fig.28.18 - Size of Uterus Throughout Pregnancy - English labels" by OpenStax, license: CC BY.)*

Effects of Hormones

Virtually all of the effects of pregnancy can be attributed in some way to the influence of hormones—particularly estrogens, progesterone, and hCG. During weeks 7–12 from the LMP, the pregnancy hormones are primarily generated by the corpus luteum. **Progesterone** secreted by the corpus luteum stimulates the production of cells of the endometrium that nourish the blastocyst before the placenta develops. As the **placenta** develops and the corpus luteum degenerates during weeks 12–17, the placenta gradually takes over as the endocrine organ of pregnancy.

The placenta converts weak androgens secreted by the maternal and fetal adrenal glands to **estrogens**, which are necessary for pregnancy to progress. Estrogen levels climb throughout the pregnancy, increasing 30-fold by childbirth. Estrogens have the following actions:

- They suppress FSH and LH production, effectively preventing ovulation. (This function is the biological basis of hormonal birth control pills.)
- They induce the growth of fetal tissues and are necessary for the maturation of the fetal lungs and liver.
- They promote fetal viability by regulating progesterone production and triggering fetal synthesis of cortisol, which helps with

the maturation of the lungs, liver, and endocrine organs such as the thyroid gland and adrenal gland.
- They stimulate maternal tissue growth, leading to uterine enlargement and mammary duct expansion and branching.

Relaxin, another hormone secreted by the corpus luteum and then by the placenta, helps prepare the mother's body for childbirth. It increases the elasticity of the symphysis pubis joint and pelvic ligaments, making room for the growing fetus and allowing expansion of the pelvic outlet for childbirth. Relaxin also helps dilate the cervix during labor.

The placenta takes over the synthesis and secretion of progesterone throughout pregnancy as the corpus luteum degenerates. Like estrogen, **progesterone** suppresses FSH and LH. It also inhibits uterine contractions, protecting the fetus from preterm birth. This hormone decreases in late gestation, allowing uterine contractions to intensify and eventually progress to true labor. The placenta also produces **hCG**. In addition to promoting survival of the corpus luteum, hCG stimulates the male fetal gonads to secrete testosterone, which is essential for the development of the male reproductive system.

The anterior pituitary enlarges and ramps up its hormone production during pregnancy, raising the levels of thyrotropin, prolactin, and adrenocorticotropic hormone (ACTH). Thyrotropin, in conjunction with placental hormones, increases the production of thyroid hormone, which raises the maternal metabolic rate. This can markedly augment a pregnant woman's appetite and cause hot flashes. Prolactin stimulates enlargement of the mammary glands in preparation for milk production. ACTH stimulates maternal cortisol secretion, which contributes to fetal protein synthesis. In addition to the pituitary hormones, increased parathyroid levels mobilize calcium from maternal bones for fetal use.

Weight Gain

The second and third trimesters of pregnancy are associated with dramatic changes in maternal anatomy and physiology. The most obvious anatomical sign of pregnancy is the dramatic enlargement of the abdominal region, coupled with maternal weight gain. This weight results from the growing fetus as well as the enlarged uterus, amniotic fluid, and placenta. Additional breast tissue and dramatically increased blood volume also contribute to weight gain (Table 24.5.1). Surprisingly, fat storage accounts for only approximately 2.3 kg (5 lbs) in a normal pregnancy and serves as a reserve for the increased metabolic demand of breastfeeding.

During the first trimester, the mother does not need to consume additional calories to maintain a healthy pregnancy. However, a weight gain of approximately 0.45 kg (1 lb) per month is common. During the second and third trimesters, the mother's appetite increases, but it is only necessary for her to consume an additional 300 calories per day to support the growing fetus. Most women gain approximately 0.45 kg (1 lb) per week.

Table 24.5.1 Contributors to Weight Gain During Pregnancy

Component	Weight (kg)	Weight (lb)
Fetus	3.2–3.6	7–8
Placenta and fetal membranes	0.9–1.8	2–4
Amniotic fluid	0.9–1.4	2–3
Breast tissue	0.9–1.4	2–3
Blood	1.4	4
Fat	0.9–4.1	3–9
Uterus	0.9–2.3	2–5
Total	10–16.3	22–36

Changes in Organ Systems During Pregnancy

As the woman's body adapts to pregnancy, characteristic physiologic changes occur. These changes can sometimes prompt symptoms often referred to collectively as the common discomforts of pregnancy.

Digestive and Urinary System Changes

Nausea and vomiting, sometimes triggered by an increased sensitivity to odors, are common during the first few weeks to months of pregnancy. This phenomenon is often referred to as “morning sickness,” although the nausea may persist all day. The source of pregnancy nausea is thought to be the increased circulation of pregnancy-related hormones, specifically circulating estrogen, progesterone, and hCG. Decreased intestinal peristalsis may also contribute to nausea. By about week 12 of pregnancy, nausea typically subsides.

A common gastrointestinal complaint during the later stages of pregnancy is gastric reflux, or heartburn, which results from the upward, constrictive pressure of the growing uterus on the stomach. The same decreased peristalsis that may contribute to nausea in early pregnancy is also thought to be responsible for pregnancy-related constipation as pregnancy progresses.

The downward pressure of the uterus also compresses the urinary bladder, leading to frequent urination. The problem is exacerbated by increased urine production. In addition, the maternal urinary system processes both maternal and fetal wastes, further increasing the total volume of urine.

Circulatory System Changes

Blood volume increases substantially during pregnancy, so that by childbirth, it exceeds its preconception volume by 30 percent, or approximately 1–2 liters. The greater blood volume helps to manage the demands of fetal nourishment and fetal waste removal. In conjunction with increased blood volume, the pulse and blood pressure also rise moderately during pregnancy. As the fetus grows, the uterus compresses underlying pelvic blood vessels, hampering venous return from the legs and pelvic region. As a result, many pregnant women develop varicose veins or hemorrhoids.

Respiratory System Changes

During the second half of pregnancy, the respiratory minute volume (volume of gas inhaled or exhaled by the lungs per minute) increases by 50 percent to compensate for the oxygen demands of the fetus and the increased maternal metabolic rate. The growing uterus exerts upward pressure on the diaphragm, decreasing the volume of each inspiration and potentially causing shortness of breath, or dyspnea. During the last several weeks of pregnancy, the pelvis becomes more elastic, and the fetus descends lower in a process called **lightening**. This typically ameliorates dyspnea.

The respiratory mucosa swell in response to increased blood flow during pregnancy, leading to nasal congestion and nose bleeds, particularly when the weather is cold and dry. Humidifier use and increased fluid intake are often recommended to counteract congestion.

Integumentary System Changes

The dermis stretches extensively to accommodate the growing uterus, breast tissue, and fat deposits on the thighs and hips. Torn connective tissue beneath the dermis can cause striae (stretch marks) on the abdomen, which appear as red or purple marks during pregnancy that fade to a silvery white color in the months after childbirth.

An increase in melanocyte-stimulating hormone, in conjunction with estrogens, darkens the areolae and creates a line of pigment from the umbilicus to the pubis called the linea nigra (Figure 24.5.2). Melanin production during pregnancy may also darken or discolor skin on the face to create a chloasma, or “mask of pregnancy.”

Figure 24.5.2: Linea Nigra. The linea nigra, a dark medial line running from the umbilicus to the pubis, forms during pregnancy and persists for a few weeks following childbirth. The linea nigra shown here corresponds to a pregnancy that is 22 weeks along. *(Image credit: "Photo of Linea Nigra" by Jeremy Kemp is in the public domain, via Wikimedia Commons.)*

Stages of Childbirth

The process of childbirth can be divided into three stages: cervical dilation, expulsion of the newborn, and afterbirth (Figure 24.5.3).

Cervical Dilation

For vaginal birth to occur, the cervix must dilate fully to 10 cm in diameter—wide enough to deliver the newborn's head. The **dilation** stage is the longest stage of labor and typically takes 6–12 hours. However, it varies widely and may take minutes, hours, or days, depending in part on whether the mother has given birth before; in each subsequent labor, this stage tends to be shorter.

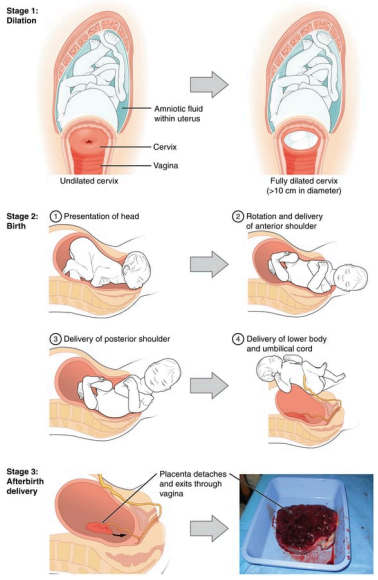

Figure 24.5.3: Stages of Childbirth. The stages of childbirth include Stage 1, early cervical dilation; Stage 2, full dilation and expulsion of the newborn; and Stage 3, delivery of the placenta and associated fetal membranes. (The position of the newborn's shoulder is described relative to the mother.) *(Image credit: "OpenStax AnatPhys fig.28.21 - Stages of Childbirth - English labels" by OpenStax, is licensed under CC BY.)*

True labor progresses in a positive feedback loop in which uterine contractions stretch the cervix, causing it to dilate and efface, or become thinner. Cervical stretching induces reflexive uterine contractions that dilate and efface the cervix further. In addition, cervical dilation boosts oxytocin secretion from the pituitary, which in turn triggers more powerful uterine contractions. When labor begins, uterine contractions may occur only every 3–30 minutes and last only 20–40 seconds; however, by the end of this stage, contractions may occur as frequently as every 1.5–2 minutes and last for a full minute.

Each contraction sharply reduces oxygenated blood flow to the fetus. For this reason, it is critical that a period of relaxation occur after each contraction. Fetal distress, measured as a sustained decrease or increase in the fetal heart rate, can result from severe

contractions that are too powerful or lengthy for oxygenated blood to be restored to the fetus. Such a situation can be cause for an emergency birth with vacuum, forceps, or surgically by Caesarian section.

The amniotic membranes rupture before the onset of labor in about 12 percent of women; they typically rupture at the end of the dilation stage in response to excessive pressure from the fetal head entering the birth canal.

Expulsion Stage

The **expulsion** stage begins when the fetal head enters the birth canal and ends with birth of the newborn. It typically takes up to 2 hours, but it can last longer or be completed in minutes, depending in part on the orientation of the fetus. The vertex presentation known as the occiput anterior vertex is the most common presentation and is associated with the greatest ease of vaginal birth. The fetus faces the maternal spinal cord and the smallest part of the head (the posterior aspect called the occiput) exits the birth canal first.

In fewer than 5 percent of births, the infant is oriented in the breech presentation, or buttocks down. In a complete breech, both legs are crossed and oriented downward. In a frank breech presentation, the legs are oriented upward. Before the 1960s, it was common for breech presentations to be delivered vaginally. Today, most breech births are accomplished by Caesarian section.

Vaginal birth is associated with significant stretching of the vaginal canal, the cervix, and the perineum. Until recent decades, it was routine procedure for an obstetrician to numb the perineum and perform an **episiotomy**, an incision in the posterior vaginal wall and perineum. The perineum is now more commonly allowed to tear on its own during birth. Both an episiotomy and a perineal tear need to be sutured shortly after birth to ensure optimal healing. Although suturing the jagged edges of a perineal tear may be more difficult than suturing an episiotomy, tears heal more quickly, are less painful, and are associated with less damage to the muscles around the vagina and rectum.

Upon birth of the newborn's head, an obstetrician will aspirate mucus from the mouth and nose before the newborn's first breath. Once the head is birthed, the rest of the body usually follows quickly. The umbilical cord is then double-clamped, and a cut is made between the clamps. This completes the second stage of childbirth.

Afterbirth

The delivery of the placenta and associated membranes, commonly referred to as the **afterbirth**, marks the final stage of childbirth. After expulsion of the newborn, the myometrium continues to contract. This movement shears the placenta from the back of the uterine wall. It is then easily delivered through the vagina. Continued uterine contractions then reduce blood loss from the site of the placenta. Delivery of the placenta marks the beginning of the postpartum period—the period of approximately 6 weeks immediately following childbirth during which the mother's body gradually returns to a non-pregnant state. If the placenta does not birth spontaneously within approximately 30 minutes, it is considered retained, and the obstetrician may attempt manual removal. If this is not successful, surgery may be required.

It is important that the obstetrician examines the expelled placenta and fetal membranes to ensure that they are intact. If fragments of the placenta remain in the uterus, they can cause postpartum hemorrhage. Uterine contractions continue for several hours after birth to return the uterus to its pre-pregnancy size in a process called **involution**, which also allows the mother's abdominal organs to return to their pre-pregnancy locations. Breastfeeding facilitates this process.

Although postpartum uterine contractions limit blood loss from the detachment of the placenta, the mother does experience a postpartum vaginal discharge called **lochia**. This is made up of uterine lining cells, erythrocytes, leukocytes, and other debris. Thick, dark, lochia rubra (red lochia) typically continues for 2–3 days, and is replaced by lochia serosa, a thinner, pinkish form that continues until about the tenth postpartum day. After this period, a scant, creamy, or watery discharge called lochia alba (white lochia) may continue for another 1–2 weeks.

Chapter Review

Hormones (especially estrogens, progesterone, and hCG) secreted by the corpus luteum and later by the placenta are responsible for most of the changes experienced during pregnancy. Estrogen maintains the pregnancy, promotes fetal viability, and stimulates tissue growth in the mother and developing fetus. Progesterone prevents new ovarian follicles from developing and suppresses uterine contractility.

Pregnancy weight gain primarily occurs in the breasts and abdominal region. Nausea, heartburn, and frequent urination are common during pregnancy. Maternal blood volume increases by 30 percent during pregnancy and respiratory minute volume increases by 50 percent. The skin may develop stretch marks and melanin production may increase.

Toward the late stages of pregnancy, a drop in progesterone and stretching forces from the fetus lead to increasing uterine irritability and prompt labor. Contractions serve to dilate the cervix and expel the newborn. Delivery of the placenta and associated fetal membranes follows.

Review Questions

Query 24.5.1

This interactive element is not available in this format. Visit the link or scan the QR code to access it online.

View this Interactive Content online

Critical Thinking Questions

Query 24.5.2

This interactive element is not available in this format. Visit the link or scan the QR code to access it online.

View this Interactive Content online

Query 24.5.3

This interactive element is not available in this format. Visit the link or scan the QR code to access it online.

View this Interactive Content online

Glossary

Query 24.5.4

This interactive element is not available in this format. Visit the link or scan the QR code to access it online.

View this Interactive Content online

This page titled 24.5: Maternal Changes During Pregnancy, Labor, and Birth is shared under a CC BY-NC-SA 4.0 license and was authored, remixed, and/or curated by Jennifer Lange et al. via source content that was edited to the style and standards of the LibreTexts platform.

24.6: Adjustments of the Infant at Birth and Postnatal Stages

Learning Objectives

- Discuss the importance of an infant's first breath
- Explain the closing of the cardiac shunts
- Describe thermoregulation in the newborn
- Summarize the importance of intestinal flora in the newborn

From a fetal perspective, the process of birth is a crisis. In the womb, the fetus was snuggled in a soft, warm, dark, and quiet world. The placenta provided nutrition and oxygen continuously. Suddenly, the contractions of labor and vaginal childbirth forcibly squeeze the fetus through the birth canal, limiting oxygenated blood flow during contractions and shifting the skull bones to accommodate the small space. After birth, the newborn's system must make drastic adjustments to a world that is colder, brighter, and louder, and where he or she will experience hunger and thirst. The neonatal period (neo- = "new"; -natal = "birth") spans the first to the thirtieth day of life outside of the uterus.

Respiratory Adjustments

Although the fetus "practices" breathing by inhaling amniotic fluid in utero, there is no air in the uterus and thus no true opportunity to breathe. (There is also no need to breathe because the placenta supplies the fetus with all the oxygenated blood it needs.) During gestation, the partially collapsed lungs are filled with amniotic fluid and exhibit very little metabolic activity. Several factors stimulate newborns to take their first breath at birth. First, labor contractions temporarily constrict umbilical blood vessels, reducing oxygenated blood flow to the fetus and elevating carbon dioxide levels in the blood. High carbon dioxide levels cause acidosis and stimulate the respiratory center in the brain, triggering the newborn to take a breath.

The first breath typically is taken within 10 seconds of birth, after mucus is aspirated from the infant's mouth and nose. The first breaths inflate the lungs to nearly full capacity and dramatically decrease lung pressure and resistance to blood flow, causing a major circulatory reconfiguration. Pulmonary alveoli open, and alveolar capillaries fill with blood. Amniotic fluid in the lungs drains or is absorbed, and the lungs immediately take over the task of the placenta, exchanging carbon dioxide for oxygen by the process of respiration.

Circulatory Adjustments

The process of clamping and cutting the umbilical cord collapses the umbilical blood vessels. In the absence of medical assistance, this occlusion would occur naturally within 20 minutes of birth because the Wharton's jelly within the umbilical cord would swell in response to the lower temperature outside of the mother's body, and the blood vessels would constrict. Natural occlusion has occurred when the umbilical cord is no longer pulsating. For the most part, the collapsed vessels atrophy and become fibrotic remnants, existing in the mature circulatory system as ligaments of the abdominal wall and liver. The ductus venosus degenerates to become the ligamentum venosum beneath the liver. Only the proximal sections of the two umbilical arteries remain functional, taking on the role of supplying blood to the upper part of the bladder (Figure 24.6.1).

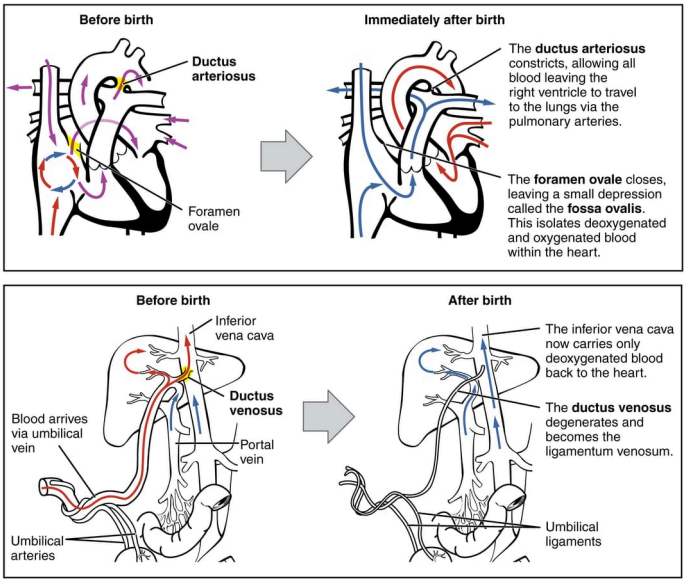

Figure 24.6.1: Neonatal Circulatory System. A newborn's circulatory system reconfigures immediately after birth. The three fetal shunts have been closed permanently, facilitating blood flow to the liver and lungs.

The newborn's first breath is vital to initiate the transition from the fetal to the neonatal circulatory pattern. Inflation of the lungs decreases blood pressure throughout the pulmonary system, as well as in the right atrium and ventricle. In response to this pressure change, the flow of blood temporarily reverses direction through the foramen ovale, moving from the left to the right atrium, and blocking the shunt with two flaps of tissue. Within 1 year, the tissue flaps usually fuse over the shunt, turning the foramen ovale into the fossa ovalis. The ductus arteriosus constricts as a result of increased oxygen concentration, and becomes the ligamentum arteriosum. Closing of the ductus arteriosus ensures that all blood pumped to the pulmonary circuit will be oxygenated by the newly functional neonatal lungs.

Thermoregulatory Adjustments

The fetus floats in warm amniotic fluid that is maintained at a temperature of approximately 98.6°F with very little fluctuation. Birth exposes newborns to a cooler environment in which they have to regulate their own body temperature. Newborns have a higher ratio of surface area to volume than adults. This means that their body has less volume throughout which to produce heat, and more surface area from which to lose heat. As a result, newborns produce heat more slowly and lose it more quickly. Newborns also have immature musculature that limits their ability to generate heat by shivering. Moreover, their nervous systems are underdeveloped, so they cannot quickly constrict superficial blood vessels in response to cold. They also have little subcutaneous fat for insulation. All these factors make it harder for newborns to maintain their body temperature.

Newborns, however, do have a special method for generating heat: **nonshivering thermogenesis**, which involves the breakdown of **brown adipose tissue**, or brown fat, which is distributed over the back, chest, and shoulders. Brown fat differs from the more familiar white fat in two ways:

- It is highly vascularized. This allows for faster delivery of oxygen, which leads to faster cellular respiration.
- It is packed with a special type of mitochondria that are able to engage in cellular respiration reactions that produce less ATP and more heat than standard cellular respiration reactions.

The breakdown of brown fat occurs automatically upon exposure to cold, so it is an important heat regulator in newborns. During fetal development, the placenta secretes inhibitors that prevent metabolism of brown adipose fat and promote its accumulation in preparation for birth.

Gastrointestinal and Urinary Adjustments

In adults, the gastrointestinal tract harbors bacterial flora—trillions of bacteria that aid in digestion, produce vitamins, and protect from the invasion or replication of pathogens. In stark contrast, the fetal intestine is sterile. The first consumption of breast milk or formula floods the neonatal gastrointestinal tract with beneficial bacteria that begin to establish the bacterial flora.

The fetal kidneys filter blood and produce urine, but the neonatal kidneys are still immature and inefficient at concentrating urine. Therefore, newborns produce very dilute urine, making it particularly important for infants to obtain sufficient fluids from breast milk or formula.

HOMEOSTATIC IMBALANCES

Homeostasis in the Newborn: Apgar Score

In the minutes following birth, a newborn must undergo dramatic systemic changes to be able to survive outside the womb. An obstetrician, midwife, or nurse can estimate how well a newborn is doing by obtaining an Apgar score. The Apgar score was introduced in 1952 by the anesthesiologist Dr. Virginia Apgar as a method to assess the effects on the newborn of anesthesia given to the laboring mother. Healthcare providers now use it to assess the general wellbeing of the newborn, whether or not analgesics or anesthetics were used.

Five criteria—skin color, heart rate, reflex, muscle tone, and respiration—are assessed, and each criterion is assigned a score of 0, 1, or 2. Scores are taken at 1 minute after birth and again at 5 minutes after birth. Each time that scores are taken, the five scores are added together. High scores (out of a possible 10) indicate the baby has made the transition from the womb well, whereas lower scores indicate that the baby may be in distress.

The technique for determining an Apgar score is quick and easy, painless for the newborn, and does not require any instruments except for a stethoscope. A convenient way to remember the five scoring criteria is to apply the mnemonic APGAR, for “appearance” (skin color), “pulse” (heart rate), “grimace” (reflex), “activity” (muscle tone), and “respiration.”

Of the five Apgar criteria, heart rate and respiration are the most critical. Poor scores for either of these measurements may indicate the need for immediate medical attention to resuscitate or stabilize the newborn. In general, any score lower than 7 at the 5-minute mark indicates that medical assistance may be needed. A total score below 5 indicates an emergency situation. Normally, a newborn will get an intermediate score of 1 for some of the Apgar criteria and will progress to a 2 by the 5-minute assessment. Scores of 8 or above are normal.

Chapter Review

The first breath a newborn takes at birth inflates the lungs and dramatically alters the circulatory system, closing the three shunts that directed oxygenated blood away from the lungs and liver during fetal life. Clamping and cutting the umbilical cord collapses the three umbilical blood vessels. The proximal umbilical arteries remain a part of the circulatory system, whereas the distal umbilical arteries and the umbilical vein become fibrotic. The newborn keeps warm by breaking down brown adipose tissue in the process of nonshivering thermogenesis. The first consumption of breast milk or formula floods the newborn’s sterile gastrointestinal tract with beneficial bacteria that eventually establish themselves as the bacterial flora, which aid in digestion.

Review Questions

Query 24.6.1

This interactive element is not available in this format. Visit the link or scan the QR code to access it online.

View this Interactive Content online

Critical Thinking Questions

Query 24.6.2

This interactive element is not available in this format. Visit the link or scan the QR code to access it online.

View this Interactive Content online

Query 24.6.3

This interactive element is not available in this format. Visit the link or scan the QR code to access it online.

View this Interactive Content online

Glossary

Query 24.6.4

This interactive element is not available in this format. Visit the link or scan the QR code to access it online.

View this Interactive Content online

This page titled 24.6: Adjustments of the Infant at Birth and Postnatal Stages is shared under a CC BY-NC-SA 4.0 license and was authored, remixed, and/or curated by Jennifer Lange et al. via source content that was edited to the style and standards of the LibreTexts platform.

24.7: Lactation

Learning Objectives

- Describe the structure of the lactating breast
- Summarize the process of lactation

Lactation is the process by which milk is synthesized and secreted from the mammary glands of the postpartum female breast in response to an infant sucking at the nipple. Breast milk provides ideal nutrition and passive immunity for the infant, encourages mild uterine contractions to return the uterus to its pre-pregnancy size (i.e., involution), and induces a substantial metabolic increase in the mother, consuming the fat reserves stored during pregnancy.

Structure of the Lactating Breast

Mammary glands are modified sweat glands. The non-pregnant and non-lactating female breast is composed primarily of adipose and collagenous tissue, with mammary glands making up a very minor proportion of breast volume. The mammary gland is composed of milk-transporting lactiferous ducts, which expand and branch extensively during pregnancy in response to estrogen, growth hormone, cortisol, and prolactin. Moreover, in response to progesterone, clusters of breast alveoli bud from the ducts and expand outward toward the chest wall. Breast alveoli are balloon-like structures lined with milk-secreting cuboidal cells, or lactocytes, that are surrounded by a net of contractile myoepithelial cells. Milk is secreted from the lactocytes, fills the alveoli, and is squeezed into the ducts. Clusters of alveoli that drain to a common duct are called lobules; the lactating female has 12–20 lobules organized radially around the nipple. Milk drains from lactiferous ducts into lactiferous sinuses that meet at 4 to 18 perforations in the nipple, called nipple pores. The small bumps of the areola (the darkened skin around the nipple) are called Montgomery glands. They secrete oil to cleanse the nipple opening and prevent chapping and cracking of the nipple during breastfeeding.

The Process of Lactation

The pituitary hormone **prolactin** is instrumental in the establishment and maintenance of breast milk supply. It also is important for the mobilization of maternal micronutrients for breast milk.

Near the fifth week of pregnancy, the level of circulating prolactin begins to increase, eventually rising to approximately 10–20 times the pre-pregnancy concentration. We noted earlier that, during pregnancy, prolactin and other hormones prepare the breasts anatomically for the secretion of milk. The level of prolactin plateaus in late pregnancy, at a level high enough to initiate milk production. However, estrogen, progesterone, and other placental hormones inhibit prolactin-mediated milk synthesis during pregnancy. It is not until the placenta is expelled that this inhibition is lifted and milk production commences.

After childbirth, the baseline prolactin level drops sharply, but it is restored for a 1-hour spike during each feeding to stimulate the production of milk for the next feeding. With each prolactin spike, estrogen and progesterone also increase slightly.

When the infant suckles, sensory nerve fibers in the areola trigger a neuroendocrine reflex that results in milk secretion from lactocytes into the alveoli. The posterior pituitary releases oxytocin, which stimulates myoepithelial cells to squeeze milk from the alveoli so it can drain into the lactiferous ducts, collect in the lactiferous sinuses, and discharge through the nipple pores. It takes less than 1 minute from the time when an infant begins suckling (the latent period) until milk is secreted (the let-down). Figure 24.7.1 summarizes the positive feedback loop of the **let-down reflex**.

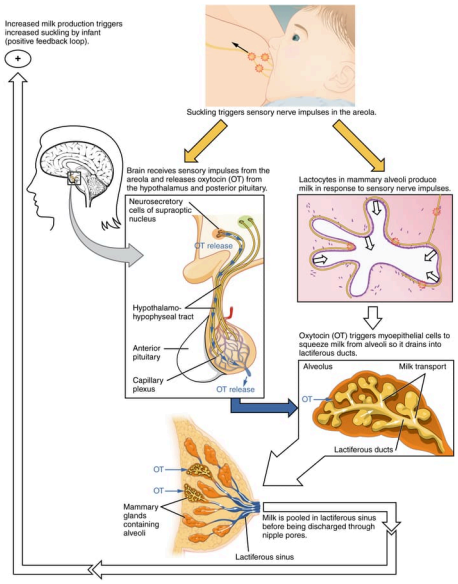

Figure 24.7.1: Let-Down Reflex. A positive feedback loop ensures continued milk production as long as the infant continues to breastfeed.

The prolactin-mediated synthesis of milk changes with time. Frequent milk removal by breastfeeding (or pumping) will maintain high circulating prolactin levels for several months. However, even with continued breastfeeding, baseline prolactin will decrease over time to its pre-pregnancy level. In addition to prolactin and oxytocin, growth hormone, cortisol, parathyroid hormone, and insulin contribute to lactation, in part by facilitating the transport of maternal amino acids, fatty acids, glucose, and calcium to breast milk.

Chapter Review

The lactating mother supplies all the hydration and nutrients that a growing infant needs for the first 4–6 months of life. During pregnancy, the body prepares for lactation by stimulating the growth and development of branching lactiferous ducts and alveoli lined with milk-secreting lactocytes, and by creating colostrum. These functions are attributable to the actions of several hormones, including prolactin. Following childbirth, suckling triggers oxytocin release, which stimulates myoepithelial cells to squeeze milk from alveoli. Breast milk then drains toward the nipple pores to be consumed by the infant.

Review Questions

Query 24.7.1

This interactive element is not available in this format. Visit the link or scan the QR code to access it online.

View this Interactive Content online

Critical Thinking Questions

Query 24.7.2

This interactive element is not available in this format. Visit the link or scan the QR code to access it online.

View this Interactive Content online

Query 24.7.3

This interactive element is not available in this format. Visit the link or scan the QR code to access it online.

View this Interactive Content online

Glossary

Query 24.7.4

This interactive element is not available in this format. Visit the link or scan the QR code to access it online.

View this Interactive Content online

This page titled 24.7: Lactation is shared under a CC BY-NC-SA 4.0 license and was authored, remixed, and/or curated by Jennifer Lange et al. via source content that was edited to the style and standards of the LibreTexts platform.

INDEX

A

abdominal aorta
18.3: Circulatory Pathways

abdominopelvic cavity
1.4: Anatomical Terminology

abducens nerve
12.3: Cranial Nerves
13.3: Hearing and Balance

abduct
9.2: Interactions of Skeletal Muscles, Their Fascicle Arrangement, and Their Lever Systems

abduction
7.4: Types of Body Movements

abductor
9.3: Naming Skeletal Muscles

abductor digiti minimi
9.6: Appendicular Muscles of the Pectoral Girdle and Upper Limbs

abductor pollicis brevis
9.6: Appendicular Muscles of the Pectoral Girdle and Upper Limbs

abductor pollicis longus
9.6: Appendicular Muscles of the Pectoral Girdle and Upper Limbs

absorption
21.3: Digestive System Processes and Regulation

accessory digestive organ
21.2: Organs of the Digestive System

accessory duct
21.7: Accessory Organs - Liver, Pancreas, and Gallbladder

accessory nerve
12.3: Cranial Nerves

acetabular labrum
7.5: Anatomy of Selected Synovial Joints

acetylcholine
14.3: Autonomic Synapses and Effects

acetylcholine (ACh)
14.2: Divisions of the Autonomic Nervous System
8.3: Skeletal Muscle Organ Structure

acinus
21.7: Accessory Organs - Liver, Pancreas, and Gallbladder

acne
4.5: Diseases, Disorders, and Injuries of the Integumentary System

acromegaly
15.3: Pituitary Gland and Hypothalamus

acromial end of the clavicle
6.6: The Pectoral Girdle

acromial process
6.6: The Pectoral Girdle

acromioclavicular joint
6.6: The Pectoral Girdle

acromion
6.6: The Pectoral Girdle

acrosomal reaction
24.2: Fertilization

acrosome
24.2: Fertilization

actin
8.3: Skeletal Muscle Organ Structure

Action Potential
10.4: Synapses
8.3: Skeletal Muscle Organ Structure

active transport
2.2: The Cell Membrane

acute inflammation
19.4: Anatomy of Lymphatic Organs and Tissues

adaptive immune response
19.3: Anatomy of Lymphatic Vessels

adduction
7.4: Types of Body Movements

adductor
9.3: Naming Skeletal Muscles

adductor brevis
9.7: Appendicular Muscles of the Pelvic Girdle and Lower Limbs

adductor longus
9.7: Appendicular Muscles of the Pelvic Girdle and Lower Limbs

adductor magnus
9.7: Appendicular Muscles of the Pelvic Girdle and Lower Limbs

adductor pollicis
9.6: Appendicular Muscles of the Pectoral Girdle and Upper Limbs

adductor tubercle
6.9: Bones of the Lower Limb

adipocytes
3.4: Connective Tissue

adipose tissue
3.4: Connective Tissue

adrenal artery
18.3: Circulatory Pathways

adrenal cortex
15.5: Adrenal Glands

adrenal glands
15.5: Adrenal Glands

adrenal medulla
14.2: Divisions of the Autonomic Nervous System
15.5: Adrenal Glands

adrenal medulla pathway
14.2: Divisions of the Autonomic Nervous System

adrenal vein
18.3: Circulatory Pathways

adrenergic
14.3: Autonomic Synapses and Effects

adrenergic receptor
14.3: Autonomic Synapses and Effects

adrenocorticotropic hormone (ACTH)
15.3: Pituitary Gland and Hypothalamus

afferent
10.2: Organization and Functions of the Nervous System

afferent branch
14.3: Autonomic Synapses and Effects

afferent lymphatic vessels
19.3: Anatomy of Lymphatic Vessels

afterbirth
24.5: Maternal Changes During Pregnancy, Labor, and Birth

agonist
9.2: Interactions of Skeletal Muscles, Their Fascicle Arrangement, and Their Lever Systems

agranular leukocytes
16.4: Leukocytes and Platelets

ala
20.3: Conducting Zone

alar cartilage
20.3: Conducting Zone

alarm reaction
15.5: Adrenal Glands

albinism
4.2: Layers of the Skin

albumin
16.2: An Overview of Blood

aldosterone
15.5: Adrenal Glands

alimentary canal
21.2: Organs of the Digestive System

allantois
24.3: Embryonic Development

alpha cell
15.8: Endocrine Pancreas

alveolar dead space
20.4: Respiratory Zone

alveolar duct
20.3: Conducting Zone

alveolar macrophage
20.3: Conducting Zone

alveolar pore
20.3: Conducting Zone

alveolar process of the mandible
6.3: The Skull

alveolar process of the maxilla
6.3: The Skull

alveolar sac
20.3: Conducting Zone

alveoli
23.3: Anatomy of the Female Reproductive System

alveolus
20.3: Conducting Zone

amacrine cell
13.3: Hearing and Balance

amnion
24.3: Embryonic Development

amniotic cavity
24.3: Embryonic Development

amphiarthrosis
7.2: Classification of Joints

amphipathic
2.2: The Cell Membrane

ampulla
13.3: Hearing and Balance
23.3: Anatomy of the Female Reproductive System

amygdala
11.4: Brain - Diencephalon, Brainstem, Cerebellum and Limbic System
14.4: Central Control of Autonomic Function

anagen
4.3: Accessory Structures of the Skin

anal canal
21.6: Small and Large Intestines

anal column
21.6: Small and Large Intestines

anal sinus
21.6: Small and Large Intestines

anal triangle
9.5: Axial Muscles of the Abdominal Wall and Thorax

anaphase
2.5: Cell Growth and Division

anastomosis
17.2: Heart Anatomy

anatomical dead space
20.4: Respiratory Zone

anatomical neck
6.7: Bones of the Upper Limb

anatomical position
1.4: Anatomical Terminology

anatomical sphincter
22.4: Urinary Tract

anatomy
1.2: Overview of Anatomy
General Human Anatomy (Lange et al.)

anchoring junction
3.3: Epithelial Tissue

anconeus
9.6: Appendicular Muscles of the Pectoral Girdle and Upper Limbs

anemia
16.3: Erythrocytes

angioblasts
18.4: Development of Blood Vessels and Fetal Circulation

angiogenesis
18.4: Development of Blood Vessels and Fetal Circulation

angiotensin I
22.3: Microscopic Anatomy of the Kidney

angiotensin II
22.3: Microscopic Anatomy of the Kidney

angiotensinogen
22.3: Microscopic Anatomy of the Kidney

angle of the mandible
6.3: The Skull

angle of the rib
6.5: The Thoracic Cage

ankle joint
6.9: Bones of the Lower Limb

annular ligament
7.5: Anatomy of Selected Synovial Joints

antagonist
9.2: Interactions of Skeletal Muscles, Their Fascicle Arrangement, and Their Lever Systems

anterior
1.4: Anatomical Terminology

anterior (ventral) sacral foramen
6.4: The Vertebral Column

anterior arch
6.4: The Vertebral Column

anterior border of the tibia
6.9: Bones of the Lower Limb

anterior cardiac veins
17.2: Heart Anatomy

Anterior Cavity
1.4: Anatomical Terminology

anterior cavity of the eye
13.3: Hearing and Balance

anterior cerebral artery
18.3: Circulatory Pathways

anterior chamber
13.3: Hearing and Balance

anterior communicating artery
18.3: Circulatory Pathways

anterior compartment of the arm
9.6: Appendicular Muscles of the Pectoral Girdle and Upper Limbs

anterior compartment of the forearm
9.6: Appendicular Muscles of the Pectoral Girdle and Upper Limbs

anterior compartment of the leg
9.7: Appendicular Muscles of the Pelvic Girdle and Lower Limbs

anterior compartment of the thigh
9.7: Appendicular Muscles of the Pelvic Girdle and Lower Limbs

anterior corticospinal tract
13.5: Taste and Smell

anterior cranial fossa
6.3: The Skull

anterior cruciate ligament
7.5: Anatomy of Selected Synovial Joints

anterior interventricular artery
17.2: Heart Anatomy

anterior interventricular sulcus
17.2: Heart Anatomy

anterior lobe
11.4: Brain - Diencephalon, Brainstem, Cerebellum and Limbic System

anterior longitudinal ligament
6.4: The Vertebral Column

anterior nucleus
13.4: Vision

anterior scalene
9.4: Axial Muscles of the Head, Neck, and Back

anterior talofibular ligament
7.5: Anatomy of Selected Synovial Joints

anterior tibial artery
18.3: Circulatory Pathways

anterior tibial vein
18.3: Circulatory Pathways

antibodies
16.2: An Overview of Blood

antibody
19.3: Anatomy of Lymphatic Vessels

antidiuretic hormone (ADH)
15.3: Pituitary Gland and Hypothalamus

antigen
19.3: Anatomy of Lymphatic Vessels

antrum
23.3: Anatomy of the Female Reproductive System

anulus fibrosus
6.4: The Vertebral Column

aorta
18.3: Circulatory Pathways

aortic arch
18.3: Circulatory Pathways

aortic hiatus
18.3: Circulatory Pathways

aortic valve
17.2: Heart Anatomy

apex
20.3: Conducting Zone

Apgar Score
24.6: Adjustments of the Infant at Birth and Postnatal Stages

aphasia
11.3: Brain - Cerebrum

apical
3.3: Epithelial Tissue

apneustic center
20.4: Respiratory Zone

apocrine secretion
3.3: Epithelial Tissue

apocrine sweat gland
4.3: Accessory Structures of the Skin

aponeurosis
8.3: Skeletal Muscle Organ Structure

apoptosis
3.7: Tissue Injury and Aging

appendicular
9.4: Axial Muscles of the Head, Neck, and Back

appendicular skeleton
6.2: Divisions of the Skeletal System

appendix
21.6: Small and Large Intestines

aquaporin
22.3: Microscopic Anatomy of the Kidney

aqueous humor
13.3: Hearing and Balance

arachnoid granulation
11.2: Support and Protection of the Brain

arachnoid mater
11.2: Support and Protection of the Brain

arachnoid trabeculae
11.2: Support and Protection of the Brain

arbor vitae
11.4: Brain - Diencephalon, Brainstem, Cerebellum and Limbic System

arcuate fiber
11.3: Brain - Cerebrum

areola
23.3: Anatomy of the Female Reproductive System

areolar tissue
3.4: Connective Tissue

arm
6.7: Bones of the Upper Limb

arrector pili
4.3: Accessory Structures of the Skin

arterial circle
18.3: Circulatory Pathways

arteriole
18.2: Structure and Function of Blood Vessels

arteriovenous anastomosis
18.2: Structure and Function of Blood Vessels

artery
18.2: Structure and Function of Blood Vessels
articular capsule
7.3: Synovial Joints
articular cartilage
5.3: Bone Structure
7.3: Synovial Joints
articular disc
7.3: Synovial Joints
articular tubercle
6.3: The Skull
articulation
5.3: Bone Structure
7.2: Classification of Joints
artificial pacemaker
17.3: Cardiac Muscle and Electrical Activity
ascending aorta
18.3: Circulatory Pathways
ascending colon
21.6: Small and Large Intestines
ascending pathway
13.4: Vision
association area
11.3: Brain - Cerebrum
13.4: Vision
association tract
11.3: Brain - Cerebrum
astrocyte
10.3: Anatomy of Nervous Tissue
3.6: Nervous Tissue
atlantoaxial joint
7.5: Anatomy of Selected Synovial Joints
atlas
6.4: The Vertebral Column
atmospheric pressure
20.4: Respiratory Zone
atrial natriuretic peptide (ANP)
15.9: Organs with Secondary Endocrine Functions
atrioventricular (AV) node
17.3: Cardiac Muscle and Electrical Activity
atrioventricular bundle
17.3: Cardiac Muscle and Electrical Activity
atrioventricular bundle branches
17.3: Cardiac Muscle and Electrical Activity
atrioventricular septum
17.2: Heart Anatomy
atrioventricular valves
17.2: Heart Anatomy
atrium
17.2: Heart Anatomy
atrophy
3.7: Tissue Injury and Aging
audition
13.3: Hearing and Balance
auditory canal
13.3: Hearing and Balance
auditory tube
13.3: Hearing and Balance
auricle
13.3: Hearing and Balance
17.2: Heart Anatomy
autocrine
15.2: An Overview of the Endocrine System
Autolysis
2.3: The Cytoplasm and Cellular Organelles
autonomic ganglion
14.2: Divisions of the Autonomic Nervous System
autonomic nervous system (ANS)
10.2: Organization and Functions of the Nervous System
14.2: Divisions of the Autonomic Nervous System
autonomic reflex
14.3: Autonomic Synapses and Effects
autonomic tone
14.3: Autonomic Synapses and Effects
autophagy
2.3: The Cytoplasm and Cellular Organelles
autorhythmicity
17.3: Cardiac Muscle and Electrical Activity
axial
9.4: Axial Muscles of the Head, Neck, and Back
axial skeleton
6.2: Divisions of the Skeletal System
axillary artery
18.3: Circulatory Pathways
axillary nerve
12.4: Spinal Nerves and Their Branches
axillary vein
18.3: Circulatory Pathways
axis
6.4: The Vertebral Column
axon
10.2: Organization and Functions of the Nervous System
10.3: Anatomy of Nervous Tissue
axon hillock
10.3: Anatomy of Nervous Tissue
axon segment
10.3: Anatomy of Nervous Tissue
axon terminal
10.3: Anatomy of Nervous Tissue
axoplasm
10.3: Anatomy of Nervous Tissue
azygos vein
18.3: Circulatory Pathways

B

B cells
19.3: Anatomy of Lymphatic Vessels
B lymphocytes
16.4: Leukocytes and Platelets
Bachmann's bundle
17.3: Cardiac Muscle and Electrical Activity
bacterial flora
21.6: Small and Large Intestines
baroreceptor
14.3: Autonomic Synapses and Effects
barrier defenses
19.3: Anatomy of Lymphatic Vessels
Bartholin's glands
23.3: Anatomy of the Female Reproductive System
basal cell
4.2: Layers of the Skin
basal cell carcinoma
4.5: Diseases, Disorders, and Injuries of the Integumentary System
basal lamina
3.3: Epithelial Tissue
basal nuclei
11.3: Brain - Cerebrum
base of the metatarsal bone
6.9: Bones of the Lower Limb
basement membrane
3.3: Epithelial Tissue
basilar artery
11.2: Support and Protection of the Brain
18.3: Circulatory Pathways
basilar membrane
13.3: Hearing and Balance
basilic vein
18.3: Circulatory Pathways
basophils
16.4: Leukocytes and Platelets
bedsore
4.5: Diseases, Disorders, and Injuries of the Integumentary System
belly
9.2: Interactions of Skeletal Muscles, Their Fascicle Arrangement, and Their Lever Systems
beta cell
15.8: Endocrine Pancreas
Betz cells
13.5: Taste and Smell
bi
9.3: Naming Skeletal Muscles
biaxial joint
7.2: Classification of Joints
biceps brachii
9.6: Appendicular Muscles of the Pectoral Girdle and Upper Limbs
biceps femoris
9.7: Appendicular Muscles of the Pelvic Girdle and Lower Limbs
bicipital groove
6.7: Bones of the Upper Limb
bicuspid valve
17.2: Heart Anatomy
bile
21.7: Accessory Organs - Liver, Pancreas, and Gallbladder
bilirubin
16.3: Erythrocytes
21.7: Accessory Organs - Liver, Pancreas, and Gallbladder
biliverdin
16.3: Erythrocytes
binocular depth cues
13.4: Vision
bipennate
9.2: Interactions of Skeletal Muscles, Their Fascicle Arrangement, and Their Lever Systems
bipolar
10.3: Anatomy of Nervous Tissue
bipolar cell
13.3: Hearing and Balance
blastocoel
24.3: Embryonic Development
blastocyst
24.3: Embryonic Development
blastomere
24.3: Embryonic Development
blood
16.2: An Overview of Blood

blood islands
18.4: Development of Blood Vessels and Fetal Circulation

blood–testis barrier
23.2: Anatomy of the Male Reproductive System

body
21.5: Stomach

body of the rib
6.5: The Thoracic Cage

body of uterus
23.3: Anatomy of the Female Reproductive System

bolus
21.4: Mouth, Pharynx, and Esophagus

bone
5.2: Functions of the Skeletal System

bone marrow
19.3: Anatomy of Lymphatic Vessels

bone marrow biopsy
16.5: Production of the Formed Elements

bone marrow transplant
16.5: Production of the Formed Elements

bony labyrinth
13.3: Hearing and Balance

Boyle's Law
20.4: Respiratory Zone

brachial artery
18.3: Circulatory Pathways

brachial plexus
12.4: Spinal Nerves and Their Branches

brachial vein
18.3: Circulatory Pathways

brachialis
9.6: Appendicular Muscles of the Pectoral Girdle and Upper Limbs

brachiocephalic artery
18.3: Circulatory Pathways

brachiocephalic vein
18.3: Circulatory Pathways

brachioradialis
9.6: Appendicular Muscles of the Pectoral Girdle and Upper Limbs

brain
10.2: Organization and Functions of the Nervous System

brain case
6.3: The Skull

brainstem
10.5: Development of the Nervous System
13.3: Hearing and Balance

Braxton Hicks contractions
24.5: Maternal Changes During Pregnancy, Labor, and Birth

breathing
20.4: Respiratory Zone

brevis
9.3: Naming Skeletal Muscles

bridge
20.3: Conducting Zone

broad ligament
23.3: Anatomy of the Female Reproductive System

Broca's area
11.3: Brain - Cerebrum

Broca's area
13.5: Taste and Smell

Brodmann's areas
11.3: Brain - Cerebrum

bronchial artery
18.3: Circulatory Pathways

bronchial bud
20.5: Embryonic Development of the Respiratory System

bronchial tree
20.3: Conducting Zone

bronchial vein
18.3: Circulatory Pathways

bronchiole
20.3: Conducting Zone

bronchoconstriction
20.2: The Lungs

bronchodilation
20.2: The Lungs

bronchus
20.3: Conducting Zone

brown adipose tissue
24.6: Adjustments of the Infant at Birth and Postnatal Stages

brush border
21.6: Small and Large Intestines
22.3: Microscopic Anatomy of the Kidney

buccinator
9.4: Axial Muscles of the Head, Neck, and Back

buffy coat
16.2: An Overview of Blood

bulbourethral glands
23.2: Anatomy of the Male Reproductive System

bulbus cordis
17.5: Development of the Heart

bundle of His
17.3: Cardiac Muscle and Electrical Activity

bursa
7.3: Synovial Joints

C

calcaneal tendon
9.7: Appendicular Muscles of the Pelvic Girdle and Lower Limbs

calcaneofibular ligament
7.5: Anatomy of Selected Synovial Joints

calcaneus
6.9: Bones of the Lower Limb

calcitonin
15.4: Thyroid Gland and Parathyroid Glands

callus
4.5: Diseases, Disorders, and Injuries of the Integumentary System

calvaria
6.3: The Skull

canaliculi
5.3: Bone Structure

capacitance
18.2: Structure and Function of Blood Vessels

capacitance vessels
18.2: Structure and Function of Blood Vessels

capacitation
24.2: Fertilization

capillary
18.2: Structure and Function of Blood Vessels

capillary bed
18.2: Structure and Function of Blood Vessels

capitate
6.7: Bones of the Upper Limb

capitulum
6.7: Bones of the Upper Limb

carbaminohemoglobin
16.3: Erythrocytes

cardia
21.5: Stomach

cardiac accelerator nerves
14.4: Central Control of Autonomic Function

cardiac cycle
17.4: Coronary Circulation

cardiac muscle
3.5: Muscle Tissue
8.2: Muscle Tissues

cardiac notch
17.2: Heart Anatomy
20.2: The Lungs

cardiac skeleton
17.2: Heart Anatomy

cardiogenic area
17.5: Development of the Heart

cardiogenic cords
17.5: Development of the Heart

cardiomyocyte
17.2: Heart Anatomy

cardiovascular center
14.4: Central Control of Autonomic Function

carotid canal
6.3: The Skull

carpal bone
6.7: Bones of the Upper Limb

carpal tunnel
6.7: Bones of the Upper Limb

carpometacarpal joint
6.7: Bones of the Upper Limb

cartilage
5.2: Functions of the Skeletal System

cartilaginous joint
7.2: Classification of Joints

catagen
4.3: Accessory Structures of the Skin

Caudal
1.4: Anatomical Terminology

caudate
11.3: Brain - Cerebrum

caval opening
9.5: Axial Muscles of the Abdominal Wall and Thorax

cavernous sinus
18.3: Circulatory Pathways

Cecum
21.6: Small and Large Intestines

celiac ganglion
14.2: Divisions of the Autonomic Nervous System

celiac trunk
18.3: Circulatory Pathways

cell
1.3: Structural Organization of the Human Body

cell cycle
2.5: Cell Growth and Division

cell junction
3.3: Epithelial Tissue

cell membrane
2.2: The Cell Membrane

cementum
21.4: Mouth, Pharynx, and Esophagus

central canal
11.2: Support and Protection of the Brain
5.3: Bone Structure

central chemoreceptor
20.4: Respiratory Zone

central nervous system (CNS)
10.2: Organization and Functions of the Nervous System

central sulcus
11.3: Brain - Cerebrum

central vein
21.7: Accessory Organs - Liver, Pancreas, and Gallbladder

centriole
2.3: The Cytoplasm and Cellular Organelles

centromere
2.5: Cell Growth and Division

centrosome
2.5: Cell Growth and Division

cephalic flexure
10.5: Development of the Nervous System

cephalic phase
21.5: Stomach

cephalic vein
18.3: Circulatory Pathways

cerebellar hemispheres
11.4: Brain - Diencephalon, Brainstem, Cerebellum and Limbic System

cerebellar nuclei
11.4: Brain - Diencephalon, Brainstem, Cerebellum and Limbic System

cerebellum
11.4: Brain - Diencephalon, Brainstem, Cerebellum and Limbic System
13.3: Hearing and Balance

cerebral aqueduct
11.2: Support and Protection of the Brain
11.4: Brain - Diencephalon, Brainstem, Cerebellum and Limbic System

cerebral cortex
11.3: Brain - Cerebrum

cerebral hemisphere
11.3: Brain - Cerebrum

cerebral nuclei
13.3: Hearing and Balance

cerebral peduncles
11.4: Brain - Diencephalon, Brainstem, Cerebellum and Limbic System
13.5: Taste and Smell

cerebrospinal fluid (CSF)
10.3: Anatomy of Nervous Tissue

cerebrovascular accident (CVA)
18.3: Circulatory Pathways

cerebrum
11.3: Brain - Cerebrum

cervical curve
6.4: The Vertebral Column

cervical enlargement
13.5: Taste and Smell

cervical plexus
12.4: Spinal Nerves and Their Branches

cervical vertebrae
6.4: The Vertebral Column

cervix
23.3: Anatomy of the Female Reproductive System

channel protein
2.2: The Cell Membrane

checkpoint
2.5: Cell Growth and Division

chemical digestion
21.3: Digestive System Processes and Regulation

chemical synapse
10.4: Synapses

chemokine
19.4: Anatomy of Lymphatic Organs and Tissues

chemoreceptor
13.2: Sensory Modalities and General Senses

chief cell
21.5: Stomach

chief sensory nucleus
13.4: Vision

cholinergic
14.3: Autonomic Synapses and Effects

chondrocytes
3.4: Connective Tissue

chordae tendineae
17.2: Heart Anatomy

chorion
24.3: Embryonic Development

chorionic membrane
24.3: Embryonic Development

chorionic villi
24.3: Embryonic Development

choroid
13.3: Hearing and Balance

choroid plexus
10.3: Anatomy of Nervous Tissue
11.2: Support and Protection of the Brain

chromaffin
15.5: Adrenal Glands

chromaffin cells
14.2: Divisions of the Autonomic Nervous System

chromatin
2.4: The Nucleus

chromosome
2.4: The Nucleus

chronic inflammation
19.4: Anatomy of Lymphatic Organs and Tissues

chyle
19.3: Anatomy of Lymphatic Vessels

chyme
21.3: Digestive System Processes and Regulation

cilia
2.3: The Cytoplasm and Cellular Organelles

ciliary body
13.3: Hearing and Balance

ciliary ganglion
14.2: Divisions of the Autonomic Nervous System

ciliary process
13.3: Hearing and Balance

cingulate gyrus
11.4: Brain - Diencephalon, Brainstem, Cerebellum and Limbic System

circadian rhythm
13.4: Vision

circle of Willis
11.2: Support and Protection of the Brain
18.3: Circulatory Pathways

circular
9.2: Interactions of Skeletal Muscles, Their Fascicle Arrangement, and Their Lever Systems

circular fold
21.6: Small and Large Intestines

circumduction
7.4: Types of Body Movements

circumflex artery
17.2: Heart Anatomy

cisterna chyli
19.3: Anatomy of Lymphatic Vessels

clavicle
6.6: The Pectoral Girdle

clavicular notch
6.5: The Thoracic Cage

cleavage
24.3: Embryonic Development

cleavage furrow
2.5: Cell Growth and Division

clitoris
23.3: Anatomy of the Female Reproductive System

closed reduction
5.5: Fractures and Bone Repair

clotting
3.7: Tissue Injury and Aging

coccyx
6.2: Divisions of the Skeletal System

cochlea
13.3: Hearing and Balance

cochlear duct
13.3: Hearing and Balance

cochlear nerve
13.3: Hearing and Balance

cochlear nuclei
13.4: Vision

collagen fiber
3.4: Connective Tissue

collateral ganglia
14.2: Divisions of the Autonomic Nervous System

colloid
15.4: Thyroid Gland and Parathyroid Glands

colon
21.6: Small and Large Intestines

colostrum
24.7: Lactation

commissural tract
11.3: Brain - Cerebrum

common bile duct
21.7: Accessory Organs - Liver, Pancreas, and Gallbladder

common carotid artery
11.2: Support and Protection of the Brain
18.3: Circulatory Pathways

common hepatic artery
18.3: Circulatory Pathways

common iliac artery
18.3: Circulatory Pathways
common iliac vein
18.3: Circulatory Pathways
common tendinous ring
13.3: Hearing and Balance
compact bone
5.3: Bone Structure
complement
19.4: Anatomy of Lymphatic Organs and Tissues
compressor urethrae
9.5: Axial Muscles of the Abdominal Wall and Thorax
Computed Tomography (CT)
1.5: Medical Imaging
concentration gradient
2.2: The Cell Membrane
conceptus
24.3: Embryonic Development
conducting zone
20.3: Conducting Zone
conduction aphasia
11.3: Brain - Cerebrum
condylar process of the mandible
6.3: The Skull
condyloid joint
7.3: Synovial Joints
cone photoreceptor
13.3: Hearing and Balance
confluence of sinuses
11.2: Support and Protection of the Brain
connective tissue
3.2: Types of Tissues
connective tissue membrane
3.2: Types of Tissues
connective tissue proper
3.4: Connective Tissue
continuous capillary
18.2: Structure and Function of Blood Vessels
continuous conduction
10.4: Synapses
contractility
8.2: Muscle Tissues
contralateral
13.4: Vision
convergent
9.2: Interactions of Skeletal Muscles, Their Fascicle Arrangement, and Their Lever Systems
coracobrachialis
9.6: Appendicular Muscles of the Pectoral Girdle and Upper Limbs
coracoclavicular ligament
6.6: The Pectoral Girdle
coracohumeral ligament
7.5: Anatomy of Selected Synovial Joints
coracoid process
6.6: The Pectoral Girdle
corn
4.5: Diseases, Disorders, and Injuries of the Integumentary System
cornea
13.3: Hearing and Balance
corneal reflex
13.5: Taste and Smell
corona radiata
24.2: Fertilization
coronary arteries
17.2: Heart Anatomy
coronary sinus
17.2: Heart Anatomy
coronary sulcus
17.2: Heart Anatomy
coronary veins
17.2: Heart Anatomy
coronoid fossa
6.7: Bones of the Upper Limb
coronoid process of the ulna
6.7: Bones of the Upper Limb
corpora quadrigemina
11.4: Brain - Diencephalon, Brainstem, Cerebellum and Limbic System
corpus albicans
23.3: Anatomy of the Female Reproductive System
corpus callosum
11.3: Brain - Cerebrum
corpus cavernosum
23.2: Anatomy of the Male Reproductive System
corpus luteum
23.3: Anatomy of the Female Reproductive System
corpus spongiosum
23.2: Anatomy of the Male Reproductive System
corrugator supercilii
9.4: Axial Muscles of the Head, Neck, and Back
cortex
4.3: Accessory Structures of the Skin
cortical reaction
24.2: Fertilization
corticobulbar tract
13.5: Taste and Smell
corticospinal tract
13.5: Taste and Smell
cortisol
15.5: Adrenal Glands
costal cartilage
6.5: The Thoracic Cage
costal facet
6.4: The Vertebral Column
costal groove
6.5: The Thoracic Cage
costoclavicular ligament
6.6: The Pectoral Girdle
Cranial
1.4: Anatomical Terminology
cranial cavity
1.4: Anatomical Terminology
6.3: The Skull
cranial dura septa
11.2: Support and Protection of the Brain
cranial nerve
10.2: Organization and Functions of the Nervous System
12.3: Cranial Nerves
cranial nerve ganglion
12.3: Cranial Nerves
craniosacral system
14.2: Divisions of the Autonomic Nervous System
cranium
6.3: The Skull
cribriform plate
6.3: The Skull
cricoid cartilage
20.3: Conducting Zone
crista galli
6.3: The Skull
crown
21.4: Mouth, Pharynx, and Esophagus
cuboid
6.9: Bones of the Lower Limb
cupula
13.3: Hearing and Balance
cuspid
21.4: Mouth, Pharynx, and Esophagus
cutaneous membrane
3.2: Types of Tissues
cuticle
4.3: Accessory Structures of the Skin
cyclin
2.5: Cell Growth and Division
cystic artery
18.3: Circulatory Pathways
cystic duct
21.7: Accessory Organs - Liver, Pancreas, and Gallbladder
cytokine
19.4: Anatomy of Lymphatic Organs and Tissues
cytokines
16.5: Production of the Formed Elements
cytokinesis
2.5: Cell Growth and Division
cytoplasm
2.3: The Cytoplasm and Cellular Organelles
cytoskeleton
2.3: The Cytoplasm and Cellular Organelles
cytosol
2.3: The Cytoplasm and Cellular Organelles

D

deciduous tooth
21.4: Mouth, Pharynx, and Esophagus
decussate
13.4: Vision
decussation of pyramids
11.4: Brain - Diencephalon, Brainstem, Cerebellum and Limbic System
Deep
1.4: Anatomical Terminology
deep anterior compartment
9.6: Appendicular Muscles of the Pectoral Girdle and Upper Limbs
deep femoral artery
18.3: Circulatory Pathways
deep femoral vein
18.3: Circulatory Pathways
deep posterior compartment of the forearm
9.6: Appendicular Muscles of the Pectoral Girdle and Upper Limbs
deep transverse perineal
9.5: Axial Muscles of the Abdominal Wall and Thorax

defecation
21.3: Digestive System Processes and Regulation
defensins
16.4: Leukocytes and Platelets
deglutition
21.4: Mouth, Pharynx, and Esophagus
9.4: Axial Muscles of the Head, Neck, and Back
delta cell
15.8: Endocrine Pancreas
deltoid
9.6: Appendicular Muscles of the Pectoral Girdle and Upper Limbs
deltoid ligament
7.5: Anatomy of Selected Synovial Joints
deltoid tuberosity
6.7: Bones of the Upper Limb
dendrite
10.2: Organization and Functions of the Nervous System
10.3: Anatomy of Nervous Tissue
dens
21.4: Mouth, Pharynx, and Esophagus
6.4: The Vertebral Column
dense connective tissue
3.4: Connective Tissue
dentin
21.4: Mouth, Pharynx, and Esophagus
dentition
21.4: Mouth, Pharynx, and Esophagus
deoxyhemoglobin
16.3: Erythrocytes
depolarize
8.3: Skeletal Muscle Organ Structure
depression
7.4: Types of Body Movements
dermal papilla
4.2: Layers of the Skin
dermatome
12.4: Spinal Nerves and Their Branches
dermis
4.2: Layers of the Skin
descending aorta
18.3: Circulatory Pathways
descending colon
21.6: Small and Large Intestines
desmosome
4.2: Layers of the Skin
detrusor muscle
22.4: Urinary Tract
diabetes mellitus
15.8: Endocrine Pancreas
diapedesis
16.4: Leukocytes and Platelets
diaphragm
9.5: Axial Muscles of the Abdominal Wall and Thorax
diaphragma sellae
11.2: Support and Protection of the Brain
diaphysis
5.3: Bone Structure
diarthrosis
7.2: Classification of Joints
diastole
17.4: Coronary Circulation
diencephalon
10.5: Development of the Nervous System
differentiation
2.6: Cellular Differentiation
diffusion
2.2: The Cell Membrane
digastric
9.4: Axial Muscles of the Head, Neck, and Back
digestion
21.3: Digestive System Processes and Regulation
digital arteries
18.3: Circulatory Pathways
digital veins
18.3: Circulatory Pathways
dilation
24.5: Maternal Changes During Pregnancy, Labor, and Birth
dilator pupillae
13.3: Hearing and Balance
diploë
5.3: Bone Structure
diploid
2.5: Cell Growth and Division
Distal
1.4: Anatomical Terminology
distal radioulnar joint
6.7: Bones of the Upper Limb
distal tibiofibular joint
6.9: Bones of the Lower Limb
DNA Polymerase
2.4: The Nucleus
DNA replication
2.4: The Nucleus
Dorsal
1.4: Anatomical Terminology
dorsal (posterior) nerve root
12.4: Spinal Nerves and Their Branches
dorsal arch
18.3: Circulatory Pathways
dorsal cavity
1.4: Anatomical Terminology
dorsal column system
13.4: Vision
dorsal group
9.7: Appendicular Muscles of the Pelvic Girdle and Lower Limbs
dorsal longitudinal fasciculus
14.4: Central Control of Autonomic Function
dorsal motor nucleus
14.4: Central Control of Autonomic Function
dorsal ramus
12.4: Spinal Nerves and Their Branches
dorsal respiratory group (DRG)
20.4: Respiratory Zone
dorsal root ganglion
12.4: Spinal Nerves and Their Branches
dorsal venous arch
18.3: Circulatory Pathways
dorsalis pedis artery
18.3: Circulatory Pathways
dorsiflexion
7.4: Types of Body Movements
dorsum nasi
20.3: Conducting Zone
dual innervation
14.3: Autonomic Synapses and Effects
ductus arteriosus
18.4: Development of Blood Vessels and Fetal Circulation
24.4: Fetal Development
ductus deferens
23.2: Anatomy of the Male Reproductive System
ductus venosus
18.4: Development of Blood Vessels and Fetal Circulation
24.4: Fetal Development
duodenal gland
21.6: Small and Large Intestines
duodenum
21.6: Small and Large Intestines
dura mater
11.2: Support and Protection of the Brain
dural sinus
11.2: Support and Protection of the Brain

E

ear canal
13.3: Hearing and Balance
ear ossicles
6.2: Divisions of the Skeletal System
early induced immune response
19.4: Anatomy of Lymphatic Organs and Tissues
eccrine sweat gland
4.3: Accessory Structures of the Skin
ectoderm
24.3: Embryonic Development
3.2: Types of Tissues
ectopic pregnancy
24.3: Embryonic Development
eczema
4.5: Diseases, Disorders, and Injuries of the Integumentary System
edoderm
3.2: Types of Tissues
effector
10.2: Organization and Functions of the Nervous System
efferent
10.2: Organization and Functions of the Nervous System
efferent branch
14.3: Autonomic Synapses and Effects
efferent lymphatic vessels
19.3: Anatomy of Lymphatic Vessels
ejaculatory duct
23.2: Anatomy of the Male Reproductive System
elastic artery
18.2: Structure and Function of Blood Vessels
elastic cartilage
3.4: Connective Tissue
elastic fiber
3.4: Connective Tissue
elasticity
8.2: Muscle Tissues
elastin fibers
4.2: Layers of the Skin
elbow joint
6.7: Bones of the Upper Limb
7.5: Anatomy of Selected Synovial Joints

electrical gradient
2.2: The Cell Membrane

electrical synapse
10.4: Synapses

electrocardiogram (ECG)
17.3: Cardiac Muscle and Electrical Activity

eleiden
4.2: Layers of the Skin

elevation
7.4: Types of Body Movements

embryo
24.3: Embryonic Development

embryonic folding
24.3: Embryonic Development

emigration
16.4: Leukocytes and Platelets

enamel
21.4: Mouth, Pharynx, and Esophagus

encapsulated ending
13.2: Sensory Modalities and General Senses

end diastolic volume (EDV)
17.4: Coronary Circulation

end systolic volume (ESV)
17.4: Coronary Circulation

endocardial tubes
17.5: Development of the Heart

endocardium
17.2: Heart Anatomy

endochondral ossification
5.4: Bone Formation and Development

endocrine gland
15.2: An Overview of the Endocrine System
3.3: Epithelial Tissue

endocrine system
15: Endocrine System
15.2: An Overview of the Endocrine System

Endocrine Systems
15.1: Introduction to the Endocrine System

endocytosis
2.2: The Cell Membrane

endoderm
24.3: Embryonic Development

endolymph
13.3: Hearing and Balance

endolymphatic duct
13.3: Hearing and Balance

endometrium
23.3: Anatomy of the Female Reproductive System

endomysium
8.3: Skeletal Muscle Organ Structure

endoneurium
12.3: Cranial Nerves

Endoplasmic Reticulum (ER)
2.3: The Cytoplasm and Cellular Organelles

endosteum
5.3: Bone Structure

endothelium
17.2: Heart Anatomy
3.3: Epithelial Tissue

enteric nervous system (ENS)
10.2: Organization and Functions of the Nervous System

enteroendocrine cell
21.5: Stomach

enterohepatic circulation
21.7: Accessory Organs - Liver, Pancreas, and Gallbladder

enteropeptidase
21.7: Accessory Organs - Liver, Pancreas, and Gallbladder

eosinophils
16.4: Leukocytes and Platelets

ependymal cell
10.3: Anatomy of Nervous Tissue

epiblast
24.3: Embryonic Development

epicardial coronary arteries
17.2: Heart Anatomy

epicardium
17.2: Heart Anatomy

epicranial aponeurosis
9.4: Axial Muscles of the Head, Neck, and Back

epidermis
4.2: Layers of the Skin

epididymis
23.2: Anatomy of the Male Reproductive System

epidural space
11.2: Support and Protection of the Brain

epiglottis
20.3: Conducting Zone

epimysium
8.3: Skeletal Muscle Organ Structure

epinephrine
14.2: Divisions of the Autonomic Nervous System
14.3: Autonomic Synapses and Effects
15.5: Adrenal Glands

epineurium
12.3: Cranial Nerves

epiphyseal line
5.4: Bone Formation and Development

epiphyseal plate
5.3: Bone Structure

epiphysis
5.3: Bone Structure

epiploic appendage
21.6: Small and Large Intestines

episiotomy
24.5: Maternal Changes During Pregnancy, Labor, and Birth

epithalamus
11.4: Brain - Diencephalon, Brainstem, Cerebellum and Limbic System

epithelial membrane
3.2: Types of Tissues

epithelial tissue
3.2: Types of Tissues

eponychium
4.3: Accessory Structures of the Skin

equilibrium
13.3: Hearing and Balance

erector spinae group
9.4: Axial Muscles of the Head, Neck, and Back

erythrocyte
16.3: Erythrocytes

erythropoietin (EPO)
15.9: Organs with Secondary Endocrine Functions
16.5: Production of the Formed Elements

esophageal artery
18.3: Circulatory Pathways

esophageal vein
18.3: Circulatory Pathways

esophagus
21.4: Mouth, Pharynx, and Esophagus

estrogens
15.7: Gonadal and Placental Hormones

ethmoid air cell
6.3: The Skull

Eustachian tube
13.3: Hearing and Balance

eversion
7.4: Types of Body Movements

excitability
8.2: Muscle Tissues

executive functions
13.5: Taste and Smell

exocrine gland
3.3: Epithelial Tissue

exocrine system
15.2: An Overview of the Endocrine System

exocytosis
2.2: The Cell Membrane

expiration
20.4: Respiratory Zone

expiratory reserve volume (ERV)
20.4: Respiratory Zone

expressive aphasia
11.3: Brain - Cerebrum

expulsion
24.5: Maternal Changes During Pregnancy, Labor, and Birth

extensibility
8.2: Muscle Tissues

extension
7.4: Types of Body Movements

extensor
9.3: Naming Skeletal Muscles

extensor carpi radialis brevis
9.6: Appendicular Muscles of the Pectoral Girdle and Upper Limbs

extensor carpi ulnaris
9.6: Appendicular Muscles of the Pectoral Girdle and Upper Limbs

extensor digiti minimi
9.6: Appendicular Muscles of the Pectoral Girdle and Upper Limbs

extensor digitorum
9.6: Appendicular Muscles of the Pectoral Girdle and Upper Limbs

extensor digitorum brevis
9.7: Appendicular Muscles of the Pelvic Girdle and Lower Limbs

extensor digitorum longus
9.7: Appendicular Muscles of the Pelvic Girdle and Lower Limbs

extensor hallucis longus
9.7: Appendicular Muscles of the Pelvic Girdle and Lower Limbs

extensor indicis
9.6: Appendicular Muscles of the Pectoral Girdle and Upper Limbs

extensor pollicis brevis
9.6: Appendicular Muscles of the Pectoral Girdle and Upper Limbs

extensor pollicis longus
9.6: Appendicular Muscles of the Pectoral Girdle and Upper Limbs
extensor radialis longus
9.6: Appendicular Muscles of the Pectoral Girdle and Upper Limbs
extensor retinaculum
9.6: Appendicular Muscles of the Pectoral Girdle and Upper Limbs
external acoustic meatus
6.3: The Skull
external anal sphincter
21.6: Small and Large Intestines
external callus
5.5: Fractures and Bone Repair
external carotid artery
18.3: Circulatory Pathways
external ear
13.3: Hearing and Balance
external elastic membrane
18.2: Structure and Function of Blood Vessels
external iliac artery
18.3: Circulatory Pathways
external iliac vein
18.3: Circulatory Pathways
external intercostal
9.5: Axial Muscles of the Abdominal Wall and Thorax
external jugular vein
18.3: Circulatory Pathways
external nose
20.3: Conducting Zone
external oblique
9.5: Axial Muscles of the Abdominal Wall and Thorax
external occipital protuberance
6.3: The Skull
external root sheath
4.3: Accessory Structures of the Skin
external urinary sphincter
22.4: Urinary Tract
exteroceptor
13.2: Sensory Modalities and General Senses
extracellular fluid (ECF)
2.2: The Cell Membrane
extraocular muscles
13.3: Hearing and Balance
extrapyramidal system
13.5: Taste and Smell
extrinsic eye muscles
9.4: Axial Muscles of the Head, Neck, and Back
extrinsic ligament
7.3: Synovial Joints
extrinsic muscles of the hand
9.6: Appendicular Muscles of the Pectoral Girdle and Upper Limbs

F

facet
6.4: The Vertebral Column
facial bones
6.3: The Skull
facial nerve
12.3: Cranial Nerves
facial nerve (VII)
14.2: Divisions of the Autonomic Nervous System
facilitated diffusion
2.2: The Cell Membrane
false ribs
6.5: The Thoracic Cage
falx cerebelli
11.2: Support and Protection of the Brain
falx cerebri
11.2: Support and Protection of the Brain
fas ligand
19.4: Anatomy of Lymphatic Organs and Tissues
fascicle
12.3: Cranial Nerves
8.3: Skeletal Muscle Organ Structure
9.2: Interactions of Skeletal Muscles, Their Fascicle Arrangement, and Their Lever Systems
fasciculus cuneatus
13.4: Vision
fasciculus gracilis
13.4: Vision
fauces
20.3: Conducting Zone
21.4: Mouth, Pharynx, and Esophagus
feces
21.6: Small and Large Intestines
femoral artery
18.3: Circulatory Pathways
femoral circumflex vein
18.3: Circulatory Pathways
femoral nerve
12.4: Spinal Nerves and Their Branches
femoral triangle
9.7: Appendicular Muscles of the Pelvic Girdle and Lower Limbs
femoral vein
18.3: Circulatory Pathways
femoropatellar joint
7.5: Anatomy of Selected Synovial Joints
femur
6.9: Bones of the Lower Limb
fenestrated capillary
18.2: Structure and Function of Blood Vessels
fenestrations
22.3: Microscopic Anatomy of the Kidney
ferritin
16.3: Erythrocytes
fertilization
24.2: Fertilization
fertilization membrane
24.2: Fertilization
fetus
24.3: Embryonic Development
fibrinogen
16.2: An Overview of Blood
fibroblast
3.4: Connective Tissue
fibrocartilage
3.4: Connective Tissue
fibrocyte
3.4: Connective Tissue
fibroelastic membrane
20.3: Conducting Zone
fibrosis
8.4: Development and Regeneration of Muscle Tissue
fibrous joint
7.2: Classification of Joints
fibrous tunic
13.3: Hearing and Balance
fibula
6.9: Bones of the Lower Limb
fibular collateral ligament
7.5: Anatomy of Selected Synovial Joints
fibular nerve
12.4: Spinal Nerves and Their Branches
fibular notch
6.9: Bones of the Lower Limb
fibular vein
18.3: Circulatory Pathways
fibularis brevis
9.7: Appendicular Muscles of the Pelvic Girdle and Lower Limbs
fibularis longus
9.7: Appendicular Muscles of the Pelvic Girdle and Lower Limbs
fibularis tertius
9.7: Appendicular Muscles of the Pelvic Girdle and Lower Limbs
filtration slits
22.3: Microscopic Anatomy of the Kidney
fimbriae
23.3: Anatomy of the Female Reproductive System
flagellum
2.3: The Cytoplasm and Cellular Organelles
flat bone
5.7: Bone Classification
flatus
21.6: Small and Large Intestines
flexion
7.4: Types of Body Movements
9.2: Interactions of Skeletal Muscles, Their Fascicle Arrangement, and Their Lever Systems
flexor
9.3: Naming Skeletal Muscles
flexor carpi radialis
9.6: Appendicular Muscles of the Pectoral Girdle and Upper Limbs
flexor carpi ulnaris
9.6: Appendicular Muscles of the Pectoral Girdle and Upper Limbs
flexor digiti minimi brevis
9.6: Appendicular Muscles of the Pectoral Girdle and Upper Limbs
flexor digitorum longus
9.7: Appendicular Muscles of the Pelvic Girdle and Lower Limbs
flexor digitorum profundus
9.6: Appendicular Muscles of the Pectoral Girdle and Upper Limbs
flexor digitorum superficialis
9.6: Appendicular Muscles of the Pectoral Girdle and Upper Limbs
flexor hallucis longus
9.7: Appendicular Muscles of the Pelvic Girdle and Lower Limbs
flexor pollicis brevis
9.6: Appendicular Muscles of the Pectoral Girdle and Upper Limbs

flexor pollicis longus
9.6: Appendicular Muscles of the Pectoral Girdle and Upper Limbs
flexor retinaculum
6.7: Bones of the Upper Limb
9.6: Appendicular Muscles of the Pectoral Girdle and Upper Limbs
floating ribs
6.5: The Thoracic Cage
fluid connective tissue
3.4: Connective Tissue
folia
11.4: Brain - Diencephalon, Brainstem, Cerebellum and Limbic System
follicle
23.3: Anatomy of the Female Reproductive System
folliculogenesis
23.3: Anatomy of the Female Reproductive System
fontanelle
6.10: Embryonic Development of the Skeleton
foot
6.9: Bones of the Lower Limb
foramen magnum
6.3: The Skull
foramen ovale
17.2: Heart Anatomy
18.4: Development of Blood Vessels and Fetal Circulation
24.4: Fetal Development
foramen ovale of the middle cranial fossa
6.3: The Skull
foramen rotundum
6.3: The Skull
foramen spinosum
6.3: The Skull
forced breathing
20.4: Respiratory Zone
forearm
6.7: Bones of the Upper Limb
forebrain
10.5: Development of the Nervous System
foregut
20.5: Embryonic Development of the Respiratory System
foremilk
24.7: Lactation
formed elements
16.2: An Overview of Blood
forming urine
22.3: Microscopic Anatomy of the Kidney
fossa
6.6: The Pectoral Girdle
fossa ovalis
17.2: Heart Anatomy
fourth ventricle
11.2: Support and Protection of the Brain
fovea
13.3: Hearing and Balance
fovea capitis
6.9: Bones of the Lower Limb
fracture
5.5: Fractures and Bone Repair
fracture hematoma
5.5: Fractures and Bone Repair
free nerve ending
13.2: Sensory Modalities and General Senses
frontal bone
6.3: The Skull
frontal eye field
11.3: Brain - Cerebrum
frontal eye fields
13.5: Taste and Smell
frontal plane
1.4: Anatomical Terminology
frontal sinus
6.3: The Skull
frontalis
9.4: Axial Muscles of the Head, Neck, and Back
functional residual capacity (FRC)
20.4: Respiratory Zone
fundus
21.5: Stomach
23.3: Anatomy of the Female Reproductive System
fusiform
9.2: Interactions of Skeletal Muscles, Their Fascicle Arrangement, and Their Lever Systems

G

G cell
21.5: Stomach
G0 phase
2.5: Cell Growth and Division
G1 phase
2.5: Cell Growth and Division
G2 phase
2.5: Cell Growth and Division
gamete
23.2: Anatomy of the Male Reproductive System
ganglion
10.2: Organization and Functions of the Nervous System
ganglionic neuron
14.2: Divisions of the Autonomic Nervous System
gap junction
3.3: Epithelial Tissue
gastric emptying
21.5: Stomach
gastric gland
21.5: Stomach
gastric phase
21.5: Stomach
gastric pit
21.5: Stomach
gastrin
21.5: Stomach
gastrocnemius
9.7: Appendicular Muscles of the Pelvic Girdle and Lower Limbs
gastrocolic reflex
21.6: Small and Large Intestines
gastroileal reflex
21.6: Small and Large Intestines
gastrulation
24.3: Embryonic Development
general adaptation syndrome (GAS)
15.5: Adrenal Glands
general sense
10.2: Organization and Functions of the Nervous System
13.2: Sensory Modalities and General Senses
genicular artery
18.3: Circulatory Pathways
genioglossus
9.4: Axial Muscles of the Head, Neck, and Back
geniohyoid
9.4: Axial Muscles of the Head, Neck, and Back
genome
2.4: The Nucleus
germinal centers
19.3: Anatomy of Lymphatic Vessels
gestation
24.3: Embryonic Development
gigantism
15.3: Pituitary Gland and Hypothalamus
gingiva
21.4: Mouth, Pharynx, and Esophagus
glabella
6.3: The Skull
glans penis
23.2: Anatomy of the Male Reproductive System
glassy membrane
4.3: Accessory Structures of the Skin
glenohumeral joint
6.6: The Pectoral Girdle
7.5: Anatomy of Selected Synovial Joints
glenohumeral ligament
7.5: Anatomy of Selected Synovial Joints
glenoid cavity
6.6: The Pectoral Girdle
glenoid labrum
7.5: Anatomy of Selected Synovial Joints
glial cell
10.2: Organization and Functions of the Nervous System
globin
16.3: Erythrocytes
globulins
16.2: An Overview of Blood
globus pallidus
11.3: Brain - Cerebrum
glossopharyngeal nerve
12.3: Cranial Nerves
glossopharyngeal nerve (CN IX)
14.2: Divisions of the Autonomic Nervous System
glottis
20.3: Conducting Zone
glucagon
15.8: Endocrine Pancreas
glucocorticoids
15.5: Adrenal Glands
gluteal group
9.7: Appendicular Muscles of the Pelvic Girdle and Lower Limbs
gluteal tuberosity
6.9: Bones of the Lower Limb
gluteus maximus
9.7: Appendicular Muscles of the Pelvic Girdle and Lower Limbs

gluteus medius
9.7: Appendicular Muscles of the Pelvic Girdle and Lower Limbs
gluteus minimus
9.7: Appendicular Muscles of the Pelvic Girdle and Lower Limbs
Glycocalyx
2.2: The Cell Membrane
gnostic area
11.3: Brain - Cerebrum
goblet cell
3.3: Epithelial Tissue
goiter
15.4: Thyroid Gland and Parathyroid Glands
Golgi apparatus
2.3: The Cytoplasm and Cellular Organelles
gonadal artery
18.3: Circulatory Pathways
gonadal vein
18.3: Circulatory Pathways
gonadotropins
15.3: Pituitary Gland and Hypothalamus
gonads
23.2: Anatomy of the Male Reproductive System
gracilis
9.7: Appendicular Muscles of the Pelvic Girdle and Lower Limbs
granular leukocytes
16.4: Leukocytes and Platelets
granulosa cells
23.3: Anatomy of the Female Reproductive System
granzyme
19.4: Anatomy of Lymphatic Organs and Tissues
gray matter
10.2: Organization and Functions of the Nervous System
gray rami communicantes
14.2: Divisions of the Autonomic Nervous System
great cardiac vein
17.2: Heart Anatomy
great cerebral vein
18.3: Circulatory Pathways
great saphenous vein
18.3: Circulatory Pathways
greater splanchnic nerve
14.2: Divisions of the Autonomic Nervous System
greater trochanter
6.9: Bones of the Lower Limb
greater tubercle
6.7: Bones of the Upper Limb
greater wings of sphenoid bone
6.3: The Skull
ground substance
3.4: Connective Tissue
growth hormone (GH)
15.3: Pituitary Gland and Hypothalamus
gyrus
11.3: Brain - Cerebrum

H

hair
4.3: Accessory Structures of the Skin
hair bulb
4.3: Accessory Structures of the Skin
hair cells
13.3: Hearing and Balance
hair follicle
4.3: Accessory Structures of the Skin
hair matrix
4.3: Accessory Structures of the Skin
hair papilla
4.3: Accessory Structures of the Skin
hair root
4.3: Accessory Structures of the Skin
hair shaft
4.3: Accessory Structures of the Skin
hallux
6.9: Bones of the Lower Limb
hamate
6.7: Bones of the Upper Limb
hamstring group
9.7: Appendicular Muscles of the Pelvic Girdle and Lower Limbs
hand
6.7: Bones of the Upper Limb
hard palate
6.3: The Skull
haustral contraction
21.6: Small and Large Intestines
haustrum
21.6: Small and Large Intestines
head of the femur
6.9: Bones of the Lower Limb
head of the fibula
6.9: Bones of the Lower Limb
head of the humerus
6.7: Bones of the Upper Limb
head of the metatarsal bone
6.9: Bones of the Lower Limb
head of the radius
6.7: Bones of the Upper Limb
head of the rib
6.5: The Thoracic Cage
Head of the ulna
6.7: Bones of the Upper Limb
heart block
17.3: Cardiac Muscle and Electrical Activity
heart bulge
17.5: Development of the Heart
heart sounds
17.4: Coronary Circulation
helicase
2.4: The Nucleus
hemangioblasts
18.4: Development of Blood Vessels and Fetal Circulation
hematocrit
16.2: An Overview of Blood
hematopoiesis
16.5: Production of the Formed Elements
5.2: Functions of the Skeletal System
heme
16.3: Erythrocytes
hemiazygos vein
18.3: Circulatory Pathways
hemocytoblast
16.5: Production of the Formed Elements
hemoglobin
16.3: Erythrocytes
hemopoiesis
16.5: Production of the Formed Elements
hemopoietic growth factors
16.5: Production of the Formed Elements
hemopoietic stem cell
16.5: Production of the Formed Elements
hemosiderin
16.3: Erythrocytes
hepatic artery
21.7: Accessory Organs - Liver, Pancreas, and Gallbladder
hepatic artery proper
18.3: Circulatory Pathways
hepatic lobule
21.7: Accessory Organs - Liver, Pancreas, and Gallbladder
hepatic portal system
18.3: Circulatory Pathways
hepatic portal vein
21.7: Accessory Organs - Liver, Pancreas, and Gallbladder
hepatic sinusoid
21.7: Accessory Organs - Liver, Pancreas, and Gallbladder
hepatic vein
18.3: Circulatory Pathways
21.7: Accessory Organs - Liver, Pancreas, and Gallbladder
hepatocytes
21.7: Accessory Organs - Liver, Pancreas, and Gallbladder
hepatopancreatic ampulla
21.6: Small and Large Intestines
hepatopancreatic sphincter
21.6: Small and Large Intestines
high endothelial venules
19.3: Anatomy of Lymphatic Vessels
hilum
20.2: The Lungs
hindbrain
10.5: Development of the Nervous System
hindmilk
24.7: Lactation
hinge joint
7.3: Synovial Joints
hip joint
6.9: Bones of the Lower Limb
hippocampus
11.4: Brain - Diencephalon, Brainstem, Cerebellum and Limbic System
histamine
19.4: Anatomy of Lymphatic Organs and Tissues
3.7: Tissue Injury and Aging
histology
3.2: Types of Tissues
histone
2.4: The Nucleus
hole
5.3: Bone Structure
holocrine secretion
3.3: Epithelial Tissue
homeostasis
1.2: Overview of Anatomy

homologous
2.5: Cell Growth and Division
hook of the hamate bone
6.7: Bones of the Upper Limb
horizontal cell
13.3: Hearing and Balance
horizontal plate
6.3: The Skull
hormone
15.2: An Overview of the Endocrine System
human chorionic gonadotropin (hCG)
24.3: Embryonic Development
humeroradial joint
7.5: Anatomy of Selected Synovial Joints
humeroulnar joint
7.5: Anatomy of Selected Synovial Joints
humerus
6.7: Bones of the Upper Limb
hyaline cartilage
3.4: Connective Tissue
hydrochloric acid (HCl)
21.5: Stomach
hydrophilic
2.2: The Cell Membrane
hydrophobic
2.2: The Cell Membrane
hymen
23.3: Anatomy of the Female Reproductive System
hyoglossus
9.4: Axial Muscles of the Head, Neck, and Back
hyoid bone
6.2: Divisions of the Skeletal System
hyperextension
7.4: Types of Body Movements
hyperflexion
7.4: Types of Body Movements
hyperglycemia
15.8: Endocrine Pancreas
hypertonic
2.2: The Cell Membrane
hypertrophic cardiomyopathy
17.2: Heart Anatomy
hypoblast
24.3: Embryonic Development
hypodermis
4.2: Layers of the Skin
hypoglossal canal
6.3: The Skull
hypoglossal nerve
12.3: Cranial Nerves
hyponychium
4.3: Accessory Structures of the Skin
hypophyseal (pituitary) fossa
6.3: The Skull
hypophyseal portal system
15.3: Pituitary Gland and Hypothalamus
hypothalamus
11.4: Brain - Diencephalon, Brainstem, Cerebellum and Limbic System
13.4: Vision
14.4: Central Control of Autonomic Function
15.3: Pituitary Gland and Hypothalamus
hypothyroidism
15.4: Thyroid Gland and Parathyroid Glands
hypotonic
2.2: The Cell Membrane
hypoxemia
16.3: Erythrocytes

I

ileocecal sphincter
21.6: Small and Large Intestines
Ileum
21.6: Small and Large Intestines
iliacus
9.7: Appendicular Muscles of the Pelvic Girdle and Lower Limbs
iliococcygeus
9.5: Axial Muscles of the Abdominal Wall and Thorax
iliocostalis cervicis
9.4: Axial Muscles of the Head, Neck, and Back
iliocostalis group
9.4: Axial Muscles of the Head, Neck, and Back
iliocostalis lumborum
9.4: Axial Muscles of the Head, Neck, and Back
iliocostalis thoracis
9.4: Axial Muscles of the Head, Neck, and Back
iliofemoral ligament
7.5: Anatomy of Selected Synovial Joints
iliopsoas group
9.7: Appendicular Muscles of the Pelvic Girdle and Lower Limbs
iliotibial tract
9.7: Appendicular Muscles of the Pelvic Girdle and Lower Limbs
immune system
19.3: Anatomy of Lymphatic Vessels
immunoglobulins
16.2: An Overview of Blood
implantation
24.3: Embryonic Development
incisor
21.4: Mouth, Pharynx, and Esophagus
incontinence
22.4: Urinary Tract
incus
13.3: Hearing and Balance
inferior
1.4: Anatomical Terminology
inferior angle of the scapula
6.6: The Pectoral Girdle
inferior articular process
6.4: The Vertebral Column
inferior cerebellar peduncle
11.4: Brain - Diencephalon, Brainstem, Cerebellum and Limbic System
inferior cervical ganglion
14.2: Divisions of the Autonomic Nervous System
inferior colliculus
11.4: Brain - Diencephalon, Brainstem, Cerebellum and Limbic System
13.4: Vision
inferior extensor retinaculum
9.7: Appendicular Muscles of the Pelvic Girdle and Lower Limbs
inferior gemellus
9.7: Appendicular Muscles of the Pelvic Girdle and Lower Limbs
inferior mesenteric artery
18.3: Circulatory Pathways
inferior mesenteric ganglion
14.2: Divisions of the Autonomic Nervous System
inferior nasal concha
6.3: The Skull
inferior oblique
13.3: Hearing and Balance
inferior olive
11.4: Brain - Diencephalon, Brainstem, Cerebellum and Limbic System
inferior phrenic artery
18.3: Circulatory Pathways
inferior rectus
13.3: Hearing and Balance
inferior rotation
7.4: Types of Body Movements
inferior vena cava
17.2: Heart Anatomy
18.3: Circulatory Pathways
inflammation
19.4: Anatomy of Lymphatic Organs and Tissues
3.7: Tissue Injury and Aging
infraglenoid fossa
6.6: The Pectoral Girdle
infraglenoid tubercle
6.6: The Pectoral Girdle
infrahyoid muscles
9.4: Axial Muscles of the Head, Neck, and Back
infraorbital foramen
6.3: The Skull
infraspinatus
9.6: Appendicular Muscles of the Pectoral Girdle and Upper Limbs
infraspinous fossa
6.6: The Pectoral Girdle
infratemporal fossa
6.3: The Skull
infundibulum
15.3: Pituitary Gland and Hypothalamus
23.3: Anatomy of the Female Reproductive System
ingestion
21.3: Digestive System Processes and Regulation
inguinal canal
23.2: Anatomy of the Male Reproductive System
inhibin
15.7: Gonadal and Placental Hormones
innate immune response
19.3: Anatomy of Lymphatic Vessels
inner cell mass
24.3: Embryonic Development
inner ear
13.3: Hearing and Balance
innermost intercostal
9.5: Axial Muscles of the Abdominal Wall and Thorax
insertion
9.2: Interactions of Skeletal Muscles, Their Fascicle Arrangement, and Their Lever Systems
inspiration
20.4: Respiratory Zone
inspiratory capacity (IC)
20.4: Respiratory Zone

inspiratory reserve volume (IRV)
20.4: Respiratory Zone

insula
11.3: Brain - Cerebrum

insulin
15.8: Endocrine Pancreas

integral protein
2.2: The Cell Membrane

integration
10.2: Organization and Functions of the Nervous System

integumentary system
4: Integumentary System
4.2: Layers of the Skin

interatrial band
17.3: Cardiac Muscle and Electrical Activity

interatrial septum
17.2: Heart Anatomy

intercalated disc
17.3: Cardiac Muscle and Electrical Activity

intercondylar eminence
6.9: Bones of the Lower Limb

intercondylar fossa
6.9: Bones of the Lower Limb

intercostal artery
18.3: Circulatory Pathways

intercostal muscles
9.5: Axial Muscles of the Abdominal Wall and Thorax

intercostal nerves
12.4: Spinal Nerves and Their Branches

intercostal vein
18.3: Circulatory Pathways

interferons
19.4: Anatomy of Lymphatic Organs and Tissues

interleukins
16.5: Production of the Formed Elements

intermediate cuneiform
6.9: Bones of the Lower Limb

intermediate filament
2.3: The Cytoplasm and Cellular Organelles

internal anal sphincter
21.6: Small and Large Intestines

internal callus
5.5: Fractures and Bone Repair

internal capsule
13.5: Taste and Smell

internal carotid artery
11.2: Support and Protection of the Brain
18.3: Circulatory Pathways

internal elastic membrane
18.2: Structure and Function of Blood Vessels

internal iliac artery
18.3: Circulatory Pathways

internal iliac vein
18.3: Circulatory Pathways

internal intercostal
9.5: Axial Muscles of the Abdominal Wall and Thorax

internal jugular vein
18.3: Circulatory Pathways

internal oblique
9.5: Axial Muscles of the Abdominal Wall and Thorax

internal root sheath
4.3: Accessory Structures of the Skin

internal thoracic artery
18.3: Circulatory Pathways

internal thoracic vein
18.3: Circulatory Pathways

internal urinary sphincter
22.4: Urinary Tract

interneuron
10.3: Anatomy of Nervous Tissue

internodal pathways
17.3: Cardiac Muscle and Electrical Activity

interoceptor
13.2: Sensory Modalities and General Senses

interosseous border of the fibula
6.9: Bones of the Lower Limb

interosseous border of the radius
6.7: Bones of the Upper Limb

interosseous border of the tibia
6.9: Bones of the Lower Limb

interosseous border of the ulna
6.7: Bones of the Upper Limb

interosseous membrane of the forearm
6.7: Bones of the Upper Limb

interosseous membrane of the leg
6.9: Bones of the Lower Limb

interphalangeal joint
6.7: Bones of the Upper Limb

interphase
2.5: Cell Growth and Division

interstitial fluid (IF)
2.2: The Cell Membrane

interthalamic adhesion
11.4: Brain - Diencephalon, Brainstem, Cerebellum and Limbic System

intertrochanteric crest
6.9: Bones of the Lower Limb

intertrochanteric line
6.9: Bones of the Lower Limb

intertubercular groove (sulcus)
6.7: Bones of the Upper Limb

interventricular foramina
11.2: Support and Protection of the Brain

interventricular septum
17.2: Heart Anatomy

intervertebral disc
6.4: The Vertebral Column

intervertebral foramen
6.4: The Vertebral Column

intestinal gland
21.6: Small and Large Intestines

intestinal juice
21.6: Small and Large Intestines

intestinal phase
21.5: Stomach

intracapsular ligament
7.3: Synovial Joints

intracellular fluid (ICF)
2.2: The Cell Membrane

intramembranous ossification
5.4: Bone Formation and Development

intramural ganglia
14.2: Divisions of the Autonomic Nervous System

intrapleural pressure
20.4: Respiratory Zone

intrinsic factor
21.5: Stomach

intrinsic ligament
7.3: Synovial Joints

intrinsic muscles of the hand
9.6: Appendicular Muscles of the Pectoral Girdle and Upper Limbs

inversion
7.4: Types of Body Movements

involution
24.5: Maternal Changes During Pregnancy, Labor, and Birth

ipsilateral
13.4: Vision

iris
13.3: Hearing and Balance

irregular bone
5.7: Bone Classification

ischiococcygeus
9.5: Axial Muscles of the Abdominal Wall and Thorax

ischiofemoral ligament
7.5: Anatomy of Selected Synovial Joints

Islets of Langerhans
15.8: Endocrine Pancreas

isotonic
2.2: The Cell Membrane

isovolumic contraction
17.4: Coronary Circulation

isovolumic ventricular relaxation phase
17.4: Coronary Circulation

isthmus
23.3: Anatomy of the Female Reproductive System

J

jejunum
21.6: Small and Large Intestines

joint
7.2: Classification of Joints

joint cavity
7.2: Classification of Joints

jugular (suprasternal) notch
6.5: The Thoracic Cage

jugular foramen
6.3: The Skull

jugular veins
11.2: Support and Protection of the Brain

juxtaglomerular apparatus (JGA)
22.3: Microscopic Anatomy of the Kidney

juxtaglomerular cell
22.3: Microscopic Anatomy of the Kidney

K

keratin
4.2: Layers of the Skin

keratinocyte
4.2: Layers of the Skin

keratohyalin
4.2: Layers of the Skin

kinesthesia
13.2: Sensory Modalities and General Senses

kinetochore
2.5: Cell Growth and Division

knee joint
6.9: Bones of the Lower Limb
kyphosis
6.4: The Vertebral Column

L

labia majora
23.3: Anatomy of the Female Reproductive System
labia minora
23.3: Anatomy of the Female Reproductive System
labial frenulum
21.4: Mouth, Pharynx, and Esophagus
labium
21.4: Mouth, Pharynx, and Esophagus
lacrimal bone
6.3: The Skull
lacrimal canaliculus
13.3: Hearing and Balance
lacrimal fossa
6.3: The Skull
lacrimal gland
13.3: Hearing and Balance
lacrimal punctum
13.3: Hearing and Balance
lacrimal sac
13.3: Hearing and Balance
lactation
24.7: Lactation
lacteal
21.6: Small and Large Intestines
lactiferous ducts
23.3: Anatomy of the Female Reproductive System
lactiferous sinus
23.3: Anatomy of the Female Reproductive System
lacunae
3.4: Connective Tissue
lambdoid suture
6.3: The Skull
lamina
6.4: The Vertebral Column
lamina propria
3.2: Types of Tissues
Langerhans cell
4.2: Layers of the Skin
lanugo
24.4: Fetal Development
large intestine
21.6: Small and Large Intestines
laryngeal prominence
20.3: Conducting Zone
laryngopharynx
20.3: Conducting Zone
21.4: Mouth, Pharynx, and Esophagus
laryngotracheal
20.5: Embryonic Development of the Respiratory System
larynx
20.3: Conducting Zone
lateral
1.4: Anatomical Terminology
lateral (external) rotation
7.4: Types of Body Movements
lateral apertures
11.2: Support and Protection of the Brain
lateral border of the scapula
6.6: The Pectoral Girdle
lateral circumflex artery
18.3: Circulatory Pathways
lateral compartment of the leg
9.7: Appendicular Muscles of the Pelvic Girdle and Lower Limbs
lateral condyle of the femur
6.9: Bones of the Lower Limb
lateral condyle of the tibia
6.9: Bones of the Lower Limb
lateral corticospinal tract
13.5: Taste and Smell
lateral cuneiform
6.9: Bones of the Lower Limb
lateral epicondyle of the femur
6.9: Bones of the Lower Limb
lateral epicondyle of the humerus
6.7: Bones of the Upper Limb
lateral excursion
7.4: Types of Body Movements
lateral flexion
7.4: Types of Body Movements
lateral geniculate nucleus
13.4: Vision
lateral group of nuclei
13.4: Vision
lateral malleolus
6.9: Bones of the Lower Limb
lateral meniscus
7.5: Anatomy of Selected Synovial Joints
lateral plantar artery
18.3: Circulatory Pathways
lateral pterygoid
9.4: Axial Muscles of the Head, Neck, and Back
lateral pterygoid plate
6.3: The Skull
lateral rectus
13.3: Hearing and Balance
lateral sacral crest
6.4: The Vertebral Column
lateral sulcus
11.3: Brain - Cerebrum
lateral supracondylar ridge
6.7: Bones of the Upper Limb
lateral tibiofemoral joint
7.5: Anatomy of Selected Synovial Joints
lateral ventricles
11.2: Support and Protection of the Brain
lateralis
9.3: Naming Skeletal Muscles
lateralization of function
11.3: Brain - Cerebrum
latissimus dorsi
9.6: Appendicular Muscles of the Pectoral Girdle and Upper Limbs
least splanchnic nerve
14.2: Divisions of the Autonomic Nervous System
left atrioventricular valve
17.2: Heart Anatomy
left colic flexure
21.6: Small and Large Intestines
left gastric artery
18.3: Circulatory Pathways
leg
6.9: Bones of the Lower Limb
lens
13.3: Hearing and Balance
leptin
15.9: Organs with Secondary Endocrine Functions
lesser splanchnic nerve
14.2: Divisions of the Autonomic Nervous System
lesser trochanter
6.9: Bones of the Lower Limb
lesser tubercle
6.7: Bones of the Upper Limb
lesser wings of the sphenoid bone
6.3: The Skull
leukemia
16.4: Leukocytes and Platelets
leukocyte
16.4: Leukocytes and Platelets
leukocytosis
16.4: Leukocytes and Platelets
leukopenia
16.4: Leukocytes and Platelets
levator ani
9.5: Axial Muscles of the Abdominal Wall and Thorax
levator palpebrae superioris
13.3: Hearing and Balance
Leydig cells
23.2: Anatomy of the Male Reproductive System
ligament of the head of the femur
6.9: Bones of the Lower Limb
7.5: Anatomy of Selected Synovial Joints
ligamentum flavum
6.4: The Vertebral Column
ligand
2.2: The Cell Membrane
lightening
24.5: Maternal Changes During Pregnancy, Labor, and Birth
limbic lobe
14.4: Central Control of Autonomic Function
limbic system
11.4: Brain - Diencephalon, Brainstem, Cerebellum and Limbic System
linea alba
9.5: Axial Muscles of the Abdominal Wall and Thorax
linea aspera
6.9: Bones of the Lower Limb
lingual frenulum
21.4: Mouth, Pharynx, and Esophagus
lingual lipase
21.4: Mouth, Pharynx, and Esophagus
lingual tonsil
20.3: Conducting Zone
lingula
6.3: The Skull
liver
21.7: Accessory Organs - Liver, Pancreas, and Gallbladder

lochia
24.5: Maternal Changes During Pregnancy, Labor, and Birth
long bone
5.7: Bone Classification
long reflex
14.3: Autonomic Synapses and Effects
longissimus capitis
9.4: Axial Muscles of the Head, Neck, and Back
longissimus group
9.4: Axial Muscles of the Head, Neck, and Back
longissimus thoracis
9.4: Axial Muscles of the Head, Neck, and Back
longitudinal fasciculi
11.3: Brain - Cerebrum
longitudinal fissure
11.3: Brain - Cerebrum
longus
9.3: Naming Skeletal Muscles
loose connective tissue
3.4: Connective Tissue
lordosis
6.4: The Vertebral Column
lower esophageal sphincter
21.4: Mouth, Pharynx, and Esophagus
lucunae
5.3: Bone Structure
lumbar arteries
18.3: Circulatory Pathways
lumbar curve
6.4: The Vertebral Column
lumbar enlargement
13.5: Taste and Smell
lumbar plexus
12.4: Spinal Nerves and Their Branches
lumbar splanchnic nerve
14.2: Divisions of the Autonomic Nervous System
lumbar veins
18.3: Circulatory Pathways
lumbar vertebrae
6.4: The Vertebral Column
Lumen
18.2: Structure and Function of Blood Vessels
lunate
6.7: Bones of the Upper Limb
lung
20.2: The Lungs
lung bud
20.5: Embryonic Development of the Respiratory System
lunula
4.3: Accessory Structures of the Skin
luteinizing hormone (LH)
15.3: Pituitary Gland and Hypothalamus
lymph
19.3: Anatomy of Lymphatic Vessels
lymph node
19.3: Anatomy of Lymphatic Vessels
lymphatic capillaries
19.3: Anatomy of Lymphatic Vessels
lymphatic system
19.3: Anatomy of Lymphatic Vessels
lymphatic trunks
19.3: Anatomy of Lymphatic Vessels
lymphocytes
16.4: Leukocytes and Platelets
19.3: Anatomy of Lymphatic Vessels
lymphoid nodules
19.3: Anatomy of Lymphatic Vessels
lymphoid stem cells
16.5: Production of the Formed Elements
lymphoma
16.4: Leukocytes and Platelets
lysosome
2.3: The Cytoplasm and Cellular Organelles
Lysozyme
16.4: Leukocytes and Platelets

M

macrophage
16.3: Erythrocytes
19.4: Anatomy of Lymphatic Organs and Tissues
macrophage oxidative metabolism
19.2: Functions of the Lymphatic System
macula
13.3: Hearing and Balance
macula densa
22.3: Microscopic Anatomy of the Kidney
macula lutea
13.3: Hearing and Balance
Magnetic Resonance Imaging (MRI)
1.5: Medical Imaging
main pancreatic duct
21.6: Small and Large Intestines
major duodenal papilla
21.6: Small and Large Intestines
malleus
13.3: Hearing and Balance
mammary glands
23.3: Anatomy of the Female Reproductive System
mammillary bodies
11.4: Brain - Diencephalon, Brainstem, Cerebellum and Limbic System
mandible
6.3: The Skull
mandibular foramen
6.3: The Skull
mandibular fossa
6.3: The Skull
mandibular notch
6.3: The Skull
manubrium
6.5: The Thoracic Cage
marginal arteries
17.2: Heart Anatomy
mass movement
21.6: Small and Large Intestines
masseter
9.4: Axial Muscles of the Head, Neck, and Back
mast cell
19.4: Anatomy of Lymphatic Organs and Tissues
mastication
21.3: Digestive System Processes and Regulation
9.4: Axial Muscles of the Head, Neck, and Back
mastoid process
6.3: The Skull
matrix
3.4: Connective Tissue
maxillary bone
6.3: The Skull
maxillary sinus
6.3: The Skull
maxillary vein
18.3: Circulatory Pathways
maximus
9.3: Naming Skeletal Muscles
meatus
20.3: Conducting Zone
mechanical digestion
21.3: Digestive System Processes and Regulation
mechanoreceptor
13.2: Sensory Modalities and General Senses
meconium
24.4: Fetal Development
medial
1.4: Anatomical Terminology
medial (internal) rotation
7.4: Types of Body Movements
medial border of the scapula
6.6: The Pectoral Girdle
medial compartment of the thigh
9.7: Appendicular Muscles of the Pelvic Girdle and Lower Limbs
medial condyle of the femur
6.9: Bones of the Lower Limb
medial condyle of the tibia
6.9: Bones of the Lower Limb
medial cuneiform
6.9: Bones of the Lower Limb
medial epicondyle of the femur
6.9: Bones of the Lower Limb
medial epicondyle of the humerus
6.7: Bones of the Upper Limb
medial excursion
7.4: Types of Body Movements
medial forebrain bundle
14.4: Central Control of Autonomic Function
medial geniculate nucleus
13.4: Vision
medial lemniscus
13.4: Vision
medial malleolus
6.9: Bones of the Lower Limb
medial meniscus
7.5: Anatomy of Selected Synovial Joints
medial nucleus
13.4: Vision
medial plantar artery
18.3: Circulatory Pathways
medial pterygoid
9.4: Axial Muscles of the Head, Neck, and Back
medial pterygoid plate
6.3: The Skull
medial rectus
13.3: Hearing and Balance
medial tibiofemoral joint
7.5: Anatomy of Selected Synovial Joints
medialis
9.3: Naming Skeletal Muscles

median antebrachial vein
18.3: Circulatory Pathways

median aperture
11.2: Support and Protection of the Brain

median cubital vein
18.3: Circulatory Pathways

median nerve
12.4: Spinal Nerves and Their Branches

median sacral artery
18.3: Circulatory Pathways

mediastinal artery
18.3: Circulatory Pathways

medius
9.3: Naming Skeletal Muscles

medulla
4.3: Accessory Structures of the Skin

medulla oblongata
11.4: Brain - Diencephalon, Brainstem, Cerebellum and Limbic System
14.4: Central Control of Autonomic Function

medullary cavity
5.3: Bone Structure

megakaryocyte
16.4: Leukocytes and Platelets

Meissner corpuscle
4.4: Functions of the Integumentary System

melanin
4.2: Layers of the Skin

melanocyte
4.2: Layers of the Skin

melanoma
4.5: Diseases, Disorders, and Injuries of the Integumentary System

melanosome
4.2: Layers of the Skin

melatonin
15.6: Pineal Gland

membranous labyrinth
13.3: Hearing and Balance

memory cell
16.4: Leukocytes and Platelets

menarche
23.3: Anatomy of the Female Reproductive System

meningeal layer
11.2: Support and Protection of the Brain

meninges
11.2: Support and Protection of the Brain

meniscus
7.3: Synovial Joints

menses
23.3: Anatomy of the Female Reproductive System

menses phase
23.3: Anatomy of the Female Reproductive System

menstrual cycle
23.3: Anatomy of the Female Reproductive System

mental foramen
6.3: The Skull

mental protuberance
6.3: The Skull

Merkel cell
4.2: Layers of the Skin

merocrine secretion
3.3: Epithelial Tissue

mesangial
22.3: Microscopic Anatomy of the Kidney

mesencephalic nucleus
13.4: Vision

mesencephalon
10.5: Development of the Nervous System

mesenchymal cell
3.4: Connective Tissue

mesenchyme
3.4: Connective Tissue

mesoappendix
21.6: Small and Large Intestines

mesoderm
17.5: Development of the Heart
24.3: Embryonic Development
3.2: Types of Tissues

mesothelium
17.2: Heart Anatomy
3.3: Epithelial Tissue

metacarpal bone
6.7: Bones of the Upper Limb

metacarpophalangeal joint
6.7: Bones of the Upper Limb

metaphase
2.5: Cell Growth and Division

metaphase plate
2.5: Cell Growth and Division

metarteriole
18.2: Structure and Function of Blood Vessels

metastasis
4.5: Diseases, Disorders, and Injuries of the Integumentary System

metatarsal bone
6.9: Bones of the Lower Limb

metatarsophalangeal joint
6.9: Bones of the Lower Limb

metencephalon
10.5: Development of the Nervous System

microcirculation
18.2: Structure and Function of Blood Vessels

microfilament
2.3: The Cytoplasm and Cellular Organelles

microglia
10.3: Anatomy of Nervous Tissue

Microscopic Anatomy
1.2: Overview of Anatomy

microtubule
2.3: The Cytoplasm and Cellular Organelles

microvillus
21.6: Small and Large Intestines

micturition
22.4: Urinary Tract

midbrain
10.5: Development of the Nervous System
11.4: Brain - Diencephalon, Brainstem, Cerebellum and Limbic System

midcarpal joint
6.7: Bones of the Upper Limb

middle cardiac vein
17.2: Heart Anatomy

middle cerebellar peduncle (MCP)
11.4: Brain - Diencephalon, Brainstem, Cerebellum and Limbic System

middle cerebral artery
18.3: Circulatory Pathways

middle cervical ganglion
14.2: Divisions of the Autonomic Nervous System

middle cranial fossa
6.3: The Skull

middle ear
13.3: Hearing and Balance

middle nasal concha
6.3: The Skull

middle sacral vein
18.3: Circulatory Pathways

middle scalene
9.4: Axial Muscles of the Head, Neck, and Back

migrating motility complex
21.6: Small and Large Intestines

mineralocorticoids
15.5: Adrenal Glands

minimus
9.3: Naming Skeletal Muscles

mitochondrion
2.3: The Cytoplasm and Cellular Organelles

mitosis
2.5: Cell Growth and Division

mitotic phase
2.5: Cell Growth and Division

mitotic spindle
2.5: Cell Growth and Division

mitral valve
17.2: Heart Anatomy

mixing wave
21.5: Stomach

modeling
5.4: Bone Formation and Development

moderator band
17.2: Heart Anatomy

molar
21.4: Mouth, Pharynx, and Esophagus

monocyte
19.4: Anatomy of Lymphatic Organs and Tissues

monocytes
16.4: Leukocytes and Platelets

mons pubis
23.3: Anatomy of the Female Reproductive System

morula
24.3: Embryonic Development

motilin
21.6: Small and Large Intestines

motility
21.2: Organs of the Digestive System

motor homunculus
11.3: Brain - Cerebrum

motor neuron
10.3: Anatomy of Nervous Tissue

mucosa
21.2: Organs of the Digestive System

mucosal barrier
21.5: Stomach

mucous connective tissue
3.4: Connective Tissue

mucous gland
3.3: Epithelial Tissue

mucous membrane
3.2: Types of Tissues

mucous neck cell
21.5: Stomach

Müllerian duct
23.4: Development of the Male and Female Reproductive Systems

multiaxial joint
7.2: Classification of Joints

multifidus
9.4: Axial Muscles of the Head, Neck, and Back

multimodal integration area
13.4: Vision

multipennate
9.2: Interactions of Skeletal Muscles, Their Fascicle Arrangement, and Their Lever Systems

multipolar
10.3: Anatomy of Nervous Tissue

multipotent
2.6: Cellular Differentiation

murmur
17.4: Coronary Circulation

muscarinic receptor
14.3: Autonomic Synapses and Effects

muscle tissue
3.2: Types of Tissues
8: Muscle Tissues and Muscle Structure

muscular artery
18.2: Structure and Function of Blood Vessels

muscularis
21.2: Organs of the Digestive System

musculocutaneous nerve
12.4: Spinal Nerves and Their Branches

mutation
2.3: The Cytoplasm and Cellular Organelles

myelencephalon
10.5: Development of the Nervous System

myelin
10.2: Organization and Functions of the Nervous System
3.6: Nervous Tissue

myelin sheath
10.3: Anatomy of Nervous Tissue

myelinated
10.3: Anatomy of Nervous Tissue

myeloid stem cells
16.5: Production of the Formed Elements

myenteric plexus
21.2: Organs of the Digestive System

mylohyoid
9.4: Axial Muscles of the Head, Neck, and Back

mylohyoid line
6.3: The Skull

myoblast
8.4: Development and Regeneration of Muscle Tissue

myocardial conducting cells
17.3: Cardiac Muscle and Electrical Activity

myocardial contractile cells
17.3: Cardiac Muscle and Electrical Activity

myocardium
17.2: Heart Anatomy

myocyte
3.5: Muscle Tissue

myofibril
8.3: Skeletal Muscle Organ Structure

myometrium
23.3: Anatomy of the Female Reproductive System

myosin
8.3: Skeletal Muscle Organ Structure

myotube
8.4: Development and Regeneration of Muscle Tissue

N

nail bed
4.3: Accessory Structures of the Skin

nail body
4.3: Accessory Structures of the Skin

nail cuticle
4.3: Accessory Structures of the Skin

nail fold
4.3: Accessory Structures of the Skin

nail root
4.3: Accessory Structures of the Skin

naïve lymphocyte
19.3: Anatomy of Lymphatic Vessels

naris
20.3: Conducting Zone

nasal bone
20.3: Conducting Zone

nasal cavity
6.3: The Skull

nasal conchae
6.3: The Skull

nasal septum
20.3: Conducting Zone
6.3: The Skull

nasolacrimal canal
6.3: The Skull

nasolacrimal duct
13.3: Hearing and Balance

nasopharynx
20.3: Conducting Zone

natural killer (NK) cells
16.4: Leukocytes and Platelets

natural killer cell (NK)
19.3: Anatomy of Lymphatic Vessels

navicular
6.9: Bones of the Lower Limb

neck of the femur
6.9: Bones of the Lower Limb

neck of the radius
6.7: Bones of the Upper Limb

neck of the rib
6.5: The Thoracic Cage

necrosis
3.7: Tissue Injury and Aging

neonatal hypothyroidism
15.4: Thyroid Gland and Parathyroid Glands

nerve
10.2: Organization and Functions of the Nervous System

nerve plexus
12.4: Spinal Nerves and Their Branches

nervi vasorum
18.2: Structure and Function of Blood Vessels

nervous tissue
3.2: Types of Tissues

neural crest
10.5: Development of the Nervous System

neural fold
10.5: Development of the Nervous System
24.3: Embryonic Development

neural groove
10.5: Development of the Nervous System

neural layer
13.3: Hearing and Balance

neural plate
10.5: Development of the Nervous System
24.3: Embryonic Development

neural tube
10.5: Development of the Nervous System
24.3: Embryonic Development

neural tunic
13.3: Hearing and Balance

neuraxis
10.5: Development of the Nervous System

neuroglia
3.6: Nervous Tissue

neuromuscular junction (NMJ)
8.3: Skeletal Muscle Organ Structure

neuron
10.2: Organization and Functions of the Nervous System
3.6: Nervous Tissue

neuronal polarity
10.3: Anatomy of Nervous Tissue

neurotransmitter
10.4: Synapses
14.3: Autonomic Synapses and Effects
8.3: Skeletal Muscle Organ Structure

neurotransmitter receptor
14.3: Autonomic Synapses and Effects

neurulation
24.3: Embryonic Development

neutralization
19.2: Functions of the Lymphatic System

neutrophil
19.4: Anatomy of Lymphatic Organs and Tissues

neutrophils
16.4: Leukocytes and Platelets

nicotinic receptor
14.3: Autonomic Synapses and Effects

nociceptor
13.2: Sensory Modalities and General Senses

node of Ranvier
10.3: Anatomy of Nervous Tissue

nonshivering thermogenesis
24.6: Adjustments of the Infant at Birth and Postnatal Stages

norepinephrine
14.2: Divisions of the Autonomic Nervous System
14.3: Autonomic Synapses and Effects
15.5: Adrenal Glands

notochord
24.3: Embryonic Development
6.10: Embryonic Development of the Skeleton

nuchal ligament
6.4: The Vertebral Column

nuclear envelope
2.4: The Nucleus

Nuclear Pore
2.4: The Nucleus

nucleolus
2.4: The Nucleus
nucleosome
2.4: The Nucleus
nucleus
10.2: Organization and Functions of the Nervous System
2.3: The Cytoplasm and Cellular Organelles
nucleus ambiguus
14.4: Central Control of Autonomic Function
nucleus cuneatus
13.4: Vision
nucleus gracilis
13.4: Vision
nucleus pulposus
6.4: The Vertebral Column
nutrient foramen
5.3: Bone Structure

O

oblique
9.3: Naming Skeletal Muscles
obturator externus
9.7: Appendicular Muscles of the Pelvic Girdle and Lower Limbs
obturator internus
9.7: Appendicular Muscles of the Pelvic Girdle and Lower Limbs
occipital bone
6.3: The Skull
occipital condyle
6.3: The Skull
occipital lobe
11.3: Brain - Cerebrum
occipital sinus
18.3: Circulatory Pathways
occipital sinuses
11.2: Support and Protection of the Brain
occipitalis
9.4: Axial Muscles of the Head, Neck, and Back
occipitofrontalis
9.4: Axial Muscles of the Head, Neck, and Back
ocular conjunctiva
13.3: Hearing and Balance
oculomotor complex
14.4: Central Control of Autonomic Function
oculomotor nerve
12.3: Cranial Nerves
13.3: Hearing and Balance
oculomotor nerve (CN III)
14.2: Divisions of the Autonomic Nervous System
olecranon fossa
6.7: Bones of the Upper Limb
olecranon process
6.7: Bones of the Upper Limb
olfactory pit
20.5: Embryonic Development of the Respiratory System
oligodendrocyte
10.3: Anatomy of Nervous Tissue
3.6: Nervous Tissue
oligopotent
2.6: Cellular Differentiation
omohyoid
9.4: Axial Muscles of the Head, Neck, and Back
ongissimus cervicis
9.4: Axial Muscles of the Head, Neck, and Back
oocyte
23.3: Anatomy of the Female Reproductive System
oogenesis
23.3: Anatomy of the Female Reproductive System
oogonia
23.3: Anatomy of the Female Reproductive System
open reduction
5.5: Fractures and Bone Repair
ophthalmic artery
18.3: Circulatory Pathways
opponens digiti minimi
9.6: Appendicular Muscles of the Pectoral Girdle and Upper Limbs
opponens pollicis
9.6: Appendicular Muscles of the Pectoral Girdle and Upper Limbs
opposition
7.4: Types of Body Movements
opsonization'
19.4: Anatomy of Lymphatic Organs and Tissues
optic chiasm
13.4: Vision
optic disc
13.3: Hearing and Balance
optic nerve
12.3: Cranial Nerves
13.3: Hearing and Balance
13.4: Vision
optic tract
13.4: Vision
oral cavity
21.4: Mouth, Pharynx, and Esophagus
oral vestibule
21.4: Mouth, Pharynx, and Esophagus
Oranelle
2.3: The Cytoplasm and Cellular Organelles
orbicularis oculi
9.4: Axial Muscles of the Head, Neck, and Back
orbicularis oris
9.4: Axial Muscles of the Head, Neck, and Back
organ
1.3: Structural Organization of the Human Body
organ of corti
13.3: Hearing and Balance
organ system
1.3: Structural Organization of the Human Body
organism
1.3: Structural Organization of the Human Body
organogenesis
24.3: Embryonic Development
origin
9.2: Interactions of Skeletal Muscles, Their Fascicle Arrangement, and Their Lever Systems
oropharynx
20.3: Conducting Zone
21.4: Mouth, Pharynx, and Esophagus
orthopedist
5.2: Functions of the Skeletal System
osmoreceptor
13.2: Sensory Modalities and General Senses
15.3: Pituitary Gland and Hypothalamus
osmosis
2.2: The Cell Membrane
osseous tissue
5.2: Functions of the Skeletal System
ossicles
13.3: Hearing and Balance
ossification
5.4: Bone Formation and Development
ossification center
5.4: Bone Formation and Development
osteoblast
5.3: Bone Structure
osteoclast
5.3: Bone Structure
osteocyte
5.3: Bone Structure
osteogenic cell
5.3: Bone Structure
osteoid
5.4: Bone Formation and Development
osteon
5.3: Bone Structure
osteoporosis
5.6: Exercise, Nutrition, Hormones, and Bone Tissue Health
otic ganglion
14.2: Divisions of the Autonomic Nervous System
otolith
13.3: Hearing and Balance
otolithic membrane
13.3: Hearing and Balance
oval window
13.3: Hearing and Balance
ovarian artery
18.3: Circulatory Pathways
ovarian cycle
23.3: Anatomy of the Female Reproductive System
ovarian vein
18.3: Circulatory Pathways
ovaries
23.3: Anatomy of the Female Reproductive System
ovulation
23.3: Anatomy of the Female Reproductive System
ovum
23.3: Anatomy of the Female Reproductive System
oxyhemoglobin
16.3: Erythrocytes
oxytocin
15.3: Pituitary Gland and Hypothalamus

P

P wave
17.3: Cardiac Muscle and Electrical Activity
pacemaker
17.3: Cardiac Muscle and Electrical Activity
Pacinian corpuscle
4.4: Functions of the Integumentary System
packed cell volume (PCV)
16.2: An Overview of Blood

palatine bone
6.3: The Skull
palatine process
6.3: The Skull
palatine tonsil
20.3: Conducting Zone
palatoglossal arch
21.4: Mouth, Pharynx, and Esophagus
palatoglossus
9.4: Axial Muscles of the Head, Neck, and Back
palatopharyngeal arch
21.4: Mouth, Pharynx, and Esophagus
palmar arches
18.3: Circulatory Pathways
palmar interossei
9.6: Appendicular Muscles of the Pectoral Girdle and Upper Limbs
palmar venous arches
18.3: Circulatory Pathways
palmaris longus
9.6: Appendicular Muscles of the Pectoral Girdle and Upper Limbs
palpebral conjunctiva
13.3: Hearing and Balance
pancreas
15.8: Endocrine Pancreas
21.7: Accessory Organs - Liver, Pancreas, and Gallbladder
pancreatic islets
15.8: Endocrine Pancreas
pancreatic juice
21.7: Accessory Organs - Liver, Pancreas, and Gallbladder
papillary layer
4.2: Layers of the Skin
papillary muscle
17.2: Heart Anatomy
paracrine
15.2: An Overview of the Endocrine System
parallel
9.2: Interactions of Skeletal Muscles, Their Fascicle Arrangement, and Their Lever Systems
paranasal sinus
20.3: Conducting Zone
paranasal sinuses
6.3: The Skull
parasympathetic division
14.2: Divisions of the Autonomic Nervous System
paravertebral ganglia
14.2: Divisions of the Autonomic Nervous System
parenchyma
3.4: Connective Tissue
parietal bone
6.3: The Skull
parietal branches
18.3: Circulatory Pathways
parietal cell
21.5: Stomach
parietal lobe
11.3: Brain - Cerebrum
parietal pleura
20.2: The Lungs
parotid gland
21.4: Mouth, Pharynx, and Esophagus
parturition
24.5: Maternal Changes During Pregnancy, Labor, and Birth
passive transport
2.2: The Cell Membrane
patella
6.9: Bones of the Lower Limb
patellar ligament
7.5: Anatomy of Selected Synovial Joints
9.7: Appendicular Muscles of the Pelvic Girdle and Lower Limbs
patellar surface
6.9: Bones of the Lower Limb
pattern recognition receptor (PRR)
19.4: Anatomy of Lymphatic Organs and Tissues
pectinate line
21.6: Small and Large Intestines
pectinate muscles
17.2: Heart Anatomy
pectineus
9.7: Appendicular Muscles of the Pelvic Girdle and Lower Limbs
pectoral girdle
6.6: The Pectoral Girdle
9.6: Appendicular Muscles of the Pectoral Girdle and Upper Limbs
pectoralis major
9.6: Appendicular Muscles of the Pectoral Girdle and Upper Limbs
pectoralis minor
9.6: Appendicular Muscles of the Pectoral Girdle and Upper Limbs
pedicels
22.3: Microscopic Anatomy of the Kidney
pedicle
6.4: The Vertebral Column
pelvic diaphragm
9.5: Axial Muscles of the Abdominal Wall and Thorax
pelvic girdle
9.7: Appendicular Muscles of the Pelvic Girdle and Lower Limbs
pelvic splanchnic nerve
14.2: Divisions of the Autonomic Nervous System
penis
23.2: Anatomy of the Male Reproductive System
pennate
9.2: Interactions of Skeletal Muscles, Their Fascicle Arrangement, and Their Lever Systems
pepsinogen
21.5: Stomach
perforating canal
5.3: Bone Structure
perforin
19.4: Anatomy of Lymphatic Organs and Tissues
perfusion
18.2: Structure and Function of Blood Vessels
pericardial artery
18.3: Circulatory Pathways
pericardial cavity
17.2: Heart Anatomy
pericardial sac
17.2: Heart Anatomy
pericardium
1.4: Anatomical Terminology
17.2: Heart Anatomy
perichondrium
5.4: Bone Formation and Development
pericyte
8.4: Development and Regeneration of Muscle Tissue
perilymph
13.3: Hearing and Balance
perimetrium
23.3: Anatomy of the Female Reproductive System
perimysium
8.3: Skeletal Muscle Organ Structure
perineum
9.5: Axial Muscles of the Abdominal Wall and Thorax
perineurium
12.3: Cranial Nerves
periosteal layer
11.2: Support and Protection of the Brain
periosteum
5.3: Bone Structure
peripheral chemoreceptor
20.4: Respiratory Zone
peripheral nervous system (PNS)
10.2: Organization and Functions of the Nervous System
peripheral protein
2.2: The Cell Membrane
peristalsis
21.3: Digestive System Processes and Regulation
peritoneum
1.4: Anatomical Terminology
permanent tooth
21.4: Mouth, Pharynx, and Esophagus
peroxisome
2.3: The Cytoplasm and Cellular Organelles
perpendicular plate of the ethmoid bone
6.3: The Skull
petrosal sinus
18.3: Circulatory Pathways
petrous ridge
6.3: The Skull
phagocytosis
19.4: Anatomy of Lymphatic Organs and Tissues
2.2: The Cell Membrane
phalanx bone of the foot
6.9: Bones of the Lower Limb
phalanx bone of the hand
6.7: Bones of the Upper Limb
pharyngeal tonsil
20.3: Conducting Zone
pharynx
20.3: Conducting Zone
21.4: Mouth, Pharynx, and Esophagus
philtrum
20.3: Conducting Zone
phrenic nerve
12.4: Spinal Nerves and Their Branches
phrenic vein
18.3: Circulatory Pathways
physiological sphincter
22.4: Urinary Tract
physiology
1.2: Overview of Anatomy

pia mater
11.2: Support and Protection of the Brain

pigmented layer
13.3: Hearing and Balance

pineal gland
11.4: Brain - Diencephalon, Brainstem, Cerebellum and Limbic System
15.6: Pineal Gland

pinealocyte
15.6: Pineal Gland

pinocytosis
2.2: The Cell Membrane

piriformis
9.7: Appendicular Muscles of the Pelvic Girdle and Lower Limbs

pisiform
6.7: Bones of the Upper Limb

pituitary dwarfism
15.3: Pituitary Gland and Hypothalamus

pituitary gland
15.3: Pituitary Gland and Hypothalamus

pivot joint
7.3: Synovial Joints

placenta
24.3: Embryonic Development

placenta previa
24.3: Embryonic Development

placentation
24.3: Embryonic Development

Plane
1.4: Anatomical Terminology

plane joint
7.3: Synovial Joints

plantar aponeurosis
9.7: Appendicular Muscles of the Pelvic Girdle and Lower Limbs

plantar arch
18.3: Circulatory Pathways

plantar flexion
7.4: Types of Body Movements

plantar group
9.7: Appendicular Muscles of the Pelvic Girdle and Lower Limbs

plantar veins
18.3: Circulatory Pathways

plantar venous arch
18.3: Circulatory Pathways

plantaris
9.7: Appendicular Muscles of the Pelvic Girdle and Lower Limbs

plasma
16.2: An Overview of Blood

plasma cell
19.3: Anatomy of Lymphatic Vessels

platelets
16.2: An Overview of Blood

pleura
1.4: Anatomical Terminology

pleural cavity
20.2: The Lungs

pleural fluid
20.2: The Lungs

pluripotent
2.6: Cellular Differentiation

pluripotent stem cell
16.5: Production of the Formed Elements

pneumotaxic center
20.4: Respiratory Zone

podocytes
22.3: Microscopic Anatomy of the Kidney

polar body
23.3: Anatomy of the Female Reproductive System

pollex
6.7: Bones of the Upper Limb

polycythemia
16.3: Erythrocytes

polymorphonuclear
16.4: Leukocytes and Platelets

polyspermy
24.2: Fertilization

pons
11.4: Brain - Diencephalon, Brainstem, Cerebellum and Limbic System

popliteal artery
18.3: Circulatory Pathways

popliteal fossa
9.7: Appendicular Muscles of the Pelvic Girdle and Lower Limbs

popliteal vein
18.3: Circulatory Pathways

popliteus
9.7: Appendicular Muscles of the Pelvic Girdle and Lower Limbs

porta hepatis
21.7: Accessory Organs - Liver, Pancreas, and Gallbladder

portal triad
21.7: Accessory Organs - Liver, Pancreas, and Gallbladder

positive chemotaxis
16.4: Leukocytes and Platelets

Positron Emission Tomography (PET)
1.5: Medical Imaging

postcentral gyrus
11.3: Brain - Cerebrum

posterior
1.4: Anatomical Terminology

posterior (dorsal) sacral foramen
6.4: The Vertebral Column

posterior arch
6.4: The Vertebral Column

posterior cardiac vein
17.2: Heart Anatomy

Posterior Cavity
1.4: Anatomical Terminology

posterior cavity of the eye
13.3: Hearing and Balance

posterior chamber
13.3: Hearing and Balance

posterior communicating artery
18.3: Circulatory Pathways

posterior compartment of the leg
9.7: Appendicular Muscles of the Pelvic Girdle and Lower Limbs

posterior compartment of the thigh
9.7: Appendicular Muscles of the Pelvic Girdle and Lower Limbs

posterior cruciate ligament
7.5: Anatomy of Selected Synovial Joints

posterior interventricular artery
17.2: Heart Anatomy

posterior interventricular sulcus
17.2: Heart Anatomy

posterior lobe
11.4: Brain - Diencephalon, Brainstem, Cerebellum and Limbic System

posterior longitudinal ligament
6.4: The Vertebral Column

posterior scalene
9.4: Axial Muscles of the Head, Neck, and Back

posterior talofibular ligament
7.5: Anatomy of Selected Synovial Joints

posterior tibial artery
18.3: Circulatory Pathways

posterior tibial vein
18.3: Circulatory Pathways

postganglionic fiber
14.2: Divisions of the Autonomic Nervous System

postganglionic sympathetic nerve pathway
14.2: Divisions of the Autonomic Nervous System

postsynaptic cell
10.4: Synapses

PP cell
15.8: Endocrine Pancreas

precapillary sphincters
18.2: Structure and Function of Blood Vessels

precentral gyrus
11.3: Brain - Cerebrum

prefrontal lobotomy
11.3: Brain - Cerebrum

preganglionic fiber
14.2: Divisions of the Autonomic Nervous System

preganglionic neuron
14.2: Divisions of the Autonomic Nervous System

preload
17.4: Coronary Circulation

premolar
21.4: Mouth, Pharynx, and Esophagus

premotor cortex
11.3: Brain - Cerebrum
13.5: Taste and Smell

prepotential depolarization
17.3: Cardiac Muscle and Electrical Activity

prepuce
23.2: Anatomy of the Male Reproductive System

presynaptic cell
10.4: Synapses

prevertebral ganglia
14.2: Divisions of the Autonomic Nervous System

primary auditory cortex
11.3: Brain - Cerebrum
13.3: Hearing and Balance

primary cortical areas
11.3: Brain - Cerebrum

primary curve
6.4: The Vertebral Column

primary fissure
11.4: Brain - Diencephalon, Brainstem, Cerebellum and Limbic System

primary follicles
23.3: Anatomy of the Female Reproductive System
primary gustatory cortex
11.3: Brain - Cerebrum
primary lymphoid organ
19.3: Anatomy of Lymphatic Vessels
primary motor cortex
11.3: Brain - Cerebrum
primary olfactory cortex
11.3: Brain - Cerebrum
primary ossification center
5.4: Bone Formation and Development
primary sensory cortex
13.4: Vision
primary somatosensory cortex
11.3: Brain - Cerebrum
primary union
3.7: Tissue Injury and Aging
primary vesicle
10.5: Development of the Nervous System
primary visual cortex
11.3: Brain - Cerebrum
13.3: Hearing and Balance
prime mover
9.2: Interactions of Skeletal Muscles, Their Fascicle Arrangement, and Their Lever Systems
primitive atrium
17.5: Development of the Heart
primitive heart tube
17.5: Development of the Heart
primitive streak
24.3: Embryonic Development
primitive ventricle
17.5: Development of the Heart
primordial follicles
23.3: Anatomy of the Female Reproductive System
process
10.2: Organization and Functions of the Nervous System
progesterone
15.7: Gonadal and Placental Hormones
projection
5.3: Bone Structure
projection tract
11.3: Brain - Cerebrum
prolactin
24.7: Lactation
prolactin (PRL)
15.3: Pituitary Gland and Hypothalamus
proliferative phase
23.3: Anatomy of the Female Reproductive System
proliferative zone
5.4: Bone Formation and Development
pronated position
7.4: Types of Body Movements
pronation
7.4: Types of Body Movements
pronator quadratus
9.6: Appendicular Muscles of the Pectoral Girdle and Upper Limbs
pronator teres
9.6: Appendicular Muscles of the Pectoral Girdle and Upper Limbs
Prone
1.4: Anatomical Terminology
propagation
10.4: Synapses
prophase
2.5: Cell Growth and Division
Proprioception
11.4: Brain - Diencephalon, Brainstem, Cerebellum and Limbic System
13.2: Sensory Modalities and General Senses
proprioceptor
13.2: Sensory Modalities and General Senses
propulsion
21.3: Digestive System Processes and Regulation
prosencephalon
10.5: Development of the Nervous System
prostate gland
23.2: Anatomy of the Male Reproductive System
protraction
7.4: Types of Body Movements
proximal
1.4: Anatomical Terminology
proximal radioulnar joint
6.7: Bones of the Upper Limb
7.3: Synovial Joints
proximal tibiofibular joint
6.9: Bones of the Lower Limb
pseudostratified columnar epithelium
3.3: Epithelial Tissue
psoas major
9.7: Appendicular Muscles of the Pelvic Girdle and Lower Limbs
pterion
6.3: The Skull
pterygopalatine ganglion
14.2: Divisions of the Autonomic Nervous System
puberty
23.4: Development of the Male and Female Reproductive Systems
pubococcygeus
9.5: Axial Muscles of the Abdominal Wall and Thorax
pubofemoral ligament
7.5: Anatomy of Selected Synovial Joints
pulmonary arteries
17.2: Heart Anatomy
pulmonary artery
18.3: Circulatory Pathways
20.2: The Lungs
pulmonary capillaries
17.2: Heart Anatomy
pulmonary circuit
17.2: Heart Anatomy
pulmonary plexus
20.2: The Lungs
pulmonary surfactant
20.3: Conducting Zone
pulmonary trunk
17.2: Heart Anatomy
18.3: Circulatory Pathways
pulmonary valve
17.2: Heart Anatomy
pulmonary veins
17.2: Heart Anatomy
18.3: Circulatory Pathways
pulmonary ventilation
20.4: Respiratory Zone
pulp cavity
21.4: Mouth, Pharynx, and Esophagus
pupil
13.3: Hearing and Balance
pupillary reflex
14.4: Central Control of Autonomic Function
Purkinje fibers
17.3: Cardiac Muscle and Electrical Activity
putamen
11.3: Brain - Cerebrum
pyloric antrum
21.5: Stomach
pyloric canal
21.5: Stomach
pyloric sphincter
21.5: Stomach
pylorus
21.5: Stomach
pyramidal decussation
13.5: Taste and Smell
pyramids
11.4: Brain - Diencephalon, Brainstem, Cerebellum and Limbic System
13.5: Taste and Smell

Q

QRS complex
17.3: Cardiac Muscle and Electrical Activity
quadratus femoris
9.7: Appendicular Muscles of the Pelvic Girdle and Lower Limbs
quadratus lumborum
9.5: Axial Muscles of the Abdominal Wall and Thorax
quadriceps femoris group
9.7: Appendicular Muscles of the Pelvic Girdle and Lower Limbs
quadriceps tendon
9.7: Appendicular Muscles of the Pelvic Girdle and Lower Limbs
quickening
24.4: Fetal Development
quiet breathing
20.4: Respiratory Zone

R

radial artery
18.3: Circulatory Pathways
radial collateral ligament
7.5: Anatomy of Selected Synovial Joints
radial fossa
6.7: Bones of the Upper Limb
radial nerve
12.4: Spinal Nerves and Their Branches
radial notch of the ulna
6.7: Bones of the Upper Limb
radial tuberosity
6.7: Bones of the Upper Limb
radial vein
18.3: Circulatory Pathways

radiocarpal joint
6.7: Bones of the Upper Limb
radius
6.7: Bones of the Upper Limb
rami communicantes
12.4: Spinal Nerves and Their Branches
ramus
12.4: Spinal Nerves and Their Branches
ramus of the mandible
6.3: The Skull
Reactive Oxygen Species (ROS)
2.3: The Cytoplasm and Cellular Organelles
receptive aphasia
11.3: Brain - Cerebrum
receptor
2.2: The Cell Membrane
receptor cell
13.2: Sensory Modalities and General Senses
rectal valve
21.6: Small and Large Intestines
rectum
21.6: Small and Large Intestines
rectus
9.3: Naming Skeletal Muscles
rectus abdominis
9.5: Axial Muscles of the Abdominal Wall and Thorax
rectus femoris
9.7: Appendicular Muscles of the Pelvic Girdle and Lower Limbs
rectus sheaths
9.5: Axial Muscles of the Abdominal Wall and Thorax
red blood cells (RBCs)
16.2: An Overview of Blood
red marrow
5.2: Functions of the Skeletal System
referred pain
14.3: Autonomic Synapses and Effects
reflex arc
14.3: Autonomic Synapses and Effects
regional anatomy
1.2: Overview of Anatomy
remodeling
5.4: Bone Formation and Development
renal artery
18.3: Circulatory Pathways
renal vein
18.3: Circulatory Pathways
renin
22.3: Microscopic Anatomy of the Kidney
reposition
7.4: Types of Body Movements
reserve zone
5.4: Bone Formation and Development
residual volume (RV)
20.4: Respiratory Zone
respiratory bronchiole
20.3: Conducting Zone
respiratory cycle
20.4: Respiratory Zone
respiratory epithelium
20.3: Conducting Zone
respiratory membrane
20.3: Conducting Zone
respiratory rate
20.4: Respiratory Zone
respiratory system
20: Respiratory System
20.1: Introduction to the Respiratory System
respiratory volume
20.4: Respiratory Zone
respiratory zone
20.3: Conducting Zone
response
10.2: Organization and Functions of the Nervous System
reticular activating system
11.4: Brain - Diencephalon, Brainstem, Cerebellum and Limbic System
reticular fiber
3.4: Connective Tissue
reticular lamina
3.3: Epithelial Tissue
reticular layer
4.2: Layers of the Skin
reticular tissue
3.4: Connective Tissue
reticulocyte
16.3: Erythrocytes
reticuloendothelial cell
21.7: Accessory Organs - Liver, Pancreas, and Gallbladder
reticulospinal tract
13.5: Taste and Smell
retina
13.3: Hearing and Balance
retinacula
9.6: Appendicular Muscles of the Pectoral Girdle and Upper Limbs
retinal ganglion cell (RGC)
13.3: Hearing and Balance
retraction
7.4: Types of Body Movements
retroperitoneal
21.2: Organs of the Digestive System
22.4: Urinary Tract
rhombencephalon
10.5: Development of the Nervous System
rhomboid major
9.6: Appendicular Muscles of the Pectoral Girdle and Upper Limbs
rhomboid minor
9.6: Appendicular Muscles of the Pectoral Girdle and Upper Limbs
ribosome
2.3: The Cytoplasm and Cellular Organelles
ribs
6.2: Divisions of the Skeletal System
rickets
4.4: Functions of the Integumentary System
right atrioventricular valve
17.2: Heart Anatomy
right colic flexure
21.6: Small and Large Intestines
right gastric artery
18.3: Circulatory Pathways
right lymphatic duct
19.3: Anatomy of Lymphatic Vessels
rod photoreceptor
13.3: Hearing and Balance
root
20.3: Conducting Zone
21.4: Mouth, Pharynx, and Esophagus
rotation
7.4: Types of Body Movements
rotator cuff
9.6: Appendicular Muscles of the Pectoral Girdle and Upper Limbs
round window
13.3: Hearing and Balance
ruga
21.5: Stomach
rugae
23.3: Anatomy of the Female Reproductive System

S

S phase
2.5: Cell Growth and Division
saccharolytic fermentation
21.6: Small and Large Intestines
saccule
13.3: Hearing and Balance
sacral canal
6.4: The Vertebral Column
sacral foramina
6.4: The Vertebral Column
sacral hiatus
6.4: The Vertebral Column
sacral micturition center
22.4: Urinary Tract
sacral plexus
12.4: Spinal Nerves and Their Branches
sacral promontory
6.4: The Vertebral Column
sacral splanchnic nerve
14.2: Divisions of the Autonomic Nervous System
sacrococcygeal curve
6.4: The Vertebral Column
sacrum
6.2: Divisions of the Skeletal System
saddle joint
7.3: Synovial Joints
sagittal plane
1.4: Anatomical Terminology
sagittal suture
6.3: The Skull
saliva
21.4: Mouth, Pharynx, and Esophagus
salivary amylase
21.4: Mouth, Pharynx, and Esophagus
salivary gland
21.4: Mouth, Pharynx, and Esophagus
salivation
21.4: Mouth, Pharynx, and Esophagus
saltatory conduction
10.4: Synapses
saphenous nerve
12.4: Spinal Nerves and Their Branches
sarcolemma
8.3: Skeletal Muscle Organ Structure
sarcomere
8.3: Skeletal Muscle Organ Structure

sarcoplasm
8.3: Skeletal Muscle Organ Structure
sarcoplasmic reticulum (SR)
8.3: Skeletal Muscle Organ Structure
sartorius
9.7: Appendicular Muscles of the Pelvic Girdle and Lower Limbs
satellite cell
10.3: Anatomy of Nervous Tissue
8.4: Development and Regeneration of Muscle Tissue
scala tympani
13.3: Hearing and Balance
scala vestibuli
13.3: Hearing and Balance
scalene muscles
9.4: Axial Muscles of the Head, Neck, and Back
scaphoid
6.7: Bones of the Upper Limb
scapula
6.6: The Pectoral Girdle
scar
4.5: Diseases, Disorders, and Injuries of the Integumentary System
Schwann cell
10.3: Anatomy of Nervous Tissue
3.6: Nervous Tissue
sciatic nerve
12.4: Spinal Nerves and Their Branches
sciatica
12.4: Spinal Nerves and Their Branches
sclera
13.3: Hearing and Balance
scleral venous sinus
13.3: Hearing and Balance
sclerotome
6.10: Embryonic Development of the Skeleton
scoliosis
6.4: The Vertebral Column
scrotum
23.2: Anatomy of the Male Reproductive System
sebaceous gland
4.3: Accessory Structures of the Skin
sebum
4.3: Accessory Structures of the Skin
secondary curve
6.4: The Vertebral Column
Secondary Endocrine Functions
15.9: Organs with Secondary Endocrine Functions
secondary follicles
23.3: Anatomy of the Female Reproductive System
secondary lymphoid organs
19.3: Anatomy of Lymphatic Vessels
secondary ossification center
5.4: Bone Formation and Development
secondary sex characteristics
23.4: Development of the Male and Female Reproductive Systems
secondary union
3.7: Tissue Injury and Aging
secondary vesicle
10.5: Development of the Nervous System
secretory phase
23.3: Anatomy of the Female Reproductive System
Section
1.4: Anatomical Terminology
segmental muscle group
9.4: Axial Muscles of the Head, Neck, and Back
segmentation
21.3: Digestive System Processes and Regulation
selective permeability
2.2: The Cell Membrane
sella turcica
6.3: The Skull
semen
23.2: Anatomy of the Male Reproductive System
semicircular canals
13.3: Hearing and Balance
semilunar valves
17.2: Heart Anatomy
semimembranosus
9.7: Appendicular Muscles of the Pelvic Girdle and Lower Limbs
seminal vesicle
23.2: Anatomy of the Male Reproductive System
seminiferous tubules
23.2: Anatomy of the Male Reproductive System
semispinalis capitis
9.4: Axial Muscles of the Head, Neck, and Back
semispinalis cervicis
9.4: Axial Muscles of the Head, Neck, and Back
semispinalis thoracis
9.4: Axial Muscles of the Head, Neck, and Back
semitendinosus
9.7: Appendicular Muscles of the Pelvic Girdle and Lower Limbs
sensation
10.2: Organization and Functions of the Nervous System
sensory association area
11.3: Brain - Cerebrum
sensory homunculus
11.3: Brain - Cerebrum
sensory modality
13.2: Sensory Modalities and General Senses
sensory neuron
10.3: Anatomy of Nervous Tissue
septal cartilage
6.3: The Skull
septum
17.2: Heart Anatomy
septum primum
17.2: Heart Anatomy
seroconversion
19.2: Functions of the Lymphatic System
serosa
1.4: Anatomical Terminology
21.2: Organs of the Digestive System
serous gland
3.3: Epithelial Tissue
serous membrane
1.4: Anatomical Terminology
3.2: Types of Tissues
serratus anterior
9.6: Appendicular Muscles of the Pectoral Girdle and Upper Limbs
Sertoli cells
23.2: Anatomy of the Male Reproductive System
sesamoid bone
5.7: Bone Classification
shaft of the femur
6.9: Bones of the Lower Limb
shaft of the fibula
6.9: Bones of the Lower Limb
shaft of the humerus
6.7: Bones of the Upper Limb
shaft of the radius
6.7: Bones of the Upper Limb
shaft of the tibia
6.9: Bones of the Lower Limb
shaft of the ulna
6.7: Bones of the Upper Limb
short bone
5.7: Bone Classification
short reflex
14.3: Autonomic Synapses and Effects
shunt
24.4: Fetal Development
sickle cell disease
16.3: Erythrocytes
sigmoid colon
21.6: Small and Large Intestines
sigmoid sinuses
11.2: Support and Protection of the Brain
18.3: Circulatory Pathways
simple columnar epithelium
3.3: Epithelial Tissue
simple cuboidal epithelium
3.3: Epithelial Tissue
simple squamous epithelium
3.3: Epithelial Tissue
sinoatrial (SA) node
17.3: Cardiac Muscle and Electrical Activity
sinus rhythm
17.3: Cardiac Muscle and Electrical Activity
sinus venosus
17.5: Development of the Heart
sinusoid capillary
18.2: Structure and Function of Blood Vessels
sister chromatid
2.5: Cell Growth and Division
Skeletal Muscle
3.5: Muscle Tissue
8.2: Muscle Tissues
skeletal system
5.2: Functions of the Skeletal System
skeleton
6.2: Divisions of the Skeletal System
skull
6.2: Divisions of the Skeletal System
small cardiac vein
17.2: Heart Anatomy
small intestine
21.6: Small and Large Intestines
small saphenous vein
18.3: Circulatory Pathways
smooth muscle
3.5: Muscle Tissue
8.2: Muscle Tissues
soft palate
21.4: Mouth, Pharynx, and Esophagus

soleal line
6.9: Bones of the Lower Limb
soleus
9.7: Appendicular Muscles of the Pelvic Girdle and Lower Limbs
solitary nucleus
13.4: Vision
14.4: Central Control of Autonomic Function
soma
10.2: Organization and Functions of the Nervous System
somatic cell
2.5: Cell Growth and Division
somatic nervous system (SNS)
10.2: Organization and Functions of the Nervous System
14.2: Divisions of the Autonomic Nervous System
somatic reflex
14.3: Autonomic Synapses and Effects
somatosensation
10.2: Organization and Functions of the Nervous System
11.3: Brain - Cerebrum
13.2: Sensory Modalities and General Senses
somite
24.3: Embryonic Development
6.10: Embryonic Development of the Skeleton
somites
8.4: Development and Regeneration of Muscle Tissue
special sense
10.2: Organization and Functions of the Nervous System
13.2: Sensory Modalities and General Senses
special senses
6.6: The Pectoral Girdle
sperm
23.2: Anatomy of the Male Reproductive System
spermatic cord
23.2: Anatomy of the Male Reproductive System
spermatid
23.2: Anatomy of the Male Reproductive System
spermatocyte
23.2: Anatomy of the Male Reproductive System
spermatogenesis
23.2: Anatomy of the Male Reproductive System
spermatogonia
23.2: Anatomy of the Male Reproductive System
spermiogenesis
23.2: Anatomy of the Male Reproductive System
sphenoid bone
6.3: The Skull
sphenoid sinus
6.3: The Skull
sphincter pupillae
13.3: Hearing and Balance
sphincter urethrovaginalis
9.5: Axial Muscles of the Abdominal Wall and Thorax
spinal cavity
1.4: Anatomical Terminology
spinal cord
10.2: Organization and Functions of the Nervous System
spinal nerve
10.2: Organization and Functions of the Nervous System
12.4: Spinal Nerves and Their Branches
13.4: Vision
spinal nerve pathway
14.2: Divisions of the Autonomic Nervous System
spinal trigeminal nucleus
13.4: Vision
spinalis capitis
9.4: Axial Muscles of the Head, Neck, and Back
spinalis cervicis
9.4: Axial Muscles of the Head, Neck, and Back
spinalis group
9.4: Axial Muscles of the Head, Neck, and Back
spinalis thoracis
9.4: Axial Muscles of the Head, Neck, and Back
spine of the scapula
6.6: The Pectoral Girdle
spinothalamic tract
13.4: Vision
spinous process
6.4: The Vertebral Column
spiral ganglion
13.3: Hearing and Balance
splanchnic nerve pathway
14.2: Divisions of the Autonomic Nervous System
splanchnic nerves
14.2: Divisions of the Autonomic Nervous System
spleen
19.3: Anatomy of Lymphatic Vessels
splenic artery
18.3: Circulatory Pathways
splenius
9.4: Axial Muscles of the Head, Neck, and Back
splenius capitis
9.4: Axial Muscles of the Head, Neck, and Back
splenius cervicis
9.4: Axial Muscles of the Head, Neck, and Back
spongy bone
5.3: Bone Structure
spontaneous depolarizationv
17.3: Cardiac Muscle and Electrical Activity
squamous cell carcinoma
4.5: Diseases, Disorders, and Injuries of the Integumentary System
squamous suture
6.3: The Skull
stage of exhaustion
15.5: Adrenal Glands
stage of resistance
15.5: Adrenal Glands
stapes
13.3: Hearing and Balance
stem cell
2.6: Cellular Differentiation
stereocilia
13.3: Hearing and Balance
sternal angle
6.5: The Thoracic Cage
sternal end of the clavicle
6.6: The Pectoral Girdle
sternoclavicular joint
6.6: The Pectoral Girdle
sternocleidomastoid
9.4: Axial Muscles of the Head, Neck, and Back
sternohyoid
9.4: Axial Muscles of the Head, Neck, and Back
sternothyroid
9.4: Axial Muscles of the Head, Neck, and Back
sternum
6.2: Divisions of the Skeletal System
stimulus
10.2: Organization and Functions of the Nervous System
stomach
21.5: Stomach
straight sinus
11.2: Support and Protection of the Brain
18.3: Circulatory Pathways
stratified columnar epithelium
3.3: Epithelial Tissue
stratified cuboidal epithelium
3.3: Epithelial Tissue
stratified squamous epithelium
3.3: Epithelial Tissue
stratum basale
4.2: Layers of the Skin
stratum corneum
4.2: Layers of the Skin
stratum granulosum
4.2: Layers of the Skin
stratum lucidum
4.2: Layers of the Skin
stratum spinosum
4.2: Layers of the Skin
stretch mark
4.5: Diseases, Disorders, and Injuries of the Integumentary System
stretch reflex
13.5: Taste and Smell
striation
3.5: Muscle Tissue
striatum
11.3: Brain - Cerebrum
styloglossus
9.4: Axial Muscles of the Head, Neck, and Back
stylohyoid
9.4: Axial Muscles of the Head, Neck, and Back
styloid process
6.3: The Skull
styloid process of the radius
6.7: Bones of the Upper Limb
styloid process of the ulna
6.7: Bones of the Upper Limb
stylomastoid foramen
6.3: The Skull
subacromial bursa
7.5: Anatomy of Selected Synovial Joints
subarachnoid space
11.2: Support and Protection of the Brain
subclavian artery
18.3: Circulatory Pathways
subclavian vein
18.3: Circulatory Pathways
subcutaneous bursa
7.3: Synovial Joints

subdural space
11.2: Support and Protection of the Brain

sublingual gland
21.4: Mouth, Pharynx, and Esophagus

submandibular ganglion
14.2: Divisions of the Autonomic Nervous System

submandibular gland
21.4: Mouth, Pharynx, and Esophagus

submucosa
21.2: Organs of the Digestive System

submuscular bursa
7.3: Synovial Joints

subscapular bursa
7.5: Anatomy of Selected Synovial Joints

subscapular fossa
6.6: The Pectoral Girdle

subscapular vein
18.3: Circulatory Pathways

subscapularis
9.6: Appendicular Muscles of the Pectoral Girdle and Upper Limbs

substantia nigra
11.4: Brain - Diencephalon, Brainstem, Cerebellum and Limbic System

subtendinous bursa
7.3: Synovial Joints

subthalamic nucleus
11.4: Brain - Diencephalon, Brainstem, Cerebellum and Limbic System

subthalamus
11.4: Brain - Diencephalon, Brainstem, Cerebellum and Limbic System

sudoriferous gland
4.3: Accessory Structures of the Skin

sulcus
11.3: Brain - Cerebrum
17.2: Heart Anatomy

Superficial
1.4: Anatomical Terminology

superficial anterior compartment of the forearm
9.6: Appendicular Muscles of the Pectoral Girdle and Upper Limbs

superficial posterior compartment of the forearm
9.6: Appendicular Muscles of the Pectoral Girdle and Upper Limbs

superior
1.4: Anatomical Terminology

superior angle of the scapula
6.6: The Pectoral Girdle

superior articular process
6.4: The Vertebral Column

superior articular process of the sacrum
6.4: The Vertebral Column

superior border of the scapula
6.6: The Pectoral Girdle

superior cerebellar peduncle (SCP)
11.4: Brain - Diencephalon, Brainstem, Cerebellum and Limbic System

superior cervical ganglion
14.2: Divisions of the Autonomic Nervous System

superior colliculus
11.4: Brain - Diencephalon, Brainstem, Cerebellum and Limbic System
13.4: Vision

superior extensor retinaculum
9.7: Appendicular Muscles of the Pelvic Girdle and Lower Limbs

superior gemellus
9.7: Appendicular Muscles of the Pelvic Girdle and Lower Limbs

superior mesenteric artery
18.3: Circulatory Pathways

superior mesenteric ganglion
14.2: Divisions of the Autonomic Nervous System

superior nuchal line
6.3: The Skull

superior oblique
13.3: Hearing and Balance

superior orbital fissure
6.3: The Skull

superior phrenic artery
18.3: Circulatory Pathways

superior rectus
13.3: Hearing and Balance

superior rotation
7.4: Types of Body Movements

superior sagittal sinus
11.2: Support and Protection of the Brain
18.3: Circulatory Pathways

superior vena cava
17.2: Heart Anatomy
18.3: Circulatory Pathways

supinated position
7.4: Types of Body Movements

supination
7.4: Types of Body Movements

supinator
9.6: Appendicular Muscles of the Pectoral Girdle and Upper Limbs

Supine
1.4: Anatomical Terminology

supplemental motor area
13.5: Taste and Smell

supporting cell
13.3: Hearing and Balance

supportive connective tissue
3.4: Connective Tissue

suprachiasmatic nucleus
13.4: Vision

supraglenoid tubercle
6.6: The Pectoral Girdle

suprahyoid muscles
9.4: Axial Muscles of the Head, Neck, and Back

supraorbital foramen
6.3: The Skull

supraorbital margin
6.3: The Skull

suprascapular notch
6.6: The Pectoral Girdle

supraspinatus
9.6: Appendicular Muscles of the Pectoral Girdle and Upper Limbs

supraspinous fossa
6.6: The Pectoral Girdle

supraspinous ligament
6.4: The Vertebral Column

surgical neck
6.7: Bones of the Upper Limb

suspensory ligaments
13.3: Hearing and Balance
23.3: Anatomy of the Female Reproductive System

sustentaculum tali
6.9: Bones of the Lower Limb

suture
6.3: The Skull

sympathetic chain ganglia
14.2: Divisions of the Autonomic Nervous System

sympathetic division
14.2: Divisions of the Autonomic Nervous System

sympathetic trunks
14.2: Divisions of the Autonomic Nervous System

synapse
10.3: Anatomy of Nervous Tissue

synaptic cleft
10.4: Synapses
8.3: Skeletal Muscle Organ Structure

synaptic end bulb
10.3: Anatomy of Nervous Tissue

synarthrosis
7.2: Classification of Joints

syncytiotrophoblast
24.3: Embryonic Development

synergist
9.2: Interactions of Skeletal Muscles, Their Fascicle Arrangement, and Their Lever Systems

synovial fluid
7.3: Synovial Joints

synovial joint
7.2: Classification of Joints

synovial membrane
3.2: Types of Tissues
7.3: Synovial Joints

Systemic Anatomy
1.2: Overview of Anatomy

systemic circuit
17.2: Heart Anatomy

systemic nerve
12.4: Spinal Nerves and Their Branches

systole
17.4: Coronary Circulation

T

T cell
19.3: Anatomy of Lymphatic Vessels

T lymphocytes
16.4: Leukocytes and Platelets

T wave
17.3: Cardiac Muscle and Electrical Activity

talocrural joint
7.5: Anatomy of Selected Synovial Joints

talus
6.9: Bones of the Lower Limb

target effector
14.2: Divisions of the Autonomic Nervous System

tarsal bone
6.9: Bones of the Lower Limb

tarsal gland
13.3: Hearing and Balance

tarsal muscle
13.3: Hearing and Balance

tectorial membrane
13.3: Hearing and Balance

tectospinal tract
13.5: Taste and Smell

tectum
11.4: Brain - Diencephalon, Brainstem, Cerebellum and Limbic System

tegmentum
11.4: Brain - Diencephalon, Brainstem, Cerebellum and Limbic System

telencephalon
10.5: Development of the Nervous System

telogen
4.3: Accessory Structures of the Skin

telophase
2.5: Cell Growth and Division

temporal bone
6.3: The Skull

temporal fossa
6.3: The Skull

temporal lobe
11.3: Brain - Cerebrum

temporal process of the zygomatic bone
6.3: The Skull

temporal vein
18.3: Circulatory Pathways

temporalis
9.4: Axial Muscles of the Head, Neck, and Back

temporomandibular joint (TMJ)
7.5: Anatomy of Selected Synovial Joints

tendinous intersections
9.5: Axial Muscles of the Abdominal Wall and Thorax

tendon
7.3: Synovial Joints

tendon sheath
7.3: Synovial Joints

tenia coli
21.6: Small and Large Intestines

tensor fascia lata
9.7: Appendicular Muscles of the Pelvic Girdle and Lower Limbs

tentorium cerebelli
11.2: Support and Protection of the Brain

teres major
9.6: Appendicular Muscles of the Pectoral Girdle and Upper Limbs

teres minor
9.6: Appendicular Muscles of the Pectoral Girdle and Upper Limbs

terminal branch
12.4: Spinal Nerves and Their Branches

terminal ganglia
14.2: Divisions of the Autonomic Nervous System

tertiary follicles
23.3: Anatomy of the Female Reproductive System

testes
23.2: Anatomy of the Male Reproductive System

testicular artery
18.3: Circulatory Pathways

testicular vein
18.3: Circulatory Pathways

testosterone
15.7: Gonadal and Placental Hormones

thalamic nuclei
11.4: Brain - Diencephalon, Brainstem, Cerebellum and Limbic System

thalamus
11.4: Brain - Diencephalon, Brainstem, Cerebellum and Limbic System
13.2: Sensory Modalities and General Senses
13.3: Hearing and Balance
13.4: Vision

thalassemia
16.3: Erythrocytes

theca cells
23.3: Anatomy of the Female Reproductive System

thermoreceptor
13.2: Sensory Modalities and General Senses

thick filament
8.3: Skeletal Muscle Organ Structure

thigh
6.9: Bones of the Lower Limb

thin filament
8.3: Skeletal Muscle Organ Structure

third ventricle
11.2: Support and Protection of the Brain

thoracic aorta
18.3: Circulatory Pathways

thoracic cage
6.2: Divisions of the Skeletal System

thoracic cavity
1.4: Anatomical Terminology

thoracic curve
6.4: The Vertebral Column

thoracic duct
19.3: Anatomy of Lymphatic Vessels

thoracic vertebrae
6.4: The Vertebral Column

thoracic wall compliance
20.4: Respiratory Zone

thoracolumbar system
14.2: Divisions of the Autonomic Nervous System

thoroughfare channel
18.2: Structure and Function of Blood Vessels

threshold
10.4: Synapses

thrombocytes
16.4: Leukocytes and Platelets

thrombocytopenia
16.4: Leukocytes and Platelets

thrombocytosis
16.4: Leukocytes and Platelets

thrombopoietin
16.5: Production of the Formed Elements

thymocyte
19.3: Anatomy of Lymphatic Vessels

thymosins
15.9: Organs with Secondary Endocrine Functions

thymus
15.9: Organs with Secondary Endocrine Functions
19.3: Anatomy of Lymphatic Vessels

thyrocervical artery
18.3: Circulatory Pathways

thyrohyoid
9.4: Axial Muscles of the Head, Neck, and Back

thyroid cartilage
20.3: Conducting Zone

thyroid gland
15.4: Thyroid Gland and Parathyroid Glands

thyroxine
15.4: Thyroid Gland and Parathyroid Glands

tibia
6.9: Bones of the Lower Limb

tibial collateral ligament
7.5: Anatomy of Selected Synovial Joints

tibial nerve
12.4: Spinal Nerves and Their Branches

tibialis anterior
9.7: Appendicular Muscles of the Pelvic Girdle and Lower Limbs

tibialis posterior
9.7: Appendicular Muscles of the Pelvic Girdle and Lower Limbs

tidal volume (TV)
20.4: Respiratory Zone

tight junction
3.3: Epithelial Tissue

tissue
1.3: Structural Organization of the Human Body
3.2: Types of Tissues

tissue membrane
3.2: Types of Tissues

tongue
21.4: Mouth, Pharynx, and Esophagus

tonsils
19.3: Anatomy of Lymphatic Vessels

topographical
13.4: Vision

total dead space
20.4: Respiratory Zone

total lung capacity (TLC)
20.4: Respiratory Zone

totipotent
2.6: Cellular Differentiation
3.2: Types of Tissues

totipotent stem cell
16.5: Production of the Formed Elements

trabeculae
5.3: Bone Structure

trabeculae carneae
17.2: Heart Anatomy

trachea
20.3: Conducting Zone

trachealis muscle
20.3: Conducting Zone

tract
10.2: Organization and Functions of the Nervous System
11.3: Brain - Cerebrum

transcription factor
2.6: Cellular Differentiation

transient ischemic attack (TIA)
18.3: Circulatory Pathways

transitional cell
13.2: Sensory Modalities and General Senses
transitional epithelium
3.3: Epithelial Tissue
transpulmonary pressure
20.4: Respiratory Zone
transverse colon
21.6: Small and Large Intestines
transverse foramen
6.4: The Vertebral Column
transverse plane
1.4: Anatomical Terminology
transverse process
6.4: The Vertebral Column
transverse sinuses
11.2: Support and Protection of the Brain
18.3: Circulatory Pathways
transversus abdominis
9.5: Axial Muscles of the Abdominal Wall and Thorax
trapezium
6.7: Bones of the Upper Limb
trapezius
9.6: Appendicular Muscles of the Pectoral Girdle and Upper Limbs
trapezoid
6.7: Bones of the Upper Limb
tri
9.3: Naming Skeletal Muscles
triad
8.3: Skeletal Muscle Organ Structure
triceps brachii
9.6: Appendicular Muscles of the Pectoral Girdle and Upper Limbs
tricuspid valve
17.2: Heart Anatomy
trigeminal ganglion
12.3: Cranial Nerves
trigeminal nerve
12.3: Cranial Nerves
trigone
22.4: Urinary Tract
triiodothyronine
15.4: Thyroid Gland and Parathyroid Glands
trimester
24.5: Maternal Changes During Pregnancy, Labor, and Birth
triquetrum
6.7: Bones of the Upper Limb
trochlea
13.3: Hearing and Balance
6.7: Bones of the Upper Limb
trochlear nerve
12.3: Cranial Nerves
13.3: Hearing and Balance
trochlear notch
6.7: Bones of the Upper Limb
trophoblast
24.3: Embryonic Development
tropomyosin
8.3: Skeletal Muscle Organ Structure
troponin
8.3: Skeletal Muscle Organ Structure
true labor
24.5: Maternal Changes During Pregnancy, Labor, and Birth
true ribs
6.5: The Thoracic Cage
true vocal cord
20.3: Conducting Zone
truncus arteriosus
17.5: Development of the Heart
trunk
12.4: Spinal Nerves and Their Branches
18.3: Circulatory Pathways
tubercle of the rib
6.5: The Thoracic Cage
tunica externa
18.2: Structure and Function of Blood Vessels
tunica intima
18.2: Structure and Function of Blood Vessels
tunica media
18.2: Structure and Function of Blood Vessels
tympanic membrane
13.3: Hearing and Balance
type I alveolar cell
20.3: Conducting Zone
type II alveolar cell
20.3: Conducting Zone

U

ulna
6.7: Bones of the Upper Limb
ulnar artery
18.3: Circulatory Pathways
ulnar collateral ligament
7.5: Anatomy of Selected Synovial Joints
ulnar nerve
12.4: Spinal Nerves and Their Branches
ulnar notch of the radius
6.7: Bones of the Upper Limb
ulnar tuberosity
6.7: Bones of the Upper Limb
ulnar vein
18.3: Circulatory Pathways
Ultrasonography
1.5: Medical Imaging
umbilical arteries
18.4: Development of Blood Vessels and Fetal Circulation
umbilical cord
24.3: Embryonic Development
umbilical vein
18.4: Development of Blood Vessels and Fetal Circulation
uniaxial joint
7.2: Classification of Joints
unipennate
9.2: Interactions of Skeletal Muscles, Their Fascicle Arrangement, and Their Lever Systems
unipolar
10.3: Anatomy of Nervous Tissue
unipotent
2.6: Cellular Differentiation
unmyelinated
10.3: Anatomy of Nervous Tissue
upper esophageal sphincter
21.4: Mouth, Pharynx, and Esophagus
urinary system
22: Urinary System
urogenital triangle
9.5: Axial Muscles of the Abdominal Wall and Thorax
uterine tubes
23.3: Anatomy of the Female Reproductive System
uterus
23.3: Anatomy of the Female Reproductive System
utricle
13.3: Hearing and Balance

V

vagina
23.3: Anatomy of the Female Reproductive System
vagus nerve
12.3: Cranial Nerves
vagus nerve (CN X)
14.2: Divisions of the Autonomic Nervous System
Valsalva's maneuver
21.6: Small and Large Intestines
valve
17.2: Heart Anatomy
varicosity
14.3: Autonomic Synapses and Effects
vasa vasorum
18.2: Structure and Function of Blood Vessels
vascular shunt
18.2: Structure and Function of Blood Vessels
vascular tubes
18.4: Development of Blood Vessels and Fetal Circulation
vascular tunic
13.3: Hearing and Balance
vasoconstriction
18.2: Structure and Function of Blood Vessels
vasodilation
18.2: Structure and Function of Blood Vessels
3.7: Tissue Injury and Aging
vasomotion
18.2: Structure and Function of Blood Vessels
vasomotor nerves
14.4: Central Control of Autonomic Function
vastus lateralis
9.7: Appendicular Muscles of the Pelvic Girdle and Lower Limbs
vastus medialis
9.7: Appendicular Muscles of the Pelvic Girdle and Lower Limbs
vein
18.2: Structure and Function of Blood Vessels
venous reserve
18.2: Structure and Function of Blood Vessels
Ventral
1.4: Anatomical Terminology
ventral (anterior) nerve root
12.4: Spinal Nerves and Their Branches
ventral cavity
1.4: Anatomical Terminology
ventral posterior nucleus
13.4: Vision
ventral ramus
12.4: Spinal Nerves and Their Branches

ventral respiratory group (VRG)
20.4: Respiratory Zone
Ventricle
10.3: Anatomy of Nervous Tissue
17.2: Heart Anatomy
ventricles
11.2: Support and Protection of the Brain
ventricular ejection phase
17.4: Coronary Circulation
venule
18.2: Structure and Function of Blood Vessels
vermis
11.4: Brain - Diencephalon, Brainstem, Cerebellum and Limbic System
vernix caseosa
24.4: Fetal Development
vertebra
6.2: Divisions of the Skeletal System
vertebral (spinal) canal
6.4: The Vertebral Column
vertebral arch
6.4: The Vertebral Column
vertebral arteries
11.2: Support and Protection of the Brain
vertebral artery
18.3: Circulatory Pathways
vertebral column
6.2: Divisions of the Skeletal System
vertebral foramen
6.4: The Vertebral Column
vertebral vein
18.3: Circulatory Pathways
Vesicle
2.2: The Cell Membrane
vestibular fold
20.3: Conducting Zone
vestibular membrane
13.3: Hearing and Balance
vestibular nerve
13.3: Hearing and Balance
vestibular nuclei
13.4: Vision
vestibular system
13.3: Hearing and Balance
vestibule
13.3: Hearing and Balance
vestibulocochlear nerve
12.3: Cranial Nerves
13.3: Hearing and Balance
vestibulospinal tract
13.5: Taste and Smell
villus
21.6: Small and Large Intestines
visceral branches
18.3: Circulatory Pathways
visceral pleura
20.2: The Lungs
visceral reflex
14.3: Autonomic Synapses and Effects
visceral sense
10.2: Organization and Functions of the Nervous System
13.2: Sensory Modalities and General Senses
vision
13.3: Hearing and Balance
visual acuity
13.3: Hearing and Balance
visual association areas
11.3: Brain - Cerebrum
Vitamin D
4.4: Functions of the Integumentary System
vitiligo
4.2: Layers of the Skin
vitreous humor
13.3: Hearing and Balance
voluntary phase
21.4: Mouth, Pharynx, and Esophagus
vomer bone
6.3: The Skull
vulva
23.3: Anatomy of the Female Reproductive System

W

Wernicke's area
11.3: Brain - Cerebrum
white matter
10.2: Organization and Functions of the Nervous System
white rami communicantes
14.2: Divisions of the Autonomic Nervous System
withdrawal reflex
13.5: Taste and Smell
Wolffian duct
23.4: Development of the Male and Female Reproductive Systems
working memory
13.5: Taste and Smell
wound contraction
3.7: Tissue Injury and Aging

Y

yellow marrow
5.2: Functions of the Skeletal System

Z

zona fasciculata
15.5: Adrenal Glands
zona glomerulosa
15.5: Adrenal Glands
zona pellucida
24.2: Fertilization
zona reticularis
15.5: Adrenal Glands
zone of calcified matrix
5.4: Bone Formation and Development
zone of maturation and hypertrophy
5.4: Bone Formation and Development
zygomatic arch
6.3: The Skull
zygomatic bone
6.3: The Skull
zygomatic process of the temporal bone
6.3: The Skull
zygote
24.2: Fertilization

This page titled Index is shared under a CC BY-NC-SA 4.0 license and was authored, remixed, and/or curated by Jennifer Lange et al..

GLOSSARY

Interactive Content

This interactive element is not available in this format. Visit the link or scan the QR code to access it online.

View this Interactive Content online

If the glossary does not display above, open it in a new tab.

This page titled Glossary is shared under a CC BY-NC-SA 4.0 license and was authored, remixed, and/or curated by Jennifer Lange et al..

DETAILED LICENSING

Overview

Title: General Human Anatomy (Lange et al.)

Webpages: 216

Applicable Restrictions: Noncommercial

All licenses found:

- CC BY-NC-SA 4.0: 99.5% (215 pages)
- Undeclared: 0.5% (1 page)

By Page

- General Human Anatomy (Lange et al.) - *CC BY-NC-SA 4.0*
  - Front Matter - *CC BY-NC-SA 4.0*
    - TitlePage - *CC BY-NC-SA 4.0*
    - InfoPage - *CC BY-NC-SA 4.0*
    - ProgramPage - *CC BY-NC-SA 4.0*
    - Table of Contents - *Undeclared*
    - Licensing - *CC BY-NC-SA 4.0*
    - Preface and Acknowledgements - *CC BY-NC-SA 4.0*
    - About the Authors - *CC BY-NC-SA 4.0*
  - 1: An Introduction to the Human Body - *CC BY-NC-SA 4.0*
    - 1.1: Introduction to the Human Body - *CC BY-NC-SA 4.0*
    - 1.2: Overview of Anatomy - *CC BY-NC-SA 4.0*
    - 1.3: Structural Organization of the Human Body - *CC BY-NC-SA 4.0*
    - 1.4: Anatomical Terminology - *CC BY-NC-SA 4.0*
    - 1.5: Medical Imaging - *CC BY-NC-SA 4.0*
    - 1.6: Anatomical Atlas - Anatomical Terminology - *CC BY-NC-SA 4.0*
    - 1.7: Practice Practical - Anatomy Introduction - *CC BY-NC-SA 4.0*
  - 2: Cellular Level of Organization - *CC BY-NC-SA 4.0*
    - 2.1: Introduction to the Cellular Level of Organization - *CC BY-NC-SA 4.0*
    - 2.2: The Cell Membrane - *CC BY-NC-SA 4.0*
    - 2.3: The Cytoplasm and Cellular Organelles - *CC BY-NC-SA 4.0*
    - 2.4: The Nucleus - *CC BY-NC-SA 4.0*
    - 2.5: Cell Growth and Division - *CC BY-NC-SA 4.0*
    - 2.6: Cellular Differentiation - *CC BY-NC-SA 4.0*
  - 3: Tissue Level of Organization - *CC BY-NC-SA 4.0*
    - 3.1: Introduction to the Tissue Level of Organization - *CC BY-NC-SA 4.0*
    - 3.2: Types of Tissues - *CC BY-NC-SA 4.0*
    - 3.3: Epithelial Tissue - *CC BY-NC-SA 4.0*
    - 3.4: Connective Tissue - *CC BY-NC-SA 4.0*
    - 3.5: Muscle Tissue - *CC BY-NC-SA 4.0*
    - 3.6: Nervous Tissue - *CC BY-NC-SA 4.0*
    - 3.7: Tissue Injury and Aging - *CC BY-NC-SA 4.0*
    - 3.8: Anatomical Atlas - Tissues - *CC BY-NC-SA 4.0*
    - 3.9: Practice Practical- Tissues - *CC BY-NC-SA 4.0*
  - 4: Integumentary System - *CC BY-NC-SA 4.0*
    - 4.1: Introduction to the Integumentary System - *CC BY-NC-SA 4.0*
    - 4.2: Layers of the Skin - *CC BY-NC-SA 4.0*
    - 4.3: Accessory Structures of the Skin - *CC BY-NC-SA 4.0*
    - 4.4: Functions of the Integumentary System - *CC BY-NC-SA 4.0*
    - 4.5: Diseases, Disorders, and Injuries of the Integumentary System - *CC BY-NC-SA 4.0*
    - 4.6: Anatomical Atlas - Integumentary System - *CC BY-NC-SA 4.0*
    - 4.7: Practice Practical - Integumentary System - *CC BY-NC-SA 4.0*
  - 5: Bone Tissue and Skeletal System - *CC BY-NC-SA 4.0*
    - 5.1: Introduction to Bone Tissue and the Skeletal System - *CC BY-NC-SA 4.0*
    - 5.2: Functions of the Skeletal System - *CC BY-NC-SA 4.0*
    - 5.3: Bone Structure - *CC BY-NC-SA 4.0*
    - 5.4: Bone Formation and Development - *CC BY-NC-SA 4.0*
    - 5.5: Fractures and Bone Repair - *CC BY-NC-SA 4.0*
    - 5.6: Exercise, Nutrition, Hormones, and Bone Tissue Health - *CC BY-NC-SA 4.0*
    - 5.7: Bone Classification - *CC BY-NC-SA 4.0*
    - 5.8: Anatomical Atlas - Bone Tissue and Bone

Structure - *CC BY-NC-SA 4.0*
- 5.9: Practice Practical - Bone Tissue and Bone Structure - *CC BY-NC-SA 4.0*

- 6: Axial and Appendicular Skeleton - *CC BY-NC-SA 4.0*
  - 6.1: Introduction to the Skeleton System - *CC BY-NC-SA 4.0*
  - 6.2: Divisions of the Skeletal System - *CC BY-NC-SA 4.0*
  - 6.3: The Skull - *CC BY-NC-SA 4.0*
  - 6.4: The Vertebral Column - *CC BY-NC-SA 4.0*
  - 6.5: The Thoracic Cage - *CC BY-NC-SA 4.0*
  - 6.6: The Pectoral Girdle - *CC BY-NC-SA 4.0*
  - 6.7: Bones of the Upper Limb - *CC BY-NC-SA 4.0*
  - 6.8: The Pelvic Girdle and Pelvis - *CC BY-NC-SA 4.0*
  - 6.9: Bones of the Lower Limb - *CC BY-NC-SA 4.0*
  - 6.10: Embryonic Development of the Skeleton - *CC BY-NC-SA 4.0*
  - 6.11: Anatomical Atlas - Skeleton - *CC BY-NC-SA 4.0*
  - 6.12: Practice Practical - Skeleton - *CC BY-NC-SA 4.0*
- 7: Joints - *CC BY-NC-SA 4.0*
  - 7.1: Introduction - *CC BY-NC-SA 4.0*
  - 7.2: Classification of Joints - *CC BY-NC-SA 4.0*
  - 7.3: Synovial Joints - *CC BY-NC-SA 4.0*
  - 7.4: Types of Body Movements - *CC BY-NC-SA 4.0*
  - 7.5: Anatomy of Selected Synovial Joints - *CC BY-NC-SA 4.0*
  - 7.6: Diseases and Injuries of Joints - *CC BY-NC-SA 4.0*
  - 7.7: Anatomical Atlas - Joints - *CC BY-NC-SA 4.0*
  - 7.8: Practice Practical - Joints - *CC BY-NC-SA 4.0*
- 8: Muscle Tissues and Muscle Structure - *CC BY-NC-SA 4.0*
  - 8.1: Introduction to Muscle Tissue - *CC BY-NC-SA 4.0*
  - 8.2: Muscle Tissues - *CC BY-NC-SA 4.0*
  - 8.3: Skeletal Muscle Organ Structure - *CC BY-NC-SA 4.0*
  - 8.4: Development and Regeneration of Muscle Tissue - *CC BY-NC-SA 4.0*
  - 8.5: Anatomical Atlas - Muscle Tissues - *CC BY-NC-SA 4.0*
  - 8.6: Practice Practical- Muscle Tissues - *CC BY-NC-SA 4.0*
- 9: Muscular System - *CC BY-NC-SA 4.0*
  - 9.1: Introduction to the Muscular System - *CC BY-NC-SA 4.0*
  - 9.2: Interactions of Skeletal Muscles, Their Fascicle Arrangement, and Their Lever Systems - *CC BY-NC-SA 4.0*
  - 9.3: Naming Skeletal Muscles - *CC BY-NC-SA 4.0*
  - 9.4: Axial Muscles of the Head, Neck, and Back - *CC BY-NC-SA 4.0*
  - 9.5: Axial Muscles of the Abdominal Wall and Thorax - *CC BY-NC-SA 4.0*
  - 9.6: Appendicular Muscles of the Pectoral Girdle and Upper Limbs - *CC BY-NC-SA 4.0*
  - 9.7: Appendicular Muscles of the Pelvic Girdle and Lower Limbs - *CC BY-NC-SA 4.0*
  - 9.8: Anatomical Atlas - Muscular System - *CC BY-NC-SA 4.0*
  - 9.9: Practice Practical- Muscles - *CC BY-NC-SA 4.0*
- 10: Nervous System and Nervous Tissue - *CC BY-NC-SA 4.0*
  - 10.1: Introduction to the Nervous System - *CC BY-NC-SA 4.0*
  - 10.2: Organization and Functions of the Nervous System - *CC BY-NC-SA 4.0*
  - 10.3: Anatomy of Nervous Tissue - *CC BY-NC-SA 4.0*
  - 10.4: Synapses - *CC BY-NC-SA 4.0*
  - 10.5: Development of the Nervous System - *CC BY-NC-SA 4.0*
  - 10.6: Anatomical Atlas - Nervous Tissue - *CC BY-NC-SA 4.0*
  - 10.7: Practice Practical - Nervous Tissue - *CC BY-NC-SA 4.0*
- 11: Central Nervous System - *CC BY-NC-SA 4.0*
  - 11.1: Introduction to the Central Nervous System - *CC BY-NC-SA 4.0*
  - 11.2: Support and Protection of the Brain - *CC BY-NC-SA 4.0*
  - 11.3: Brain - Cerebrum - *CC BY-NC-SA 4.0*
  - 11.4: Brain - Diencephalon, Brainstem, Cerebellum and Limbic System - *CC BY-NC-SA 4.0*
  - 11.5: Spinal Cord - *CC BY-NC-SA 4.0*
  - 11.6: Anatomical Atlas - Central Nervous System - *CC BY-NC-SA 4.0*
  - 11.7: Practice Practical - Central Nervous System - *CC BY-NC-SA 4.0*
- 12: Peripheral Nervous System - *CC BY-NC-SA 4.0*
  - 12.1: Introduction to the Peripheral Nervous System - *CC BY-NC-SA 4.0*
  - 12.2: Nerve and Ganglion Structure - *CC BY-NC-SA 4.0*
  - 12.3: Cranial Nerves - *CC BY-NC-SA 4.0*
  - 12.4: Spinal Nerves and Their Branches - *CC BY-NC-SA 4.0*
  - 12.5: Anatomical Atlas - Peripheral Nervous System - *CC BY-NC-SA 4.0*
  - 12.6: Practice Practical - *CC BY-NC-SA 4.0*
- 13: Somatic Senses - *CC BY-NC-SA 4.0*
  - 13.1: Introduction to the Somatic Senses - *CC BY-NC-SA 4.0*
  - 13.2: Sensory Modalities and General Senses -

CC BY-NC-SA 4.0
- 13.3: Hearing and Balance - CC BY-NC-SA 4.0
- 13.4: Vision - CC BY-NC-SA 4.0
- 13.5: Taste and Smell - CC BY-NC-SA 4.0
- 13.6: Anatomical Atlas - Somatic Senses - CC BY-NC-SA 4.0
- 13.7: Practice Practical - Somatic Senses - CC BY-NC-SA 4.0

◦ 14: Autonomic Nervous System - CC BY-NC-SA 4.0
- 14.1: Introduction to the Autonomic Nervous System - CC BY-NC-SA 4.0
- 14.2: Divisions of the Autonomic Nervous System - CC BY-NC-SA 4.0
- 14.3: Autonomic Synapses and Effects - CC BY-NC-SA 4.0
- 14.4: Central Control of Autonomic Function - CC BY-NC-SA 4.0
- 14.5: Anatomical Atlas - Autonomic Nervous System - CC BY-NC-SA 4.0
- 14.6: Practice Practical - ANS - CC BY-NC-SA 4.0

◦ 15: Endocrine System - CC BY-NC-SA 4.0
- 15.1: Introduction to the Endocrine System - CC BY-NC-SA 4.0
- 15.2: An Overview of the Endocrine System - CC BY-NC-SA 4.0
- 15.3: Pituitary Gland and Hypothalamus - CC BY-NC-SA 4.0
- 15.4: Thyroid Gland and Parathyroid Glands - CC BY-NC-SA 4.0
- 15.5: Adrenal Glands - CC BY-NC-SA 4.0
- 15.6: Pineal Gland - CC BY-NC-SA 4.0
- 15.7: Gonadal and Placental Hormones - CC BY-NC-SA 4.0
- 15.8: Endocrine Pancreas - CC BY-NC-SA 4.0
- 15.9: Organs with Secondary Endocrine Functions - CC BY-NC-SA 4.0
- 15.10: Development and Aging of the Endocrine System - CC BY-NC-SA 4.0
- 15.11: Anatomical Atlas - Endocrine System - CC BY-NC-SA 4.0
- 15.12: Practice Practical- Endocrine System - CC BY-NC-SA 4.0

◦ 16: Cardiovascular System - Blood - CC BY-NC-SA 4.0
- 16.1: Introduction to Blood - CC BY-NC-SA 4.0
- 16.2: An Overview of Blood - CC BY-NC-SA 4.0
- 16.3: Erythrocytes - CC BY-NC-SA 4.0
- 16.4: Leukocytes and Platelets - CC BY-NC-SA 4.0
- 16.5: Production of the Formed Elements - CC BY-NC-SA 4.0
- 16.6: Anatomical Atlas - Blood - CC BY-NC-SA 4.0
- 16.7: Practice Practical- Blood - CC BY-NC-SA 4.0

◦ 17: Cardiovascular System - Heart - CC BY-NC-SA 4.0
- 17.1: Introduction to the Heart - CC BY-NC-SA 4.0
- 17.2: Heart Anatomy - CC BY-NC-SA 4.0
- 17.3: Cardiac Muscle and Electrical Activity - CC BY-NC-SA 4.0
- 17.4: Coronary Circulation - CC BY-NC-SA 4.0
- 17.5: Development of the Heart - CC BY-NC-SA 4.0
- 17.6: Anatomical Atlas - Heart - CC BY-NC-SA 4.0
- 17.7: Practice Practical- Heart - CC BY-NC-SA 4.0

◦ 18: Cardiovascular System - Blood Vessels - CC BY-NC-SA 4.0
- 18.1: Introduction to Blood Vessels and Circulation - CC BY-NC-SA 4.0
- 18.2: Structure and Function of Blood Vessels - CC BY-NC-SA 4.0
- 18.3: Circulatory Pathways - CC BY-NC-SA 4.0
- 18.4: Development of Blood Vessels and Fetal Circulation - CC BY-NC-SA 4.0
- 18.5: Anatomical Atlas - Blood Vessels and Circulation - CC BY-NC-SA 4.0
- 18.6: Practice Practical- Blood Vessels and Circulation - CC BY-NC-SA 4.0

◦ 19: Lymphatic System - CC BY-NC-SA 4.0
- 19.1: Introduction to the Lymphatic System - CC BY-NC-SA 4.0
- 19.2: Functions of the Lymphatic System - CC BY-NC-SA 4.0
- 19.3: Anatomy of Lymphatic Vessels - CC BY-NC-SA 4.0
- 19.4: Anatomy of Lymphatic Organs and Tissues - CC BY-NC-SA 4.0
- 19.5: Anatomical Atlas - Lymphatic System - CC BY-NC-SA 4.0
- 19.6: Practice Practical- Lymphatic System - CC BY-NC-SA 4.0

◦ 20: Respiratory System - CC BY-NC-SA 4.0
- 20.1: Introduction to the Respiratory System - CC BY-NC-SA 4.0
- 20.2: The Lungs - CC BY-NC-SA 4.0
- 20.3: Conducting Zone - CC BY-NC-SA 4.0
- 20.4: Respiratory Zone - CC BY-NC-SA 4.0
- 20.5: Embryonic Development of the Respiratory System - CC BY-NC-SA 4.0
- 20.6: Anatomical Atlas - Respiratory System - CC BY-NC-SA 4.0
- 20.7: Practice Practical - the Respiratory System - CC BY-NC-SA 4.0

◦ 21: Digestive System - CC BY-NC-SA 4.0
- 21.1: Introduction to the Digestive System - CC BY-NC-SA 4.0
- 21.2: Organs of the Digestive System - CC BY-NC-SA 4.0
- 21.3: Digestive System Processes and Regulation - CC BY-NC-SA 4.0
- 21.4: Mouth, Pharynx, and Esophagus - CC BY-

NC-SA 4.0
- 21.5: Stomach - *CC BY-NC-SA 4.0*
- 21.6: Small and Large Intestines - *CC BY-NC-SA 4.0*
- 21.7: Accessory Organs - Liver, Pancreas, and Gallbladder - *CC BY-NC-SA 4.0*
- 21.8: Anatomical Atlas - Digestive System - *CC BY-NC-SA 4.0*
- 21.9: Practice Practical- Digestive system - *CC BY-NC-SA 4.0*

◦ 22: Urinary System - *CC BY-NC-SA 4.0*
- 22.1: Introduction to the Urinary System - *CC BY-NC-SA 4.0*
- 22.2: Overview of the Kidney - *CC BY-NC-SA 4.0*
- 22.3: Microscopic Anatomy of the Kidney - *CC BY-NC-SA 4.0*
- 22.4: Urinary Tract - *CC BY-NC-SA 4.0*
- 22.5: Anatomical Atlas - Urinary System - *CC BY-NC-SA 4.0*
- 22.6: Practice Practical- Urinary System - *CC BY-NC-SA 4.0*

◦ 23: Reproductive Systems - *CC BY-NC-SA 4.0*
- 23.1: Introduction to the Reproductive System - *CC BY-NC-SA 4.0*
- 23.2: Anatomy of the Male Reproductive System - *CC BY-NC-SA 4.0*
- 23.3: Anatomy of the Female Reproductive System - *CC BY-NC-SA 4.0*
- 23.4: Development of the Male and Female Reproductive Systems - *CC BY-NC-SA 4.0*
- 23.5: Practice Practical- the Reproductive System - *CC BY-NC-SA 4.0*
- 23.6: Anatomical Atlas - Reproductive Systems - *CC BY-NC-SA 4.0*

◦ 24: Embryology and Fetal Development - *CC BY-NC-SA 4.0*
- 24.1: Overview of Embryology and Fetal Development - *CC BY-NC-SA 4.0*
- 24.2: Fertilization - *CC BY-NC-SA 4.0*
- 24.3: Embryonic Development - *CC BY-NC-SA 4.0*
- 24.4: Fetal Development - *CC BY-NC-SA 4.0*
- 24.5: Maternal Changes During Pregnancy, Labor, and Birth - *CC BY-NC-SA 4.0*
- 24.6: Adjustments of the Infant at Birth and Postnatal Stages - *CC BY-NC-SA 4.0*
- 24.7: Lactation - *CC BY-NC-SA 4.0*

◦ Back Matter - *CC BY-NC-SA 4.0*
- Index - *CC BY-NC-SA 4.0*
- Glossary - *CC BY-NC-SA 4.0*
- Detailed Licensing - *CC BY-NC-SA 4.0*

This page titled General Human Anatomy (Lange et al.) is shared under a CC BY-NC-SA 4.0 license and was authored, remixed, and/or curated by Jennifer Lange et al..

- Human Anatomy (OERI) by Whitney Menefee, Julie Jenks, Chiara Mazzasette, and Kim-Leiloni Nguyen is licensed CC BY 4.0.