ATLAS OF COMPARATIVE VERTEBRATE ANATOMY

LibreTexts™

Atlas of Comparative Vertebrate Anatomy

This text is disseminated via the Open Education Resource (OER) LibreTexts Project (https://LibreTexts.org) and like the thousands of other texts available within this powerful platform, it is freely available for reading, printing, and "consuming."

The LibreTexts mission is to bring together students, faculty, and scholars in a collaborative effort to provide an accessible, and comprehensive platform that empowers our community to develop, curate, adapt, and adopt openly licensed resources and technologies; through these efforts we can reduce the financial burden born from traditional educational resource costs, ensuring education is more accessible for students and communities worldwide.

Most, but not all, pages in the library have licenses that may allow individuals to make changes, save, and print this book. Carefully consult the applicable license(s) before pursuing such effects. Instructors can adopt existing LibreTexts texts or Remix them to quickly build course-specific resources to meet the needs of their students. Unlike traditional textbooks, LibreTexts' web based origins allow powerful integration of advanced features and new technologies to support learning.

LibreTexts is the adaptable, user-friendly non-profit open education resource platform that educators trust for creating, customizing, and sharing accessible, interactive textbooks, adaptive homework, and ancillary materials. We collaborate with individuals and organizations to champion open education initiatives, support institutional publishing programs, drive curriculum development projects, and more.

The LibreTexts libraries are Powered by NICE CXone Expert and was supported by the Department of Education Open Textbook Pilot Project, the California Education Learning Lab, the UC Davis Office of the Provost, the UC Davis Library, the California State University Affordable Learning Solutions Program, and Merlot. This material is based upon work supported by the National Science Foundation under Grant No. 1246120, 1525057, and 1413739.

Any opinions, findings, and conclusions or recommendations expressed in this material are those of the author(s) and do not necessarily reflect the views of the National Science Foundation nor the US Department of Education.

Have questions or comments? For information about adoptions or adaptions contact info@LibreTexts.org or visit our main website at https://LibreTexts.org.

This text was compiled on 06/05/2026

TABLE OF CONTENTS

Licensing

1: Lamprey
- 1.1: Larval lamprey
- 1.2: Adult lamprey

2: Skeletal systems
- 2.1: Squalus skeleton
- 2.2: Necturus skull
- 2.3: Necturus skeleton
- 2.4: Pigeon skull
- 2.5: Pigeon skeleton
- 2.6: Turtle skull
- 2.7: Turtle skeleton
- 2.8: Cat skeleton- overview
- 2.9: Cat skull
- 2.10: Cat vertebral column
- 2.11: Cat scapula and ribs
- 2.12: Cat limbs

3: Nervous systems
- 3.1: Squalus brain
- 3.2: Sheep brain

4: Digestive systems
- 4.1: Squalus digestive system
- 4.2: Necturus digestive system
- 4.3: Cat digestive system

5: Muscular systems
- 5.1: Squalus musculature
- 5.2: Necturus musculature
- 5.3: Cat Musculature

6: Urogenital systems
- 6.1: Squalus urogenital systems
- 6.2: Necturus urogenital systems
- 6.3: Cat urogenital systems

7: Cardiovascular systems
- 7.1: Squalus vasculature
- 7.2: Cat Vasculature

Index

Glossary

Detailed Licensing

Licensing

*A detailed breakdown of this resource's licensing can be found in **Back Matter/Detailed Licensing**.*

CHAPTER OVERVIEW

1: Lamprey

1.1: Larval lamprey
1.2: Adult lamprey

1: Lamprey is shared under a CC BY 4.0 license and was authored, remixed, and/or curated by LibreTexts.

1.1: Larval lamprey

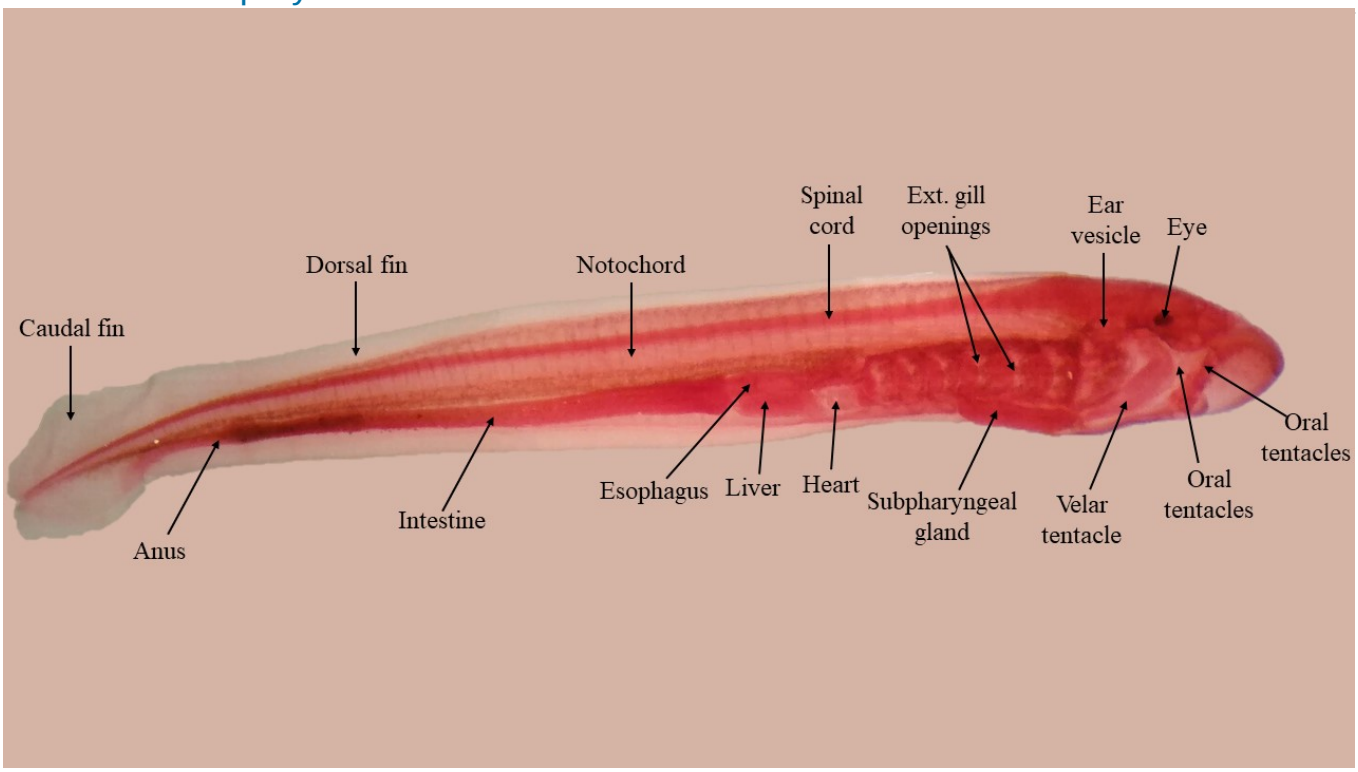

Whole mount of larval lamprey. CC-BY Kristen Roosa

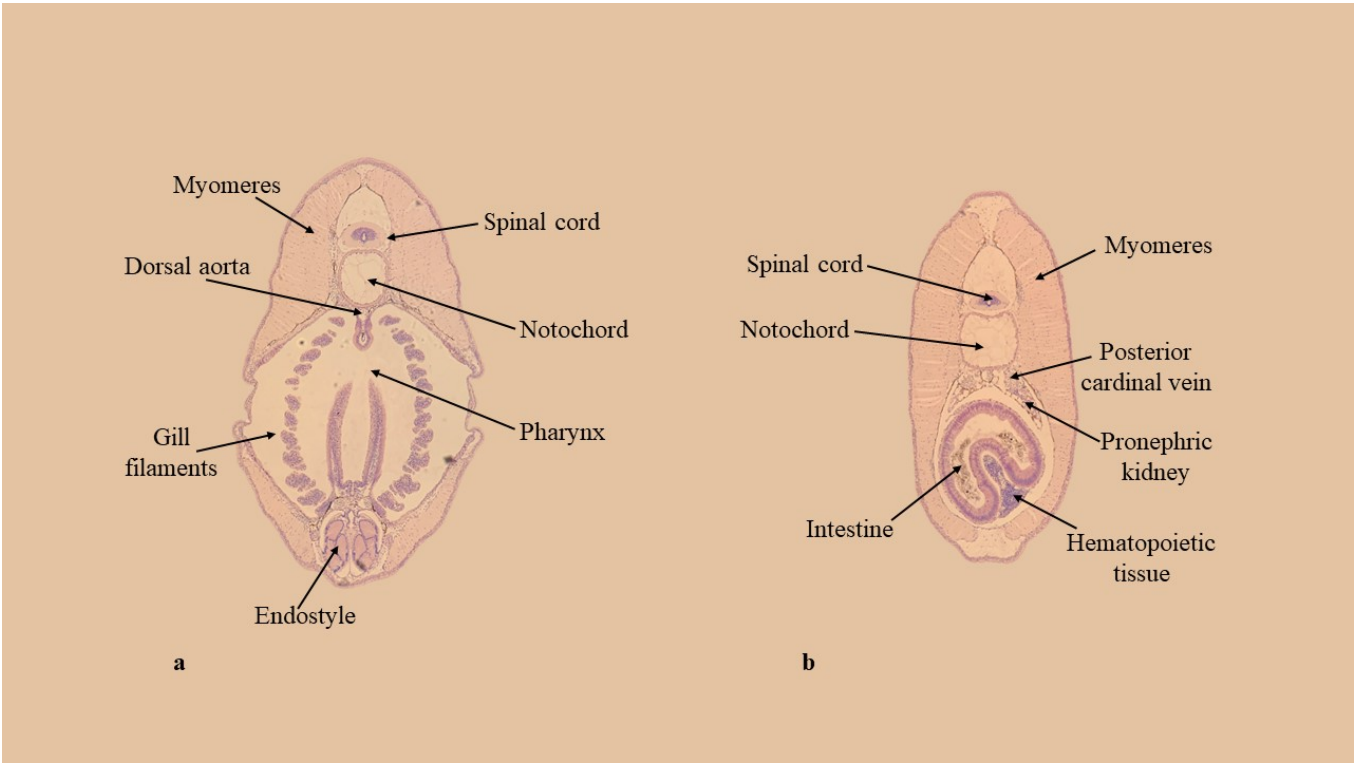

a. Cross section through pharynx of larval lamprey, b. Cross section through trunk region of larval lamprey. CC-BY Skylar Jackson.

Contributors and Attributions

- Lamprey anatomy. **Authored by**: Skylar Jackson & Kristen Roosa. **License**: *CC BY: Attribution*

1.1: Larval lamprey is shared under a CC BY 4.0 license and was authored, remixed, and/or curated by LibreTexts.

1.2: Adult lamprey

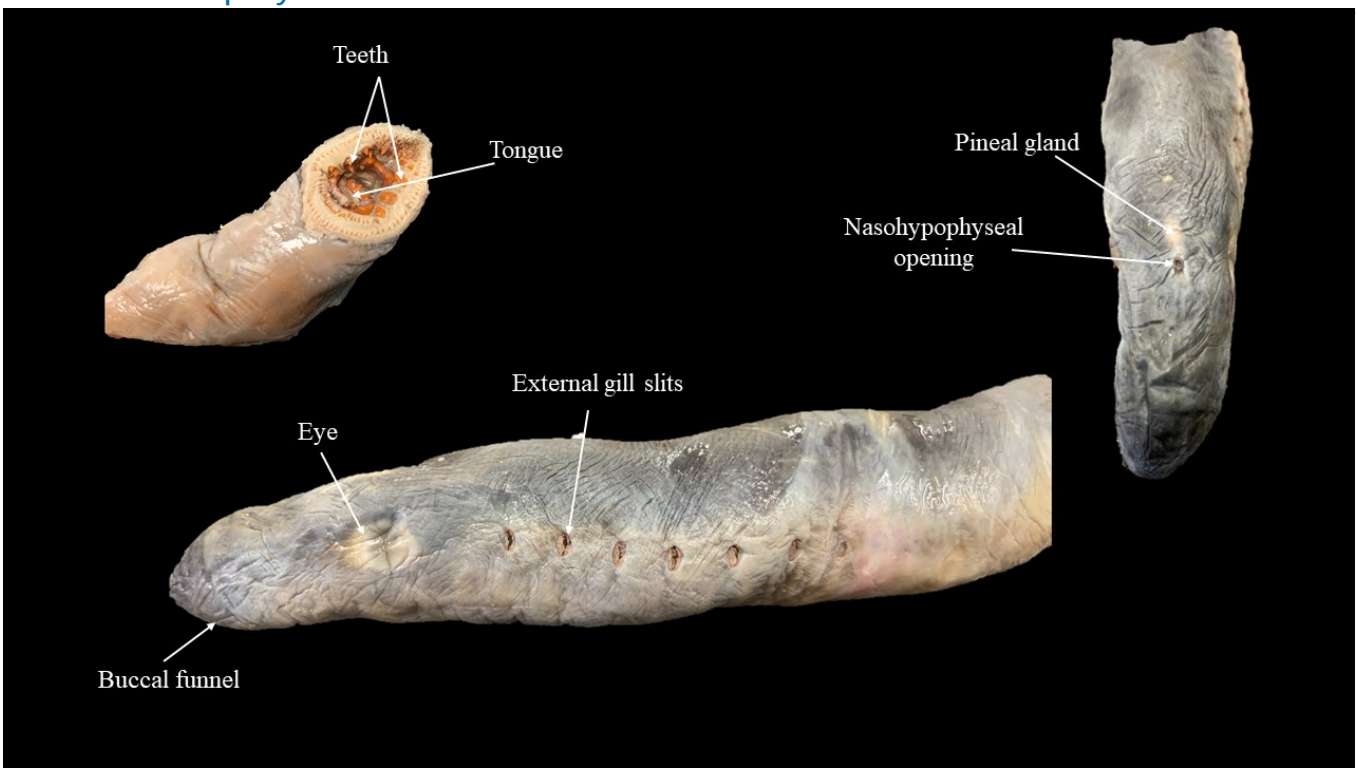

External anatomy of head and pharynx of adult lamprey. CC-BY Skylar Jackson.

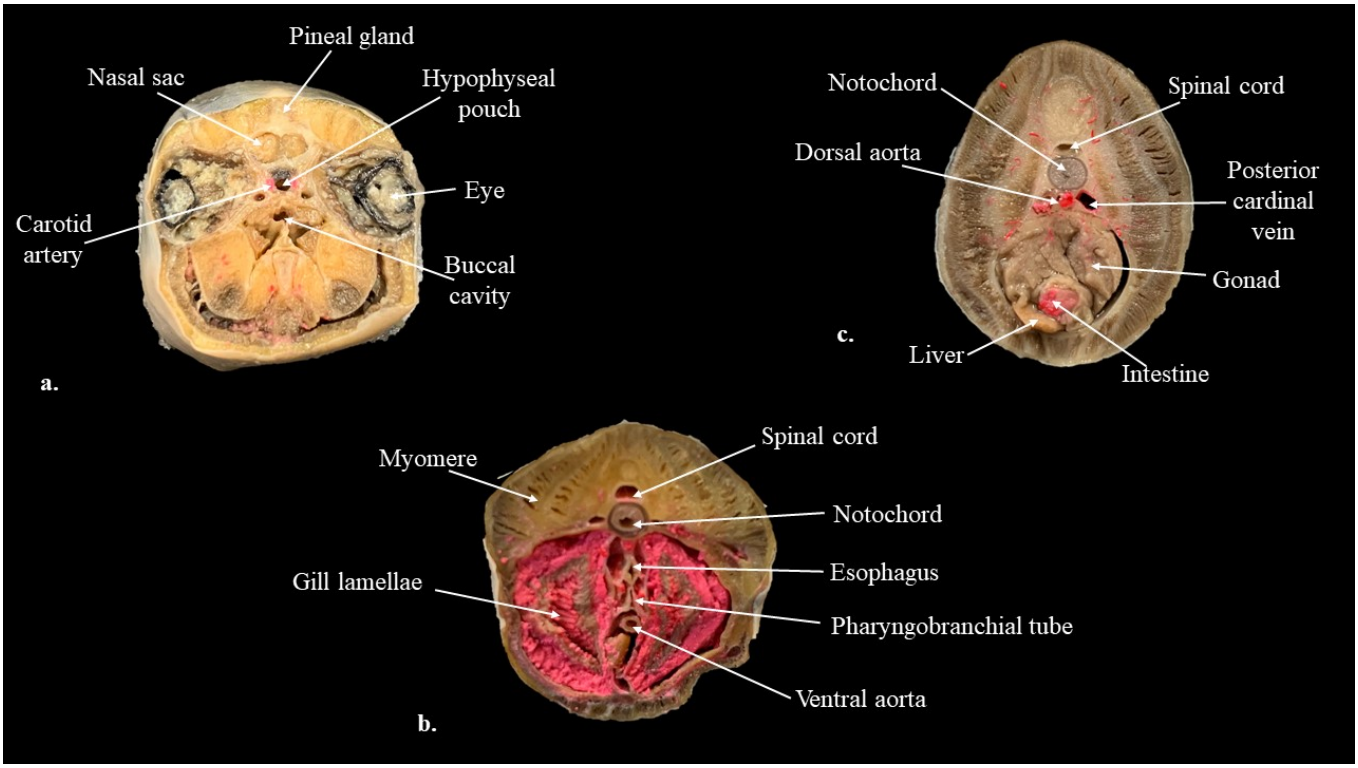

Transverse sections of the head (a), pharynx (b), and trunk (c) regions of the lamprey. CC-BY Skylar Jackson.

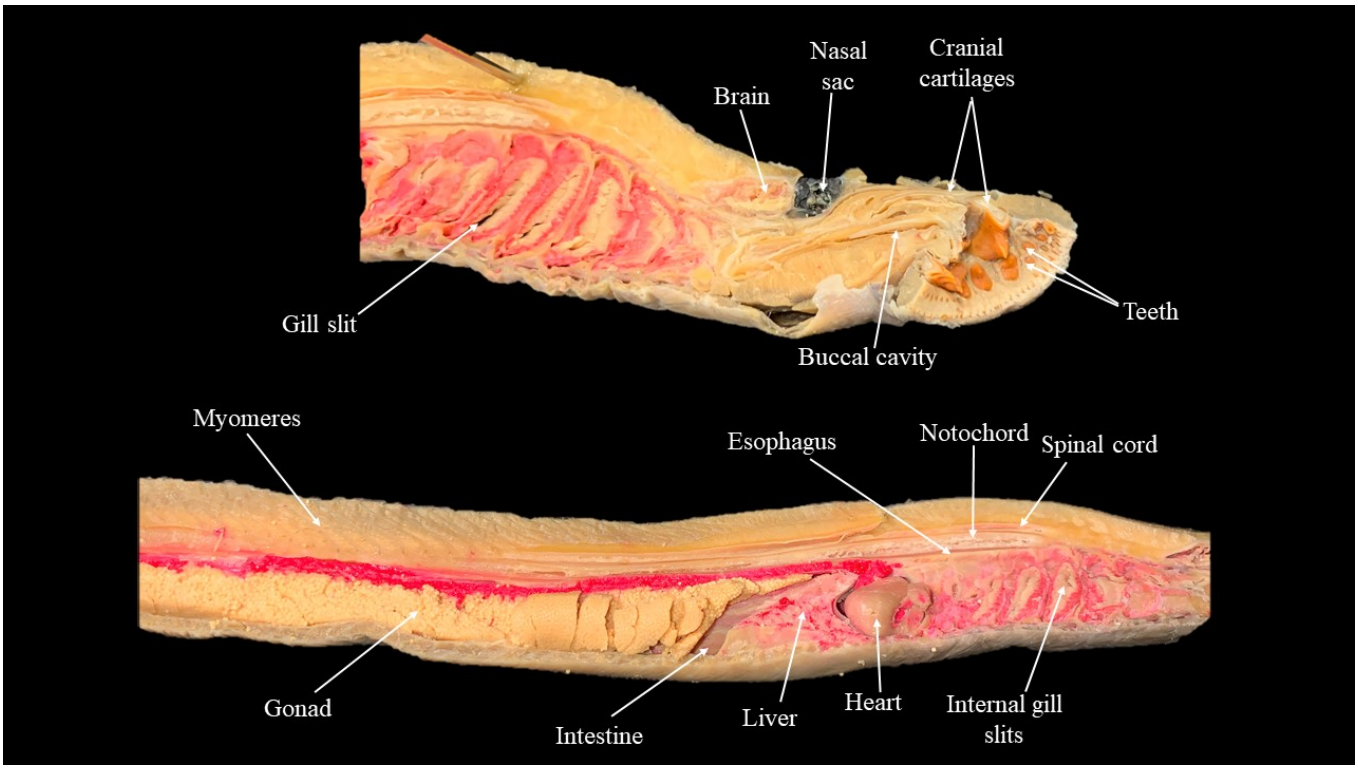

Midsagittal section of lamprey. CC-BY Skylar Jackson.

1.2: Adult lamprey is shared under a CC BY 4.0 license and was authored, remixed, and/or curated by LibreTexts.

CHAPTER OVERVIEW

2: Skeletal systems

2.1: Squalus skeleton
2.2: Necturus skull
2.3: Necturus skeleton
2.4: Pigeon skull
2.5: Pigeon skeleton
2.6: Turtle skull
2.7: Turtle skeleton
2.8: Cat skeleton- overview
2.9: Cat skull
2.10: Cat vertebral column
2.11: Cat scapula and ribs
2.12: Cat limbs

2: Skeletal systems is shared under a CC BY 4.0 license and was authored, remixed, and/or curated by LibreTexts.

2.1: Squalus skeleton

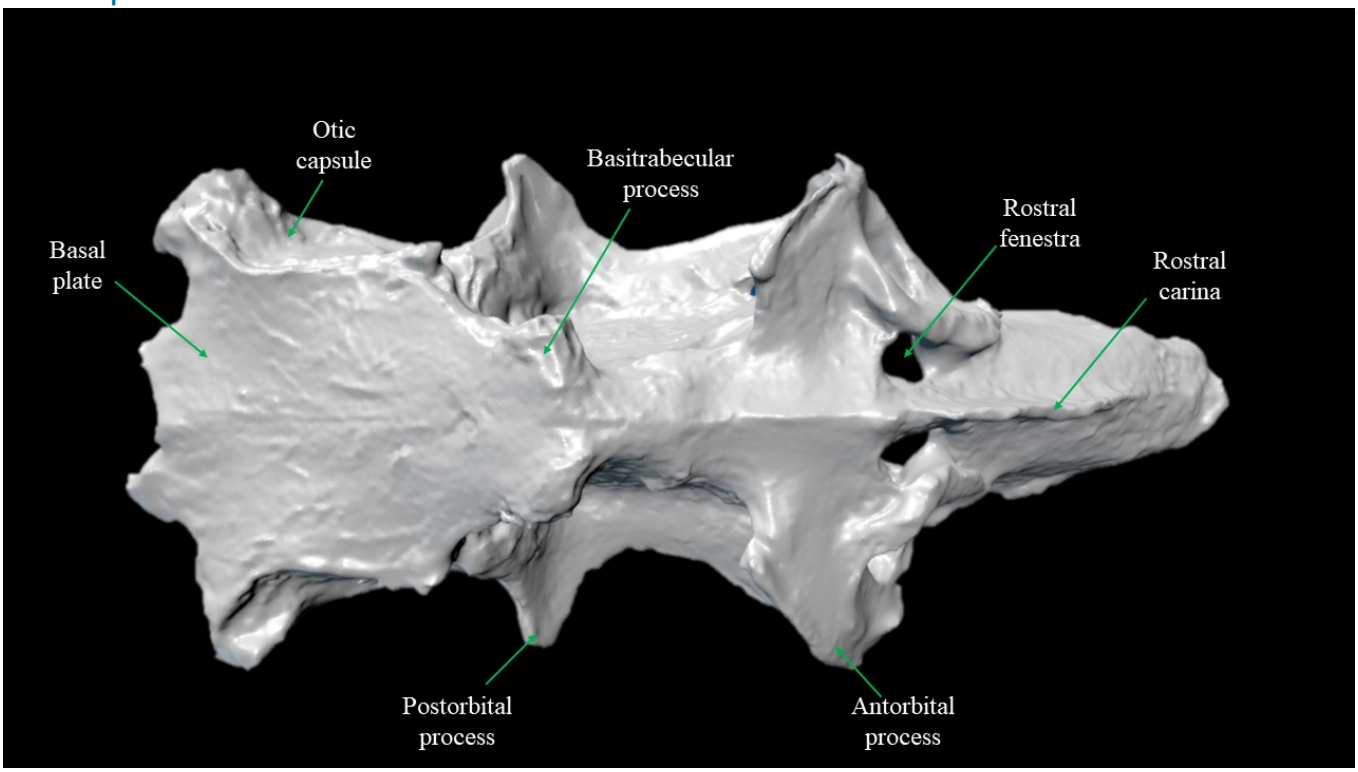

Ventral view of *Squalus* chondrocranium. Based on Thomas DB et al. (2016). 3D scanning and printing skeletal tissues for anatomy education. *Journal of Anatomy.* CC BY-NC 4.0.

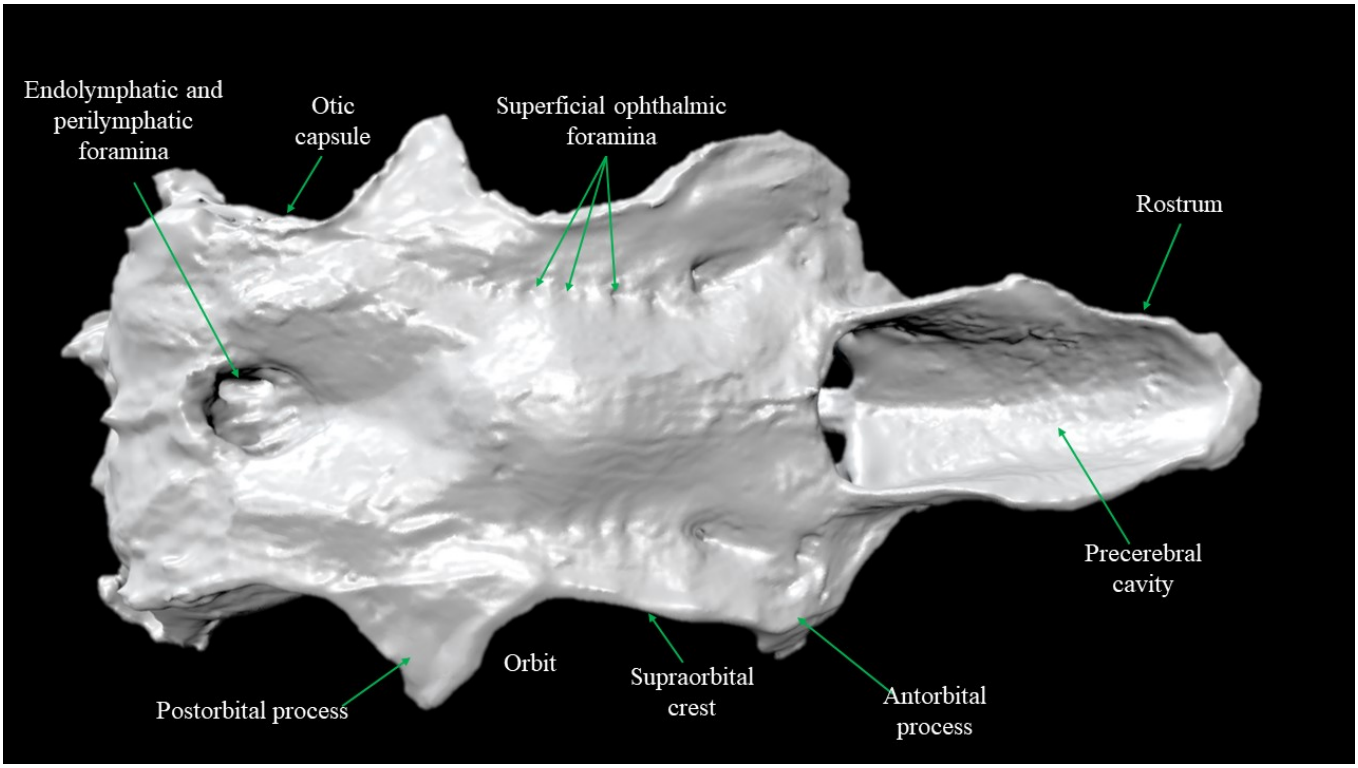

Dorsal view of *Squalus* chondrocranium. Based on Thomas DB et al. (2016). 3D scanning and printing skeletal tissues for anatomy education. *Journal of Anatomy.* CC BY-NC 4.0.

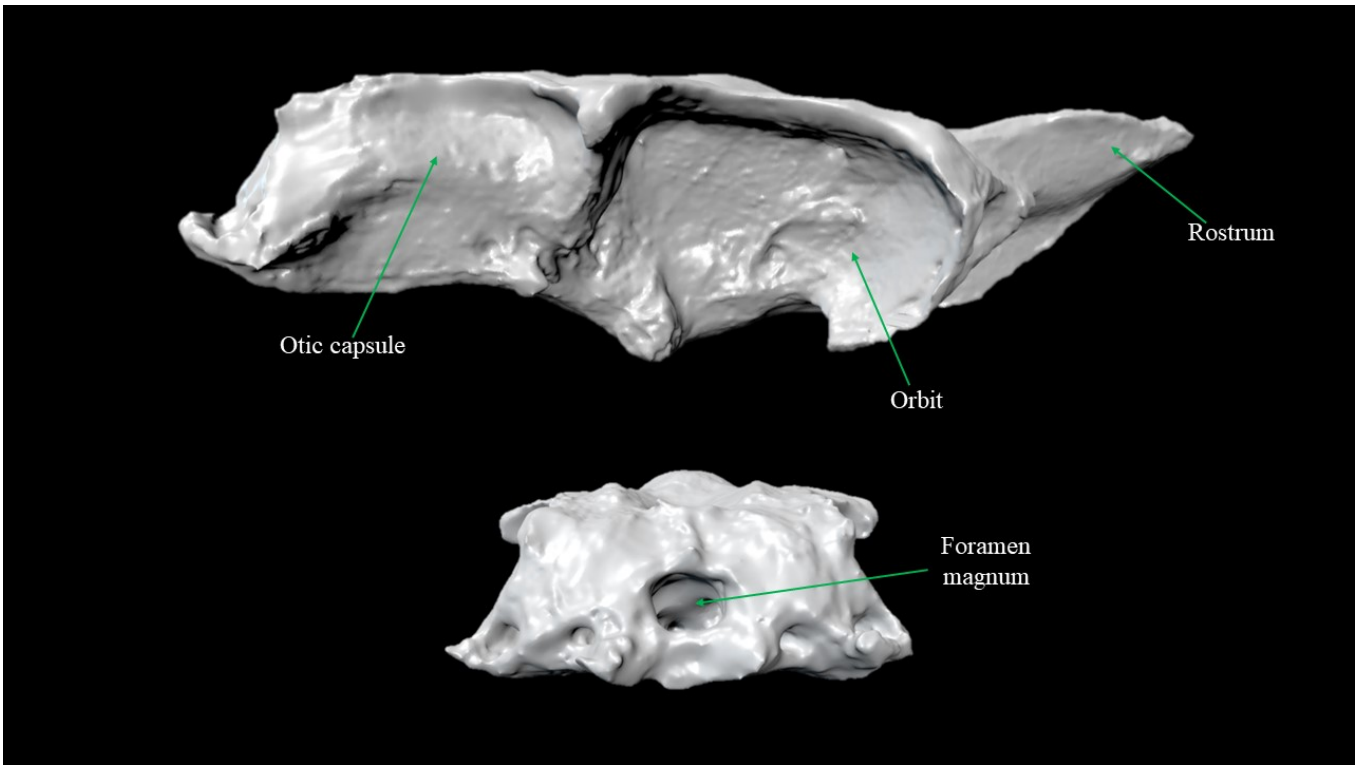

Lateral and posterior views of *Squalus* chondrocranium. Based on Thomas DB et al. (2016). 3D scanning and printing skeletal tissues for anatomy education. *Journal of Anatomy.* CC BY-NC 4.0.

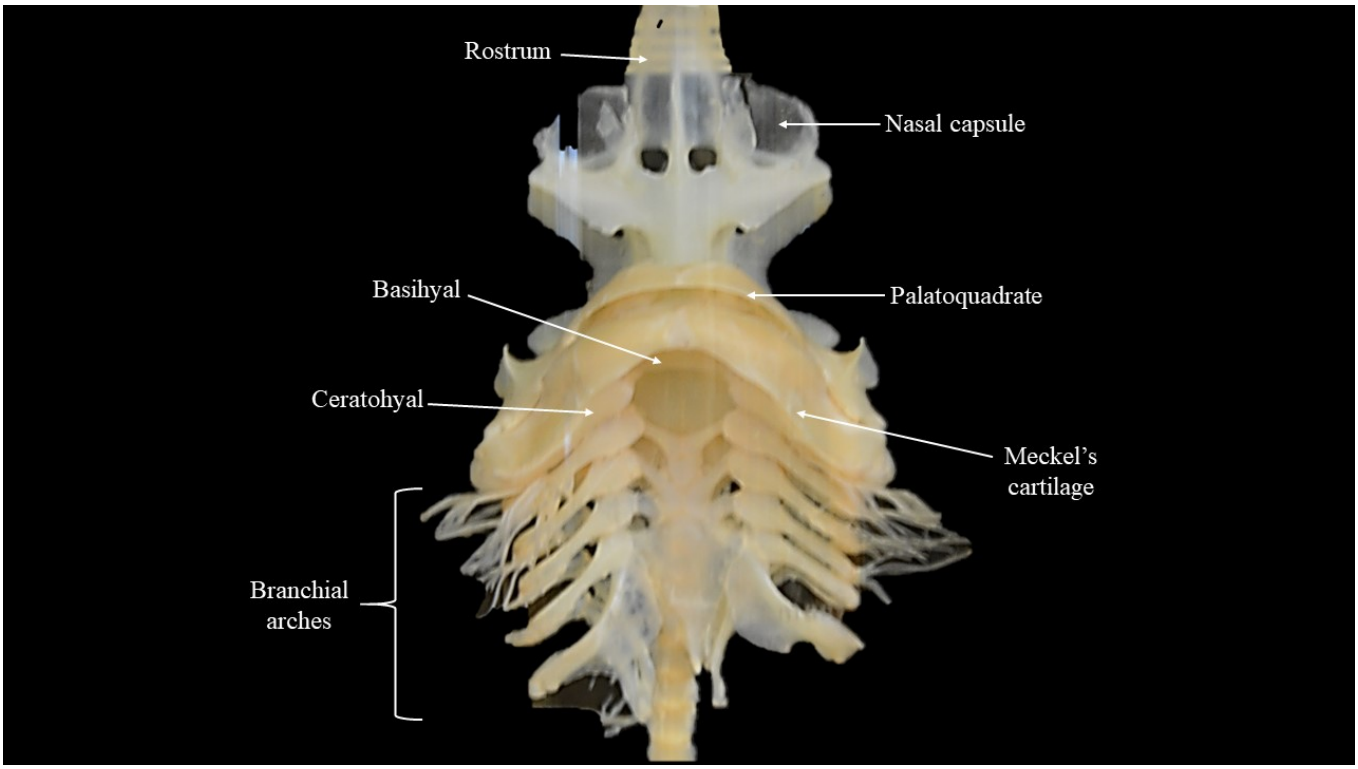

Ventral view of the splanchnocranium and chondrocranium of *Squalus.* CC BY Elizabeth Swislosky & Kristen Roosa.

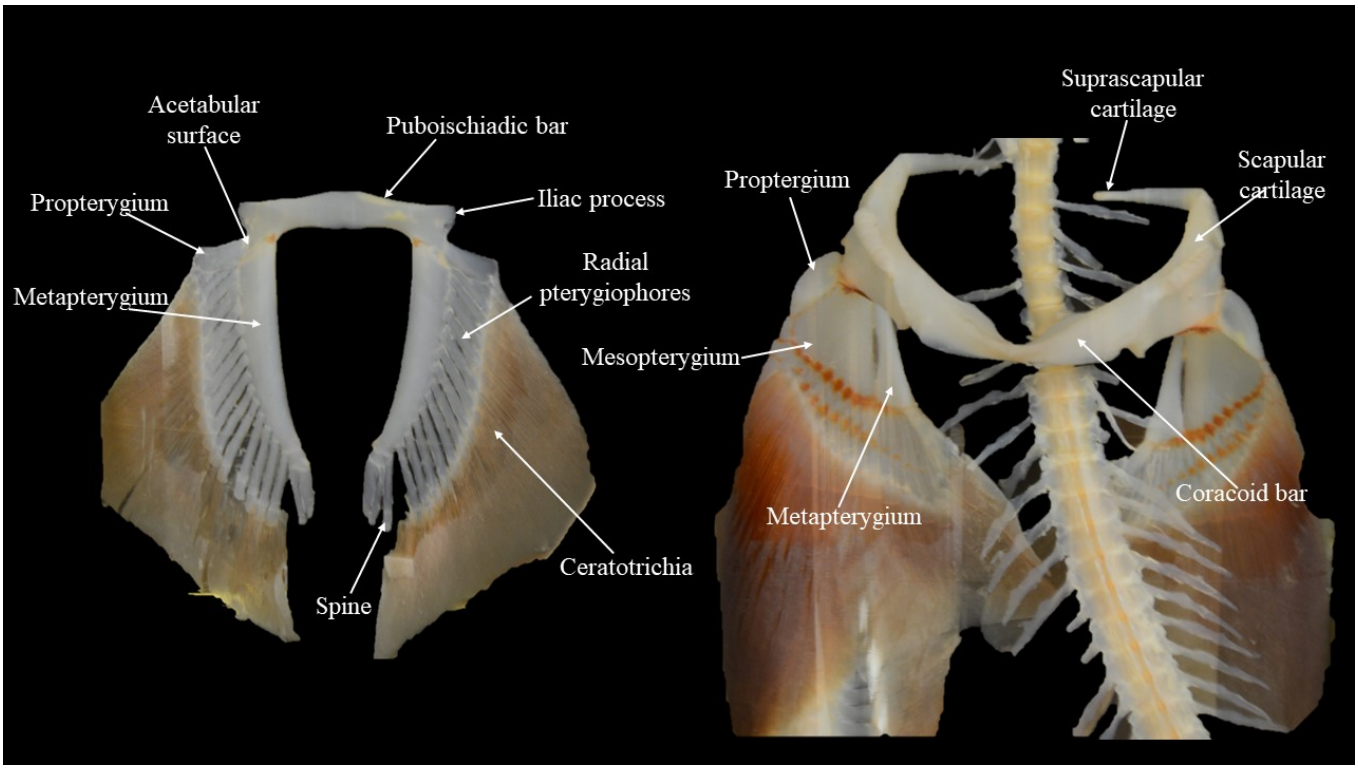

Pelvic girdle (left) and pectoral girdle (right) of *Squalus*. CC BY Elizabeth Swislosky & Kristen Roosa.

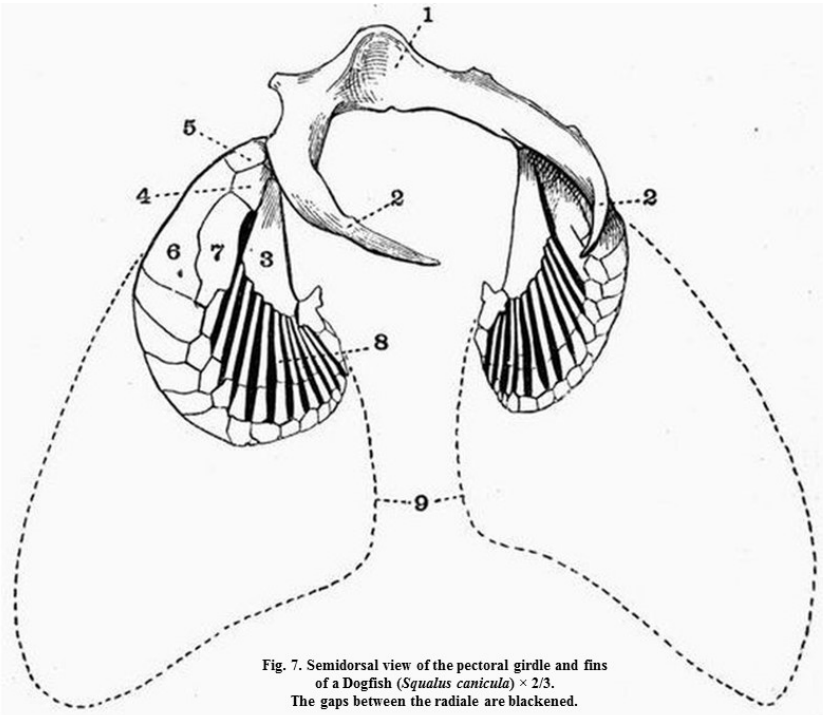

Fig. 7. Semidorsal view of the pectoral girdle and fins of a Dogfish (*Squalus canicula*) × 2/3. The gaps between the radiale are blackened.

1. hollow in the mid-ventral part of the pectoral girdle which supports the pericardium.
2. dorsal (scapular portion) of pectoral girdle.
3. meta-pterygium.
4. meso-pterygium.
5. propterygium.
6. propterygial radial.
7. meso-pterygial radial.
8. meta-pterygial radial.
9. outline of the distal part of the fin which is supported by horny fin-rays.

Semidorsal view of the pectoral girdle and finsof a Dogfish (*Squalus canicula*). From The Vertebrate Skeleton , Reynolds, S.H. 1897. In the public domain.

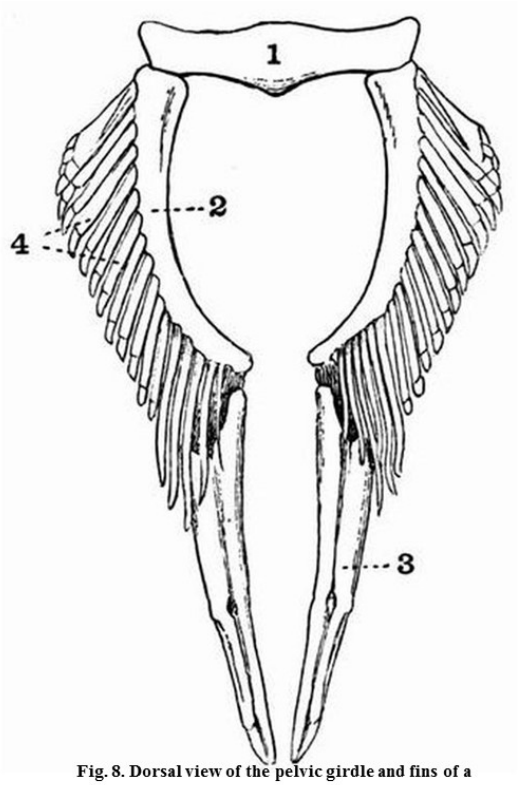

Fig. 8. Dorsal view of the pelvic girdle and fins of a male Dogfish (*Squalus canicula*).

1. pelvic girdle. 3. clasper.

2. basi-pterygium. 4. radiale.

Dorsal view of the pelvic girdle and fins of a male Dogfish (*Squalus canicula*). From The Vertebrate Skeleton , Reynolds, S.H. 1897. In the public domain.

Contributors and Attributions

- Squalus Splanchnocranium . **Authored by**: Elizabeth Swislosky. **License**: *CC BY: Attribution*

2.1: Squalus skeleton is shared under a CC BY 4.0 license and was authored, remixed, and/or curated by LibreTexts.

2.2: Necturus skull

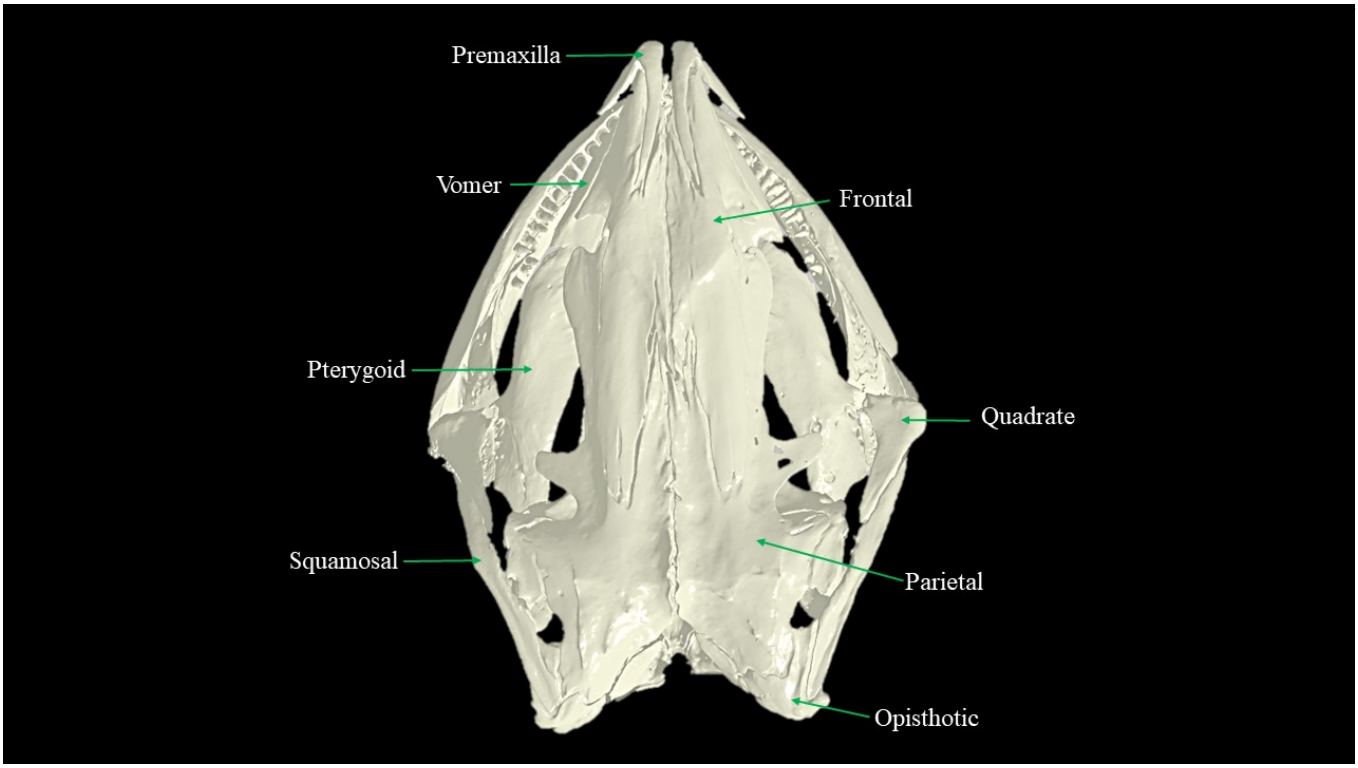

Dorsal view of Necturus skull. Based on CT scan of *Necturus beyeri* by the University of Florida Museum of Natural History CC BY-NC.

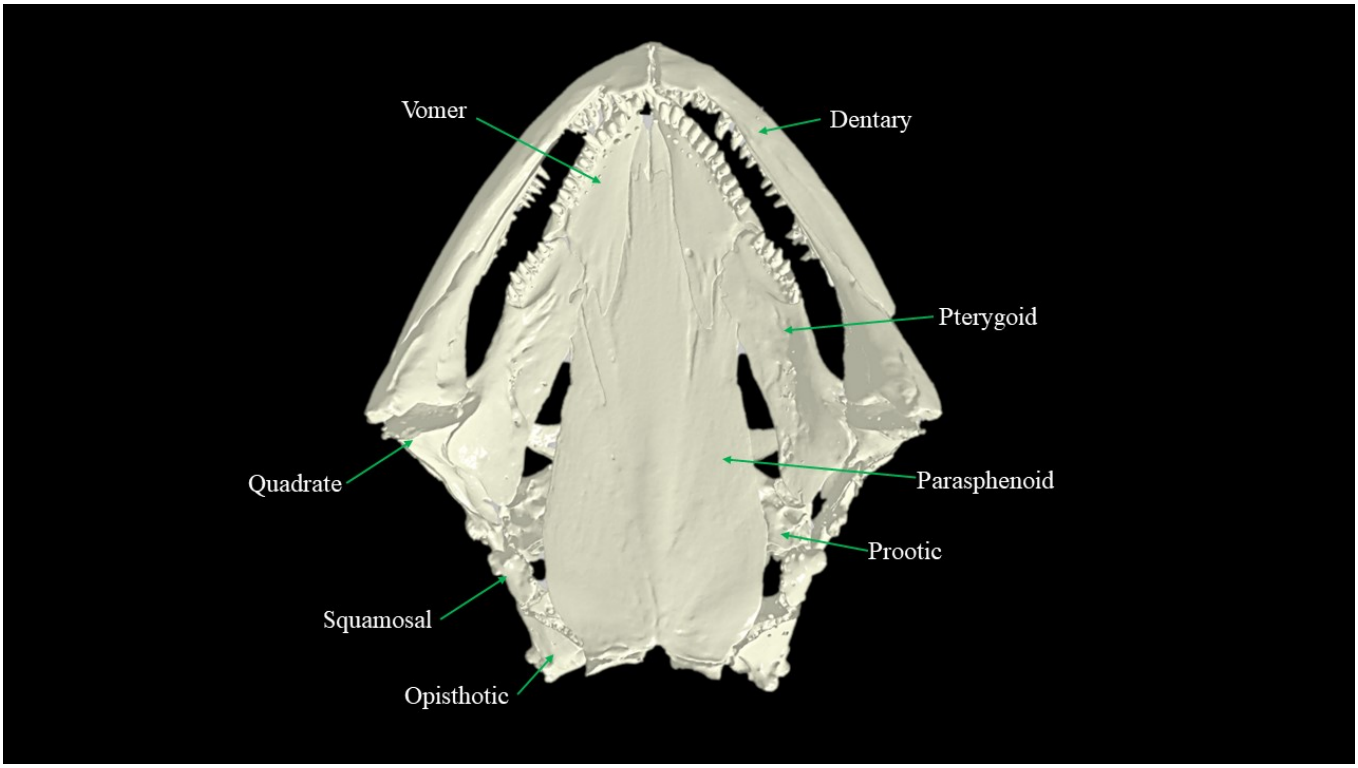

Ventral view of Necturus skull. Based on CT scan of *Necturus beyeri* by the University of Florida Museum of Natural History CC BY-NC.

Contributors and Attributions

CC licensed content, Shared previously

- Necturus Skeleton. **Authored by**: Kristen Roosa. **License**: *CC BY-NC: Attribution-NonCommercial*

2.2: Necturus skull is shared under a CC BY 4.0 license and was authored, remixed, and/or curated by LibreTexts.

2.3: Necturus skeleton

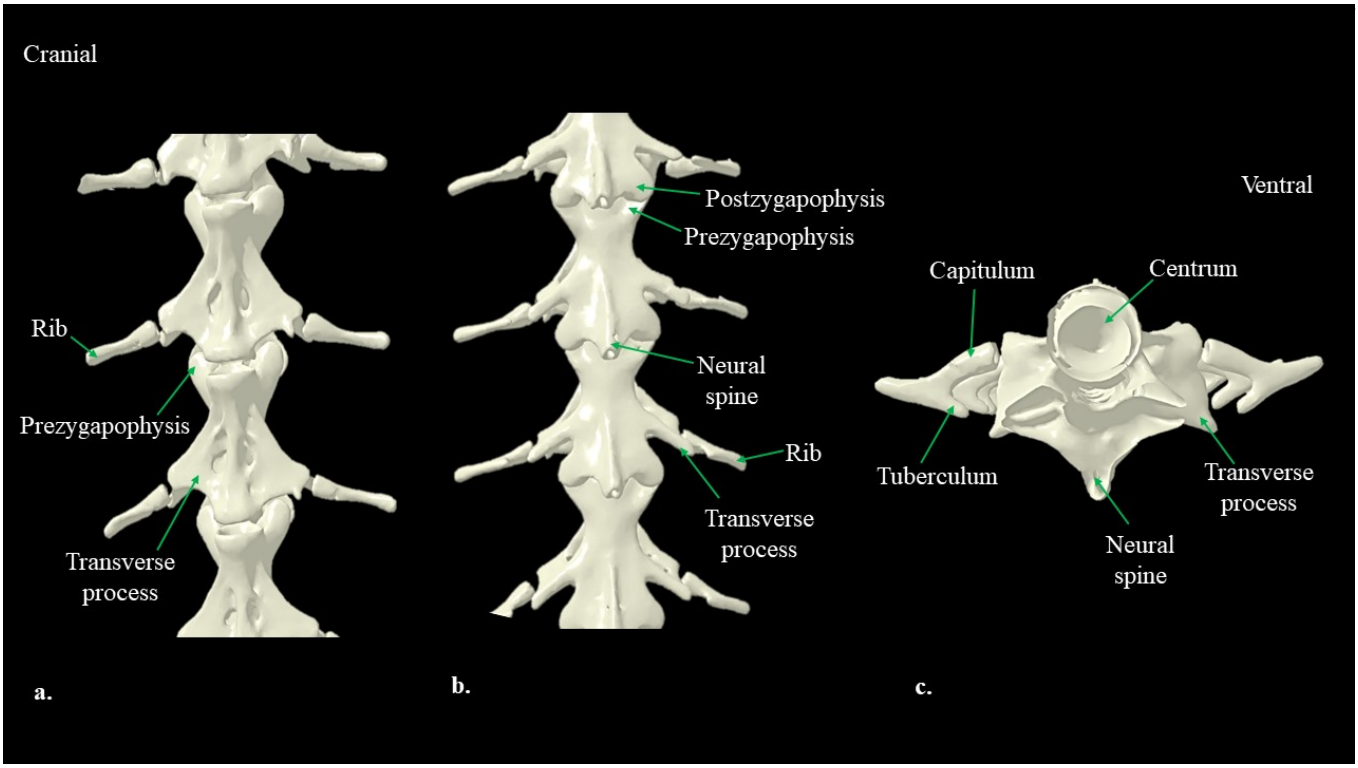

a. Ventral view of *Necturus* vertebrae and ribs, b. Dorsal view of *Necturus* vertebrae and ribs, c. Cranial view of *Necturus* vertebra and ribs. Based on CT scan of *Necturus beyeri* by the University of Florida Museum of Natural History CC BY-NC.

2.3: Necturus skeleton is shared under a CC BY 4.0 license and was authored, remixed, and/or curated by LibreTexts.

2.4: Pigeon skull

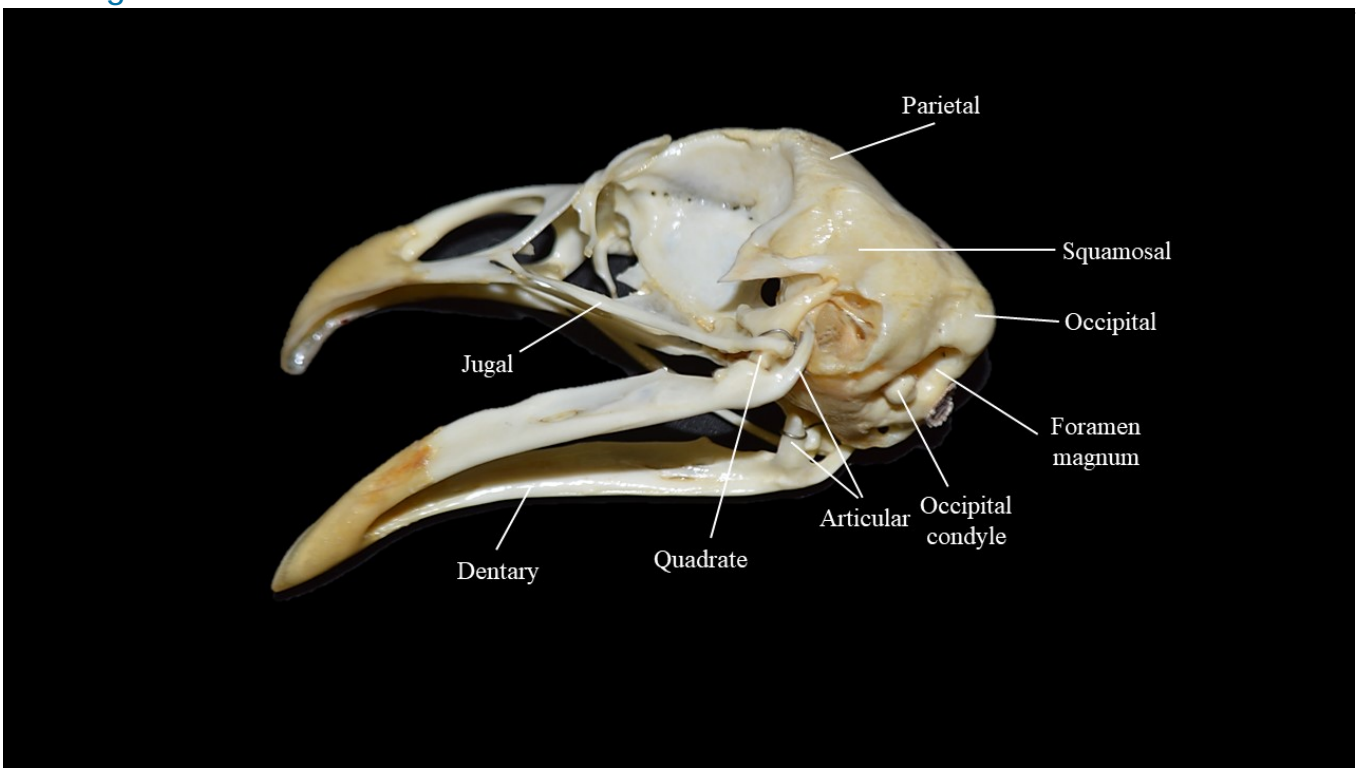

Ventrolateral view of pigeon skull. CC-BY Alexandra Caffrey.

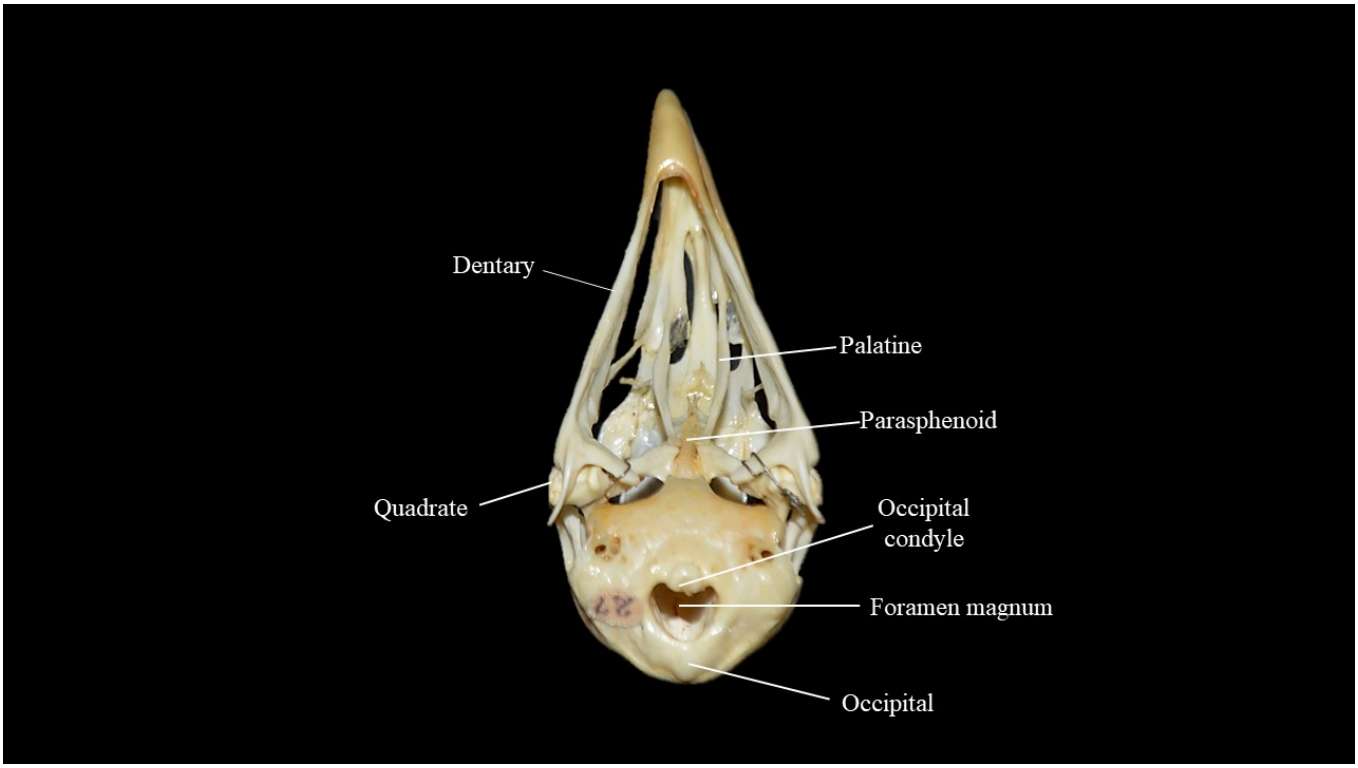

Ventral view of pigeon skull. CC-BY Alexandra Caffrey.

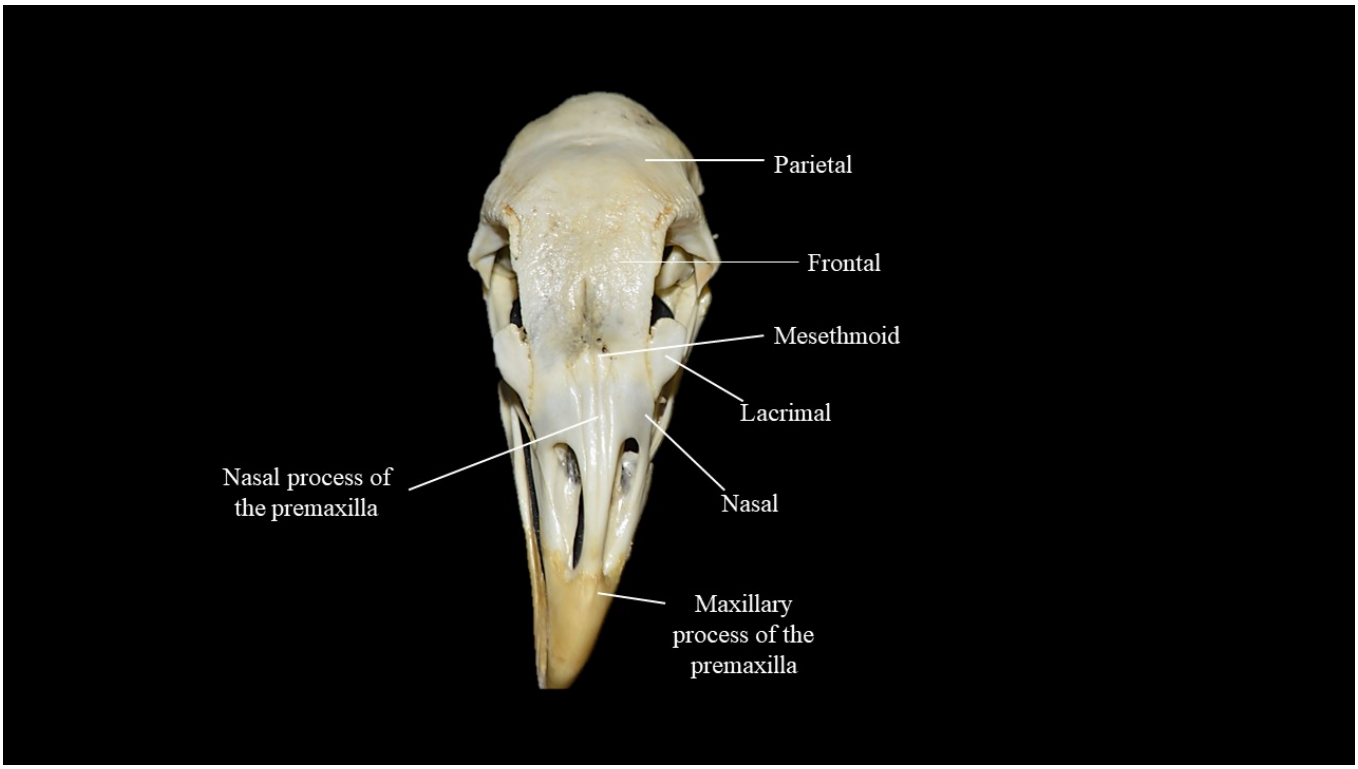

Dorsal view of pigeon skull. CC-BY Alexandra Caffrey.

2.4: Pigeon skull is shared under a CC BY 4.0 license and was authored, remixed, and/or curated by LibreTexts.

2.5: Pigeon skeleton

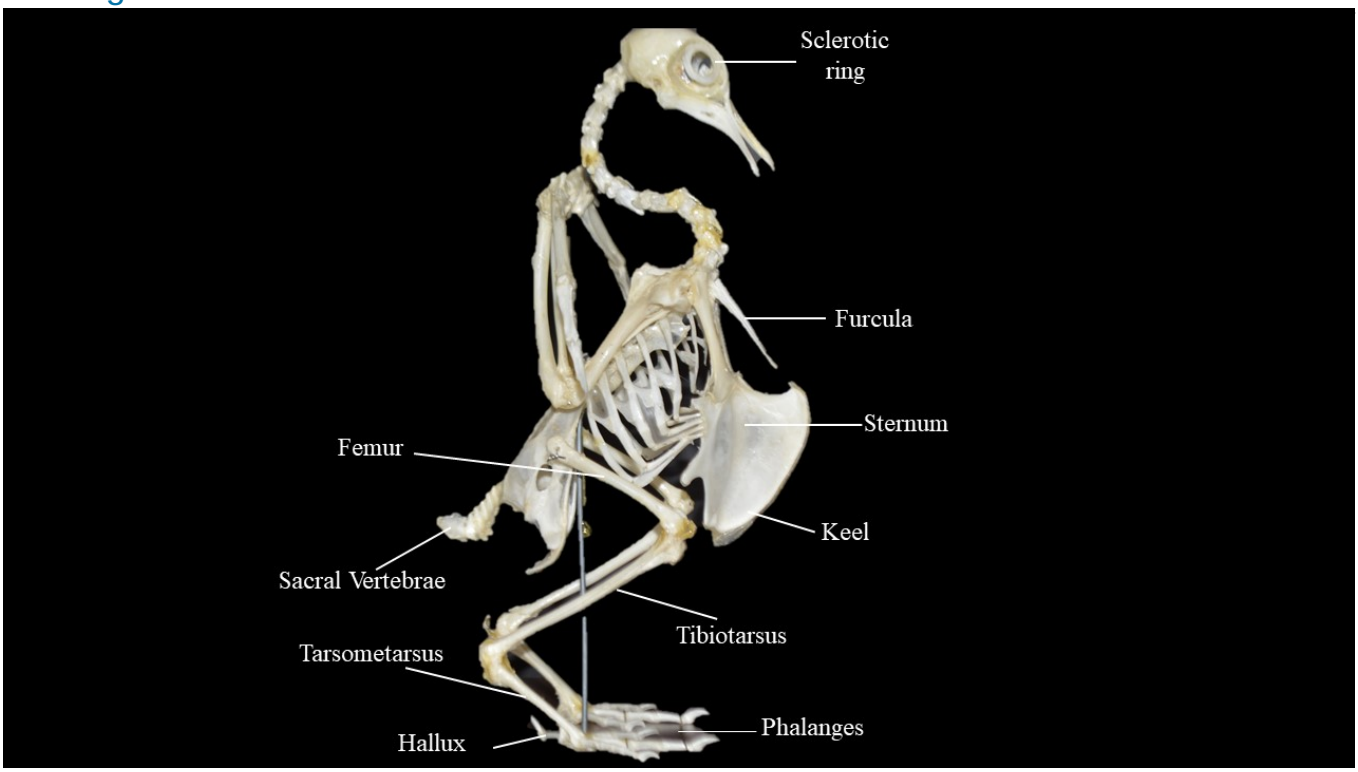

Lateral view of pigeon skeleton. CC-BY Alexandra Caffrey.

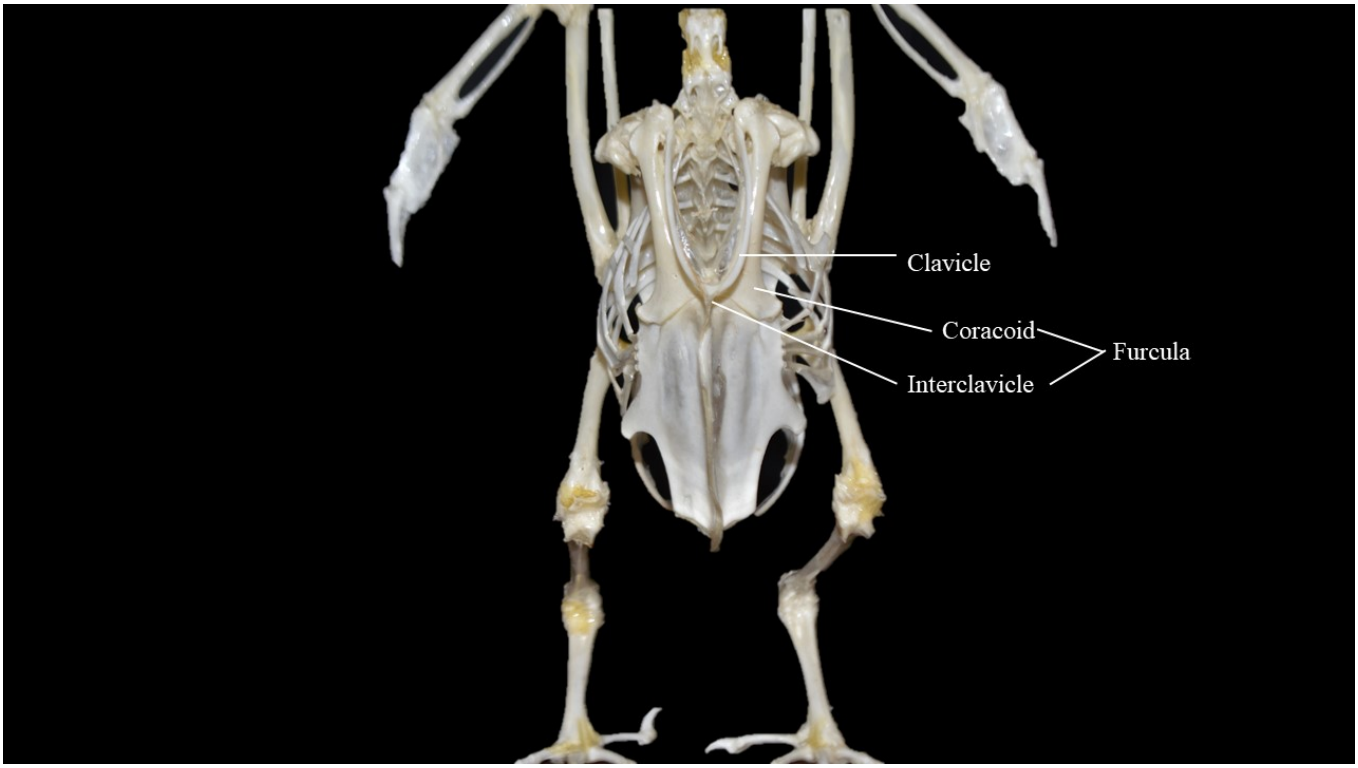

Anterior view of pigeon skeleton. CC-BY Alexandra Caffrey.

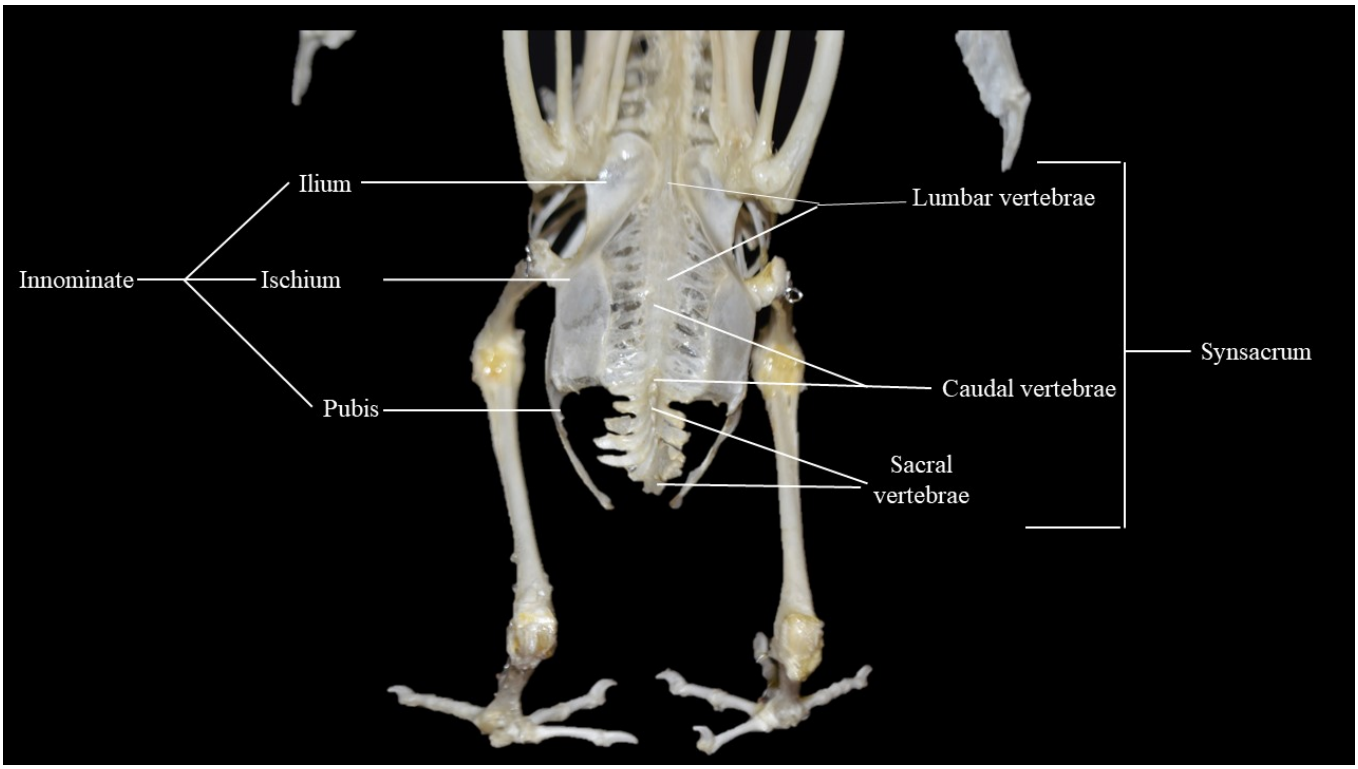

Posterior view of pigeon skeleton. CC-BY Alexandra Caffrey.

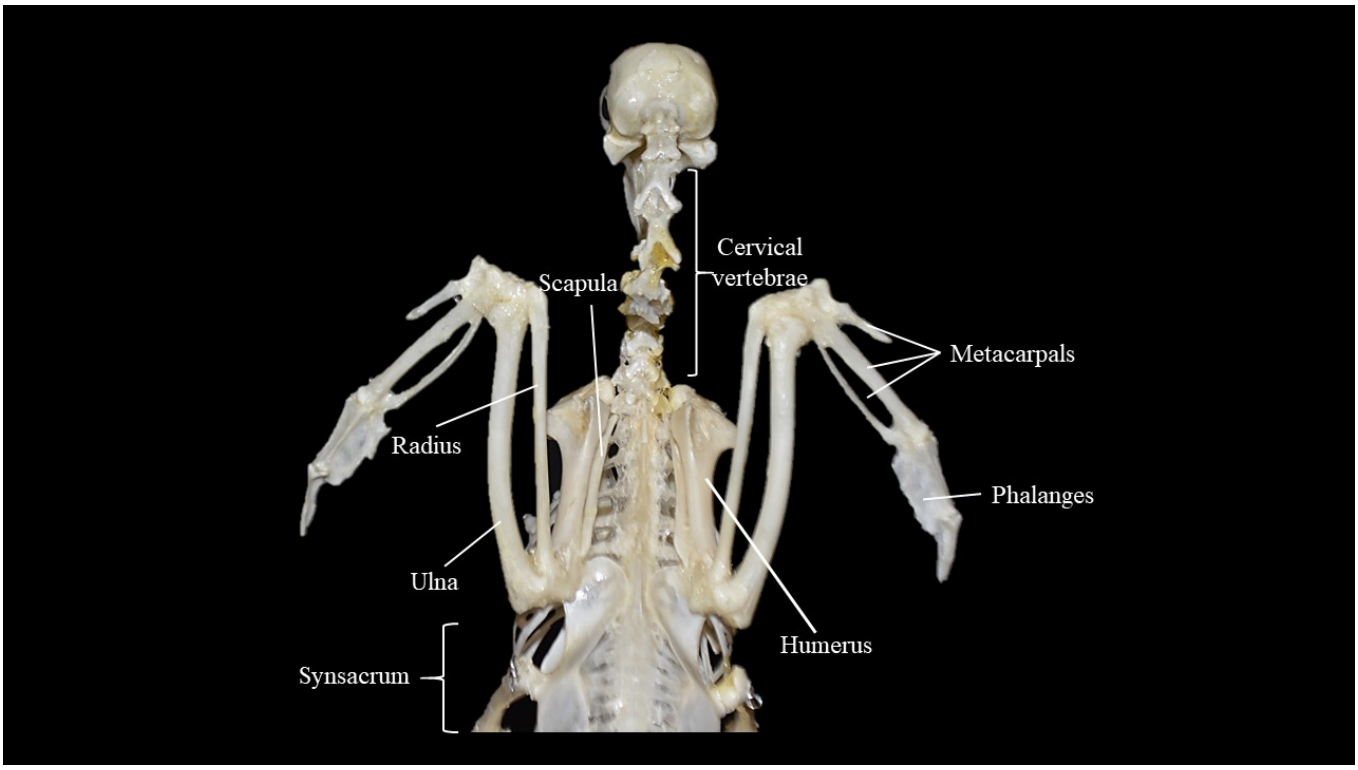

Posterior view of pigeon forelimb and thoracic region. CC-BY Alexandra Caffrey.

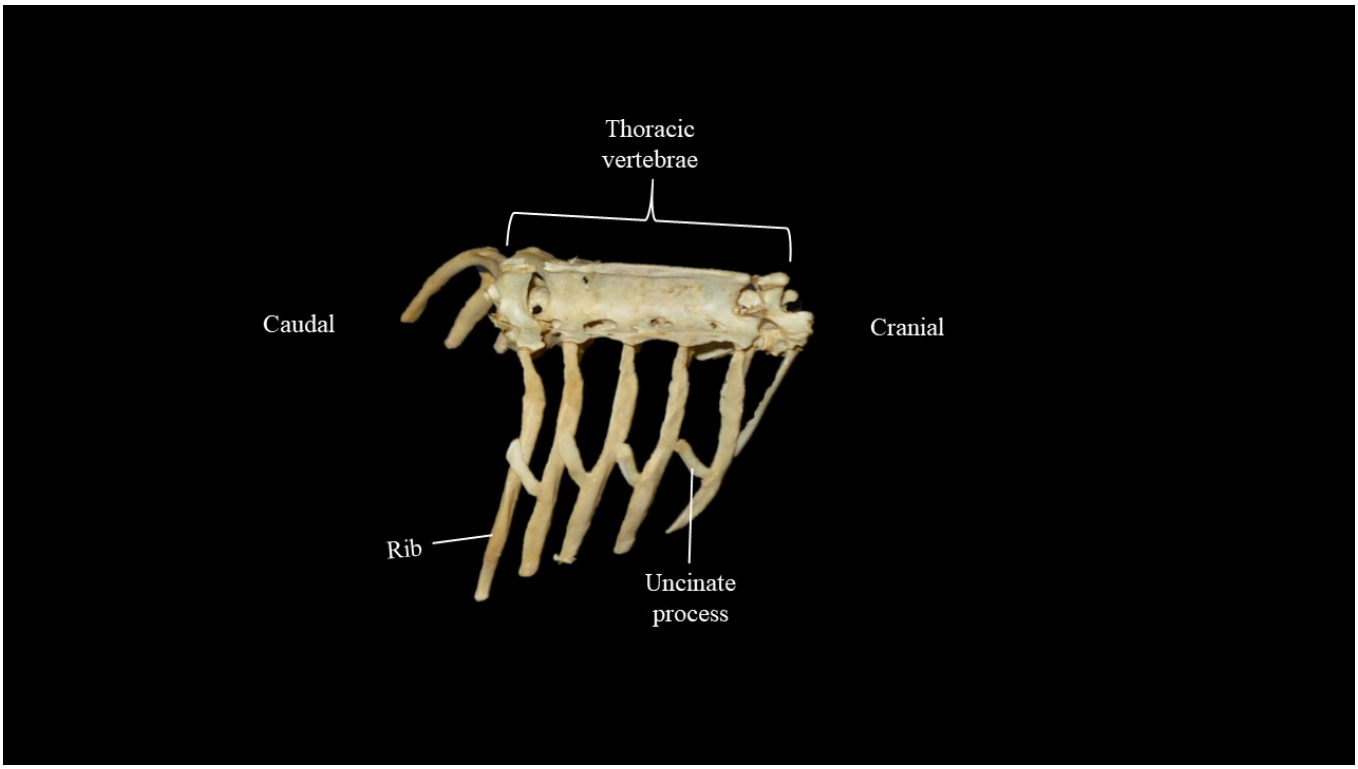

Lateral view of pigeon thoracic cage. CC-BY Alexandra Caffrey & Kristen Roosa

Contributors and Attributions

- **License**: *CC BY: Attribution*

2.5: Pigeon skeleton is shared under a CC BY 4.0 license and was authored, remixed, and/or curated by LibreTexts.

2.6: Turtle skull

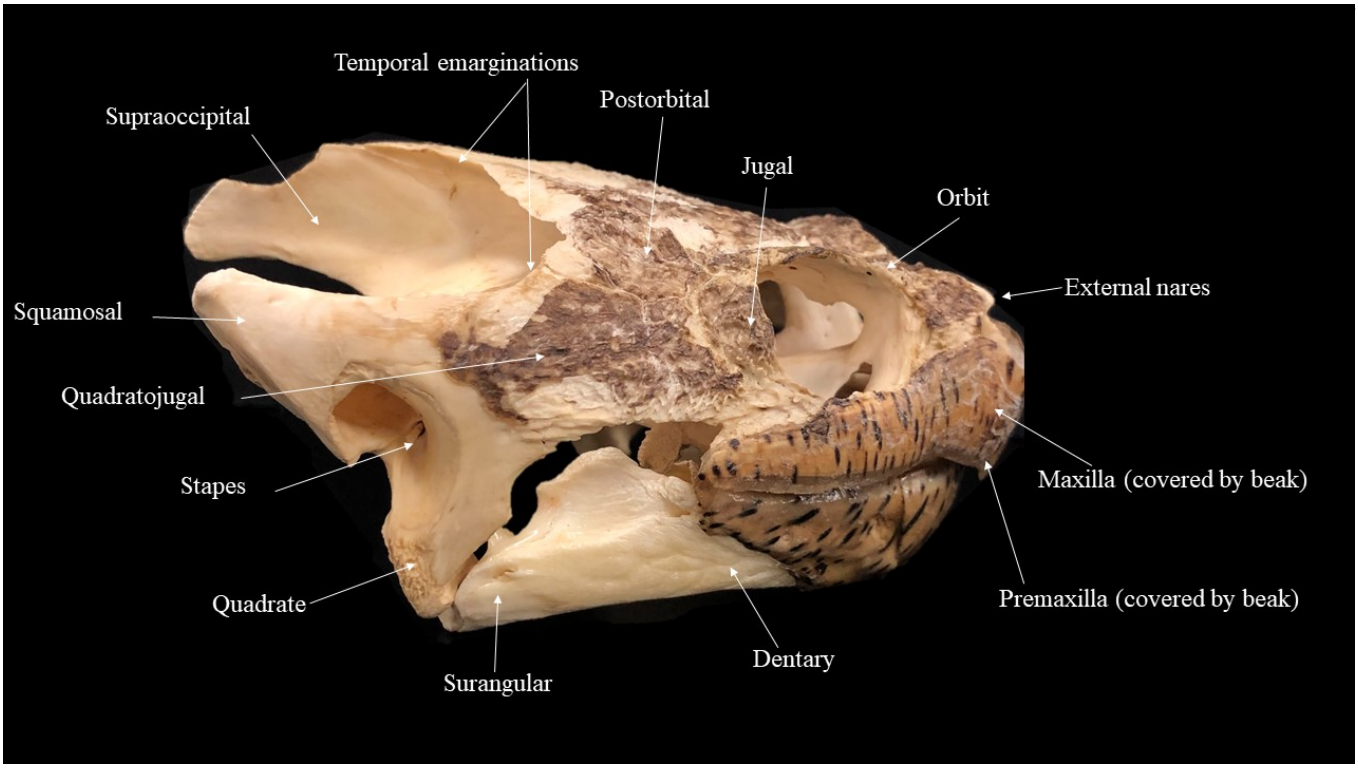

Lateral view of turtle skull and jaw. CC-BY Kelsey Murdock.

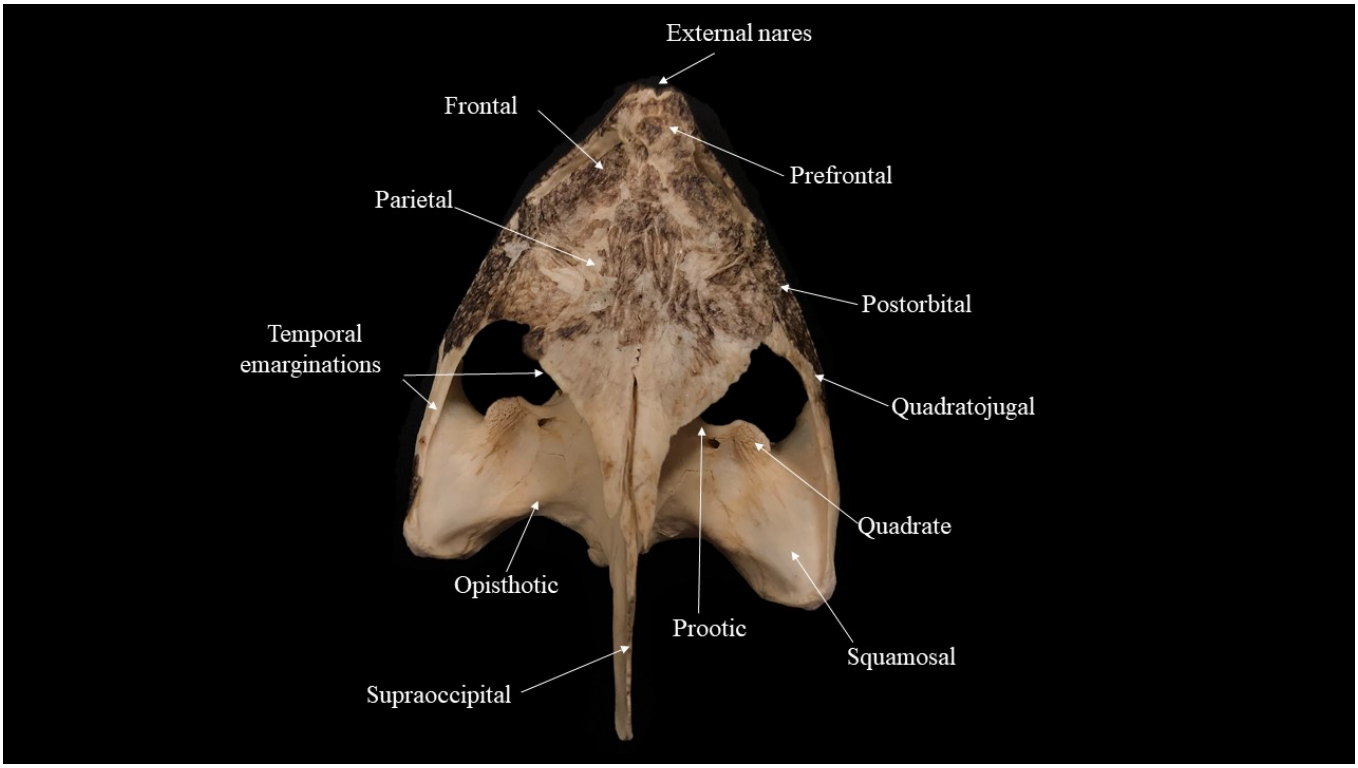

Dorsal view of turtle skull. CC-BY Kelsey Murdock.

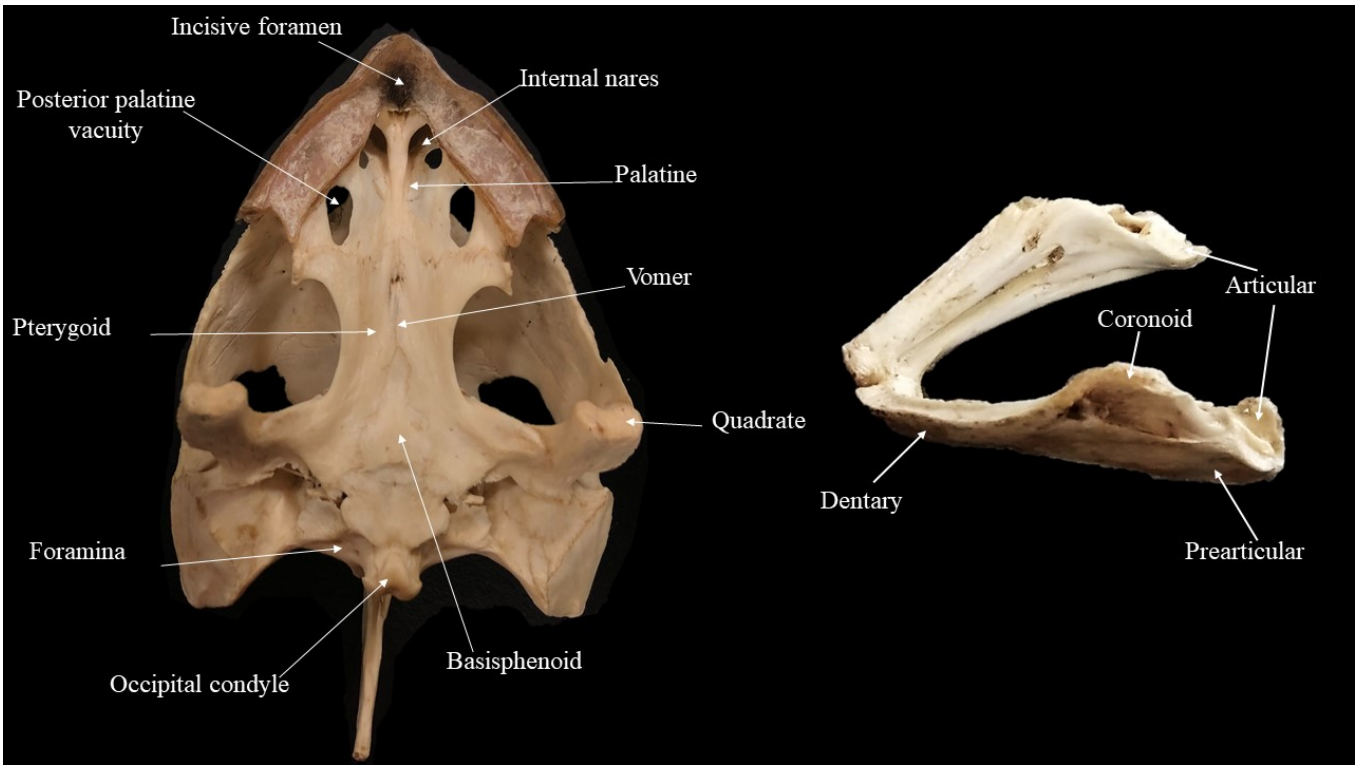

Ventral view of turtle skull. CC-BY Kelsey Murdock & Kristen Roosa.

Contributors and Attributions

- Turtle skull - dorsal, ventral, and lateral views. **Authored by**: Kelsey Murdock & Kristen Roosa. **License**: *CC BY: Attribution*

2.6: Turtle skull is shared under a CC BY 4.0 license and was authored, remixed, and/or curated by LibreTexts.

2.7: Turtle skeleton

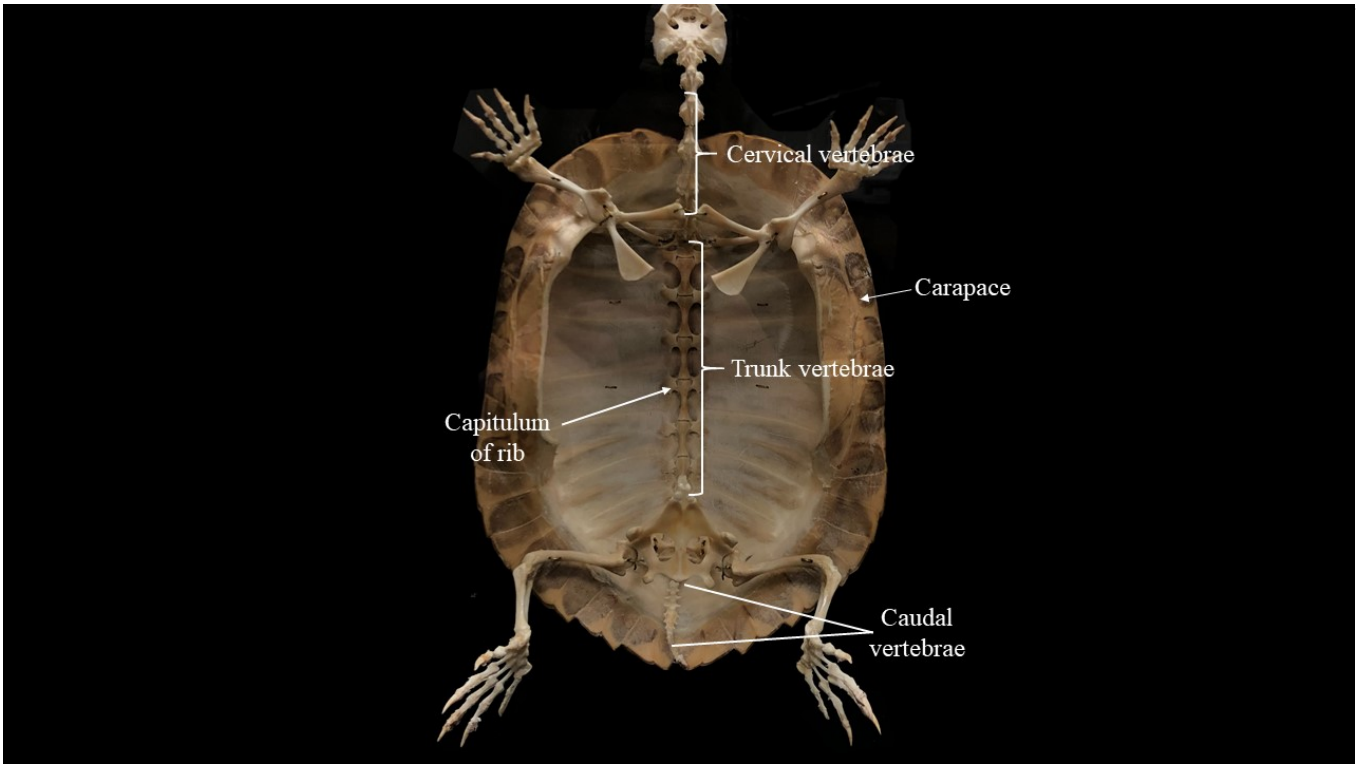

Ventral view of turtle skeleton, plastron removed. CC-BY Kelsey Murdock.

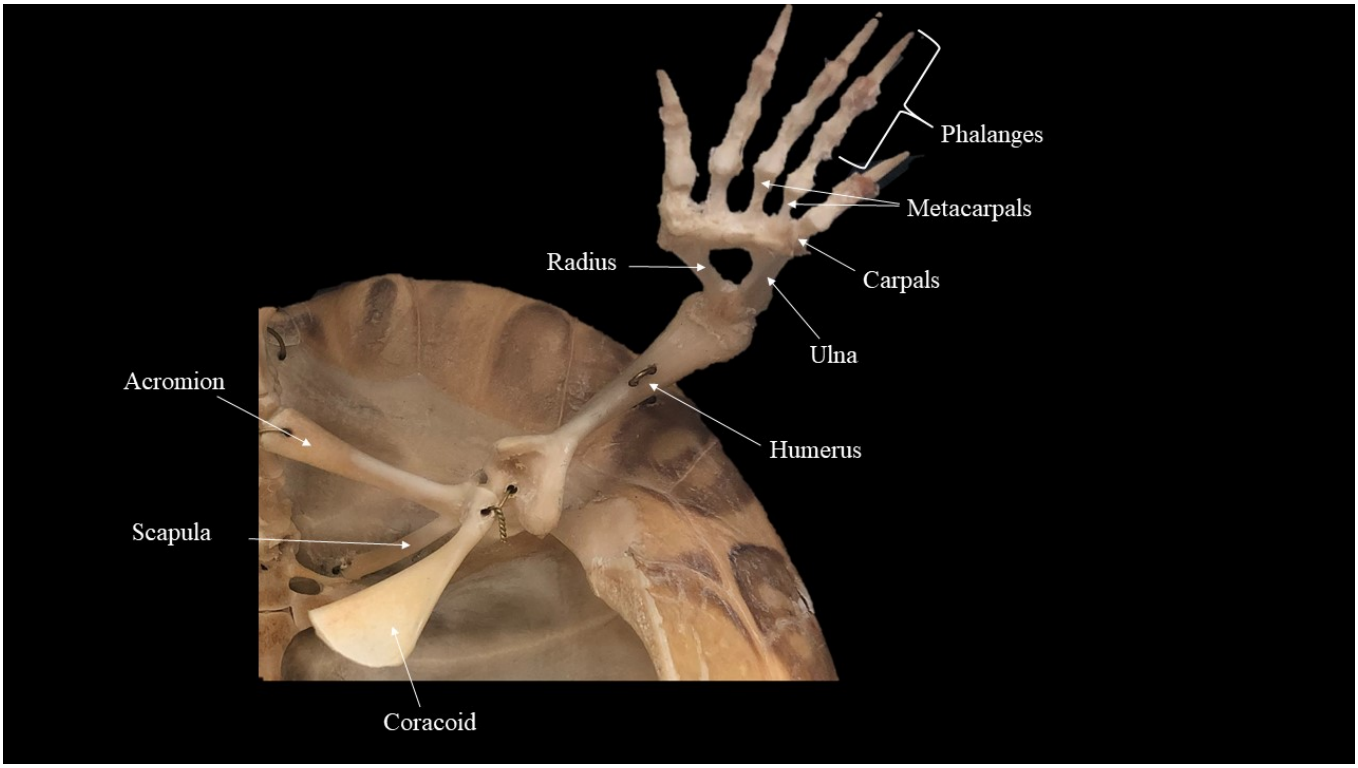

Left pectoral girdle and limb of turtle, ventral view. CC-By Kelsey Murdock.

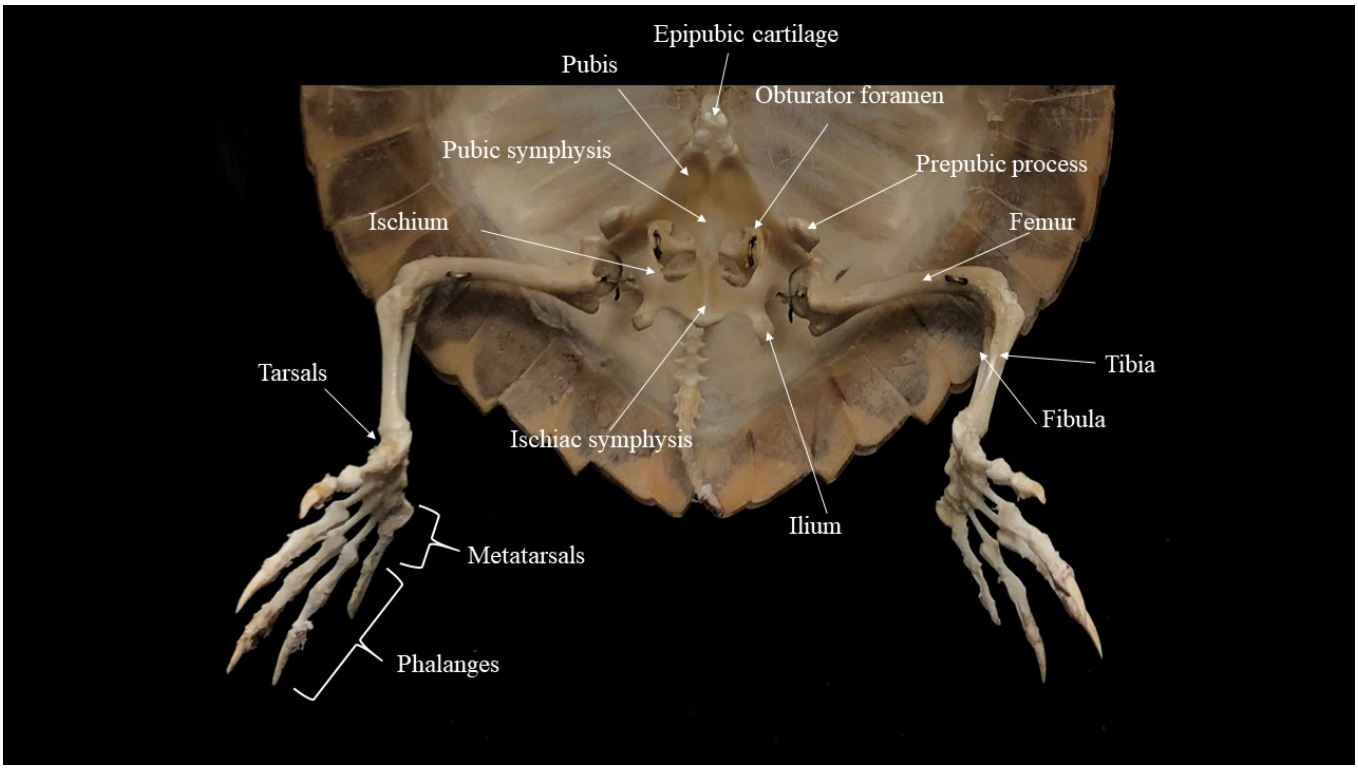

Pelvic girdle and hindlimbs of turtle, ventral view. CC-BY Kelsey Murdock.

Contributors and Attributions

- Skeleton of the turtle. **Authored by**: Kelsey Murdock. **License**: *CC BY: Attribution*

2.7: Turtle skeleton is shared under a CC BY 4.0 license and was authored, remixed, and/or curated by LibreTexts.

2.8: Cat skeleton- overview

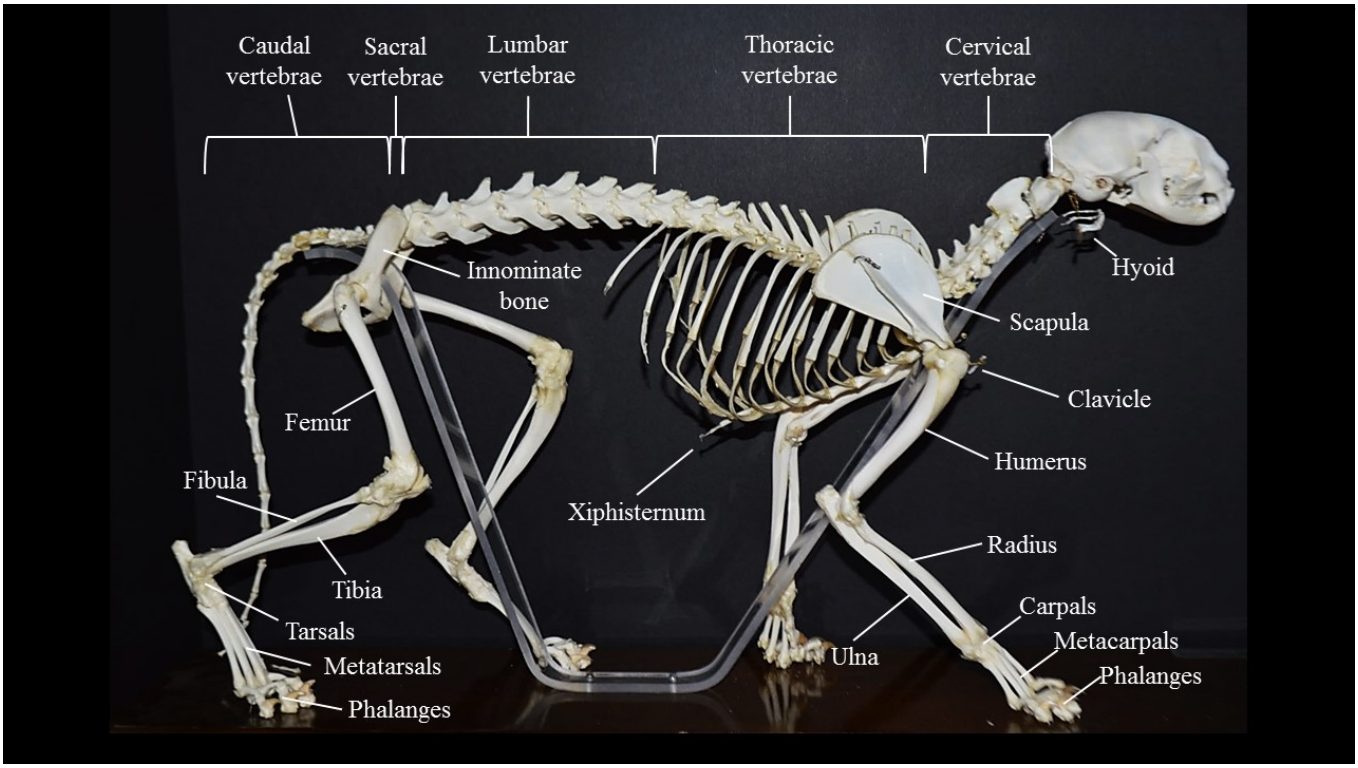

Lateral view of the cat skeleton. CC-BY Sisina Macchiarelli & Daniel Saugar

Contributors and Attributions

- Lateral view of the cat skeleton.. **Authored by**: Sisina Machiarelli & Daniel Saugar. **License**: *CC BY: Attribution*

2.8: Cat skeleton- overview is shared under a CC BY 4.0 license and was authored, remixed, and/or curated by LibreTexts.

2.9: Cat skull

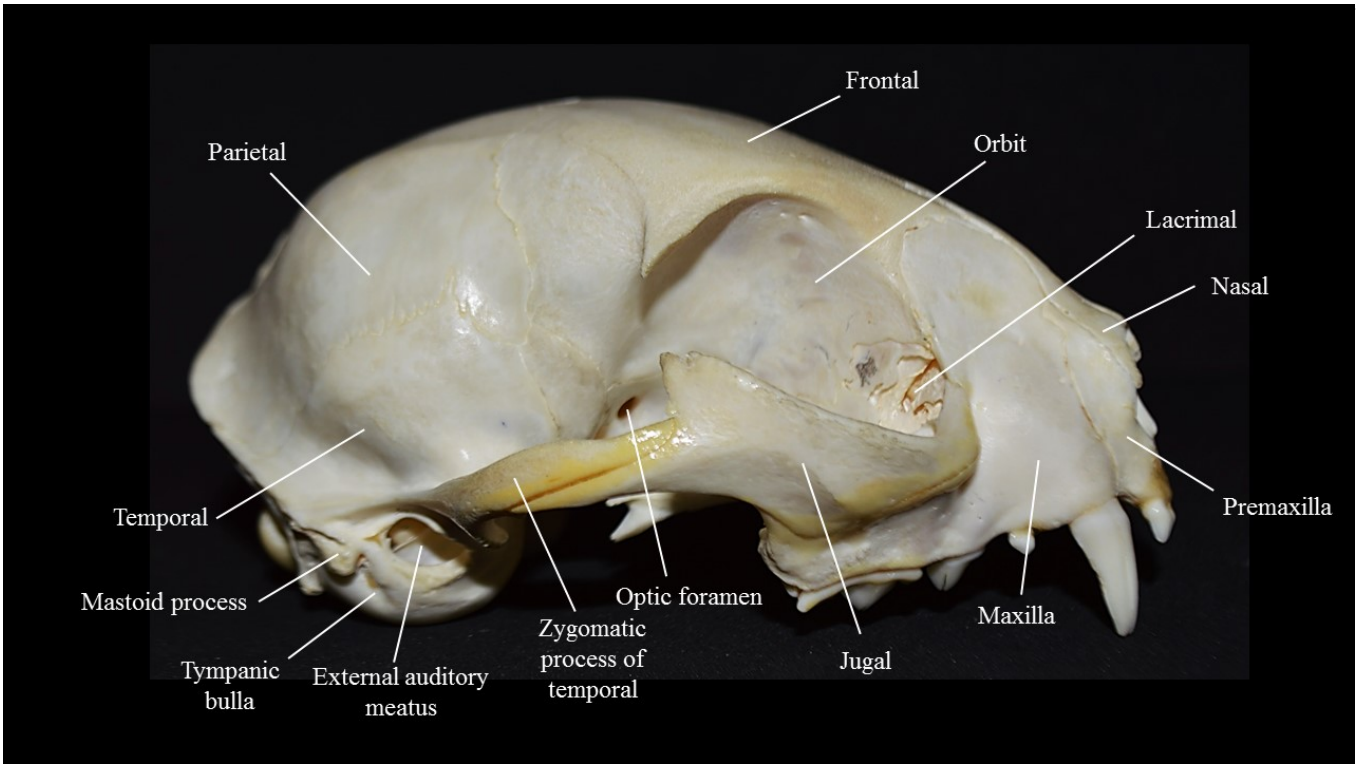

Lateral view of the cat skull, dentary bone removed. CC BY Kristen Roosa.

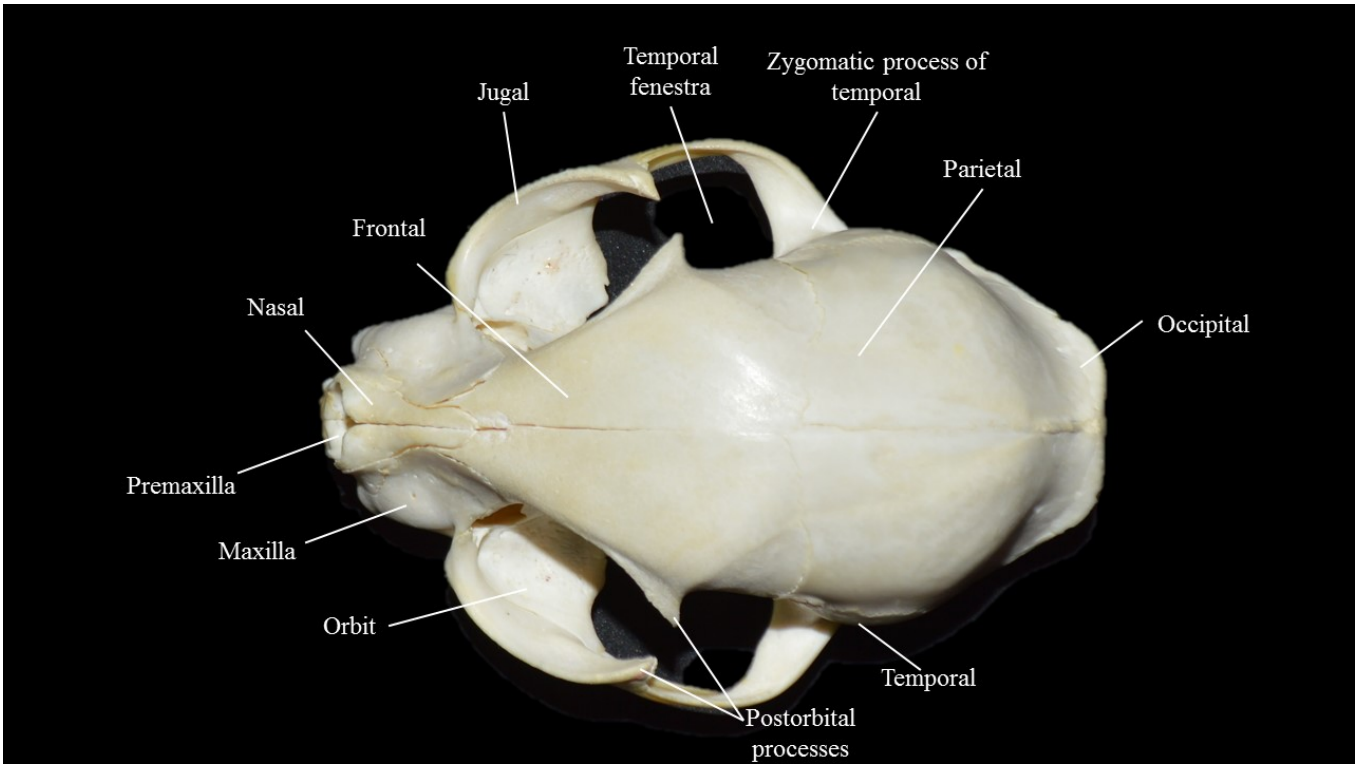

Dorsal view of the cat skull. CC BY Kristen Roosa.

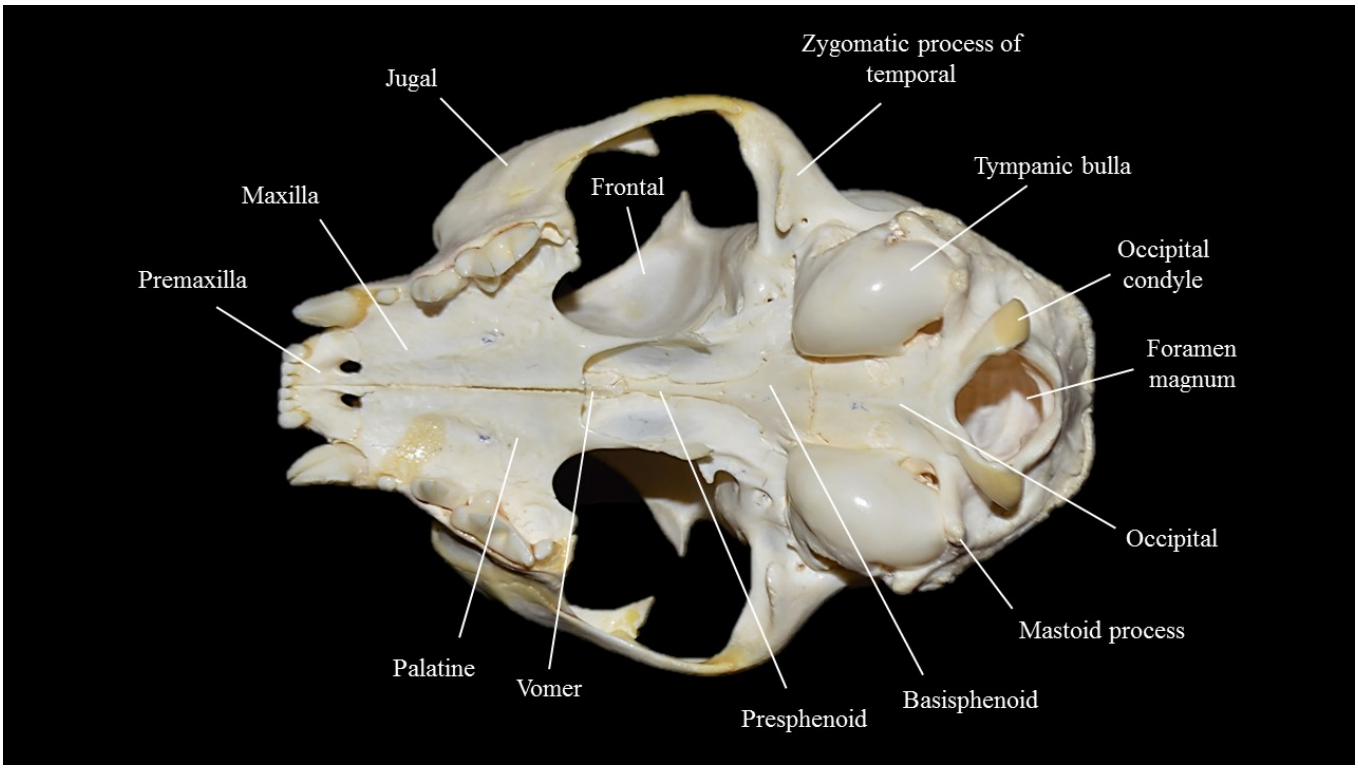

Ventral view of the cat skull, dentary bone removed. CC BY Kristen Roosa.

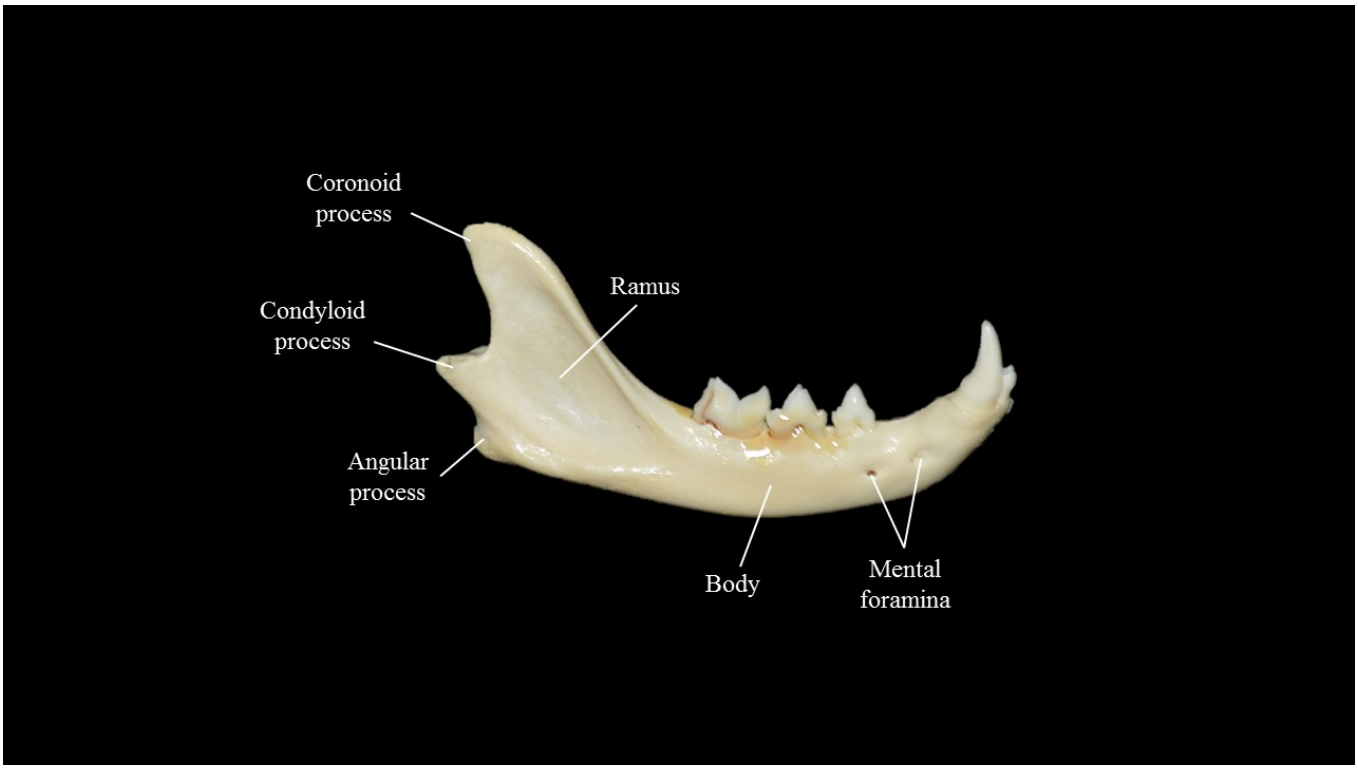

Lateral view of the dentary bone of the cat.CC BY Kristen Roosa.

Contributors and Attributions

- Cat skull. **Authored by**: Kristen A. Roosa. **License**: *CC BY: Attribution*
- **License**: *Public Domain: No Known Copyright*

2.9: Cat skull is shared under a CC BY 4.0 license and was authored, remixed, and/or curated by LibreTexts.

2.10: Cat vertebral column

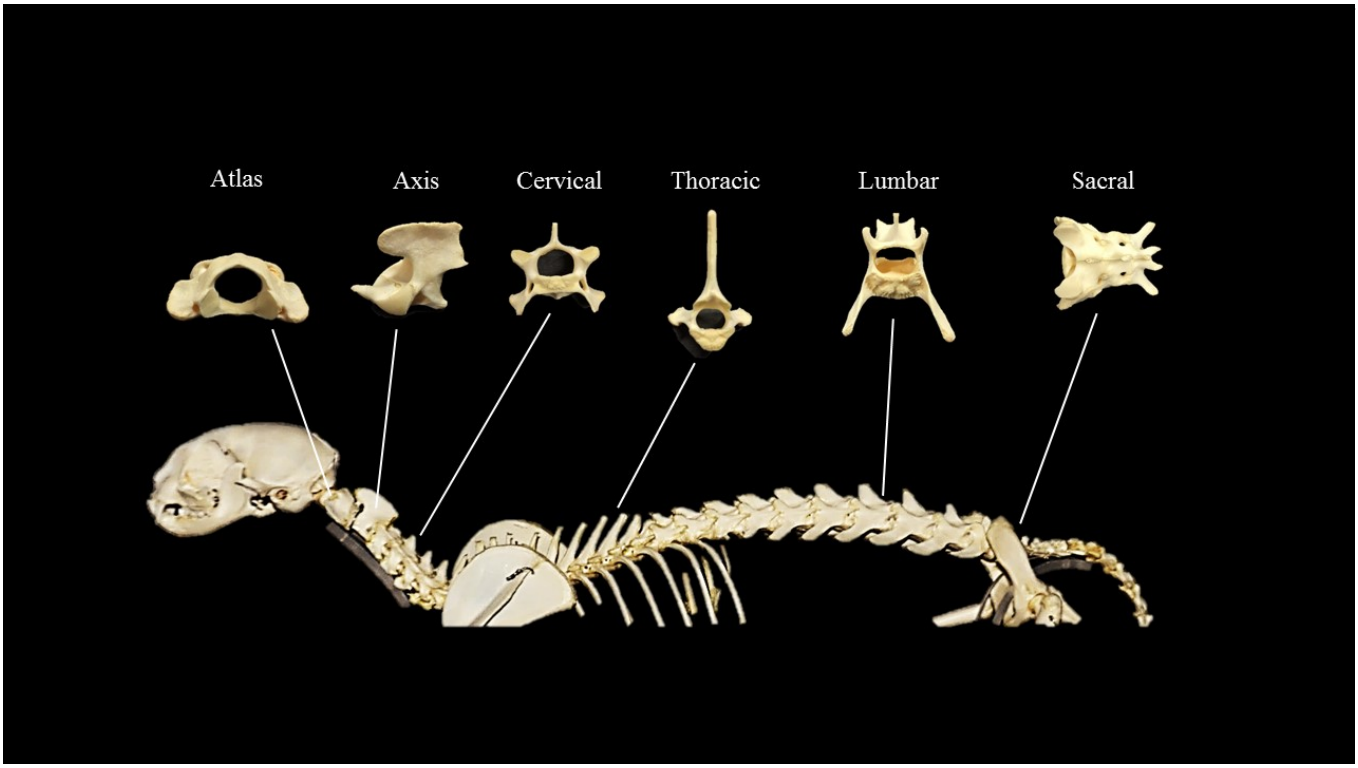

Vertebrae of the cat. CC-BY Sisina Macchiarelli & Daniel Saugar.

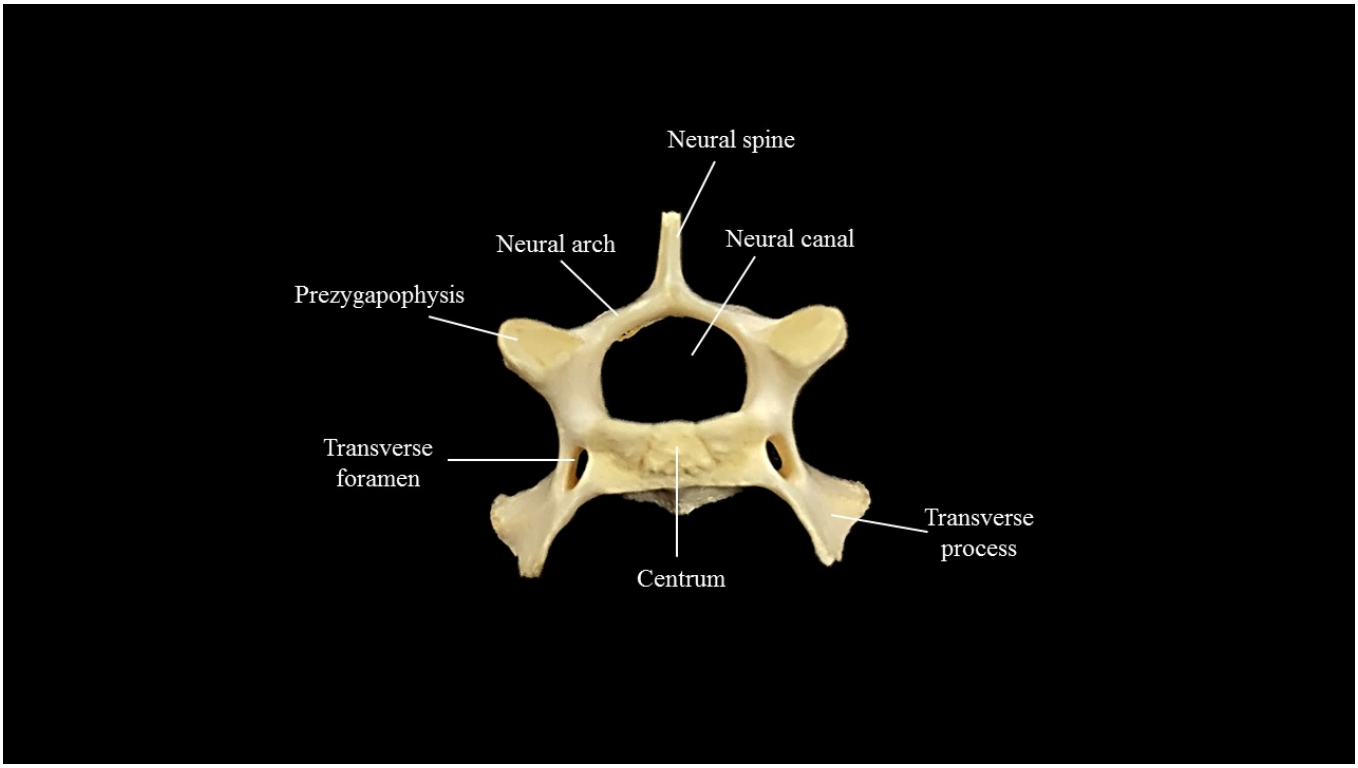

Cervical vertebra of the cat. CC-BY Sisina Macchiarelli & Daniel Saugar.

Contributors and Attributions

- Cat vertebral column. **Authored by**: Sisina Macchiarelli & Daniel Saugar. **License**: *CC BY: Attribution*

2.10: Cat vertebral column is shared under a CC BY 4.0 license and was authored, remixed, and/or curated by LibreTexts.

2.11: Cat scapula and ribs

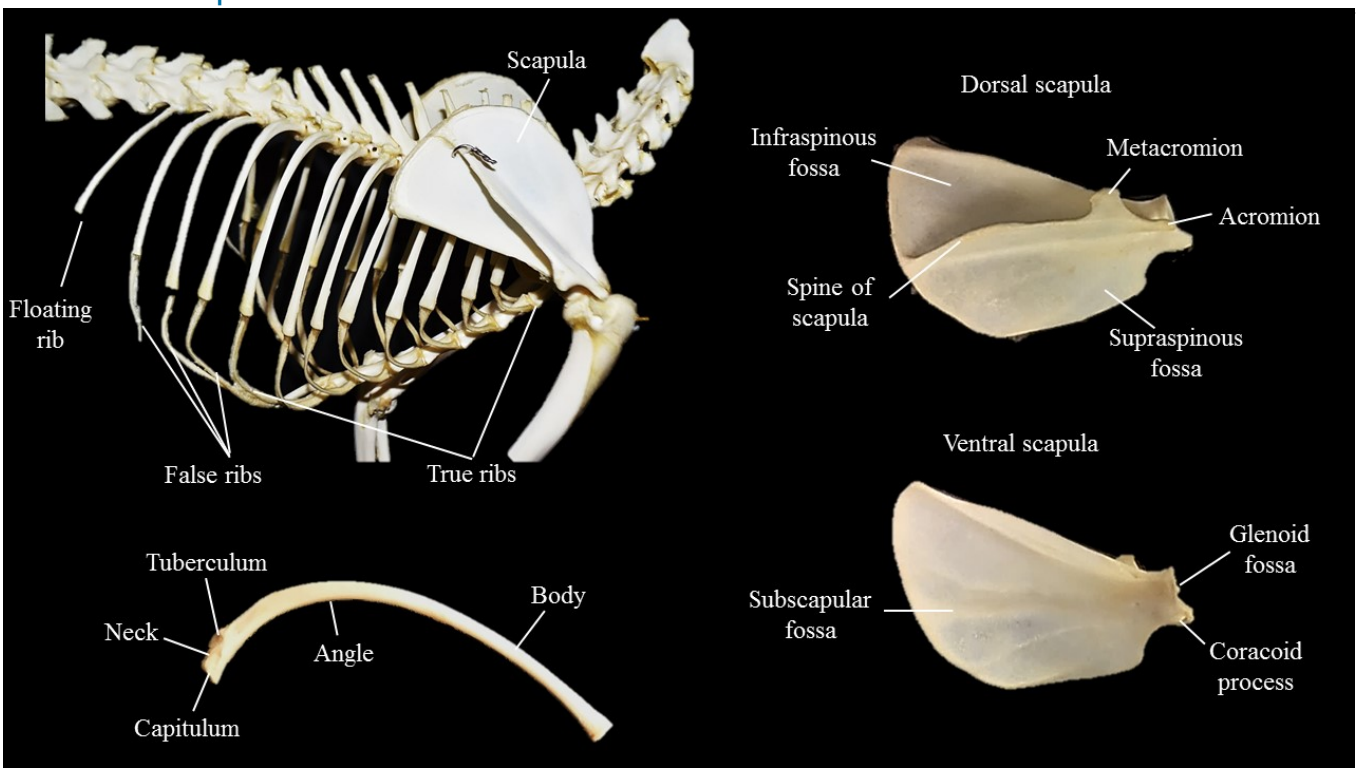

Scapula and ribs of the cat. CC-BY Sisina Macchiarelli & Daniel Saugar.

Contributors and Attributions

- Scapula and ribs of the cat. . **Authored by**: Sisina Macchiarelli & Daniel Saugar. **License**: *CC BY: Attribution*

2.11: Cat scapula and ribs is shared under a CC BY 4.0 license and was authored, remixed, and/or curated by LibreTexts.

2.12: Cat limbs

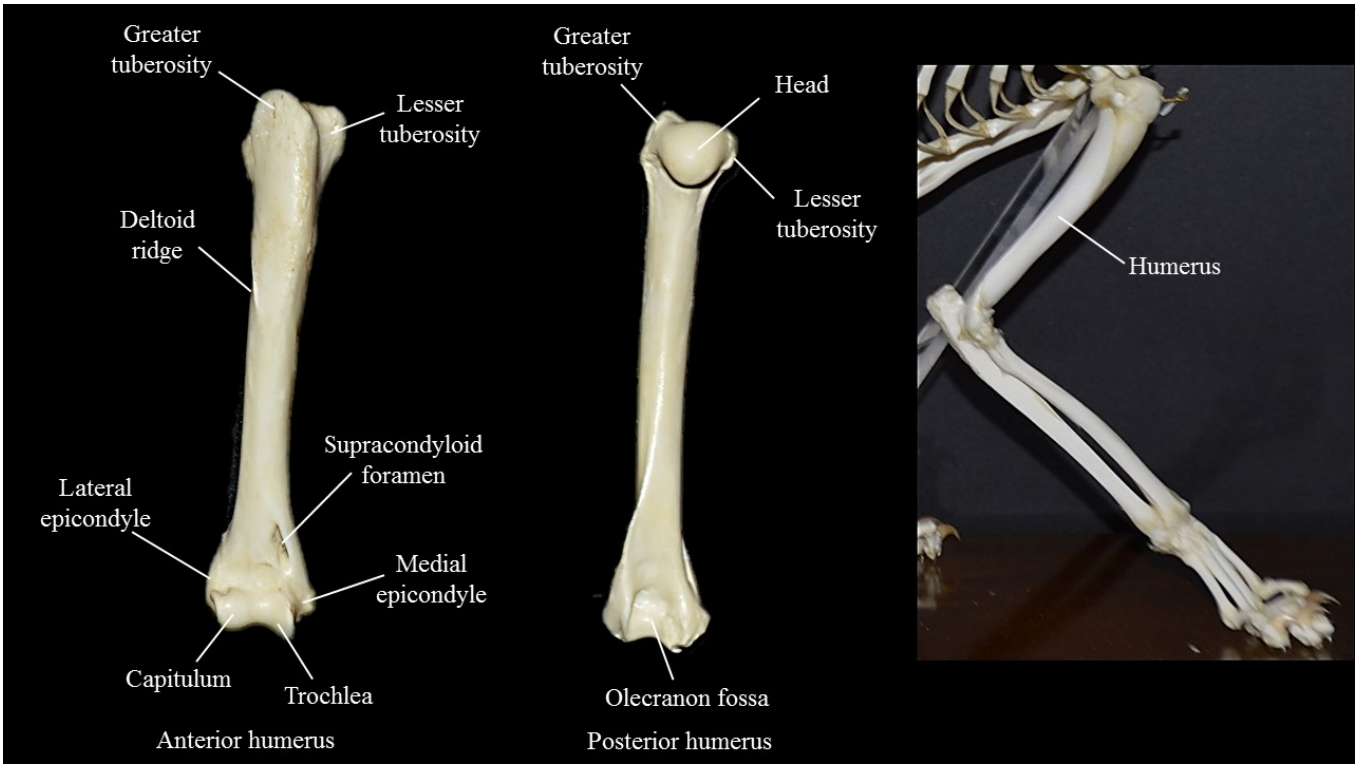

Humerus of the cat. CC-BY Sisina Macchiarelli, Daniel Saugar, & Kristen Roosa.

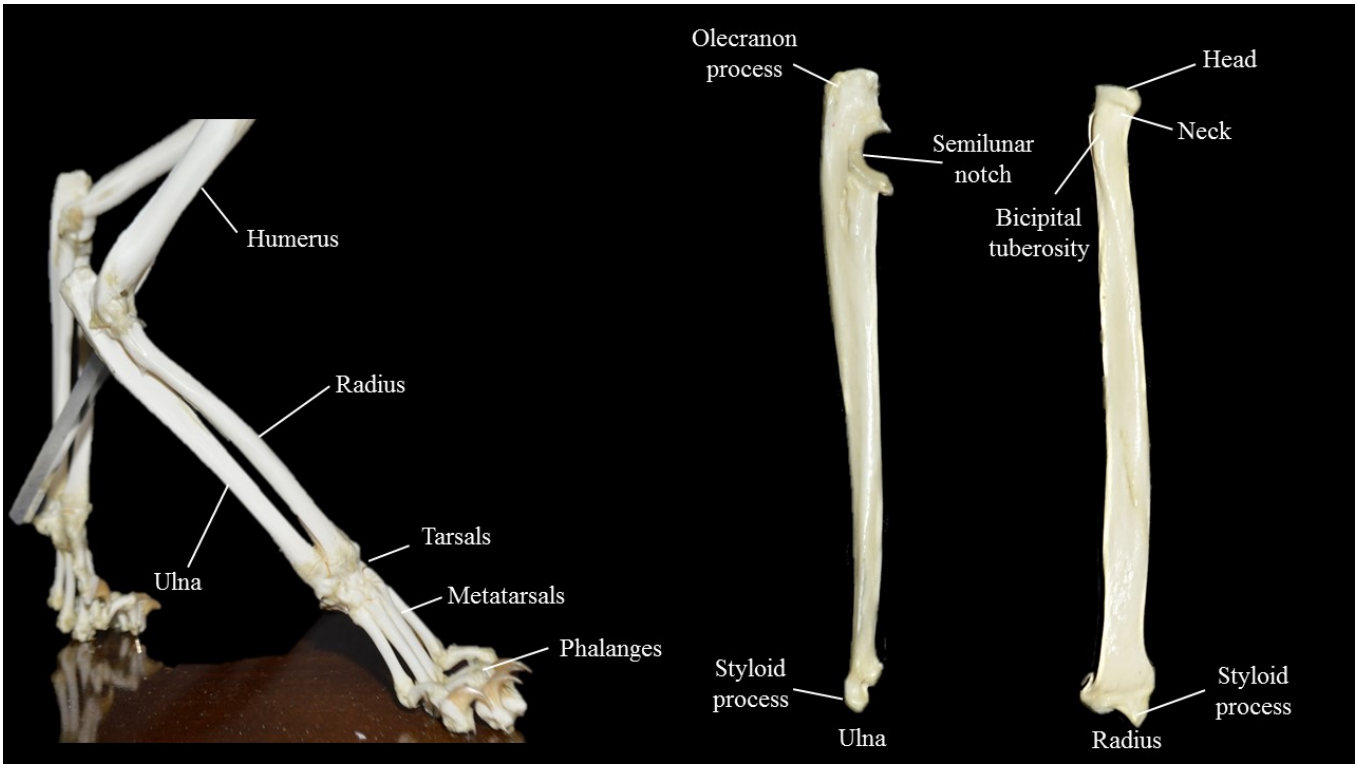

Radius and ulna of the cat. CC-BY Sisina Macchiarelli, Da

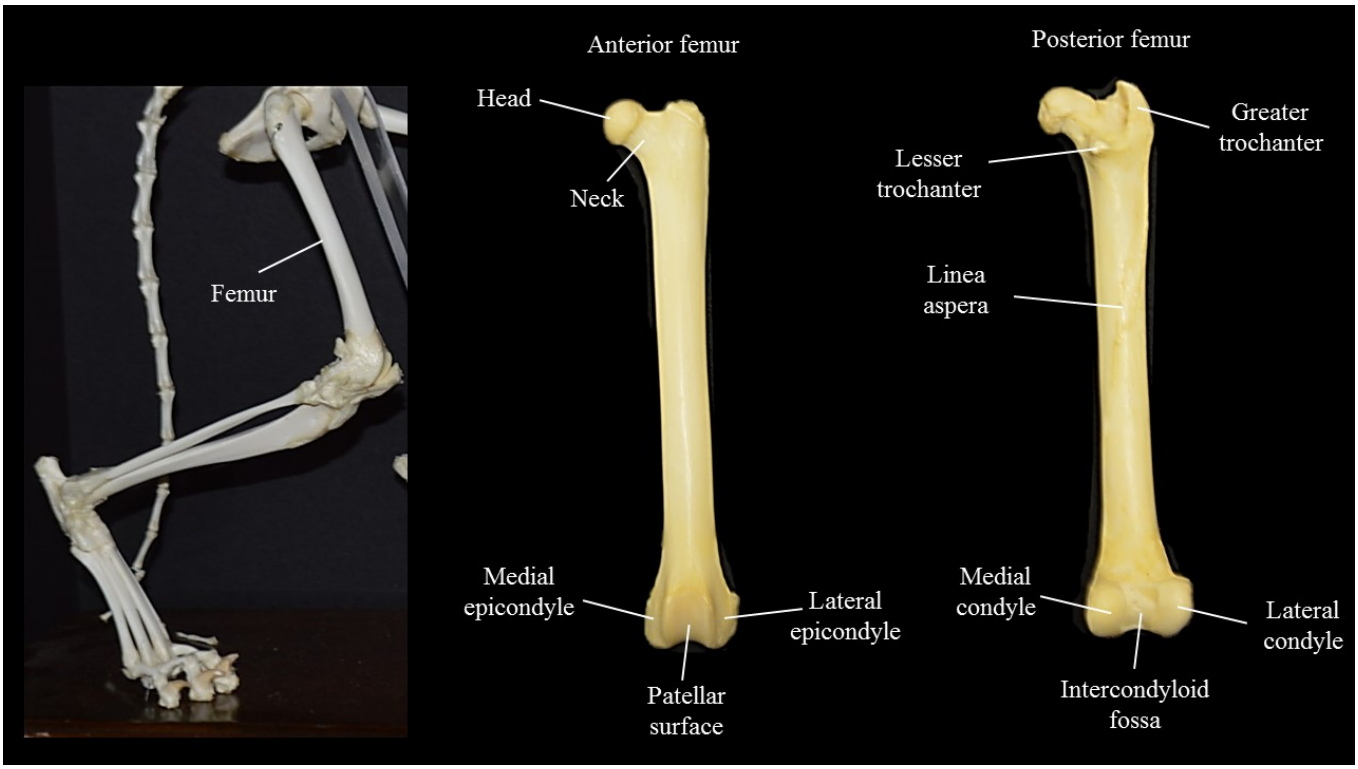

Femur of the cat. CC-BY Sisina Macchiarelli, Daniel Saugar, & Kristen Roosa

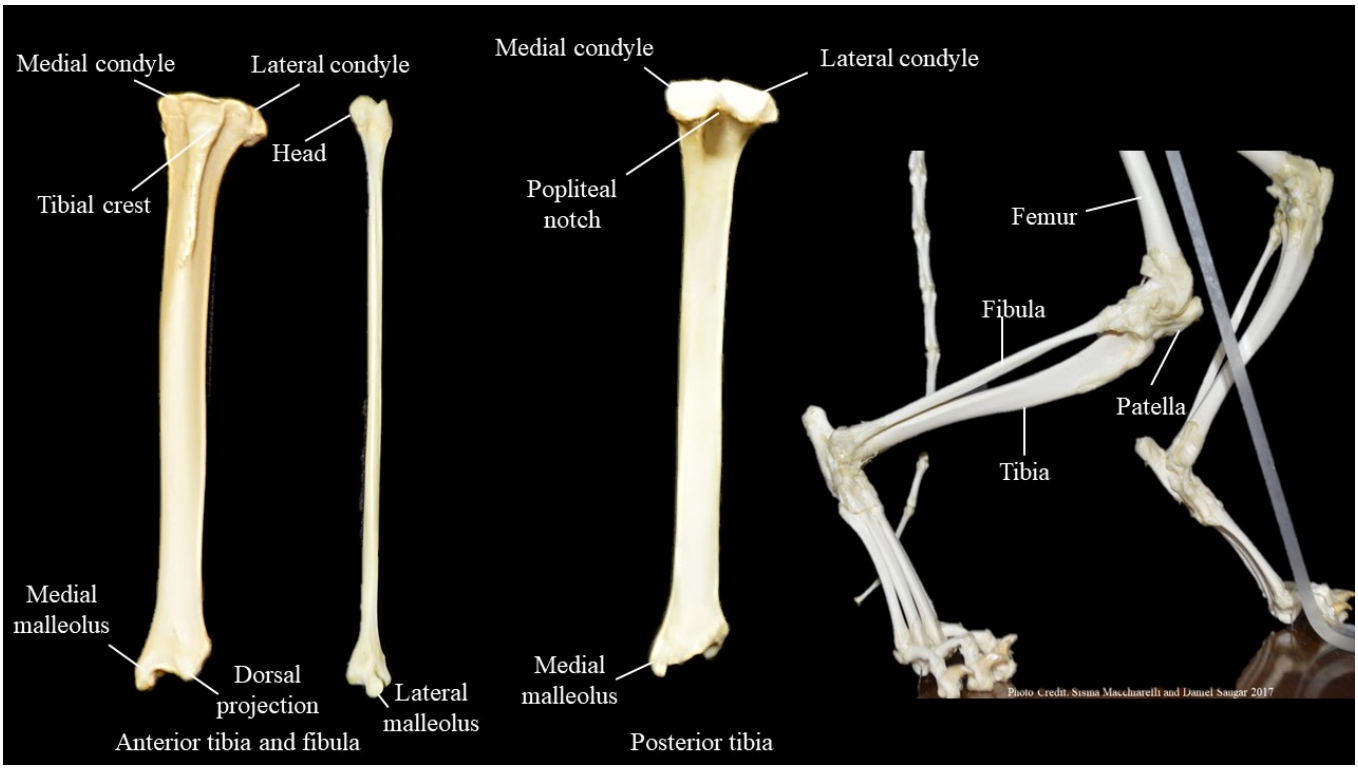

Tibia and fibula of the cat. CC-BY Sisina Macchiarelli, Daniel Saugar, & Kristen Roosa.

Contributors and Attributions

- Femur of the cat. **Authored by**: Sisina Macchiarelli, Daniel Saugar, & Kristen Roosa. **License**: *CC BY: Attribution*

2.12: Cat limbs is shared under a CC BY 4.0 license and was authored, remixed, and/or curated by LibreTexts.

CHAPTER OVERVIEW

3: Nervous systems

- 3.1: Squalus brain
- 3.2: Sheep brain

Page ID 55363

3: Nervous systems is shared under a CC BY 4.0 license and was authored, remixed, and/or curated by LibreTexts.

3.1: Squalus brain

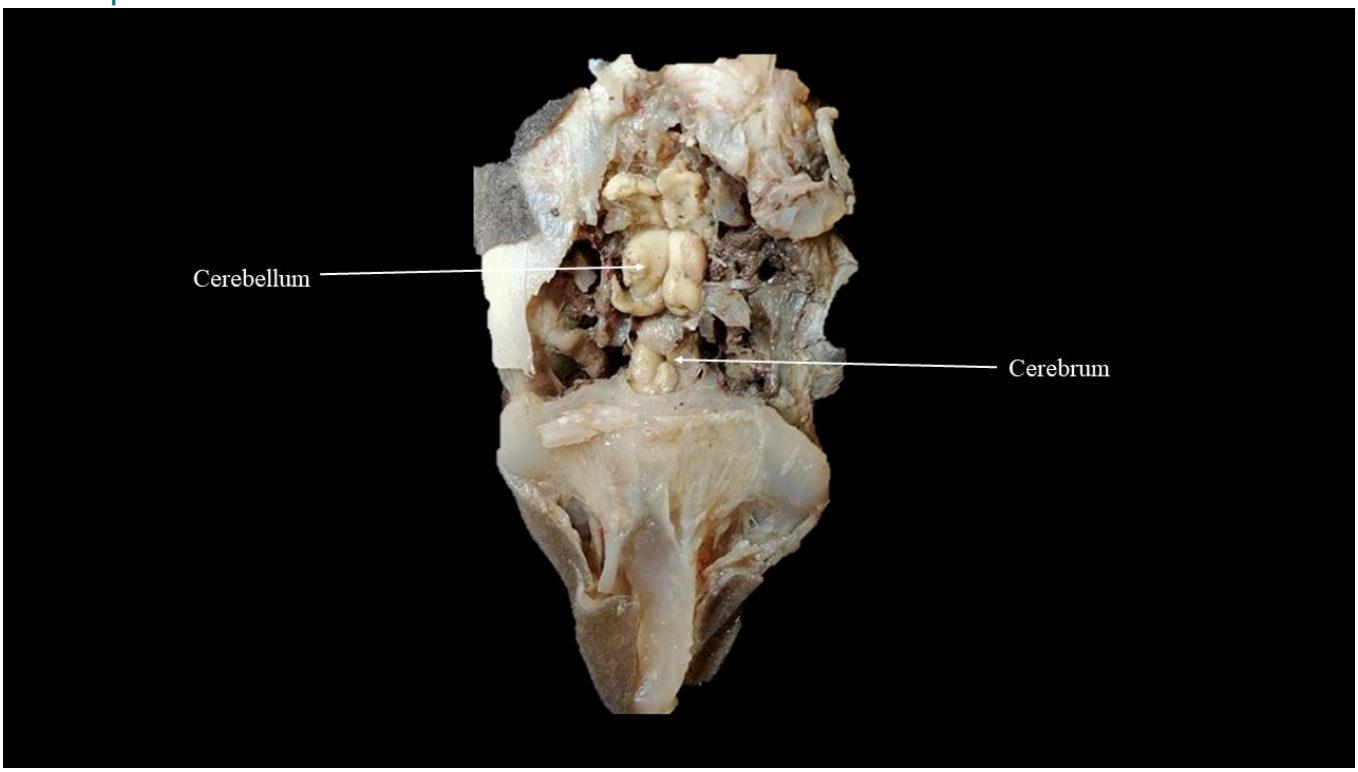

Dorsal view of the shark brain. CC BY Elizabeth Swislosky and Kristin Conroy.

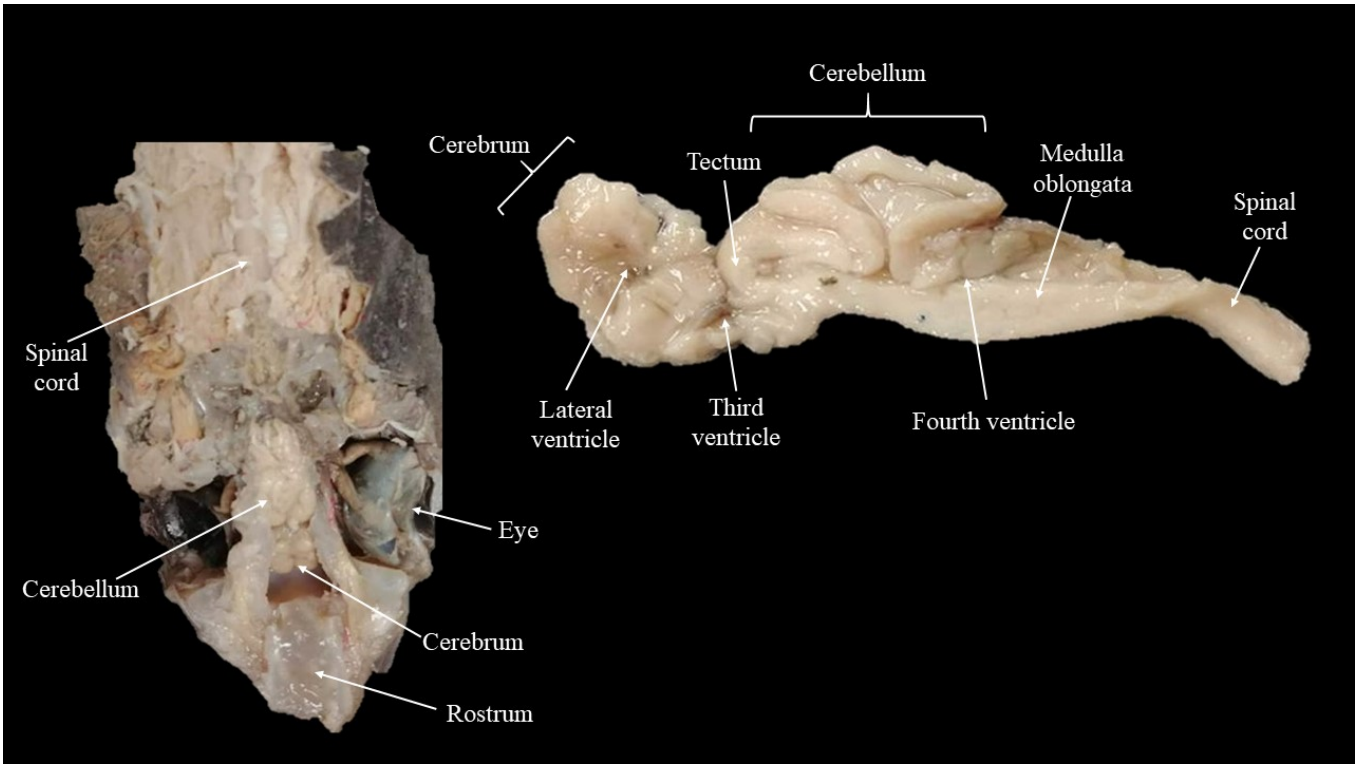

Dorsal view (left) of Squalus brain and midsagittal section through Squalus brain (right). CC BY Kristin Conroy & Elizabeth Swislosky.

Contributors and Attributions

- Shark brain . **Authored by**: Elizabeth Swislosky & Kirstin Conroy. **License**: *CC BY: Attribution*

3.1: Squalus brain is shared under a CC BY 4.0 license and was authored, remixed, and/or curated by LibreTexts.

3.2: Sheep brain

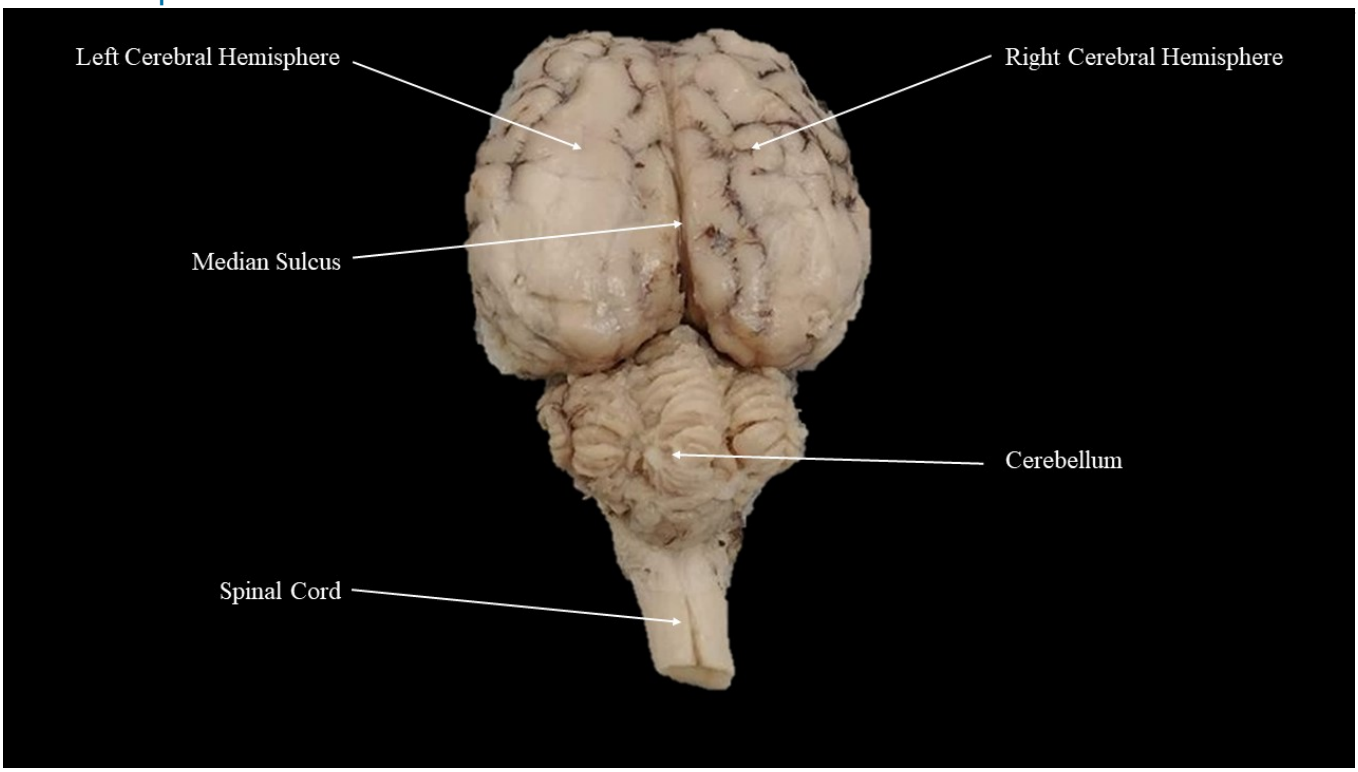

Dorsal view of the sheep brain. Dura matter removed. CC-BY: Elizabeth Swislosky and Kirstin Conroy

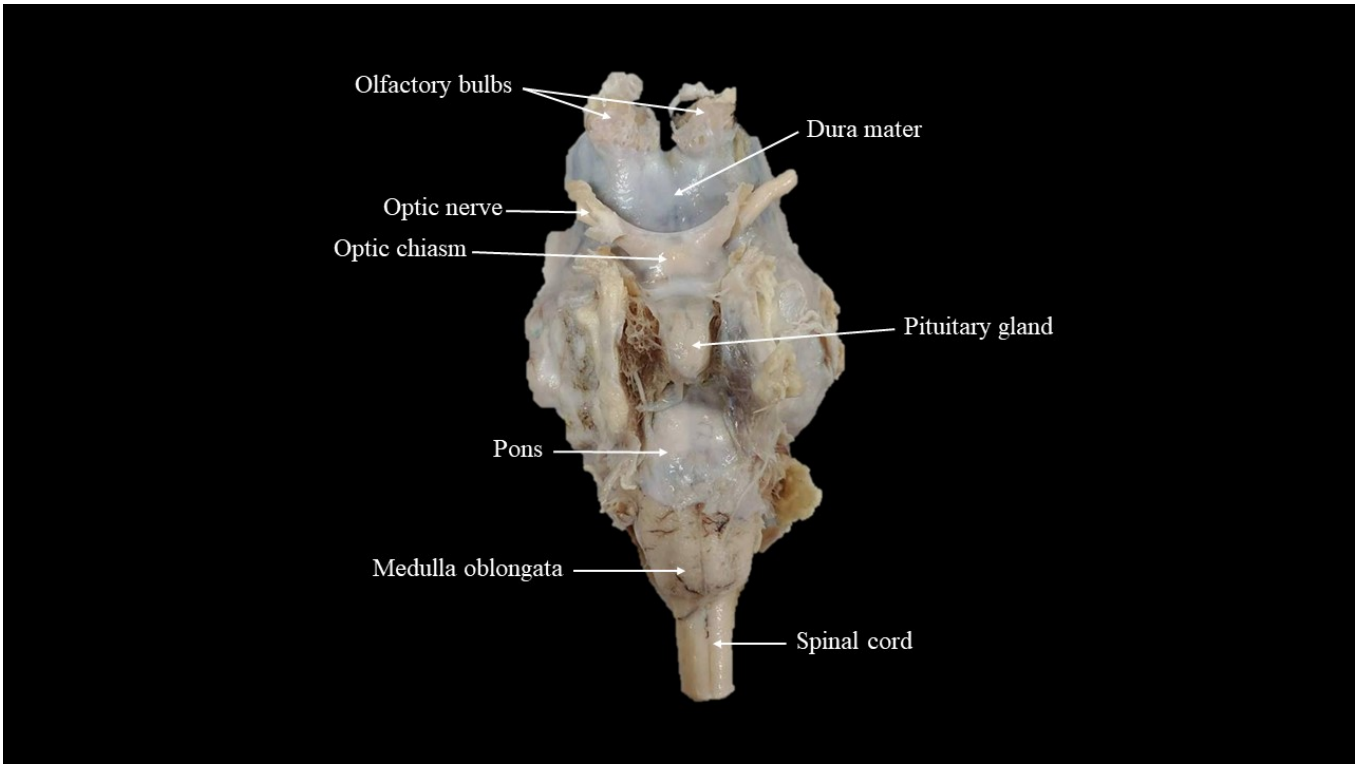

Ventral view of the sheep brain. CC-BY: Elizabeth Swislosky and Kirstin Conroy

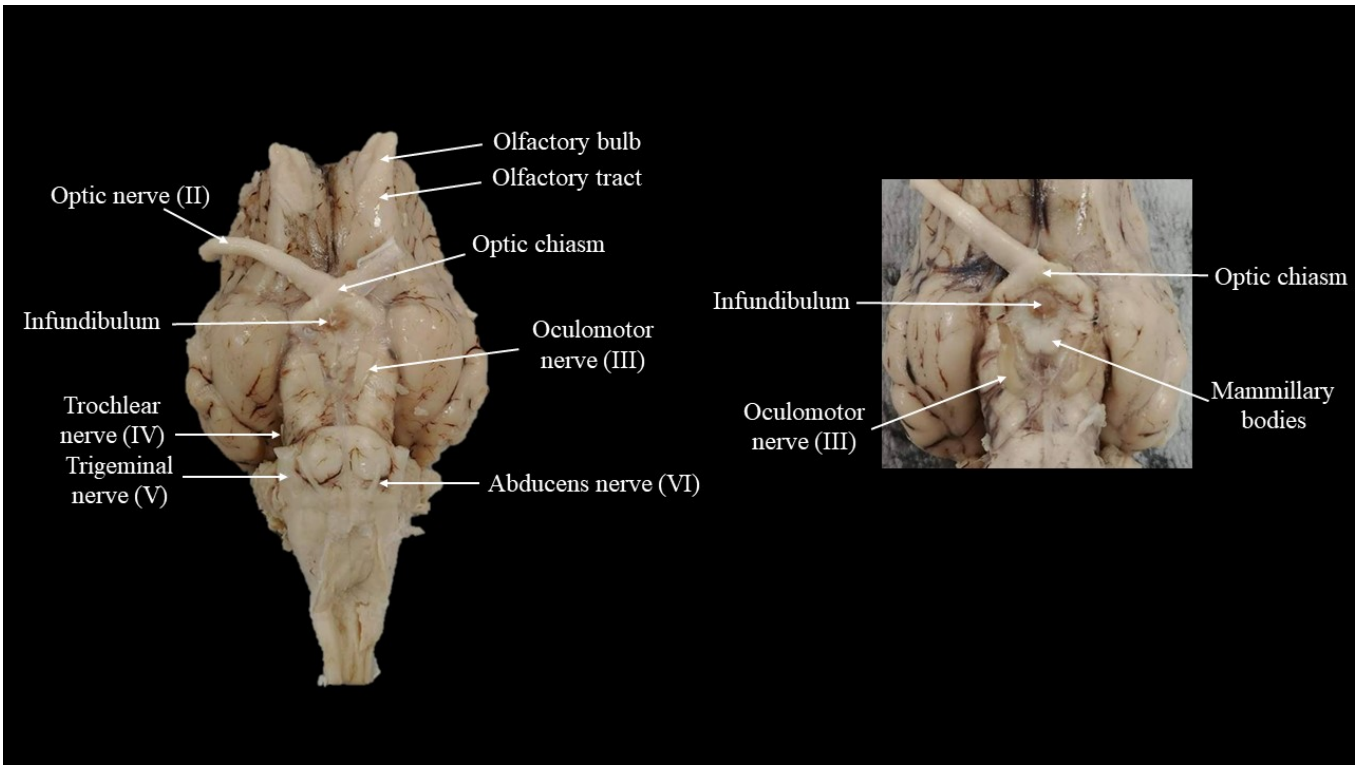

Ventral view of the sheep brain and close up. CC-BY: Elizabeth Swislosky and Kristin Conroy

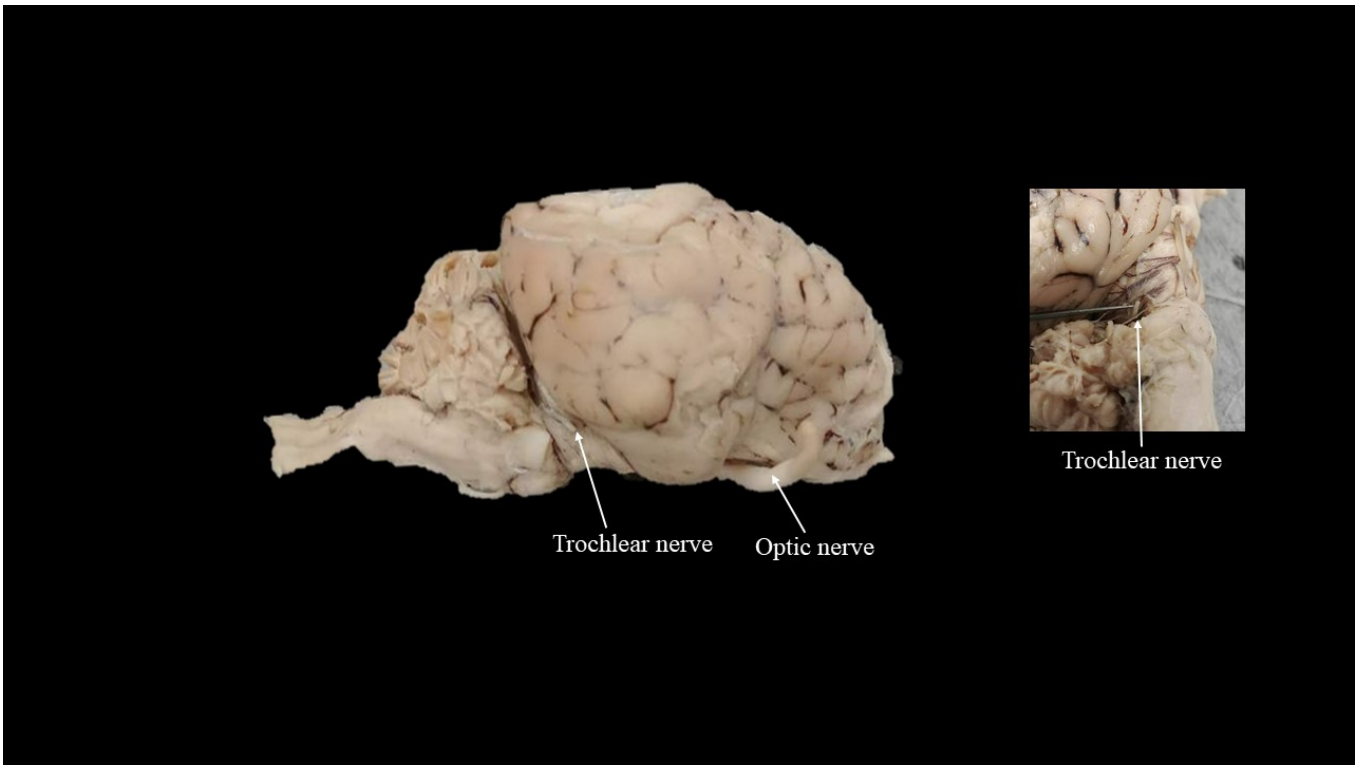

Lateral view of the sheep brain. CC-BY: Elizabeth Swislosky and Kristin Conroy

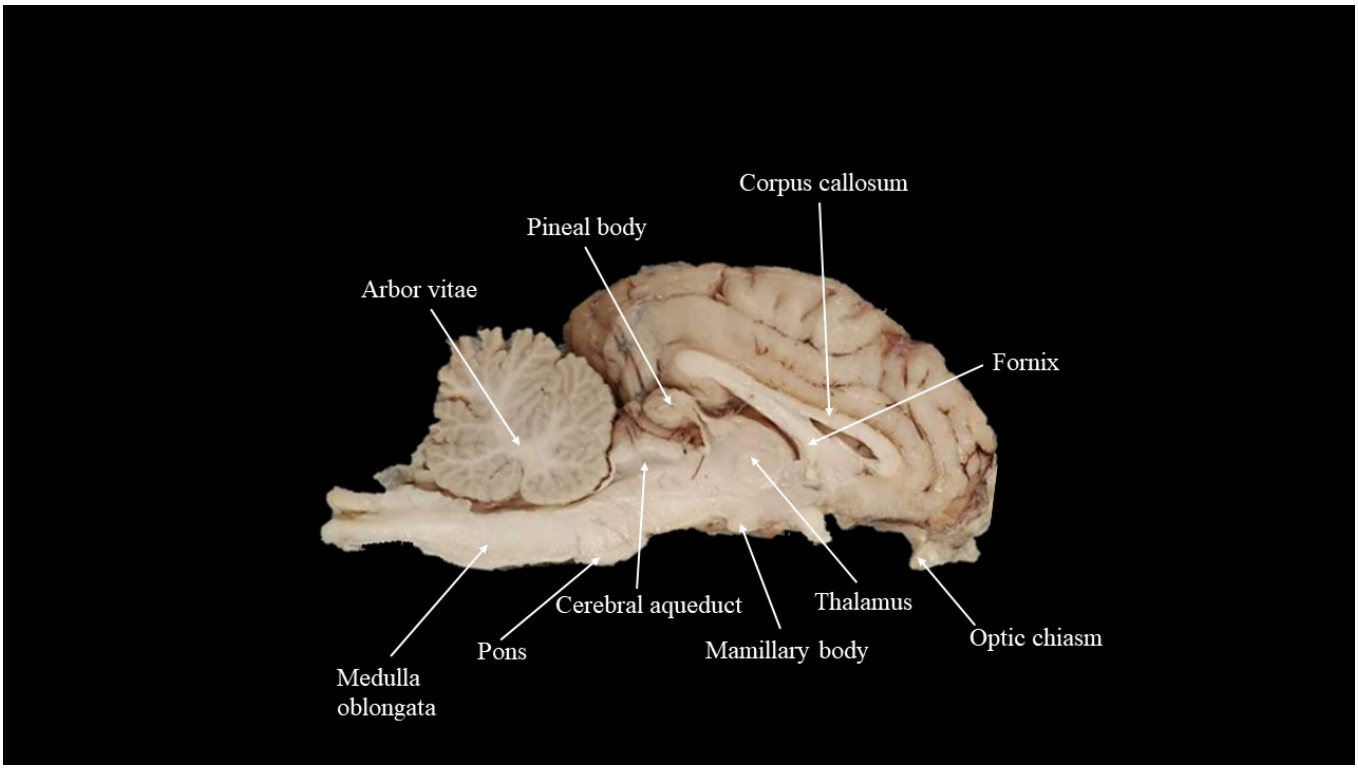

Sagittal view of the sheep brain. CC-BY: Elizabeth Swislosky and Kristin Conroy

Contributors and Attributions

- Sheep Brain . **Authored by**: Elizabeth Swislosky & Kirstin Conroy. **License**: *CC BY: Attribution*

3.2: Sheep brain is shared under a CC BY 4.0 license and was authored, remixed, and/or curated by LibreTexts.

CHAPTER OVERVIEW

4: Digestive systems

4.1: Squalus digestive system
4.2: Necturus digestive system
4.3: Cat digestive system

4: Digestive systems is shared under a CC BY 4.0 license and was authored, remixed, and/or curated by LibreTexts.

4.1: Squalus digestive system

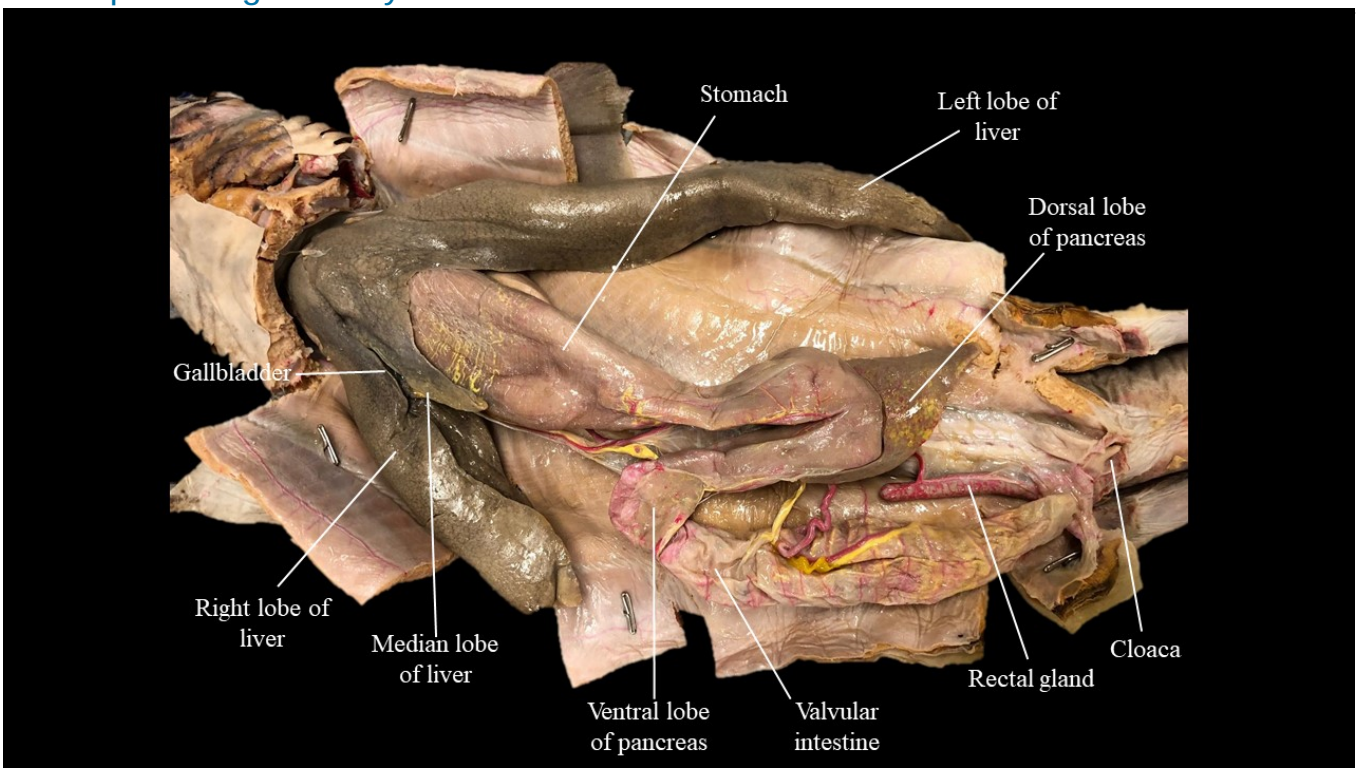

Ventral view of the shark digestive system. CC-BY: Brittany Riddick and Morgan Gray

Contributors and Attributions

- Shark digestive system. **Authored by**: Brittany Riddick & Morgan Gray. **License**: *CC BY: Attribution*

4.1: Squalus digestive system is shared under a CC BY 4.0 license and was authored, remixed, and/or curated by LibreTexts.

4.2: Necturus digestive system

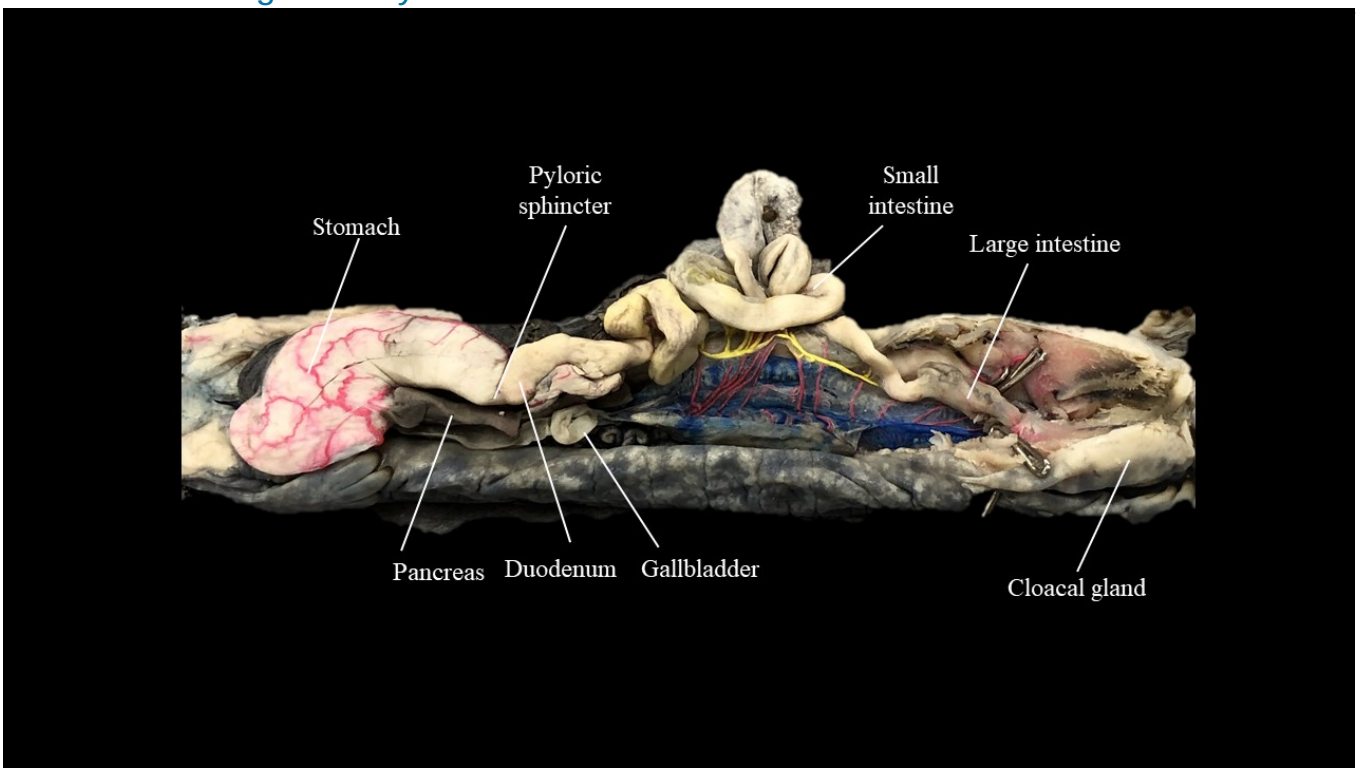

Ventral view of mudpuppy digestive system. CC-BY: Brittany Riddick and Morgan Gray

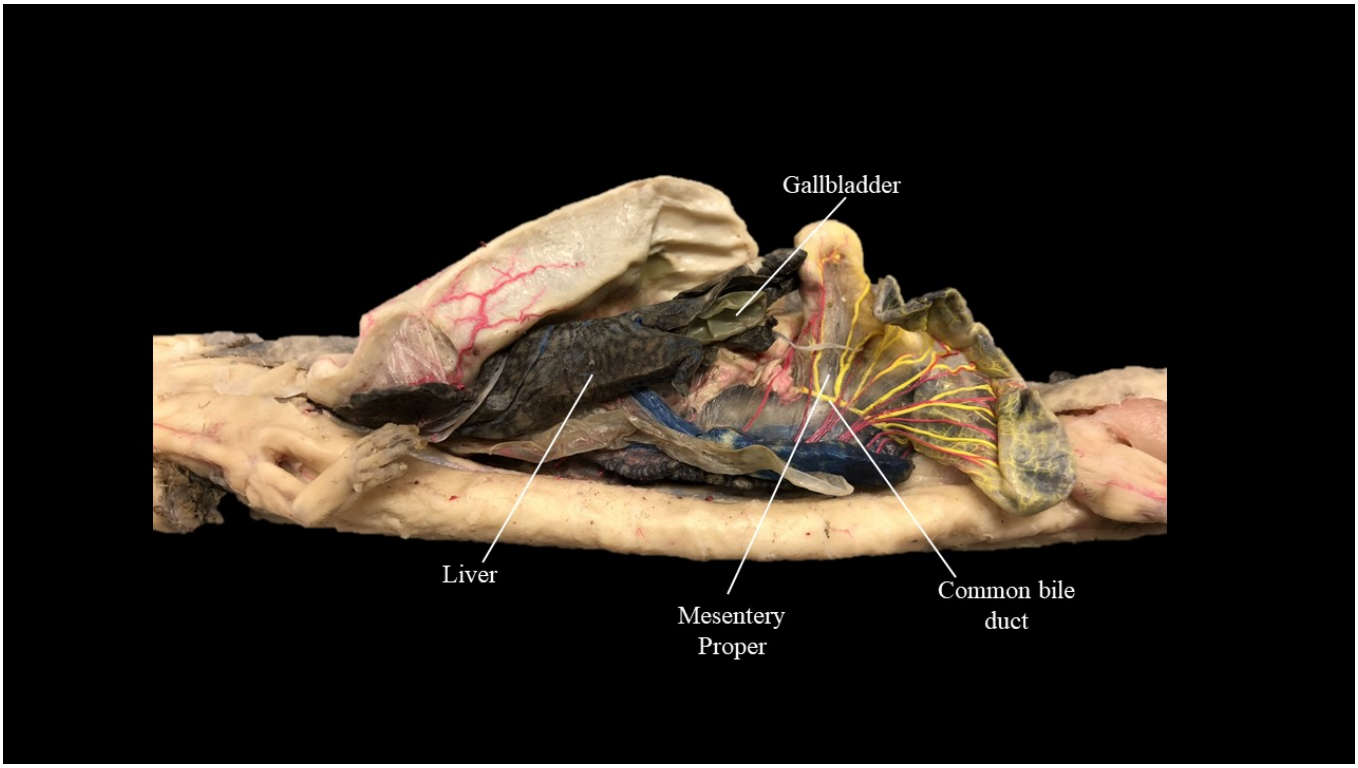

Lateral view of the mudpuppy digestive system. CC-BY: Brittany Reddick and Morgan Gray

Contributors and Attributions

- **Authored by**: Brittany Riddick & Morgan Gray. **License**: *CC BY: Attribution*

4.2: Necturus digestive system is shared under a CC BY 4.0 license and was authored, remixed, and/or curated by LibreTexts.

4.3: Cat digestive system

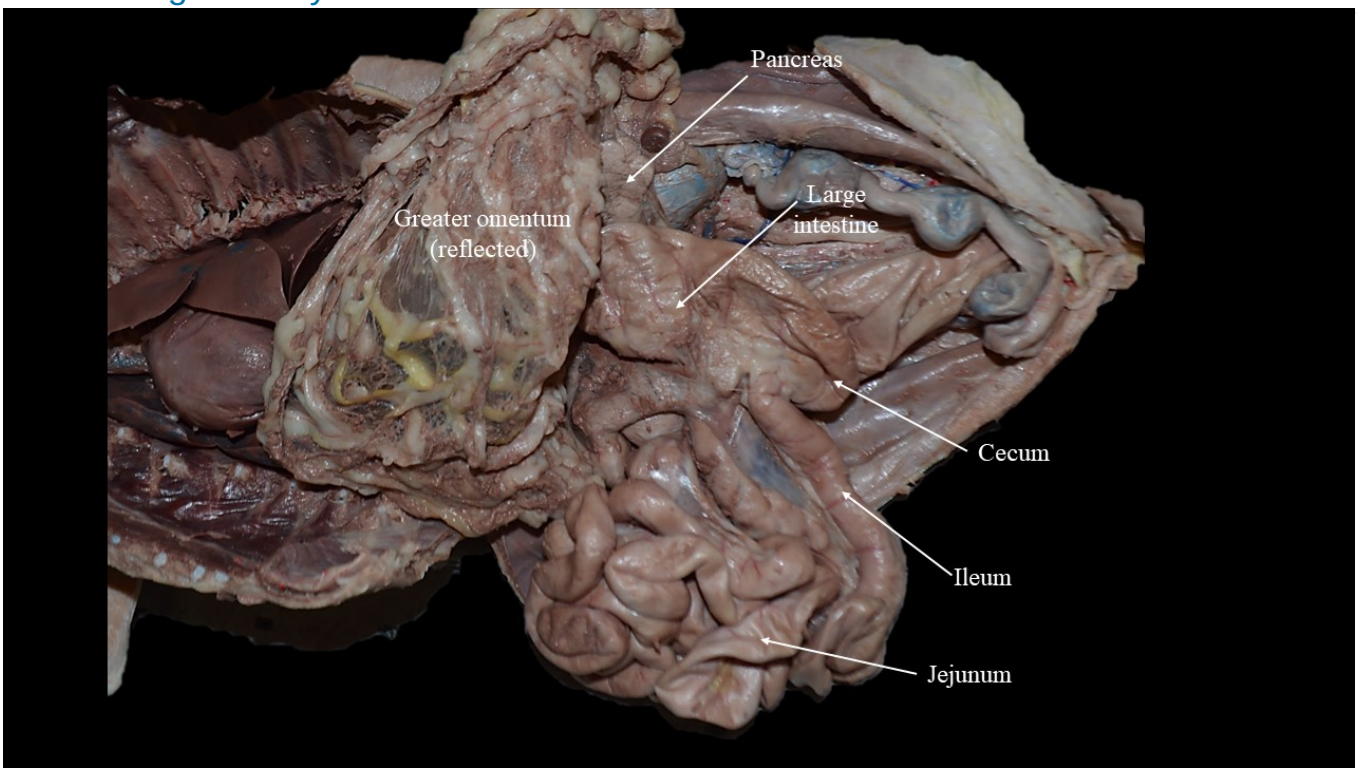

Digestive tract of the cat. CC-BY Kristen Roosa.

4.3: Cat digestive system is shared under a CC BY 4.0 license and was authored, remixed, and/or curated by LibreTexts.

CHAPTER OVERVIEW

5: Muscular systems

5.1: Squalus musculature
5.2: Necturus musculature
5.3: Cat Musculature

5: Muscular systems is shared under a CC BY 4.0 license and was authored, remixed, and/or curated by LibreTexts.

5.1: Squalus musculature

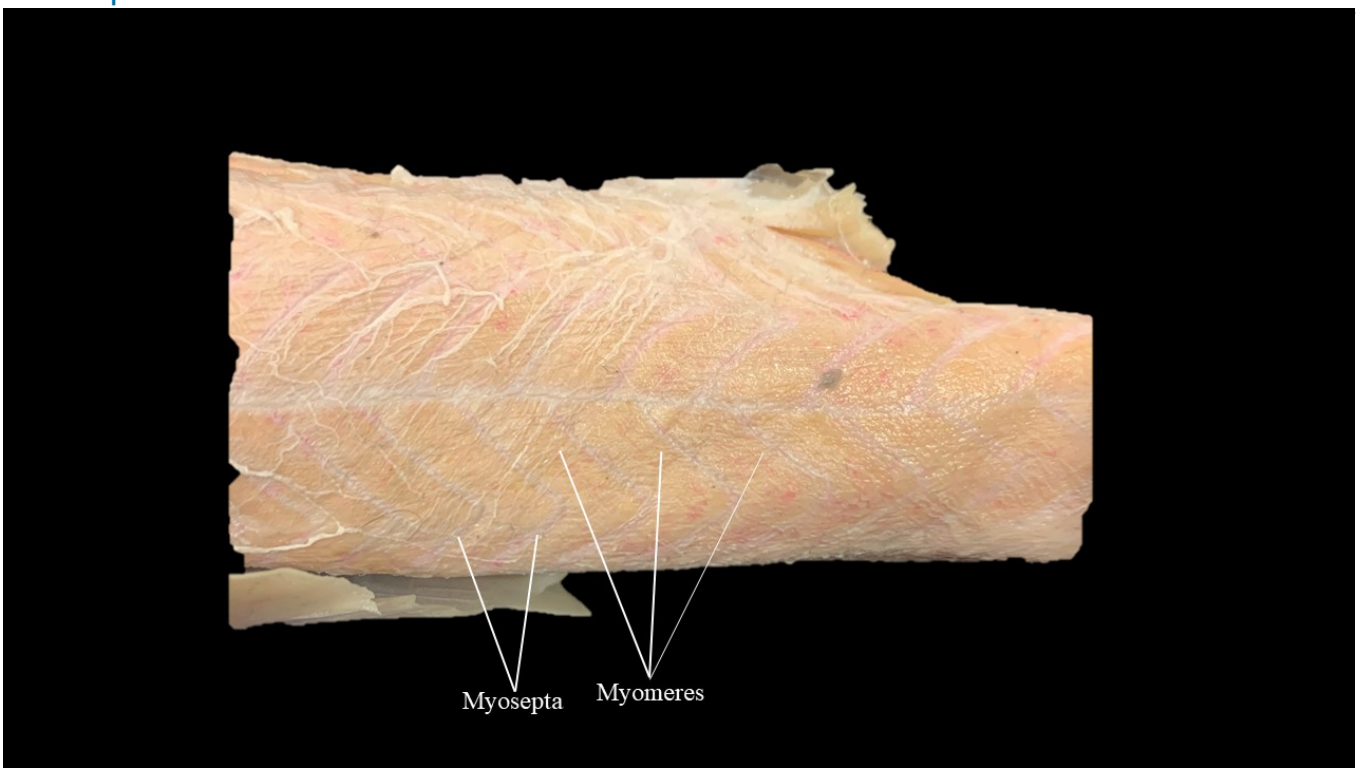

Squalus myomeres. CC-BY Jarred Epps.

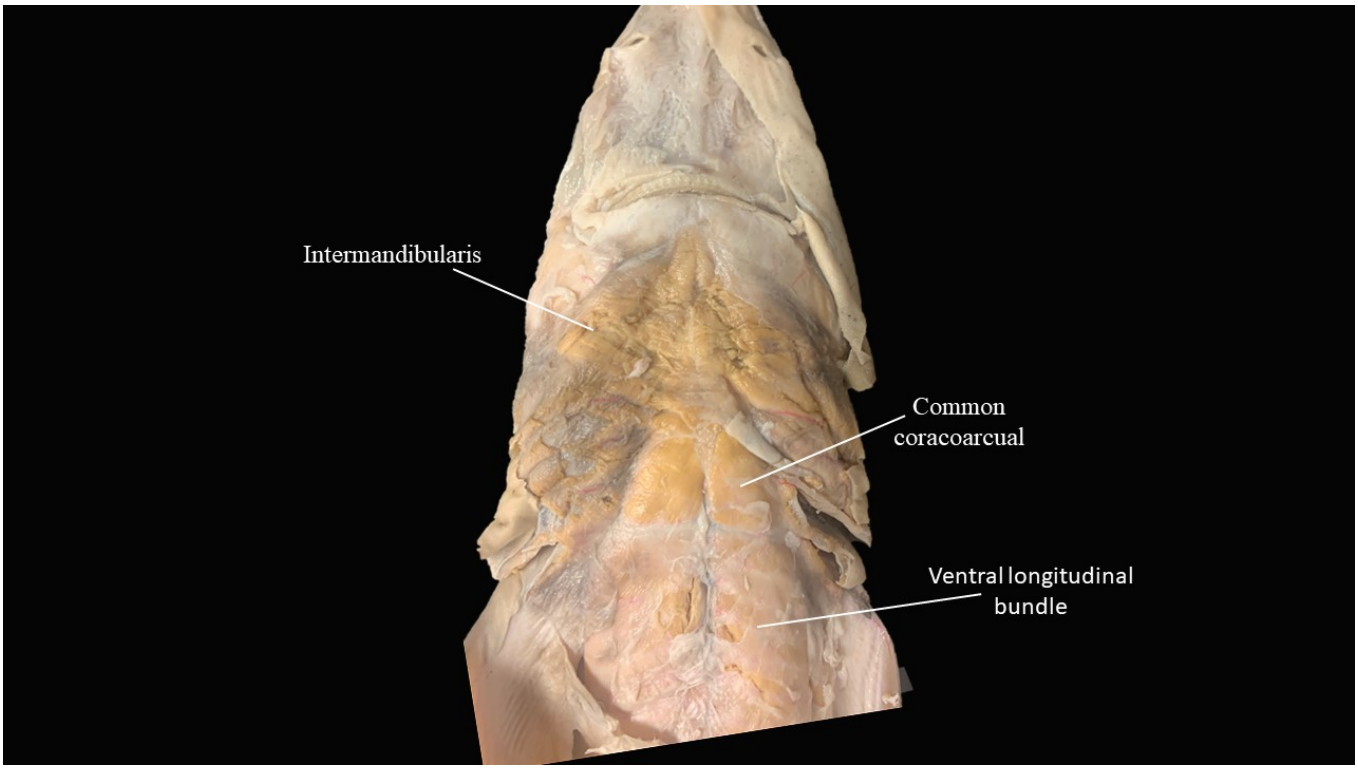

Ventral view of head musculature of *Squalus*. CC-BY Jarred Epps.

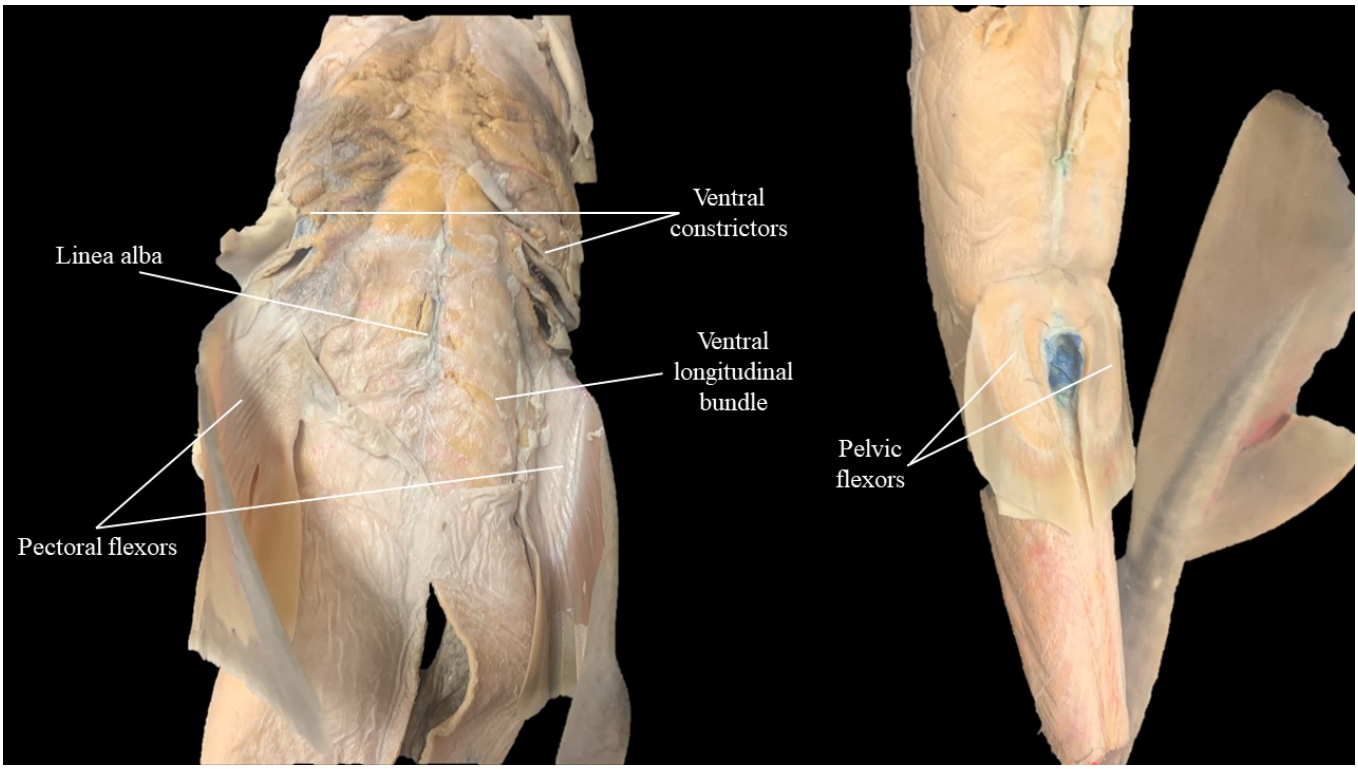

Ventral view of head and trunk musculature of *Squalus*. CC-BY Jarred Epps.

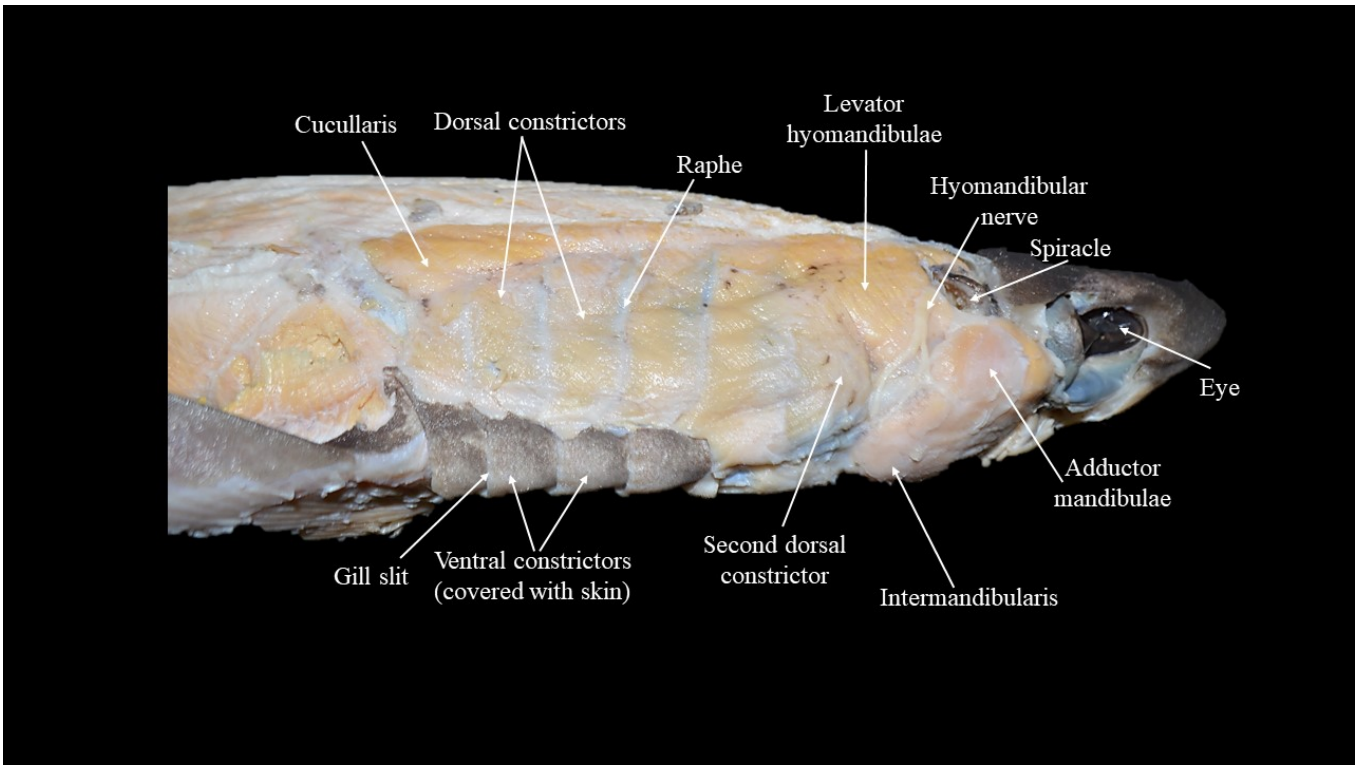

Lateral view of head musculature of *Squalus*. CC BY Kristen Roosa.

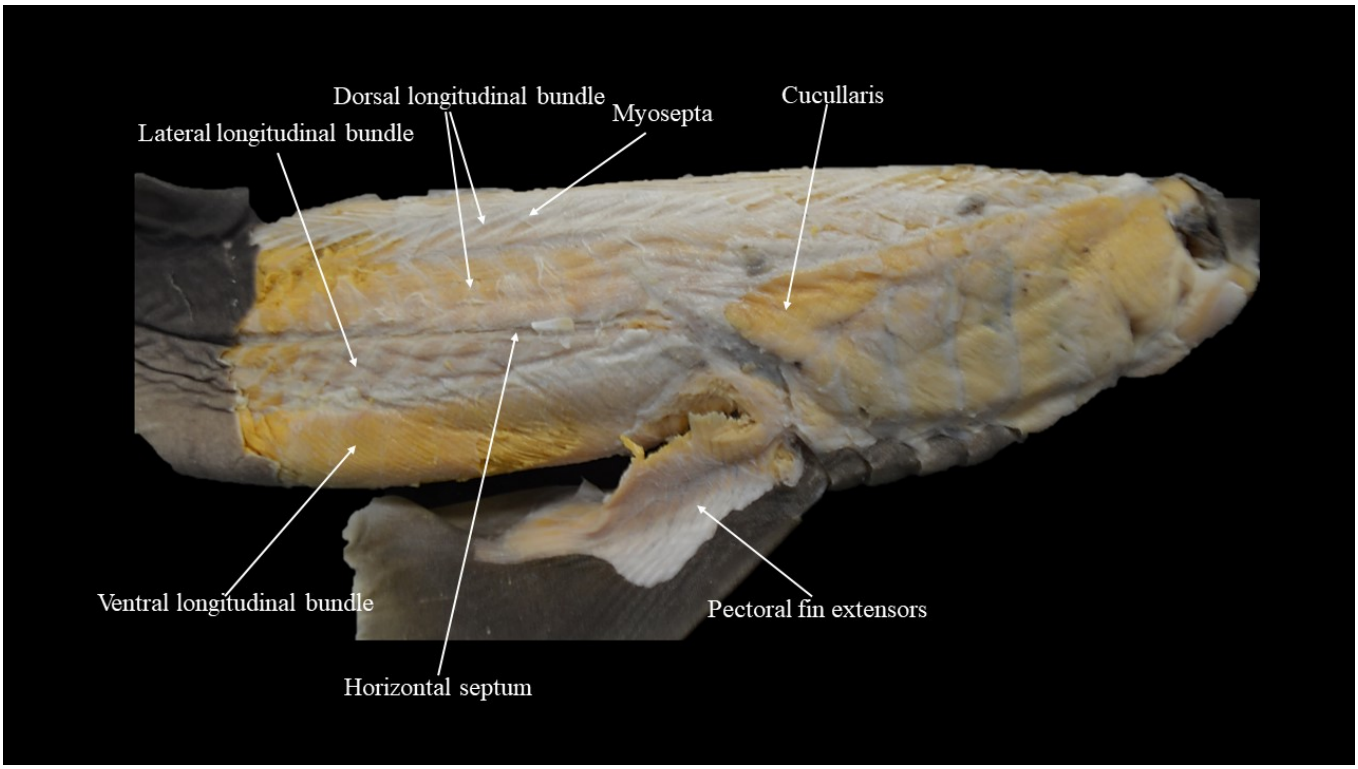

Lateral view of the trunk musculature of *Squalus*. CC BY Kristen Roosa.

Contributors and Attributions

- Musculature of Squalus. **Authored by**: Jarred Epps. **License**: *CC BY: Attribution*

5.1: Squalus musculature is shared under a CC BY 4.0 license and was authored, remixed, and/or curated by LibreTexts.

5.2: Necturus musculature

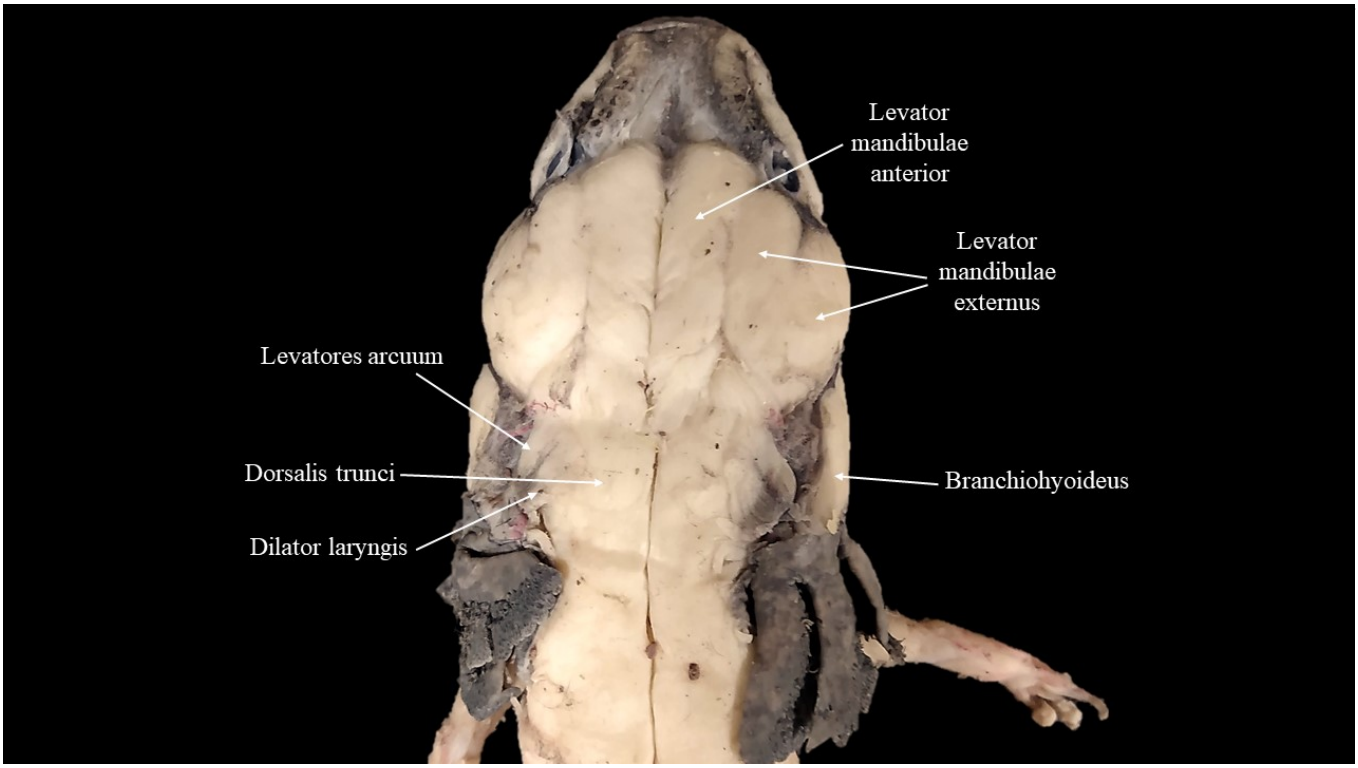

Musculature of the dorsal aspect of the head of Necturus. CC-BY Kristen Roosa.

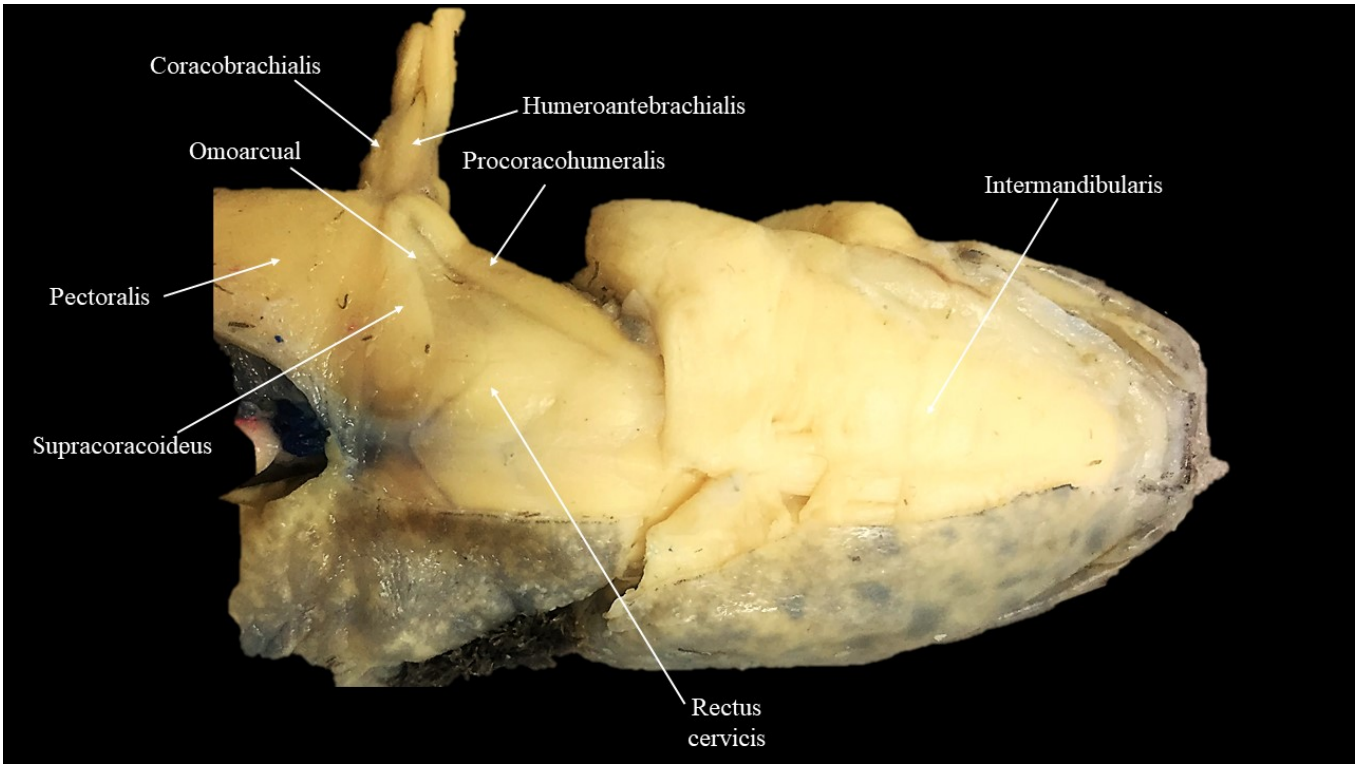

Superficial musculature of the ventral aspect of head of Necturus. CC-BY Jessica Carson & Jaclyn Ruhl.

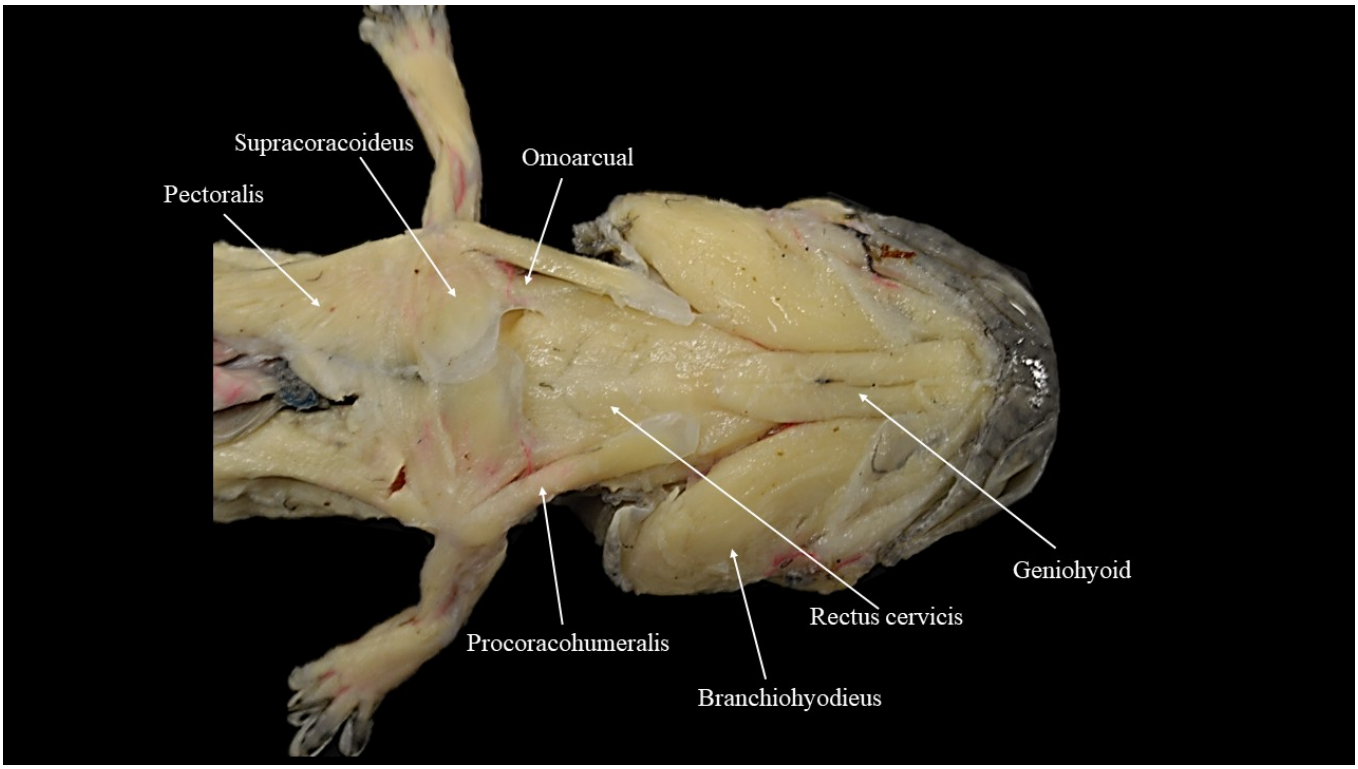

Deep musculature of the ventral aspect of head of Necturus. CC-BY Kristen Roosa.

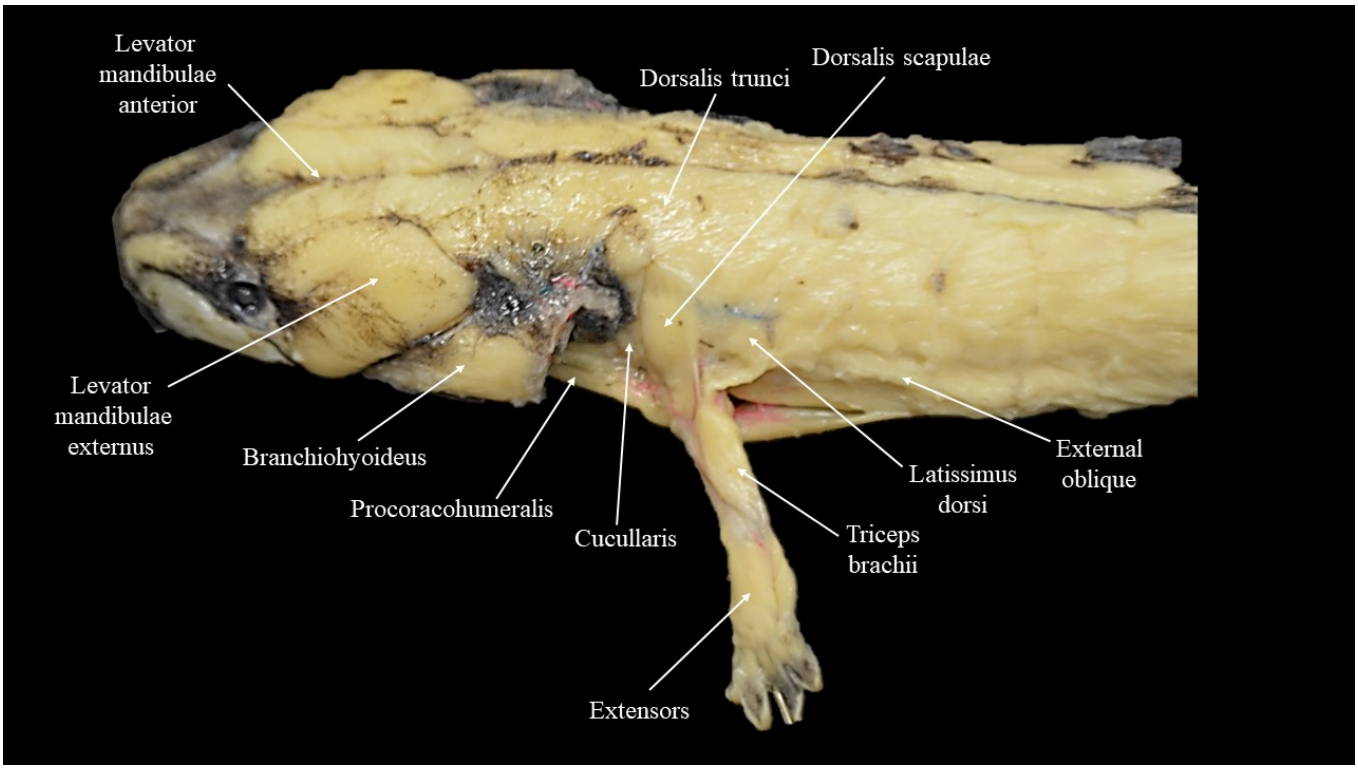

Lateral view of the forelimb musculature of Necturus. CC-BY Elizabeth Swislosky.

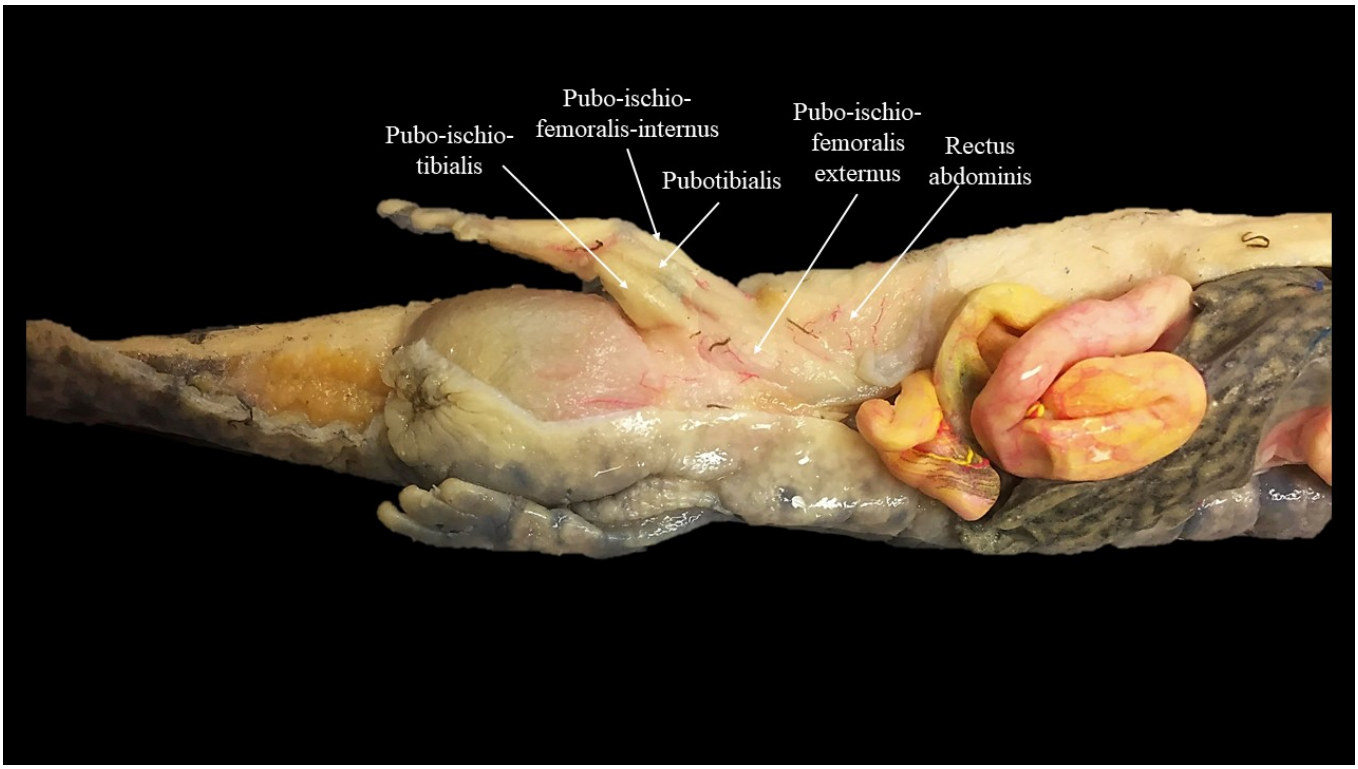

Musculature of ventral aspect of hind limb of Necturus. CC-BY Kristen Roosa.

Contributors and Attributions

- Necturus muscular system. **Authored by**: Kristen Roosa, Elizabeth Swislosky, Jaclyn Ruhl, Jessica Carson . **License**: *CC BY: Attribution*

5.2: Necturus musculature is shared under a CC BY 4.0 license and was authored, remixed, and/or curated by LibreTexts.

5.3: Cat Musculature

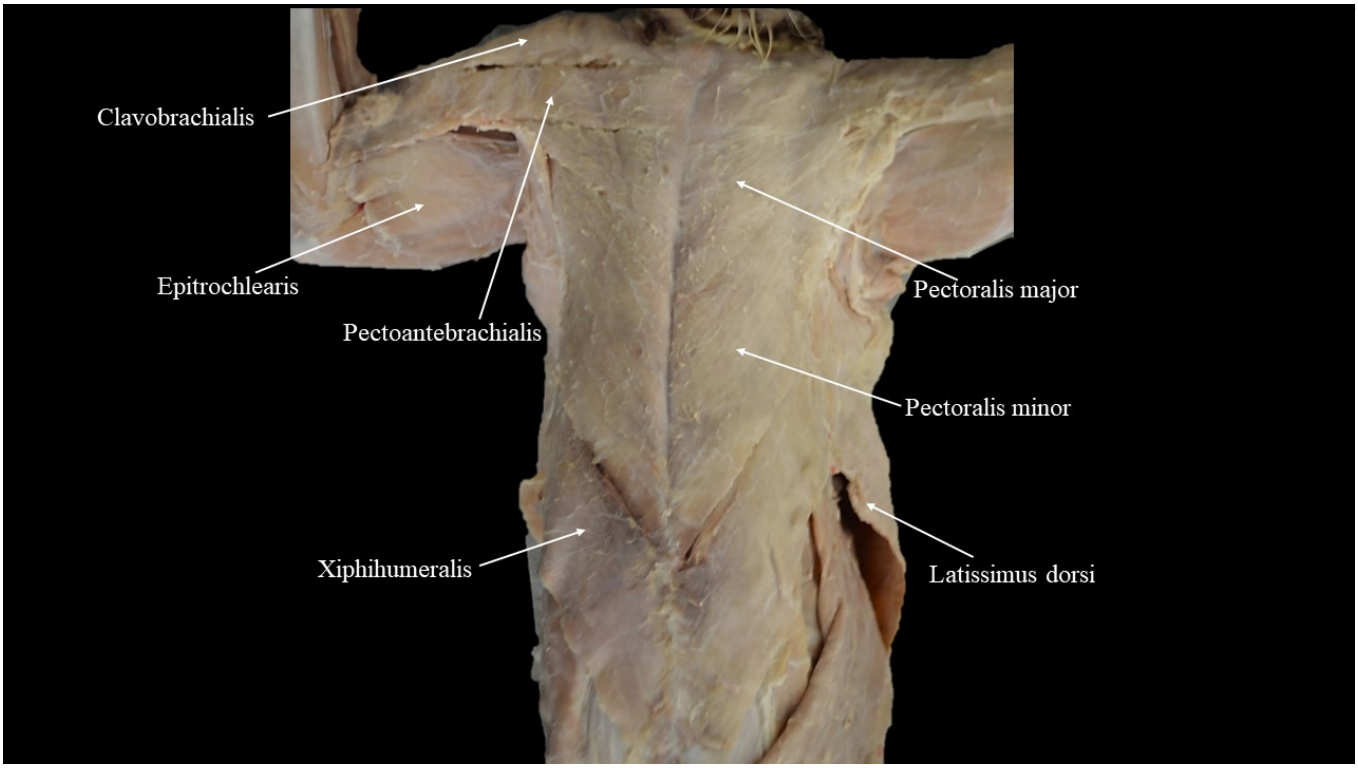

Ventral view of the cat chest muscles. CC-BY: Elizabeth Swislosky

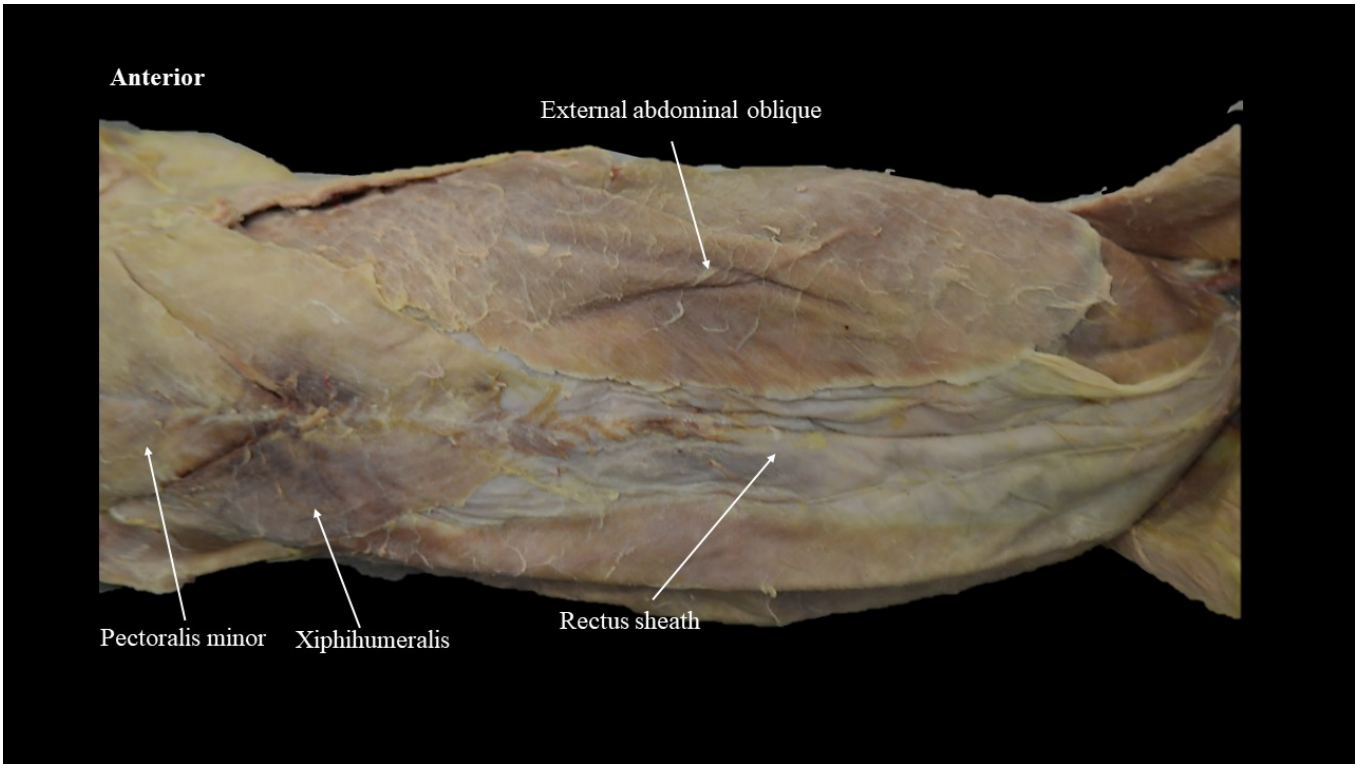

Ventral view of the cat abdominal external muscles. CC-BY: Elizabeth Swislosky

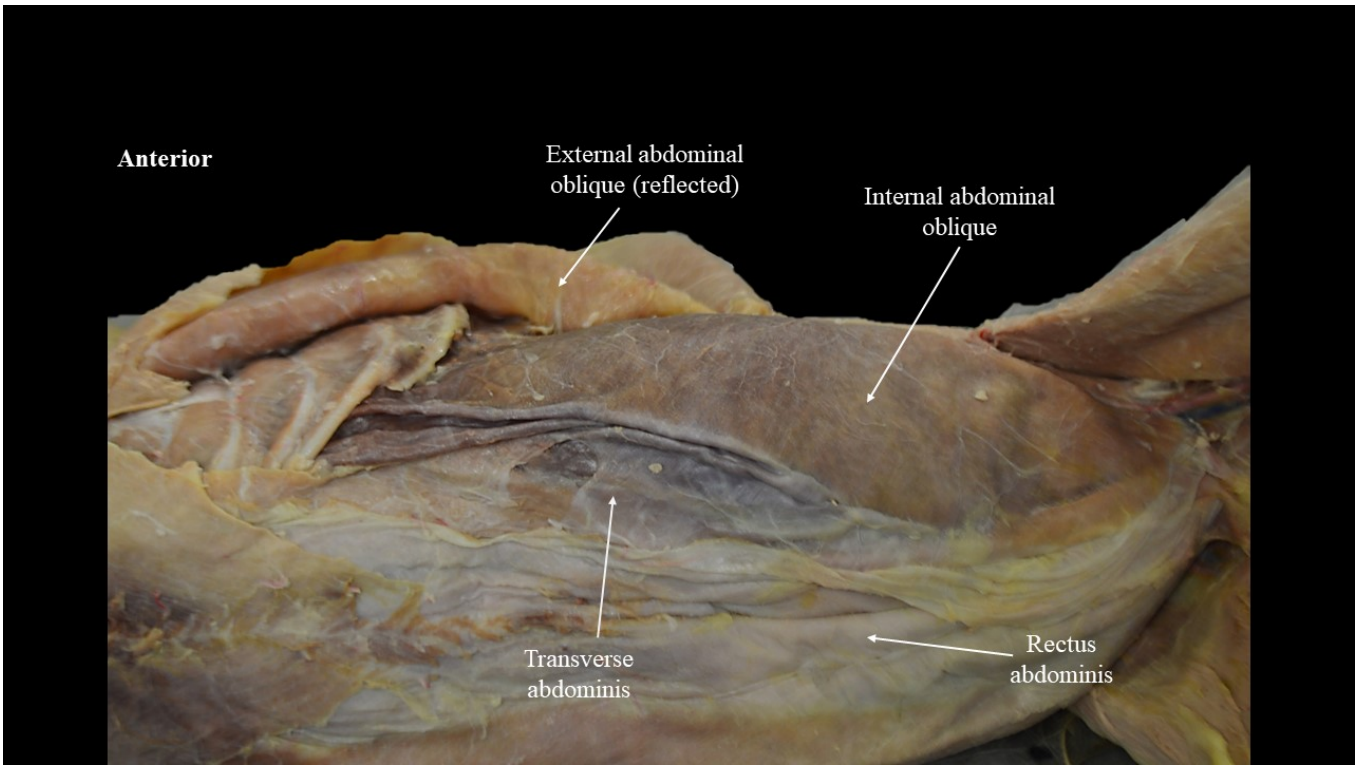

Ventral view of the interior cat abdominal muscles, external abdominal oblique reflected. CC-BY: Elizabeth Swislosky

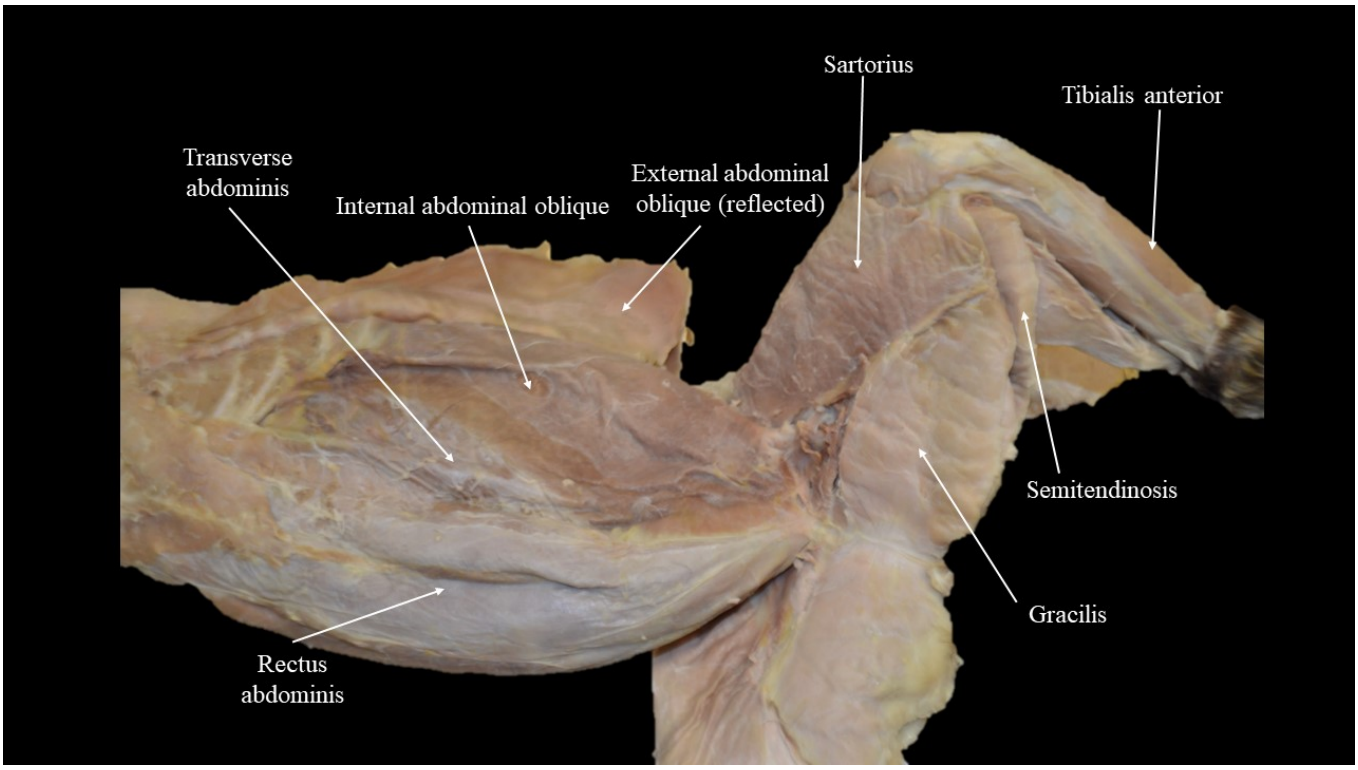

Ventral view of the cat abdominal and hind leg muscles. CC-BY: Elizabeth Swislosky

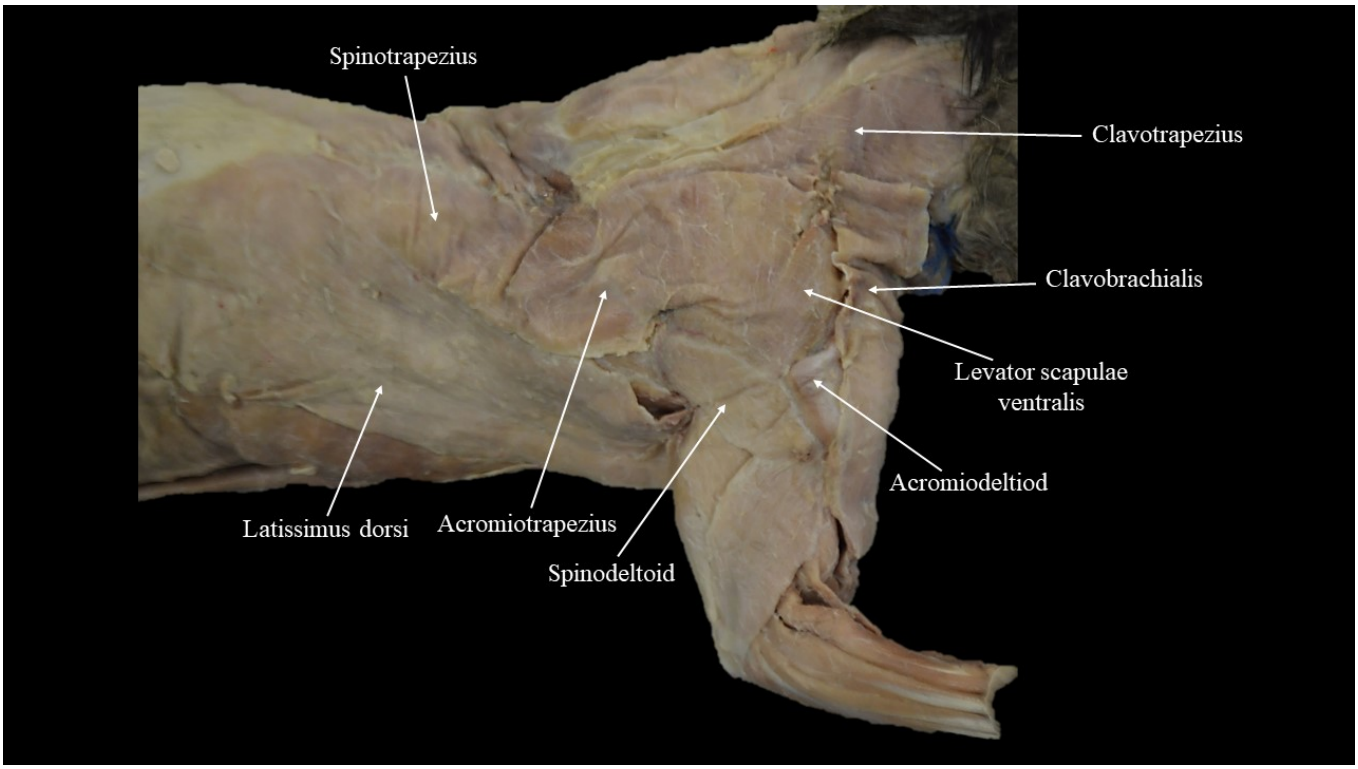

Lateral view of the external cat neck and back muscles. CC-BY: Elizabeth Swislosky

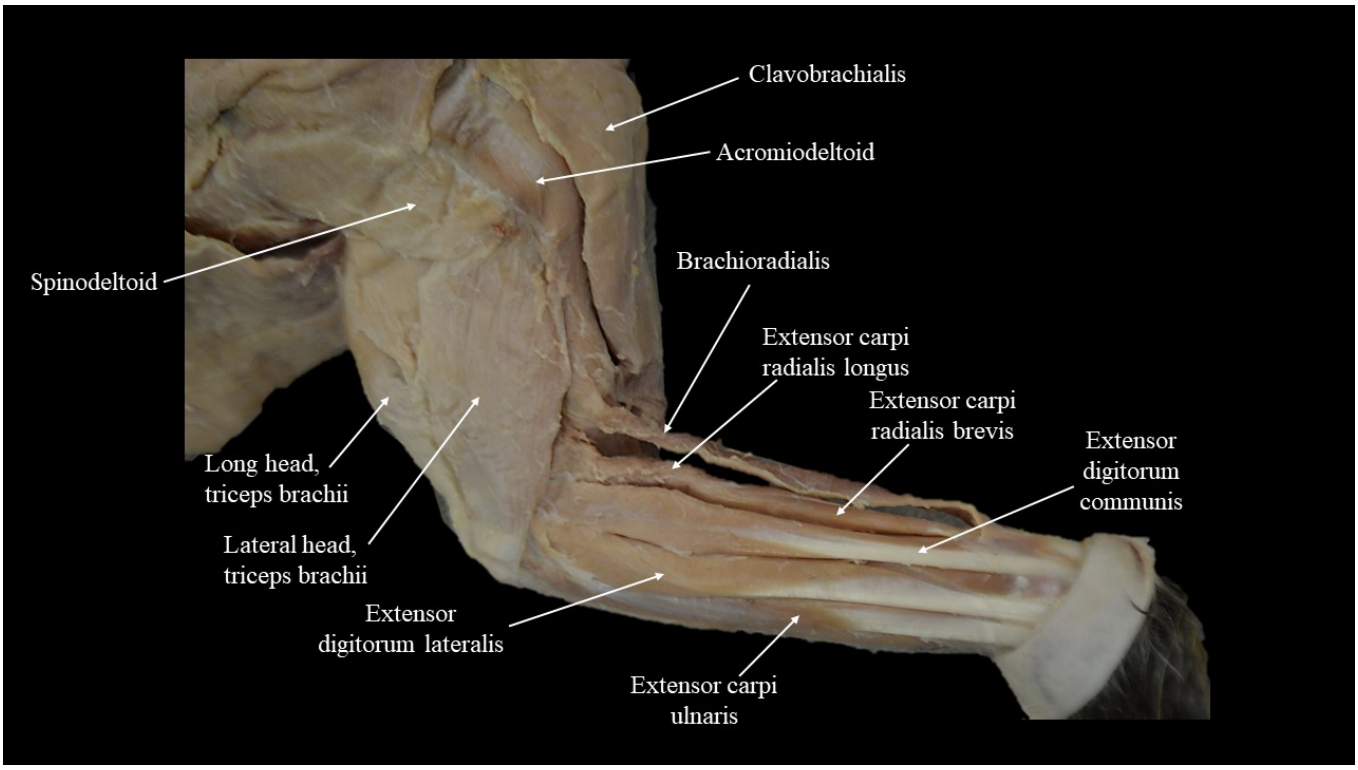

Lateral view of the cat front leg muscles. CC-BY: Elizabeth Swislosky

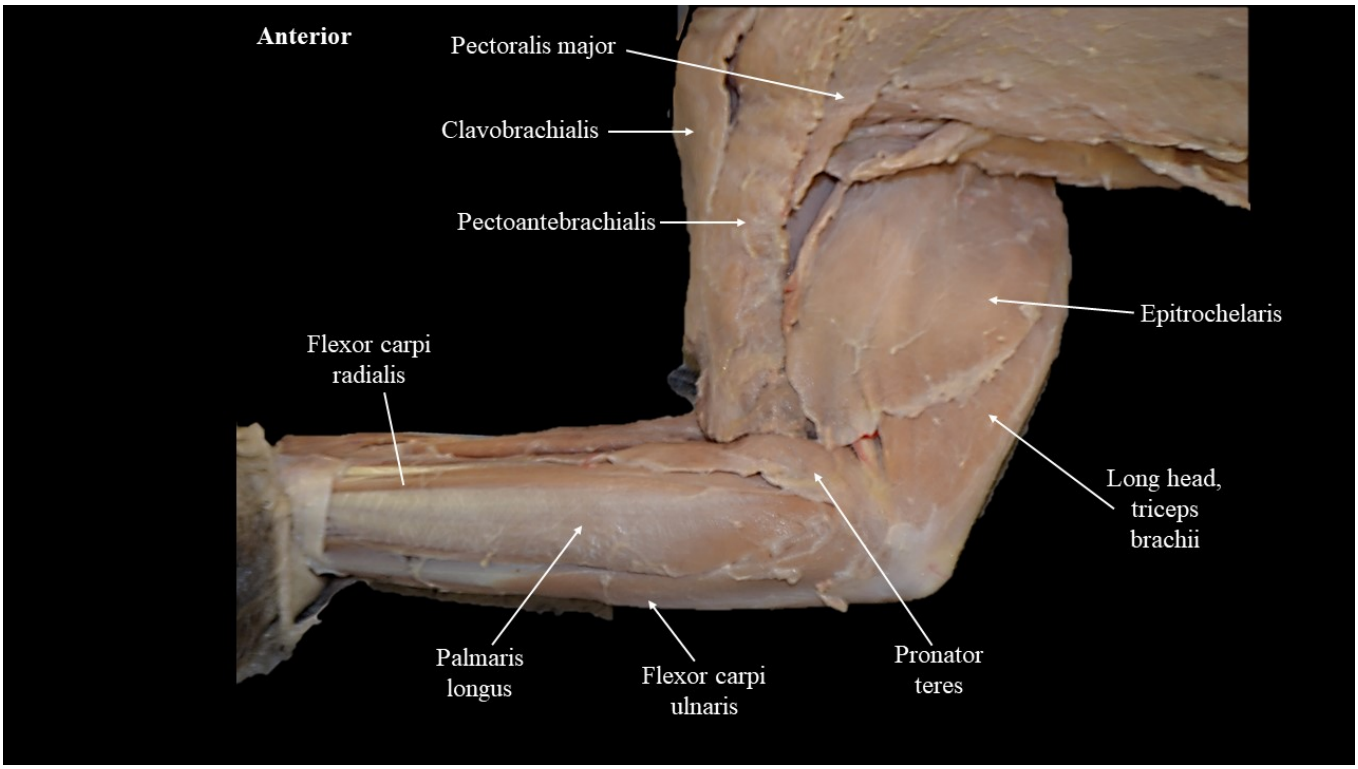

Ventral view of the cat front leg. CC-BY: Elizabeth Swislosky

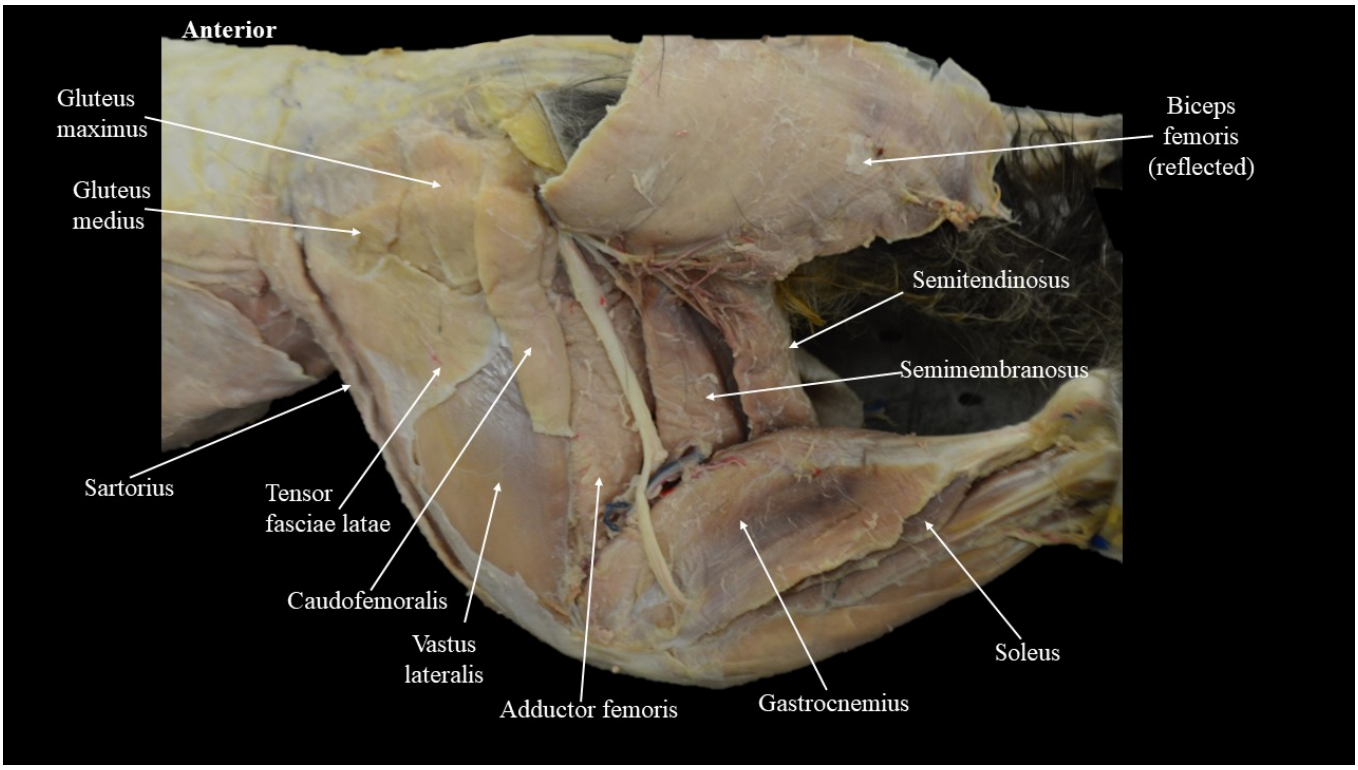

Lateral view of the cat hind leg, bicep femoris reflected. CC-BY: Elizabeth Swislosky

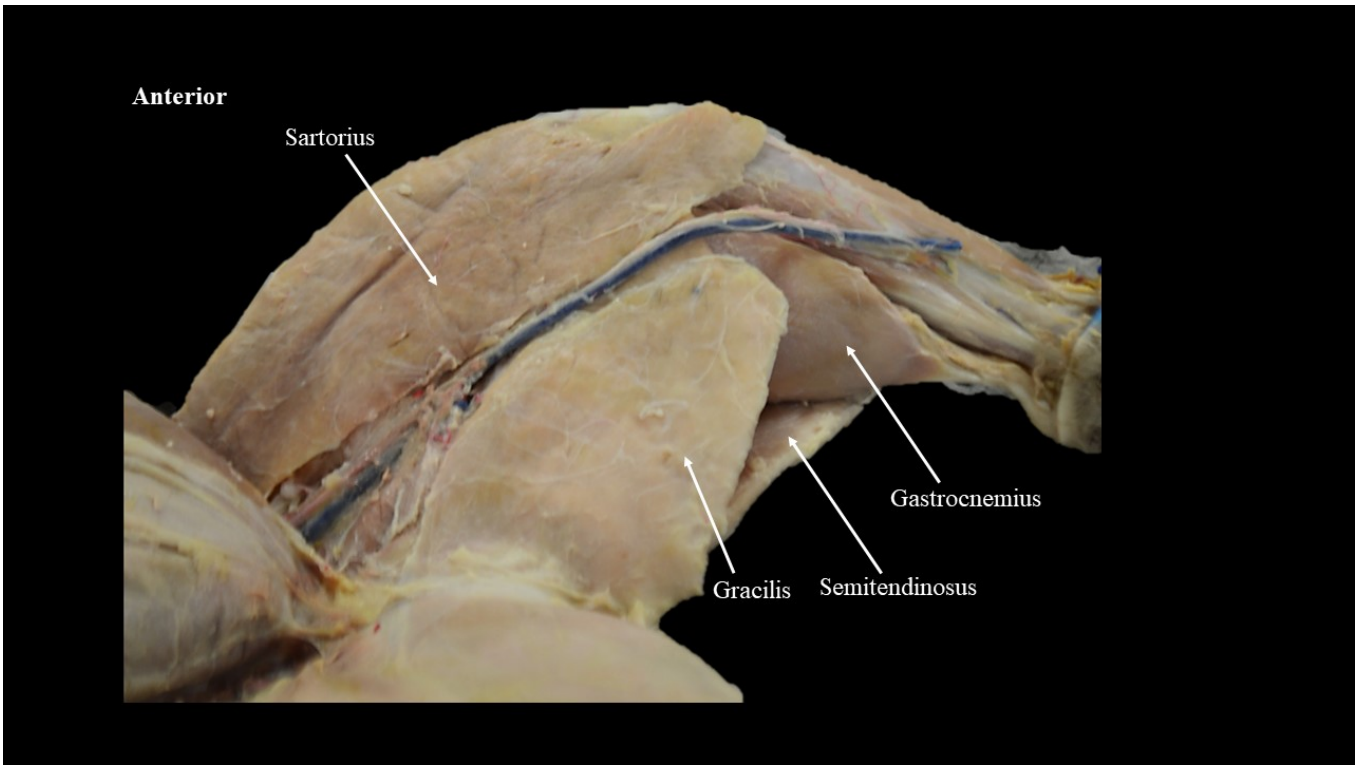

Ventral view of the cat hind leg. CC-BY: Elizabeth Swislosky

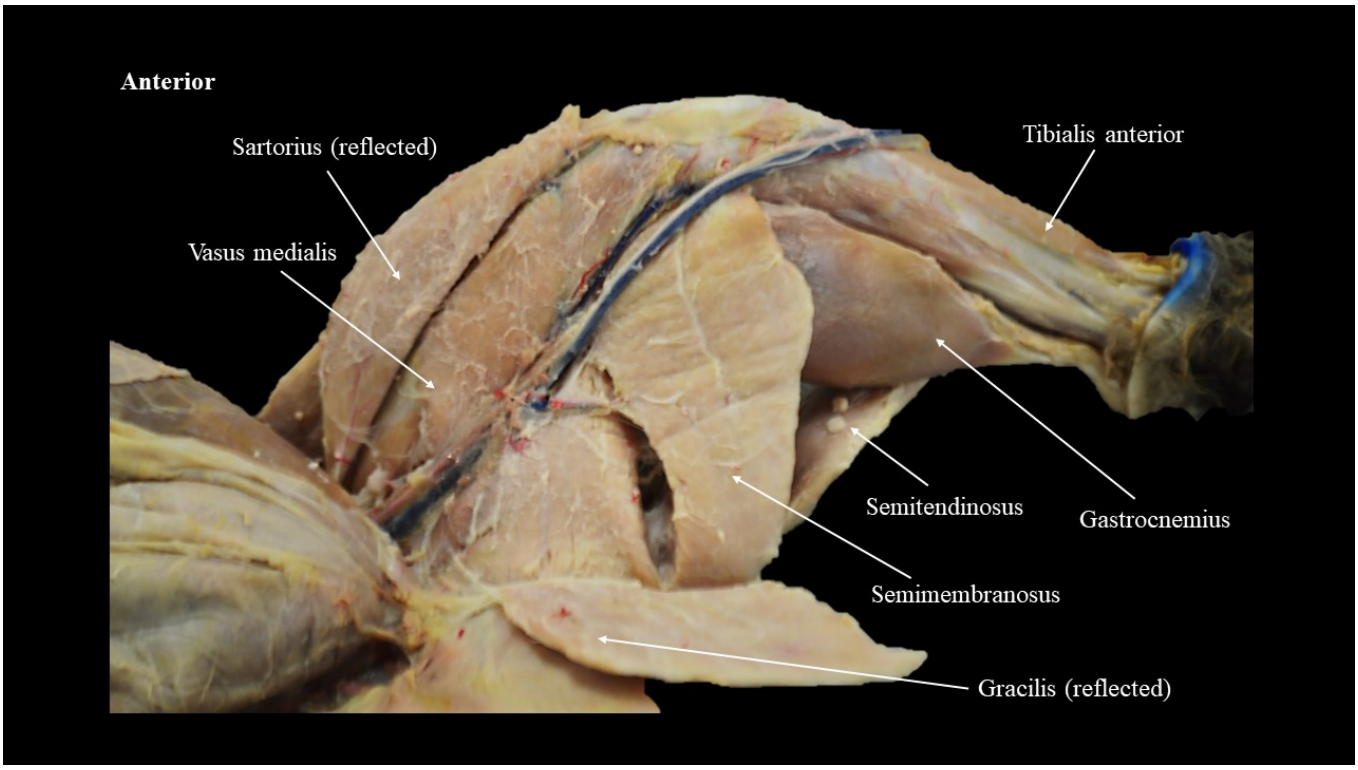

Ventral view of the cat hind leg muscles, gracilis reflected. CC-BY: Elizabeth Swislosky.

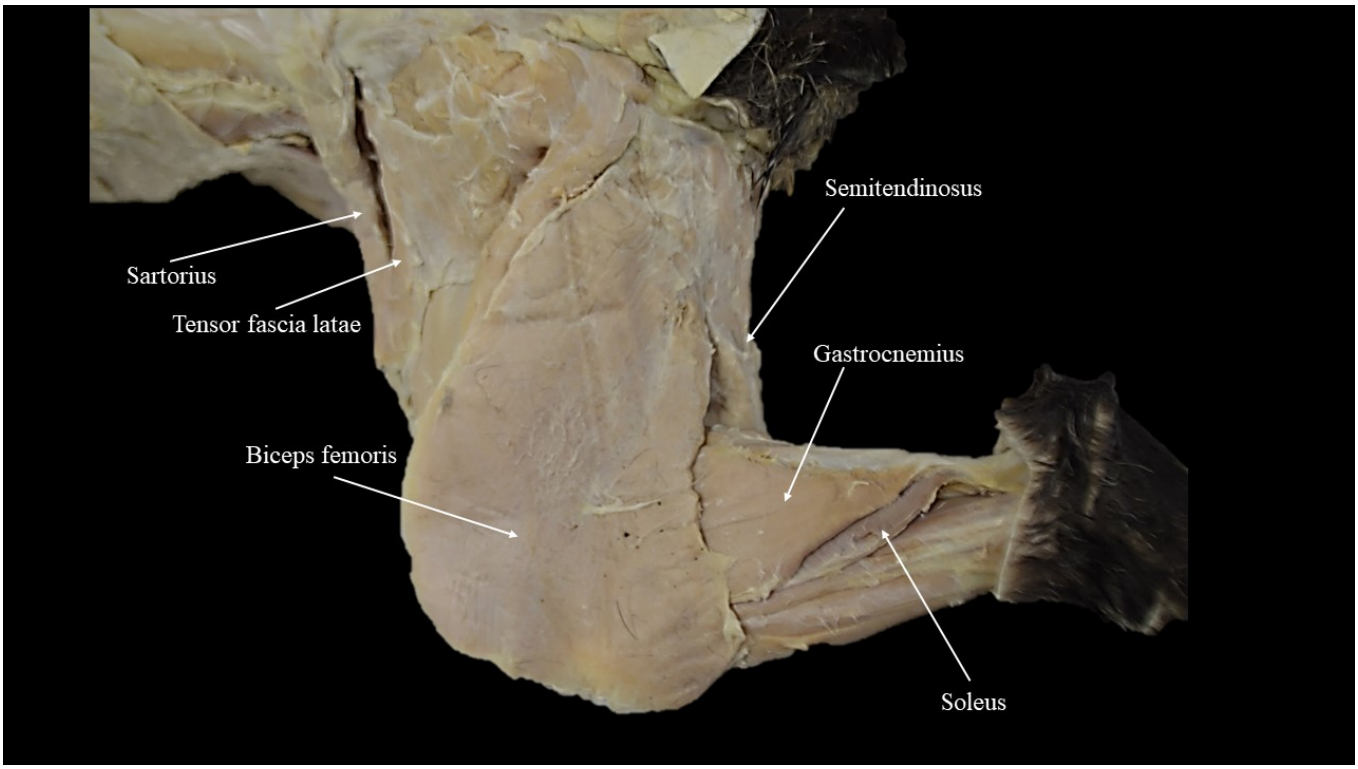

Dorsal view of the superficial musculature of cat hindlimb. CC-BY Kristen Roosa.

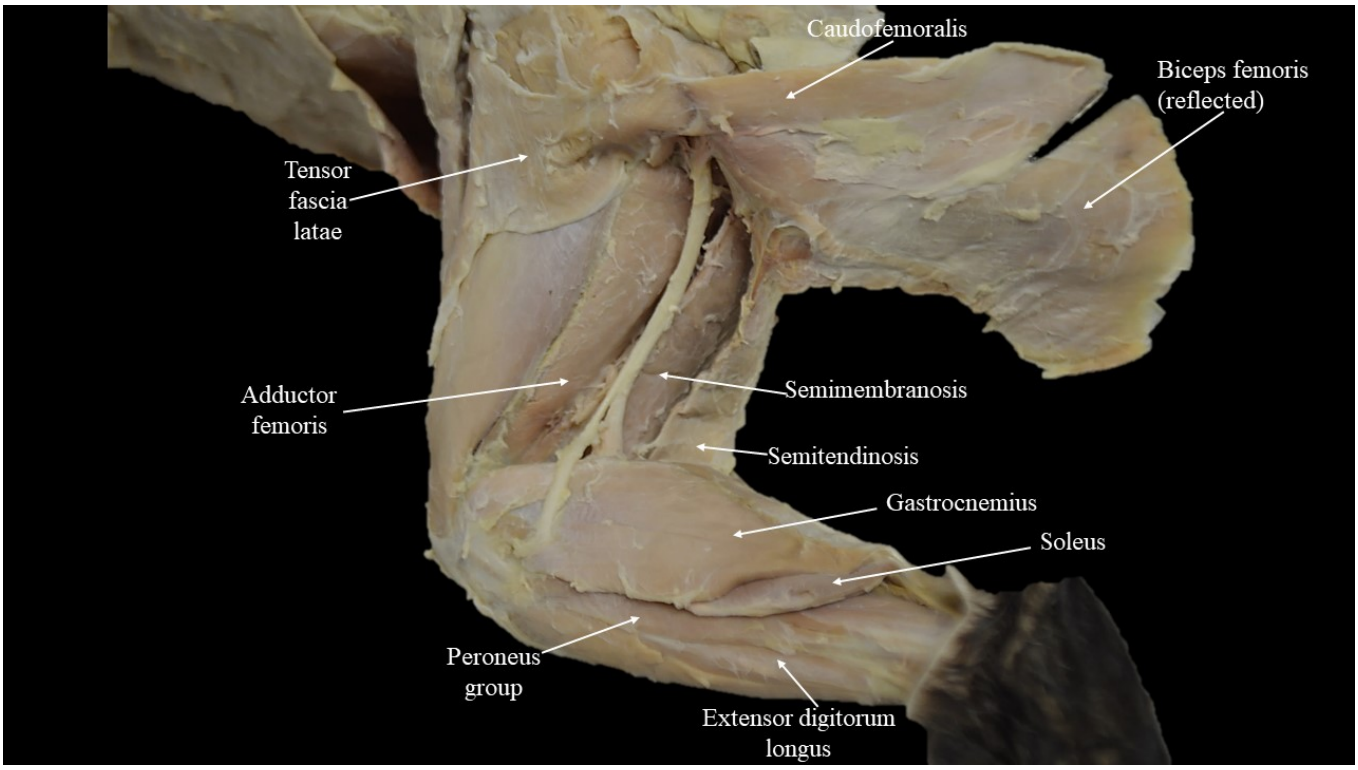

Dorsal view of the deep musculature of the cat hindlimb. CC-BY Kristen Roosa.

Contributors and Attributions

- Cat muscular system. **Authored by**: Kristen Roosa. **License**: *CC BY: Attribution*
- **License**: *CC BY: Attribution*

5.3: Cat Musculature is shared under a CC BY 4.0 license and was authored, remixed, and/or curated by LibreTexts.

CHAPTER OVERVIEW

6: Urogenital systems

6.1: Squalus urogenital systems
6.2: Necturus urogenital systems
6.3: Cat urogenital systems

6: Urogenital systems is shared under a CC BY 4.0 license and was authored, remixed, and/or curated by LibreTexts.

6.1: Squalus urogenital systems

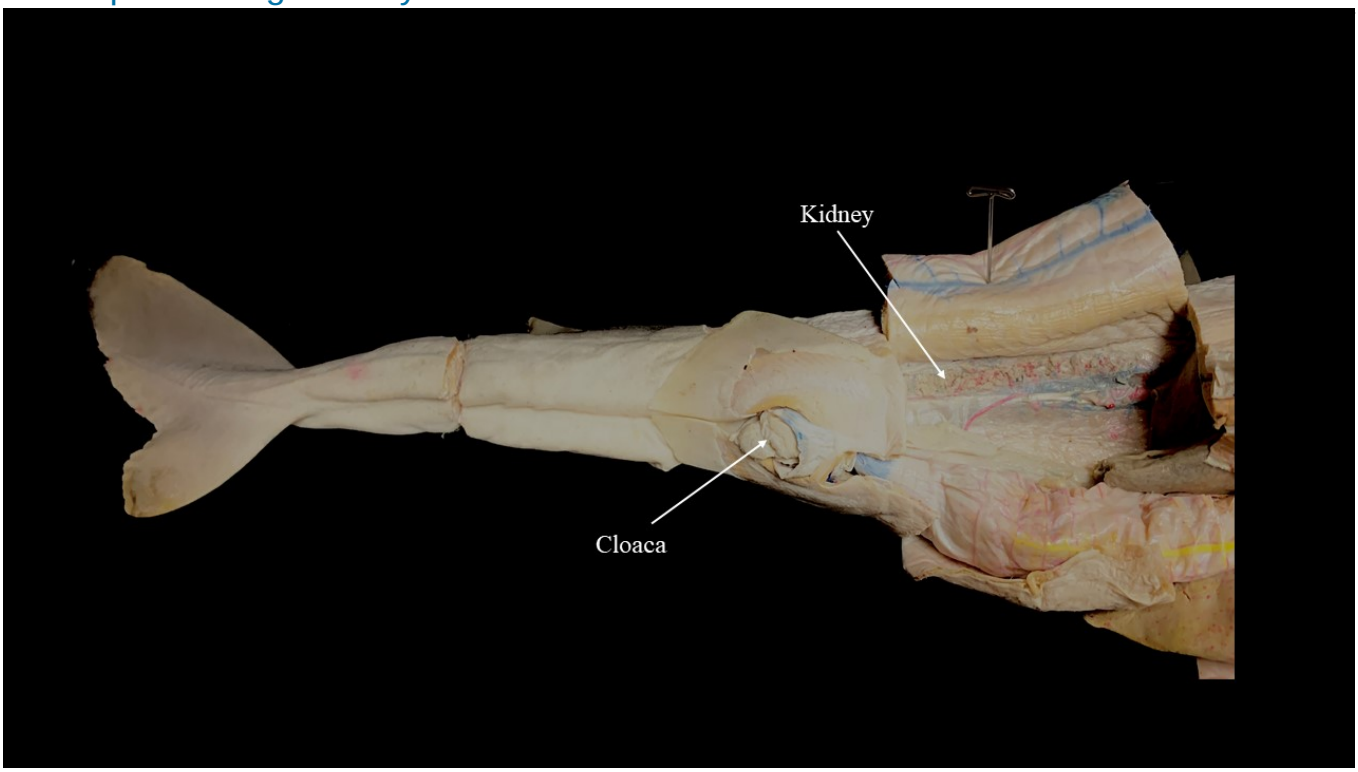

Ventral view of internal and external urogenital organs of the female Dogfish shark, digestive organs removed. CC-BY Destiny Woodson.

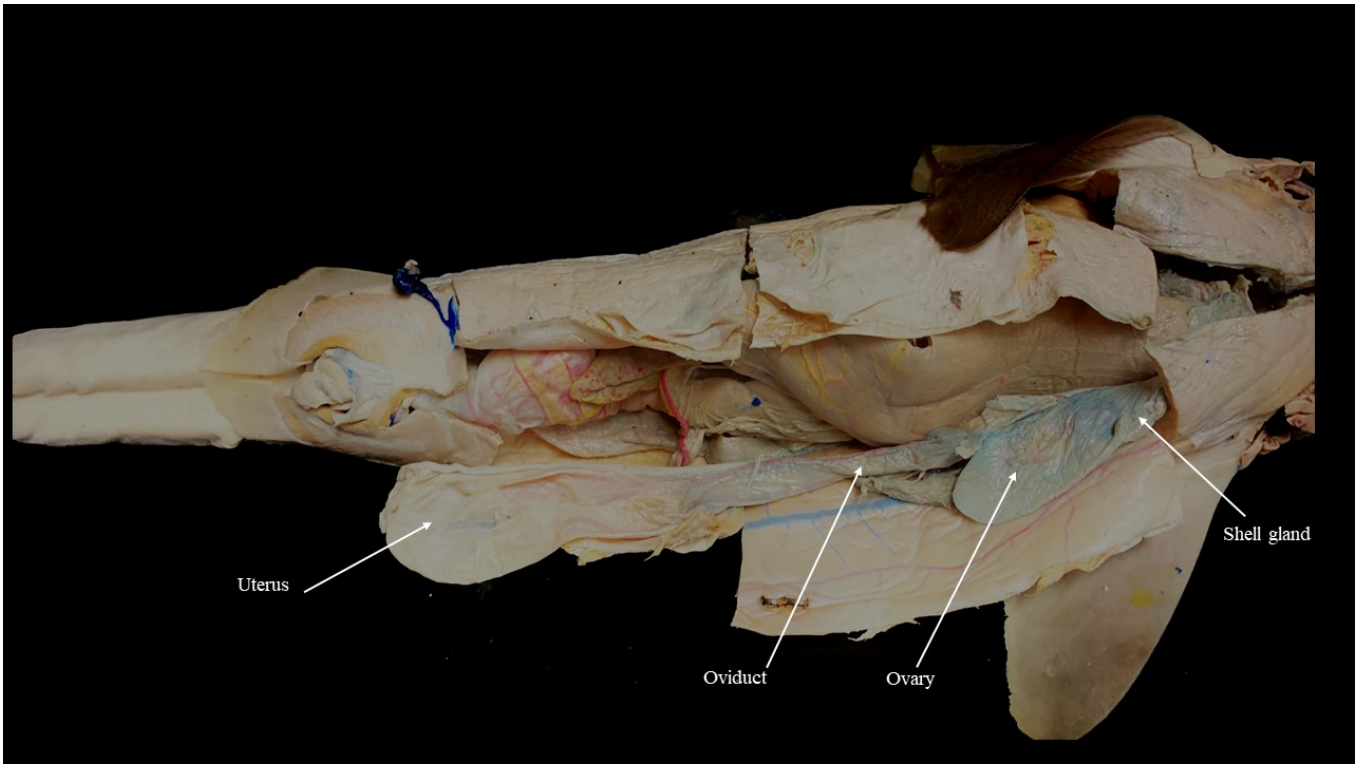

Ventral view of internal urogenital organs of the female Dogfish shark. CC-BY Destiny Woodson.

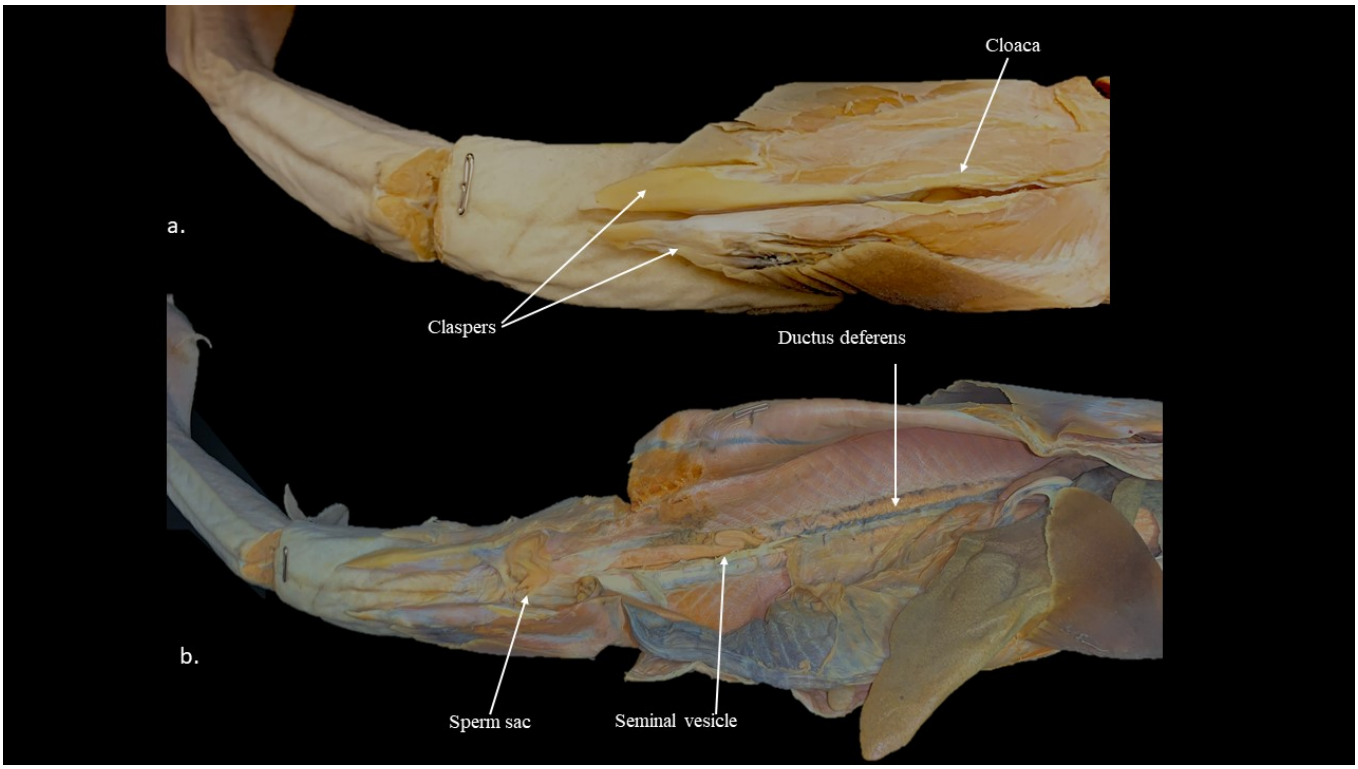

A) Ventral view of male external urogenital organs of Dogfish shark. B) Ventral view of internal urogenital organs of the male Dogfish shark, digestive organs removed. CC-BY Destiny Woodson.

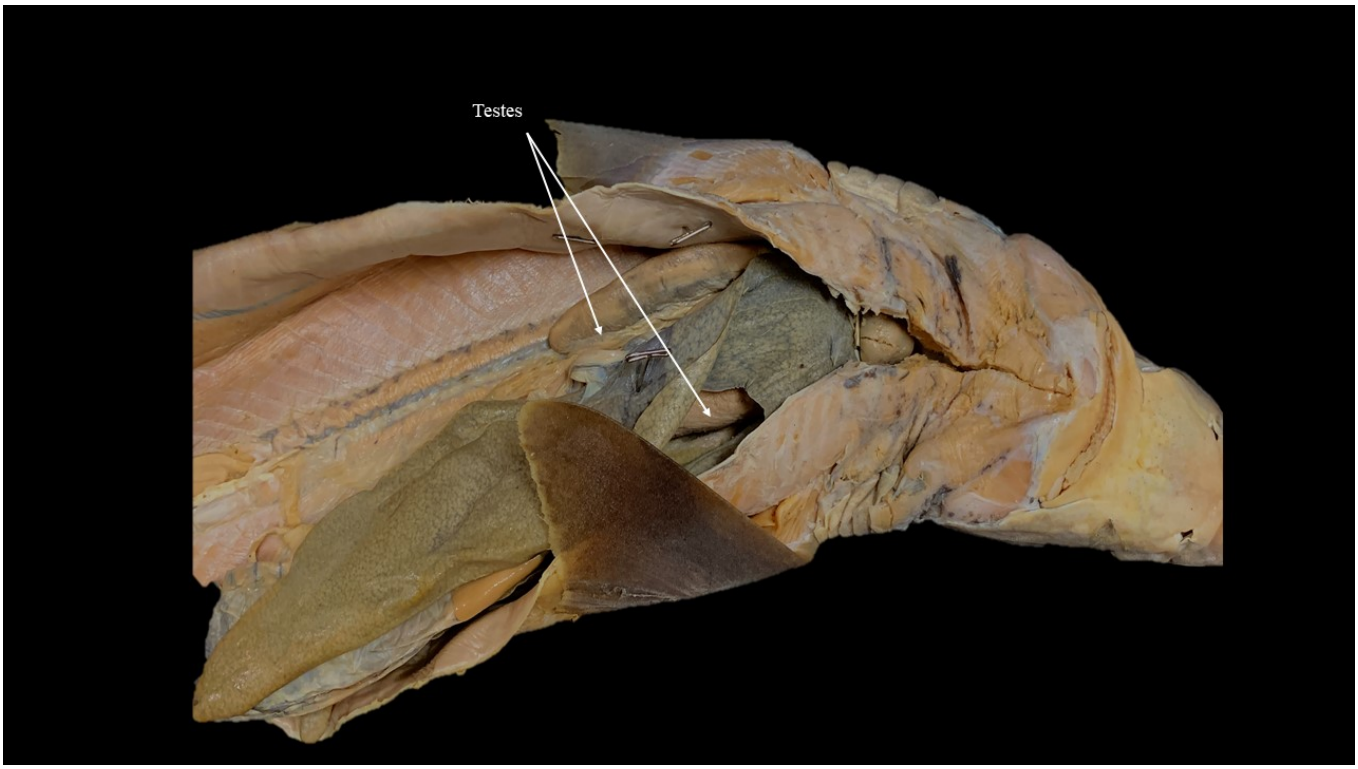

Ventral view of testes of the male Dogfish shark, digestive organs removed. CC-BY Destiny Woodson.

Contributors and Attributions

- Shark reproductive system. **Authored by**: Elizabeth Swislosky. **License**: *CC BY: Attribution*

6.1: Squalus urogenital systems is shared under a CC BY 4.0 license and was authored, remixed, and/or curated by LibreTexts.

6.2: Necturus urogenital systems

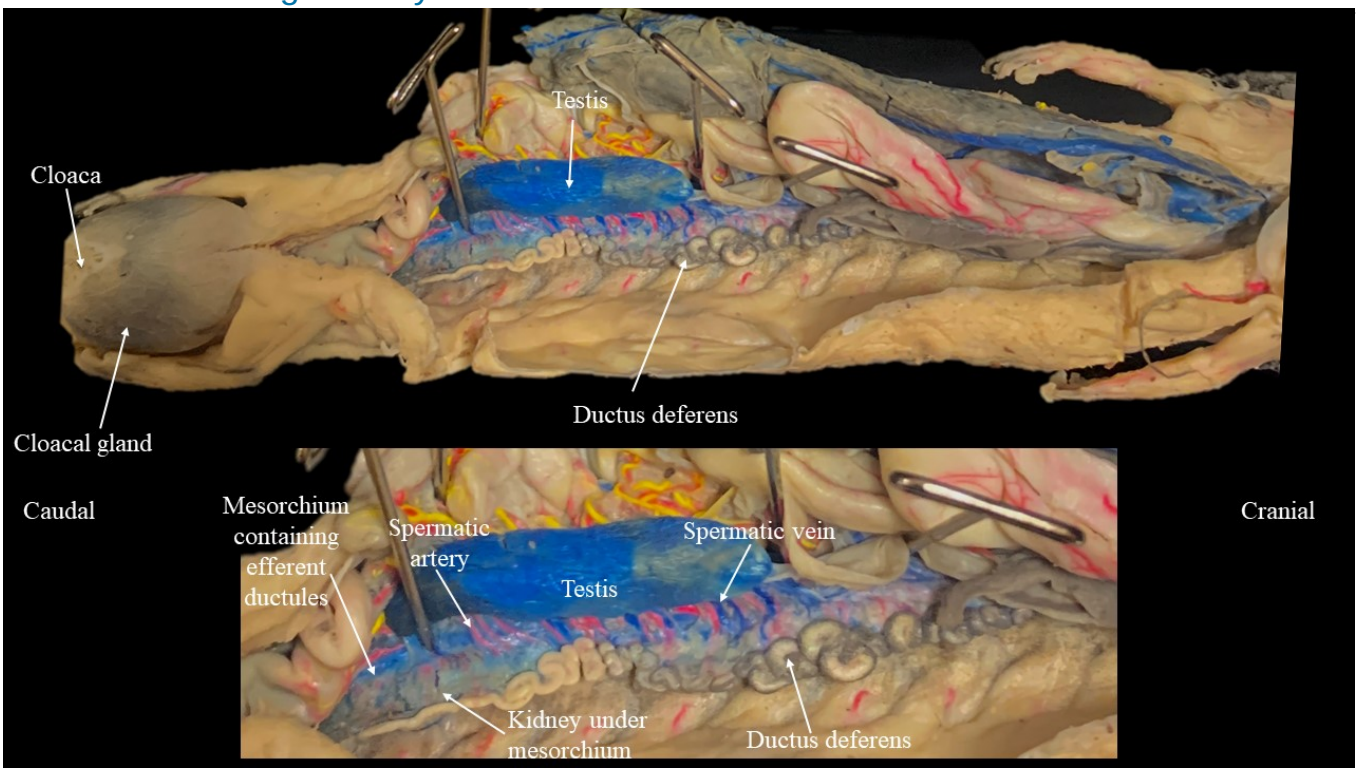

Ventral view of internal reproductive organs of male *Necturus*. CC-BY Destiny Woodson.

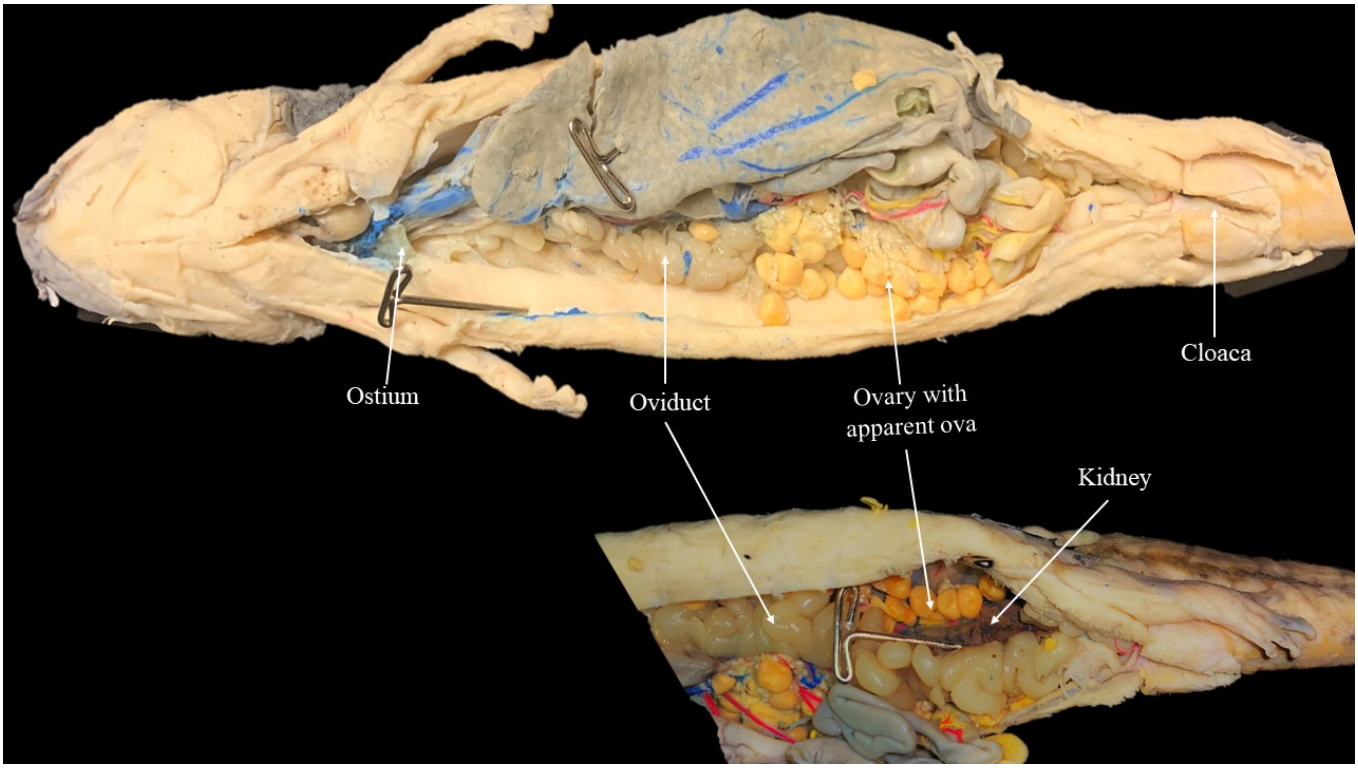

Ventral view of internal urogenital organs of female *Necturus*. CC-BY Destiny Woodson.

6.2: Necturus urogenital systems is shared under a CC BY 4.0 license and was authored, remixed, and/or curated by LibreTexts.

6.3: Cat urogenital systems

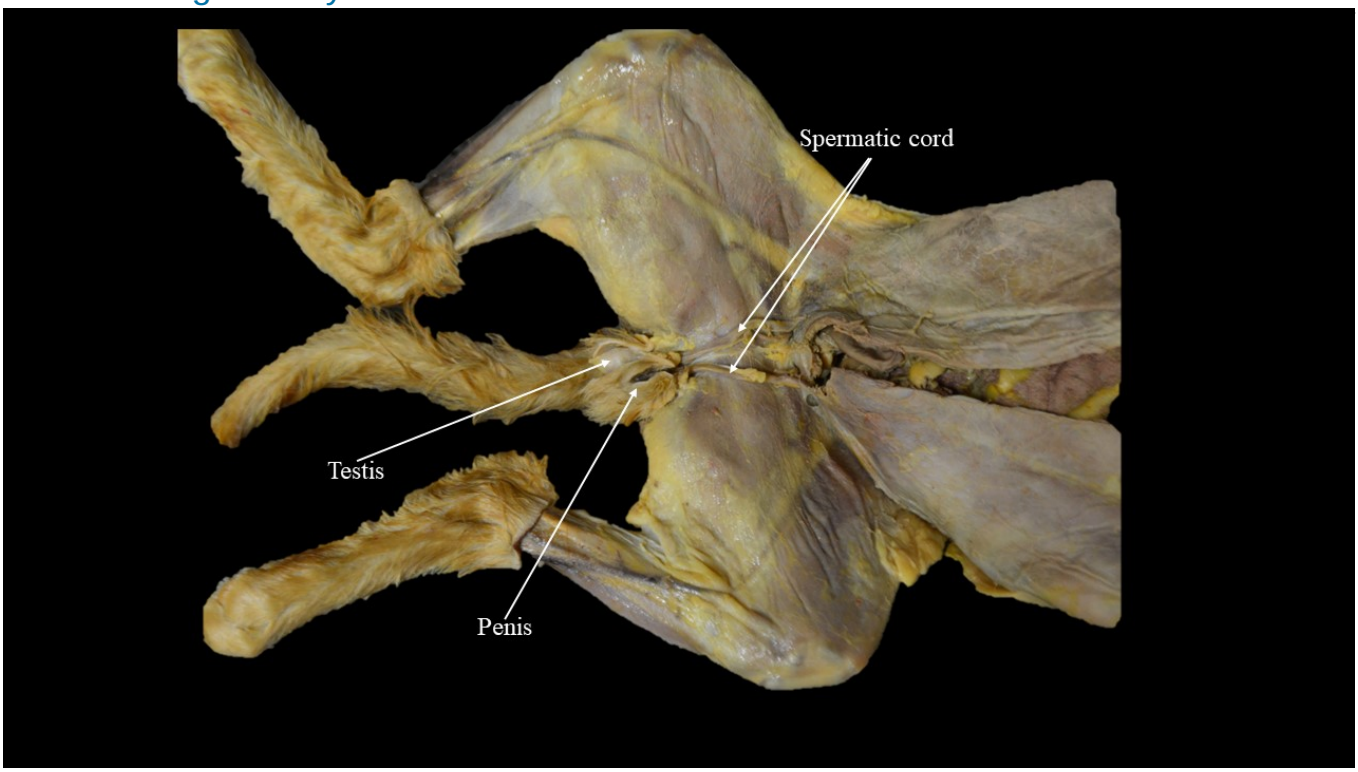

Ventral view of the male cat reproductive system. CC-BY: Elizabeth Swislosky.

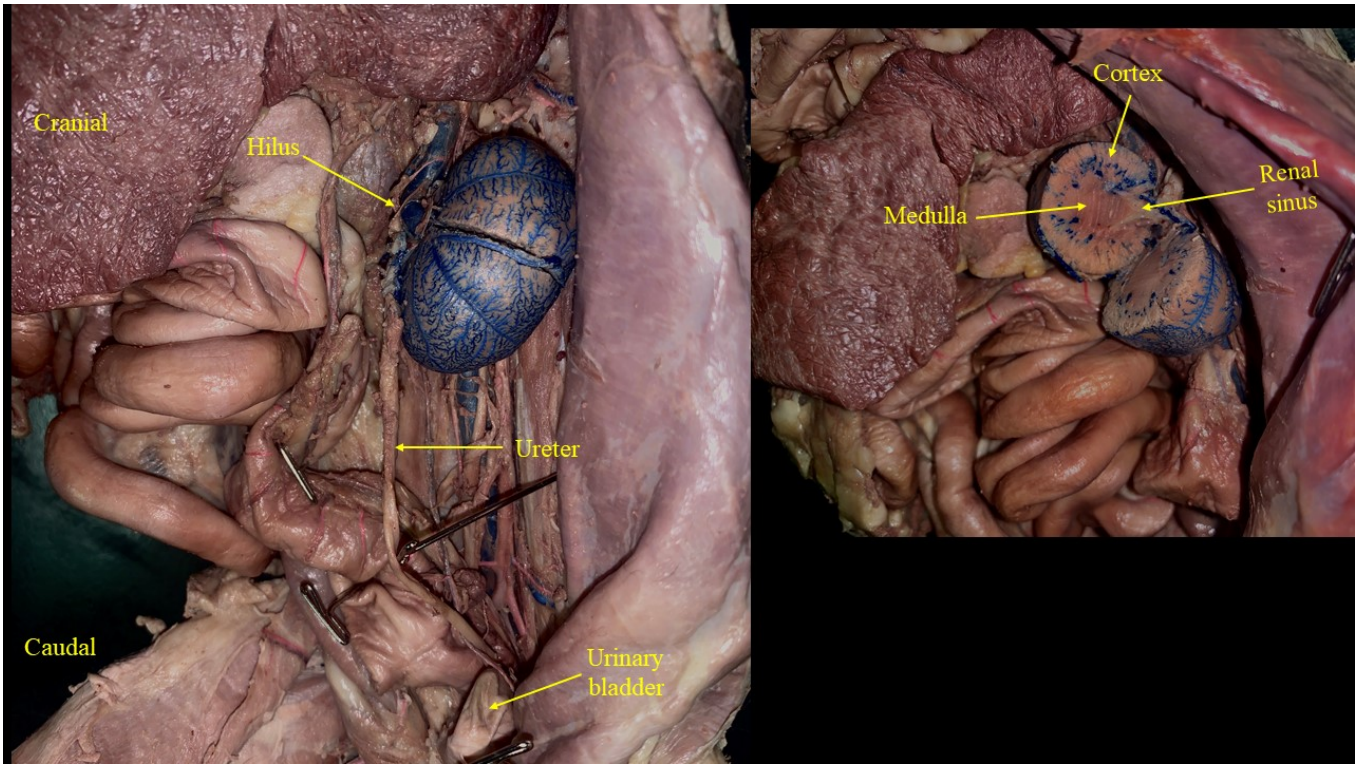

Ventral view of internal urogenital tract of the male cat. CC-BY Destiny Woodson.

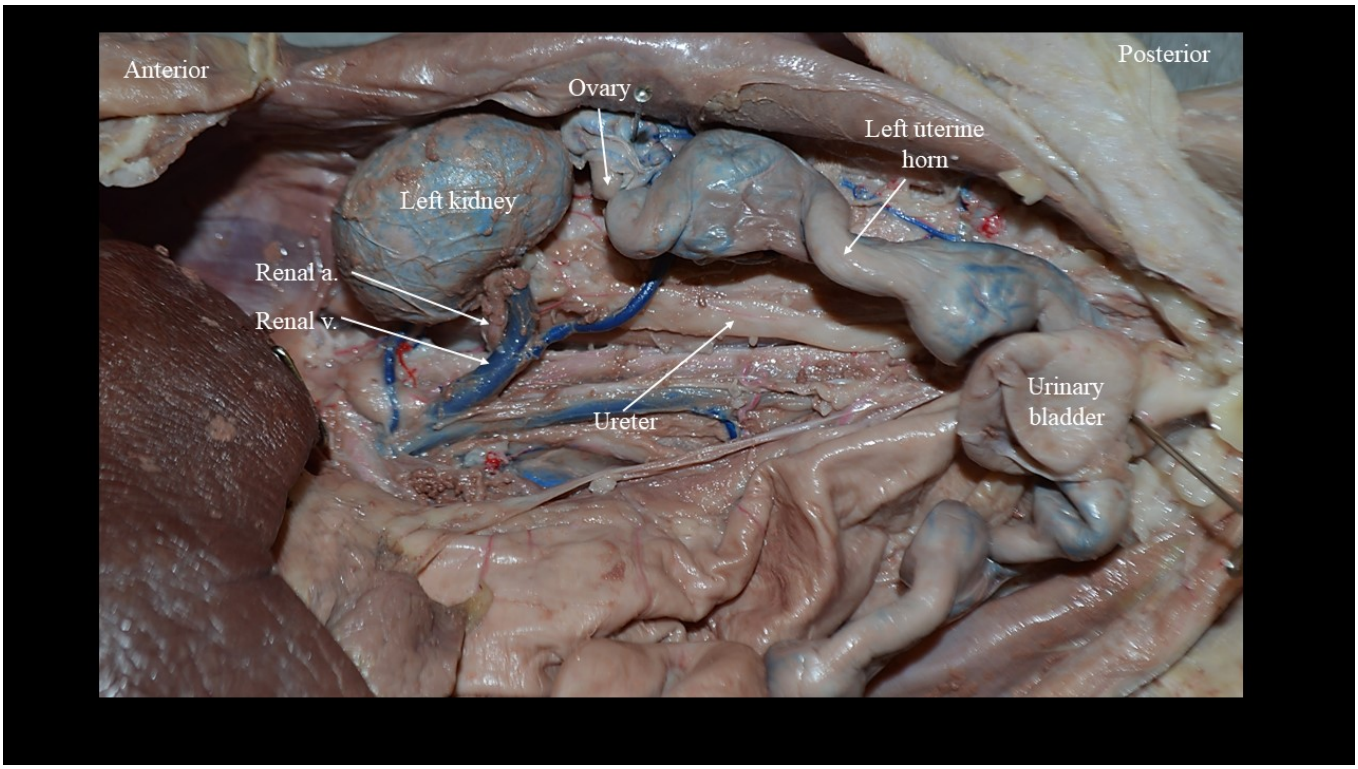

Urogenital organs of the female cat. CC-BY Kristen Roosa.

Contributors and Attributions

- Cat reproductive system. **Authored by**: Elizabeth Swislosky. **License**: *CC BY: Attribution*

6.3: Cat urogenital systems is shared under a CC BY 4.0 license and was authored, remixed, and/or curated by LibreTexts.

CHAPTER OVERVIEW

7: Cardiovascular systems

7.1: Squalus vasculature
7.2: Cat Vasculature

7: Cardiovascular systems is shared under a CC BY 4.0 license and was authored, remixed, and/or curated by LibreTexts.

7.1: Squalus vasculature

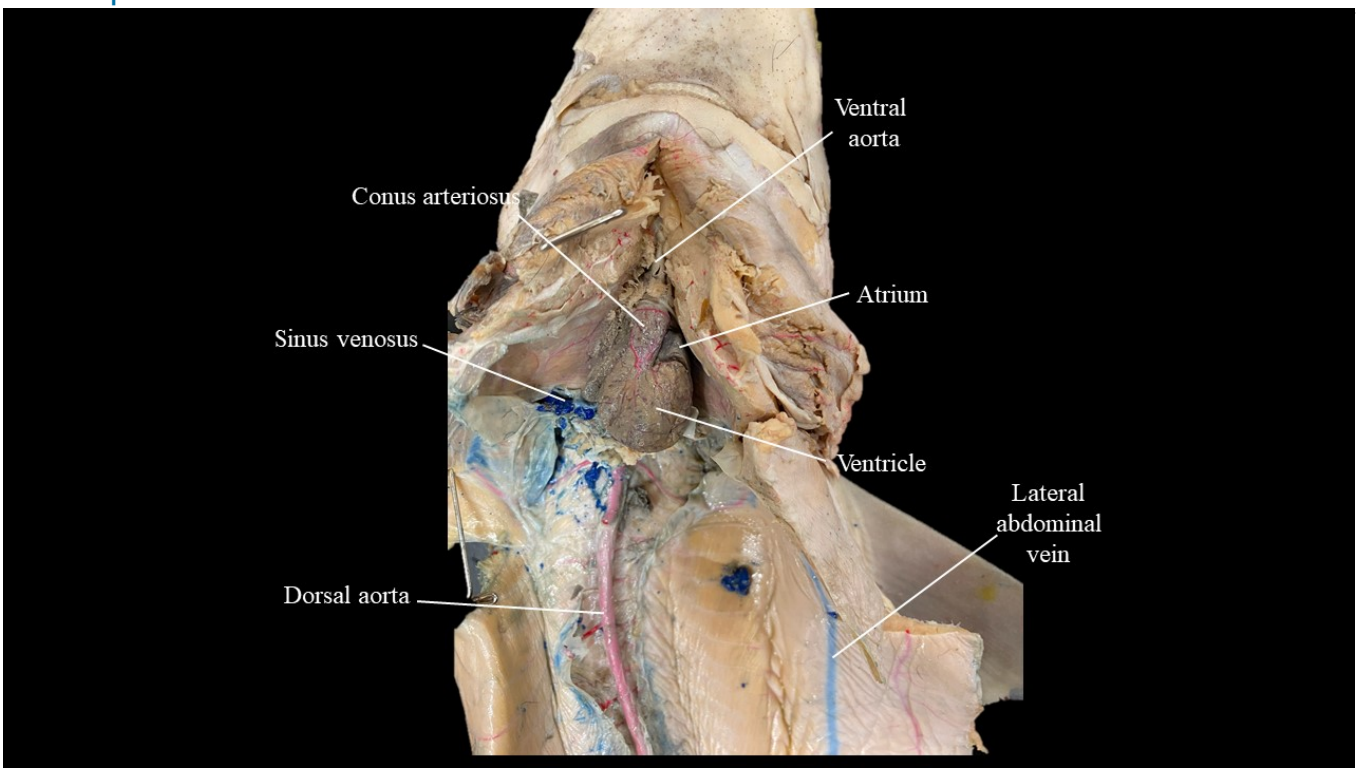

Ventral view of *Squalus* heart and major vessels. digestive organs removed. CC BY Christina Chumpitazi.

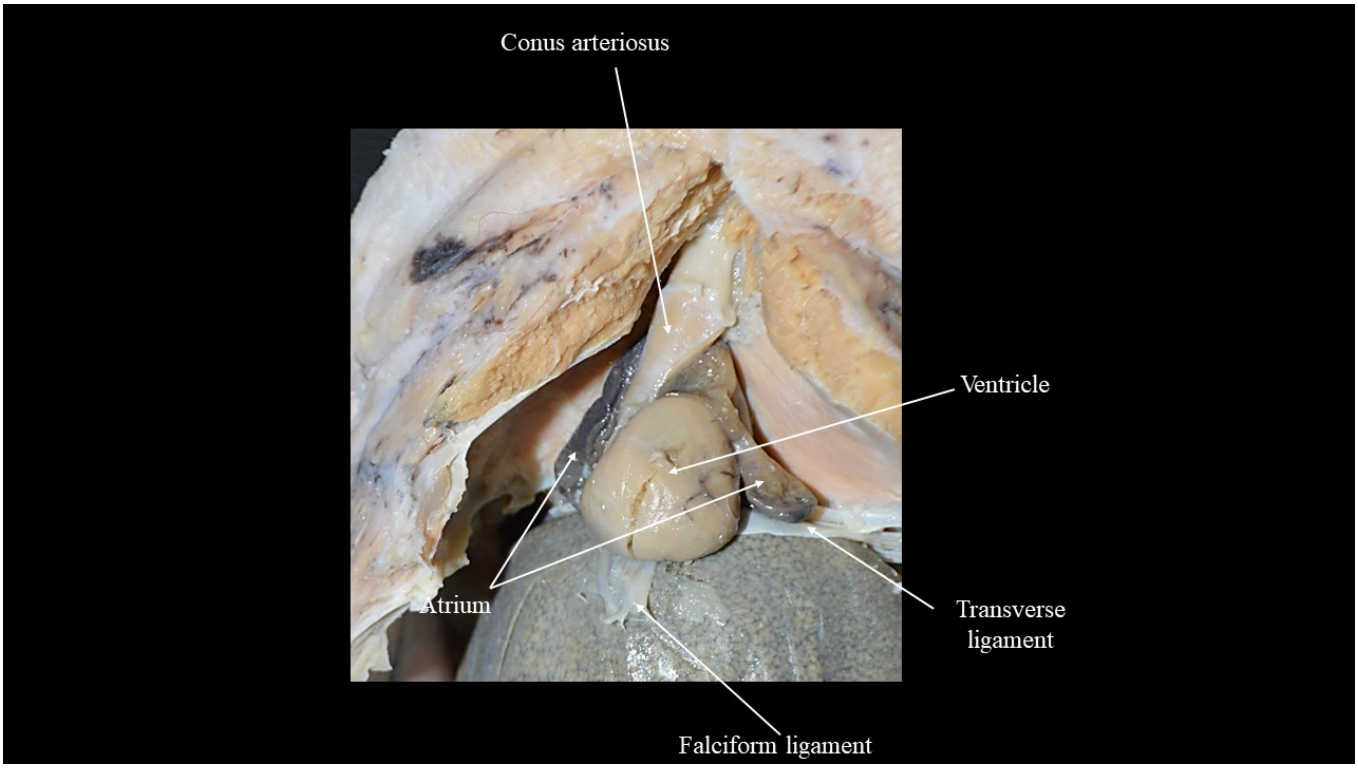

Close up view of *Squalus* heart. CC BY Kristen Roosa.

7.1: Squalus vasculature is shared under a CC BY 4.0 license and was authored, remixed, and/or curated by LibreTexts.

7.2: Cat Vasculature

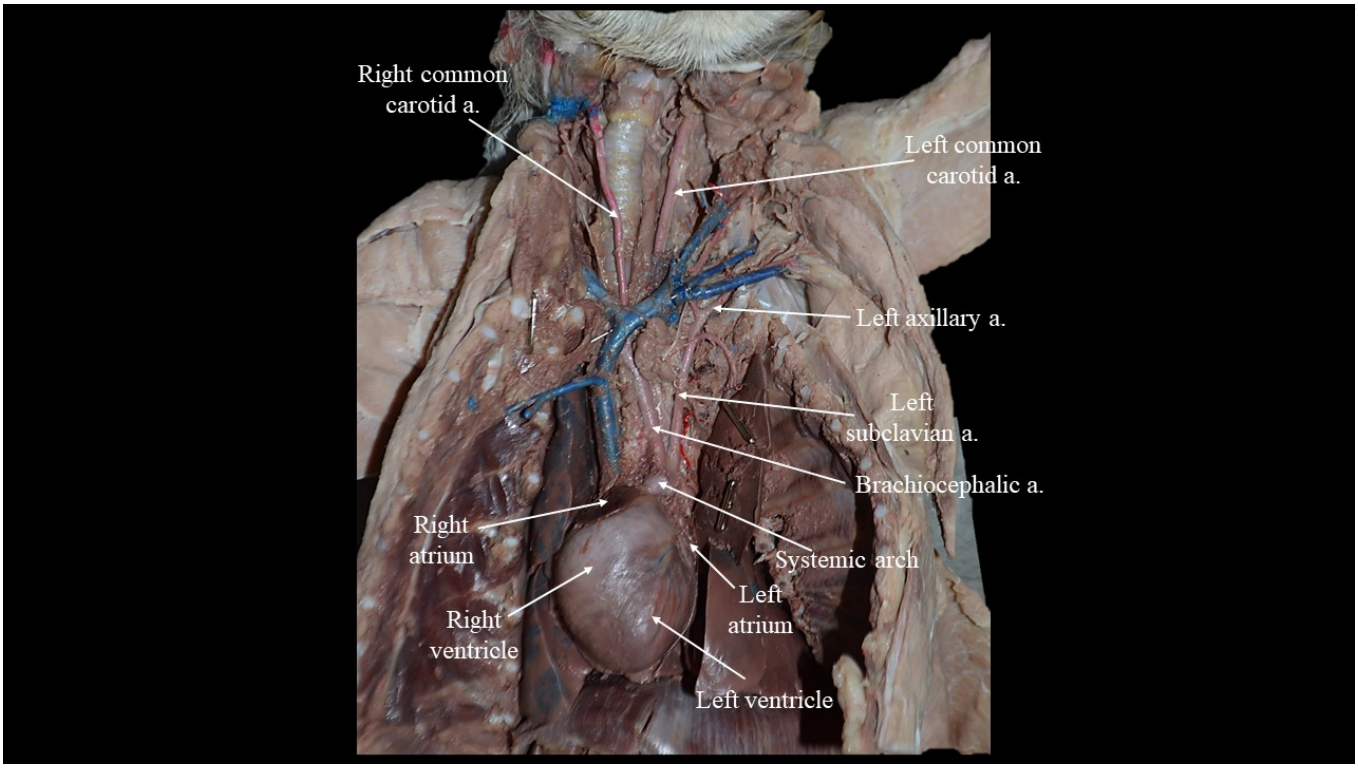

Ventral view of the arteries of the trunk of the cat. CC BY Kristen Roosa.

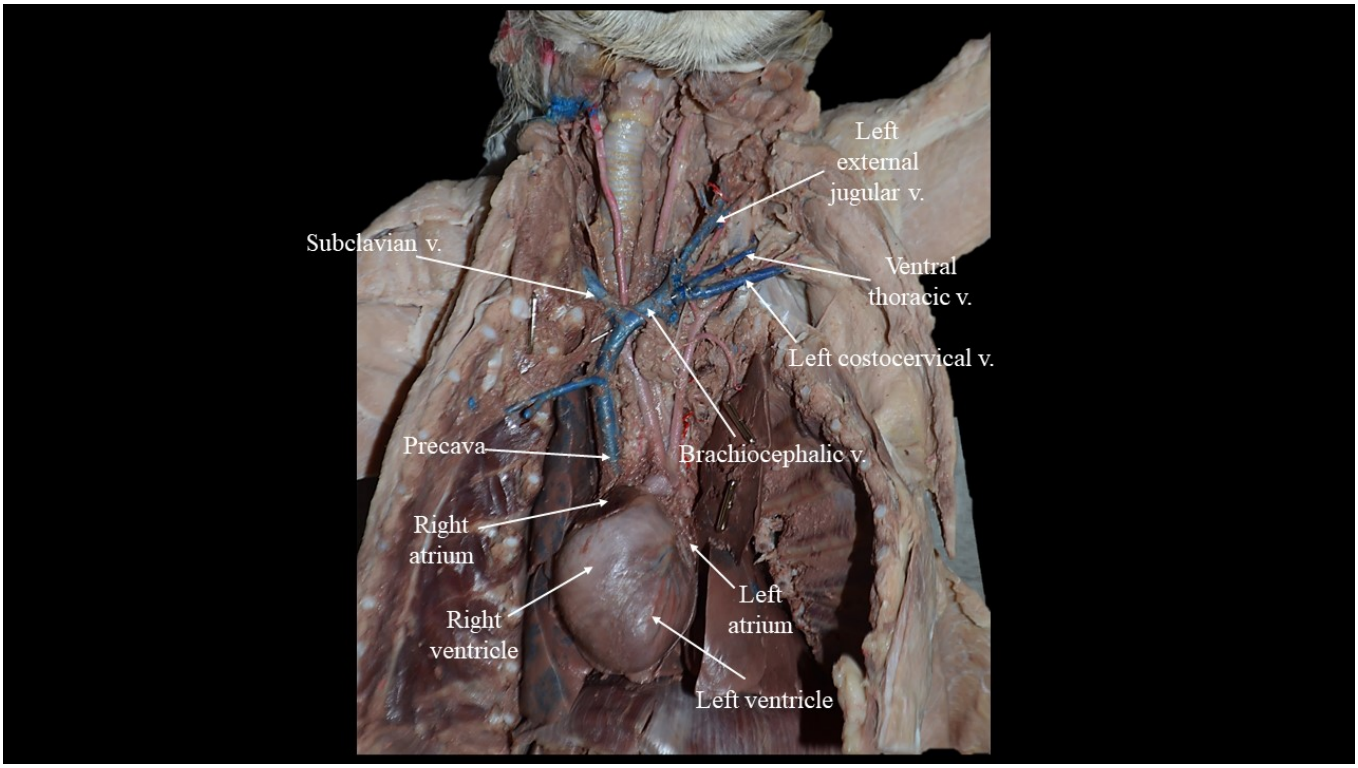

Ventral view of the veins of the trunk of the cat. CC BY Kristen Roosa.

Contributors and Attributions

- Cat vasculature . **Authored by**: Kristen Roosa. **License**: *CC BY: Attribution*

7.2: Cat Vasculature is shared under a CC BY 4.0 license and was authored, remixed, and/or curated by LibreTexts.

Index

D

dire

Glossary

Sample Word 1 | Sample Definition 1

Detailed Licensing

Overview

Title: Atlas of Comparative Vertebrate Anatomy

Webpages: 44

Applicable Restrictions: Noncommercial

All licenses found:

- CC BY 4.0: 93.2% (41 pages)
- CC BY-NC-SA 4.0: 4.5% (2 pages)
- Undeclared: 2.3% (1 page)

By Page

- Atlas of Comparative Vertebrate Anatomy - *CC BY 4.0*
  - Front Matter - *CC BY 4.0*
    - TitlePage - *CC BY 4.0*
    - InfoPage - *CC BY 4.0*
    - Table of Contents - *Undeclared*
    - Licensing - *CC BY-NC-SA 4.0*
  - 1: Lamprey - *CC BY 4.0*
    - 1.1: Larval lamprey - *CC BY 4.0*
    - 1.2: Adult lamprey - *CC BY 4.0*
  - 2: Skeletal systems - *CC BY 4.0*
    - 2.1: Squalus skeleton - *CC BY 4.0*
    - 2.2: Necturus skull - *CC BY 4.0*
    - 2.3: Necturus skeleton - *CC BY 4.0*
    - 2.4: Pigeon skull - *CC BY 4.0*
    - 2.5: Pigeon skeleton - *CC BY 4.0*
    - 2.6: Turtle skull - *CC BY 4.0*
    - 2.7: Turtle skeleton - *CC BY 4.0*
    - 2.8: Cat skeleton- overview - *CC BY 4.0*
    - 2.9: Cat skull - *CC BY 4.0*
    - 2.10: Cat vertebral column - *CC BY 4.0*
    - 2.11: Cat scapula and ribs - *CC BY 4.0*
    - 2.12: Cat limbs - *CC BY 4.0*
  - 3: Nervous systems - *CC BY 4.0*
    - 3.1: Squalus brain - *CC BY 4.0*
    - 3.2: Sheep brain - *CC BY 4.0*
  - 4: Digestive systems - *CC BY 4.0*
    - 4.1: Squalus digestive system - *CC BY 4.0*
    - 4.2: Necturus digestive system - *CC BY 4.0*
    - 4.3: Cat digestive system - *CC BY 4.0*
  - 5: Muscular systems - *CC BY 4.0*
    - 5.1: Squalus musculature - *CC BY 4.0*
    - 5.2: Necturus musculature - *CC BY 4.0*
    - 5.3: Cat Musculature - *CC BY 4.0*
  - 6: Urogenital systems - *CC BY 4.0*
    - 6.1: Squalus urogenital systems - *CC BY 4.0*
    - 6.2: Necturus urogenital systems - *CC BY 4.0*
    - 6.3: Cat urogenital systems - *CC BY 4.0*
  - 7: Cardiovascular systems - *CC BY 4.0*
    - 7.1: Squalus vasculature - *CC BY 4.0*
    - 7.2: Cat Vasculature - *CC BY 4.0*
  - Back Matter - *CC BY 4.0*
    - Index - *CC BY 4.0*
    - Glossary - *CC BY 4.0*
    - Detailed Licensing - *CC BY-NC-SA 4.0*